



## Preimplantation genetic diagnosis for retinoblastoma predisposition

Seema Dhanjal, Georgia Kakourou, Thalia Mamas, Natasha Saleh, Alpesh Doshi, Sarah Gotts, Sarah Nuttall, Karen Fordham, Paul Serhal, Joy Delhanty, Joyce Harper and Sioban SenGupta

*Br. J. Ophthalmol.* 2007;91;1090-1091  
doi:10.1136/bjo.2006.108597

---

Updated information and services can be found at:  
<http://bjournal.bmj.com/cgi/content/full/91/8/1090>

---

*These include:*

### References

This article cites 8 articles, 2 of which can be accessed free at:  
<http://bjournal.bmj.com/cgi/content/full/91/8/1090#BIBL>

### Rapid responses

You can respond to this article at:  
<http://bjournal.bmj.com/cgi/eletter-submit/91/8/1090>

### Email alerting service

Receive free email alerts when new articles cite this article - sign up in the box at the top right corner of the article

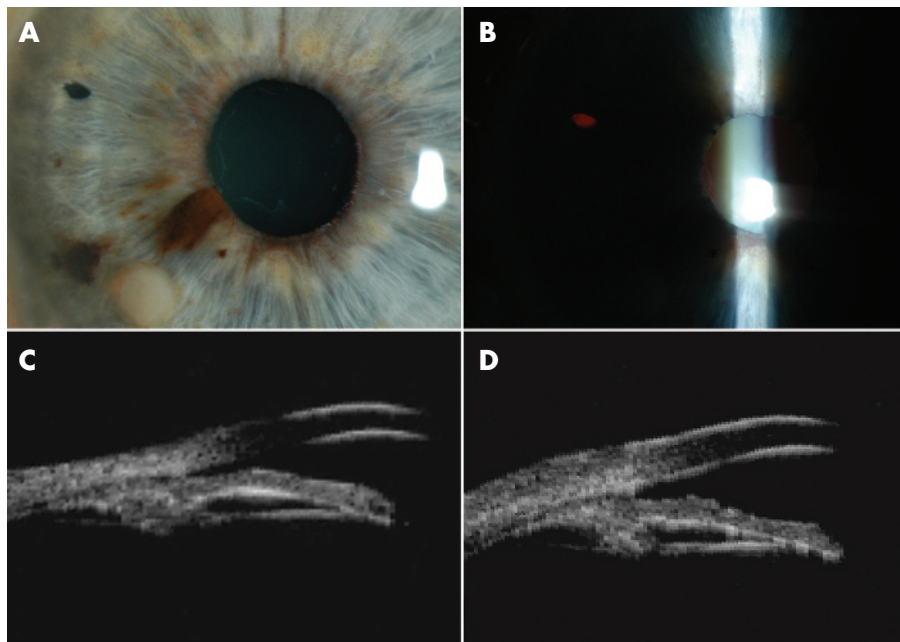
---

### Notes

---

To order reprints of this article go to:  
<http://journals.bmj.com/cgi/reprintform>

To subscribe to *British Journal of Ophthalmology* go to:  
<http://journals.bmj.com/subscriptions/>



**Figure 1** (A) A slit-lamp photograph of the Finger iridectomy technique (FIT) result. Also note the complex melanotic and amelanotic iris melanoma in the inferonasal quadrant. (B) Transillumination through the superonasal iridotomy demonstrates its patency. (C) A 35 MHz high-frequency B-scan ultrasonography (ultrasound biomicroscopy) prior to FIT iridotomy demonstrates a severely narrowed anterior chamber angle (before small-incision surgical iridotomy for glaucoma). (D) At 3 weeks after successful FIT iridotomy, the anterior chamber angle has widened.

Centre, New York City, New York, USA). Ophthalmic examination included a 35 MHz high-frequency ultrasound (ultrasound biomicroscopy) in movie mode. Both her narrow angles and tumour were evaluated (fig 1).

### Methods of procedure

This study conformed to the tenets of the Declaration of Helsinki<sup>2</sup> and the Health Insurance Portability and Accountability Act of 1996.<sup>3</sup> The Finger iridectomy technique (FIT) was performed for glaucoma immediately after an FIT the iris tumour biopsy was found positive for melanoma.<sup>4</sup> A 0.3 forceps was used to stabilise the eye at the limbus. A 25-gauge trochar was used to create an incision through clear juxta-limbal cornea into the anterior chamber. The first incision was made on the same side as the tumour to avoid the pupil and lens. Acetylcholine chloride 10 mg/ml was introduced to induce miosis, then sodium hyaluronate 1% was filled to maintain the anterior chamber.

For iridectomy, a second 25-gauge incision was made in the superotemporal cornea.<sup>5</sup>

Using sodium hyaluronate 1%, the aspiration cutter was inserted and the port rotated for occlusion by the superonasal iris stroma. Aspiration cutting (suction of 300 mm Hg and cutting rate of 600 cuts/min) was used to perform a single full-thickness superonasal iridectomy (fig 1). Once engaged with iris tissue, aspiration, cutting and full-thickness iridectomy are almost instantaneous. At the end of surgery, the sodium hyaluronate 1% was removed, and peribulbar antibiotic-steroid and topical ocular hypotensive agents were used. No adverse side effects were noted.

At 3 weeks after iridectomy, slit-lamp photography and high-frequency ultrasound were used to document the patient's patent iridectomy and deepening of her anterior chamber

(fig 1) Her intraocular pressure decreased by 5 mm Hg (off medications).

### Comment

A review of the literature shows that relatively large aspiration cutters have been used to perform iridectomy.<sup>6</sup> For example, Ghanem *et al*<sup>6</sup> used an aspiration cutter during phacoemulsification in patients with iridoschisis. The FIT is different in that it is a minimally invasive approach using a smaller 25-gauge aspiration cutter probe to perform localised iridectomy through a self-sealing 25-gauge incision. No large incision, irrigation or sutures are required in FIT.<sup>4,5</sup>

The FIT introduces the concept of using a 25-gauge aspiration cutter to perform a minimally invasive iridectomy for glaucoma. Unlike standard surgical iridectomy, the FIT 25-gauge corneal incision allows for a relatively safe self-sealing corneal wound.

### Paul T Finger

The New York Eye and Ear Infirmary, New York City, New York, USA

Correspondence to: Dr P T Finger, The New York Eye Cancer Center, 115 East 61st Street, New York City, NY 10021, USA; [pfinger@paulfingermd.com](mailto:pfinger@paulfingermd.com)

doi: 10.1136/bjo.2006.108126

Accepted 18 October 2006

Funding: This work was supported by The EyeCare Foundation, New York City, NY, USA.

Competing interests: None.

### References

- 1 **Quigley HA.** Surgery of the glaucomas. In: Rice TA, Michels RG, Stark WJ, eds. *Ophthalmic surgery*, 4th edn. St Louis: Mosby, 1984, 177–81 (Chapter 7).

- 2 **World Medical Association.** Declaration of Helsinki (2000). Ethical Principles for Medical Research Involving Human Subjects. *Bull Med Eth* 2000;162:8–11.
- 3 **Health Insurance Portability and Accountability Act of 1996.** Public law 104–191. 104th Congress, United States of America, Aug 21, 1996.
- 4 **Finger PT, Laskany P, Kurli M, et al.** The Finger iridectomy technique: small incision biopsy of anterior segment tumours. *Br J Ophthalmol* 2005;89:946–9.
- 5 **Finger PT.** Small incision surgical iridotomy and iridectomy. *Graefes Arch Clin Exp Ophthalmol* 2006;244:399–400.
- 6 **Ghanem VC, Ghanem EA, Ghanem RC.** Iridectomy of the anterior iris stroma using the vitreocutter during phacoemulsification in patients with iridoschisis. *J Cataract Refract Surg* 2003;29:2057–9.

## Preimplantation genetic diagnosis for retinoblastoma predisposition

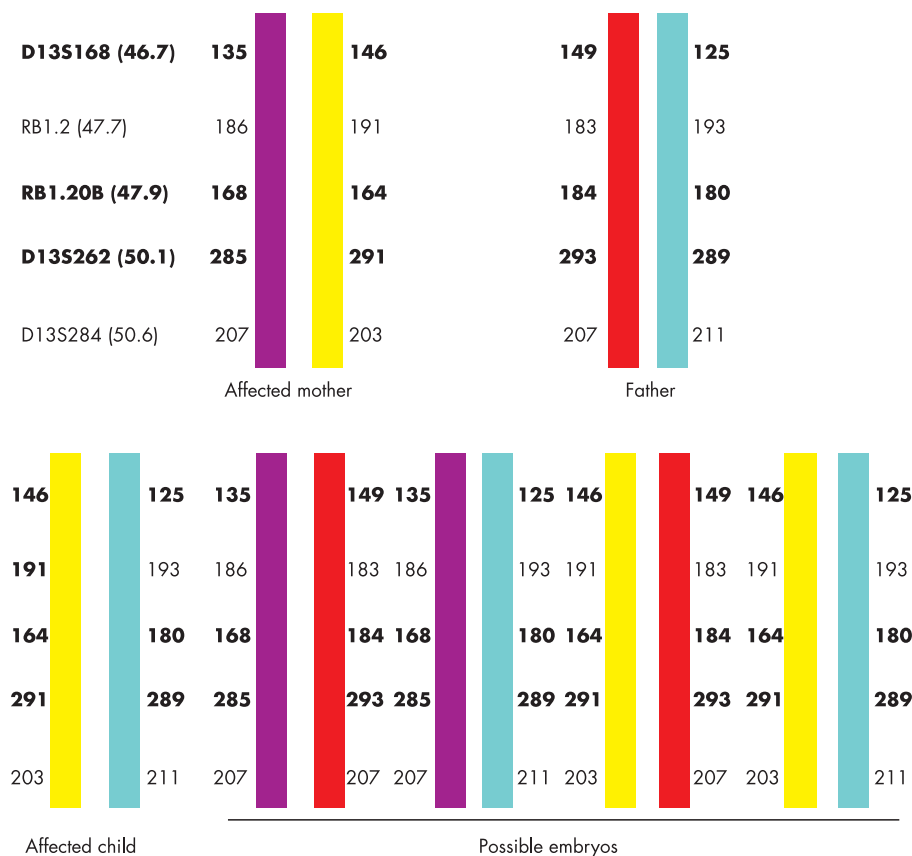
Heritable mutations in the *RB1* gene cause an autosomal dominant condition resulting in retinoblastoma<sup>1,2</sup> and an increased risk of malignancies including pineoblastoma, neuroblastoma, chondrosarcoma, rhabdomyosarcoma, glioma, leukaemia, sebaceous carcinoma, squamous cell carcinoma and cutaneous melanoma.<sup>3–6</sup> Individuals with heritable retinoblastoma can undergo prenatal diagnosis followed by termination to avoid passing on the mutation to the next generation.<sup>7</sup> Preimplantation genetic diagnosis (PGD) offers a means of achieving an unaffected pregnancy from the outset. IVF is required for PGD to allow cell biopsy from embryos for genetic testing. Embryos without the germline *RB1* mutation are transferred to the mother for implantation and pregnancy.

### Case study

A 24-year-old woman with bilateral retinoblastoma (*RB1*, OMIM#180200), had a *de novo* M708R mutation in *RB1* and was referred for PGD. She had a one-year-old child with the mutation and also had had a miscarriage and two terminations of affected pregnancies.

Following ovarian stimulation, 15 eggs were collected, of which 12 oocytes matured and eight fertilised normally 18–20 hours post-intracytoplasmic sperm injection (ICSI). Seven embryos were suitable for biopsy on day 3. DNA from biopsied cells was amplified by PCR using fluorescently labelled intragenic (*RBi20*) and linked polymorphic micro-satellite markers (D13S168 and D13S262). The PCR products were analysed using an ABI 3730 Prism. Three embryos (E4, E6 and E7) were diagnosed as carrying the maternal affected chromosome, while two embryos (E5 and E1) did not give clear results. Embryos E3 and E8 were diagnosed as unaffected. Figure 1 shows the haplotype for the family and figure 2 shows electrophoretograms of the parental DNA, a normal and an affected blastomere. All cell negatives and PCR negatives showed no DNA amplification.

On day 4 post-insemination unaffected embryos E3 (5 cell) and E8 (morula), were transferred to the uterus. Six+ weeks gestation ultrasound showed two sacs, one with a viable fetal pole while the other was anembryonic. A healthy boy was delivered at 35/40 weeks. Here we report the first successful use of PGD for retinoblastoma in the UK.



**Figure 1** Haplotype diagram of the family showing the allele sizes for each of the markers tested. The chromosome depicted in yellow carried the mutation as it was the one shared between the affected proband and her affected child. Using this information it was possible to predict from the haplotype which embryos carried the RB1 mutation. The markers shown in bold were used for PGD. The position of each of the markers on chromosome 13, in Mb, is given in parentheses.

## Comment

This report highlights the feasibility of PGD for rare cancer predispositions. The indirect mutation detection strategy by haplotyping that we have reported may be applied to more than one family with different germline mutations provided DNA is available from other affected family members in order to identify the chromosome carrying the mutation. The difficulty in doing PGD for heritable retinoblastoma is that a large number of germline mutations have been identified<sup>8</sup> and approximately half of these are *de novo* mutations.<sup>9</sup> Separate PGD protocols need to be developed for each *de novo* germline mutation. PGD for cancer predisposition is therefore labour intensive and expensive, however, the value of PGD for retinoblastoma should be considered within the context of childhood manifestation of the disorder and a lifetime cancer risk in multiple organs.<sup>4-6</sup> Inherited predisposition to retinoblastoma is very rare with a yearly UK incidence of approximately 20 cases.<sup>10</sup> PGD could significantly reduce the incidence of this inherited disorder.

**Seema Dhanjal, Georgia Kakourou, Thalia Mamas, Natasha Saleh**

UCL Centre for Preimplantation Genetic Diagnosis, Department of Obstetrics and Gynaecology, University College London, UK

**Alpesh Doshi, Sarah Gotts, Sarah Nuttall**

Assisted Conception Unit, University College Hospital, Eastman Dental Hospital, London, UK

**Karen Fordham**

UCL Centre for Preimplantation Genetic Diagnosis, Department of Obstetrics and Gynaecology, University College London, UK

**Paul Serhal**

Assisted Conception Unit, University College Hospital, Eastman Dental Hospital, London, UK

**Joy Delhanty, Joyce Harper, Sioban SenGupta**

UCL Centre for Preimplantation Genetic Diagnosis, Department of Obstetrics and Gynaecology, University College London, UK

Correspondence to: Sioban SenGupta, UCL Centre for Preimplantation Genetic Diagnosis, Department of Obstetrics and Gynaecology, University College London, 86-96 Chenies Mews, London WC1E 6HX; [s.sengupta@ucl.ac.uk](mailto:s.sengupta@ucl.ac.uk)

doi: 10.1136/bjo.2006.108597

Accepted 19 January 2007

Competing interests: None.

## References

- 1 Sparkes RS, Murphree AL, Lingua RW, *et al*. Gene for hereditary retinoblastoma assigned to human chromosome-13 by linkage to esterase-D. *Science* 1983;219:971-3.
- 2 Vogel F. Genetics of retinoblastoma. *Hum Genet* 1979;52:1-54.
- 3 Bader JL, Meadows AT, Zimmerman LE, *et al*. Bilateral retinoblastoma with ectopic intra-cranial

retinoblastoma: trilateral retinoblastoma. *Cancer Genet Cytogenet* 1982;5:203-13.

- 4 Draper GJ, Sanders BM, Kingston JE. 2nd primary neoplasms in patients with retinoblastoma. *Br J Cancer* 1986;53:661-71.
- 5 Roarty JD, Mclean IW, Zimmerman LE. Incidence of 2nd neoplasms in patients with bilateral retinoblastoma. *Ophthalmology* 1988;95:1583-7.
- 6 Traboulsi EI, Zimmerman LE, Manz HJ. Cutaneous malignant-melanoma in survivors of heritable retinoblastoma. *Arch Ophthalmol* 1988;106:1059-61.
- 7 Overton C, Serhal P, Davies M. In: Harper JC, Delhanty JDA, Handyside AH, eds. *Preimplantation Genetic Diagnosis*. Chichester: Wiley, 2001:123-40.
- 8 Valverde JR, Alonso J, Palacios I, *et al*. RB1 gene mutation up-date, a meta-analysis based on 932 reported mutations available in a searchable database. *BMC Genet* 2005;6:53.
- 9 Garber JE, Offit K. Hereditary cancer predisposition syndromes. *J Clin Oncol* 2005;23:276-92.
- 10 Childhood Eye Cancer Trust. <http://www.chect.org.uk> (accessed 4 Jun 2007).

## Rise in intraocular pressure during haemodialysis in a patient with reduced outflow facility

Intraocular pressure (IOP) during haemodialysis (HD) has previously been measured with ambiguous results.<sup>1</sup> Some studies have shown that HD does not affect the IOP,<sup>2-4</sup> whereas others have shown an increase<sup>5-7</sup> or decrease<sup>8-10</sup> in IOP during HD. The discrepancy in these results may be due in part to functional differences in the ocular system of the investigated patients. Indeed, there is some evidence that outflow facility status plays a significant role in IOP fluctuation during HD treatment.<sup>7</sup> We present a case of unilateral reduction of outflow facility showing an increase in IOP during HD, which persisted even after active aqueous humour secretion is reduced by cyclocryocoagulation.

## Case report

A 68-year-old HD patient with end-stage renal disease of unknown aetiology presented with central retinal vein occlusion in the right eye, which was followed by rubeosis iridis. Despite local antiglaucomatous medication, IOP reached levels up to 36 mm Hg, whereas the IOP of the left eye remained normal (10 mm Hg). The patient reported severe headache confined to the right frontal region during HD, which ceased without need of medication within hours after HD was completed. The patient was otherwise asymptomatic and had no personal or family history of headache and/or migraine. Due to persistent high IOP in the right eye, cyclocryocoagulation was successfully performed, with IOP declining to levels around 15 mm Hg (4 weeks postprocedure). The HD-associated pain also ceased. The fact that the pain was confined to the right orbita led to the hypothesis that it might be caused by a transient rise in IOP. To investigate this hypothesis, we measured IOP at 10 min intervals in both eyes prior to (baseline) and during HD on three independent occasions. A Medtronic Tono-Pen<sup>®</sup> XL applanation tonometer (Jacksonville, Florida, USA) was used. There was no significant difference between the two eyes at baseline and during the first 90 min of HD treatment (fig 1). However, IOP in the right eye rose after 90 min by 4.0 (1.3) mm Hg (mean (SEM)) to result in a significant IOP difference between the right eye and the healthy left eye of 7.9 (4.0) mmHg ( $p < 0.01$ )