



## Local delivery of adenoviral vectors encoding murine interleukin 10 induces colonic interleukin 10 production and is therapeutic for murine colitis

J O Lindsay, C J Ciesielski, T Scheinin, F M Brennan and H J Hodgson

*Gut* 2003;52;363-369  
doi:10.1136/gut.52.3.363

---

Updated information and services can be found at:  
<http://gut.bmj.com/cgi/content/full/52/3/363>

---

*These include:*

### References

This article cites 30 articles, 11 of which can be accessed free at:  
<http://gut.bmj.com/cgi/content/full/52/3/363#BIBL>

4 online articles that cite this article can be accessed at:  
<http://gut.bmj.com/cgi/content/full/52/3/363#otherarticles>

### Email alerting service

Receive free email alerts when new articles cite this article - sign up in the box at the top right corner of the article

---

### Correction

A correction has been published for this article. The contents of the [correction](#) have been appended to the original article in this reprint. The correction is also available online at:  
<http://gut.bmj.com/cgi/content/full/53/5/774-a>

---

### Notes

---

To order reprints of this article go to:  
<http://journals.bmj.com/cgi/reprintform>

To subscribe to *Gut* go to:  
<http://journals.bmj.com/subscriptions/>

## INFLAMMATORY BOWEL DISEASE

# Local delivery of adenoviral vectors encoding murine interleukin 10 induces colonic interleukin 10 production and is therapeutic for murine colitis

J O Lindsay, C J Ciesielski, T Scheinin, F M Brennan, H J Hodgson

*Gut* 2003;**52**:363–369

**Introduction:** Interleukin 10 knockout (IL-10<sup>-/-</sup>) mice spontaneously develop a Th1 T cell mediated colitis with many similarities to Crohn's disease. Daily injections of IL-10 are unable to induce remission in mice with established disease. In contrast, we have shown previously that intravenous administration of adenoviral vectors encoding IL-10 (AdvmuIL-10) induces hepatic IL-10 release and leads to long term disease suppression with profound systemic immunoregulatory changes.

**Aims:** To determine whether rectal delivery of AdvmuIL-10 induces localised colonic IL-10 expression without systemic immune suppression, and assess its therapeutic efficacy in IL-10<sup>-/-</sup> mice with established colitis.

**Results:** A single rectal infusion of 5×10<sup>8</sup> PFU AdvmuIL-10 to 10 week IL-10<sup>-/-</sup> mice resulted in a median level of 27.3 pg/mg IL-10 in colonic homogenates harvested one week later. IL-10<sup>-/-</sup> mice with established colitis treated with an enema of 5×10<sup>8</sup> PFU AdvmuIL-10 entered clinical and histological remission whereas empty cassette adenovirus (AdvO) or phosphate buffered saline (PBS) treated mice developed progressive disease. After four weeks, the histological score of AdvmuIL-10 treated mice (4.4 (1.5)) was significantly lower than that of AdvO (11.1 (1.1); p<0.001) and PBS (10.9 (1.0); p<0.01) treated controls. In addition, the stool concentration of IL-1β over the four week experiment was significantly higher in mice treated with saline or AdvO than in those treated with AdvmuIL-10 (p<0.01).

**Conclusion:** Local AdvmuIL-10 therapy reverses colitis in IL-10<sup>-/-</sup> mice without the systemic effects seen after intravenous administration. Gene therapy strategies using adenoviral vectors encoding immunoregulatory cytokines may prove to be a potent approach to the treatment of chronic inflammatory diseases such as Crohn's disease.

See end of article for authors' affiliations

Correspondence to:  
Dr J O Lindsay, Kennedy  
Institute of Rheumatology  
Division, Imperial College  
School of Medicine, 1  
Aspenlea Road, London  
W6 8LH, UK;  
[j.lindsay@doctors.org.uk](mailto:j.lindsay@doctors.org.uk)

Accepted for publication  
18 September 2002

The chronic gastrointestinal inflammation that characterises Crohn's disease is associated with loss of tolerance to resident enteric bacteria,<sup>1</sup> activation of immune cells, and leucocytic infiltration.<sup>2</sup> These inflammatory processes are orchestrated by the production of chemokines, proinflammatory monokines, and Th1 cytokines.<sup>3</sup> Studies of mice in which interleukin (IL)-10 signalling is disrupted provide compelling evidence for the role of this immunoregulatory cytokine in maintaining mucosal homeostasis. Thus both gene targeted IL-10 knockout (IL-10<sup>-/-</sup>) and IL-10 receptor 2 deficient mice develop a Th1 lymphocyte mediated colitis with many similarities to Crohn's disease.<sup>4,5</sup> IL-10 has broad immunoregulatory activity and thus acts to suppress intestinal inflammation on several levels.<sup>6</sup> It diminishes both antigen presentation and IL-12 release, which inhibits differentiation of Th1 lymphocytes. In addition, IL-10 suppresses the release of many other proinflammatory cytokines and chemokines, including tumour necrosis factor α (TNF-α), IL-1, IL-6, and IL-8. Finally, there is strong evidence that IL-10 acts to promote differentiation and augment the activity of regulatory T cells.<sup>7</sup>

Administration of systemic IL-10 injections is sufficient to inhibit proinflammatory Th1 lymphocyte responses and abrogate colitis in both dextran sodium sulphate and CD4<sup>+</sup>CD45RB<sup>high</sup> transfer models of colitis.<sup>8,9</sup> Furthermore, in vitro studies have shown that exogenous IL-10 downregulates enhanced proinflammatory cytokine release from lamina propria mononuclear cells isolated from patients with Crohn's disease.<sup>10</sup> Despite this, two recent clinical trials in patients with either steroid naïve or steroid resistant Crohn's disease have shown that daily systemic IL-10 injections are safe and well tolerated but have minimal therapeutic efficacy compared

with placebo.<sup>11,12</sup> One explanation for these disappointing results is that the pharmacodynamics of daily systemic IL-10 delivery does not allow sufficient mucosal penetration to inhibit the proinflammatory response. Thus strategies that result in a more sustained and focused delivery of IL-10 to the gastrointestinal mucosa may prove effective.

Recently, we have demonstrated that a single systemic injection of an adenoviral vector encoding murine IL-10 (AdvmuIL-10) targets hepatocytes and results in at least 10 weeks of bioactive IL-10 expression.<sup>13</sup> Unlike daily recombinant IL-10 injections,<sup>14</sup> systemic AdvmuIL-10 therapy induced remission in IL-10<sup>-/-</sup> mice with established disease, leading to lower clinical and histological scores with reduced faecal proinflammatory cytokine levels. Finally, delivery of IL-10 also appeared to limit the host response to viral vector, as antiadenovirus antibody titres were lower in AdvmuIL-10 treated mice than in littermates treated with control virus. However, in addition to these beneficial effects, systemic AdvmuIL-10 therapy led to generalised immunoregulatory changes in IL-10<sup>-/-</sup> mice, such as an impaired splenocyte response to lipopolysaccharide (LPS), that may limit its potential in patients with Crohn's disease. Likewise, clinical

**Abbreviations:** IL-10, interleukin 10; AdvmuIL-10, adenoviral vector encoding murine IL-10; Advβgal, adenoviral vector encoding β-galactosidase; AdvO, empty cassette adenoviral vector; TNF-α, tumour necrosis factor α; IFN-γ, interferon γ; LPS, lipopolysaccharide; FCS, fetal calf serum; PBS, phosphate buffered saline; DMEM, Dulbecco's modified Eagle's medium; CAR, Coxsackie virus and adenovirus receptor; LPMN, lamina propria mononuclear cell; MOI, multiplicity of infection.

trials of systemic IL-10 have reported a dose dependant but fully reversible anaemia and thrombocytopenia and the long term sequelae of this treatment are not known.<sup>11 12</sup>

It is possible that targeted local IL-10 would be sufficient to treat intestinal inflammation while avoiding the side effects associated with systemic therapy. Thus oral administration of non-pathogenic bacteria (*Lactococcus lactis*) that have been genetically modified to secrete murine IL-10 led to histological improvement in dextran sodium sulphate and IL-10<sup>-/-</sup> models of colitis.<sup>15</sup> Concerns raised by the release of genetically modified organisms into the environment may be avoided by the use of replication deficient adenoviral vectors such as AdvmuIL-10. Adenoviruses have strong tropism for epithelial tissues, and adenoviral vectors delivered per rectum have been shown to induce expression of the delivered transgene within colonocytes.<sup>16</sup> In this paper, we demonstrate the ability of rectal AdvmuIL-10 to induce colonic IL-10 expression and ameliorate established colitis in IL-10<sup>-/-</sup> mice without the generalised side effects associated with systemic therapy. Furthermore, we show that local AdvmuIL-10 results in a diminished host antiadenoviral response compared with control adenoviral vectors.

## MATERIALS AND METHODS

General reagents were of research grade and purchased from Sigma (St Louis, Missouri, USA). All reagents used for cell culture were determined to be LPS free using a limulus amoebocyte lysate assay (Biowhitacker, Berkshire, UK), as directed by the manufacturer (sensitivity <10 pg/ml).

### Adenoviral vectors

The recombinant E1 deleted type 5 adenoviral vectors, encoding murine IL-10 under the transcriptional control of the rous sarcoma virus promoter (AdvmuIL-10),  $\beta$ -galactosidase under the cytomegalovirus promoter (Adv $\beta$ Gal), or having no insert (Adv0), were generously donated by Professor Dallman (Imperial College, London, UK). Viruses were propagated in the 293 human embryonic kidney cell line (Quantum Biotechnology Inc., Canada) and purified by ultracentrifugation through two caesium chloride gradients (Boehringer Mannheim, Lewes, Sussex, UK). The titre of adenoviral vectors was determined by plaque assay on 293 cells. Viral stocks were diluted with 10% glycerol and stored in aliquots at -80°C until use.<sup>17</sup>

### In vitro epithelial cell infection

The transformed human colonic epithelial cell lines HT29 and SW620 (ATCC, Maryland, USA) were cultured at a density of  $1 \times 10^6$ /ml in RPMI 1640 medium (PAA Laboratories Ltd, Yeovil, UK) supplemented with 10% fetal calf serum (FCS), 100 u/ml penicillin, and 100  $\mu$ g/ml streptomycin (Biowhitacker). Initial experiments demonstrated that at least 95% infection with Adv $\beta$ gal was obtained with a multiplicity of infection of (MOI) 50:1 and an incubation time of 36 hours; thus these conditions were used in subsequent experiments. Cells were cultured in triplicate, infected with Adv0, AdvmuIL-10, or saline vehicle and cultured for 28 days with weekly passaging. Supernatants were sampled daily and frozen until assay. IL-10 bioactivity was determined by the ability of serial dilutions of the supernatant to inhibit TNF- $\alpha$  release from a murine monocyte cell line (RAW cells; ATCC) plated at  $1 \times 10^5$ /ml in a 96 well plate stimulated with 10 ng/ml LPS. Serial dilutions of recombinant murine IL-10 was used as a standard while the specificity of the effect was determined by preincubation of the supernatants and standards with 10  $\mu$ g/ml of a rat monoclonal antimurine IL-10 antibody (JES52A5; donated by DNAX Research Institute, California, USA) or a rat IgG1 isotype control (OX20; ATCC).

### Animals

IL-10<sup>-/-</sup> mice on a C57BL/6 background (purchased from Harlan UK Ltd, Oxon, UK) were backcrossed for one

generation onto DBA/1 mice to increase breeding vigour and disease expression. Progeny from the interbreeding of the heterozygous offspring were used in all experiments. Newly bred mice were screened for the homozygote IL-10<sup>-/-</sup> or wild-type genotype (C57BL/6xDBA1), as described previously.<sup>13</sup> Mice were maintained in specific pathogen free conditions in a laminar flow hood at all times with free access to food and water. All experiments involving animals were approved by the local ethics review process committee and performed under license from the Home Office.

Preliminary experiments demonstrated that under standard laboratory conditions, IL-10<sup>-/-</sup> animals developed a progressive colitis from four weeks of age. Clinical manifestations of disease included the passage of mucous, diarrhoea, rectal prolapse, and weight loss of greater than 5% of total body weight. Mice were examined weekly, and given a clinical score that consisted of one point for each of the above signs. Previous work has demonstrated a close correlation between the clinical score and histological severity of colitis (correlation coefficient 0.865; Dr T Scheinin, personal communication).

### Experimental protocols

Ten week old IL-10<sup>-/-</sup> mice with established colitis received  $5 \times 10^8$  PFU of AdvmuIL-10, Adv0, or phosphate buffered saline (PBS) vehicle as a 100  $\mu$ l rectal infusion under sedation. Mice were held vertically for one minute and then suspended on tilted racks for a further 10 minutes to prevent seepage. Wild-type C57BL/6xDBA1 mice were used as a negative control. The clinical score of each animal was assessed and stool samples were collected weekly throughout the experiment. Animals were sacrificed by cervical dislocation four weeks after adenoviral therapy. Serum was collected via cardiac puncture, spleens were harvested, stool samples collected, and serial segments of colon, caecum, and ileum were fixed in 10% neutral buffered formalin for histological analysis. In a separate experiment, IL-10<sup>-/-</sup> mice that had received saline or AdvmuIL-10 by rectal instillation were sacrificed after seven days. The liver, spleen, and colon of these animals were weighed and homogenised in 5  $\mu$ l PBS per mg tissue. Supernatants were harvested after centrifugation and stored at -20°C until assay.

### Histological analysis

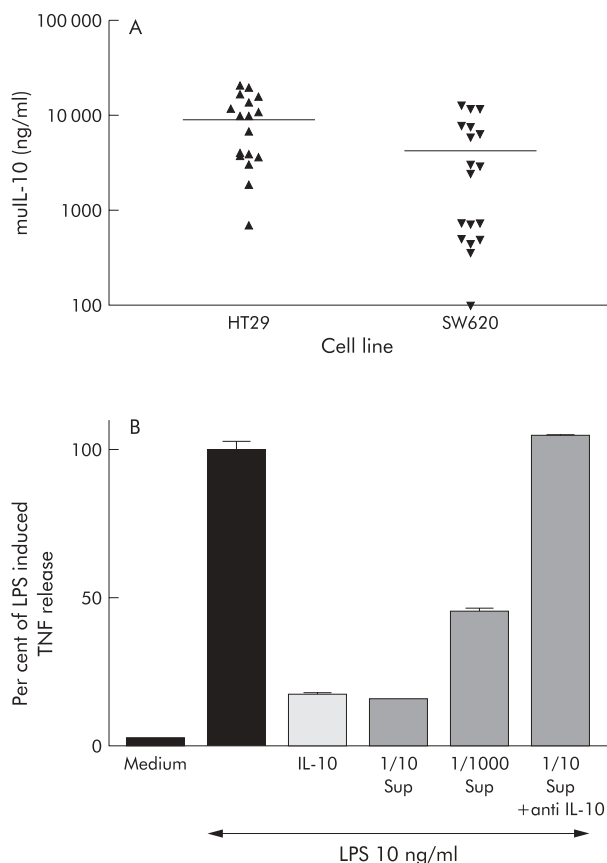
Samples were routinely processed, embedded in paraffin, sectioned at 5  $\mu$ m, and stained with haematoxylin and eosin for light microscopic examination. Histological assessment was performed by an investigator (TS) blinded to the treatment group. The terminal ileum and five segments of colon were examined per mouse and each given a histological score from 0 to 4 as described previously<sup>14</sup>; thus a total score for each mouse from 0 (no change in any segment) to 24 (grade 4 changes in all segments) was obtained. Scores of less than 5 were deemed to be within normal limits.

### Stool samples

Stool samples were collected weekly from all animals and weighed. Samples were emulsified in 500  $\mu$ l per 100  $\mu$ g stool weight of a solution of 1 mg/ml soy trypsin inhibitor and 1 mg/ml phenylmethylsulphonyl fluoride in PBS. Supernatants were collected after centrifugation at 10 000 *g* for 15 minutes and stored at -20°C.

### Spleen cell cultures

After sacrifice, each spleen was placed in RPMI 1640 supplemented with 10% FCS, 100 u/ml penicillin, and 100  $\mu$ g/ml streptomycin. Cell suspensions were obtained by passing tissue through a 200  $\mu$ m<sup>2</sup> nylon mesh. After erythrocyte lysis, cells were washed in Hanks balanced salt solution three times before resuspension in medium. Cells were plated at  $2 \times 10^6$ /well in 12 well plates (Falcon, Becton Dickinson Labware, USA) in a final volume of 1 ml of medium

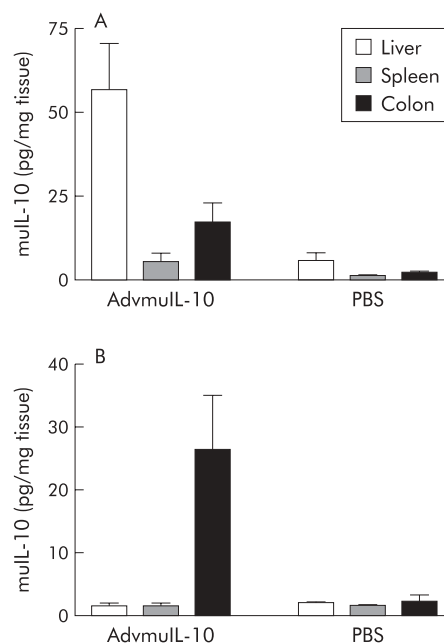


**Figure 1** Adenoviral vector encoding murine interleukin 10 (AdvmuIL-10) induced bioactive IL-10 release from epithelial cells in vitro. HT29 and SW620 cells were plated at  $1 \times 10^6$ /ml in a 12 well plate and infected with AdvmuIL-10 or empty cassette adenoviral vector (Adv0, MOI 50:1). Supernatants were sampled at 36 hours and daily thereafter. Cultures were passaged 1:2 every week. No IL-10 was detected in Adv0 infected epithelial cells. (A) IL-10 release from AdvmuIL-10 infected cells. (B) RAW cells ( $2 \times 10^5$ ) were plated onto a 96 well plate and incubated with IL-10 10 ng/ml, dilutions of the supernatant (Sup) from AdvmuIL-10 infected HT29 cells, or supernatant that had been preincubated with 10  $\mu$ g/ml (final) antimurine IL-10 antibody for one hour. Cells were cultured for 24 hours with or without 10 ng/ml lipopolysaccharide (LPS). Supernatants were harvested and assayed for tumour necrosis factor  $\alpha$  (TNF- $\alpha$ ) release by ELISA. Results are expressed as a percentage of the LPS induced TNF- $\alpha$  response (mean of three experiments). Identical results were obtained using supernatants from SW620 cells.

with or without LPS 10  $\mu$ g/ml, recombinant muIL-10 10 ng/ml (Schering Plough, New Jersey, USA), 10  $\mu$ g/ml neutralising rat antimurine IL-10 antibody (JES52A5; donated by DNAX Research Institute), or a rat IgG1 isotype control (OX20; ATCC). Cultures were maintained for 24 hours before supernatants were harvested and stored at  $-20^\circ\text{C}$ .

#### Measurement of serum antiadenoviral antibody response

The neutralising antiadenovirus antibody response was analysed in serum from untreated or treated IL-10 $^{-/-}$  mice four weeks after gene transfer with  $5 \times 10^8$  PFU of AdvmuIL-10, Adv0, or PBS vehicle.<sup>18</sup> Serum samples (100  $\mu$ l) were heat inactivated at  $56^\circ\text{C}$  for 30 minutes and diluted twofold in serum free Dulbecco's modified Eagle's medium (DMEM). Each dilution was incubated for 90 minutes at  $37^\circ\text{C}$  with  $2 \times 10^6$  PFU of Adv $\beta$ gal, and applied in duplicate to 80% confluent 293 cells on a 96 well plate. After one hour at  $37^\circ\text{C}$ , 50  $\mu$ l of DMEM containing 10% FCS was added to each well, and cells were cultured for a further 36 hours. Cell supernatants were then removed and replaced with 30  $\mu$ l of 0.25 mM Tris HCl, pH 7.8.



**Figure 2** Local adenoviral vector encoding murine interleukin 10 (AdvmuIL-10) induced colonic IL-10 release. Ten week old IL-10 $^{-/-}$  mice received  $5 \times 10^8$  PFU of AdvmuIL-10 or saline vehicle either by tail vein injection (A) or rectal infusion (B) under light sedation ( $n=3$ /group). After seven days, mice were sacrificed by cervical dislocation. The liver, spleen, and colon were homogenised in 5  $\mu$ l phosphate buffered saline (PBS) per mg tissue. After centrifugation, supernatants were assayed for murine IL-10 by ELISA (sensitivity 8 pg/mg).

Plates were vortexed, frozen, and then thawed for three cycles to detach and lyse cells, and centrifuged at 1000 rpm for 20 minutes. The supernatant (10  $\mu$ l) from each well was mixed with 90  $\mu$ l of a  $\beta$ -galactosidase substrate solution containing 1 mg/ml *o*-nitrophenyl- $\beta$ -D-galactopyranoside, 1 mM MgCl<sub>2</sub>, 45 mM 2-mercaptoethanol, in 0.1 M sodium phosphate buffer, pH 7.5. The enzyme reaction was stopped after five minutes with addition of 150  $\mu$ l of 0.1 M Na<sub>2</sub>CO<sub>3</sub>, and plates were read at 405 nm. Mean optical density of serum from five animals for each group was compared.

#### Cytokine analysis

Cytokine concentrations were measured by sandwich ELISA using paired antibodies according to the manufacturer's recommendations (IL-10 and TNF- $\alpha$  were purchased from Pharmingen, Sorentino, California, USA; interferon  $\gamma$  (IFN- $\gamma$ ) was purchased from Genzyme diagnostics, USA; IL-1 $\beta$  was purchased from R&D Systems (Abingdon, Oxon, UK)).

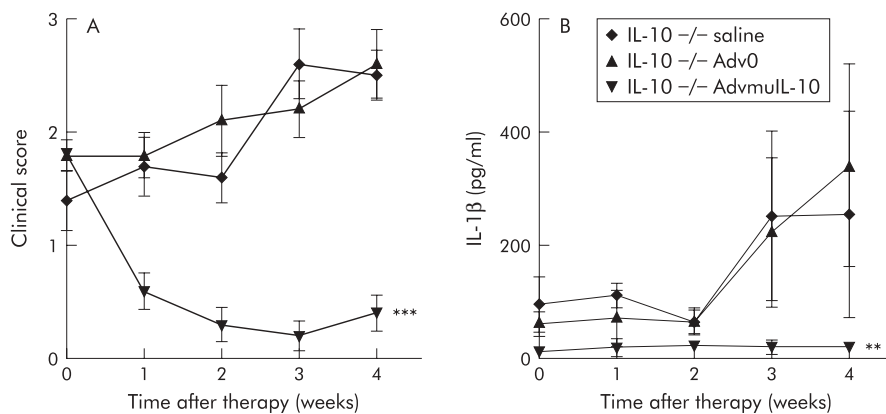
#### Statistical analysis

Data that exhibited a normal distribution were analysed using a two tailed *t* test; for comparison of more than two means a two way analysis of variance (ANOVA) was performed.

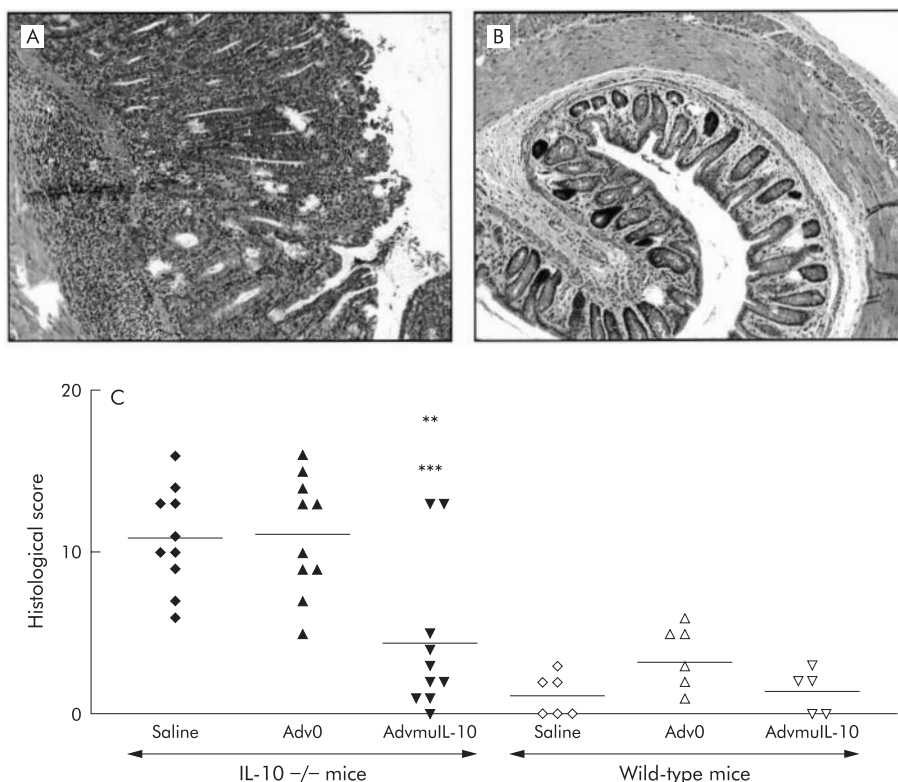
## RESULTS

### In vitro infection of epithelial cell lines with AdvmuIL-10 induces bioactive murine IL-10 release

In order to ascertain whether AdvmuIL-10 induces IL-10 secretion from epithelial cells, cultures of the human colonic epithelial cell lines HT29 and SW620 were infected with AdvmuIL-10 at an MOI of 50:1 for 36 hours; separate wells were infected with Adv0 or saline vehicle as controls. Supernatants were sampled daily, and cultures were passaged weekly. No IL-10 was detected in the supernatants of Adv0 or vehicle treated cells. In contrast, 36 hours after AdvmuIL-10 infection, the supernatants of HT29 and SW620 cells contained 297 (44) ng/ml and 790 (43)



**Figure 3** Local adenoviral vector encoding murine interleukin 10 (AdvmuIL-10) was therapeutic for established murine colitis. IL-10<sup>-/-</sup> mice (n=10/group) with clinical evidence of colitis and C57BL/6×DBA1 wild-type controls (n=5/group) received  $5 \times 10^8$  PFU of AdvmuIL-10, empty cassette adenoviral vector (Adv0), or vehicle by rectal instillation under light sedation. (A) Clinical score (one point each for rectal mucous, rectal prolapse, diarrhoea, and weight loss >5% body weight) and (B) stool IL-1β levels were measured weekly, and are expressed as mean (SEM) for each group. \*\*p<0.01, \*\*\*p<0.001, two way ANOVA.



**Figure 4** Local adenoviral vector encoding murine interleukin 10 (AdvmuIL-10) therapy reduced histological colitis scores in IL-10<sup>-/-</sup> mice with established disease. Four weeks after therapy, mice were sacrificed by cervical dislocation and sections of five regions of the colon were processed for histology. Representative samples from an IL-10<sup>-/-</sup> mouse treated with empty cassette adenoviral vector (Adv0) (A) and AdvmuIL-10 (B) are shown. An investigator, blinded to treatment group, gave each section an inflammatory score from 0 to 4. The sum of these scores is shown for each mouse (C), with the bar representing the mean for the group (\*\*p<0.01 versus IL-10<sup>-/-</sup> saline group; \*\*\*p<0.001 versus IL-10<sup>-/-</sup> Adv0 group; one way ANOVA with Bonferroni correction).

ng/ml muIL-10, respectively (mean (SEM)). IL-10 release continued for the 28 days of the experiment, as shown in fig 1. In order to confirm that this IL-10 was bioactive, the ability of the supernatants from AdvmuIL-10 infected HT29 cells to inhibit LPS induced TNF-α release from cultures of RAW cells was compared with recombinant murine IL-10. muIL-10 10 ng/ml reduced TNF-α release to 17.5 (0.7)% of LPS stimulated levels whereas a 1/10 dilution of the supernatant of AdvmuIL-10 infected HT29 cells reduced TNF-α release to 15.8 (0.29)%. Addition of a monoclonal antimurine IL-10 antibody (but not isotype control antibody) abrogated this inhibitory effect completely (fig 1).

#### Rectal instillation of AdvmuIL-10 results in localised colonic IL-10 expression

Systemic delivery of adenoviral vectors predominantly targets hepatocytes although some splenic and colonic expression of the delivered transgene has been reported.<sup>19</sup> In order to assess whether rectal AdvmuIL-10 delivery results in localised colonic IL-10 release,  $5 \times 10^8$  PFU of AdvmuIL-10 or PBS vehicle were delivered to 10 week old IL-10<sup>-/-</sup> mice either by tail vein injection or by rectal instillation (n=3/group). Mice were sacrificed one week after adenoviral administration. IL-10 concentration in colonic homogenates from mice that had received rectal AdvmuIL-10 was mean 26.5 (SEM 8.7) pg/mg

compared with 13 (6.5) pg/mg in mice that had received an intravenous injection. In contrast, while liver and spleen IL-10 concentrations after rectal AdvmuIL-10 administration did not differ significantly from the background seen in PBS treated controls (the sensitivity of the ELISA was approximately 8 pg/mg), IL-10 concentrations in the liver and spleen of mice given an intravenous injection were significantly elevated (52.5 (22.5) pg/ml and 5.7 (4.3) pg/ml, respectively) (fig 2).

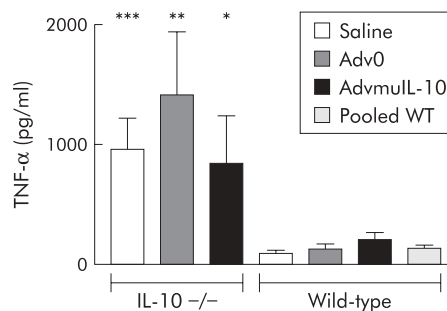
#### Local AdvmuIL-10 treatment is therapeutic for established colitis in IL-10<sup>-/-</sup> mice

IL-10<sup>-/-</sup> mice develop a spontaneous enterocolitis associated with weight loss, passage of mucous, rectal prolapse, and diarrhoea. It has been reported that daily injections of recombinant murine IL-10 prevent disease but are not sufficient to reverse established colitis.<sup>14</sup> In order to determine the therapeutic efficacy of local AdvmuIL-10 delivery, 10 week old IL-10<sup>-/-</sup> mice with established colitis received a single rectal instillation of 5×10<sup>8</sup> PFU of AdvmuIL-10, Adv0, or PBS vehicle. Wild-type mice received the same treatment to act as a negative control. IL-10<sup>-/-</sup> mice that received AdvmuIL-10 demonstrated a significant improvement in their colitis scores over the four week experiment whereas those that had received Adv0 or vehicle continued to develop progressive disease (fig 3). Thus the mean (SEM) clinical score in the AdvmuIL-10 group fell from 1.8 (0.13) to 0.4 (0.16) whereas clinical scores increased from 1.4 (0.27) to 2.5 (0.27) and from 1.8 (0.22) to 2.6 (0.13) in the PBS and Adv0 treated groups, respectively ( $p < 0.001$  for both Adv0 and PBS compared with AdvmuIL-10; two way ANOVA). No clinical evidence of colitis was detected in any wild-type mice, irrespective of their treatment group (data not shown). Analysis of weekly stool samples demonstrated that the progressive colitis observed in the Adv0 and PBS treated IL-10<sup>-/-</sup> mice was associated with release of significantly higher levels of the proinflammatory cytokine IL-1 $\beta$  than AdvmuIL-10 treated IL-10<sup>-/-</sup> mice ( $p < 0.01$ ; fig 3). IL-1 $\beta$  was not detected in stools collected from wild-type mice treated with Adv0, AdvmuIL-10, or PBS vehicle (data not shown).

Histological analysis of colonic tissue from 10 week old IL-10<sup>-/-</sup> mice demonstrated a marked colitis with a histological score of 9.4 (1.3) ( $n = 5$ ). The histological score of colitic IL-10<sup>-/-</sup> mice four weeks after local instillation of 5×10<sup>8</sup> PFU of Adv0 or saline vehicle increased to 11.1 (1.1) and 10.9 (1.0), respectively. The histological severity of colitis was consistent throughout the colon (data not shown). In contrast, a single dose of rectal AdvmuIL-10 induced histological remission in IL-10<sup>-/-</sup> mice with established disease (fig 4). Thus four weeks after AdvmuIL-10 therapy the mean histological score had fallen to 4.4 (1.5) ( $p < 0.01$  compared with saline,  $p < 0.001$  compared with Adv0 therapy); this was not significantly different from the scores of age matched wild-type mice that had received a rectal enema of saline, Adv0, or AdvmuIL-10 four weeks previously (1.2 (0.5), 3.2 (0.8), and 1.4 (0.6), respectively). Interestingly, local AdvmuIL-10 therapy ameliorated histological colitis throughout the colon as there were no significant differences between the histological scores of the proximal and distal sections of the colon in AdvmuIL-10 treated mice (data not shown).

#### Local AdvmuIL-10 treatment has no effect on TNF- $\alpha$ release from LPS stimulated splenocytes.

IL-10<sup>-/-</sup> mice challenged with LPS released elevated levels of proinflammatory cytokines and suffered higher mortality than wild-type controls.<sup>20</sup> We have reported that a single systemic injection of AdvmuIL-10 is sufficient to inhibit the elevated TNF- $\alpha$  and IFN- $\gamma$  release from LPS stimulated splenocytes harvested 10 weeks after therapy.<sup>13</sup> In order to determine the systemic effects of local AdvmuIL-10 therapy, we compared TNF- $\alpha$  release from LPS stimulated spleen cells harvested from mice used in the above experiments. TNF- $\alpha$

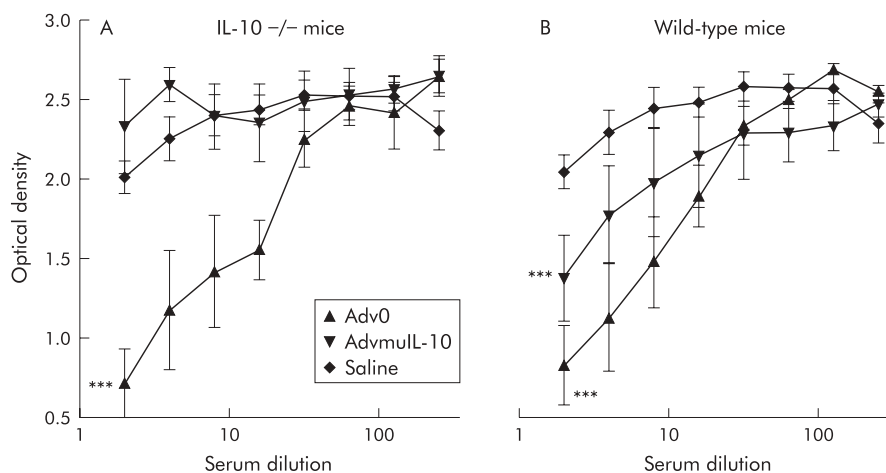


**Figure 5** Rectal adenoviral vector encoding murine interleukin 10 (AdvmuIL-10) did not diminish the lipopolysaccharide (LPS) splenocyte response in IL-10<sup>-/-</sup> mice. Splenocytes were isolated at sacrifice from both IL-10<sup>-/-</sup> ( $n = 10$ /group) and wild-type ( $n = 5$ /group) mice treated with 5×10<sup>8</sup> PFU empty cassette adenoviral vector (Adv0), saline, or AdvmuIL-10 by rectal instillation four weeks previously. Cells (2×10<sup>6</sup> per well) were cultured for 24 hours in the presence of LPS 10  $\mu$ g/ml. Supernatants were harvested and assayed for tumour necrosis factor  $\alpha$  (TNF- $\alpha$ ) by ELISA. Cells from each animal were assayed in triplicate; results are expressed as mean (SEM) for each group. \* $p < 0.05$ ; \*\* $p < 0.01$ ; \*\*\* $p < 0.001$  versus pooled wild-type (WT) mice.

release from unstimulated splenocytes was below the sensitivity of the ELISA for all animals ( $< 40$  pg/ml). As expected, LPS (10  $\mu$ g/ml) induced significantly higher levels of TNF- $\alpha$  from splenocytes harvested from IL-10<sup>-/-</sup> mice than wild-type controls (964 (266) pg/ml and 98 (21) pg/ml, respectively;  $p < 0.02$ , two tailed  $t$  test). However, in contrast with systemic delivery, prior treatment of IL-10<sup>-/-</sup> mice with rectal AdvmuIL-10 had no effect on TNF- $\alpha$  release (fig 5). Thus TNF- $\alpha$  release from LPS stimulated splenocytes harvested from IL-10<sup>-/-</sup> mice that had received rectal Adv0, AdvmuIL-10, or saline four weeks previously was 1414 (530) pg/ml, 845 (399) pg/ml, and 964 (266) pg/ml, respectively. Furthermore, neutralising IL-10 in LPS stimulated splenocyte cultures of IL-10<sup>-/-</sup> mice that had been treated with rectal AdvmuIL-10 had no effect on levels of TNF- $\alpha$  secreted (1326 (792) pg/ml with OX20 isotype control compared with 1406 (676) pg/ml when cultured with JES52A5 anti-IL-10 antibodies). As a positive control for this experiment, TNF- $\alpha$  release from LPS stimulated splenocytes harvested from saline treated wild-type mice cultured with either JES52A5 or the OX20 was examined. As predicted, neutralising endogenous IL-10 significantly increased TNF- $\alpha$  release (353 (60) pg/ml with JES52A5 compared with 138 (26) pg/ml with OX20;  $p < 0.02$  by two tailed  $t$  test).

#### Neutralising antiadenovirus antibody response is diminished in AdvmuIL-10 treated IL-10<sup>-/-</sup> mice

Previous studies have shown elevated titres of antiadenovirus antibodies in mice treated with adenoviral vectors.<sup>21</sup> We hypothesised that the neutralising antibody response to AdvmuIL-10 vectors would be diminished, as the protein encoded for by this virus will act to suppress both T cell activation and antigen presentation. A bioassay was used to detect the presence of antibodies directed to adenoviral proteins in the serum of mice that had received a rectal infusion of Adv0, AdvmuIL-10, or saline vehicle four weeks previously. Serum from both IL-10<sup>-/-</sup> and wild-type mice that had received rectal Adv0 contained neutralising antiadenoviral antibodies were compared with serum from mice that had received saline ( $p < 0.001$  two way ANOVA; fig 6). However, there was no difference in the antiadenoviral antibody titre in serum from IL-10<sup>-/-</sup> mice that had received rectal AdvmuIL-10 compared with those that had received saline. Interestingly, the diminished antiadenoviral response to AdvmuIL-10 was less pronounced in wild-type mice than in IL-10<sup>-/-</sup> mice.



**Figure 6** Rectal adenoviral vector encoding murine interleukin 10 (AdvmuIL-10) induced a diminished antiadenoviral response in IL-10<sup>-/-</sup> mice. The neutralising antiadenovirus antibody titre was analysed in serum from (A) IL-10<sup>-/-</sup> and (B) wild-type mice four weeks after rectal instillation of  $5 \times 10^8$  PFU of AdvmuIL-10, empty cassette adenoviral vector (Adv0), or saline vehicle. Serial serum dilutions were incubated for 90 minutes at 37°C with  $2 \times 10^6$  PFU of adenoviral vector encoding  $\beta$ -galactosidase (Adv $\beta$ gal) and applied in duplicate to 80% confluent 293 cells on a 96 well plate. After one hour at 37°C, 50  $\mu$ l of Dulbecco's modified Eagle's medium containing 10% fetal calf serum was added to each well, and cells were cultured for a further 36 hours. Cell supernatants were then removed and assayed using a  $\beta$ -galactosidase substrate solution. In this assay, a low optical density reflects a high titre of serum antiadenoviral antibodies. Results are expressed as mean (SEM) optical density for each group. \*\*\* $p < 0.001$  compared with saline treated mice, two way ANOVA).

## DISCUSSION

We have explored the potential of local AdvmuIL-10 administration as a therapy for intestinal inflammation. This strategy has the advantage that IL-10 delivery is targeted to the sites of inflammation which may prevent the side effects associated with high dose systemic IL-10 administration. The use of the IL-10<sup>-/-</sup> model of colitis allows accurate determination of the site of IL-10 expression after local AdvmuIL-10 delivery. In addition, as daily systemic injections of murine IL-10 are unable to reverse established colitis in this model,<sup>14</sup> it allows a comparison of the therapeutic efficacy of local AdvmuIL-10 and recombinant IL-10 injections.

Adenoviral vectors bind to cell surface integrins ( $\alpha\beta 3$  and  $\alpha\beta 5$ ) and gain entry by receptor mediated endocytosis using a receptor such as the Coxsackie virus and adenovirus receptor (CAR).<sup>22</sup> CAR mRNA can be detected in human intestinal tissue by northern blotting.<sup>23</sup> Thus infection of human colonic epithelial cells with AdvmuIL-10 in vitro resulted in the release of high levels of functional IL-10 as determined by a specific bioassay. The effect of the secreted murine IL-10 on epithelial cell function was not assessed, as despite 73% amino acid homology between murine and human IL-10 proteins, murine IL-10 has no activity on human cells.<sup>24</sup>

The presence of CAR on murine colonic epithelial cells has not been determined.<sup>23</sup> However, recent reports have suggested that the MHC class I receptor may also function as a high affinity receptor for adenoviral vectors.<sup>25</sup> Irrespective of this, previous studies in mice have demonstrated that colonic administration of adenoviral vectors leads to colonic reporter gene expression, which peaks at 48–72 hours.<sup>16</sup> These findings were confirmed by the significant levels of IL-10 that were detected in colonic homogenates of IL-10<sup>-/-</sup> mice one week after local AdvmuIL-10 administration. The duration of IL-10 expression in this experiment is surprising considering that colonic epithelial cell turnover occurs every 2–3 days.<sup>26</sup> However, Foreman *et al* also reported low level  $\beta$ -galactosidase expression for up to 180 hours after colonic Adv $\beta$ gal administration.<sup>19</sup> Although rectal administration of adenoviral vectors predominantly targets the colonic epithelial cell, some expression has been reported in lamina propria mononuclear (LPMN) cells.<sup>16</sup> Thus the late phase of gene expression after local adenoviral vector administration may represent LPMN cell infection. Furthermore, Wirtz *et al* have reported that the ratio of LPMN cells to epithelial cells

infected by rectal adenoviral administration is increased in mice that have colitis.<sup>16</sup> This may explain the prolonged duration of IL-10 expression that we report after AdvmuIL-10 delivery to IL-10<sup>-/-</sup> mice with established colitis. In addition, AdvmuIL-10 induces a diminished host antiadenovirus response in IL-10<sup>-/-</sup> mice compared with control vectors that may also permit prolonged IL-10 expression.

Whereas systemic AdvmuIL-10 administration leads to IL-10 expression in the liver, spleen, and colon, IL-10 protein was not detected in the liver and spleen of IL-10<sup>-/-</sup> mice that received AdvmuIL-10 as an enema. The absence of systemic IL-10 activity after local AdvmuIL-10 therapy was confirmed by experiments examining the response of harvested splenocytes to stimulation with LPS. Local delivery of replication deficient adenoviral vectors was well tolerated and did not exacerbate intestinal inflammation. Studies of adenoviral vectors encoding non-immunoregulatory proteins have demonstrated host antiviral immune responses that limit the duration of gene expression and prevent retreatment.<sup>21</sup> However, in contrast with the marked antibody response to control vectors, local AdvmuIL-10 delivery significantly diminished the host antiadenoviral response in IL-10<sup>-/-</sup> mice. It is interesting that the reduction in antiadenoviral response seen with AdvmuIL-10 administration is not as marked in wild-type as in IL-10<sup>-/-</sup> mice. The explanation for this dichotomy is not clear but is likely to represent alterations in B cell maturation in IL-10<sup>-/-</sup> mice.<sup>4</sup>

IL-10<sup>-/-</sup> mice develop a spontaneous Th-1 cell mediated enterocolitis with many similarities to Crohn's disease.<sup>4</sup> Steidler *et al* investigated the therapeutic efficacy of local IL-10 delivery using bacteria that had been genetically modified to secrete high levels of IL-10.<sup>15</sup> A four week oral course of these bacteria led to a 75% reduction in the histological severity of colitis in IL-10<sup>-/-</sup> mice. However, this therapy was administered to three week old mice prior to the onset of their disease. In contrast, we demonstrated that, unlike daily IL-10 injections, a single AdvmuIL-10 enema was capable of reversing established disease in IL-10<sup>-/-</sup> mice. Furthermore, clinical remission was maintained for at least four weeks after therapy. The dramatic improvement in clinical score was associated with a fall in the levels of the proinflammatory cytokine IL-1 $\beta$  that was detected in high concentrations in the stool of IL-10<sup>-/-</sup> mice with colitis. Most strikingly, rectal AdvmuIL-10 therapy led to a 60% reduction in the histological severity of

colitis compared with control treated mice. Thus a single dose of IL-10 gene therapy delivered directly to the colon was sufficient to suppress established disease in IL-10<sup>-/-</sup> mice for at least four weeks.

The mechanisms by which IL-10 induced by AdvmuIL-10 therapy could have diminished disease severity in the intestine were not addressed directly in our experiments. However, they include downregulation of antigen presenting cell activity and inhibition of proinflammatory cytokine production. The fact that the therapeutic effects of AdvmuIL-10 therapy persisted for at least four weeks and extended throughout the colon suggest that its mechanism of action may extend beyond the local suppression of proinflammatory cytokine release. An analogous situation occurs in mice with collagen induced arthritis in which an intrarticular injection of AdvmuIL-10 is therapeutic for both the treated and contralateral paw.<sup>27</sup> As in our experiments, the duration of this therapeutic effect persisted far longer than the period in which local IL-10 can be detected. Thus it is possible that local IL-10 release induces differentiation or activation of regulatory T cell clones.<sup>7</sup> This hypothesis is supported by studies of transgenic mice that overexpress IL-10 in the intestinal epithelium.<sup>28</sup> The mucosal lymphocyte population of these transgenic mice contains a higher proportion of immunoregulatory CD4<sup>+</sup>CD25<sup>+</sup> T cells than wild-type controls. Furthermore, stimulated intestinal lymphocytes from IL-10 transgenic mice secrete lower levels of Th1 cytokines and higher levels of transforming growth factor  $\beta$  than controls.<sup>28</sup>

Thus delivery of AdvmuIL-10 directly to the intestinal lumen provides local IL-10 production minimising the side effects associated with systemic therapy. Most strikingly, local AdvmuIL-10 therapy induces clinical and histological remission in IL-10<sup>-/-</sup> mice with established colitis. The concept of local gene delivery as a therapy for intestinal inflammation is supported by the demonstration that intrarectal administration of an E1 deleted adenoviral vector expressing IL-18 antisense mRNA inhibits mucosal IFN- $\gamma$  release and suppresses inflammation in the transfer model of colitis.<sup>29</sup> However, patients with Crohn's disease are not IL-10 deficient and may mount an immune response to AdvmuIL-10, as seen in wild-type mice. This would limit the duration of a therapeutic response and prevent retreatment. Alternative viral vectors may be more appropriate for clinical trials of IL-10 gene therapy than the replication deficient adenoviral vectors used in the current study. Adeno associated viruses are less immunogenic, and by integrating into the host genome have been shown to provide long term gene expression in the intestinal tract.<sup>30</sup> Furthermore, therapy could be targeted to sites of active disease using an inflammation inducible C3-tat/HIV promoter that induces IL-10 release in response to inflammatory stimuli such as TNF- $\alpha$ .<sup>31</sup>

In conclusion, local gene therapy strategies using viral vectors encoding immunoregulatory cytokines may prove to be a potent approach to the treatment of chronic inflammatory diseases such as Crohn's disease.

## ACKNOWLEDGEMENTS

We gratefully acknowledge Patricia Green for her technical assistance, and Philip Connolly who kindly performed the histological processing. This work was supported by the Digestive Diseases Foundation and a Clinical Training Fellowship from the Medical Research Council of the UK.

## Authors' affiliations

**J O Lindsay, C J Ciesielski, F M Brennan,** Kennedy Institute of Rheumatology Division, Imperial College School of Medicine, London, UK  
**T Scheinin,** Fourth Department of Surgery, University of Helsinki Central Hospital, Kasarmikatu 11-13, FIN-00130 Helsinki, Finland  
**H J Hodgson,** Department of Hepatology, Royal Free and University College Medical School, Royal Free Campus, London, UK

## REFERENCES

- Duchmann R,** Kaiser I, Hermann E, *et al.* Tolerance exists towards resident intestinal flora but is broken in active inflammatory bowel disease (IBD). *Clin Exp Immunol* 1995;**102**:448-55.
- Pallone F,** Fais S, Squarcia O, *et al.* Activation of peripheral blood and intestinal lamina propria lymphocytes in Crohn's disease. In vivo state of activation and in vitro response to stimulation as defined by the expression of early activation antigens. *Gut* 1987;**28**:745-53.
- Fiocchi C.** Inflammatory bowel disease: etiology and pathogenesis. *Gastroenterology* 1998;**115**:182-205.
- Kuhn R,** Lohler J, Rennick D, *et al.* Interleukin-10-deficient mice develop chronic enterocolitis. *Cell* 1993;**75**:263-74.
- Spencer SD,** Di Marco F, Hooley J, *et al.* The orphan receptor CRF2-4 is an essential subunit of the interleukin 10 receptor. *J Exp Med* 1998;**187**:571-8.
- Moore KW,** de Waal Malefyt R, Coffman RL, *et al.* Interleukin-10 and the interleukin-10 receptor. *Annu Rev Immunol* 2001;**19**:683-765.
- Groux H,** O'Garra A, Bigler M, *et al.* A CD4<sup>+</sup> T-cell subset inhibits antigen-specific T-cell responses and prevents colitis. *Nature* 1997;**389**:737-42.
- Tomoyose M,** Mitsuyama K, Ishida H, *et al.* Role of interleukin-10 in a murine model of dextran sulfate sodium-induced colitis. *Scand J Gastroenterol* 1998;**33**:435-40.
- Powrie F,** Leach MW, Mauze S, *et al.* Inhibition of Th1 responses prevents inflammatory bowel disease in scid mice reconstituted with CD45RBhi CD4<sup>+</sup> T cells. *Immunity* 1994;**1**:553-62.
- Schreiber S,** Heinig T, Thiele HG, *et al.* Immunoregulatory role of interleukin 10 in patients with inflammatory bowel disease. *Gastroenterology* 1995;**108**:1434-44.
- Schreiber S,** Fedorak RN, Nielsen OH, *et al.* Safety and efficacy of recombinant human interleukin 10 in chronic active Crohn's disease. *Gastroenterology* 2000;**119**:1461-72.
- Fedorak RN,** Gangl A, Elson CO, *et al.* Recombinant human interleukin 10 in the treatment of patients with mild to moderately active Crohn's disease. *Gastroenterology* 2000;**119**:1473-82.
- Lindsay JO,** Ciesielski CJ, Scheinin T, *et al.* The prevention and treatment of murine colitis using gene therapy with adenoviral vectors encoding IL-10. *J Immunol* 2001;**166**:7625-33.
- Berg DJ,** Davidson N, Kuhn R, *et al.* Enterocolitis and colon cancer in interleukin-10-deficient mice are associated with aberrant cytokine production and CD4(+) TH1-like responses. *J Clin Invest* 1996;**98**:1010-20.
- Steidler L,** Hans W, Schotte L, *et al.* Treatment of murine colitis by Lactococcus lactis secreting interleukin-10. *Science* 2000;**289**:1352-5.
- Wirtz S,** Galle PR, Neurath MF. Efficient gene delivery to the inflamed colon by local administration of recombinant adenoviruses with normal or modified fibre structure. *Gut* 1999;**44**:800-7.
- Graham FL,** Prevec L. Methods for construction of adenovirus vectors. *Mol Biotechnol* 1995;**3**:207-20.
- David A,** Coupel-Clauze H, Chetritt J, *et al.* Anti-adenovirus immune responses in rats are enhanced by interleukin 4 but not interleukin 10 produced by recombinant adenovirus. *Hum Gene Ther* 1998;**9**:1755-68.
- Foreman PK,** Wainwright MJ, Alick B, *et al.* Adenovirus-mediated transduction of intestinal cells in vivo. *Hum Gene Ther* 1998;**9**:1313-21.
- Berg DJ,** Kuhn R, Rajewsky K, *et al.* Interleukin-10 is a central regulator of the response to LPS in murine models of endotoxin shock and the Shwartzman reaction but not endotoxin tolerance. *J Clin Invest* 1995;**96**:2339-47.
- Yang Y,** Li Q, Ertl HC, *et al.* Cellular and humoral immune responses to viral antigens create barriers to lung-directed gene therapy with recombinant adenoviruses. *J Virol* 1995;**69**:2004-15.
- Bergelson JM,** Cunningham JA, Droguett G, *et al.* Isolation of a common receptor for Coxsackie B viruses and adenoviruses 2 and 5. *Science* 1997;**275**:1320-3.
- Tomko RP,** Xu R, Philipson L. HCAR and MCAR: the human and mouse cellular receptors for subgroup C adenoviruses and group B coxsackieviruses. *Proc Natl Acad Sci U S A* 1997;**94**:3352-6.
- Moore KW,** O'Garra A, de Waal Malefyt R, *et al.* Interleukin-10. *Annu Rev Immunol* 1993;**11**:165-90.
- Hong SS,** Karayan L, Tournier J, *et al.* Adenovirus type 5 fiber knob binds to MHC class I alpha2 domain at the surface of human epithelial and B lymphoblastoid cells. *Embo J* 1997;**16**:2294-306.
- Gordon JI,** Schmidt GH, Roth KA. Studies of intestinal stem cells using normal, chimeric, and transgenic mice. *Faseb J* 1992;**6**:3039-50.
- Whalen JD,** Lechman EL, Carlos CA, *et al.* Adenoviral transfer of the viral IL-10 gene periarticularly to mouse paws suppresses development of collagen-induced arthritis in both injected and uninjected paws. *J Immunol* 1999;**162**:3625-32.
- De Winter H,** Elewaut D, Turovskaya O, *et al.* Regulation of mucosal immune responses by recombinant interleukin 10 produced by intestinal epithelial cells in mice. *Gastroenterology* 2002;**122**:1829-41.
- Wirtz S,** Becker C, Blumberg R, *et al.* Treatment of T cell-dependent experimental colitis in SCID mice by local administration of an adenovirus expressing IL-18 antisense mRNA. *J Immunol* 2002;**168**:411-20.
- During MJ,** Xu R, Young D, *et al.* Peroral therapy of lactose intolerance using an adeno-associated virus vector. *Nat Med* 1998;**4**:1131-5.
- Miagkov AV,** Varley AW, Munford RS, *et al.* Endogenous regulation of a therapeutic transgene restores homeostasis in arthritic joints. *J Clin Invest* 2002;**109**:1223-9.



# PostScript

## LETTERS

If you have a burning desire to respond to a paper published in the *Gut*, why not make use of our "rapid response" option?

Log on to our website ([www.gutjnl.com](http://www.gutjnl.com)), find the paper that interests you, and send your response via email by clicking on the "eLetters" option in the box at the top right hand corner.

Providing it isn't libellous or obscene, it will be posted within seven days. You can retrieve it by clicking on "read eletters" on our homepage.

The editors will decide as before whether to also publish it in a future paper issue.

### Investigation of chronic diarrhoea

I congratulate the authors of the recently revised "BSG guidelines for the investigation of diarrhoea" for their excellent overview of this important clinical problem (*Gut* 2003; 52(suppl V):v1-15). I would however take issue with the suggestion that measurement of stool volumes in outpatients is impractical. In my experience such measurement is readily achievable and cheap, merely requiring a suitable container and some weighing scales. A three day stool collection should be considered early in the investigation of chronic diarrhoea, particularly if a factitious aetiology is suspected which is unfortunately often underdiagnosed and over investigated.<sup>1</sup>

**R C G Pollok**

Department of Gastroenterology, St George's Hospital, London SW17 0QT, UK; [rpollok@sghms.ac.uk](mailto:rpollok@sghms.ac.uk)

### Reference

- 1 Pollok RCG, Banks MR, Fairclough PD, *et al*. Dilutional diarrhoea: under-diagnosed and over-investigated. *Eur J Gastroenterol Hepatol* 2000;12:609-11.

### Authors' reply

We welcome Dr Pollock's comments on the use of a three day stool collection in the investigation of chronic diarrhoea. Our concern about its use in the outpatient setting, and particularly when factitious diarrhoea is suspected, is that collection is unsupervised and potentially susceptible to interference. It was for this reason that inpatient collection was suggested. Furthermore, we think there will be widespread doubt by clinicians about the acceptability of this approach. Excepting these caveats, we agree that it is a relatively simple and effective way to assess stool volume which may limit the need for other investigations in these patients.

**P Thomas, A Forbes**

St Mark's Hospital, Wafford Road, Harrow HA1 3UJ, UK

Correspondence to: Dr A Forbes; [alastair.forbes@ic.ac.uk](mailto:alastair.forbes@ic.ac.uk)

### Interstitial pneumonia associated with autoimmune pancreatitis

We read with interest the article by Kamisawa *et al* reporting IgG4 positive plasma cells in peripancreatic tissue, extrahepatic bile duct, gall bladder, and salivary gland (*Gut* 2003;52:683-7). The association of retroperitoneal fibrosis and sclerosing pancreatitis with IgG4 bearing plasma cells in the tissues of both lesions has been also reported.<sup>1</sup>

We would like to report the first case of interstitial pneumonia associated with autoimmune pancreatitis and IgG4 positive plasma cells in the interstitium.

Hyperamylasemia was detected in a routine blood examination in a 63 year old man who had been treated for duodenal ulcer at a clinic. He was admitted to our hospital for further examination. He did not complain of epigastralgia or back pain. Serum amylase was 323 (39-130 IU/l), IgG was elevated to 2350 (800-1600 mg/dl), and IgG4 was 1690 (<80 mg/dl). Antinuclear antibody, anti-SS-A antibody, anti-SS-B antibody, rheumatoid factor, and antismooth muscle antibody were all negative. Abdominal ultrasonography and computed tomography (CT) showed swelling of the head and tail of the pancreas. Endoscopic retrograde pancreatography showed irregular narrowing of the main pancreatic duct in the head and tail. Magnetic resonance cholangiography showed extrinsic stenosis of the lower common bile duct. The patient was diagnosed with autoimmune pancreatitis but he refused steroid therapy and was followed as an outpatient.

Three months later, honeycombing of the bilateral lower lung field was detected in a follow up abdominal CT. Chest CT revealed ground glass attenuation in the middle and lower lobe, and honeycombing predominantly at the back of the lower lobe, bilaterally (fig 1A). (Figure 1 (A-D) is available for viewing online at <http://gut.bmjournals.com/cgi/eletters/52/5/683#127>.)

Retrospectively, a slight reticular shadow in the lower lung field was detected in the chest roentgenogram taken at the first admission but the lesion had progressed over three months. He was readmitted for further examination. He had a history of smoking 30-40 cigarettes a day for approximately 40 years. IgG was 3934 mg/dl, IgG4 was 2690 mg/dl, KL-6 was 1440 (<500 u/ml), serum amylase was 142, and lipase was 121 (0-49 IU/l). Schirmer's test indicated a decrease in lacrimal secretion. Swelling of the head and tail of the pancreas were not changed on abdominal ultrasonography and CT.

With gallium scintigraphy, uptake was observed bilaterally at the back of the lower lobe, suggesting active pneumonia. Histology obtained by transbronchial lung biopsy from segment 8a of the right lobe showed marked thickening of the alveolar septum with marked infiltration of plasma cells and lymphocytes (fig 1B).

Immunostaining with IgG4 was performed using the immunoperoxidase method (mouse antihuman IgG4; ICN Biomedicals, Inc, Ohio, Canada). Infiltration of IgG4 positive plasma cells was detected in the alveolar septum (fig 1C).

Macrophages in the alveoli are considered to be due to smoking which often coexists with interstitial pneumonia in smokers.<sup>2</sup>

Because interstitial pneumonia associated with autoimmune pancreatitis was strongly suggested, prednisolone (40 mg/day) was administered for two weeks and then the dose was tapered. Chest CT taken two weeks after treatment showed that the ground glass attenuation in the middle and lower lobe had disappeared whereas the honeycombing remained (fig 1D).

Abdominal ultrasonography performed two weeks after treatment showed a marked decrease in the swelling of the pancreas.

In the present case, infiltration of IgG4 positive plasma cells in the interstitium strongly suggests that the interstitial lung disease was associated with autoimmune pancreatitis. Interstitial pneumonia associated with Sjogren's syndrome is unlikely in this case although there was decreased lacrimal secretion. Sicca syndrome observed in autoimmune pancreatitis is distinctive from classical Sjogren's syndrome in that it is negative for anti-SS-A or anti-SS-B antibodies, serum IgG4 is elevated, and infiltration of IgG4 positive plasma cells in the salivary glands is observed.<sup>3</sup>

Autoimmune pancreatitis, in some cases, may be part of a systemic disease associated with IgG4.

**T Taniguchi, M Ko, S Seko, O Nishida, F Inoue, H Kobayashi, T Saiga, M Okamoto**

Department of Internal Medicine, Radiology, and Pathology, Ohtsu Red Cross Hospital, Ohtsu, Japan

**T Fukuse**

Department of Thoracic Surgery, Kyoto University Faculty of Medicine, Kyoto, Japan

Correspondence to: Dr T Taniguchi, Department of Internal Medicine, Ohtsu Red Cross Hospital, 1-1-35 Nagara, Ohtsu, Shiga Ohtsu, Japan

### References

- 1 Hamano H, Kawa S, Ochi Y, *et al*. Hydronephrosis associated with retroperitoneal fibrosis and sclerosing pancreatitis. *Lancet* 2002;359:1403-4.
- 2 American Thoracic Society. American Thoracic Society/European Respiratory Society International Multidisciplinary Consensus Classification of the Idiopathic Interstitial Pneumonias. *Am J Respir Crit Care Med* 2002;165:277-304.
- 3 Hamano H, Kawa S, Horiuchi A, *et al*. High serum concentration in patients with sclerosing pancreatitis. *N Engl J Med* 2001;344:732-8.

### Author's reply

We thank Dr Taniguchi *et al* for the interesting presentation of interstitial pneumonia associated with autoimmune pancreatitis (AIP).

We have experienced 24 cases of AIP but no cases showed interstitial pneumonia clinically. Recently, we immunohistochemically examined the organs of eight patients with AIP using anti-IgG4 antibody. IgG4 positive plasmacytic infiltration was detected in the portal area of the liver, gastric mucosa, colonic mucosa, and bone marrow as well as in the pancreas, peripancreatic tissue, extrahepatic bile duct, gall bladder, salivary gland,

and lymph nodes of patients with AIP. However, few IgG4 positive plasma cells were observed in identical control specimens. From these findings, we proposed a new clinicopathological entity of IgG4 related autoimmune disease, and stressed that AIP is not simply pancreatitis but a pancreatic lesion involved in this systemic autoimmune disease.<sup>1,2</sup> As IgG4 positive plasmacytic infiltration was observed in the transbronchially biopsied pulmonary specimens of the patient with AIP (unpublished data), it is likely that interstitial pneumonia occurs in association with AIP.

**T Kamisawa, N Funata, A Okamoto**

Tokyo Metropolitan Komagome Hospital, Tokyo, Japan

Correspondence to: Dr T Kamisawa, Tokyo Metropolitan Komagome Hospital, 3-18-22 Honkomagome, Bunkyo-ku, Tokyo 113-8677, Japan; [kamisawa-k@komagome-hospital.bunkyo.tokyo.jp](mailto:kamisawa-k@komagome-hospital.bunkyo.tokyo.jp)

## References

- 1 **Kamisawa T**, Egawa N, Nakajima H. Autoimmune pancreatitis is a systemic autoimmune disease. *Am J Gastroenterol* 2003;**98**:2811–12.
- 2 **Kamisawa T**, Funata N, Hayashi Y, *et al.* A new clinicopathological entity of IgG4-related autoimmune disease. *J Gastroenterol* 2003;**38**:982–4.

## The diagnostic dilemmas in discrimination between pancreatic carcinoma and chronic pancreatitis

In response to the letter of Harlozinska-Szmyrka and Strutyńska-Karpinska (*Gut* 2004;**53**:469–70) commenting on our study,<sup>1</sup> we agree with the remarks made in relation to the difficulties in discriminating between chronic pancreatitis and adenocarcinoma using currently employed diagnostic imaging and tumour marker analysis. Our study was aimed at determining the risk of cancer development in patients with proven chronic pancreatitis,<sup>1</sup> examining age and sex standardised incidence ratios calculated from the number of observed cases of pancreatic cancer in our cohort of 373 patients with predominantly alcohol related chronic pancreatitis to the number of cases expected in the National Cancer Registry. Our study design did not take into consideration diagnostic dilemmas and focused purely on cancer risk in our cohort of patients using defined stringent criteria. Indeed, we previously underlined the interest of biological markers in this situation (for example, CA19-9 and circulating K-ras)<sup>2,3</sup>; however these markers have problems with both sensitivity and specificity.

We acknowledge that given the difficulties in diagnosing cancer in this situation, the establishment of new tumour markers such as tissue polypeptide specific antigen (TPS)<sup>4</sup> with proven good sensitivity and specificity should provide for progress in the future. It has to be stressed however that TPS, a marker of proliferation activity, is not specific to pancreatic cancer, and other digestive and non-digestive cancers as well as benign chronic disorders may have high levels of this marker.<sup>5–7</sup> Thus validated data concerning tumour markers, either alone or in combination, in distinguishing pancreatic

cancer from chronic pancreatitis should prove important in diagnostic situations.

**P Ruzsniwski, D Malka, P Hammel, F Maire, P Rufat, I Madeira, F Pessione, P Lévy**

Department of Gastroenterology, Beaujon Hospital, Clichy, France

Correspondence to: Professor P Ruzsniwski, Service de Gastroentérologie, Hôpital Beaujon, F-92118, Clichy, France; [philippe.ruzsniwski@bjn.ap-hop-paris.fr](mailto:philippe.ruzsniwski@bjn.ap-hop-paris.fr)

## References

- 1 **Malka D**, Hammel P, Maire F, *et al.* Risk of pancreatic adenocarcinoma in chronic pancreatitis. *Gut* 2002;**51**:849–52.
- 2 **Nouts A**, Levy P, Voitot H, *et al.* Diagnostic value of serum Ca 19-9 antigen in chronic pancreatitis and pancreatic adenocarcinoma. *Gastroenterol Clin Biol* 1998;**22**:152–9.
- 3 **Maire F**, Micard S, Hammel P, *et al.* Differential diagnosis between chronic pancreatitis and pancreatic cancer: value of the detection of KRAS2 mutations in circulating DNA. *Br J Cancer* 2002;**27**, **87**:551–4.
- 4 **Slesak B**, Harlozinska-Szmyrka A, Knast W, *et al.* Tissue polypeptide specific antigen (TPS), a marker for differentiation between pancreatic carcinoma and chronic pancreatitis. A comparative study with CA 19-9. *Cancer* 2000;**89**:83–8.
- 5 **Malamitsi-Puchner A**, Vazeou-Gerasimidi A, Sarandakou A, *et al.* Tissue polypeptide-specific antigen serum concentrations in children, adolescents, and young adults with type 1 diabetes. *Diabetes Care* 2002;**25**:240–1.
- 6 **Hrycek A**, Kokocinska D, Kosmider J, *et al.* Tissue polypeptide-specific antigen in SLE patients treated with low doses of quinagolide. *Lupus* 2003;**12**:149–52.
- 7 **Valik D**, Nekulova M. Serum tissue polypeptide-specific antigen (TPS): what is its diagnostic value? *Br J Cancer* 2000;**82**:1756–8.

## In search of the correct strategy for preventing the spread of HCV infection

Hepatitis C virus (HCV) infection is an emerging global healthcare issue. Apart from affecting approximately 3% of the world population, HCV is also a silent disease—the majority of incidences go unrecognised and serve unknowingly as sources of infection to others.<sup>1,2</sup> Add to that the scant information defining the transmission routes and rates of HCV, the programme presented by Skipper *et al* in their paper evaluating the diagnosis and prevention of HCV in a prison outreach clinic (*Gut* 2003;**52**:1500–4) seems a model that could significantly constrain a situation that appears to be reaching epidemic proportions, especially here in Southern Italy.

Studies on the epidemiology of HCV infection in Italy have shown that this infection represents a major health problem throughout Southern Italy, with a prevalence of up to 12.6% in the general population.<sup>3–5</sup> Also, HCV has been linked to the high incidence and mortality rates for liver cancer found in our region (standardised incidence rates per 100 000 inhabitants: 18.9 male, 13.2 female; mortality rates 15.2 male, 9.0 female).<sup>6</sup> Between January 2000 and December 2001, we performed a cross sectional study of 5844 individuals (4260 men; 1584 women) from the general population and from five select groups in the city of Naples, with the purpose of assessing the prevalence of HCV infection in select groups with different exposure

patterns in Southern Italy. Below are the preliminary data from this study:

- general population (n = 1972; prevalence 8.5%);
- imprisonment (n = 524; prevalence 37.4%);
- intravenous drug use (n = 1436; prevalence 31.8%);
- haemodialysis (n = 678; prevalence 2.9%);
- routine medical examination of patients (n = 453; prevalence 12.6%); and
- health care workers at the National Cancer Institute of Naples (n = 781; prevalence 6.4%).

Our findings confirm the high prevalence among drugs users (31.8%) but the highest prevalence was found among male prisoners (37.4%), particularly those in the 30–49 year age range (47.3%). In fact, we concur with Skipper *et al* that “those involved with IDU frequently pass through the penal system and spend time in prisons” thus indicating a probable interrelationship between these two groups.

Our other findings from this study shed light on the unusually high prevalence of this disease in the general population of Southern Italy. Previous reports have shown that the prevalence of HCV infection is generally low in the general population of most industrialised countries (<5%).<sup>7</sup> In Southern Italy, the high prevalence of HCV infection may be the result of past iatrogenic transmission, aggravated by:

- (1) extensive use of glass syringes or non-sterile syringes<sup>8</sup>; and
- (2) social conditions which may indirectly favour the spread of infection:

- general poverty,
- poor education etc,<sup>9,10</sup> and
- especially among females, haemodialysis procedures.

Prisons do play a significant role in the hepatitis C epidemic, especially as the same social conditions mentioned above which may facilitate spread of infection also predict imprisonment.<sup>11</sup> In fact, a disproportionate share of the burden of HCV infection is found among those who pass through correctional facilities.<sup>12</sup> As stated previously, HCV seroprevalence is high among this group. A history of incarceration is one of the strongest associations with HCV seropositivity.<sup>13</sup> Yet despite these high levels, reports of HCV transmission in the prison setting are uncommon.<sup>14,15</sup> In fact, studies have revealed that an overwhelming number of these infections are being brought into prisons via inmates who are already previously infected; drug users are most likely to become infected with HCV at the beginning of their addiction—long before being imprisoned for the first time.<sup>16–18</sup> Yet it must be taken into account the fact that the dynamic movement of people in and out of prisons makes it very difficult to detect transmission.<sup>19</sup> While the available data do not prove that infections are acquired in prison, they do indicate prisons as high risk institutions for the spread of HCV.<sup>20</sup>

What is of great concern to us are the implications of the previous and following data:

- HCV is easily transmitted parenterally.

- Our prisons are overcrowded (the Secondigliano prison located in Naples, for example, has 1350 prisoners and only 750 beds).
- In Southern Italy, the health system in general is less efficient and less meticulous than that in the north of Italy (and in the rest of the EU and in the USA).<sup>8</sup>
- We have no harm reduction programmes in place.

The limited availability of prevention methods has been linked to the transmission of HCV infection.<sup>21</sup> This association, and its relation to inadequate management of a manageable problem, surely opens up our National Health System to costly retaliations. If it can be proven that an inmate contracted HCV while incarcerated, due to a lack of sufficient care and prevention on the part of the system, he then has the right to seek judicial indemnification—a costly process for all concerned.

How much more economical to initiate admission screening programmes in our overcrowded prisons where, as detailed above, there is an identifiable elevated risk. By so doing, we move one step closer to correcting a problem that is grossly out of control. As HCV is associated with different kinds of neoplasms (liver, possibly non-Hodgkins lymphoma) and with autoimmune diseases (cryoglobulinaemia, thyroiditis, Hashimoto thyroiditis), which develop after the virus has caused immune system alterations,<sup>22</sup> routine health screening on admission to prison presents a unique opportunity to identify health needs and plan health services at an early stage.<sup>23</sup> In fact, studies have found that screening provides a preventive function, as those who had previously presented for a hepatitis C test, regardless of the result, were less likely to have recently engaged in high risk behaviour (that is, sharing injecting equipment).<sup>24</sup>

How much more economical to initiate a good educational harm reduction programme such as that implemented by Skipper *et al.* Correctional interventions of this kind stand to benefit not only the inmates themselves and their families and partners, but also the public health of the communities to which the vast majority of inmates return.<sup>12</sup> By implementing such a programme, the health-care system would be doing its job, demonstrating efficient management of a crucial problem and sustaining the welfare of its people.

**M Montella, A Crispo, J Wynn-Bellezza**

National Cancer Institute, Naples, Italy

Correspondence to: Dr M Montella;  
epidemiologia.int@tin.it

## References

- Mohsen AH, Group TH, Trent HCV Study Group. The epidemiology of hepatitis C in a UK health regional population of 5.12 million. *Gut* 2001;**48**:707–13.
- Thomas DL, Astemorski J, Rai RM, *et al.* The natural history of hepatitis C virus infection: host, viral and environmental factors. *JAMA* 2000;**284**:450–6.
- Guadagnino V, Stroffolini T, Rapicetta M, *et al.* Prevalence, risk factors and genotype distribution of hepatitis C virus infection in the general population: a community-based survey in Southern Italy. *Hepatology* 1997;**26**:1006–11.
- Maio G, d'Argenio P, Stroffolini T, *et al.* Hepatitis C virus infection and alanine transaminase levels in the general population: a survey in a southern Italian town. *J Hepatol* 2000;**33**:116–20.
- Raffaele A, Valentini M, Iovenitti M, *et al.* High prevalence of HCV infection among the general population in a rural area of Central Italy. *Eur J Epidemiol* 2001;**17**:41–6.
- Zanetti R, Gafà L, Pannelli F, *et al.* Cancer in Italy: Incidence data from Cancer Registries, third volume: 1993–1998. Rome: Il Pensiero Scientifico Editore, 2002.
- Touzet S, Kraemer L, Colin C, *et al.* Epidemiology of hepatitis C virus infection in seven European Union countries: a critical analysis of the literature. HENCORE Group (Hepatitis C European Network for Co-operative Research). *Eur J Gastroenterol Hepatol* 2000;**12**:667–78.
- Di Stefano R, Stroffolini T, Ferraro D, *et al.* Endemic hepatitis C virus infection in a Sicilian town: further evidence for iatrogenic transmission. *J Med Virol* 2002;**67**:339–44.
- Sarbah SA, Younussi ZM. Hepatitis C: an update on the silent epidemic. *J Gastroenterol Hepatol* 2000;**30**:125–43.
- Geddes M, Berlinguer G. *La Salute in Italia, rapporto*. Rome: Ediesse Edition, 1998.
- McCarthy N. The legitimacy of punishment systems should be addressed. *BMJ* 2000;**321**:1406.
- Hammitt TM, Harmon MP, Rhodes W. The burden of infectious disease among inmates of and releases from US correctional facilities, 1997. *Am J Pub Health* 2002;**92**:1789–94.
- Crofts N, Jolley D, Kaldor J, *et al.* The epidemiology of hepatitis C virus infection among Australian injecting drug users. *J Epidemiol Community Health* 1997;**51**:692–7.
- Haber PS, Parsons SJ, Harper SE, *et al.* Transmission of hepatitis C within Australian prisons. *Med J Aust* 1999;**171**:31–3.
- Rosen HR. Acquisition of hepatitis C by a conjunctival splash. *Am J Infect Control* 1997;**25**:242–7.
- Lamden KH, Kennedy N, Beeching NJ, *et al.* Hepatitis B and hepatitis C virus infections: risk factors among drug users in Northwest England. *J Infect* 1998;**37**:260–9.
- Chang CJ, Lin CH, Lee CT, *et al.* Hepatitis C virus infection among short-term intravenous drug users in southern Taiwan. *Eur J Epidemiol* 1999;**15**:597–601.
- Rezza G, Saggiocca L, Zaccarelli M, *et al.* Incidence rate and risk factors for HCV seroconversion among injecting drug users. *Scand J Infect Dis* 1996;**28**:27–9.
- Dolan KA. Can hepatitis C transmission be reduced in Australian prisons? *Med J Aust* 2001;**174**:378–9.
- Allwright S, Bradley F, Long J, *et al.* Prevalence of antibodies to hepatitis B, hepatitis C, and HIV and risk factors in Irish prisoners: results of a national cross sectional survey. *BMJ* 2000;**321**:78–82.
- Butler TG, Dolan KA, Ferson MJ, *et al.* Hepatitis B and C in New South Wales prisons: prevalence and risk factors. *Med J Aust* 1997;**166**:127.
- Farci P, Shimoda A, Coiana A, *et al.* The outcome of acute hepatitis C predicted by the evolution of the viral quasispecies. *Science* 2000;**288**:339–44.
- Morrison DS, Gilchrist G. Prison admission health screening as a measure of health needs. *Health Bull (Edinb)* 2001;**59**:114–9.
- Cook PA, McVeigh J, Syed Q, *et al.* Predictors of hepatitis B and C infection in injecting drug users both in and out of drug treatment. *Addiction* 2001;**96**:1787–97.

## Cross reactivity due to positive canrenone interference

Canrenone is a selective competitive inhibitor of the aldosterone receptor and a diuretic drug commonly used in the treatment of cirrhotic patients both with and without ascites.<sup>1</sup> The aim of our observation was to determine if canrenone cross reacts with aldosterone in an immunoradiosorbent assay kit used for the hormonal scoring system according to the Child-Pugh classification for liver cirrhosis.<sup>2</sup> Canrenone, in vitro experi-

ments, was a gift from GiEnne Pharma (Group Therabel) Diagnostics. Canrenone, potassium canrenoate, and spironolactone are often used with digoxin in clinical practice and can cause falsely low readings in common assays for digoxin (that is, AxSym MEIA-Abbott) due to negative cross reactivity, and falsely elevated serum digoxin concentrations with the fluorescence polarisation immunoassay for digoxin.

Human hepatic stellate cells, isolated from wedge sections of normal human liver unsuitable for transplantation, were separated, after digestion with collagenase/pro-nase, from other liver non-parenchymal cells by ultracentrifugation over gradients of stractan. Cells were cultured on plastic culture dishes in Iscove's modified Dulbecco's medium, supplemented as described elsewhere.<sup>3</sup> Cells were plated ( $1 \times 10^5$  cells in well dishes) and incubated with increasing concentrations of canrenone or with no drug (SFIF or control conditions), after a 24 hour incubation period in serum free insulin free (SFIF) medium. After 24 hours, medium was removed and then lyophilised in a dry vacuum. Pellets were then resuspended in a total volume of 1 ml and aliquots of 200  $\mu$ l were processed for aldosterone assay (Radim kit, Italy: KS17CT, RIA method). The results showed increasing linearity (0.007 (0.003); 0.018 (0.004); 0.027 (0.003) nmol/l (mean (SD)); n = 3). As values obtained in SFIF samples were below the lower limit of the assay (0.009 (0.001)), it is conceivable that these cells do not produce aldosterone under basal conditions.<sup>4</sup>

To further validate this observation, we then spiked sera with increasing concentrations of canrenone (10, 50, 100  $\mu$ M) and, subsequently, aldosterone concentrations were determined. Sera were collected from patients with different degrees of liver disease (from acute hepatitis (n = 1), to non-alcoholic steatohepatitis (n = 1), or chronic active hepatitis with (n = 3) or without (n = 6) cirrhosis). Aldosterone concentrations were as follows: 0.32 (0.18), 0.63 (0.22), 0.85 (0.26), and 1.07 (0.35) nmol/l (n = 11). Comparing these concentrations with the increasing concentrations of canrenone spiked into sera, a statistically significance was found (from  $r = 0.874$  to  $r = 0.988$ ;  $p < 0.001$ ).

To date, only positive interferences leading to falsely high digoxin readings, including those due to spironolactone and canrenone, have been reported.<sup>5</sup> Negative interference is much more dangerous. Toxic concentrations may remain undetected. Less severe negative interferences or interferences from clinically less significant cross reactants have been reported. Assay manufacturers should assess potential cross reactivity in the presence of the primary ligand. This difficulty may apply to immunoassays and cross reactants other than digoxin and canrenone. Pathologists and clinicians should be aware of negative interference so that intoxication due to drug dosing guided by monitoring of its concentration in serum can be avoided. For positive interference of a low molecular weight substance, such as in our observation, false positive test results for hormonal and electrolyte disturbances during liver cirrhosis can be avoided.

These in vitro results can be considered effective in measuring aldosterone concentrations in plasma under in vivo conditions using a more cautious approach, as cross

reactivity could hardly affect biological determinations.

**R G Romanelli, P Gentilini**

Università degli Studi di Firenze, Dipartimento di  
Medicina Interna, Viale Morgagni, 85 50134  
Florence, Italy

Correspondence to: Dr R G Romanelli;  
[r.romanelli@dmi.unifi.it](mailto:r.romanelli@dmi.unifi.it)

## References

- 1 **La Villa G**, Barletta G, Romanelli RG, *et al.* Cardiovascular effects of canrenone in patients with preascitic cirrhosis. *Hepatology* 2002;**35**:1441–8.
- 2 **Pugh RNH**, Murray-Lyon IM, Dawson JL. Transection of the esophagus for bleeding esophageal varices. *Br J Surg* 1973;**60**:646–9.
- 3 **Pinzani M**, Failli P, Ruocco C, *et al.* Fat-storing cells as liver-specific pericytes: spatial dynamics of agonist-stimulated intracellular calcium transients. *J Clin Invest* 1992;**90**:642–6.
- 4 **Caligiuri A**, De Franco RMS, Romanelli RG, *et al.* Antifibrogenic effects of canrenone, an antialdosterone drug, on human hepatic stellate cells. *Gastroenterology* 2003;**124**:504–20.
- 5 **Huffman DH**. The effect of spironolactone and canrenone on the digoxin radioimmunoassay. *Res Commun Chem Pathol Pharmacol* 1974;**9**:787–90.

## Responses to endothelin-1 in patients with advanced cirrhosis before and after liver transplantation

In response to Helmy's comments in his recent letter (*Gut* 2004;**53**:470–1), we wish to emphasise the following points, many of which were clearly stated in our original paper.<sup>1</sup>

In agreement with the comments on "generalised vasodilatation" in cirrhosis, we made it clear that basal forearm blood flow was normal in our patient cohort despite the presence of a vasodilated circulation, as evidenced by a reduced systemic vascular resistance index. As pointed out in our paper, this observation is consistent with findings of previous studies and suggests that beds other than the forearm circulation, such as those of the splanchnic and pulmonary circulation, were dilated in our patients.

With regard to the issues raised about the use of one arm plethysmography, our own results and those of others have shown that under well controlled circumstances the effects of external stimuli on results obtained using this approach are minimal.<sup>2</sup> Indeed, in our study, the results of forearm plethysmography were very consistent across both the control and cirrhotic patient groups.<sup>1</sup> However, we acknowledge that single forearm plethysmography could be affected by changes in systemic haemodynamics (due for example to the effects of drug infusions). However, as stated in the text, neither heart rate nor blood pressure altered significantly throughout the course of the experiment.

In forearm resistance arteries (and elsewhere), ET<sub>B</sub> receptors on vascular smooth muscle and endothelial cells mediate opposing effects on vascular tone.<sup>3</sup> Thus ET<sub>B</sub> blockade could result in either vasodilatation or vasoconstriction, depending on which receptor subpopulation is most affected. In our hands, preliminary experiments with the ET<sub>B</sub> blocker BQ788 yielded ambiguous responses, even in control subjects, causing vasoconstriction in some and vasodilatation

in others. Until a selective ET<sub>B</sub> receptor antagonist (for VSMC or endothelium) is available, interpretation of the results obtained using BQ788 remains difficult.

As for the concern that similar vasodilatation was observed with endothelin-1 (ET-1) and BQ123 (an ET<sub>A</sub> antagonist), we wish to re-emphasise these were two very different experiments in two separate groups of patients, asking two different questions. We observed:

- (1) that ET-1 infusion in these advanced cirrhotics produced mild vasodilatation; and
- (2) in similar patients, there was no difference between cirrhotics and controls in the effects of BQ123 on vascular tone.

We put these two results together to propose that it is likely that the abnormal response to ET-1 infusion reflects alterations in ET<sub>B</sub> mediated responses in cirrhotics (either via receptor changes or downstream pathways such as changes in nitric oxide synthesis, prostanoid production, or endothelium derived hyperpolarising factor).

As pointed out by Helmy, there was an early dilatory response following ET-1 infusion in cirrhotics. This is not totally unexpected as it has previously been demonstrated that ET-3 (an ET<sub>B</sub> receptor agonist) causes early vasodilatation in control subjects; similarly, a trend towards an early vasodilatory effect of ET-1 has been observed in healthy subjects.<sup>3</sup>

Regarding the use of concomitant drug therapy, all medications were ceased more than 24 hours prior to the experiments. While some residual effect of these agents is possible, more prolonged cessation of drug therapy in these decompensated patients was not considered safe or ethical. With regard to measurement of ET-1, as detailed in our paper, a commercially available assay with cross reactivity between big ET-1 and ET-1 was used. The study was not powered (nor was it designed to) to pick up small differences in brachial artery ET-1 levels.

**P W Angus, R B Vaughan, J P F Chin-Dusting**

Department of Gastroenterology, Austin Hospital,  
Heidelberg 3084, Australia

Correspondence to: Professor P W Angus;  
[Peter.Angus@austin.org.au](mailto:Peter.Angus@austin.org.au)

## References

- 1 **Vaughan RB**, Angus PW, Chin-Dusting JPF. Evidence for altered vascular responses to exogenous endothelin-1 in patients with advanced cirrhosis with restoration of the normal vasoconstrictor response following successful liver transplantation. *Gut* 2003;**52**:1505–10.
- 2 **Duffy SJ**, Tran BT, Gishel N, *et al.* Continuous release of vasodilator prostanoids contributes to regulation of resting forearm blood flow in humans. *Am J Physiol* 1998;**274**:H1174–83.
- 3 **Haynes WG**, Strachan FE, Gray GA, *et al.* Forearm vasoconstriction to endothelin-1 is mediated by ETA and ETB receptors in vivo in humans. *J Cardiovasc Pharmacol* 1995;**26**:S40–3.

## Cluster's last stand

Guthrie and colleagues (*Gut* 2003;**52**:1616–22) described the results of cluster analysis in a patient sample with severe irritable bowel syndrome (IBS). Their analysis investigated a broad range of factors in addition to symptoms; these included psychosocial measures (psychiatric involvement, health service

encounters, quality of life) and physiological parameters (rectal thresholds). The authors have demonstrated that severe IBS can be classified according to non-symptom characteristics and, in particular, according to the level of psychological distress, service encounters, and rectal sensitivity. They describe three groups which they labelled "distressed high utilisers," "distressed low utilisers", and "tolerant low utilisers." The authors defend their analysis on clinical grounds and point to treatment implications for each of these groups.

We feel that there are some fundamental points about the nature of cluster analysis that readers of this paper should not overlook. Cluster analysis was initially developed to create and/or evaluate classifications.<sup>1</sup> Its application to gastrointestinal research has followed this approach. In recent years, clustering techniques have been applied to confirm that IBS and functional dyspepsia exist as separate clinical entities, and to evaluate specific syndrome subgroups, as described by the current Rome criteria.<sup>2–4</sup> Following traditional clinical approaches, cluster solutions have generally been derived from symptom based parameters, including frequency, severity, and predominant complaint.

The term "cluster analysis" describes a range of procedures which use empirical methods to form groups of highly similar entities. While the notion that cluster analysis is solution seeking, operation of these techniques is essentially solution imposing; that is, clustering methods will *always* place objects into groups. Furthermore, as there are no formal statistical procedures to evaluate the resulting solution, the reasonableness of any solution is determined only on the basis of personal judgement. This is a problem. Indeed, critics of the approach have argued that cluster analysis encourages "naïve empiricism"—that is, inclusion of as many variables as possible in the hope that a meaningful structure will come out.<sup>1,5</sup> However, proponents of cluster analysis have suggested that careful selection of variables on theoretical grounds can overcome this limitation.<sup>1</sup>

It is intuitively obvious that any single entity can be classified according to a broad range of dimensions, and Guthrie *et al* have certainly demonstrated this with respect to IBS. However, we rarely classify any object or entity according to all possible dimensions simultaneously; this would lead to a complex set of descriptors which may be unwieldy and contain many redundancies. Rather, we tend to select out a subset of meaningful dimensions that best suit our purposes in forming a classification.

There are certainly theoretical grounds for considering psychological involvement when evaluating patients with IBS. The association of IBS with psychological disturbance and health care seeking has been well described, and our understanding of these factors has contributed greatly to current therapeutic approaches. However, we challenge the proposed classification of IBS according to psychological involvement on two grounds. Firstly, we view this as a step towards naïve empiricism; other researchers may be encouraged to replicate these analyses across a broader and even more diverse (yet irrelevant) range of dimensions. This is not likely to produce a parsimonious classification scheme that is useful in either clinical practice or the research setting. Secondly, classification of IBS according to psychological and/or psychiatric involvement

may stigmatise some patients with this complaint; one of the unfortunate consequences of classification is the tendency to attach labels to the subgroups that emerge.

#### S C Howell

School of Public Health, The University of Sydney, Nepean Hospital, Penrith, New South Wales, Australia

#### G D Eslick

Department of Medicine, The University of Sydney, Nepean Hospital, Penrith, New South Wales, Australia

#### N J Talley

Center for Enteric Neurosciences and Translational Epidemiological Research (CENTER), Mayo Clinic, Rochester, Minnesota, USA

Correspondence to: Mr S C Howell, School of Public Health, The University of Sydney, Nepean Hospital, Level 5, South Block, PO Box 63, Penrith, NSW 2751, Australia; [HowellS@wahs.nsw.gov.au](mailto:HowellS@wahs.nsw.gov.au)

## References

- 1 Aldenderfer MS, Blashfield RK. *Cluster analysis, Sage University paper series on quantitative application in the social sciences*. New Delhi: Sage Publications, 1984.
- 2 Eslick GD, Howell SC, Hammer J, et al. Empirically derived symptom sub-groups correspond poorly with diagnostic criteria for functional dyspepsia and irritable bowel syndrome. A factor and cluster analysis of a patient sample. *Aliment Pharmacol Ther* 2004;**19**:133–140.
- 3 Talley NJ, Holtmann G, Agreus L, et al. Gastrointestinal symptoms and subjects cluster into distinct upper and lower groupings in the community: a four nations study. *Am J Gastroenterol* 2000;**95**:1439–47.
- 4 Ragnarsson G, Bodemar G. Division of the irritable bowel syndrome into subgroups on the basis of daily recorded symptoms in two outpatient samples. *Scand J Gastroenterol* 1999;**34**:993–1000.
- 5 Everitt B. Unresolved problems in cluster analysis. *Biometrics* 1979;**35**:169–81.

## Small bowel carcinoma and coeliac disease

We thank Howdle *et al* for their comments on our study, detailed recently in their letter (*Gut* 2003;**53**:470). In their British Society of Gastroenterology (BSG) National Survey,<sup>1</sup> Howdle *et al* relied mainly on gastroenterologists and surgeons to report cases of small bowel carcinoma and whether they were associated with either coeliac or Crohn's disease. This may have resulted in underestimation of associated coeliac disease. In our series, we had two cases in which the original pathologist had failed to recognise the histological features of coeliac disease in mucosa adjacent to the adenocarcinoma.<sup>2</sup> The diagnosis of coeliac disease was made after review of the original

resections. This problem has been recognised previously<sup>3</sup> and results in the underdiagnosis of coeliac disease and further diagnostic delay for the patient with coeliac disease.

While the individual risk for patients with coeliac disease in developing adenocarcinoma of the small intestine is not great, poor survival should prompt rapid evaluation when symptoms occur. In addition, there should be a consideration of whether there is a subset of patients with coeliac disease who would benefit from screening for these cancers. Because patients with coeliac disease do not have a significantly increased risk of duodenal adenomas,<sup>4</sup> the role of video capsule endoscopy of the entire small intestine needs to be explored.

#### P H R Green, S D Rampertab

Columbia University College of Physicians and Surgeons, New York, USA

Correspondence to: Dr P H R Green, Columbia University College of Physicians and Surgeons, 161 Fort Washington Ave, Room 645, New York 10032, USA; [pg11@columbia.edu](mailto:pg11@columbia.edu)

## References

- 1 Howdle PD, Jalal PK, Holmes GK, et al. Primary small-bowel malignancy in the UK and its association with coeliac disease. *Q J Med* 2003;**96**:345–53.
- 2 Rampertab SD, Forde KA, Green PH. Small bowel neoplasia in coeliac disease. *Gut* 2003;**52**:1211–14.
- 3 MacGowan DJ, Hourihane DO, Tanner WA, et al. Duodeno-jejunal adenocarcinoma as a first presentation of coeliac disease. *J Clin Pathol* 1996;**49**:602–4.
- 4 Rampertab SD, Fleischauer A, Neugut AI, et al. Risk of duodenal adenoma in celiac disease. *Scand J Gastroenterol* 2003;**38**:831–3.

## RETRACTION

Due to an administrative error, one article has been published on two occasions. The journal would like to retract the paper by Lindsay *et al* in the July issue (*Gut* 2003;**52**:981–7) as it is a replicated version of a paper by the same authors in the March issue (*Gut* 2003;**52**:363–9). The journal apologises for this error.

## NOTICES

### British Society of Gastroenterology Paul Brown Travel Fellowships

The Paul Brown Travel Fellowships are awarded by the Endoscopy Committee of

the BSG. They are intended to assist trainee gastroenterologists and established consultants in visits to units outside the United Kingdom for specialist experience and training in endoscopy.

Specialist registrars who have not achieved their CCST are expected to have the approval of their Postgraduate Dean and their Regional Training Director when they apply for a Travel Fellowship. Applicants are expected to provide confirmation that they have been accepted for training in the unit that they wish to visit.

Successful applicants will be expected to provide a brief written report to the Endoscopy Committee of the outcome of their visit.

Application forms are available from the British Society of Gastroenterology Office, 3 St Andrew's Place, London NW1 4LB. Email: [bsg@mailbox.ucl.ac.uk](mailto:bsg@mailbox.ucl.ac.uk)

### 14<sup>th</sup> International Workshop of Digestive Endoscopy, Ultrasonography and Radiology

The 14<sup>th</sup> International Workshop of Digestive Endoscopy, Ultrasonography and Radiology will be held in Marseille on 27–28 May 2004. For further information, please contact: Nathalie Fontant, Atelier Phenix, 41 rue Docteur Morrucci, 13006 — Marseille (tel: (33) 04-91-37-50-83; fax: (33) 04-91-57-15-28; e-mail: [nfontant@aphenix.com](mailto:nfontant@aphenix.com)).

### European Postgraduate Gastro-surgical School (EPGS) Courses 2004

The EPGS at the Academic Medical Center of the University of Amsterdam will be holding the following courses during the year: 'Benign Hepato-Biliary Disorders' will be held on 22 & 23 April 2004, 'Endosonography live in Amsterdam' will be held on 2, 3 & 4 June 2004, and 'Update in Coloproctology' will be held on 28 & 29 October 2004. For further information, please contact: J Goedkoop (tel: (31) 566 3926; fax: (33) 267 5594; e-mail: [j.goedkoop@amc.uva.nl](mailto:j.goedkoop@amc.uva.nl); website: [www.epgs.nl](http://www.epgs.nl)).

### 8<sup>th</sup> Southeast European Symposium of Paediatric Surgery

The 8<sup>th</sup> Southeast European Symposium of Paediatric Surgery will focus upon 'Infectious Problems in Paediatric Surgery.' The event will be held between 24–25 September 2004, at the University of Graz, Austria. For further information, please contact: Professor M E Höllwarth, Department of Paediatric Surgery, Medical University of Graz, Austria, Auenbruggerplatz 34, 8036 Graz; tel: + 43 316 385 3762; fax: tel: + 43 316 385 3775; e-mail: [kinderchirurgie@uni-graz.at](mailto:kinderchirurgie@uni-graz.at).