

Validation and Clinical Application of Molecular Methods for the Identification of Molds in Tissue

P. J. Paterson,^{1,2} S. Seaton,¹ T. D. McHugh,¹ J. McLaughlin,³ M. Potter,² H. G. Prentice,² and C. C. Kibbler¹

Departments of ¹Medical Microbiology, ²Haematology, and ³Pathology, Royal Free and University College Medical School, Royal Free Campus and Royal Free Hospital, London, United Kingdom

Background. Invasive fungal infections due to less-common molds are an increasing problem, and accurate diagnosis is difficult.

Methods. We used our previously established molecular method, which allows species identification of molds in histological tissue sections, to test sequential specimens from 56 patients with invasive fungal infections who were treated at our institution from 1982 to 2000.

Results. The validity of the method was demonstrated with the establishment of a molecular diagnosis in 52 cases (93%). Confirmation of the causative organism was made in all cases in which a mold had been cultured from the tissue specimen. Less-common molds were identified in 7% of cases and appear to be an increasing problem.

Conclusions. Our previously established method has proven to be of value in determining the incidence of invasive infection caused by less-common molds. Institutions should continue to pursue diagnosis of invasive fungal infections by means of tissue culture and microbiologic analysis.

There is a gradual and significant shift toward new fungal opportunists in the etiology of invasive fungal infection (IFI) [1, 2]. Diagnosis of IFI is difficult, and new methods are required that allow species identification in histologically proven cases.

Many fungi have similar histological features, and hyphae tend to be identified as representing *Aspergillus* species by default. Species identification can be achieved with tissue culture, but this method only yields a result in ~50% of cases [34–5]. Immunohistochemical [6, 7] and in situ hybridization techniques [8–13] have been evaluated, but their use is restricted to very few pathogens. PCR amplification of fungal DNA extracted from both fresh [14] and formalin-fixed paraffin-embedded (wax) [4] tissue sections has been reported.

Until recently, routine resection of pulmonary fungal lesions was performed in all operable cases in our institution [15], providing an invaluable collection of ar-

chived tissue samples. A number of tissue samples have also been obtained by diagnostic biopsy and postmortem examination.

We have previously described a molecular method capable of identifying fungal pathogens in wax tissue sections [16]. The aim of this study was to confirm the validity of this method by testing our collection of tissue samples and, in doing so, determine the incidence of IFI due to less-common molds in our institution. Cases of zygomycosis were not investigated, because their histological appearances are characteristic.

MATERIALS AND METHODS

Wax tissue specimens from 56 patients treated in the hematology department of the Royal Free Hospital between 1982 and 2000 who had histologically-proven IFI suggestive infection with of a mold not from the Zygomycetes family were identified from pathology records. Ten-micrometer sections were cut from each specimen; a new sterile blade was used for each one (outer sections were discarded).

Mycological culture results for the 56 patients were analyzed and were used to divide the patients into groups. Group A was made up of patients with a tissue culture positive for *Aspergillus fumigatus* or *Aspergillus*

Received 10 December 2004; accepted 4 August 2005; electronically published 29 November 2005.

Reprints or correspondence: Dr. C. C. Kibbler, Consultant Microbiologist, Dept. of Medical Microbiology, Royal Free Hospital, Pond St., London NW3 2QG, United Kingdom (c.kibbler@medsch.ucl.ac.uk).

Clinical Infectious Diseases 2006;42:51–6

© 2005 by the Infectious Diseases Society of America. All rights reserved.
1058-4838/2006/4201-0008\$15.00

Table 1. Results of culture and molecular analysis of tissue samples from 56 patients who had invasive fungal infections from 1982 to 2000.

Patient, by group	Year	Tissue sample used for testing	Culture analysis			Molecular analysis		
			Tissue culture result	Other culture performed	Fungus identified	PCR result	Southern blot result	Fungus or fungi identified
Group A								
1	1984	Resected lung	+	...	<i>A. fumigatus</i>	+	+	<i>A. fumigatus</i> or <i>A. flavus</i>
2	1986	Bronchial biopsy	+	BAL fluid and sputum	<i>Aspergillus</i> species	-	+	<i>A. fumigatus</i> or <i>A. flavus</i>
3	1986	PM lung	+	...	<i>A. flavus</i>	+	+	<i>A. fumigatus</i> or <i>A. flavus</i>
	1986	PM heart	+	+	<i>A. fumigatus</i> or <i>A. flavus</i>
	1986	PM kidney	-	-	<i>A. fumigatus</i> or <i>A. flavus</i>
4	1988	Resected lung	+	...	<i>A. fumigatus</i>	+	+	<i>A. fumigatus</i> or <i>A. flavus</i>
5	1988	Resected lung	+	...	<i>A. flavus</i>	+	+	<i>A. fumigatus</i> or <i>A. flavus</i>
6	1989	Resected lung	+	...	<i>A. fumigatus</i>	+	+	<i>A. fumigatus</i> or <i>A. flavus</i>
7	1989	Resected lung	+	...	<i>A. fumigatus</i>	+	+	<i>A. fumigatus</i> or <i>A. flavus</i>
8	1990	Resected lung	+	...	<i>A. fumigatus</i>	+	+	<i>A. fumigatus</i> or <i>A. flavus</i>
9	1990	Resected lung	+	...	<i>A. fumigatus</i>	-	+	<i>A. fumigatus</i> or <i>A. flavus</i>
10	1991	Resected lung	+	...	<i>A. fumigatus</i>	-	+	<i>A. fumigatus</i> or <i>A. flavus</i>
11	1991	Resected lung	+	...	<i>A. flavus</i>	+	+	<i>A. fumigatus</i> or <i>A. flavus</i>
12	1991	Resected lung	+	...	<i>A. fumigatus</i>	+	+	<i>A. fumigatus</i> or <i>A. flavus</i>
13	1991	PM lung	+	...	<i>A. fumigatus</i>	-	+	<i>A. fumigatus</i> or <i>A. flavus</i>
14	1991	Resected lung	+	...	<i>A. fumigatus</i>	-	+	<i>A. fumigatus</i> or <i>A. flavus</i>
15	1992	Resected lung	+	BAL fluid	<i>A. fumigatus</i>	+	+	<i>A. fumigatus</i> or <i>A. flavus</i>
16	1993	Resected lung	+	...	<i>A. fumigatus</i>	+	+	<i>A. fumigatus</i> or <i>A. flavus</i>
17	1993	Resected lung	+	...	<i>A. fumigatus</i>	+	+	<i>A. fumigatus</i> or <i>A. flavus</i>
18	1994	Resected lung	+	BAL fluid and BC	<i>A. flavus</i>	+	+	<i>A. fumigatus</i> or <i>A. flavus</i>
	1994	Biopsy upper limb mass	-	-	+	<i>A. fumigatus</i> or <i>A. flavus</i>
19	1994	Nasal mucosa biopsy	+	...	<i>A. flavus</i>	-	+	<i>A. fumigatus</i> or <i>A. flavus</i>
20	1995	Resected lung	+	...	<i>A. flavus</i>	+	+	<i>A. fumigatus</i> or <i>A. flavus</i>
21	1996	Nasal mucosa biopsy	+	...	<i>A. flavus</i>	-	+	<i>A. fumigatus</i> or <i>A. flavus</i>
22	1998	Resected lung	+	...	<i>A. flavus</i>	+	+	<i>A. fumigatus</i> or <i>A. flavus</i>
23	1999	Sinus biopsy	-	...	<i>A. fumigatus</i>	-	+	<i>A. fumigatus</i> or <i>A. flavus</i>
	1999	Sinus biopsy	+	+	+	<i>A. fumigatus</i> or <i>A. flavus</i>
Group B								
24	1994	Resected lung	+	...	<i>C. globosum</i>	+	-	<i>C. globosum</i>
25	1997	Resected lung	+	BAL fluid and sputum	<i>S. apiospermum</i>	+	-	<i>S. apiospermum</i>
Group C								
26	1985	PM lung	-	BAL fluid	<i>A. fumigatus</i>	+	+	<i>A. fumigatus</i> or <i>A. flavus</i>
27	1989	Resected lung	-	TS and sputum	<i>A. flavus</i>	+	+	<i>A. fumigatus</i> or <i>A. flavus</i>
28	1994	Resected lung	-	Vitreous fluid	<i>A. fumigatus</i>	+	+	<i>A. fumigatus</i> or <i>A. flavus</i>
29	1996	Soft palate	-	Sputum	<i>A. fumigatus</i>	+	-	<i>C. glabrata</i>
30	1997	Skin biopsy	-	BAL fluid and BC	<i>A. flavus</i>	-	+	<i>A. fumigatus</i> or <i>A. flavus</i>
31	1997	PM lung	-	BAL fluid	<i>A. fumigatus</i>	-	-	...
Group D								
32	1982	PM lung	-	+	+	<i>A. fumigatus</i> or <i>A. flavus</i>
33	1984	PM lung	-	-	-	...
34	1985	Resected lung	-	+	+	<i>A. fumigatus</i> or <i>A. flavus</i>
35	1985	PM lung	-	+	+	<i>A. fumigatus</i> or <i>A. flavus</i>
	1985	PM brain	+	+	<i>A. fumigatus</i> or <i>A. flavus</i>
36	1988	Thyroid biopsy	-	-	+	<i>A. fumigatus</i> or <i>A. flavus</i>
37	1989	Resected lung	-	-	+	<i>A. fumigatus</i> or <i>A. flavus</i>
38	1990	Resected lung	-	+	+	<i>A. fumigatus</i> or <i>A. flavus</i>
39	1991	PM lung	-	-	+	<i>A. fumigatus</i> or <i>A. flavus</i>
	1991	PM intestine	-	+	<i>A. fumigatus</i> or <i>A. flavus</i>

(continued)

Table 1. (Continued.)

Patient, by group	Year	Tissue sample used for testing	Culture analysis			Molecular analysis		
			Tissue culture result	Other culture performed	Fungus identified	PCR result	Southern blot result	Fungus or fungi identified
40	1991	Resected lung	—	+	+	<i>A. fumigatus</i> or <i>A. flavus</i>
41	1992	Resected lung	—	—	—	...
42	1992	Resected lung	—	+	+	<i>A. fumigatus</i> or <i>A. flavus</i>
43	1992	Resected lung	—	+	—	Probable <i>Alternaria</i> species
44	1992	Resected lung	—	+	+	<i>A. fumigatus</i> or <i>A. flavus</i>
45	1992	Resected lung	—	—	+	<i>A. fumigatus</i> or <i>A. flavus</i>
46	1993	Resected lung	—	+	+	<i>A. fumigatus</i> or <i>A. flavus</i>
47	1994	Brain biopsy	—	—	—	<i>A. fumigatus</i> or <i>A. flavus</i>
	1994	PM lung	+	+	<i>A. fumigatus</i> or <i>A. flavus</i>
	1994	PM heart	+	+	<i>A. fumigatus</i> or <i>A. flavus</i>
	1994	PM kidney	—	+	<i>A. fumigatus</i> or <i>A. flavus</i>
	1994	PM brain	+	+	<i>A. fumigatus</i> or <i>A. flavus</i>
48	1995	Resected lung	—	+	+	<i>A. fumigatus</i> or <i>A. flavus</i>
49	1995	Resected lung	—	+	+	<i>A. fumigatus</i> or <i>A. flavus</i>
50	1995	Resected lung	—	—	+	<i>A. fumigatus</i> or <i>A. flavus</i>
51	1995	PM lung	—	+	—	Unidentified
52	1996	Resected lung	—	—	+	<i>A. fumigatus</i> or <i>A. flavus</i>
53	1996	Resected lung	—	—	+	<i>A. fumigatus</i> or <i>A. flavus</i>
	1996	Resected lung	—	+	<i>A. fumigatus</i> or <i>A. flavus</i>
54	1997	Resected lung	—	+	+	<i>A. fumigatus</i> or <i>A. flavus</i>
55	1997	Resected lung	—	+	+	<i>A. fumigatus</i> or <i>A. flavus</i>
56	2000	PM lung	—	+	+	<i>A. fumigatus</i> or <i>A. flavus</i>

NOTE. *A. flavus*, *Aspergillus flavus*; *A. fumigatus*, *Aspergillus fumigatus*; BAL, bronchoalveolar lavage; BC, blood cultures; *C. glabrata*, *Candida glabrata*; *C. globosum*, *Chaetomium globosum*; PM, postmortem; *S. apiospermum*, *Scedosporium apiospermum*; TS, throat swab.

flavus; group B patients had a tissue culture positive for a less-common mold; group C patients had a negative tissue culture result but a positive result of culture of a sample from another site (e.g., from a bronchoalveolar lavage fluid specimen); and group D patients had no positive tissue culture results.

In addition to archived wax sections of normal lung tissue, specimens of tissue with histological evidence of other infective pathogens—including *Mycobacterium tuberculosis*, cytomegalovirus, *Pneumocystis jiroveci*, and gram-positive cocci—were used as controls.

DNA was extracted using a method based on the TaKaRa Dexpat kit (TaKaRa Biomedicals), as described elsewhere [16]. Panfungal primers were used for PCR amplification, and Southern blot hybridization was performed using a DNA probe specific for *A. fumigatus*, *A. flavus*, and *Aspergillus versicolor* [16, 17]. PCR products that did not hybridize with the probe, despite attempts, were purified with the Wizard PCR Preps DNA Purification System (Promega). Purified DNA was sequenced commercially (by Cytomyx, Cambridge, United Kingdom), and sequence analysis was performed with the Emboss software package (Human Genome Mapping Project–Resource Center, UK Medical Research Council). Sequences were identified using a BLAST search of GenBank and European Molecular Biology Laboratory (EMBL) nucleotide sequence databases.

RESULTS

Sixty-seven wax tissue specimens from 56 patients with IFI were tested (table 1). Species identification for groups A and B correlated with results of tissue culture, confirming the validity of the method. Sequence analysis of DNA from patient 24 (group B) confirmed infection with *Chaetomium globosum*, and sequence data were submitted to the EMBL nucleotide sequence database (accession number AJ781794). The isolate cultured from the lung tissue of patient 24 has been added to the UK National Collection of Pathogenic Fungi (NCPF catalog number 7115). Sequencing of genomic DNA from a subculture of this isolate yielded a sequence that was identical to that obtained from the tissue sample, which confirmed the causative role of this organism in this case. Likewise, the results of the sequence analysis of DNA extracted from tissue samples and the clinical isolate cultured from a tissue sample from patient 25 (group B) were identical, and both were identified as *Scedosporium apiospermum* (EMBL nucleotide sequence database accession number AJ812012).

In group C, 6 patients had negative tissue culture results, but cultures of samples from other sites were positive for *A. fumigatus* or *A. flavus*. IFI due to *A. fumigatus* or *A. flavus* was molecularly confirmed in 4 (67%) of these patients. Patient 29

```

P 1   tagcgatatattaagttggtgcagttaaaaagctcgtagttgaaacttgggcctggctgg 60
      |||
A 30   tagcgatatattaagttggtgcagttaaaaagctcgtagttgaaacttgggcctggctgg 89
      |||
M 534  tagcgatatattaagttggtgcagttaaaaagctcgtagttgaaacttgggcctggctgg 593
      |||
U 515  tagcgatatattaagttggtgcagttaaaaagctcgtagttgaaacttgggcctggctgg 574

P 61   cgggtccgcctcaccggtgcactcgtccggccgggccttccttctgaagaacctcatgc 120
      |||
A 90   cgggtccgcctcaccggtgcactcgtccggccgggccttccttctgaagaacctcatgc 149
      |||
M 594  cgggtccgcctcaccggtgcactcgtccggccgggccttccttctgaagaacctcatgc 653
      |||
U 575  cgggtccgcctcaccggtgcactcgtccggccgggccttccttctgaagaacctcatgc 634

P 121  ccttcactgggcgtgtctggggaatcaggacttttactttgaaaaattagagtgttca 179
      |||
A 150  ccttcactgggcgtg-ctggggaatcaggacttttactttgaaaaattagagtgttca 207
      |||
M 654  ccttcactgggcgtg-ctggggaatcaggacttttactttgaaaaattagagtgttca 711
      |||
U 635  ccttcactgggcgtg-ctggggaatcaggacttttactttgaaaaattagagtgttca 692

```

Figure 1. Comparison of sequences of DNA from patient 43 (P). A, *Alternaria alternata* (accession number AY669336); M, *Alternaria malorum* (accession number AY251131); and U, *Ulocladium botrytis* (accession number AF548106).

had a positive PCR result, but the results of Southern blotting were negative. Sequencing of purified DNA revealed *Candida glabrata* (EMBL nucleotide sequence database accession number AJ842962). Cultures of sputum samples initially yielded a scanty growth of *A. fumigatus* and subsequently grew *C. glabrata*. Histological examination revealed that necrotic tissue had extensively infiltrated by branched, septate fungal hyphae, in keeping with *Aspergillus* infection, along with numerous *Candida* spores on the surface of the material. Therefore, only the colonizing organism was identified by molecular analysis. The results of culture were negative for patient 31, and histological examination revealed only small clusters of *Aspergillus* organisms in alveolar walls.

Of the 25 patients with no positive fungal culture results (group D), it was possible to establish a diagnosis of infection with *A. fumigatus* or *A. flavus* in 21 (84%). Samples from patients 43 and 51 yielded positive PCR results but negative Southern blot results. A short sequence of 179 bases was available for analysis from patient 43 (EMBL nucleotide sequence database accession number AJ850082). Using a BLAST search, we found this sequence to have a high degree of homology with *Alternaria alternata*, and other *Alternaria* species (*Alternaria malorum*, *Alternaria selini*, *Alternaria petroselini*, *Alternaria japonica*, *Alternaria brassicicola*, and *Alternaria raphani*) and *Ulocladium* species (*Ulocladium botrytis*, *Ulocladium atrum*, and *Ulocladium alternariae*) (figure 1). Attempts to sequence

DNA from patient 51 failed, despite the preparation of PCR amplimers on separate occasions. The cause of infection in this patient's case was thought to be a mold other than *A. fumigatus* or *A. flavus*. The diagnosis could not be confirmed for patients 33 and 41, because the results of both PCR and Southern blot hybridization were negative. Histological examination of patient 33 revealed only that scanty *Aspergillus* had been seen.

Results are summarized in table 2. In total, a diagnosis of IFI caused by *A. fumigatus* or *A. flavus* was made in 48 cases (86%), and a diagnosis of IFI due to less-common molds was made in 4 cases (7%). A molecular diagnosis could not be established in 4 cases (7%). Results for all control samples were as expected.

The 4 cases of IFI due to less-common molds occurred in the 1990s: case 1 (1992) was probably caused by *Alternaria* species, case 2 (1994) was caused by *Chaetomium globosum*, case 3 (1995) was caused by an unidentified mold, and case 4 (1997) was caused by *Scedosporium apiospermum* (figure 2). Cases of histologically-confirmed zygomycosis that occurred in our institution over this time period are also shown in figure 2.

DISCUSSION

The results of this study—species identification achieved in 52 (93%) of 56 cases—confirm the validity and clinical applicability of our previously developed method for identifying molds

Table 2. Summary of the results of culture and molecular analysis of tissue samples from 56 patients.

Group(s)	Group definition	No. (%) of patients with a positive molecular diagnosis, by mold(s) and method(s)				No. (%) of patients with a non-diagnostic molecular test result	Total no. of patients
		<i>Aspergillus fumigatus</i> or <i>Aspergillus flavus</i>			Less-common molds, by PCR and sequence		
		PCR and blot	Blot only	Any method			
Group A	Tissue culture result positive for <i>A. fumigatus</i> or <i>A. flavus</i>	16 (70)	7 (30)	23 (100)	0 (0)	0 (0)	23
Group B	Tissue culture result positive for other fungus	0 (0)	0 (0)	0 (0)	2 (100)	0 (0)	2
Group C	Tissue culture result negative, result of culture specimen from other site positive	3 (50)	1 (17)	4 (67)	0 (0)	2 (33)	6
Group D	Culture result negative	14 (56)	7 (28)	21 (84)	2 (8)	2 (8)	25
All groups	...	33 (59)	15 (27)	48 (86)	4 (7)	4 (7)	56

in wax tissue specimens. This compares favorably with results published by Willinger et al. [4], who used molecular methods to test wax tissue sections from patients with proven IFI of the maxillary sinuses, and who achieved species identification in 58% of cases.

Confirmation of the causative organism was made in all cases that had positive tissue culture results. Of the cases that had negative tissue culture results, molecular identification was not achieved in 4. These cases may have been caused by less-common molds, and the quantity of DNA extracted might have been insufficient for detection by PCR alone. However, in 2

cases, only scant hyphae were noted on histological examination, and therefore, *A. fumigatus* or *A. flavus* DNA may not have been detected, even after Southern blotting. Only the colonizing organism was identified in patient 29 (in group C).

Definitive identification of the mold in the specimen from patient 43 (in group D) was difficult because of the shortness of the DNA sequence that was suitable for analysis and the high degree of sequence homology that exists between *Alternaria* species and *Ulocladium* species. It is likely that the causative organism in this case was an *Alternaria* species, although the sequence was also highly homologous with *Ulocladium* spe-

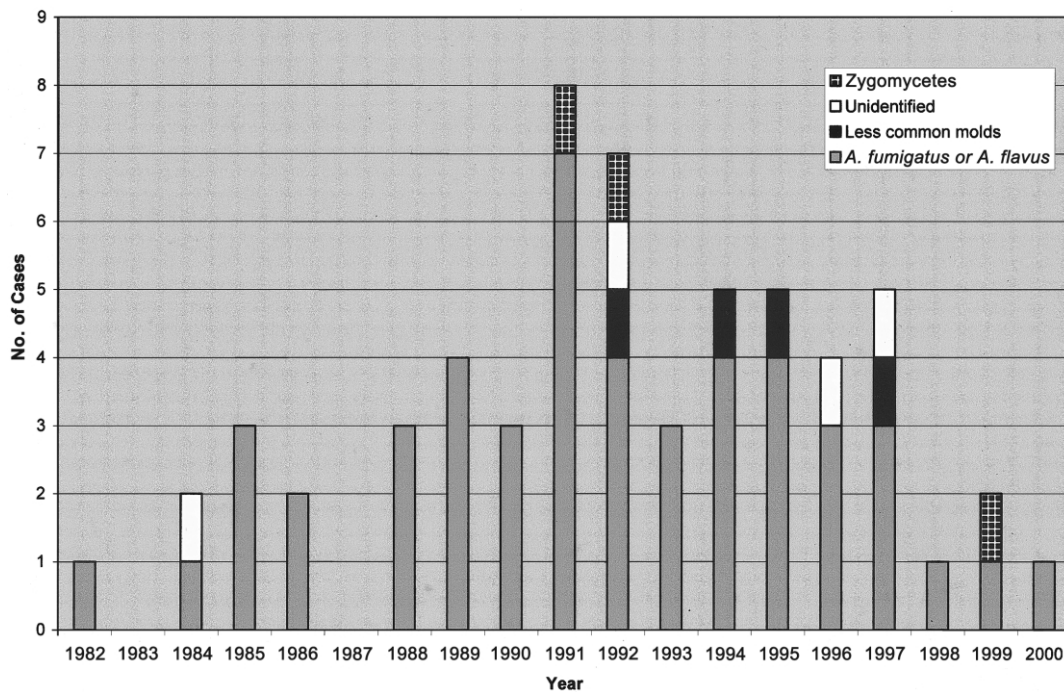


Figure 2. Temporal distribution of proven cases of invasive fungal infection at Royal Free Hospital, London, United Kingdom, 1982–2000

cies. Both *Alternaria* and *Ulocladium* species are dematiaceous fungi that usually act as soil saprophytes and plant pathogens. Some *Alternaria* species, most commonly *A. alternata*, are recognized causes of IFI [18, 19]. To date, *Ulocladium* species have only been reported to cause cutaneous infections [20].

Our method revealed that the incidence of IFI due to less-common molds in our institution was 7% (4 of 56 cases of IFI). There were no clinical, radiological, or histological features to indicate an unusual cause of infection in any of these cases. We have previously reported details of the case of *C. globosum* infection in patient 24 [21, 22]. The 4 patients in whom IFI was caused by less-common molds were profoundly immunocompromised, and it is easier for low-virulence organisms to take hold and cause infection in such clinically high-risk patients. In addition, antifungal prophylaxis had been administered to these 4 patients for prolonged periods, and this may have allowed more-resistant molds to be selected. A major concern regarding the emergence of these molds is that they are not universally susceptible to amphotericin B. Despite therapy, all 4 patients died, and all had documented evidence of active IFI at the time of death.

It appears that the incidence of infection with less-common molds may be increasing. All 4 cases caused by less-common molds in our institution occurred in the 1990s, as did 3 cases in which the diagnosis was not confirmed by molecular methods and 3 cases of zygomycosis (figure 2). The overall incidence of IFI with less-common molds in our institution from 1982 to 2000 is therefore 12% (7 of 59 cases of IFI).

In conclusion, given the increasing incidence of infection with less-common molds that have varying sensitivity to antifungal agents, institutions should continue to vigorously pursue diagnosis of IFI by means of tissue culture and microbiologic analysis. Our method is a valuable diagnostic tool for both patient management and future epidemiological and diagnostic studies.

Acknowledgments

We thank Linda Boxer and the staff of the Pathology Department of the Royal Free Hospital, for cutting the tissue samples, and the medical and nursing staff in the Haematology Department of the Royal Free Hospital, including Professor A. V. Hoffbrand and Dr. A. B. Mehta.

Financial support. Nexstar Pharmaceuticals (educational grant to P.J.P.).

Potential conflicts of interest. All authors: no conflicts.

References

1. Perfect JR, Schell WA. The new fungal opportunists are coming. *Clin Infect Dis* **1996**; 22(Suppl 2):S112–8.
2. Marr KA, Carter RA, Crippa F, Wald A, Corey L. Epidemiology and outcome of mould infections in hematopoietic stem cell transplant recipients. *Clin Infect Dis* **2002**; 34:909–17.
3. Tarrand JJ, Lichterfield M, Warraich I, et al. Diagnosis of invasive septate mold infections: a correlation of microbiological culture and histologic or cytologic examination. *Am J Clin Path* **2003**; 119:854–8.
4. Willinger B, Obradovic A, Selitsch B, et al. Detection and identification of fungi from fungus balls of the maxillary sinus by molecular techniques. *J Clin Microbiol* **2003**; 41:581–5.
5. Yeghen T, Kibbler CC, Prentice HG, et al. Management of invasive pulmonary aspergillosis in hematology patients: a review of 87 consecutive cases at a single institution. *Clin Infect Dis* **2000**; 31:859–68.
6. Verweij PE, Smedts F, Poot T, Bult P, Hoogkamp-Korstanje JA, Meis JF. Immunoperoxidase staining for identification of *Aspergillus* species in routinely processed tissue sections. *J Clin Path* **1996**; 49:798–801.
7. Kaufman L, Standard PG, Jalbert M, Kraft DE. Immunohistologic identification of *Aspergillus* spp. and other hyaline fungi by using polyclonal fluorescent antibodies. *J Clin Microbiol* **1997**; 35:2206–9.
8. Montone KT, Litzky LA. Rapid method for detection of *Aspergillus* 5S ribosomal RNA using a genus-specific oligonucleotide probe. *Am J Clin Path* **1995**; 103:48–51.
9. Park CS, Kim J, Montone KT. Detection of *Aspergillus* ribosomal RNA using biotinylated oligonucleotide probes. *Diagn Mol Pathol* **1997**; 6: 255–60.
10. Perez-Jaffe LA, Lanza DC, Loevner LA, Kennedy DW, Montone KT. In situ hybridisation for *Aspergillus* and *Penicillium* in allergic fungal sinusitis: a rapid means of speciating fungal pathogens in tissues. *Laryngoscope* **1997**; 107:233–40.
11. Kobayashi M, Sonobe H, Ikezoe T, Hakoda E, Ohtsuki Y, Taguchi H. In situ detection of *Aspergillus* 18S ribosomal RNA in invasive pulmonary aspergillosis. *Intern Med* **1999**; 38:563–9.
12. Hanazawa R, Murayama SY, Yamaguchi H. In-situ detection of *Aspergillus fumigatus*. *J Med Microbiol* **2000**; 49:285–90.
13. Hayden RT, Qian X, Roberts GD, Lloyd RV. In situ hybridisation for the identification of yeastlike organisms in tissue section. *Diagn Mol Pathol* **2001**; 10:15–23.
14. Hendolin PH, Paulin L, Koukila-Kahkola P, et al. Panfungal PCR and multiplex liquid hybridisation for detection of fungi in tissue specimens. *J Clin Microbiol* **2000**; 38:4186–92.
15. McWhinney PHM, Kibbler CC, Hamon MD, et al. Progress in the diagnosis and management of aspergillosis in bone marrow transplantation: 13 year's experience. *Clin Infect Dis* **1993**; 17:397–404.
16. Paterson PJ, Seaton S, McLaughlin J, Kibbler CC. Development of molecular methods for the identification of *Aspergillus* and emerging moulds in wax tissue sections. *Mol Pathol* **2003**; 56:368–70.
17. Einsele H, Hebart H, Roller G, et al. Detection and identification of fungal pathogens in blood by using molecular probes. *J Clin Microbiol* **1997**; 35:1353–60.
18. Rossmann SN, Cernoch PL, Davis JR. Dematiaceous fungi are an increasing cause of human disease. *Clin Infect Dis* **1996**; 22:73–80.
19. Revankar SG, Patterson JE, Sutton DA, Pullen R, Rinaldi MG. Disseminated phaeohyphomycosis: review of an emerging mycosis. *Clin Infect Dis* **2002**; 34:467–76.
20. Duran MT, Pozo JD, Yebra MT, et al. Cutaneous infection caused by *Ulocladium chartarum* in a heart transplant recipient: case report and review. *Acta Derm Venereol* **2003**; 83:218–21.
21. Yeghen T, Fenelon L, Campbell CK, et al. *Chaetomium* pneumonia in patient with acute myeloid leukaemia. *J Clin Pathol* **1996**; 49:184–6.
22. Paterson PJ, Seaton S, Yeghen T, et al. Molecular confirmation of invasive infection caused by *Chaetomium globosum*. *J Clin Pathol* **2005**; 58:334.