

Epidemiology and Infection

<http://journals.cambridge.org/HYG>


Additional services for *Epidemiology and Infection*:

Email alerts: [Click here](#)

Subscriptions: [Click here](#)

Commercial reprints: [Click here](#)

Terms of use : [Click here](#)



Incidence of symptomatic toxoplasma eye disease: aetiology and public health implications

R. E. GILBERT, D. T. DUNN, S. LIGHTMAN, P. I. MURRAY, C. E. PAVESIO, P. D. GORMLEY, J. MASTERS, S. P. PARKER and M. R. STANFORD

Epidemiology and Infection / Volume 123 / Issue 02 / October 1999, pp 283 - 289
DOI: null, Published online: 08 September 2000

Link to this article: http://journals.cambridge.org/abstract_S0950268899002800

How to cite this article:

R. E. GILBERT, D. T. DUNN, S. LIGHTMAN, P. I. MURRAY, C. E. PAVESIO, P. D. GORMLEY, J. MASTERS, S. P. PARKER and M. R. STANFORD (1999). Incidence of symptomatic toxoplasma eye disease: aetiology and public health implications. *Epidemiology and Infection*, 123, pp 283-289

Request Permissions : [Click here](#)

Incidence of symptomatic toxoplasma eye disease: aetiology and public health implications

R. E. GILBERT^{1*}, D. T. DUNN¹, S. LIGHTMAN², P. I. MURRAY³, C. E. PAVESIO²,
P. D. GORMLEY², J. MASTERS¹, S. P. PARKER¹ AND M. R. STANFORD⁴

¹ Department of Epidemiology and Public Health, Institute of Child Health, University College London Medical School, 30 Guilford Street, London WC1N 1EH, UK

² Department of Clinical Ophthalmology, Institute of Ophthalmology, Moorfield's Eye Hospital, City Road, London EC1 2PD, UK

³ Academic Unit of Ophthalmology, The University of Birmingham, Birmingham and Midland Eye Centre, City Road NHS Trust, Dudley Road, Birmingham B18 7QU, UK

⁴ Medical Eye Unit, St Thomas' Hospital, London SE1 7EH, UK

(Accepted 14 May 1999)

SUMMARY

Ocular disease is the commonest disabling consequence of toxoplasma infection. Incidence and lifetime risk of ocular symptoms were determined by ascertaining affected patients in a population-based, active reporting study involving ophthalmologists serving a population of 7·4 million. Eighty-seven symptomatic episodes were attributed to toxoplasma infection. Bilateral visual acuity of 6/12 or less was found in seven episodes (8%) and was likely to have been transient in most cases. Black people born in West Africa had a 100-fold higher incidence of symptoms than white people born in Britain. Only two patients reported symptoms before 10 years of age. The estimated lifetime risk of symptoms in British born individuals (52% of all episodes) was 18/100000 (95% confidence interval: 10·8–25·2). The low risk and mild symptoms in an unscreened British population indicate limited potential benefits of prenatal or postnatal screening. The late age at presentation suggests a mixed aetiology of postnatally acquired and congenital infection for which primary prevention may be appropriate, particularly among West Africans.

INTRODUCTION

In many European countries, considerable resources (at least \$48 million per year in France alone, 1992 prices [1]) are devoted to screening to reduce the risks of congenital toxoplasmosis [2–5]. Acquisition of toxoplasma infection outside pregnancy is rarely considered to be a public health problem.

The benefits of prenatal or postnatal screening for congenital toxoplasmosis depend on the risk of symptoms in the absence of screening and the effectiveness of treatment in reducing this risk. In

symptomatic patients, congenital toxoplasmosis most commonly causes ocular symptoms manifest as episodes of transient visual loss and pain during child and adulthood due to reactivation of latent cysts and the formation of new retinochoroidal lesions. Affected individuals may also present with signs or symptoms of permanent visual impairment due to lesions arising within the macular vascular arcade. In five prospective cohort studies [1a, 2, 6–8] 29/102 (28%) congenitally infected children developed retinochoroidal lesions, but in 4 of these follow-up was limited to 1–6 years of age. In one study, 11 congenitally infected individuals were examined at 20 years of age and retinochoroidal

* Author for correspondence.

lesions were detected in 9 (82%), in 7 of these before 7 years of age [6].

Toxoplasma retinochoroidal lesions are considered to originate from congenital infection except where there is clear evidence of acquired toxoplasmosis [9–12]. This view is difficult to challenge as serological evidence to date infection as congenital or postnatally acquired is rarely available. Nevertheless, the pattern of ocular disease described in cohort studies of congenitally infected children differs from that seen by ophthalmologists. Most patients present aged 10–40 years with acute onset of pain and visual impairment lasting 6–8 weeks [13, 14] due to reactivation of latent toxoplasma cysts.

In Britain, screening for congenital toxoplasmosis is not routinely offered due to the lack of information on the burden of preventable disease [15]. The aim of this study was to estimate the lifetime risk and describe the clinical severity of symptoms associated with retinochoroidal lesions in an unscreened, British-born population. Secondly, we assessed variation in the incidence of symptoms by country of birth and ethnic group in order to identify high risk groups. Lastly, we compared the age at onset of symptoms in our patients with that reported in cohort studies of congenitally infected children. We established a population-based, active reporting scheme among ophthalmologists serving a population of 7.4 million to ascertain patients presenting with any symptoms suspected to be due to toxoplasma infection.

METHOD

Reporting scheme

An 'active' monthly reporting scheme was established among 25 ophthalmology units serving 39 districts in 4 areas of England: south Greater London (12 districts, population 2 574 000), North East Greater and outer metropolitan London (14 districts, population 1 973 000 and 9 districts, population 1 012 000 respectively), Leicester metropolitan district (1 district, population 266 000), and Birmingham (3 districts, population 1 435 000). Two ophthalmology units sited outside the four regions were used to detect patient drift.

In each unit the ophthalmologist who would usually see patients with toxoplasma retinochoroiditis received a monthly card asking whether or not any cases of suspected symptomatic toxoplasma eye disease had been seen in the unit within the previous month.

Efforts to improve ascertainment included placing study information packs in each outpatient and casualty department to remind staff to refer all suspected cases, publicising the study at local ophthalmology meetings, sending a newsletter to all units, and sending reminders by post and telephone if cards were not returned.

The scheme operated over 18 months from January 1994 to July 1995 and involved 19 reporting ophthalmologists in 25 units (due to local referral patterns, 3 ophthalmologists reported cases for several units). Sixteen of 19 ophthalmologists returned at least 80% of the monthly report cards, two reported patients retrospectively and one never responded. Five ophthalmologists reported no patients during the study period.

Data collection

For each case, the reporting ophthalmologist recorded age, postcode, country of birth and ethnic group (using the 1991 census terms), clinical presentation and signs, and dates at similar previous episodes. They were also asked to attribute each patient's findings to toxoplasmosis as follows: definite (retinitis with cells present in vitreous in association with one or more pigmented retinochoroid scars in the same eye); probable (retinitis with cells present in vitreous with one or more pigmented retinochoroid scars in the contralateral eye); and possible (severe vitritis obscuring retinal detail but retinal inflammation or scar identifiable).

Serum samples were analysed centrally for toxoplasma-specific antibodies using the EIKEN agglutination test [16] and ISAGA for specific IgM [17]. All IgM positive samples, EIKEN and ISAGA negative samples and an unselected sample of others were sent for confirmatory testing using the dye test and ISAGA IgM test at the Regional Reference Laboratory (St George's Hospital Medical School, London).

Incidence estimates were derived using patients resident within the study area as the numerator and residents of all ages according to country of birth and ethnic group for each district as the denominator (obtained from the National Census, 1991 local base statistics, Office for Population Censuses and Surveys). The annual incidence of all symptomatic episodes, whether first or repeat, reflects overall morbidity due to the risk of the disease and risk of recurrence. However, the risk of ever having symptomatic toxoplasma retinochoroiditis (lifetime risk) is

also important to individuals. Lifetime risk was calculated from the cumulative lifetime risk of symptoms by age 60 years [18] based on patients presenting with a first symptomatic episode as inclusion of repeat episodes would have introduced referral bias. This estimation was limited to patients born in Britain or West Africa due to small numbers in other ethnic groups.

RESULTS

A total of 112 patients was reported during the study period of whom 103 fulfilled the criteria of symptomatic eye disease suspected to be due to toxoplasma infection. Of the 9 excluded, 2 had been detected by optometrists during routine eye examination for refractory errors and were asymptomatic (i.e. no visual impairment or acute symptoms of reactivation); 3 had serum samples taken but no clinical data (1 was the mother of an affected person); 2 children reviewed for congenital toxoplasmosis had no detectable retinochoroiditis; and 1 adult and 1 child reviewed for permanent visual impairment had no new symptoms during the study period.

The 103 patient reports included 16 patients resident outside the study area. Results are reported on 87 episodes in 84 patients resident within the study area (3 had a repeat symptomatic episode during the 18 month study period). Forty-one of 84 patients were male.

Diagnostic certainty

Clinical assessment was the sole basis for determining whether eye signs were due to toxoplasma infection, and in the majority of cases (71/87, 82%), this judgement was reported before serology results were available. Ophthalmologists' attribution of findings to toxoplasma infection were: definite in 69/87 (79%), probable in 14/87 (16%), possible in 3 and in 1 case the likelihood of toxoplasma infection was not stated. Antibodies were not detected by the EIKEN, Dye (< 2 IU/ml) or ISAGA tests in 3 patients (1 probable, 1 possible and 1 not stated to be due to toxoplasma infection) and serum specimens were not obtained from 5 patients.

Clinical characteristics

Mean age at presentation for all 87 episodes was 31.1 years. For patients presenting with a first episode ($n = 41$) the mean age was 26.5 years (Fig. 1) and was

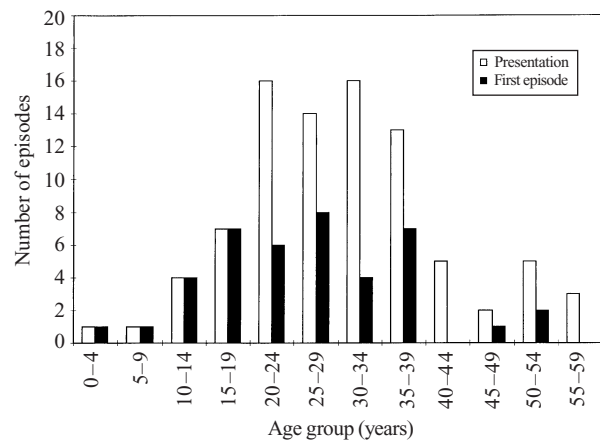


Fig. 1. Age at presentation for all patient episodes ($n = 87$) and for patients reporting no previous episode ($n = 41$).

similar for patients born in Britain or West Africa: 25.7 years ($n = 24$) and 29.7 ($n = 10$) respectively.

Presenting symptoms were acute visual impairment in 80 (92%) episodes and pain in 30 (34%). No patient was identified for the first time with chronic visual impairment or reported to be immunocompromised. In 55/87 (63%) episodes lesions involved the posterior pole, 4 of which were bilateral. Unilateral visual acuity was 6/60 or less in 18 (21%) episodes and in 7 (8%) bilateral visual acuity was 6/12 or less, which disqualifies patients from driving. Visual acuity was the same or improved in all 3 patients seen during a repeat episode, only 1 of whom had been treated during the first episode. There was no evidence of a difference in site of lesions or visual acuity according to country of birth or ethnic group, but these comparisons involve small numbers. Systemic treatment (antibiotics, steroids or both) was prescribed for 43/87 episodes, 35 (81%) of which involved active retinochoroidal lesions at the posterior pole (i.e. within the macular vascular arcade).

Two patients, both born in Britain, had evidence of congenital infection. One presented with a painful red eye at 2.9 years, having been blind since birth (best eye 6/60) due to bilateral posterior pole lesions. Toxoplasma-specific IgM antibodies, intracranial bleeding and liver disease were present at age 1 month. The second presented with acute visual loss at 34 years, having had a similar episode at 13 years. She had been treated for amblyopia and retinal detachment in early childhood (assumed to be due to toxoplasma retinochoroiditis), had unilateral posterior pole lesions and no neurological symptoms.

Five patients (all aged 29 years or older) had toxoplasma-specific IgM antibodies and no history of

Table 1. Incidence of symptomatic toxoplasma retinochoroiditis according to country of birth and ethnic group

Country or region of birth	Ethnic group	No. episodes/18 months	Denominator population ($\times 10^3$)	Incidence rate/100000/year (95% CI)
All	All	87	7423	0.8 (0.6–1.0)
Britain	All	45	6652	0.4 (0.3–0.6)
Britain	White	29	5674	0.3 (0.2–0.7)
Britain	Black	10	266	2.5 (1.2–4.6)
Britain	Other	6	712	0.6 (0.2–1.2)
W. Africa	Black	24	55	29.3 (18.8–43.6)
E. Africa	Black	2	9	14.7 (1.8–53.1)
W. Indies	Black	6	139	2.9 (1.0–6.3)
Indian Sub Continent	All	0	254	(0–0.8)
Europe (not Britain)	All	4	334	0.8 (0.2–2.0)
Rest/unknown	All	6		

Table 2. Cumulative lifetime risk of symptomatic toxoplasma retinochoroiditis for people born in Britain and West Africa based on first observed episode

Age group	British born (all ethnic groups)			West African born (black)		
	Number of episodes observed during study	Number of first episodes	Cumulative risk per 100000 population	Number of episodes observed during study	Number of first episodes	Cumulative risk per 100000 population
0–4	1	1	0.7	0	0	0
5–15	3	3	2.9	0	0	0
16–19	4	4	6.6	2	2	175.4
20–29	17	9	12.5	6	2	238.9
30–44	14	5	16.1	16	6	381.8
45–59	6	2	18.0	0	0	381.8
Total	45	24	18.0	24	10	381.8

signs or symptoms in early childhood. Three reported episodes with similar symptoms 14 years, 4 years, and 7 months previously. Four out of five patients had old scars as well as an active lesion.

Incidence rate

The overall incidence of 0.8 episodes/100000 per year differed substantially according to country of birth and ethnic group (Table 1). Of the 87 episodes, 45 (52%) occurred in patients born in Britain, giving an incidence of symptomatic toxoplasma retinochoroiditis of 0.45 per 100000 per year (95% CI: 0.33–0.60). There was a tenfold higher incidence in black compared with white people born in Britain and the rate in black people born in West Africa was tenfold higher than for black people born in Britain. The latter had a similar rate to black people born in the West Indies. Only two black East Africans were identified giving a high incidence rate for this group

but with wide confidence intervals. No patients born in the Indian subcontinent were identified, despite a large denominator population.

Lifetime risk

The cumulative risk of symptomatic retinochoroiditis was calculated from the age specific incidence for the first symptomatic episode which occurred during the study period (Table 2). For people born in Britain, the estimated risk by age 60 years was 18 per 100000 liveborns (95% CI: 10.8–25.2). Black people born in West Africa had a 20-fold higher lifetime risk (382/100000 population; 95% CI: 99–664) compared with people of any ethnicity born in Britain.

DISCUSSION

In our study population, symptoms of toxoplasma retinochoroiditis were mild and, for people born in Britain, 18 in every 100000 would eventually develop

symptoms, mainly in adulthood. Black people (particularly those born in West Africa) were affected more commonly than white. What implications do these findings have for public health?

The introduction of a new screening programme should require the demonstration of an important health problem which can be prevented by early detection and treatment [19]. We estimated a low burden of ocular disease. If the lifetime risk were extrapolated to the 700 000 births in Britain each year, an estimated 75–178 individuals would eventually develop symptoms requiring ophthalmological attention at a mean age of 26 years; 8% would have bilateral visual impairment sufficient to disqualify them from driving although this would be likely to be transient in most cases [13]. How much reduction in disease might be achieved by early detection and treatment is not known, as no controlled studies have been published on the effect of prenatal or infant treatment on the development of retinochoroiditis. Even if all symptomatic retinochoroiditis were due to congenital toxoplasmosis, the low risk and mild symptoms in an unscreened British population indicate limited potential benefits for prenatal or postnatal screening.

Error in our estimates may have arisen for several reasons. Firstly, our findings largely reflect the experience of individuals born 20–40 years ago. Since then, the incidence of toxoplasma infection in adults, and presumably of congenital toxoplasmosis, has fallen approximately twofold [20]. Secondly, we included three seronegative patients. Although similar cases have been reported [6, 8], they may have been misdiagnosed leading to an overestimate of the risk of toxoplasma eye disease. Thirdly, we have assumed that the risk of disease observed in British-born individuals living mainly in urban Greater London, the West Midlands or Leicester, was the same across the rest of Britain. Data on regional variation in symptomatic toxoplasma eye disease in Britain are lacking. An urban–rural gradient in the prevalence of toxoplasma IgG in British-born individuals has been reported in one study in South East England [21] but not confirmed by a study in East England [22].

Fourthly, we may have underestimated the risk of symptomatic eye disease due to underascertainment of cases although the ‘active’ reporting method has achieved high ascertainment rates for other disorders [23]. Failure to refer patients to an ophthalmologist who are initially identified in a casualty department, by an optician or a general practitioner is unlikely, but

some clinicians may have failed to suspect the condition. However, the study missed individuals who did not seek medical care and excluded patients with permanent visual impairment who did not develop symptoms during the study period. We determined the frequency of patients with permanent visual impairment by reviewing all ophthalmological case notes of patients with suspected toxoplasmosis over 2 years at the tertiary referral centre for children (1994–6, Great Ormond Street Hospital for Children) and the tertiary referral unit for ophthalmology (1992–4, Moorfield’s Eye Hospital). One of nine children in the study area at the former and 1/70 patients at the latter were under review during the study period for permanent visual impairment and had no history of symptoms of acute inflammation. Evidence from cause-specific studies of children failing vision screening [24] and from blind registrations [25] further supports clinicians’ perceptions that patients with permanent visual impairment without episodes of acute inflammation are rare.

Decisions about screening need to take account of non-ocular symptoms due to congenital toxoplasmosis, although data are limited due to small numbers affected and lack of long-term follow up. Mental retardation or abnormal motor development was reported in 3 of the 102 congenitally infected children in 5 prospective cohort studies births [1a, 2, 6–8]. Only one study compared intellectual development in infected and uninfected children and reported no difference in school performance at age 7 years [6]. Reports of more frequent adverse developmental outcome may be due to selective recruitment of symptomatic children [26]. In Britain, a surveillance study based on all births in 1989/90 (approx. 700 000) detected 14 severely affected congenitally infected offspring, some of whom were stillborn and some had no involvement of the central nervous system [27].

At the present time, public health programmes are largely focused on congenital toxoplasmosis. We found evidence of congenital infection in only 2/84 patients and no others presented with, or reported having had similar symptoms before 10 years of age. This contrasts with the high incidence of lesions (29/102, 28%) detected in cohort studies of congenitally infected children, in 27 before 7 years of age. Unilateral visual impairment or macular lesions (likely to result in permanent visual impairment) were noted in half (14/29) of these children.

These contrasting clinical patterns suggest different aetiologies and a role for postnatally acquired in-

fection in a proportion of our patients. However, conclusive evidence of acquired disease was lacking. Five adult patients had specific IgM antibodies, of whom three reported similar symptoms 14 years, 4 years and 7 months previously. Persistence or re-surgence of IgM antibodies has rarely been reported in congenital infection [28] but occurs in about 5% of postnatally acquired infection [12]. Hence presence of IgM in adults is more likely to reflect recent or old postnatally acquired infection but does not rule out congenital infection.

There were no findings to favour an acquired or congenital aetiology in the remaining 77 patients. Calculation of the expected risks of retinochoroiditis attributable to congenital or acquired infection, produces broad and uncertain estimates due to the paucity of published data. Recent cohort studies in northern Europe and north America give figures for the birth prevalence of congenital toxoplasmosis ranging from 0.8 to 5/10000 live births [1a, 2, 6–8]. If we apply these rates to the British-born population and assume that 80% of children develop lesions by adulthood [6], 6–40/100000 people would develop retinochoroidal lesions due to congenital toxoplasmosis. Approximately 13% of the British-born population aged 60 years in the regions studied have acquired toxoplasmosis postnatally (based on age specific seroprevalence rates for British people born in 1988–90 [29]). Burnet and colleagues [30] reported that 0.3–0.7% people with toxoplasma infection acquired during an outbreak in Vancouver presented with symptoms to ophthalmologists. If the same risks applied to Britain, between 39 and 91 per 100000 people aged 60 and under (13% times 0.3–0.7%) would have symptoms due to acquired toxoplasma retinochoroiditis, well in excess of our estimated lifetime risk of 18/100000. This discrepancy may be due to underestimation of the denominator in Vancouver, a higher prevalence of symptoms (possibly due to excessive organism load or virulence), and different thresholds for ophthalmological consultation. However, until further research generates more robust estimates, these limited data suggest that retinochoroidal lesions due to acquired toxoplasmosis are at least as common as those due to congenital infection.

The high incidence of symptomatic toxoplasma retinochoroiditis in black people born in West Africa confirms findings of a smaller study [25] and has been noted previously [31–33]. Possible explanations include a high incidence of congenital or postnatally acquired infection, increased susceptibility to the

development of symptomatic lesions, possibly due to differences in strain or organism load (through acquisition of tissue cysts rather than oocysts), or genetic susceptibility to disease. Our study predicts that more than 1 in 300 West Africans will be affected. These findings require confirmation in West African settings and further studies to relate acquisition of infection to preventable risk factors. Exposure to *Toxoplasma gondii*, commonly by ingestion of infected, undercooked meat and oocyst contaminated soil, may be reduced by primary prevention measures and warrants public health attention.

ACKNOWLEDGEMENTS

We are grateful to Ralph Rosenthal, David Taylor and other ophthalmologists who reported patients to the study, Sarah Scutt who co-ordinated the reporting scheme, Tony Ades and Catherine Peckham for comments on the study design and drafts of this report and David Cubitt, Richard Holliman and David Joynson for laboratory testing.

REFERENCES

- Petithory JC, Garin JP, Milgram M. Serologie de la toxoplasmose. Aspect actuels a travers le controle de qualite national en parasitologie en France. In: Anonymous Formation continue conventionnelle des Directeurs de Laboratoires Privés d'Analyses de Biologie Medicale, 1992. Paris: Bioforma, 1993: 25–51.
- Lebech M, Andersen O, Christensen N, et al. Feasibility of neonatal screening for toxoplasma infection in the absence of prenatal treatment. *Lancet* 1999; **353**: 1834–7.
- Guerina NG, Hsu HW, Meissner HC, et al. Neonatal serologic screening and early treatment for congenital *Toxoplasma gondii* infection. The New England Regional Toxoplasma Working Group. *N Engl J Med* 1994; **330**: 1858–63.
- Scaravelli G, Thorne C, Newell M-L. The management of pregnancy and delivery in HIV infected women in Europe. *Eur J Obstet Gynaec Reprod Biol* 1995; **62**: 7–13.
- Thulliez P. Screening programme for congenital toxoplasmosis in France. *Scand J Infect Dis Suppl* 1992; **84**: 43–5.
- Aspöck H, Pollak A. Prevention of prenatal toxoplasmosis by serological screening of pregnant women in Austria. *Scand J Infect Dis Suppl* 1992; **84**: 32–7.
- Koppe JG, Loewer Sieger DH, de Roeber Bonnet H. Results of 20-year follow-up of congenital toxoplasmosis. *Lancet* 1986; **i**: 254–6.

7. Conyn-van-Spaendonck MAE. Prevention of congenital toxoplasmosis in the Netherlands. (Thesis). National Institute of Public Health and Environmental Protection 1991; ISBN 90-9004179-6.
8. Lappalainen M, Koskiniemi M, Hiilesmaa V, et al. Outcome of children after maternal primary toxoplasma infection during pregnancy with emphasis on avidity of specific IgG. *The Study Group. Pediatr Infect Dis J* 1995; **14**: 354–61.
9. Perkins ES. Ocular toxoplasmosis. *Br J Ophthalmol* 1973; **57**: 1–17.
10. O'Connor GR. Toxoplasma: In: Tasman W, Jaeger EA, eds. Duane's biomedical foundation of ophthalmology, Philadelphia: Harper and Row, 1987: 1–14.
11. Dubey JP. Toxoplasmosis in man. In: Dubey JP, Beattie C, eds. Toxoplasmosis in animals and man, 1st ed. Boca Raton, Florida: CRC Press, 1988: 41–59.
12. Remington JS, McLeod R, Desmonts G. Toxoplasmosis. In: Remington JS, Klein J, eds, 4th ed. Infectious diseases of the fetus and newborn. Pennsylvania: WB Saunders, 1995: 140–267.
13. Rothova A. Ocular involvement in toxoplasmosis. *Br J Ophthalmol* 1993; **77**: 371–7.
14. Friedmann CT, Knox DL. Variations in recurrent active toxoplasmic retinochoroiditis. *Arch Ophthalmol* 1969; **81**: 481–93.
15. Multidisciplinary Working Group. Prenatal screening for toxoplasmosis in the UK. London: Royal College of Obstetricians and Gynaecologists, 1992.
16. Cubitt WD, Ades AE, Peckham CS. Evaluation of five commercial assays for screening antenatal sera for antibodies to *Toxoplasma gondii*. *J Clin Pathol* 1992; **45**: 435–8.
17. Duffy KT, Wharton PJ, Johnson JD, New L, Holliman RE. Assessment of immunoglobulin-M immunosorbent agglutination assay (ISAGA) for detecting toxoplasma specific IgM. *J Clin Pathol* 1989; **42**: 1291–5.
18. Breslow NE, Day NE. Statistical methods in cancer research. Volume II. The design and analysis of cohort studies. Lyon: IARC Scientific Publications, 1987: 57–9.
19. Wilson J, Jungner G. Principles and practice of screening for disease. Geneva: World Health Organisation, 1968. (Public Health Papers No. 34).
20. Ades AE, Nokes DJ. Modeling age- and time-specific incidence from seroprevalence: toxoplasmosis. *Am J Epidemiol* 1993; **137**: 1022–34.
21. Ades AE, Parker S, Gilbert RE, et al. Maternal prevalence of toxoplasma antibody based on anonymous neonatal serosurvey: a geographical analysis. *Epidemiol Infect* 1993; **110**: 127–33.
22. Allain JP, Palmer CR, Pearson G. Epidemiological study of latent and recent infection by *Toxoplasma gondii* in pregnant women from a regional population in the UK. *J Infect* 1998; **36**: 189–96.
23. Lynn R, Hall SM. The British Paediatric Surveillance Unit: activities and developments in 1990 and 1991. *CDR Rev* 1992; **2**: R145–8.
24. Rahi J, Dezateux C. Epidemiology of visual impairment in Britain. *Arch Dis Child* 1998; **78**: 381–6.
25. Gilbert RE, Stanford MR, Jackson H, Holliman RE, Sanders MD. Incidence of acute symptomatic toxoplasma retinochoroiditis in south London according to country of birth. *BMJ* 1995; **310**: 1037–40.
26. Roizen N, Swisher CN, Stein MA et al. Neurologic and developmental outcome in treated congenital toxoplasmosis. *Pediatrics* 1995; **95**: 11–20.
27. Hall SM. Congenital toxoplasmosis. *BMJ* 1992; **305**: 291–7.
28. Sibalic D, Djurkovic Djakovic O, Bobic B. Onset of ocular complications in congenital toxoplasmosis associated with immunoglobulin M antibodies to *Toxoplasma gondii*. *Eur J Clin Microbiol Infect Dis* 1990; **9**: 671–4.
29. Walker J, Nokes DJ, Jennings R. Longitudinal study of toxoplasma seroprevalence in South Yorkshire. *Epidemiol Infect* 1992; **108**: 99–106.
30. Burnett A, Shortt S, Isaac-Renton J, King A, Werker D, Bowie WR. Multiple cases of acquired toxoplasmosis retinitis presenting in an outbreak. *Ophthalmology* 1998; **105**: 1032–7.
31. Perkins ES. Epidemiology of uveitis. *Trans Ophthalmol Soc UK* 1976; **96**: 105–7.
32. Olurin O, Fleck DG, Osuntokun B. Toxoplasmosis and chorioretinitis in Nigeria. *Trop Geogr Med* 1972; **24**: 240–5.
33. Ronday MJ, Stilma JS, Barbe RF, et al. Aetiology of uveitis in Sierra Leone, west Africa. *Br J Ophthalmol* 1996; **80**: 956–61.