

1 **INTRAOPERATIVE ULTRASOUND IN PATIENTS UNDERGOING TRANSSPHOIDAL**
2 **SURGERY FOR PITUITARY ADENOMA: A SYSTEMATIC REVIEW**

3 Hani J Marcus, PhD^{1,2*}; Tom Vercauteren, PhD²; Sebastien Ourselin, PhD², Neil L
4 Dorward, MS¹

5

6 ¹Department of Neurosurgery, The National Hospital for Neurology and Neurosurgery,
7 London, UK; ²Translational Imaging Group, CMIC, Department of Medical Physics and
8 Biomedical Engineering, University College London, UK

9

10 *Correspondence:

11 Hani J Marcus, PhD

12 Specialty Registrar

13 Department of Neurosurgery, National Hospital for Neurology and Neurosurgery

14 Queen Square

15 London WC1N 3BG, UK

16 Tel 020 3456 7890

17 E mail: h.marcus@ucl.ac.uk

18

19 **INTRAOPERATIVE ULTRASOUND IN PATIENTS UNDERGOING TRANSSPENOIDAL**
20 **SURGERY FOR PITUITARY ADENOMA: A SYSTEMATIC REVIEW**

21

22

Abstract

23

24 Background: Transsphenoidal surgery is the gold standard for pituitary adenoma
25 resection. However, despite advances in microsurgical and endoscopic techniques, some
26 pituitary adenomas can be challenging to cure.

27

28 Objective: To determine whether, in patients undergoing transsphenoidal surgery for
29 pituitary adenoma, intraoperative ultrasound is a safe and effective technological adjunct.

30

31 Methods: The PubMed database was searched between January 1996 and January 2016 to
32 identify relevant publications that (1) featured patients undergoing transsphenoidal
33 surgery for pituitary adenoma, (2) used intraoperative ultrasound, and (3) reported on
34 safety or effectiveness. Reference lists were also checked and expert opinion sought to
35 identify further publications.

36

37 Results: Ultimately, ten studies were included comprising one cohort study, seven case
38 series' and two case reports. One study reported their prototype probe malfunctioned
39 leading to false-positive results in two cases, and another study that their prototype probe
40 was too large to safely enter the sphenoid sinus in two cases. Otherwise, no safety issues
41 directly related to use of intraoperative ultrasound were reported. In the only comparative
42 study, remission occurred in 89.7% (61/68) of patients with Cushing's disease in whom

43 intraoperative ultrasound was used, compared with 83.8% (57/68) in whom it was not.

44 All studies reported that surgeons anecdotally found intraoperative ultrasound helpful.

45

46 Conclusions: Although there is limited and low quality evidence available, the use of

47 intraoperative ultrasound appears to be a safe and effective technological adjunct to

48 transsphenoidal surgery for pituitary adenoma. Advances in ultrasound technology may

49 allow for more widespread use of such devices.

50

51 Keywords: Endoscopy; Neurosurgery; Minimally Invasive Surgery; Ultrasound

52 **INTRAOPERATIVE ULTRASOUND IN PATIENTS UNDERGOING TRANSSPHENOIDAL**
53 **SURGERY FOR PITUITARY ADENOMA: A SYSTEMATIC REVIEW**

54 **Introduction**

55 Transsphenoidal surgery is the gold standard for pituitary adenoma resection. Advances
56 in microscopy and, more recently, endoscopy represent among the most important
57 technological innovations in neurosurgery.¹ However, some pituitary adenomas remain
58 challenging to cure. In contemporary series' approximately a third of patients undergoing
59 transsphenoidal surgery for pituitary adenoma will have an incomplete resection.²

60 Several adjuncts have been used to improve resection in patients undergoing
61 transsphenoidal surgery for pituitary adenoma. Intraoperative CT and MRI offer high-
62 contrast and high-resolution imaging that are familiar to all neurosurgeons, but have
63 important limitations; the former results in exposure to ionising radiation, the latter
64 requires specialised non-ferromagnetic instruments, and both are costly and significantly
65 interrupt the surgical workflow and prolong the operating time.³ To this end,
66 intraoperative ultrasound has become an increasingly popular tool in neurosurgery, and
67 provides a relatively inexpensive and simple method of real-time feedback.

68 The technical specifications for ultrasound probes in transsphenoidal surgery are highly
69 demanding and conflicting; they must be both slender enough to allow for their use
70 within a narrow surgical corridor, and provide imaging of sufficient resolution to allow
71 for meaningful analysis. Nonetheless, ultrasound technology has advanced considerably
72 over the last 20 years, and several devices suitable for transsphenoidal surgery have now
73 been developed.

74 The aim of the present systematic review was to determine whether, in patients
75 undergoing transsphenoidal surgery for pituitary adenoma, intraoperative ultrasound is a
76 safe and effective technological adjunct.

77 **Materials and Methods**

78 The Preferred Reporting Items for Systematic Reviews and Meta-Analyses (PRISMA)
79 Statement was used in the preparation of this manuscript.⁴

80 *Search Methods*

81 The PubMed database was searched over a 20-year period between January 1996 and
82 December 2016. The Boolean search term (microadenoma OR macroadenoma OR
83 adenoma) AND (pituitary OR hypophysectomy OR transsphenoidal) AND (ultrasound
84 OR ultrasonography OR sonography) was used. References lists of included articles were
85 also reviewed, and expert opinion sought, to identify further eligible publications. Two
86 authors (HJM and TV) independently identified articles using the above search criteria.

87 *Inclusion and exclusion criteria*

88 Titles and abstracts were screened to identify publications that (1) featured patients
89 undergoing transsphenoidal surgery for pituitary adenoma, (2) used intraoperative
90 ultrasound, and (3) reported on safety or effectiveness. Full articles were obtained and
91 further assessed for eligibility. Discrepancies were resolved by discussion with the senior
92 author.

93 *Data extraction*

94 The following data was extracted from eligible full articles: (1) study design, (2) study
95 group characteristics including the number of patients and pathology, (3) ultrasound
96 device details, and (4) safety and effectiveness including radiological and endocrine
97 outcomes.

98 Corresponding authors and device manufacturers were contacted to provide supplemental
99 data when required.

100 *Appraisal of evidence*

101 The Jadad and Methodological Index for Non-Randomised Studies (MINORS) scoring
102 systems were used to guide evaluation of the quality of randomised and non-randomised
103 studies respectively^{5, 6}. Studies of greater quality were given greater weighting in the
104 qualitative analysis.

105 **Results**

106 A total of 997 articles were pooled from the electronic databases, with an additional
107 article identified following expert opinion (Figure 1). Of these, 981 articles were
108 excluded on the basis of their title and abstract because they did not present original data,
109 did not feature patients undergoing transsphenoidal surgery for pituitary adenoma, did not
110 include intraoperative ultrasound, or did not report on safety or effectiveness. Full text
111 screening of the remaining seventeen articles led to the exclusion of a further seven
112 articles. In all, ten studies were identified that satisfied the inclusion criteria comprising
113 one cohort study, seven case series', and two case reports; no randomised studies were
114 found (Table 1).⁷⁻¹⁶

115 The quality of the included studies was variable (Table 2). Watson *et al* performed the
116 only prospective comparative study, which was high quality (MINORS 20/24), although
117 they did include non-contemporaneous controls. The remaining studies were
118 retrospective case series' and case reports; many included non-consecutive patients,
119 inappropriate or biased assessments of endpoints, and inadequate follow up. None of the
120 studies documented a prospective calculation of study size.

121 *Ultrasound devices*

122 Bao *et al* and Ota *et al* reported the use of Doppler ultrasonography but did not provide
123 any device or manufacturer details.^{7, 10} The remaining 8 studies reported the use of 10
124 different ultrasound systems.

125 Ultrasound systems vary greatly in their form and function. Ultrasound image quality
126 depends upon the number of ultrasound elements; placing linear array probe elements on
127 the side of a probe (side-viewing) allows for a more slender design, while placing these
128 elements on the front of a probe (forward-viewing) allows for more intuitive imaging of
129 sellar structures. Similarly, because of frequency-dependent attenuation of ultrasound
130 waves, there is a trade-off between image resolution and depth.

131 Several studies used probes designed for transbronchial needle aspiration and
132 transoesophageal echo (off-label use use).^{9, 15} Watson *et al* used two prototype ultrasound
133 probes specifically designed for transsphenoidal surgery with long and rather thin shaft
134 dimensions (150x11mm) operating at 12Mhz and 15MHz (Linscan Systems, USA).
135 Solheim *et al* initially used a prototype side-looking ultrasound probe with a 3x4mm tip

136 diameter and 4mm shaft diameter, operating at 10.3MHz (Vermon, France).¹³ In a
137 subsequent study an improved prototype bayonet-shaped forward-looking ultrasound
138 probe operating at 12MHz was used (Vermon, France).⁸ The improved probe was,
139 however, more bulky with a transducer footprint of 12x8mm. Knappe *et al* used the only
140 commercially available probe designed for pituitary surgery, the UST-534 probe (Hitachi,
141 Japan), a forward-looking probe, 9mm in diameter, and operating at 12MHz.¹²

142 Solheim *et al* described the integration of their prototype ultrasound probes with a
143 neuronavigation platform (Sonowand, Norway).^{8, 13} They reported that this allowed for
144 improved image interpretation, particularly when viewing the unfamiliar image
145 projections of the side-viewing probe.

146 *Safety and effectiveness*

147 Watson *et al* reported probe malfunction during one day of their study, leading to false-
148 positive results in two cases (2.9%).¹⁴ Solheim *et al* found that their bayonet-shaped
149 forward-looking probe was too large to safely enter the sphenoid sinus in two cases
150 (8.3%).⁸

151 There were no cases of operative mortality reported in the any of the studies. Several
152 operative complications were reported that were not directly related to use of
153 intraoperative ultrasound. In one study a patient sustained injury to the internal carotid
154 artery and subsequently underwent digital subtraction angiography and stent insertion and
155 made a good recovery.⁷ Three studies reported panhypopituitism, and two studies
156 reported permanent diabetes insipidus as complications following transsphenoidal

157 surgery. Other complications included CSF leak, meningitis, monocular blindness, and
158 cranial nerve palsies.

159 Several studies explicitly reported on the extent of radiological resection or
160 endocrinological remission. The pooled rate of complete radiological resection in patients
161 in whom intraoperative ultrasound was used was 67.1% (range 63.5 to 77.8%) and
162 endocrine remission was 88.4% (range 76.0 to 100%). Watson *et al* found remission in
163 89.7% (61/68) of patients with Cushing's disease in whom intraoperative ultrasound was
164 used, compared with 83.8% (57/68) in whom it was not.¹⁴ Although this was not
165 statistically significant ($p = 0.45$), the authors did subsequently perform a subgroup
166 analysis of patients undergoing primary rather than revision surgery and found
167 intraoperative ultrasound helpful. Notably, they found that the use of intraoperative
168 ultrasound allowed for more frequent identification of adenoma tissue (90% versus 75%;
169 $p = 0.02$).

170 Bao *et al* reported complete resection in 63.5% (33/52) of patients with pituitary adenoma
171 invading the cavernous sinus (Knosp grade 3 and 4), and remission in 76.0% (19/25) of
172 patients with functioning adenoma.⁷ Solheim *et al* reported complete resection in 77.8%
173 (7/9) of patients in their initial and 70.8% (17/24) of patients in their subsequent study.⁸
174 ¹³ Knappe *et al* reported remission in 100% (18/18) of patients with Cushing's disease.

175 All of the studies reported that surgeons anecdotally found ultrasound helpful in
176 identifying intraoperative anatomy including the internal carotid artery and residual
177 tumour tissue.

178

Discussion179 *Summary of evidence*

180 At present, there is limited and low quality evidence on the safety and effectiveness of
181 intraoperative ultrasound in patients undergoing transsphenoidal surgery for pituitary
182 adenoma. Only ten studies met the inclusion criteria, including only one comparative
183 study, which failed to demonstrate any statistically significant difference in the primary
184 outcome. However, none of the studies reported any major safety issues directly related
185 to use of intraoperative ultrasound, and all of the studies reported that surgeons
186 anecdotally found intraoperative ultrasound helpful.

187 *Comparison with other studies*

188 The pooled rate of complete radiological resection in patients in whom intraoperative
189 ultrasound was used was 67.1% (range 63.5 to 77.8%) and endocrine remission was
190 88.4% (range 76.0 to 100%). Although difficult to make direct comparisons between
191 heterogeneous groups, these findings are broadly comparable to the reported outcomes of
192 patients undergoing transsphenoidal surgery for pituitary adenoma with intraoperative CT
193 and MRI. In a recent study, for example, Berkmann *et al* found an initial complete
194 radiological resection rate of 43.5% without intraoperative MRI versus 65.9% with
195 intraoperative MRI.¹⁷

196 Intraoperative CT and MRI have been more widely used as adjuncts to improve the
197 resection in patients undergoing transsphenoidal surgery for pituitary adenoma. In a
198 systematic review, Patel *et al* identified 24 studies (2 CT and 22 MRI), with improved

199 resection in 15-83% of patients.¹⁸ Recent guidelines by the Congress of Neurological
200 Surgeons (CNS), however, found insufficient evidence to recommend their use,
201 suggesting they may help improve immediate overall gross total resection of
202 nonfunctioning pituitary adenoma but at the cost of removing normal tissue.¹⁹ Indeed, the
203 present review also identified intraoperative ultrasound probe malfunction leading to
204 false-positive results in two cases. These studies underscore the importance of experience
205 in the interpretation of intraoperative imaging for surgical decision making, regardless of
206 the modality used.

207 *Limitations*

208 The present systematic review has a number of limitations. First, the scarcity and small
209 size of included studies, means it is likely underpowered to observe small effect sizes.
210 Second, the fact that all but one of the included studies were retrospective case series'
211 and case reports makes it impossible to draw any firm conclusions on the safety and
212 effectiveness compared to standard transsphenoidal surgery or other intraoperative
213 modalities. Finally, the technical specifications of the intraoperative ultrasound devices
214 used, and the experience of the operating surgeon, varied widely in the included studies
215 making generalisations difficult. Advances intraoperative ultrasound and image guidance
216 technology, including greater image quality, more ergonomic design, and automated
217 interpretation, may improve their cost-benefit profile.

218

Conclusions

219 At present there is limited and low quality evidence to support the use of intraoperative
220 ultrasound in patients undergoing transsphenoidal surgery for pituitary adenoma. Given
221 the rapid advances in imaging technology, further prospective and comparative
222 preclinical and clinical studies are warranted to determine the extent to which subjective
223 benefits to surgeons correspond objective improvement in patient outcomes.

224

References

- 225 1. Marcus HJ, Hughes-Hallett A, Kwasnicki RM, Darzi A, Yang GZ, Nandi D.
226 Technological innovation in neurosurgery: a quantitative study. *J Neurosurg*. Feb
227 20 2015:1-8.
- 228 2. Dallapiazza RF, Grober Y, Starke RM, Laws ER, Jr., Jane JA, Jr. Long-term
229 results of endonasal endoscopic transsphenoidal resection of nonfunctioning
230 pituitary macroadenomas. *Neurosurgery*. Jan 2015;76(1):42-52; discussion 52-43.
- 231 3. Nimsky C, von Keller B, Ganslandt O, Fahlbusch R. Intraoperative high-field
232 magnetic resonance imaging in transsphenoidal surgery of hormonally inactive
233 pituitary macroadenomas. *Neurosurgery*. Jul 2006;59(1):105-114; discussion 105-
234 114.
- 235 4. Moher D, Liberati A, Tetzlaff J, Altman DG, Group P. Preferred reporting items
236 for systematic reviews and meta-analyses: the PRISMA statement. *BMJ*.
237 2009;339:b2535.
- 238 5. Slim K, Nini E, Forestier D, Kwiatkowski F, Panis Y, Chipponi J. Methodological
239 index for non-randomized studies (minors): development and validation of a new
240 instrument. *ANZ journal of surgery*. Sep 2003;73(9):712-716.

- 241 6. Jadad AR, Moore RA, Carroll D, et al. Assessing the quality of reports of
242 randomized clinical trials: Is blinding necessary? *Controlled Clinical Trials*.
243 1996;17(1):1-12.
- 244 7. Bao X, Deng K, Liu X, et al. Extended transsphenoidal approach for pituitary
245 adenomas invading the cavernous sinus using multiple complementary
246 techniques. *Pituitary*. Feb 2016;19(1):1-10.
- 247 8. Solheim O, Johansen TF, Cappelen J, Unsgård G, Selbekk T. Transsellar
248 ultrasound in pituitary surgery with a designated probe: early experiences.
249 *Operative Neurosurgery*. 2016;12(2):128-134.
- 250 9. Ishikawa M, Ota Y, Yoshida N, Iino Y, Tanaka Y, Watanabe E. Endonasal
251 ultrasonography-assisted neuroendoscopic transsphenoidal surgery. *Acta*
252 *Neurochir (Wien)*. May 2015;157(5):863-868; discussion 868.
- 253 10. Ota Y, Mami I. Ultrasonography imaging during nasal endoscopic
254 transsphenoidal surgery. *ORL J Otorhinolaryngol Relat Spec*. 2013;75(1):27-31.
- 255 11. Furtado SV, Thakar S, Hegde AS. The use of image guidance in avoiding
256 vascular injury during trans-sphenoidal access and decompression of recurrent
257 pituitary adenomas. *J Craniomaxillofac Surg*. Dec 2012;40(8):680-684.
- 258 12. Knappe UJ, Engelbach M, Konz K, et al. Ultrasound-assisted microsurgery for
259 Cushing's disease. *Exp Clin Endocrinol Diabetes*. Apr 2011;119(4):191-200.
- 260 13. Solheim O, Selbekk T, Lovstakken L, et al. Intracellular ultrasound in
261 transsphenoidal surgery: a novel technique. *Neurosurgery*. Jan 2010;66(1):173-
262 185; discussion 185-176.

- 263 14. Watson JC, Shawker TH, Nieman LK, DeVroom HL, Doppman JL, Oldfield EH.
264 Localization of pituitary adenomas by using intraoperative ultrasound in patients
265 with Cushing's disease and no demonstrable pituitary tumor on magnetic
266 resonance imaging. *J Neurosurg*. Dec 1998;89(6):927-932.
- 267 15. Arita K, Kurisu K, Tominaga A, et al. Trans-sellar color Doppler ultrasonography
268 during transsphenoidal surgery. *Neurosurgery*. Jan 1998;42(1):81-85; discussion
269 86.
- 270 16. Yamasaki T, Moritake K, Hatta J, Nagai H. Intraoperative monitoring with pulse
271 Doppler ultrasonography in transsphenoidal surgery: technique application.
272 *Neurosurgery*. Jan 1996;38(1):95-97; discussion 97-98.
- 273 17. Berkmann S, Schlaffer S, Nimsky C, Fahlbusch R, Buchfelder M. Follow-up and
274 long-term outcome of nonfunctioning pituitary adenoma operated by
275 transsphenoidal surgery with intraoperative high-field magnetic resonance
276 imaging. *Acta Neurochir (Wien)*. Dec 2014;156(12):2233-2243; discussion 2243.
- 277 18. Patel KS, Yao Y, Wang R, Carter BS, Chen CC. Intraoperative magnetic
278 resonance imaging assessment of non-functioning pituitary adenomas during
279 transsphenoidal surgery. *Pituitary*. Apr 2016;19(2):222-231.
- 280 19. Kuo JS, Barkhoudarian G, Farrell CJ, et al. Congress of Neurological Surgeons
281 Systematic Review and Evidence-Based Guideline on Surgical Techniques and
282 Technologies for the Management of Patients With Nonfunctioning Pituitary
283 Adenomas. *Neurosurgery*. Oct 2016;79(4):E536-538.

284

ACCEPTED MANUSCRIPT

286

Figures

287 Figure 1. PRISMA flow diagram of article selection.

ACCEPTED MANUSCRIPT

Table 1. Summary of included studies. pts = patients; US = ultrasound

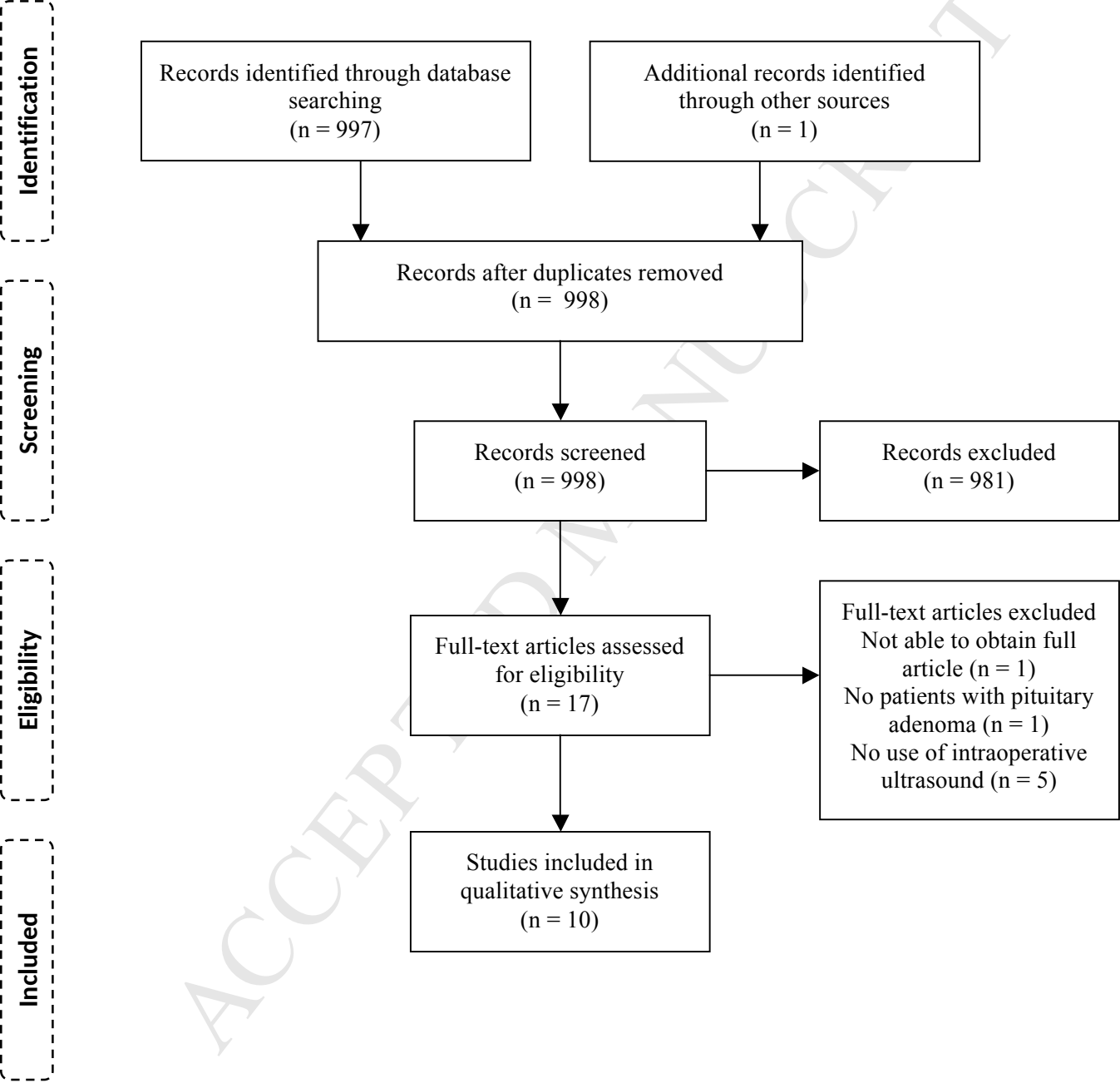
Study	Study design	Patients	Ultrasound devices	Safety	Effectiveness
Watson (1998) ¹⁴	Cohort study	136 pts with Cushing's disease and negative or equivocal pre-operative MRI; 68 pts with US and 68 pts without	Two prototype probes (Linscan Systems, USA), 150mm long x 11mm diameter operating at 12MHz and 15MHz respectively	Malfunction in probe in 2/68 (2.9%) leading to false-positive results No operative complications reported	Remission in 61/68 (89.7%) with US versus 57/68 (83.8%) without US; in patients undergoing primary procedures remission in 54/57 (94.7%) with US versus 46/53 (86.8%) with US
Bao (2016) ⁷	Case series	52 pts with pituitary adenoma invading the cavernous sinus (Knosp Grade 3 and 4) undergoing extended transsphenoidal approach	Doppler US (not specified)	Operative complications: carotid injury (1.9%), CSF leak (1.9%), meningitis (1.9%), permanent diabetes insipidus (1.9%), panhypopituitarism (3.8%), monocular blindness (1.9%), cranial nerve palsies (9.6%)	Complete resection in 33/52 (63.5%) Remission in 19/25 (76.0%) with functioning tumours
Solheim (2016) ⁸	Case series	24 pts; 20 with macroadenoma and 4 with microadenoma	Prototype bayonet-shaped forward-viewing probe (Vermon, France), 120 long x ca 10mm diameter, operating at 12MHz	Probe too large in 2/24 (8.3%) Operative complications: Permanent diabetes insipidus (4.2%), panhypopituitarism (4.2%)	Complete resection in 17/24 (70.8%) Remission in 9/10 (90.0%) with functioning adenoma

Ishikawa (2015) ⁹	Case series	7 pts; 5 with pituitary adenoma	EB-530US probe for transbronchial needle aspiration (Fujifilm, Japan) for sagittal images, 6.7mm diameter, operating at 12MHz UST-52110S-5 probe for TEE (Aloka, Japan) for coronal images, 4.8mm diameter, operating at 3-8MHz	No operative complications reported	
Furtado (2012) ¹¹	Case series	10 pts with pituitary adenoma	Nicolet Companion Micro transducer (Nicolet Biomedical, USA) for Doppler, 3mm diameter, operating at 10Mhz	No operative complications reported	
Knappe (2011) ¹²	Case series	18 pts with Cushing's disease	UST-534 probe connected to an SSD-3500 SX system (Aloka, Japan), 9mm diameter, operating at 12MHz	Operative complications: panhypopituitarism (5.5%)	Remission in 18/18 (100%)
Solheim (2010) ¹³	Case series	9 pts	Prototype side-viewing probe (Vermon, France), 4mm diameter, operating at 10MHz	No operative complications reported	Complete resection in 7/9 (77.8%)
Arita (1998) ¹⁵	Case series	23 pts; 18 with macroadenoma and 5 with microadenoma	EUP-ES533 biplane probe for TEE probe with EUB555 color Doppler system	No operative complications reported	

			(Hitachi, Japan), 800mm flexible shaft x 9.8mm diameter, operating at 7.5MHz; the probe has two tandem heads performing transverse and longitudinal imaging respectively		
Ota (2013) ¹⁰	Case report	One pt with pituitary adenoma	Doppler US (not specified)	No operative complications reported	
Yamasaki (1996) ¹⁶	Case report	One pt with acromegaly	MF20 and TC2-64 Doppler US probes (Eden Medizinische Elektronik, Germany)	No operative complications reported	

Table 2. Quality of studies using MINORS criteria

Study (year)	Clearly stated aim	Inclusion of consecutive patients	Prospective collection of data	Endpoints appropriate to the aim of the study	Unbiased assessment of the study endpoint	Follow-up period appropriate to the aim of the study	Loss to follow up less than 5%	Prospective calculation of the study size	An adequate control group	Contemporary groups	Baseline equivalence of groups	Adequate statistical analysis	TOTAL
Watson (1998) ¹⁴	2	2	2	2	2	2	2	0	2	1	2	1	20/24
Bao (2016) ⁷	2	2	0	2	1	2	2	0	NA	NA	NA	NA	11/16
Solheim (2016) ⁸	2	0	0	2	1	2	2	0	NA	NA	NA	NA	9/16
Ishikawa (2015) ⁹	2	0	0	1	1	0	0	0	NA	NA	NA	NA	4/16
Furtado (2012) ¹¹	2	0	0	1	1	0	0	0	NA	NA	NA	NA	4/16
Knappe (2011) ¹²	2	2	0	2	2	2	2	0	NA	NA	NA	NA	12/16
Solheim (2010) ¹³	2	0	0	2	1	2	2	0	NA	NA	NA	NA	9/16
Arita (1998) ¹⁵	2	2	0	1	1	0	0	0	NA	NA	NA	NA	6/16
Ota (2013) ¹⁰	2	0	0	1	1	0	0	0	NA	NA	NA	NA	4/16
Yamasaki (1997) ¹⁶	2	0	0	1	1	0	0	0	NA	NA	NA	NA	4/16



1 **INTRAOPERATIVE ULTRASOUND IN PATIENTS UNDERGOING TRANSSPHOIDAL**
2 **SURGERY FOR PITUITARY ADENOMA: A SYSTEMATIC REVIEW**

3 Hani J Marcus, PhD^{1,2*}; Tom Vercauteren, PhD²; Sebastien Ourselin, PhD², Neil L
4 Dorward, MS¹

5

6 Abbreviations:

7 CT = Computed Tomography

8

9 MRI = Magnetic Resonance Imaging

10

11 CSF = Cerebrospinal fluid

ACCEPTED MANUSCRIPT

1 **INTRAOPERATIVE ULTRASOUND IN PATIENTS UNDERGOING TRANSSPHOIDAL**
2 **SURGERY FOR PITUITARY ADENOMA: A SYSTEMATIC REVIEW**

3 Hani J Marcus, PhD^{1,2*}; Tom Vercauteren, PhD²; Sebastien Ourselin, PhD², Neil L
4 Dorward, MS¹

5

6 Disclosure:

7 No specific funding was received for this work.

8

9 Conflicts of interest:

10 The authors have no conflicts of interest to disclose.

11

ACCEPTED MANUSCRIPT