

## An Uncommon Site of *Streptococcus pneumoniae* Colonization Leading to Recurrent Pneumococcal Disease

Parham Sendi,<sup>1,4</sup> Eva Maria Moser Schaub,<sup>2</sup> Konstantinos Nirgianakis,<sup>3</sup> Lucy J. Hathaway,<sup>4</sup> Pascal Bittel,<sup>4</sup> David Goldblatt,<sup>6</sup> and Sven Streit<sup>5</sup>

Departments of <sup>1</sup>Infectious Diseases, <sup>2</sup>Visceral Surgery and Medicine, and <sup>3</sup>Obstetrics and Gynecology, Bern University Hospital, Switzerland; Institutes of <sup>4</sup>Infectious Diseases and <sup>5</sup>Primary Health Care (BIHAM), University of Bern, Switzerland; <sup>6</sup>Great Ormond Street Institute of Child Health, University College London, London, United Kingdom

This report describes a case of relapsing pneumococcal peritonitis. The postulated source of infection was vaginal colonization and secondary adherence of pneumococci to an intrauterine contraceptive device. After immunization with a conjugate pneumococcal vaccine, her antibody levels were observed. She remained infection free at the 2-year follow-up investigation.

**Keywords.** peritonitis; *Streptococcus pneumoniae*; tertiary peritonitis.

*Streptococcus pneumoniae* is a commensal of the upper respiratory tract. Colonization is often symptomless, although it can progress to pneumonia or systemic invasive disease [1]. Uncommon colonization sites leading to invasive diseases may cause rare clinical manifestations. It then becomes a diagnostic challenge to find the source of infection. We report the case of a 30-year-old woman with relapsing abdominal infection before detection of a colonized intrauterine contraceptive device. Vaginal colonization with *S pneumoniae* was proven on several visits. After removal of the device and antimicrobial treatment, the patient was vaccinated with the 13-valent pneumococcal polysaccharide conjugate vaccine. Her antibody response was observed for 2 years.

### CASE REPORT

A 30-year-old mother of 2 sons (2 months and 2 years old) presented with a 4-day history of vomiting and diarrhea. She reported that her 2-year-old son had the same symptoms before she did.

Thereafter, she became ill, followed by her husband, and finally her other son. All family members recovered except for her. She reported having abdominal cramps. On clinical examination she appeared dehydrated; blood pressure was 110/50 mmHg, heart rate was 110 beats per minute, and temperature was 39.9°C. Her abdomen was diffusely tender on palpation with slight rebound tenderness but no clear signs of acute abdomen. Laboratory examination of blood revealed white blood cell count of  $7.6 \times 10^9/L$  with a left shift and C-reactive protein level of 407 mg/L (normal, <5 mg/L). Abdominal ultrasound demonstrated free fluid in all quadrants and colon wall thickening surrounded by significant fluid. After blood cultures were obtained, the differential diagnosis of bacterial gastroenteritis was postulated, and rehydration and electrolyte substitution were prescribed.

Blood and stool cultures were negative. The latter was screened for *Yersinia* spp, *Campylobacter* spp, and *Salmonella* spp; examinations for the presence of *Clostridium difficile* toxin and *Norovirus* were negative. Vaginal ultrasound showed no evidence of endometritis, adnexitis, or ovarian abscess. The intrauterine contraceptive device (IUCD) that was introduced 1 month previously was in the correct position and therefore left in situ. On day 3 of hospitalization, her clinical condition had not improved. In addition to a urine culture, blood cultures were obtained again and empiric antimicrobial treatment with ceftriaxone and metronidazole was started. *Streptococcus pneumoniae* grew in all newly obtained blood and urine cultures. Treatment was switched to amoxicillin. Despite antimicrobial treatment, abdominal pain and fever persisted. Abdominal ultrasound was repeated and showed progressive cloudy ascites in multiple compartments. Thus, progressive pyogenic peritonitis was suspected, and surgical intervention indicated. Laparoscopy demonstrated generalized peritonitis with ascites and broad layers of fibrin in the whole abdomen (Figure 1). Fibrin was removed meticulously, and irrigation with 12 liters of Ringer solution was performed.

Intraoperative samples showed no bacterial growth, but *S pneumoniae* was detected via polymerase chain reaction (PCR). Thus, pneumococcal peritonitis was diagnosed. Antimicrobial treatment continued for a total of 14 days. The further course was favorable, and the patient discharged after 12 days of hospitalization. A follow-up examination by her private gynecologist 1 month later was unremarkable. *Streptococcus pneumoniae* grew from a routinely obtained vaginal swab.

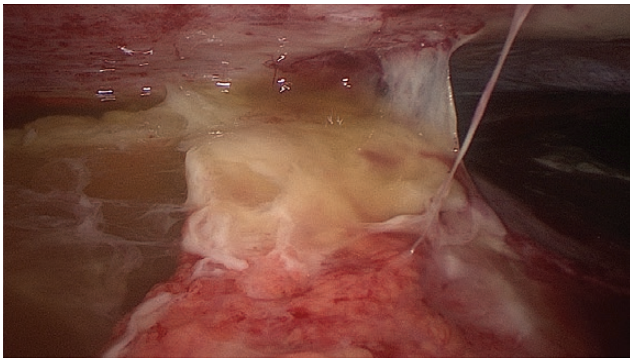
One week later (6 weeks after stopping antimicrobial treatment), the patient was referred to our center again because of an acute abdomen. A computed tomography scan was consistent with tubo-ovarian abscess on the right side and pyosalpinx on the left-side. Via laparoscopy, the abscess was incised and drained and the peritoneum irrigated. A vaginal swab was

Received 5 October 2016; editorial decision 17 November 2016; accepted 18 November 2016.

Correspondence: P. Sendi, MD, IDSA, Department of Infectious Diseases, Bern University Hospital, and Institute for Infectious Diseases, University of Bern, Friedbühlstrasse 51, 3010 Bern, Switzerland (parham.sendi@ifik.unibe.ch).

### Open Forum Infectious Diseases®

© The Author 2016. Published by Oxford University Press on behalf of the Infectious Diseases Society of America. This is an Open Access article distributed under the terms of the Creative Commons Attribution-NonCommercial-NoDerivs licence (<http://creativecommons.org/licenses/by-nc-nd/4.0/>), which permits non-commercial reproduction and distribution of the work, in any medium, provided the original work is not altered or transformed in any way, and that the work is properly cited. For commercial re-use, please contact journals.permissions@oup.com.  
DOI: 10.1093/ofid/ofw257



**Figure 1.** Intraoperative image: laparoscopy demonstrated generalized peritonitis with ascites and broad layers of fibrin in the whole abdomen.

obtained and the IUCD removed. *Streptococcus pneumoniae* grew in all samples obtained during surgery as well as on the IUCD and on the vaginal swab. The diagnosis of recurrent pneumococcal peritonitis was made, and the colonized IUCD was considered as the source of infection. Empiric antimicrobial treatment with amoxicillin/clavulanate was streamlined to amoxicillin and continued for a total treatment duration of 28 days. The following clinical course was favorable, and the patient was discharged after 5 days of hospitalization.

Two weeks after cessation of antimicrobial treatment, the patient was vaccinated with 13-valent pneumococcal polysaccharide conjugate vaccine (PCV13). Clinical follow-up investigations 1 month and 2 years after vaccinations were unremarkable.

## METHODS AND RESULTS

### Susceptibility Tests

Minimum inhibitory concentrations of *S pneumoniae* strains isolated from both infection episodes were determined using Etests on Mueller-Hinton sheep blood agar plates; the ATCC 49619 was used for quality control. The results were as follows: penicillin 0.016, vancomycin 0.50, doxycycline 0.125, clindamycin 0.125, erythromycin 0.125, and moxifloxacin 0.19 µg/mL.

### Polymerase Chain Reaction of Peritoneum Samples From the First Infection Episode

Multiplex PCR (Seeplex PneumoBacter ACE Detection, version 3.0; Seegene Inc., Seoul, Korea), used according to the manufacturer's instructions, detected *S pneumoniae* in peritoneum samples.

### Capsular Serotyping and Multilocus Sequence Typing

Bacterial isolates from blood cultures (first infection episode), intraoperatively obtained samples (second infection episode), and the vaginal swab were characterized by capsular serotyping and multilocus sequence typing (MLST). Serotyping was performed by Quellung reaction with serotype-specific antisera from the Statens Serum Institute (Copenhagen, Denmark), and MLST was performed as previously described [2, 3]. The

Institute for Infectious Diseases, University of Bern, is the Swiss National Reference Centre for Pneumococci [4]. All isolates from both episodes were serotype 3 and MLST 1377.

### Serum Antibody to Pneumococcal Capsular Polysaccharides

An enzyme-linked immunosorbent assay was used to assay 4 serum samples for antibodies to 13 vaccine-type capsular polysaccharides (1, 3, 4, 5, 6A, 6B, 7F, 9V, 14, 18C, 19A, 19F, and 23F). Serum was obtained during the second infection episode, 56 days after initial presentation (serum 1, T-d56-inf2), after the second infection episode but before vaccination (serum 2, T-d98-preVac), 1 month after vaccination (serum 3, T-d165-postVac), and 2 years after vaccination (serum 4, T-2y-FU). The assays were performed at the University College London Institute of Child Health (London, UK), a World Health Organization reference laboratory for pneumococcal serology [5]. The patient responded to all the PCV13 serotypes except the infecting serotype 3 (Table 1). Antibody titers to serotype 23F were high before vaccination, indicating an earlier immune response, although no previous pneumococcal infection was reported in the patient history.

## DISCUSSION

Peritonitis and pelvic inflammatory disease in adults are rare manifestations of pneumococcal disease. Pneumococcal peritonitis is reported in 3 distinct patient groups [6, 7]. Namely, in patients with a pre-existing peritoneal disease (eg, cirrhosis, ascites), or when an infection of an intra-abdominal organ is present. The third group includes young, previously healthy women. In this group, pneumococcal peritonitis occurs postpartum, after an abortion or gynecologic procedure, or in association with an IUCD [6–8]. A frequently postulated pathogenesis is an ascendant infection from a genitourinary source

**Table 1. Antibody Levels Against Pneumococcal Serotypes<sup>a</sup>**

Serum Samples	T-d56-inf2	T-d98-preVac	T-d165-postVac	T-2y-FU
Serotype				
1	<0.150	<0.150	3.532	1.600
3	0.192	0.210	0.201	0.334
4	<0.150	<0.150	1.462	0.259
5	<0.150	<0.150	2.841	0.649
6A	0.204	0.314	20.100	6.840
6B	0.152	0.252	8.523	3.753
7F	0.252	0.210	1.751	0.466
9V	0.193	0.282	10.164	3.570
14	0.783	0.826	6.825	3.057
18C	2.163	6.879	27.159	12.604
19A	0.190	0.270	6.342	1.713
19F	0.236	0.399	11.343	4.110
23F	22.668	25.614	13.617	7.861

<sup>a</sup>Serum samples: T-d56-inf2 (during second infection episode, day 56 after first clinical presentation), T-d98-preVac (after second infection episode, immediately before vaccination with the 13-valent pneumococcal conjugate vaccine), T-d165-postVac 1 month after vaccination, T-2y-FU (2 years after vaccination).

[8–10], and the disease manifests as complicated salpingitis or pyosalpinx [6, 7]. After peritoneal infection, bacteremia may occur. This sequence in the pathogenesis of pneumococcal peritonitis is believed to arise more frequently than is hematogenous spread to an uninfected peritoneum [9].

In this study, pneumococcal vaginal colonization was proven in an asymptomatic episode after the first infection episode and during the second infection episode. It is conceivable that the IUCD was secondarily colonized after its introduction and served as the source for both infection episodes. Although *S pneumoniae* typically colonizes the upper respiratory tract, it can be part of the commensal flora of the female genital tract [11]. The proportion of women vaginally colonized with *S pneumoniae* is unknown, because antenatal screening and corresponding epidemiological results report on group B *Streptococcus*. In 1987, Darbás and Boyer [12] found 7 pneumococcal isolates in 1064 (0.75%) vaginal secretions. It is unclear how long vaginal colonization with *S pneumoniae* persists. Study results on nasal colonization cannot be uncritically extrapolated to other body sites [13, 14]. The effect of pneumococcal vaccination on vaginal colonization is unknown.

## CONCLUSIONS

In conclusion, vaginal *S pneumoniae* colonization is uncommon but may be the source of invasive disease. This case and other reports from the literature [6–9] suggest that pneumococcal peritonitis in previously healthy young women should raise the suspicion of an ascending infection from the genitourinary tract. If present, the IUCD must be removed [9, 10]. Immunization with PCV13 is effective except against serotypes that previously caused an infection [15]. The long-term clinical benefit of vaccinating young adults who have experienced invasive pneumococcal disease is unknown.

## Acknowledgments

We thank the patient for supporting publication of this article. We acknowledge the many physicians, surgeons, and nurses involved in patient care, including Daniela Lengsfeld, Corina Kim Fuchs, Christoph Hauser,

Marc Baumann, and Luigi Raio, among others. We thank Marianne Küffer, Suzanne Aebi, Sarah Schaller, and Polly Burbidge for performing serotyping, multilocus sequence typing and enzyme-linked immunosorbent assay. Barbara Every, ELS, of BioMedical Editor, St. Albert, Alberta, Canada, provided English language editing.

**Potential conflicts of interest.** All authors: No reported conflicts.

All authors have submitted the ICMJE Form for Potential Conflicts of Interest. Conflicts that the editors consider relevant to the content of the manuscript have been disclosed.

## References

1. Bogaert D, De Groot R, Hermans PW. *Streptococcus pneumoniae* colonisation: the key to pneumococcal disease. *Lancet Infect Dis* **2004**; 4:144–54.
2. Hathaway LJ, Stutzmann Meier P, Bättig P, et al. A homologue of aliB is found in the capsule region of nonencapsulated *Streptococcus pneumoniae*. *J Bacteriol* **2004**; 186:3721–9.
3. Jolley KA, Maiden MC. BIGSdb: scalable analysis of bacterial genome variation at the population level. *BMC Bioinformatics* **2010**; 11:595.
4. Kronenberg A, Zucs P, Droz S, Muhlemann K. Distribution and invasiveness of *Streptococcus pneumoniae* serotypes in Switzerland, a country with low antibiotic selection pressure, from 2001 to 2004. *J Clin Microbiol* **2006**; 44:2032–8.
5. Andrews NJ, Waight PA, Burbidge P, et al. Serotype-specific effectiveness and correlates of protection for the 13-valent pneumococcal conjugate vaccine: a postlicensure indirect cohort study. *Lancet Infect Dis* **2014**; 14:839–46.
6. Capdevila O, Pallares R, Grau I, et al. Pneumococcal peritonitis in adult patients: report of 64 cases with special reference to emergence of antibiotic resistance. *Arch Intern Med* **2001**; 161:1742–8.
7. Dugi DD 3rd, Musher DM, Clarridge JE 3rd, Kimbrough R. Intraabdominal infection due to *Streptococcus pneumoniae*. *Medicine (Baltimore)* **2001**; 80:236–44.
8. Westh H, Skibsted L, Korner B. *Streptococcus pneumoniae* infections of the female genital tract and in the newborn child. *Rev Infect Dis* **1990**; 12:416–22.
9. Hemsley C, Eykyn SJ. Pneumococcal peritonitis in previously healthy adults: case report and review. *Clin Infect Dis* **1998**; 27:376–9.
10. Lemoyne S, Van Leemput J, Smet D, et al. Pelvic inflammatory disease due to *Streptococcus pneumoniae*: a usual pathogen at an unusual place. *Acta Clin Belg* **2008**; 63:398–401.
11. Larsen B, Monif GR. Understanding the bacterial flora of the female genital tract. *Clin Infect Dis* **2001**; 32:e69–77.
12. Darbás H, Boyer G. [Isolation of *Streptococcus pneumoniae* from genital samples. Discussion of its pathogenic role]. *Pathol Biol* **1987**; 35:177–80.
13. Weinberger DM, Dagan R, Givon-Lavi N, et al. Epidemiologic evidence for serotype-specific acquired immunity to pneumococcal carriage. *J Infect Dis* **2008**; 197:1511–8.
14. Sjöström K, Spindler C, Ortqvist A, et al. Clonal and capsular types decide whether pneumococci will act as a primary or opportunistic pathogen. *Clin Infect Dis* **2006**; 42:451–9.
15. Borrow R, Stanford E, Waight P, et al. Serotype-specific immune unresponsiveness to pneumococcal conjugate vaccine following invasive pneumococcal disease. *Infect Immun* **2008**; 76:5305–9.