

Reproducible fast T₁ mapping of the human cervical spinal cord *in vivo*

Marco Battiston¹, Torben Schneider², Ferran Prados^{3,1}, Francesco Grussu¹, Marios C Yiannakas¹, Sebastien Ourselin³, Claudia AM Gandini Wheeler-Kingshott^{1,4,5}, Rebecca S Samson¹

¹ *UCL Institute of Neurology, Queen Square MS Centre, University College London, London, United Kingdom*

² *Philips Healthcare, Guilford, Surrey, England*

³ *Translational Imaging Group, Centre for Medical Image Computing, Department of Medical Physics and Biomedical Engineering*

⁴ *Department of Brain and Behavioural Sciences, University of Pavia, Pavia, Italy*

⁵ *Brain MRI 3T Mondino Research Center, C. Mondino National Neurological Institute, Pavia, Italy*

Synopsis:

The T₁ relaxation time is a fundamental quantitative Magnetic Resonance parameter widely used to characterize healthy and pathological tissue. However, quantitative T₁ mapping in the human spinal cord (SC) has been limited to date, mainly due to its small size and sensitivity to artefacts. Here we assess the reproducibility of a time efficient (<5min) SC protocol for Inversion Recovery T₁ mapping, which is considered the “gold-standard” method for T₁ estimation. Scan-rescan experiments were performed in a cohort of 4 healthy subjects. High reproducibility (whole cord intraclass correlation=0.94) of T₁ estimates was found, with whole cord intra-subject coefficient-of-variation<15% for all subjects.

Purpose:

To assess the reproducibility of a fast (<5 minutes) protocol for measuring T_1 in the whole cervical spinal cord *in vivo* at 3T.

Introduction

The longitudinal relaxation time (T_1) is related to macromolecular concentration, water binding and water content¹, and is therefore important for tissue characterisation and assessment of pathology. Furthermore, the accurate knowledge of T_1 serves as the basis for several other quantitative MR methods, including *in vivo* spectroscopy, perfusion imaging, quantitative magnetization transfer imaging and macromolecular total volume mapping², in addition to sequence optimisation and development.

In the spinal cord, standard protocols using Inversion Recovery (IR) for T_1 estimation are hampered by low resolution, limited coverage and long scan times. Furthermore, fast T_1 mapping techniques such as Look-Locker or Variable-Flip-Angle-based methods suffer from poor accuracy and precision³.

Here, we investigate the reproducibility of a recently developed fast T_1 mapping protocol for the spinal cord⁴, which is able to simultaneously address spatial coverage and scan time limitations by combining reduced field-of-view (FOV) acquisition with an IR approach.

Material and Methods

A spatially non-selective adiabatic inversion pulse is combined with multi-slice reduced FOV imaging using ZOOM-EPI⁵. The repetition time for the inversion pulse (TR) is set to allow complete recovery of the longitudinal magnetization of the tissue of interest (i.e. $TR \geq 5T_1$). Slice acquisition order is shuffled alongside sequence repetitions to allow sampling of magnetization recovery at different delays from the inversion without increasing the nominal TR⁴.

In vivo imaging uses a stack of 24 5mm-thick slices to achieve full coverage of C2-C7 cervical cord levels, with an axial FOV of $64 \times 48 \text{mm}^2$, giving an in-plane resolution of $1 \times 1 \text{mm}^2$. The recovery curve is sampled at 8 TIs ($T_{I_{\min}}/\Delta TI = 100/320 \text{ms}$), $TR/TE = 8345 \text{ms}/24 \text{ms}$. Total scan time is 4:10min, including an additional noise-only scan (with no RF and no gradients applied, during the last sequence repetition) to characterise noise in the T_1 fitting.

4 healthy subjects (3M, 27-38 years) were each scanned twice to assess reproducibility of T_1 estimates for the proposed protocol. A 3D gradient-echo anatomical scan was also performed to facilitate delineation of the whole cord, white matter (WM) and grey matter (GM) regions-of-interest (ROIs) in the subsequent analysis.

Motion correction was performed on the IR data using a model-based image registration approach⁷, to deal with highly varying (or reversed) contrasts along different time points. Spinal cord straightening⁶ was used to co-register IR data to 3D anatomical images. A mono-exponential model was fitted to magnitude data using maximum likelihood estimation, assuming Rician distributed noise.

Coefficients-of-variation (COV) and intra-class correlation coefficient (ICC) among scans and subjects, defined as in⁸, were calculated for T_1 estimates for whole-cord, WM and GM ROIs. These regions, defined in a common template⁹, were warped to each subject's native space through non-linear transformation. COVs and ICC were calculated between C2-C7 after template registration.

Results

Figure 1 shows a scan-rescan comparison in one subject of T_1 and M_0 per spinal cord level, as identified using the spinal cord template⁹. Overall, good qualitative correspondence between scan and rescan is observed.

Mean and standard deviation (SD) scan-rescan T_1 values for all the subjects are reported in figure 2, for whole-cord, WM and GM ROIs. T_1 COVs within subject, averaged among two repetitions, are below 19% for all the ROIs considered.

Total T_1 variability between subjects and scans is very low: CVs of 3.5%, 3.0% and 4.4% are found for the whole-cord, WM and GM respectively. For the same ROIs, ICC values of 0.94, 0.95 and 0.88 were found.

Discussion and Conclusions

We have proposed a scan time efficient T_1 mapping protocol for large coverage in the spinal cord. Reproducible T_1 estimates can be obtained within approximately 4 minutes examination. High ICC index indicates that most of the variability in the T_1 estimates is driven by biological differences among the subjects.

Scanner time can be further reduced through protocol optimisation (allowing reduction in the number of sampled TIs) or through combination with ultra-fast imaging techniques (e.g. simultaneous multi slice imaging). Additional time gain could be, in turn, used to increase SNR through signal averaging.

Compared to previous measurements in the spinal cord at $3T^2$, we found higher T_1 values for both WM and GM. Further work is required to investigate T_1 in the different tissue types in more detail.

Due to the short acquisition time and the excellent reproducibility, the protocol proposed could easily be added as a routine method for spinal cord T_1 quantification in a variety of applications, including clinical trials.

Acknowledgements:

The UK MS Society; Brain Research Trust; NIHR BRC UCLH/UCL High Impact Initiative (BW.mn.BRC10269); EPSRC (EP/H046410/1,EP/J020990/1,EP/K005278); MRC (MR/J01107X/1); ISRT, WfL & CHNF (INSPIRED); Horizon2020-EU3.1 CDS-QUAMRI (ref: 634541).

References

- 1 - Mezer, Aviv, et al. "Quantifying the local tissue volume and composition in individual brains with magnetic resonance imaging." *Nature medicine* 19.12 (2013): 1667-1672.
- 2 - Duval, Tanguy, et al. "In vivo mapping of human spinal cord microstructure at 300mT/m." *NeuroImage* 118 (2015): 494-507.
- 3 – Smith S et al, Measurement of T1 and T2 in the cervical spinal cord at 3 Tesla. *MRM* 60:213-210(2008)
- 4 – Battiston M, Schneider T, Gandini Wheeler-Kingshott C AM et al. *In vivo* T1 mapping of the spinal cord using a reduced Field-of-View Inversion Recovery sequence (IR-ZOOM-EPI). In: Proceedings of ISMRM 2016, Singapore.
- 5 – Wheeler-Kingshott C AM et al, Investigating cervical spinal cord structure using axial diffusion tensor imaging. *Neuroimage* 16, 93-102 (2002)
- 6 – Cohen-Adad, J., Levi, S., Avants, B., 2015. Slice-by-slice regularized registration for spinal cord MRI: SliceReg . In: Proceedings of ISMRM 2015, Toronto, Canada. p. 5553
- 7 - Ben-Amitay, Shani, Derek K. Jones, and Yaniv Assaf. "Motion correction and registration of high b-value diffusion weighted images." *Magnetic resonance in medicine* 67.6 (2012): 1694-1702.
- 8 - Grussu, Francesco, et al. "Neurite orientation dispersion and density imaging of the healthy cervical spinal cord in vivo." *Neuroimage* 111 (2015): 590-601.
- 9 – V.S. Fonov, A. Le Troter, M. Taso, B. De Leener, G. Lévêque, M. Benhamou, M. Sdika, H. Benali, P.-F. Pradat, D.L. Collins, V. Callot, J. Cohen-Adad, Framework for integrated MRI average of the spinal cord white and gray matter: The MNI–Poly–AMU template, *NeuroImage*, Volume 102, Part 2, 15 November 2014, Pages 817-827,

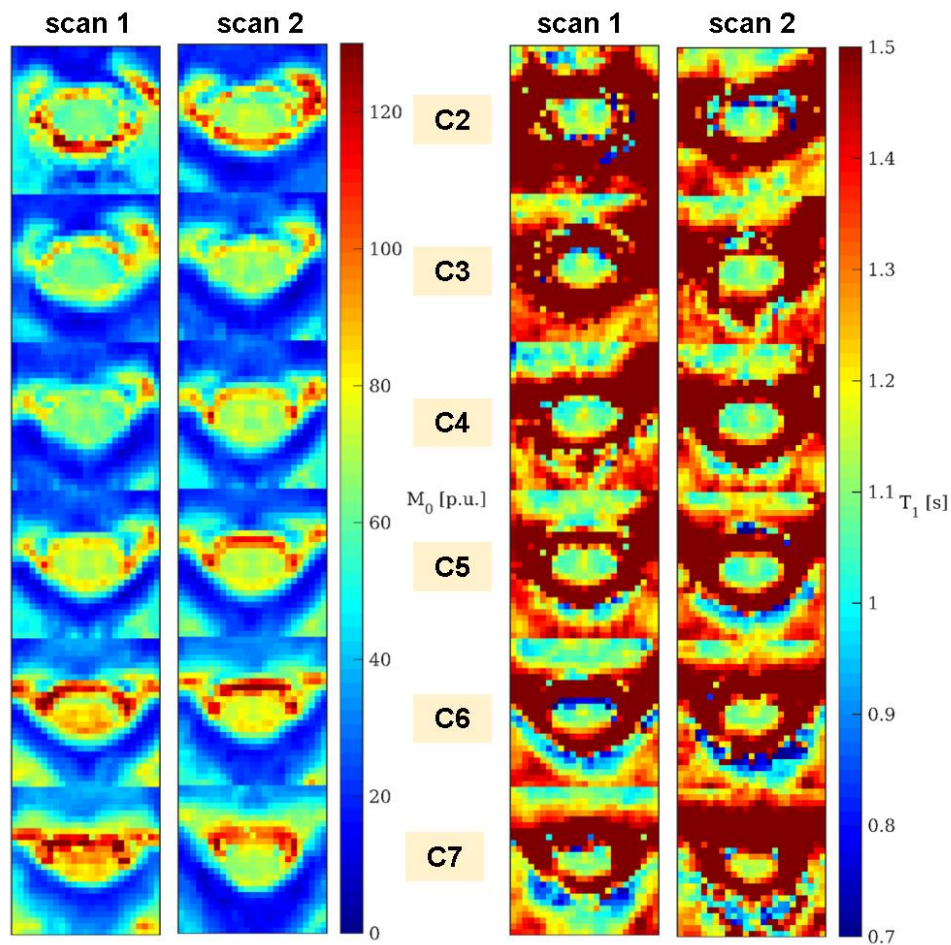


Figure 1: comparison of M_0 (left) and T_1 (right) between scan-rescan in an example subject. Parametric maps at different spinal cord levels are obtained by averaging slice-wise maps for slices labelled at the same disc level following registration of spinal cord template to the subject's native space. M_0 maps have been calibrated to mean WM value to allow quantitative comparisons.

	scan 1			scan 2			average		
	whole cord T ₁ [ms]	WM T ₁ [ms]	GM T ₁ [ms]	whole cord T ₁ [ms]	WM T ₁ [ms]	GM T ₁ [ms]	whole cord CV [%]	WM CV [%]	GM CV [%]
1	1091.0 (111.7)	1092.8 (131.7)	1093.1 (75.0)	1109.7 (91.6)	1116.1 (95.7)	1096.6 (74.8)	9.2	10.3	6.8
2	1183.8 (84.7)	1177.3 (87.2)	1199.5 (78.5)	1159.9 (185.5)	1144.4 (230.3)	1172.7 (66.8)	11.6	13.8	6.1
3	1138.4 (99.8)	1146.1 (103.1)	1120.8 (82.8)	1132.7 (127.5)	1133.7 (129.3)	1127.4 (83.7)	10.0	10.2	7.4
4	1106.9 (206.2)	1114.3 (258.8)	1092.5 (81.2)	1135.4 (142.9)	1144.1 (163.9)	1128.0 (79.7)	15.6	18.8	7.3

Figure 2. T₁ mean and standard deviation in the cohort of subjects included in the study. T₁ Resume values (in ms) are reported for both scans, in the whole cord (black), WM (red) and GM (blue) ROIs. Mean percentage COVs for each subject in the different ROIs are also reported in the last group of columns.