

**A rare case of bilateral optic neuritis and Guillain-Barré Syndrome post- Mycoplasma pneumoniae infection**

Journal:	<i>Neuro-Ophthalmology</i>
Manuscript ID	NOPH-2016-0036.R1
Manuscript Type:	Case Report
Date Submitted by the Author:	n/a
Complete List of Authors:	Ross Russell, Amy; Darent Valley Hospital, Neurology Baheerathan, Aravindhan; National Hospital for Neurology and Neurosurgery Farmer, Simon; National Hospital for Neurology and Neurosurgery, Neurology
Keywords:	Mycoplasma pneumoniae, Optic neuritis, Radiculopathy

SCHOLARONE™  
Manuscripts

Only

## TITLE PAGE

Title: A rare case of bilateral optic neuritis and Guillain–Barré Syndrome post-  
Mycoplasma Pneumoniae infection

Short title: Mycoplasma optic neuropathy

Authors:

Aravindhana Baheerathan<sup>1\*</sup>

Core Medical Trainee

Amy Ross Russell<sup>2\*</sup>

Neurology Specialist Registrar

Simon F Farmer<sup>1</sup>

Consultant Neurologist

\*Aravindhana Baheerathan and Amy Ross Russell contributed equally to this manuscript  
and are joint first co-authors

Affiliations:

1) Department Neurology  
National Hospital for Neurology & Neurosurgery  
Queen Square London  
WC1N 3BG

2) Department of Neurology  
Darent Valley Hospital  
Dartford & Gravesham NHS Trust  
Dartford  
DA2 8DA

Corresponding Author: Amy Ross Russell  
Darent Valley Hospital  
Dartford & Gravesham NHS Trust  
Dartford  
DA2 8DA  
Email: amyrossrussell@nhs.net

**Acknowledgements**

SFF acknowledges funding support from the UCLH Biomedical Research Centre

**Conflict of interest**

The authors declared no potential conflicts of interests with respect to the authorship and/or publication of this article.

**Financial disclosure/funding**

The authors received no financial support for the research and/or authorship of this article.

**Ethical approval**

Not applicable.

1  
2  
3 **A rare case of bilateral optic neuritis and Guillain–Barré syndrome post-Mycoplasma**  
4 **pneumoniae infection**  
5  
6  
7  
8  
9

10 **Abstract**

11 Neurological complications are the most commonly encountered extra-pulmonary  
12 manifestation of infection with Mycoplasma pneumoniae. Here we report the case of a 39-  
13 year-old female who was admitted with acute onset, bilateral visual loss coinciding with  
14 ascending numbness. Clinical examination, neurological imaging and nerve conduction  
15 studies revealed a syndrome of bilateral optic neuritis and acute inflammatory  
16 demyelinating polyneuropathy. Serological testing confirmed recent exposure to  
17 Mycoplasma pneumoniae. The patient did not experience any clinical benefit with pulsed  
18 intravenous methylprednisolone but demonstrated marked clinical and radiological  
19 improvement following five days of plasma exchange. This report will explore the diagnostic  
20 and therapeutic approach to patients with neuro-ophthalmological and neurological  
21 complications of Mycoplasma pneumoniae infection in addition to discussing previously  
22 encountered cases.  
23  
24  
25  
26  
27

28 **Case report**

29  
30 A 39-year-old Afro-Caribbean female was admitted urgently to our neurological department  
31 from the local ophthalmic hospital casualty department, having presented with acute-onset  
32 bilateral visual loss. Ten days preceding her admission, she had noted a frontal headache,  
33 followed by bilateral eye pain and gradual reduction in visual clarity over the subsequent  
34 five days. Upon initial assessment visual acuity (VA) was nil perception of light (NPL) in  
35 either eye. Pupillary reflexes were absent. She had bilateral swelling of the optic discs with  
36 splinter haemorrhages (figure 1a). There was bilateral globe tenderness but no pain on eye  
37 movements. Assessment of her visual fields demonstrated large central scotomas bilaterally  
38 (figure 1b). The remainder of cranial nerve examination was normal.  
39  
40  
41

42 She also noted sensory disturbance in her fingers and toes. Examination revealed reduction  
43 in both light-touch and pin-prick in a length dependent fashion in both the upper and lower  
44 limbs. Reflexes were symmetrical and present bilaterally, although were later lost in the  
45 lower limbs.  
46  
47

48 MRI of the brain and orbits on admission showed bilateral enhancement and enlargement  
49 of the intra-orbital portion of the optic nerves (figure 3a). The remainder of the brain  
50 parenchyma were normal. PET-CT of the whole body did not show any pathological uptake.  
51

52 Electrophysiological investigation demonstrated a motor predominant acquired distal  
53 demyelinating polyneuropathy.  
54

55 Cerebrospinal fluid showed protein of 0.21g/L, white cell count of 4, negative culture and  
56 cytology. Routine blood tests were normal. HIV, aquaporin-4; anti-neuronal antibodies and  
57 other auto-antibodies were negative. Mycoplasma pneumoniae serology showed a titre of  
58  
59  
60

1  
2  
3 1:20480, highly suspicious of acute infection. Subsequent convalescent sera confirmed that  
4 this was a recent exposure and on further questioning the patient recalled a mild upper  
5 respiratory tract infection two weeks earlier in the community characterised by a dry cough  
6 and headache. Mycoplasma was not isolated from the CSF, and CSF Mycoplasma PCR was  
7 negative.  
8  
9

10 A diagnosis of bilateral optic neuritis and acute inflammatory demyelinating polyneuropathy  
11 secondary to Mycoplasma pneumoniae infection was made.  
12

13 The mycoplasma infection was treated on admission with an oral course of clarithromycin  
14 (seven days). The patient was treated on admission with six doses of 1g intravenous  
15 methylprednisolone on consecutive days without clinical improvement. We then proceeded  
16 immediately to plasma exchange, completing five courses over five days. This produced  
17 rapid clinical improvement of visual acuity and gradual improvement of her sensory  
18 symptoms. Upon discharge of the patient, the VA in the right eye was 6/18 and the VA in  
19 the left eye was 6/9. She was discharged on an oral taper of prednisolone over 1 month  
20 starting at 1 mg/kg.  
21  
22  
23

24 Repeat imaging two weeks after completion of plasma exchange demonstrated radiological  
25 resolution of the bilateral optic neuritis (figure 3b) and repeat nerve conduction studies  
26 showed marked improvement of the polyneuropathy. Fundal photography eight weeks  
27 post-treatment demonstrated bilateral optic disc pallor (figure 2a).  
28  
29

30 Eight months later, upon review in the outpatient clinic, the patient had a VA of 6/5 in the  
31 left eye and a VA of 6/12 in the right eye. Despite improvement in the diameter of the  
32 scotomas, there were persisting visual field deficits in the right & left eyes (figure 2b). She  
33 has not had any relapse of her optic neuritis following complete tapering of oral steroid  
34 therapy. She had no remaining symptoms of her previous polyneuropathy.  
35  
36

### 37 **Discussion**

38 Mycoplasma pneumoniae is a commonly encountered pathogen that is often associated  
39 with infection of the respiratory system and produces a highly variable clinical phenotype,  
40 ranging from a mild upper respiratory tract infection to a severe pneumonia<sup>1</sup>. In addition to  
41 its respiratory manifestations it can also give rise to numerous extra-pulmonary  
42 manifestations, particularly neurological<sup>1</sup>.  
43  
44

45 Neurological complications have been reported to occur in between 0.1- 7% of patients  
46 infected with Mycoplasma pneumoniae, typically occurring between 2 and 14 days after  
47 initial respiratory symptoms<sup>2</sup>. These have been widely reported in the paediatric  
48 population<sup>1-3</sup>. Central nervous system (CNS) manifestations include: encephalitis,  
49 meningoencephalitis, aseptic meningitis, transverse myelitis, cerebellar ataxia,  
50 choreoathetosis, ischaemic stroke and syndrome of inappropriate anti-diuretic hormone.  
51 Peripheral nervous system manifestations are less commonly described but include: optic  
52 neuritis, cranial nerve palsies, Guillain-Barré Syndrome, polyradiculitis and peripheral  
53 neuropathy (box 1)<sup>1-5</sup>.  
54  
55  
56  
57  
58  
59  
60

1  
2  
3 The pathogenesis of the neurological complications of Mycoplasma infection is poorly  
4 understood and is a source of debate<sup>1,6</sup>. It has been postulated that there may be two  
5 distinct mechanisms of mycoplasma-induced neurological disease: first, the direct result of  
6 mycoplasma invasion into the CSF<sup>7</sup> and second, a systemic immune-mediated response to  
7 infection, with CNS sequelae. The latter mechanism fits best with the clinical presentation  
8 of our patient.  
9

10  
11 The diagnosis of Mycoplasma pneumoniae can prove challenging. Historically, cold  
12 agglutinins were used to aid the diagnosis of Mycoplasma pneumoniae infection. Cold  
13 agglutinins are produced 1-2 weeks after infection in 50% of patients and may persist for  
14 several weeks but due to their poor sensitivity and specificity they are now considered  
15 obsolete in making a diagnosis. Microbial culture is technically demanding, and seldom  
16 successful in routine medical practice. Diagnosis of Mycoplasma infection is primarily  
17 achieved through a consistent clinical presentation that coincides with positive serological  
18 testing, such as passive agglutination, complement fixation and ELISA. Serological tests for  
19 anti-Mycoplasma antibody represent the most common method for retrospective diagnosis  
20 of Mycoplasma infections but they depend on convalescent sera for confirmation and false  
21 positive results from cross reactivity are a problem<sup>1,2</sup>. Seroconversion is defined as a four-  
22 fold increase in titre between acute and convalescent sera, or a single high anti-Mycoplasma  
23 complement fixation antibody titre of >1:128<sup>1</sup>. These criteria were both met in our patient.  
24 A combination of PCR and serology is recommended for accurate diagnosis especially for  
25 patients with neurological and other extra-pulmonary manifestations<sup>1,2</sup>.  
26  
27

28  
29 The concomitant occurrence of bilateral optic neuritis and Guillain-Barré Syndrome post-  
30 Mycoplasma infection has been reported on four previous occasions in the published  
31 literature; however, in three of the four cases the onset of an acute inflammatory  
32 demyelinating polyneuropathy (AIDP) preceded the onset of bilateral optic neuritis<sup>9,10</sup>.  
33 Ginesta *et al.*<sup>8</sup> described a similar case of bilateral ON preceding AIDP, however, in contrast  
34 to our case, their patient demonstrated an AIDP with predominantly motor symptoms. In all  
35 four cases, excellent motor recovery and partial visual recovery was achieved with the use  
36 of immunotherapy (two cases treated with intravenous immunoglobulins, one with plasma  
37 exchange and one with intravenous steroids). Whilst our patient did not improve with the  
38 use of intravenous steroid therapy, the use of plasma exchange produced rapid recovery of  
39 visual acuity and resolution of the sensory symptoms.  
40  
41

42  
43 The role of antimicrobials in the treatment of neurological manifestations of Mycoplasma  
44 infection remains controversial whilst the mechanism of disease is unclear. If Mycoplasma  
45 infection is directly responsible for the pathology, then antibiotic treatment would be  
46 recommended. Antibiotic treatment recommendations also need to take in to account CSF  
47 bioavailability. If the mechanism is immune-mediated then it is less clear whether  
48 antimicrobial therapy is appropriate<sup>10,11</sup>, particularly after the acute illness has resolved<sup>1</sup>. In  
49 practice patients such as ours are treated urgently with antibiotic and immune therapy.  
50  
51  
52  
53  
54  
55  
56  
57  
58  
59  
60

### **Conclusion**

We report a rare case of bilateral optic neuritis in association with acute inflammatory demyelinating polyneuropathy secondary to *Mycoplasma pneumoniae* with severe neuro-ophthalmological deterioration and a poor initial response to intravenous steroid therapy; thus requiring escalation to plasma exchange with good response.

The most effective treatment protocol is not known, and good clinical response has been seen with steroids and intravenous immunoglobulin therapy. However, given our patient's dramatic response to plasma exchange in the absence of any improvement with steroid therapy we believe this should be considered early in patients presenting with this clinical syndrome, in order to minimise the potential for long term neurological and neuro-ophthalmic damage.

#### **Key messages**

- **M. pneumoniae can lead to a diverse range of neurological manifestations and should be considered, particularly in cases with an infectious prodrome**
- **We report a case of bilateral optic neuritis and acute inflammatory demyelinating polyneuropathy post-M. pneumoniae infection**
- **The infection can be difficult to diagnose but serological testing and PCR are the most commonly utilised methods**
- **Early immunotherapy and antibiotic therapy are essential.**

### References

1. Sánchez-Vargas FM, Gómez-Duarte OG. Mycoplasma pneumoniae-an emerging extra-pulmonary pathogen. *Clin Microbiol Infect.* 2008 Feb;14(2):105-17.
2. Guleira R, Nisar N, Chawla TC, Biswas NR. Mycoplasma pneumoniae and central nervous system complications: a review. *J Lab Clin Med.* 146 2005, pp. 55–6
3. Tsiodras S, Kelesidis I, Kelesidis T, Stamboulis E, Gimarellou H. Central nervous system manifestations of Mycoplasma pneumoniae infections. *J Infect.* 2005;51(5):343-354
4. Yimenicioğlu S, Yakut A, Ekici A et al. Mycoplasma Pneumoniae Infection with Neurologic Complications. *Iran J Pediatr* 2014; Vol24(No5), Pp:647-651
5. Panagariya A, Sharma AK, Dev A, Kankane A, Sharma B, Dubey P. Reversible neurological syndromes with atypical pneumonia. *Ann Indian Acad Neurol.* 2011 Apr;14(2):127-9.
6. Narita M. Pathogenesis of extra-pulmonary manifestations of Mycoplasma pneumoniae infection with special reference to pneumonia. *J Infect Chemother.* 2010 Jun;16(3):162-9
7. Al-Zaidy SA, MacGregor D, Mahant S, Richardson SE, Bitnun A. Neurological complications of PCR-proven M.pneumoniae infections in children: Prodromal illness duration may reflect pathogenic mechanism. *Clin Infect Dis.* 2015 Oct 1;61(7):1092-8
8. Ginestal RC, Plaza JF, Callejo JM, Rodríguez-Espinosa N, Fernández-Ruiz LC, Masjuán J. Bilateral optic neuritis and Guillain-Barré syndrome following an acute Mycoplasma pneumoniae infection. *J Neurol* 2004 251:767–768
9. Nadkarni S, Rubin S. Mechanisms of Action and Clinical Application of Macrolides as Immunomodulatory Medications. *Clin. Microbiol. Rev.* 2010 vol. 23 no. 3 590-615

Acknowledgements. SFF acknowledges funding support from the UCLH Biomedical Research Centre



1  
2  
3  
4  
5  
6  
7  
8  
9  
10  
11  
12  
13  
14  
15  
16  
17  
18  
19  
20  
21  
22  
23  
24  
25  
26  
27  
28  
29  
30  
31  
32  
33  
34  
35  
36  
37  
38  
39  
40  
41  
42  
43  
44  
45  
46  
47  
48  
49  
50  
51  
52  
53  
54  
55  
56  
57  
58  
59  
60

**Box 1: Neurological manifestations  
of mycoplasma Pneumoniae  
infection**

**CNS**

Encephalitis  
Meningoencephalitis  
Aseptic meningitis  
Cerebellar ataxia  
Choreoathetosis  
Transverse myelitis  
Acute psychosis  
Ischaemic stroke

**PNS**

Optic neuritis  
Cranial nerve palsies  
Guillain Barre syndrome  
Polyradiculitis  
Peripheral neuropathy

210x297mm (200 x 200 DPI)

1  
2  
3  
4  
5  
6  
7  
8  
9  
10  
11  
12  
13  
14  
15  
16  
17  
18  
19  
20  
21  
22  
23  
24  
25  
26  
27  
28  
29  
30  
31  
32  
33  
34  
35  
36  
37  
38  
39  
40  
41  
42  
43  
44  
45  
46  
47  
48  
49  
50  
51  
52  
53  
54  
55  
56  
57  
58  
59  
60

Figure 1 A

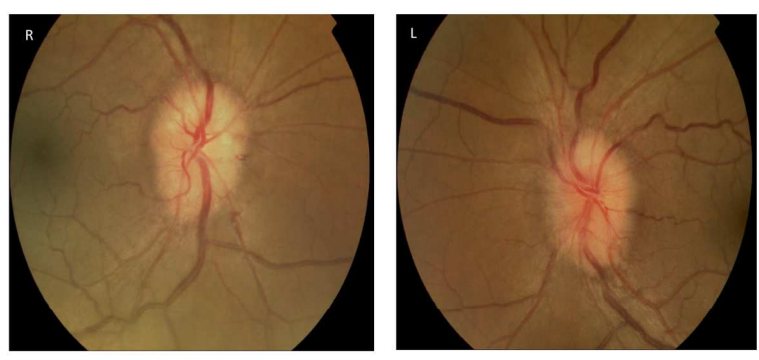


Figure 1 B

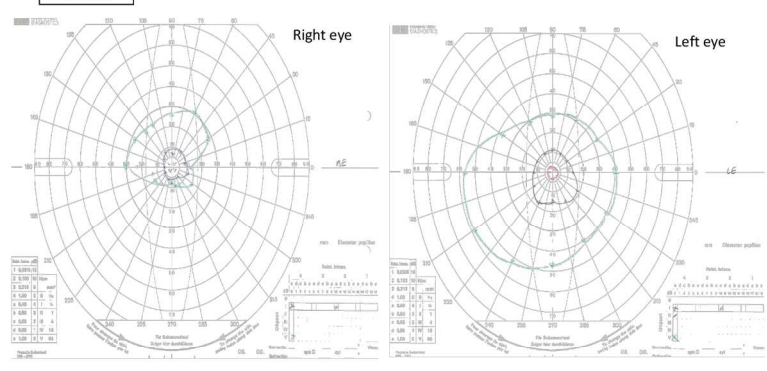


Figure 1a: Fundal imaging demonstrating bilateral optic disc swelling with splinter haemorrhages in both right and left eyes

Figure 1b: Visual fields obtained via Goldman perimetry on admission demonstrating bilateral central scotomas

Figure 1  
210x297mm (200 x 200 DPI)

1  
2  
3  
4  
5  
6  
7  
8  
9  
10  
11  
12  
13  
14  
15  
16  
17  
18  
19  
20  
21  
22  
23  
24  
25  
26  
27  
28  
29  
30  
31  
32  
33  
34  
35  
36  
37  
38  
39  
40  
41  
42  
43  
44  
45  
46  
47  
48  
49  
50  
51  
52  
53  
54  
55  
56  
57  
58  
59  
60

Figure 2 A

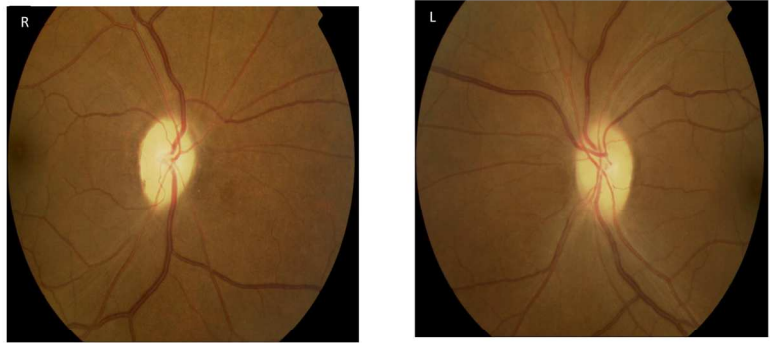


Figure 2 B

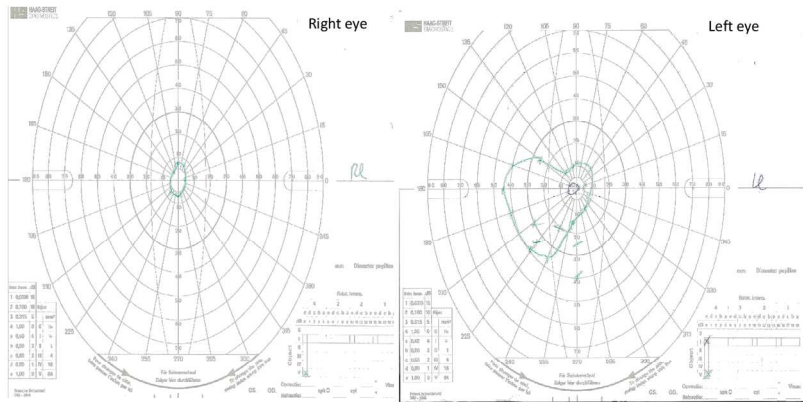


Figure 2a: Fundal imaging 2 months following initial treatment demonstrating bilateral optic disc pallor  
Figure 2b: Visual fields assessed via gold perimetry at 8 months following completion of plasma exchange demonstrating improvement in the size of the bilateral central scotomas

Figure 2  
210x297mm (200 x 200 DPI)

1  
2  
3  
4  
5  
6  
7  
8  
9  
10  
11  
12  
13  
14  
15  
16  
17  
18  
19  
20  
21  
22  
23  
24  
25  
26  
27  
28  
29  
30  
31  
32  
33  
34  
35  
36  
37  
38  
39  
40  
41  
42  
43  
44  
45  
46  
47  
48  
49  
50  
51  
52  
53  
54  
55  
56  
57  
58  
59  
60

Figure 3 A and 3 B

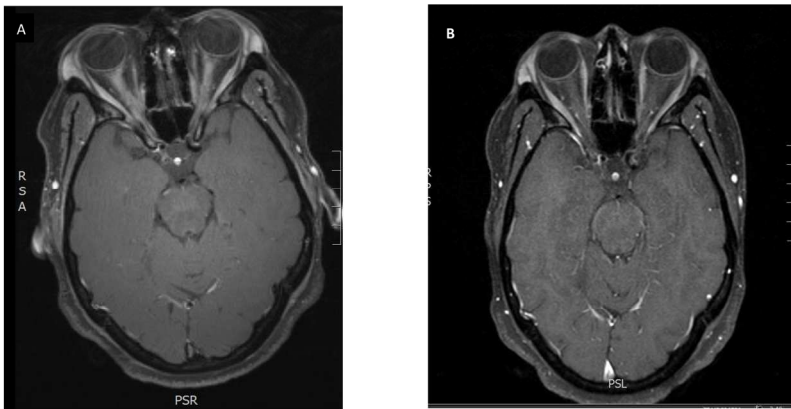


Figure 3a: Bilateral enlargement and post-gadolinium enhancement of the intra-orbital and intra-canalicular portions of the optic nerve

Figure 3b: Following plasma exchange, marked improvement of the swelling of both optic nerves with minimal enhancement seen post-gadolinium administration

Figure 3  
210x297mm (200 x 200 DPI)