

Title of the article:

Kidney disease in primary antiphospholipid antibody syndrome

Authors' names and affiliations:

Borja Gracia-Tello. Internal Medicine. Lozano Blesa University Hospital,
Zaragoza. Spain.

David Isenberg. Centre for Rheumatology, University College London Hospitals,
London, UK

Corresponding author:

David Isenberg, Centre for Rheumatology, University College London Hospitals,
London, UK

d.isenberg@ucl.ac.uk

Short title:

Kidney disease in primary antiphospholipid syndrome

KIDNEY DISEASE IN PRIMARY ANTIPHOSPHOLIPID ANTIBODY SYNDROME

ABSTRACT:

Antiphospholipid syndrome (APS) is an autoimmune disease defined by the presence of arterial or venous thrombotic events and/or pregnancy morbidity in patients who test positive for antiphospholipid antibodies. APS can be isolated (primary APS) or associated with other autoimmune diseases. The kidney is a major target organ in APS and renal thrombosis can occur at any level within the vasculature of the kidney (renal arteries, intrarenal vasculature and renal veins). Histological findings vary widely, including ischaemic glomeruli and thrombotic lesions without glomerular or arterial immune deposits on immunofluorescence. Renal involvement in patients with definite APS is treated with long-term anticoagulants as warfarin but new treatments are being tried. The aim of this article is to review the links between primary APS and kidney disease.

KEYWORDS:

Primary antiphospholipid syndrome
Thrombosis
Kidney disease
Antiphospholipid-associated nephropathy
Treatment
Antiphospholipid antibodies

INTRODUCTION:

Antiphospholipid syndrome (APS) is a pro-thrombotic acquired autoimmune disease, characterized principally by vascular thrombosis (arterial and/or venous), pregnancy morbidity and the presence of antiphospholipid antibodies (aPL). These heterogeneous antibodies bind serum phospholipid-binding plasma proteins (mainly β_2 glycoprotein-I, prothrombin, protein C, protein S, annexin V, annexin II, and oxidized low-density lipoprotein), phospholipid-protein complexes, and anionic phospholipids. The aPL tested routinely are the IgG and IgM anticardiolipin antibodies (aCL) detected by enzyme-linked immunosorbent assay (ELISA) and the lupus anticoagulant (LA), detected by clotting tests. Many laboratories now also test for IgG and IgM anti- β_2 glycoprotein-I antibodies (by ELISA)

APS can be primary or associated with other conditions, notably systemic lupus erythematosus (SLE). It may affect any organ and/or vessel. Renal involvement can be present in patients with either primary or SLE-associated APS.

Renal involvement can be a serious problem for patients with APS. However, this complication has been poorly recognized and little studied. It can be present in either type of APS. In the most recent consensus criteria of APS [1,2] the term antiphospholipid-associated nephropathy (APLN) was suggested to describe the

entity of aPL in association with renal vasculopathy.

The true prevalence of APLN is unknown (ranging from 6 to 25% of patients with APS). An accompanying thrombocytopenia may limit the possibility of doing a renal biopsy. Furthermore, a recent study by Jordan and coworkers [3] identified the LA, presence of thrombotic microangiopathy (TMA) on renal biopsy, age >40years, and elevated serum creatinine (>400 μ moles/liter) as independent risk factors in a lupus cohort for increased risk of bleeding and major bleeding complications. These factors were significantly more common in those with coexisting APS and/or aPL. Severe renal histopathological lesions may be found in the absence of significant renal clinical abnormalities [4].

MATERIAL AND METHODS:

A search was performed using a computer-assisted search engine. Some terms used were: primary APS and anti-cardiolipin antibodies (aCL), anti-phospholipid-associated nephropathy and APS, APS and renal vascular thrombosis, primary APS and treatment, primary APS nephropathy treatment, rituximab and APS, in the literature published until 2015.

We performed a electronic search, piloted in PubMed and Embase. We supplemented electronic searches by checking references cited in published papers and in the articles extracted from the electronic searches. Unpublished studies were not searched.

The following limits were applied: (a) written in English, Spanish or French; and (b) performed in humans.

Studies were screened for inclusion in different phases: (a) duplicated articles were deleted; (b) we first screened by title and then by abstract. When a title seemed relevant, the abstract was reviewed for eligibility; if any doubt remained, the full text of the article was retrieved and discussed (Figure 1)

After the selection, a total of 114 articles were selected. To facilitate the analysis, articles were classified according to the following categories: pathophysiology, renal artery lesions, renal vein thrombosis, APS nephropathy and treatment.

PATHOPHYSIOLOGY

A 'two hit' model of thrombosis in APS has been hypothesized in which a 'first hit' creates a pro-thrombotic state followed by a 'second hit', possibly inflammatory, that perturbs the endothelium and initiates thrombosis [5].

The pathophysiologic mechanisms that contribute to the prothrombotic phenotype (first hit) include aPL-mediated activation of monocytes, endothelial cells and/or platelets, and/or inhibition of natural anticoagulant and fibrinolytic systems by aPL [6].

The various factors potentially involved in the pathogenesis of the prothrombotic

phenotype are shown in Figure 2.

- ANTIPHOSPHOLIPID ANTIBODIES

aPL are directed principally against phospholipid binding proteins, likely to be the main factor in the pathogenesis of APS, by binding to the surface of endothelial cells, monocytes and platelets.

The loss of immune tolerance is thought to be responsible for the origin of pathogenic aPL, which appears to be predominantly antigen driven. Bacterial and viral infections have been implicated in the development of aPL and shown to induce pathogenic antibodies against b2GPI. aPL develop in mice immunized with a cytomegalovirus-derived peptide, and a recent study demonstrated that protein H of *Streptococcus pyogenes* can bind b2GPI and expose neoepitopes that induce production of anti-b2GPI antibodies [7,8].

It is probable that at least part of the injury observed in renal biopsies is related to the pathogenic action of aPL, which may be linked to prolonged immunological damage mediated by anti-DNA/nucleosome antibodies [9].

APLN is particularly associated with triple anti-phospholipid antibody positivity [10]. Gerhadsson and coworkers found that APLN was associated with aCL, but a strong trend between APLN and anti- β_2 GP1 or LA was also detected. However, in other studies [11], focussing on glomerular microthrombi, a strong association with LA and anti- β_2 GP1, but not with aCL was noted. Alternatively, it has been proposed that both LA and aCL are associated with an increased risk of vascular thrombosis [12,13], while other reports have verified this relationship only with LA [14-16].

Finally, a study of 51 patients [17], suggested that the presence of aCL and/or glomerular thrombi predicts a worse renal outcome, as patients with aPL-positivity had significantly more crescents, sclerosis, and glomerular necrosis. These patients tend to develop hypertension and raised serum creatinine levels, in addition to other manifestations of APS, especially arterial thromboses, during the course of the disease.

It has been further demonstrated that aPL-associated vascular lesions have an ominous effect on long-term renal function, arterial hypertension, and absence of response to immunosuppressive agents [9,18,19].

In contrast, others have shown no significant differences between patients with or without aPL-associated nephropathy in complete or partial remission, non-response to treatment or at end-stage renal disease [20].

The divergent aPL associations previously reported are likely to be due to methodological issues, as different assays for aPL and LA detection have been

used, and cut-off values have varied between studies.

- CELLULAR ACTIVATION

aPL have been reported to bind to, and activate vascular endothelial cells, monocytes, and platelets in a b2GPI-dependent manner [21-24].

Endothelial cells, through the expression of anticoagulant proteins and the elaboration of antithrombotic substances such as prostacyclin, glycosaminoglycans and nitric oxide, play an important role in maintaining blood fluidity. Endothelial cell activation via aPL – b2GPI interactions leads to loss of these anticoagulant properties with transformation to a pro-adhesive, procoagulant phenotype, characterized by increased expression of adhesion molecules and tissue factor, enhanced secretion of pro-inflammatory cytokines and chemokines, and the release of procoagulant and proinflammatory microparticles [25].

The vascular endothelium of proliferating intrarenal vessels, from patients with APLN, showed indications of the mechanistic target of rapamycin complex (mTORC) pathway activation. This phenomenon was also found in the vessels of autopsy specimens from patients with the sinister catastrophic APS. Patients with APLN who required transplantation and were receiving sirolimus, had no recurrence of vascular lesions and had decreased vascular proliferation on biopsy, compared to patients with aPL not on the drug. These results suggest that mTORC pathway is involved in the vascular lesions associated with the antiphospholipid syndrome [26].

In contrast, Rauch et al. [27] showed TLR4 involvement in inducing a break in immune tolerance and production of aPL. Dysregulation of other TLRs including TLR7, TLR8, and TLR9 may also contribute to the development of aPL [28]. Hydroxychloroquine inhibits TLR7 and is associated with reduced persistence of aPL in patients with SLE [29].

- COMPLEMENT ACTIVATION

Recent studies have shown that complement activation (induced by or coordinated with aPL), and the complement-induced tissue factor activation, may play a significant role in renal tissue injury [30].

Activation of the complement system is implicated in the development of thrombosis and fetal loss in APS [31]. Activated complement fragments bind to and activate cells through, the C5b-9 membrane attack complex or, through the C5a-receptor-mediated effects. aPL, which activate complement may generate the potent inflammatory mediator C5a, which recruits neutrophils and monocytes, and leads to the tissue factor exposure by endothelial cells and neutrophils [32].

Recently, several case reports have documented the successful use of eculizumab (humanized anti-C5a monoclonal antibody) in patients with complicating renal transplantation APS [33].

- HLA

A link between certain HLA haplotypes and ALPN has been described. Thus, Gerhadsson and co-workers found a significantly higher frequency of HLA-DRB1*13 as concluded that a genetic predisposition may contribute to APLN [10].

The activation of mTORC pathway in endothelial cells during humoral rejection by anti-HLA antibodies (particularly anti-HLA class I antibodies) of primary APS. However, a recent study has shown that anti-HLA antibodies did not account for mTORC activation in microvascular endothelial cells; therefore, more studies are necessary to correlate this association [26].

CLINICAL MANIFESTATIONS

APS nephropathy is clinically characterized by a vascular nephropathy syndrome associated with hypertension, acute or chronic renal failure and proteinuria [34]. Proteinuria is generally mild (range between 0.5–3.0 g per day), but is occasionally nephrotic (>3.5 g per day) [9,35,36].

The presence of newly developed hypertension in a patient with positive aPL, in combination with proteinuria, haematuria and/or renal insufficiency should raise a suspicion of APLN, and kidney biopsy should be performed. When APLN lesions are detected in kidney biopsies, other causes associated with similar histological lesions should be excluded including malignant hypertension, thrombotic thrombocytopenic purpura or haemolytic uremic syndrome, scleroderma, cyclosporine use or human immunodeficiency virus (HIV) infection [30].

When APLN is a result of renal artery thrombosis, different clinical feature may be observed, most commonly, pain in the renal area or renal failure associated with severe hypertension or worsening of known systemic hypertension. Renal ultrasonography, abdominal CT, renal angiography, renal scintigraphy and gadolinium-enhanced magnetic resonance angiography have proved useful for diagnostic and prognostic purposes. Magnetic resonance angiography and renal ultrasonography with colour Doppler sonography are comparable methods for the detection of renal artery stenosis with lumen diameter narrowing $\geq 60\%$. However, renal ultrasonography with colour Doppler sonography is preferred as a screening method which helps to exclude renal vein thrombosis [37-39].

Nephrotic syndrome is uncommon among patients with primary APS, being more frequent in patients with secondary APS concomitant with SLE [40]. In the large patient cohort described by Tektonidou and co-workers, patients with APLN developed hypertension, raised serum creatinine levels and histological progression of lesions, all of which are associated with poor renal. However, the frequency of renal insufficiency did not differ between patients with or without APLN during 7-years follow-up [9].

Usually APLN progresses slowly, only rarely leading to end-stage renal failure [41]. Primary APS is not usually considered in children with unexplained acute renal

failure, nor is it considered to be cause of end-stage renal disease (ESRD), in adults or children [42]. However, there is a case report about a 53-year-old lady with end-stage renal failure in primary APS [43,44].

MACRO-ANATOMIC AND MICROSCOPIC FINDINGS

There are numerous classifications for renal manifestations of APLN based on their location [45]. They can be divided in 3 main groups, each having its own pathogenic, clinical and diagnostic characteristics: (Figure 3)

- Renal artery lesions, secondary to thrombosis, stenosis or occlusion of the main artery (uni- or bilateral)
- Intrarenal vascular lesions (require biopsy confirmation)
- Renal vein thrombosis

- RENAL ARTERY

Renal artery involvement is a relatively common manifestation in patients with APS. In 2003, magnetic resonance angiography (MRA) was performed in 88 APS patients with poor control of their blood pressure and compared them to two control groups, one of young patients with hypertension and the other of potential kidney donors. A total of 20 patients (28%) affected by APS had lesions in the renal artery, significantly higher than in the other groups [46,47].

Although early studies focused on cases of APS associated with SLE, there is an increasing number of reports that focus on the presence of renal artery impairment in patients with primary APS [48].

In 1992, Rossi et al. [49] reported two cases of renovascular hypertension with renal artery stenosis, and suggested a possible relationship between renal stenosis, thrombosis, aPL and fibromuscular dysplasia. This idea was supported by Mandreodi and colleagues [50]. Other studies described many cases of renal artery occlusion as a manifestation of APS, and related them to severe hypertension as the prime clinical manifestation [49,51-60].

In general, two patterns of renal artery stenotic (RAS) lesions, with some unique features, have been documented in APS patients. The more frequent pattern is characterized by smooth, well-delineated, and often noncritical stenosis, distal to the ostium of the renal artery. Less frequently a pattern similar to atherosclerotic lesions, proximal and occasionally involving the aorta has been reported [47, 61, 62].

Thus renal artery occlusion may be due to two different mechanisms; the renal disease may be related to an in situ stenosis or thrombosis, or be due to an embolic event (such as a heart valve vegetation). However, some reports were not able to find a definitive cause for the renal infarction [52].

Occasionally hypertension may not be present in early stages of the disease, which may complicate the differential diagnosis and lead to delayed diagnosis [63].

Therefore, in all cases of unknown cause of renal artery stenosis, a diagnosis of APS should be considered. In addition to laboratory tests, renal scintigraphy and selective renal angiography facilitates the confirmation of the diagnosis and the extent of the lesions [45].

- INTRARENAL VASCULAR LESIONS

- Glomerular thrombosis

Unlike lupus nephritis, where there are studies suggesting that patients with proliferative glomerulonephritis have a capillary thrombosis rate up to 50% and whose presence implies a stronger prognostic marker [64], in primary APS, this finding is not specific. Amigo, et al described vascular lesions (both in arterioles and glomerular capillaries) often presenting with mesangiolytic, mesangial interposition, electronlucent subendothelial material, and ischemic obsolescence of glomeruli. Renal biopsies also showed arterial luminal narrowing due to medial hypertrophy, amorphous mucoid deposits within the intima, thrombosis, and general fibrosis [35,65]

Nochy and colleagues studied kidney biopsy specimens from 16 patients with APS, in which, a combination of glomerular basement membrane wrinkling and reduplication were seen ultra-structurally [66].

Other histopathologic findings have been described, but these are not specific for APLN [45]. (Figure 4)

- Intra-renal vascular lesions

Several reviews considered the involvement of the renal microvasculature to be the most frequent biopsy finding [67-69].

Gerhandsson et al. described 236 renal biopsies from 112 SLE patients concluding that, in comparison to patients with pure lupus nephritis, the presence of APLN was associated with intimal changes, inflammatory infiltrates, interstitial fibrosis and tubular atrophy [10].

The most commonly reported and characteristic intrarenal vascular lesion, in patients with APS [35,45,70-73] is TMA, characterized by the presence of distinctive microscopic and ultrastructural changes [74].

The most common clinical features of TMA include: hypertension, proteinuria, and renal impairment. Proteinuria is often mild but can be within nephrotic range [35,75].

Histologically, focal or diffuse microangiopathic changes, affecting the whole intrarenal vascular tree and the glomerular tufts, have been observed [35,66].

TMA is characterized by the presence of fibrin thrombi in glomeruli and/or renal arterioles and an absence of immune complexes and inflammatory cells. It lacks an association with any specific histologic class of lupus nephritis [30]. Rarely, TMA can be associated to diffuse mesangial interposition with numerous double contours. By immunofluorescence (IF), the immunoglobulins are absent and the thrombi contain fibrin.

Intrarenal TMA may be the first manifestation that leads to a diagnosis of primary APS [76]. It has been emphasized that APS should be considered in the differential diagnosis of systemic hypertension and, that APS-related TMA may cause isolated hypertension without significant renal impairment.

Histologically, the morphological features of TMA are specific to a pathophysiology associated with thromboses, but they do not show any etiologic specificity. Other conditions including thrombotic thrombocytopenic purpura, haemolytic uremic syndrome, post-partum renal failure, pre-eclampsia/eclampsia, scleroderma, malignant arterial hypertension or drugs (cyclosporine, chemotherapy, contraceptives), can produce similar lesions. The morphologic lesions are insufficient to make an "etiologic diagnosis", and require additional clinical and laboratory data, including aCL and LA determination, as well as exclusion of colibacillary infections, chronic hypertension, systemic sclerosis among others [45,77].

A recent study [78] found that the inclusion of renal vascular lesions in the 2003 International Society of Nephrology/Renal Pathology Society (ISN/RPS) histological classification system of lupus nephritis, improves renal outcome prediction. TMA was associated with the poorest renal outcome among the other renal vascular lesions.

Atherosclerosis, among the fibrous lesions, present in 75% of biopsies in some reports [35], is not specific. By contrast, fibrous intimal hyperplasia (FIH) (described in 75% of the specimens), arteriolar occlusions (68%) and focal cortical atrophy (FCA) (62%) are only seen infrequently in other vascular nephropathies, and are highly suggestive of APLN when they are observed in the same biopsy with interstitial fibrosis and foci of tubular atrophy with pseudothyroidization (75%)

FIH of arterioles and interlobular arteries show a plexiform pattern of tortuous vessels with a cellular proliferation of actin-positive myofibroblastic cells in the intima, associated with an increased extracellular matrix. Most of these vessels have a reduced lumen obstructed by fibrous projections, cushions or organizing thrombi with recanalization [36].

FIH with organized thrombi was the second vascular lesion observed [79] in renal biopsies from a group of pregnant women with APS and LA. These lesions were also described by others in patients with primary APS, not only in intrarenal arteries, but also in other organs like: brain, lung, heart or skin [72,80-83].

The fibrotic vascular lesions of typical nephroangiosclerosis (NAS) are relatively acellular, with diffuse arteriosclerosis and exceptional FIH. Arteriosclerosis is more fibrous, often characterized by an atrophic media with, on occasions, an

onion-skin arrangement of the intima of the blood vessels.

Tubular atrophy with pseudothyroidization and interstitial fibrosis are frequently observed, but tend to be more diffusely distributed without the isolated subcapsular foci, typical of FCA. This appearance is likely to be because the lesions of typical NAS are more uniformly distributed than is the case for FCA in APLN. Furthermore, the organized thrombi, responsible for vascular occlusion in APLN, are absent in NAS [4].

Among the chronic pathological aspects, atherosclerosis is typically associated with intimal fibrous hyperplasia, thickening of arteries due to fibrosis, and proliferation of myofibroblastic cells; with the consequent lumen restriction and ischemia, which is common in APLN and rarely seen in other nephropathies [36,84].

Redundant and wrinkled segments of basal membrane accompanied by a duplicate straighter thin membrane adjacent to the endothelium have been reported as a pathognomonic feature of the syndrome. In addition, some authors suggest an association between minimal change nephropathy and focal segmental glomerulosclerosis, both as independent clinical-pathological presentations of APLN [39,74,85]

Fakhouri and co-workers [86] reported some new aspects of the renal involvement in APS, in a study of 29 biopsies from patients with GN associated with APS in the absence of underlying autoimmune disorders. Twenty biopsies showed characteristic APLN features. However, predominant pathological features, distinct from vascular APS nephropathy, were noted in 9 biopsies, including: membranous nephropathy (MN) (3 cases), minimal change disease/focal segmental glomerulosclerosis (3 cases), mesangial C3 nephropathy (2 cases), and pauci-immune crescentic GN (1 case).

Other cases of MN in association with APS have been reported [72,86-88]. Moreover, in a series reported by Quereda and colleagues, aPL were detected in 3 out of 15 patients with MN (20%), 2 of whom fulfilled APS diagnostic criteria [89].

- Cortical renal ischemia

Occlusion of small isolated parenchymatous renal vessels causes small foci of cortical necrosis. These are generally asymptomatic. However, if they are multiple or generalized they may lead to patchy or diffuse cortical necrosis as described in the catastrophic APS [90].

One of the first reported cases was a 27-year-old man with coronary occlusion, arterial hypertension, thrombophlebitis, atrial thrombus, and positive aPL. An abdominal CT scan revealed cortex hypodensity in both kidneys. Renal biopsy showed diffuse interstitial fibrosis, mononuclear infiltration, sclerotic and ischemic glomeruli with negative immunofluorescence studies. These findings suggest cortical sclerosis and atrophy as sequelae from old cortical necrosis [91].

Pérez et al. [83] reported a man with APS and multi-organ arterial and venous thrombosis, seemingly a catastrophic syndrome. This patient had a 2-cm renal

cortical infarction and multiple petechiae in the renal cortex. At autopsy, an organizing interlobular vein thrombus plus microthrombi in the microvasculature of the medulla were found. This case illustrated medium- and small-vessel thrombosis affecting the intra- and extra-renal vasculature.

The FCA, located in the subcapsular renal cortex, associated with dense interstitial fibrosis leading to tissue retraction and kidney contour depression, giving it a scar-like appearance with sharp borders surrounded by areas of normal parenchyma, which is considered to be very typical of APLN [24,84].

The fibrotic lesions of FIH and FCA are observed in surgical nephrectomies performed to reduce hypertension in cases of unilateral renal artery stenosis. In these surgical samples, zones of subcapsular depression representing foci of FCA with ischemic and cystic changes can be found with vascular lesions of FIH, often quite proliferative, with zones of tubular pseudothyroidization.

The great similarities of these lesions with those of APLN suggest they have the same pathophysiology. This could be the consequence of parenchymal ischemia and activation of the renin-angiotensin system. By contrast, the vascular occlusions by thrombi with recanalization are not seen in these kidneys downstream nor are arterial stenosis [4].

Amigo and García-Torres suggested that cortical renal ischemia is a well-defined clinicopathologic entity in patients with APS. The lesion may leave a variable impairment of renal function [45].

The additional presentation of renal cortical ischemia was described by Leaker et al. [75] This is an insidious, slowly progressive nephropathy that in the long term, leads to renal failure. Clinically, patients have arterial hypertension, mild proteinuria, and a slowly progressive renal failure.

- Renal vein thrombosis

Surprisingly, renal vein thrombosis is a rare complication of primary APS, whereas peripheral vein thrombosis is a common feature. By contrast, renal vein thrombosis is a well-known complication of membranous nephropathy with nephrotic syndrome, either idiopathic or associated with SLE [92-96].

Isolated cases of renal vein thrombosis have been reported in patients with PAPS, including one case of bilateral renal vein thrombosis in the postpartum period [96].

TREATMENT

Control of hypertension, associated with various other drugs (antiplatelet drugs, anticoagulants, steroids, or rarely plasma exchange) may lead to remarkable improvement in renal function [1,69,76,97,98].

Heparin anticoagulation, followed by long-term vitamin K antagonist anticoagulation is the mainstay of thrombotic APS therapy. However, a significant proportion of patients have recurrent thrombosis despite antithrombotic therapy

[99]. Vitamin K antagonists are also problematic due to food or drug interactions, bleeding complications, and the need for frequent monitoring. Furthermore, aPL interact variably with different thromboplastin reagents, affecting the prothrombin time monitoring and international normalized ratio [100].

Sangle et al. reported the effect of anticoagulation on blood pressure (BP) control and renal function in hypertensive APS patients. 14 such APS patients with renal artery stenosis, who received oral anticoagulation for more than 1 year, were studied retrospectively. Patients were divided into 2 groups based on their International Normalized Ratio (INR) (<3.0 and ≥ 3.0). The results suggested that patients whose INR was maintained ≥ 3.0 did well, their BP was better controlled (BP was 120/80 mm Hg), renal function remained stable or improved, and renal artery stenosis was reversed in some patients. In contrast, patients with a median INR <3.0 had poorly controlled BP, a significant deterioration in mean serum creatinine values [101].

Remondino and coworkers [102] described recanalization of bilateral RAS and BP normalization in a young hypertensive woman with APS. These findings support the idea that anticoagulation with maintained ≥ 3.0 INR, may have an important role in preventing the progression of these renal artery lesions.

However, the role of anticoagulation therapy in the evolution of renal function is uncertain, due to the limited number of patients and follow-up period in the majority of cases [30]. Even when full anticoagulation is administered following renal allografting, the risks of graft loss and systemic thrombosis were not completely eliminated [103].

Unfortunately, there are no available recommendations about the optimal anticoagulation regimen to be used during renal transplantation.

The risk of systemic or renal vasculature thrombosis is high in aPL-positive patients; However, the risk of graft failure due to major bleeding should be considered. In addition, the anticoagulation therapy efficacy in preventing thrombotic microangiopathy is uncertain [104,105].

The oral direct thrombin inhibitors (dabigatran) and direct factor Xa inhibitors (rivaroxaban and apixaban) overcome some of these disadvantages. They are prescribed at a fixed dose, do not need routine monitoring, and have few drug or food interactions. However, they are irreversible and there is limited experience in patients with APS. There are no data recommending their use in APS patients with APLN, though results of the RAPS (rivaroxaban in anti-phospholipid antibody syndrome) study comparing warfarin and rivaroxaban in PAS patients with history of venous thrombosis are expected shortly.

Good control of systemic hypertension may be hard to achieve, but is vital to prevent the progression to end-stage renal disease [43].

Biologic therapy

Other therapeutic approaches have been attempted in refractory cases, including

the use of intravenous Ig, plasmapheresis and rituximab [106,107].

Rituximab has been shown to decrease the titres of aPL and, therefore, should decrease the thrombotic risk of patients with APS [108]. Thus, Ioannou and colleagues [109] reported a major fall in IgG anticardiolipin (aCL) antibody titres in seven SLE patients who had received treatment with rituximab and cyclophosphamide. Moreover, 8 out of 12 APS patients treated with rituximab due to recurrent thrombosis or refractory thrombocytopenia showed normalization or a reduction in aPL titres [110]. The Rituximab in AntiPhospholipid Syndrome (RITAPS) trial, a prospective, open-label, phase II trial of rituximab in primary APS patients, reported that rituximab is also effective in controlling some noncriteria manifestations of APS such as thrombocytopenia, haemolytic anaemia, skin ulcers, and nephropathy [111]. The authors suggested that improvement might be due to the blockade of B-cell effector functions independent of antibody production.

Two APLN patients were included in the open-label phase II trial of rituximab for non-criteria manifestations of APS; one patient withdrew early due to an infusion reaction, and the other had a partial response to treatment with rituximab [112].

Given this evidence, rituximab is an attractive alternative in the treatment of APLN. Reducing the number of B cells, rituximab may decrease both the aPL titres and also the production of ferritin and cytokines such as tumor necrosis factor-alpha, interleukin (IL)-1, IL-2, and IL-6, that may be responsible for some of the clinical features of APS [112].

Abatacept, a CTLA4 blocker, and belimumab, a BAFF antagonist, are approved for the treatment of rheumatoid arthritis and SLE, respectively, but to our knowledge have not yet been used in patients with antiphospholipid syndrome.

Complement inhibition with the C5a inhibitor eculizumab has been successfully used in isolated kidney post-transplant TMA cases [113]. Eculizumab carries a risk of infection with encapsulated organisms and patients should be immunized against meningococcus before starting treatment [114].

The therapeutic effects on the complement inhibition, tissue factor inhibition and anti-CD20, need to be investigated in prospective long-term studies. Further research on APS pathogenesis may identify new potential targets for its treatment. Multicenter, prospective studies are also needed for the validation of APLN histological criteria and the identification of histological, clinical and laboratory characteristics of this worse renal prognosis nephropathy.

Disclosure statement

Neither of the authors has any relevant disclosures in relation to this manuscript.

1. Miyakis S, Lockshin MD, Atsumi T et al. International consensus statement on an update of the classification criteria for definite antiphospholipid syndrome (APS). *J Thromb Haemost*. 2006;4:295–306
2. Sinico RA1, Cavazzana I, Nuzzo M et al. Renal involvement in primary antiphospholipid syndrome: retrospective analysis of 160 patients. *Clin. J. Am. Soc. Nephrol* 2010;5:1211–1217.
3. Jordan N, Chaib A, Sangle S, et al. Association of thrombotic microangiopathy and intimal hyperplasia with bleeding post-renal biopsy in antiphospholipid antibody-positive patients. *Arthritis Care Res*. 2014; 66(5): 725-31.
4. Nochy D1, Daugas E, Hill G, Grünfeld JP. “Antiphospholipid Syndrome Nephropathy.” *Journal of Nephrology*. 2002;15(4): 446–61.
5. Meroni PL, Borghi MO, Raschi E, Tedesco F. Pathogenesis of antiphospholipid syndrome: understanding the antibodies. *Nat Rev Rheumatol* 2011;7:330–339.
6. Giannakopoulos B, Krilis SA. The pathogenesis of the antiphospholipid syndrome. *N Engl J Med* 2013;11:1033 –1044.
7. Uthman IW, Gharavi AE. Viral infection and antiphospholipid antibodies. *Semin Arthritis Rheum*. 2002;31:256–263.
8. Van Os GM1, Meijers JC, Agar Ç, et al. Induction of anti-b2 glycoprotein I autoantibodies in mice by protein H of *Streptococcus pyogenes*. *J Thromb Haemost* 2011; 9:2447 – 2456.
9. Tektonidou MG, Sotsiou F, Nakopoulou L, et al. Antiphospholipid syndrome nephropathy in patients with systemic lupus erythematosus and antiphospholipid antibodies. *Arthritis Rheum* 2004;50:2569-79.
10. Gerhardtsson J, Sundelin B, Zickert A et al. “Histological Antiphospholipid-Associated Nephropathy versus Lupus Nephritis in Patients with Systemic Lupus Erythematosus: An Observational Cross-Sectional Study with Longitudinal Follow-Up.” *Arthritis Research & Therapy*. 2015;17:109
11. Zheng H, Chen Y, Ao W, et al. Antiphospholipid antibody profiles in lupus nephritis with glomerular microthrombosis: a prospective study of 124 cases. *Arthritis Res Ther*. 2009;11:R93.
12. Prieto LN, Suki WN. Frequent hemodialysis graft thrombosis: association with antiphospholipid antibodies. *Am J Kidney Dis* 1994;23: 587-90.
13. Prakash R, Miller CC Suki WN. Anticardiolipin antibody in patients on maintenance hemodialysis and its association with recurrent arteriovenous graft thrombosis. *Am J Kidney Dis* 1995;26:347-52.
14. Daugas E, Nochy D, Huong DL, et al. Antiphospholipid syndrome nephropathy in systemic lupus erythematosus. *J Am Soc Nephrol*. 2002;13:42–52.
15. Chew SL, Lins RL, Daelemans R, et al. Are antiphospholipid antibodies clinically relevant in dialysis patients? *Nephrol Dial Transplant* 1992;7:1194-8.
16. Haviv YS. Association of anticardiolipin antibodies with vascular access occlusion in hemodialysis patients: cause or effect? *Nephron* 2000;86:447-54.
17. Bhandari S, Harnden P, Brownjohn AM, Turney JH. Association of anticardiolipin antibodies with intraglomerular thrombi and renal dysfunction in lupus nephritis. *QJM* 1998;91: 401-9.
18. Nochy D, Daugas E, Piette J-C. Antiphospholipid syndrome nephropathy in systemic lupus erythematosus. *J Am Soc Nephrol* 2002;13: 42-52
19. Cheunsuchon B, Rungkaew P, Chawanasantorapoj R, et al. Prevalence and clinicopathologic findings of antiphospholipid syndrome nephropathy in Thai systemic lupus erythematosus patients who underwent renal biopsies. *Nephrology* 2007;12:474-80.
20. Silvairiño R, Sant F, Espinosa G, et al. Nephropathy associated with antiphospholipid antibodies in patients with systemic lupus erythematosus. *Lupus* 2011; 20: 721–729.
21. Simantov R, LaSala JM, Lo SK, et al. Activation of cultured vascular endothelial cells by antiphospholipid antibodies. *J Clin Invest* 1995; 96:2211 – 2219.
22. Zhang J, McCrae KR. Annexin A2 mediates endothelial cell activation by antiphospholipid/antibeta2 glycoprotein I antibodies. *Blood* 2005; 105: 1964 – 1969.
23. Nojima J, Masuda Y, Iwatani Y, et al. Tissue factor expression on monocytes induced by antiphospholipid antibodies as a strong risk factor for thromboembolic complications in SLE patients. *Biochem Biophys Res Commun* 2008; 365:195 – 200.

24. Martinuzzo ME, Maclouf J, Carreras LO, Levy-Toledano S. Antiphospholipid antibodies enhance thrombin-induced platelet activation and thromboxane formation. *Thromb Haemost* 1993; 70:667 – 671.
25. Williams FM, Parmar K, Hughes GR, Hunt BJ. Systemic endothelial cell markers in primary antiphospholipid syndrome. *Thromb Haemost* 2000; 84:742 – 746.
26. Canaud G, Bienaimé F, Tabarin F, et al. “Inhibition of the mTORC Pathway in the Antiphospholipid Syndrome.” *New England Journal of Medicine*. 2014;371(4):303–12.
27. Rauch J, Dieude M, Subang R, Levine JS. The dual role of innate immunity in the antiphospholipid syndrome. *Lupus* 2010; 19:347 – 353.
28. Aguilar-Valenzuela R, Nickerson K, Romay-Penabad Z, et al. Involvement of TLR7 and TLR9 in the production of antiphospholipid antibodies. *Arthritis Rheum* 2011; 63:s281.
29. Broder A, Putterman C. Hydroxychloroquine use is associated with lower odds of persistently positive antiphospholipid antibodies and/or lupus anticoagulant in systemic lupus erythematosus. *J Rheumatol* 2013; 40:30 – 33
30. Tektonidou, M. “Identification and Treatment of APS Renal Involvement.” *Lupus*. 2014;23(12): 1276–78.
31. Fischetti F, Durigutto P, Pellis V, et al. Thrombus formation induced by antibodies to beta 2-glycoprotein I is complement dependent and requires a priming factor. *Blood* 2005; 106:2340 – 2346. 46.
32. Ritis K, Doumas M, Mastellos D, et al. A novel C5a receptor-tissue factor crosstalk in neutrophils links innate immunity to coagulation pathways. *J Immunol* 2006; 177:4794 – 4802.
33. Lonze BE, Zachary AA, Magro CM, et al. Eculizumab prevents recurrent antiphospholipid antibody syndrome and enables successful renal transplantation. *Am J Transplant* 2014; 14:459 – 465.
34. Sciascia S, Cuadrado MJ, Khamashta M, Roccatello D. “Renal Involvement in Antiphospholipid Syndrome.” *Nature Reviews Nephrology*. 2014;10(5):279–89.
35. Amigo MC, Garcia-Torres R, Robles M, Bochicchio T, Reyes PA. Renal involvement in primary antiphospholipid syndrome. *J Rheumatol* 1992;19:118-25.
36. Nochy D, Daugas E, Droz D et al. The intrarenal vascular lesions associated with primary antiphospholipid syndrome. *J. Am. Soc. Nephrol.* 1999; 10: 507–518.
37. Voiculescu A, Hofer M, Hetzel GR, et al. Noninvasive investigation for renal artery stenosis: contrast-enhanced magnetic resonance angiography and color Doppler sonography as compared to digital subtraction angiography. *Clin. Exp. Hypertens.* 2011;23:521–531.
38. Rountas, C. Imaging modalities for renal artery stenosis in suspected renovascular hypertension: prospective intraindividual comparison of color Doppler, US, CT angiography, GD-enhanced MR angiography, and digital subtraction angiography. *Ren. Fail.* 2007;29:295–302.
39. D’Cruz DP. Renal manifestations of the antiphospholipid syndrome. *Lupus* 2005;14:45-8.
40. Moss, K. E. & Isenberg, D. A. Comparison of renal disease severity and outcome in patients with primary antiphospholipid syndrome, antiphospholipid syndrome secondary to systemic lupus erythematosus (SLE) and SLE alone. *Rheumatology (Oxford)*. 2001;40:863–867.
41. Saracino A, Ramunni A, Pannarale G, Coratelli P. “Kidney Disease Associated with Primary Antiphospholipid Syndrome: Clinical Signs and Histopathological Features in an Case Experience of Five Cases.” *Clinical Nephrology*. 2005;63(6):471–76.
42. Butani L. “End-Stage Renal Disease from Glomerulonephritis Associated with Anti-Phospholipid Syndrome.” *Pediatric Nephrology*: 2004;19(7):812–14.
43. Dayal, N. A, Isenberg D.A. “Endstage Renal Failure in Primary Antiphospholipid Syndrome-- Case Report and Review of Literature.” *Rheumatology*. 2003;42(9):1128–29.
44. Sciascia S., Lopez-Pedraera C., Roccatello D. and Cuadrado M. J. Catastrophic antiphospholipid syndrome (CAPS). *Best Pract. Res. Clin. Rheumatol.* 2012;26:535–541.
45. García-Torres R, and Amigo MC. “Kidney Disease in Antiphospholipid Syndrome.” *Rheum Dis Clin North Am.* 2006;32(3):509–22.
46. Sangle SR, D’Cruz DP, Jan W, et al. Renal artery stenosis in the antiphospholipid (Hughes) syndrome and hypertension. *Ann Rheum Dis* 2003;62:999-1002.
47. Harris EN, Gharavi AE, Boey C, et al. Anticardiolipin antibodies: detection by radioimmunoassay and association with thrombosis in systemic lupus erythematosus. *Lancet* 1983;II:1211–1214.
48. Alarcón-Segovia D, Cardiel MH, Reyes E. Antiphospholipid arterial vasculopathy. *J Rheumatol* 1989;16:762–767.
49. Rossi E, Sani C, Zini M, Casoli MC, Restori G. Anticardiolipin antibodies and renovascular hypertension. *Ann Rheum Dis* 1992;51:1180–1181.

50. Mandreoli M, Zucchelli P. Renal vascular disease in patients with primary antiphospholipid antibodies. *Nephrol Dial Transplant* 1993;8:1277–1280.
51. Asherson RA, Noble GE, Hughes GR. Hypertension, renal artery stenosis and the “primary” antiphospholipid syndrome. *J Rheumatol* 1991;18:1413-5.
52. Cacoub P, Wechsler B, Piette JC, et al. Malignant hypertension in antiphospholipid syndrome without overt lupus nephritis. *Clin Exp Rheumatol* 1993;11:479-85.
53. Riccialdelli L, Arnaldi G, Giacchetti G, Pantanetti P, Mantero F. Hypertension due to renal artery occlusion in a patient with antiphospholipid syndrome. *Am J Hypertens* 2001;14:62-5.
54. Sirvent AE, Enriquez R, Antolin A, et al. Malignant hypertension and antiphospholipid syndrome. *Nephron* 1996;73:368-9.
55. Serino R, Osajima A, Hiroshige K, et al. Renovascular hypertension associated with antiphospholipid antibodies in a woman with systemic lupus erythematosus. *Nippon Jinzo Gakkai Shi* 1996;38:417-22.
56. Ames PR, Cianciaruso B, Bellizzi V, et al. Bilateral renal artery occlusion in a patient with primary antiphospholipid antibody syndrome: thrombosis, vasculitis or both? *J Rheumatol* 1992;19:1802-6.
57. Mandreoli M, Zuccala A, Zucchelli P. Fibromuscular dysplasia of the renal arteries associated with antiphospholipid autoantibodies: two case reports. *Am J Kidney Dis* 1992;20:500–503.
58. Poux JM, Boudet R, Lacroix P, et al. Renal infarction and thrombosis of the infrarenal aorta in a 35 year-old man with primary antiphospholipid syndrome. *Am J Kidney Dis* 1996;27:721–725.
59. Godfrey T, Khamashta MA, Hughes GRV, Abbs I. Antiphospholipid syndrome and renal artery stenosis. *Q J Med* 2000;93:127–129.
60. Aizawa K, Nakamura T, Sumino H, et al. Renovascular hypertension observed in a patient with antiphospholipid-antibody syndrome. *Jpn Circ J* 2000;64:541–543.
61. George J, Shoenfeld Y. The anti-phospholipid (Hughes) syndrome: a crossroads of autoimmunity and atherosclerosis. *Lupus* 1997;6:559- 60.
62. Harats D, George J, Levy Y, et al. Atheroma: links with antiphospholipid antibodies, Hughes syndrome and lupus. *QJM* 1999;92:57-9.
63. Hughes GRV, Harris EN, Gharavi AE. The anticardiolipin syndrome. *JRheumatol* 1987; 13: 486–489.
64. Kant KS, Polla KVE, Weiss MA, et al. Glomerular thrombosis in systemic lupus erythematosus: Prevalence and significance. *Medicine (Baltimore)* 1981;60:71–86.
65. Glueck HI, Kant KS, Weiss MA, et al. Thrombosis in systemic lupus erythematosus. Relation to the presence of circulating anticoagulants. *Arch Intern Med* 1985;145:1389–1395.
66. Nochy D, Daugas E, Droz D, et al. The intrarenal vascular lesions associated with primary antiphospholipid syndrome. *J Am Soc Nephrol* 1999;10:507-18.
67. Dmorongkitchaiporns S, Cameron EC, Jetha N, Kassen BO, Sutton RA. Renal microangiopathy in the primary antiphospholipid syndrome: a case report with literature review. *Nephron* 1994; 68: 128-32.
68. Petras T, Rudolph B, Filler G, et al. An adolescent with acute renal failure, thrombocytopenia and femoral vein thrombosis. *Nephrol Dial Transplant* 1998; 13: 480-3
69. Hamidou MA, Moreau A, Jego P, et al. Captopril and aspirin in treatment of renal microangiopathy in primary antiphospholipid syndrome. *Am J Kidney Dis* 1995; 25: 486-8
70. Piette JC, Cacoub P, Wechsler B. Renal manifestations of the antiphospholipid syndrome. *Semin Arthritis Rheum* 1994;23:357-66
71. Kleinknecht D, Bobrie G, Meyer O, et al. Recurrent thrombosis and renal vascular disease in patients with a lupus anticoagulant. *Nephrol Dial Transplant* 1989;4:854-8
72. D’Agati V, Kunis C, Williams G, Appel GB. Anti-cardiolipin antibody and renal disease: a report of three cases. *J Am Soc Nephrol* 1990;1: 777-84.
73. Becquemont L, Thervet E, Rondeau E, et al. Systemic and renal fibrinolytic activity in a patient with anticardiolipin syndrome and renal thrombotic microangiopathy. *Am J Nephrol* 1990;10:254-8.
74. Griffiths MH, Papadaki L, Neild GH. The renal pathology of primary antiphospholipid syndrome: a distinctive form of endothelial injury. *QJM* 2000;93:457-67.
75. Leaker B, McGregor A, Griffiths M, et al. Insidious loss of renal function in patients with anticardiolipin antibodies and absence of overt nephritis. *Br J Rheumatol* 1991;30:422-5.
76. Lacueva J, Enriquez R, Cabezuolo JB, et al. Acute renal failure as first clinical manifestation of the primary antiphospholipid syndrome. *Nephron* 1993; 64: 479-80.
77. Karim MY, Alba P, Tungekar MF, et al. Hypertension as the presenting feature of the antiphospholipid syndrome. *Lupus* 2002;11:253–256.

78. Wu LH, Yu F, Tan Y, et al. Inclusion of renal vascular lesions in the 2003 ISN/RPS system for classifying lupus nephritis improves renal outcome predictions. *Kidney Int* 2013; 83: 715–723.
79. Kincaid-Smith P, Fairley KF, Kloss M. Lupus anticoagulant associated with renal thrombotic microangiopathy and pregnancy-related renal failure. *Q J Med* 1988; 68: 795-815.
80. Asherson RA, Cervera R, Piette JC, et al. Catastrophic antiphospholipid syndrome. Clinical and laboratory features in 50 patients. *Medicine (Baltimore)* 1998; 77: 195-207
81. Isenberg DA, Griffiths M, Neild GH. Woman with livedo reticularis, renal failure, and benign urinary sediment. *Nephrol Dial Transplant* 1995; 10: 295-7.
82. Hughson MD, McCarty GA, Brumback RA. Spectrum of vascular pathology affecting patients with the antiphospholipid syndrome. *Hum Pathol* 1995; 26: 716-24.
83. Perez RE, McClendon JR, Lie JT. Primary antiphospholipid syndrome with multiorgan arterial and venous thromboses. *J Rheumatol* 1992; 19: 1289-92.
84. Nochy D. Antiphospholipid syndrome nephropathy. *Ann Med Interne Paris* 2003;154:51-8.
85. Rossinol T, Cervera R, López C, Sole M, Ramos-Casals M, Font J. Antiphospholipid syndrome and minimal change nephropathy. *Lupus* 2006;15:547.
86. Fakhouri F, Noel LH, Zuber J, et al. The expanding spectrum of renal diseases associated with antiphospholipid syndrome. *Am J Kidney Dis* 2003;41:1205-11.
87. Levy Y, George J, Ziporen L, et al. Massive proteinuria as a main manifestation of primary antiphospho- lipid syndrome. *Pathobiology* 1998;66:49-52.
88. Dorel M, Daniel L, Liprandi A, Lerda D, Pellissier JF. Idiopathic membranous glomerulonephritis associated with primary antiphospho- lipid syndrome. *Nephron* 2000;86:366-7.
89. Quereda C, Otero GG, Pardo A, Orte L, et al. Prevalence of antiphospholipid antibodies in nephropathies not due to systemic lupus erythematosus. *Am J Kidney Dis* 1994;23:555-61.
90. Asherson RA. The catastrophic antiphospholipid syndrome. *J Rheumatol* 1992;19:508–512.
91. Ramdane M, Gryman R, Bacques P, Callard P, Kleinknecht D. Ischémie rénale corticale, thrombose auriculaire droite et occlusion coronaire au cours d'un syndrome des anticorps antiphospholipides. *Néphrologie* 1989;10:189–193.
92. Ko Ws, Lim PS, Sung YP. Renal vein thrombosis as first clinical manifestation of the primary antiphospholipid syndrome. *Nephrol Dial Transplant* 1995; 10: 1929-31
93. La Milia V, Tentori F, Pozzi C, Taddei G, Locatelli F. Primary antiphospholipid antibody syndrome with membranous obstruction of the interior vena cava- succesful PTA and thrombolytic therapy. *Nephrol Dial Transplant* 1998; 13:2641-4
94. Liano F, Mampaso F, Garcia Martin F, et al. Allograft membranous glomerulonephritis and renal-vein thrombosis in a patient with a lupus anticoagulant factor. *Nephrol Dial Transplant* 1988; 3: 684-9
95. Morgan RJ, Feneley CL. Renal vein thrombosis caused by primary antiphospholipid syndrome. *Br J Urol* 1994;74:807–808.
96. Asherson RA, Buchanan N, Baguley E, Hughes GRV. Postpartum bilateral renal vein thrombosis in the primary antiphospholipid syndrome. *J Rheumatol* 1993;20:874–876.
97. Sokunbi DO, Miller F, Wadhwa NK, Nord EP. Reversible renal failure in the primary antiphospholipid síndrome- a report of two cases. *J Am Soc Nephrol* 1993; 4: 28-35.
98. [No authors listed] KDIGO clinical practice guideline for glomerulonephritis—chapter 12: lupus nephritis. *Kidney Int. Suppl.* 2012; 2:S221–S232.
99. Cervera R, Khamashta MA, Shoenfeld Y, et al. Morbidity and mortality in the antiphospholipid syndrome during a 5 year period: a multicenter prospective study of 1000 patients. *Ann Rheum Dis* 2009; 68:1428 – 1432.
100. Tripodi A, Chantarangkul V, Clerici M, et al. Laboratory control of oral anticoagulant treatment by the INR system in patients with the antiphospholipid syndrome and lupus anticoagulant. *Br J Haematol* 2001; 115:672 – 678.
101. Sangle SR, D'Cruz DP, Abbs IC, Khamashta MA, Hughes GR. Renal artery stenosis in hypertensive patients with antiphospholipid (Hughes) syndrome: outcome following anticoagulation. *Rheumatology (Oxford)* 2005;44:372-7.
102. Remondino GI, Mysler E, Pissano MN, et al. A reversible bilateral renal artery stenosis in association with antiphospholipid syndrome. *Lupus* 2000;9:65-7.
103. Amigo MC, Garcia-Torres R. Morphology of vascular, renal, and heart lesions in the antiphospholipid syndrome: relationship to pathogenesis. *Curr Rheumatol Rep* 2000;2:262-70.
104. Barbour TD, Crosthwaite A, Chow K, et al. Antiphospholipid syndrome in renal transplantation. *Nephrology.* 2014;19:177–85.
105. Espinosa G, and Cervera R. “Current Treatment of Antiphospholipid Syndrome: Lights and

- Shadows.” *Nature Reviews Rheumatology*. 2015;11(10):586-96.
106. Chaturvedi S, McCrae KR. “Recent Advances in the Antiphospholipid Antibody Syndrome” *Current Opinion in Hematology*. 2014;21(5): 371–79.
 107. Silverman, G. and Weisman, S. Rituximab therapy and autoimmune disorders: prospects for anti-B cell therapy. *Arthritis Rheum*. 2003; 48: 1484–1492
 108. Youinou, P. and Renaudineau, Y. The antiphospholipid syndrome as a model for B cell-induced autoimmune diseases. *Thromb Res*; 2004;114: 363–369
 109. Ioannou Y, Lambrianides A, Cambridge et al. B cell depletion therapy for patients with systemic lupus erythematosus results in a significant drop in anticardiolipin antibody titres. *Ann Rheum Dis* 2008;67: 425–426
 110. Erre G, Pardini S, Faedda R and Passiu G. Effect of rituximab on clinical and laboratory features of antiphospholipid syndrome: a case report and a review of literature. *Lupus*. 2008;17: 50–55.
 111. Erkan D, Vega J, Ramón G, Kozora E, Lockshin MD. A pilot open-label phase II trial of rituximab for non-criteria manifestations of antiphospholipid syndrome. *Arthritis Rheum*. 2013; 65: 464–471.
 112. Rodriguez-Pinto I, Cervera R, and Espinosa G. “Rituximab and Its Therapeutic Potential in Catastrophic Antiphospholipid Syndrome.” *Therapeutic Advances in Musculoskeletal Disease*. 2015;1: 26–30.
 113. Safa K, Logan MS, Batal I, et al. Eculizumab for drug-induced de novo post-transplantation thrombotic microangiopathy: A case report. *Clin Nephrol*. 2015 Feb;83(2):125-9.
 114. Erkan D, Aguiar CL, Andrade D, et al. 14th International Congress on Antiphospholipid Antibodies: Task Force report on antiphospholipid syndrome treatment trends. *Autoimmun Rev* 2014; 13:685 – 696.

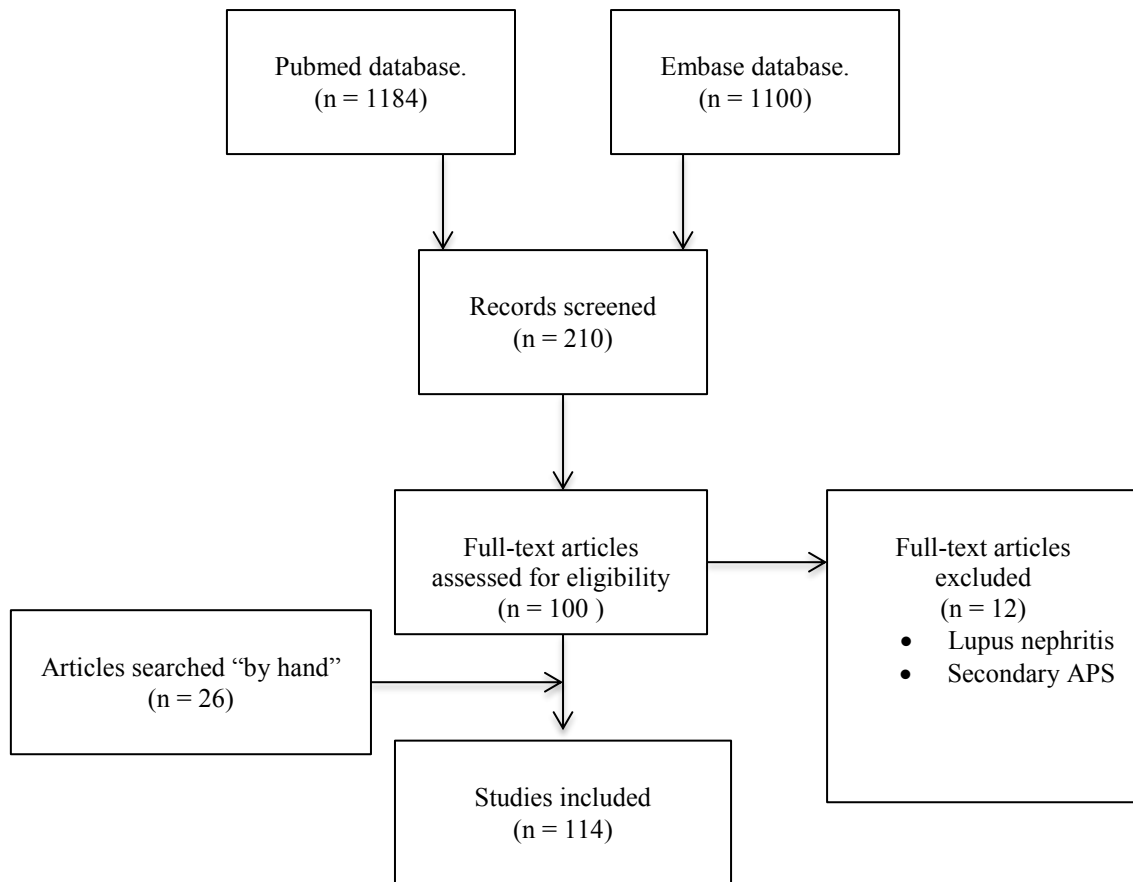


Figure 1.

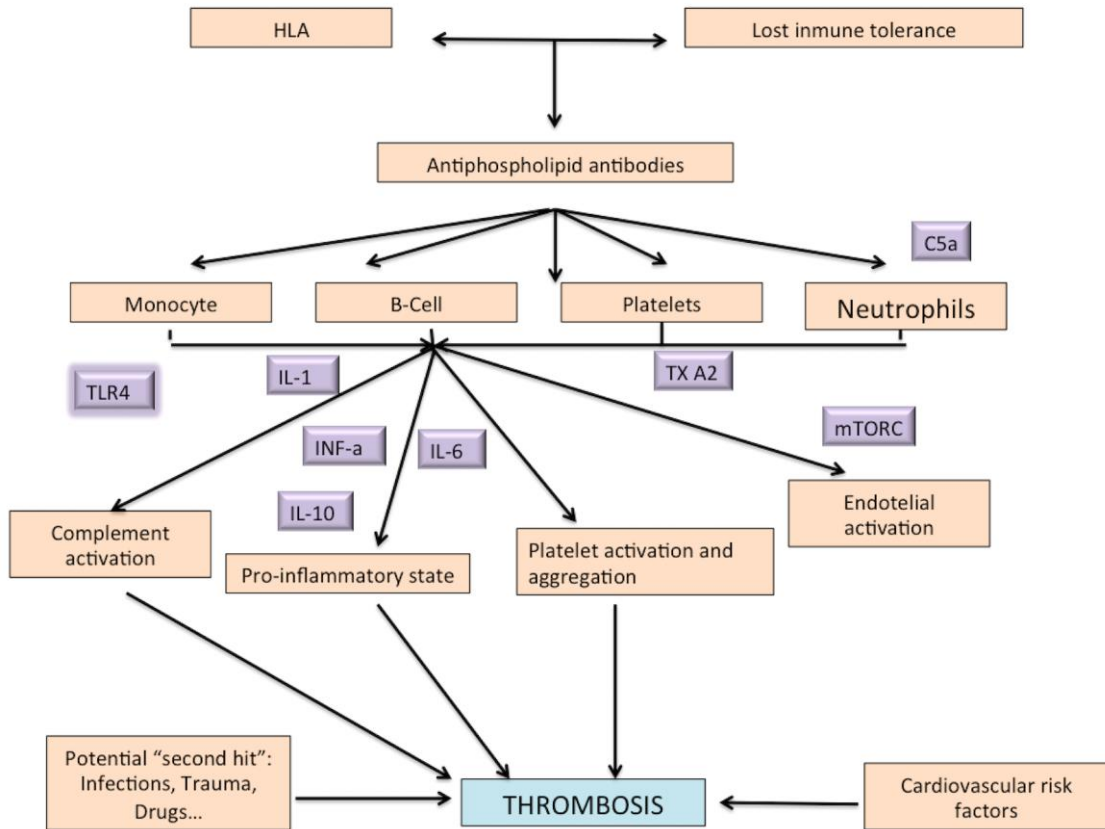


Figure 2. Modified from Chaturvedi, Shruti, and Keith R. McCrae. Recent Advances in the Antiphospholipid Antibody Syndrome. Current Opinion in Hematology 2014; 21(5):371-79.

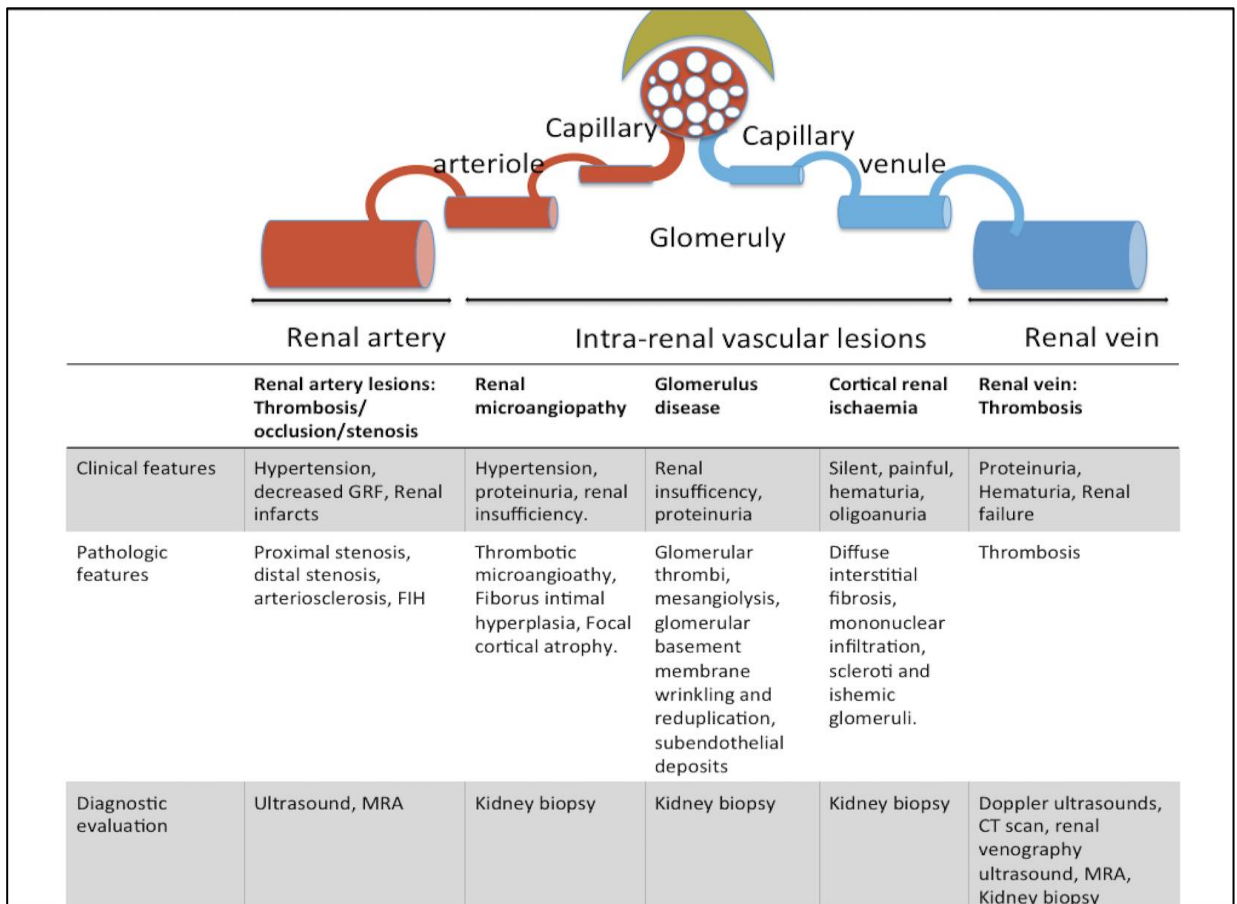


Figure 3. PAPS and renal disease. Modified from R. García-Torres, and MC. Amigo. Kidney Disease in Antiphospholipid Syndrome. *Rheum Dis Clin North Am* 2006; 32(3):509–22 and Uthman, Imad, and Munther Khamashta. Antiphospholipid Syndrome and the Kidneys. *Seminars in Arthritis and Rheumatism* 2006; 35(6): 360–67.

Acute lesions	Chronic lesions
Mesangial expansion	Glomerular Basement membrane thickening
Mesangiolysis	Cellular vanishing
Glomerular capillary collapse	Glomerular tuft retraction
Basement membrane wrinkling	Bowman's space widening
"Double contours" with mesangial interposition	Ischemic obsolescence
Translucent subendothelial deposits	Segmental or global glomerular sclerosis
Intracapillary thrombi	
Thrombotic/haemorrhagic infarction	

Figure 4. Glomerular affectation. Modified from R. García-Torres, and MC. Amigo. Kidney Disease in Antiphospholipid Syndrome. Rheum Dis Clin North Am 2006; 32(3):509-22.