



eastman DENTAL
INSTITUTE

CASE REPORT

**Management of Dento-alveolar Trauma
(Paediatric Dentistry Advanced Clinical Care 3)**

**In partial fulfilment of the degree
Clinical Doctorate in Paediatric Dentistry
Eastman Dental Institute University
College London 2013 - 2016**

**Submitted by
Abdulfatah Alazmah
BDS (Saudi Arabia)
Candidate Number: 12092520**

Content

Content	1
Case Summary	2
Pre-operative Imaging (15/5/2014)	3
a. Intraoral photographs	4
b. Intraoral radiographs	4
Post-operative imaging (19/12/2014)	5
a. Intraoral photographs	5
b. Intraoral radiographs	5
Case History	6
Personal data:	6
Reason for attendance:	6
Chief complaint:	6
Medical History:	6
Social and Family History:	6
Dental History:	7
Dietary History:	7
Oral Hygiene:	7
Habits:	7
Clinical Examination	8
Extra-oral Examination:	8
Intra-oral Examination:	8
Diagnosis and Treatment Planning	10
Diagnosis:	10
Treatment Objectives	10
Provisional Treatment Plan	11
Treatment Progress and Dental Management	12
First Visist 15/5/2014	10
Second Visist 21/5/2014	13
Thirst Visit 11/6/2014	14
Forth Visist 16/9/2014	16
Fifth Visist 1/12/2014	17
Appraisal and Discussion	18
References	20

Case Summery

N.L is a 12 year old female, fit and healthy who suffered pain and difficulty in closing the mouth due to a severe trauma to her upper central incisor teeth at school, she accidentally fell down and hit her face with her knee while playing somersault, she. This accident resulted in lateral luxation injury UR1 and UL1 in addition to uncomplicated Incisal edge of UR1 slightly chipped, grade 1 mobility and gingival inflammation with minimal bleeding from the pocket buccally of UL1. She was immediately transferred to the Accident and Emergency Department by her mum where they took x-rays and prescribed her Amoxicillin for 5 days in liquid form and Calpol as pain killer.

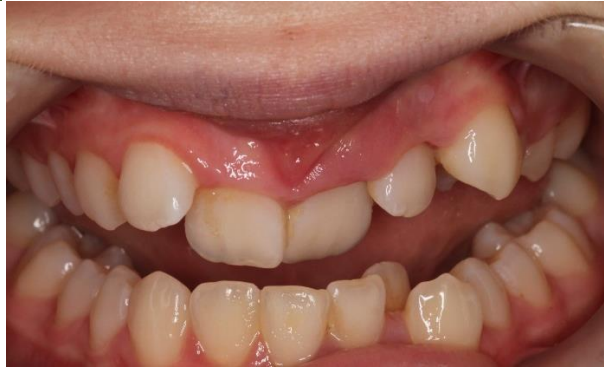N presented to EDH 1 week following the trauma, when she was on pain during biting in relation to UL1, however the difficulty in closure of the mouth is still present.

Full medical history, clinical and radiographical examinations were carried out. Pulp extirpation was performed for UL1 after 2 weeks of her first appointment and the canal dressed with non-setting Calcium Hydroxide (Ca(OH)₂) to minimise inflammatory process. UL1 was reviewed until the infection is controlled then the canal was obturated with Gutta Percha.

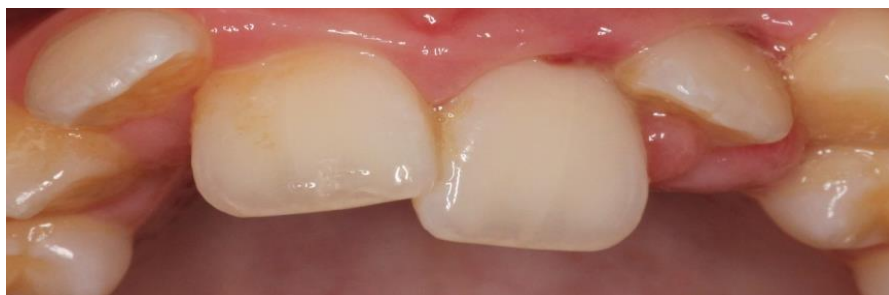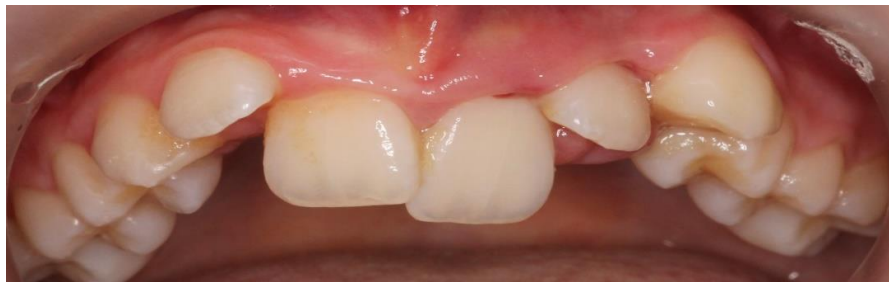Pre-operative Imaging (15/5/2014)

a. Intraoral photographs

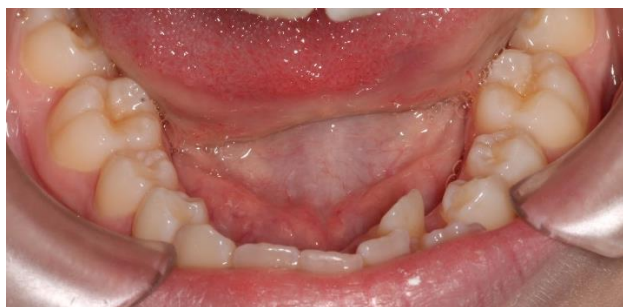Anterior
View



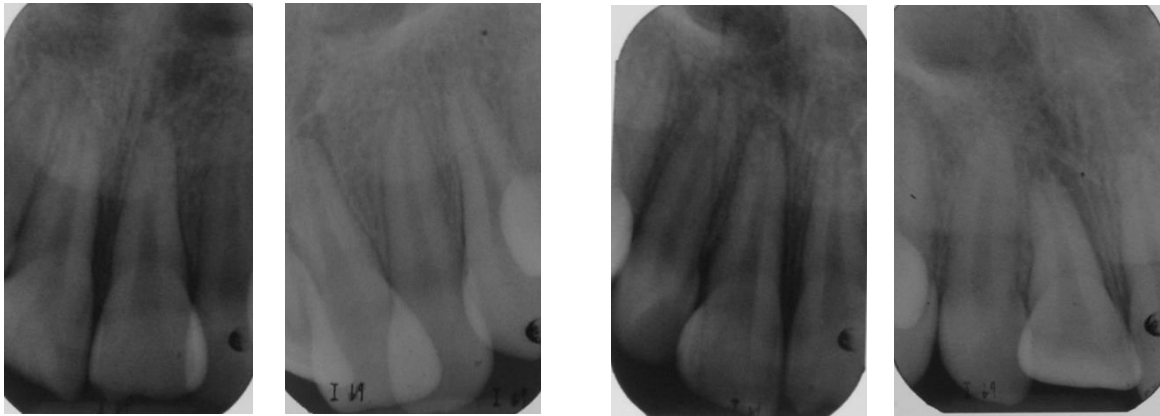
Upper Arch



Lower Arch



b. Intraoral radiographs

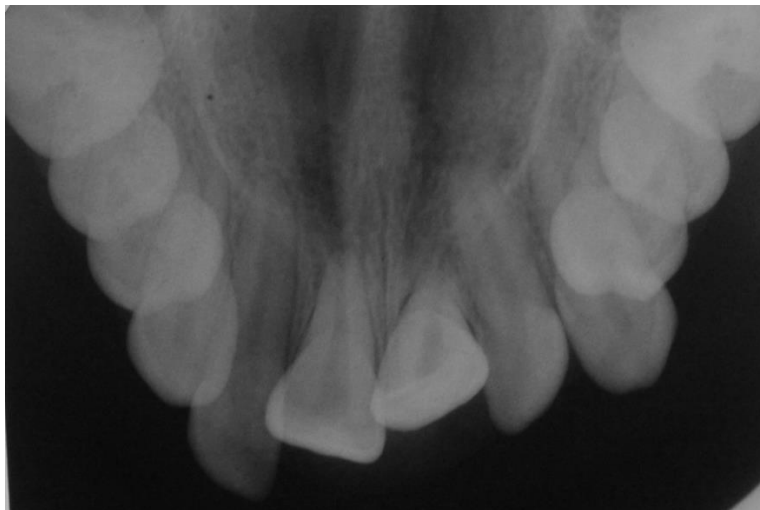

UR1

UL1

Radiolucencies in relation to the apex of UL1.

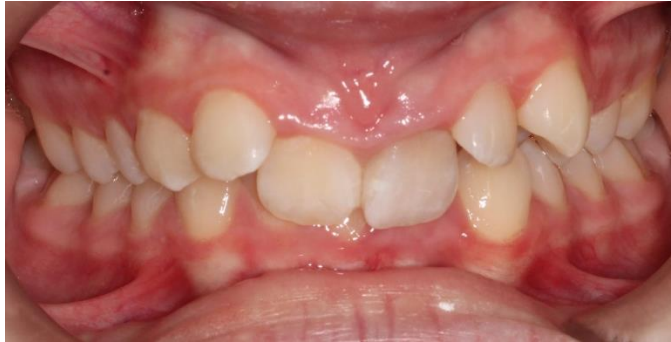Anterior occlusal view



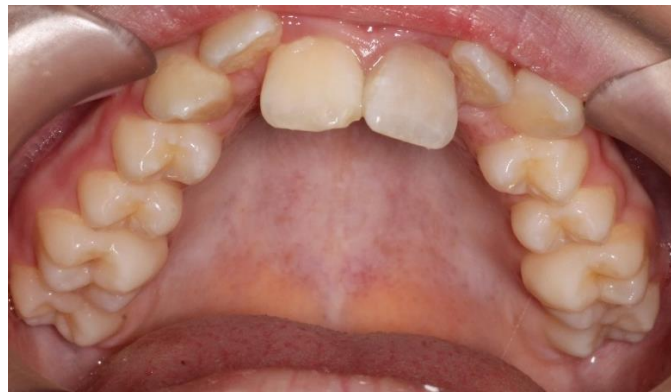Post-operative imaging (19/12/2014)

a. Intraoral photographs

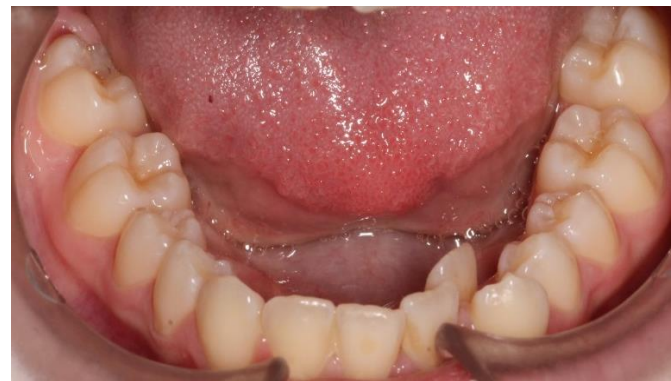Frontal View



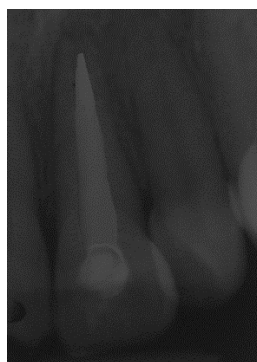Upper Arch



Lower Arch



b. Intraoral radiographs



Case History

Personal data:

Name: N. L

DOB: 13/03/2002

Age: 12 years

Sex: Female

First attended in: 15/05/2014

Reason for attendance:

Trauma to upper central incisors.

Chief complaint (C/O):

- Pain in her upper central teeth, difficulty in closing her mouth and remaining swelling of the upper lip.
- History of chief complaint:
 - When: 1 week ago (Friday 09/05/2014).
 - Where: at school
 - How: while playing somersault, she fell down accidentally and hit her face with her knee.
 - Action: mom took her to local medical center.
 - At Accident and Emergency Department: took x-rays and prescribed her: Amoxicillin for 5 days in liquid form and Calpol as pain killer
 - Other Signs and Symptoms: No headache, no concussion, no nausea, no vomiting.

Medical History (MH):

- Medically fit and well with no relevant medical problems.
- No current medication.
- No known allergy.
- Full term pregnancy, normal birth.
- No history of severe illness during the first three years of life.

Social and Family History:

- Has an older brother (19 years old), and a younger sister (10 years old).
- English is the first language.
- No family history of teeth abnormalities.
- Attends school.

Dental History:

- Regular attendee to dentist.
- Had previous check-ups.

Dietary History:

- Good appetite.
- Snacks: Sweets and chocolate.
- Drinks mostly water.
- Breastfeeding stopped by the age of two.

Oral Hygiene:

- Brushes twice daily with adult toothpaste using regular tooth brush.

Habits:

- Thumb sucking but stopped at the age of 6 years.

Clinical Examination

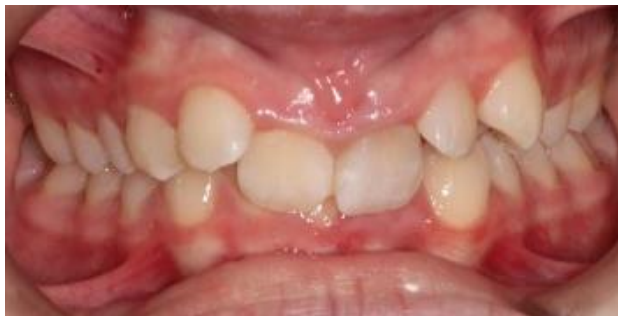Extra-oral Examination:

- Maxilla and mandible (NAD)
- Normal TMJ (no tenderness, no clicking, no crepitus).
- No lymphadenopathy.
- No facial asymmetry.
- Swollen upper lip.
- Difficulty during mouth closure due to pain during biting in relation to UL1.

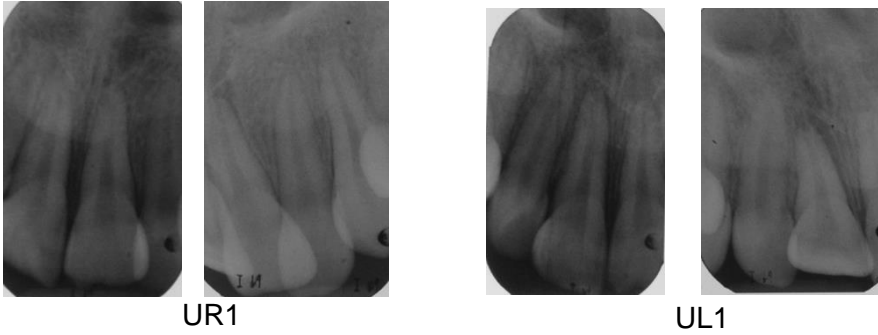
Intra-oral Examination:

- Incisal edge of UR1 slightly chipped.
- Soft tissue: Inflamed gingiva around UL1.
- Oral hygiene: Cannot be determined due to trauma.
- Dentition: Permanent dentition

7	6	5	4	3	2	1		1	2	3	4	5	6
7	6	5	4	3	2	1		1	2	3	4	5	6
- Occlusion:
 - Class II skeletal relation and reduced facial proportions.
 - Class II division 2 incisor relationship.
 - Class I molar relationship.
 - Deep overbite, upper central incisors are retroclined and luxated due to trauma.
- Malocclusion:
 - sever crowding specially in upper arch
 - teeth do not occlude due to UL1 interfere with bite
- Mobility: grade 1 mobility in UL1.
- TTP: + to UL1.

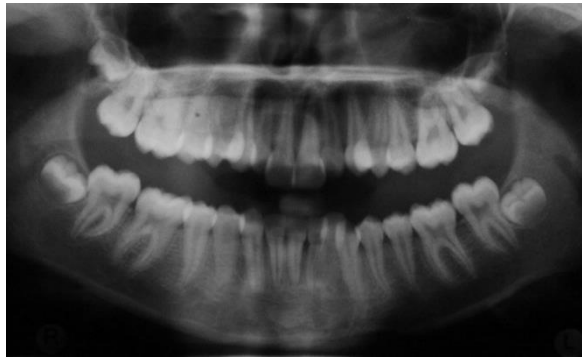

- Pre-operative radiographs:



- Findings:

- Apical radiolucency in relation to UL1
- DPT was taken by orthodontist
- All permanent teeth are present including the developing third molars



Diagnosis and Treatment Planning

Diagnosis:

- a. Soft tissue
 - Swelling of upper lip
 - Gingival inflammation around UL1
 - Minimal bleeding around UL1
- b. Dentition
 - Lateral luxation injury of both UR1 and UL1
 - Crowding in both upper and lower anterior teeth
 - Grade 1 mobility UL1
 - Incisal edge of UR1 slightly chipped
- c. Behavior
 - Dental anxiety

Tooth	UR1	UL1
Hard tissue and pulp	Incisal chipping	-ve
Periodontal	Lateral luxation	Lateral luxation

Treatment Objectives

- Liaise with Ortho/Paed joint clinic regarding upper anterior teeth.
- Remove the source of infection and extirpate UL1 as soon as possible.
- Maintain the vitality of UR1, UR2 and UL2.
- To preserve the traumatised teeth.
- Restore oral health (function & aesthetics).
- Prevent/ manage the sequelae of the trauma as appropriate.
- Manage anxiety and promote positive attitude towards dental care.

Provisional Treatment Plan

Emergency (immediate) treatment

- Repositioning of UL1, UR1.
- Antibiotics prescription (already on antibiotics).
- Chlorhexidine mouth wash and analgesics prescription.
- Give patient instructions.
- Explain treatment options and long term prognosis.

Intermediate Treatment:

- Initiate root canal treatment UL1.
- Explain the possible outcome and poor prognosis.

Long Term Treatment:

- Monitor the vitality of UR1, UR2 and UL2.
- Root canal obturation of UL1.
- Explain the possible replacement options if poor outcomes in UL1.

Maintenance and Follow up:

- Clinical review every 3 months.
- Radiological review every 6 -12 months.
- Reinforcement of dietary & oral hygiene advice.
- Note: - Treatment to be Carried on under L.A if needed.

Treatment Progress and Dental Management

First Visit (15/5/2014):

- Patient attended with mother in an emergency appointment.
- C/O: discomfort in upper anterior teeth with little swelling in the upper lip.
- E/O: slight swelling in upper lip.
- I/O:
 - N can open her mouth
 - Gingival inflammation with slight bleeding around UL1
 - Incisal edge of UR1 slightly chipped
 - Grade 1 mobility of UL1
- Complete history taken.
- Clinical and radiographic examination.
- Pre-operative clinical photographs.
- Provisional treatment plan formulated and discussed with both patient and mother.

Treatment:

- Correction of the incisors position from *traumatic* to *atraumatic occlusion*:
 - L.A: buccal and palatal infiltration administered (2.2 ml of 2% lignocaine hydrochloride with 1:80,000 adrenaline)
 - Trying to move the teeth by finger pressure (Failed).
 - Using forceps, teeth were moved as much as possible from their malocclusion position.
- Ortho consultation done; No splints needed due to minimal mobility (grade1).
- Long term *prognosis* of teeth explained to mother.
- Chlorhexidine mouth wash and analgesics prescribed.
- Soft diet must be followed for the first 24 hours.

Behaviour: anxious, potential cooperative.

Second Visit (21/5/2014)

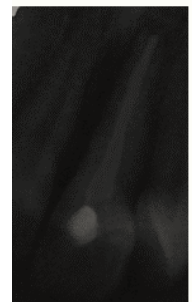
- Patient attended with mother.
- C/O: Patient reported less pain.
- E/O: No more swelling in upper lip.
- I/O:
 - N can open her mouth
 - Patient eating habits improved
 - Patient sleeping improved
 - Gingival healed nicely around UL1
 - No more mobility of UL1
 - UL1 appeared dark in colour

Treatment:

- Follow up trauma of UL1 and UR1.
- Sensibility tests done: UL1 no respond; diagnosed as necrotic and requires RCT.

Test	Tooth			
	UR2	UR1	UL1	UL2
<i>EPT</i>	48	32	80	50
<i>Ethyl Chloride</i>	+ve	+ve	-ve	+ve
<i>Colour</i>	--	--	Slight Darker	--

- Pulp extirpation of UL1:
 - Topical anesthesia (xylocaine gel on dry mucosa)
 - 1 carpule of lignocaine 1:80,000 epinephrine (Labial infiltration)
 - Dry dam isolation from UR1 to UL2
 - UL1; Access cavity preparation (palatal)
 - Removal of pulp tissue
 - Canal irrigation with sodium hypochlorite (0.5%)
 - WL determination (UL1=25 mm)
 - Drying the canal using paper point
 - Non-setting calcium hydroxide dressing (CaOH), Ultracal used for canal dressing
 - Cotton pledget + IRM used to close access cavity of this tooth



Behaviour: cooperative.

Third Visit (11/6/2014)

- Patient attended with mother
- C/O: Patient reported no pain
- E/O: NAD
- I/O: NAD

Treatment:

- Follow up trauma of UL1 and UR1.
- Sensibility tests done:

Test	Tooth			
	UR2	UR1	UL1	UL2
<i>EPT</i>	48	32	80	50
<i>Ethyl Chloride</i>	+ve	+ve	-ve	+ve
<i>Colour</i>	--	--	--	--
<i>TTP & lateral</i>	--	--	--	--
<i>Mobility</i>	--	--	--	--
<i>Tenderness in sulcus</i>	--	--	--	--
<i>Sinus tract</i>	--	--	--	--
<i>Percussion sound</i>	--	--	Metallic	--

- UL1:
 - Dry dam isolation from UR1 to UL2
 - IRM removed using 330 bur
 - Cotton pledget removed
 - Canal irrigation with sodium hypochlorite (0.5%)
 - Canal dried with paper point
 - Non-setting calcium hydroxide dressing (CaOH), Ultracal used for canal dressing
 - Cotton pledget + IRM used to close access cavity of this tooth
- Patient was referred to the ortho/paed clinic for orthodontic consideration and long term planning.

- Orthodontist opinion is requested.

Obtained data:

- Class II div 2 incisor relationship on a skeletal 2 base with reduced facial proportions
- Deep overbite; retroclined upper central incisors which were luxated during trauma
- Crowding in the anterior segment of both arches

The plan is as the following:

- Initially provide a medium opening activator with a palatal re-curve spring to procline the upper incisors and start AP sagittal correction
- Depending on the outcome of this consider more comprehensive orthodontic management with or without extraction as appropriate.

Behaviour: cooperative.

Forth Visit (16/9/2014)

- Patient attended with mother.
- C/O: Patient reported no pain.
- E/O: NAD
- I/O: NAD

Treatment:

- Follow up trauma of UL1 and UR1.
- Sensibility tests done.

Test	Tooth			
	UR2	UR1	UL1	UL2
<i>EPT</i>	48	32	80	50
<i>Ethyl Chloride</i>	+ve	+ve	-ve	+ve
<i>Colour</i>	--	--	--	--
<i>TTP & lateral</i>	--	--	--	--
<i>Mobility</i>	--	--	--	--
<i>Tenderness in sulcus</i>	--	--	--	--
<i>Sinus tract</i>	--	--	--	--
<i>Percussion sound</i>	--	--	Metallic	--

- UL1:
 - Dry dam isolation from UR1 to UL2
 - IRM removed using 330 bur
 - Cotton pledget removed
 - Canal irrigation with sodium hypochlorite (0.5%)
 - Canal dried with paper point
 - Non-setting calcium hydroxide dressing (CaOH), Ultracal used for canal dressing
 - Cotton pledget + IRM used to close access cavity of this tooth

Behaviour: very cooperative.

Fifth Visit (1/12/2014)

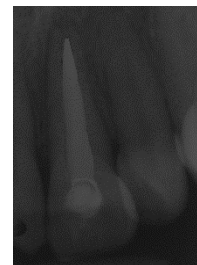- Patient attended with mother.
- C/O: Patient reported no pain.
- E/O: NAD
- I/O: NAD

Treatment:

- Follow up trauma of UL1 and UR1.
- Sensibility tests done.

Test	Tooth			
	UR2	UR1	UL1	UL2
<i>EPT</i>	48	30	80	49
<i>Ethyl Chloride</i>	+ve	+ve	-ve	+ve
<i>Colour</i>	--	--	--	--
<i>TTP & lateral</i>	--	--	--	--
<i>Mobility</i>	--	--	--	--
<i>Tenderness in sulcus</i>	--	--	--	--
<i>Sinus tract</i>	--	--	--	--
<i>Percussion sound</i>	--	--	Metallic	--

- UL1:
 - Dry dam isolation from UR1 to UL2
 - IRM removed using 330 bur.
 - Cotton pledget removed.
 - No signs of infection noticed.
 - Instrumentation reaching size 40 and WL = 25mm
 - Canal irrigation with sodium hypochlorite (0.5%)
 - Canal dried with paper point
 - Obturation with GP (lateral condensation technique)
 - Layer of GIC was placed at the orifice
 - Etching
 - bonding
 - Composite filling shade 3.5
- UR1:
 - Smoothing using sofex discs



Behaviour: very cooperative.

Appraisal and Discussion

Traumatic dental injury is one of the most common problems that have high prevalence worldwide. Although the percentages of dental injuries vary among countries, statistical analysis revealed around one-third of preschool children have experienced dental injuries and approximately one-fourth and one third of schoolchildren and adults also have suffered trauma to their permanent teeth (Glendor 2008). The most common type of trauma in the permanent teeth is crown fracture (Flores, Andersson et al. 2007). Central incisor is the most common tooth to be affected and it compromises around 73% of all dental injuries (Roberts, Longhurst et al. 1996).

N.L, a 12 year old girl, came with her mother regarding trauma to her upper teeth at school which caused pain in upper anterior teeth and swollen upper lip. Emergency treatment had been carried out at A/E Department where they did x-rays and prescribed antibiotic and pain killer to the child.

When N presented, examination was a bit difficult as a result of pain and the following diagnosis was made:

1. UL1: lateral luxation, with slight mobility and inflamed gingival margin
2. UR1: uncomplicated crown fracture (Enamel shipped incisor edge)
3. Swollen upper lip (initially but subsided the visit day)
4. Difficulty in closing the mouth

Lateral luxation injury might have a long term poor prognosis and resorption of the root and ankylosis might be expected.

The aim of our treatment is to extirpate the pulp of this luxated tooth within 7-10 days to reduce the possibilities of inflammation and to preserve the tooth as long as possible. In addition, the second aim is to monitor and maintain the vitality of the other upper anterior teeth. Pulp extirpation and dressing the canal using $\text{Ca}(\text{OH})_2$ was carried out to have infection free canal, to arrest the infection and the possibility of root resorption. (Andreasen et al, 2002). Composite was chosen to be the final restoration after completion of root canal filling using GP, as it has better long term bonding compared to GIC (Xie, Zhang et al. 2008). UR1 simple enamel fracture was smoothed using Soflex discs, no restorative treatment needed due to it's simplicity and minimal fracture with no dentin exposure.

Splinting the luxated tooth was unfeasible in this case. Due to minimal mobility and splint more likely to interfere with occlusion and lip closure. (Andersson, Andreasen et al. 2012).

As UL1 and UR1 is palataly displaced, N was referred to ortho/paed joint clinic to have their opinion. As N has class II division 2 incisor relationship on a skeletal class II base, deep over bite, retroclined upper central incisors and lower anterior crowding, the treatment plan for her was to provide a medium opening activator with a palatal re-curve spring to procline the upper incisors and start anterior posterior sagittal correction. Depend on the result of this, the final treatment plan will be set.

Orthodontic treatment was set following the repositioning of the incisors to correct both dental and skeletal dsicprancies. The Activator will correct the skeletal anterior posterior discrepancy by forward positioning of the mandible which will lead to stimulation the Condylar growth and restricting the maxillary growth (O'brain 2003). The appliance was modified by springs on the upper central incisors to procline them and move them to a more favorable position.

The appliance of choice was MOA due to its favorable effect in patients with reduce lower facial height. The design of the appliance doesn't restrict the posteriors to extrude during the active phase of the treatment causing an increase of facial height.

The consequences of trauma to her permanent teeth were clarified and explained properly to her mother. These consequences included discoloration, infection, resorption, ankylosis and eventually losing the traumatised tooth.

Appraisal: Mum and N are happy with the results of the treatment.

References

- Andreasen, J.O., Farik, B. & Munksgaard, E.C., (2002). Long-term calcium hydroxide as a root canal dressing may increase risk of root fracture. *Dental Traumatology*. 18, p. 134-137.
- Andreasen, J.O., Andreasen, F.M., Bakland, L.K. & Flores, M.T., (2003). *Traumatic Dental Injuries. A Manual*. 2nd ed. Oxford, UK: Blackwell Munksgaard.
- Andersson, Lars, O. Jens, Anthony J. DiAngelis, J. David, Asgeir Sigurdsson Kenny, Cecilia Bourguignon, Marie Therese Flores et al. "International Association of Dental Traumatology guidelines for the management of traumatic dental injuries~ 2. Avulsion of permanent teeth." (2012).
- Bastone EB, Freer TJ, McNamara JR. Epidemiology of dental trauma: A review of the literature. *Australian Dent J* 2000; 45:2-9.
- Flores, M.T., Andersson, L., Andreasen, J.O., Bakland, L.K., Malmgren, B., (2007). Guidelines for the management of traumatic dental injuries. I. Fractures and luxations of permanent teeth. *Dental Traumatology. IADT guidelines*. 23, 66-71.
- Li Peng, Ling Ye, Hong Tan, Xuedong Zhou. Outcome of root canal obturation by warm guttapercha versus cold lateral condensation: A meta-analysis. *J Endod* 2007; 33: 106109.
- ROBERTS, G. J. & LONGHURST, P. 1996. *Oral and dental trauma in children and adolescents*, Oxford ; New York, Oxford University Press.
- Sheehy EC, Roberts GJ. Use of calcium hydroxide for apical barrier formation and healing in non – vital immature permanent teeth: a review. *Br Dent J* 1997; 183: 241-246.
- Welbury, R. & Gregg, T., (2006). *Managing Dental Trauma in Practice*. London: Quintessence Publishing Co. Ltd.
- Welbury, R.R., Duggal, M.S. & Hosey, M.T., (2005). *Pediatric Dentistry*. 3rd ed. New York: Oxford University Press.
- Walker, M. "Fractured-tooth fragment reattachment." *General dentistry* 44, no. 5 (1995): 434-436.
- Andersson, L., J. O. Andreasen, et al. (2012). "International Association of Dental Traumatology guidelines for the management of traumatic dental injuries: 2. Avulsion of permanent teeth." *Dental Traumatology* 28(2): 88-96.
- Flores, M. T., L. Andersson, et al. (2007). "Guidelines for the management of traumatic dental injuries. I. Fractures and luxations of permanent teeth." *Dent Traumatol* 23(2): 66-71.
- Glendor, U. (2008). "Epidemiology of traumatic dental injuries--a 12 year review of the literature." *Dent Traumatol* 24(6): 603-611.
- Roberts, G. J., P. Longhurst, et al. (1996). *Oral and dental trauma in children and adolescents*, Oxford University Press London.
- Xie, H., F. Zhang, et al. (2008). "Dentine bond strength and microleakage of flowable composite, compomer and glass ionomer cement." *Australian dental journal* 53(4): 325-331.