



**eastman** DENTAL  
INSTITUTE

## **CASE REPORT**

### **Management of Medically Compromised Case**

**(Paediatric Dentistry Advanced Clinical Care 3)**

**In partial fulfilment of the degree  
Clinical Doctorate in Paediatric Dentistry  
Eastman Dental Institute University  
College London 2013 - 2016**

**Submitted by**

**Abdulfatah Alazmah**

**BDS (Saudi Arabia)**

**Candidate Number: 12092520**

## Content

<b>Content</b> .....	<b>1</b>
<b>Case Summary</b> .....	<b>2</b>
Pre-operative Imaging (10/10/2013) .....	3
a. Intraoral photographs .....	4
b. Intraoral radiographs .....	4
Post-operative imaging (2/2/2015) .....	5
a. Intraoral photographs .....	5
b. Intraoral radiographs .....	6
<b>Case History</b> .....	<b>7</b>
Personal data: .....	7
Reason for attendance: .....	7
Chief complaint: .....	7
Medical History: .....	7
Social and Family History: .....	7
Dental History: .....	8
Dietary History: .....	8
Oral Hygiene: .....	8
Habits: .....	8
<b>Clinical Examination</b> .....	<b>9</b>
Extra-oral Examination: .....	9
Intra-oral Examination: .....	9
<b>Diagnosis and Treatment Planning</b> .....	<b>11</b>
Diagnosis: .....	11
Treatment Objectives .....	11
Provisional Treatment Plan .....	12
<b>Treatment Progress and Dental Management</b> .....	<b>13</b>
First Visist 10/10/2013 .....	13
Second Visist 11/11/2013 .....	14
Thirst Visit 3/3/2014 .....	15
Forth Visist 12/5/2014 .....	16
Fifth Visist 17/6/2014 .....	17
Sixth Visit 18/8/2014 .....	18
Seventh Visist 18/10/2014 .....	19
Eighth Visist 2/2/2015 .....	20
<b>Appraisal and Discussion</b> .....	<b>21</b>
<b>References</b> .....	Error! Bookmark not defined.

## Case Summery

H.J is a 9 year old boy, who was referred by team of physicians in NHS specialist services to the Eastman Dental Hospital (EDH), Department of Paediatric Dentistry for management and treatment of his primary and permanent teeth.

J. main complaint was pain in lower right quadrant with swelling. He was diagnoses by a team of physicians in Osteogenesis Imperfecta service at NHS specialist services, that he has Osteogenesis Imperfecta, clinically type 4. He was first diagnosed at 8 years and 5 month age. Family history reveals that younger sister suffers from the same disease which may imply that this condition may have positive parental family history. In addition J. got treated of vitamin D deficiency recently.

He is taking variable drugs at the current time:

- Calcichew D3 Forte tablets once a day
- Pamidronate 1 mg/kg per dose per 3 days every 3 months at Croydon University Hospital
- Paracetamol and Nurofen as required
- Bisphosphonate, Sept 2013

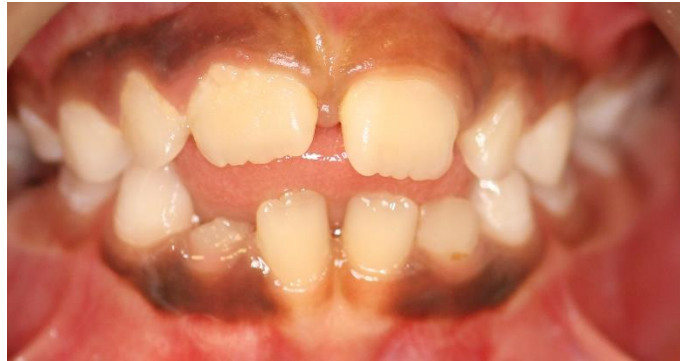On clinical oral examination no evidence of Dentinogenesis Imperfecta on both permanent and primary teeth. Although multiple caries lesions were found and remaining roots. Treatment was carried mainly using non–pharmacological behaviour management (NPBM) techniques, Local anaesthesia and inhalation sedation. Treatment provided:

- Prevention and acclimatization
- Oral hygiene instructions (OHIs).
- Dietary advice.
- Liaison with orthodontic department
- Restorations:
  - Extraction of remaining roots in ULD and LRE
  - Composite restorations on URE, ULE
  - Pre-formed metal crowns (PMCs) on LLD

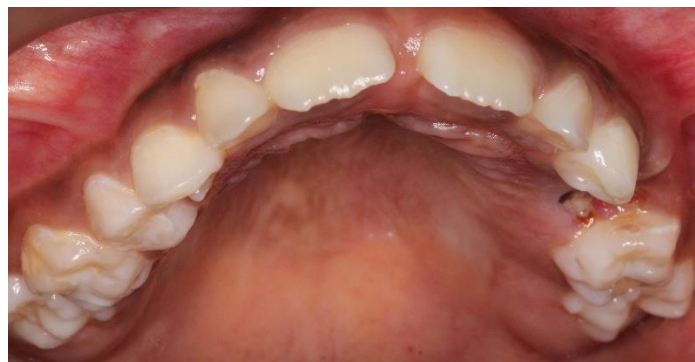*Pre-operative Imaging (10/10/2013)*

a. Intraoral photographs

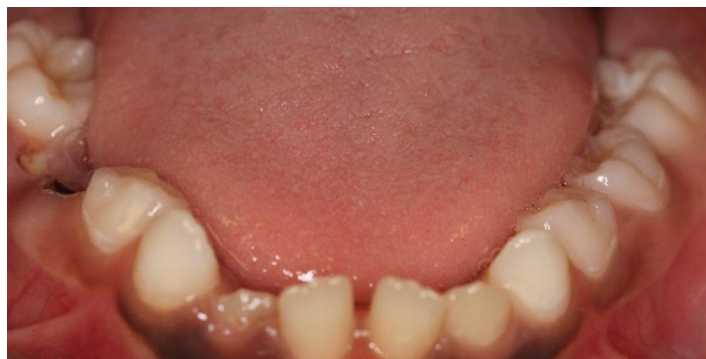Anterior  
View



Upper Arch

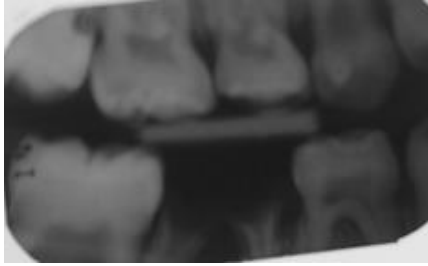


Lower Arch

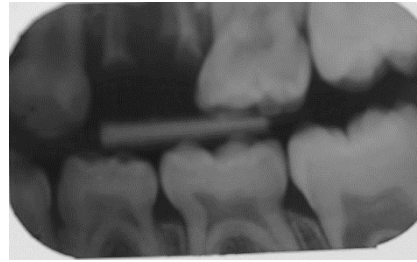


b. Intraoral radiographs

Bitewings view



Right Bitewings



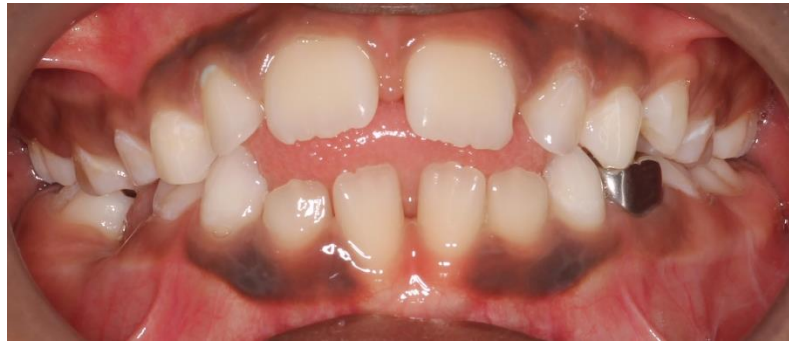Left Bitewings

Furcation radiolucency in relation to ULD and LRE  
Occlusal caries in URE, ULE and LLD

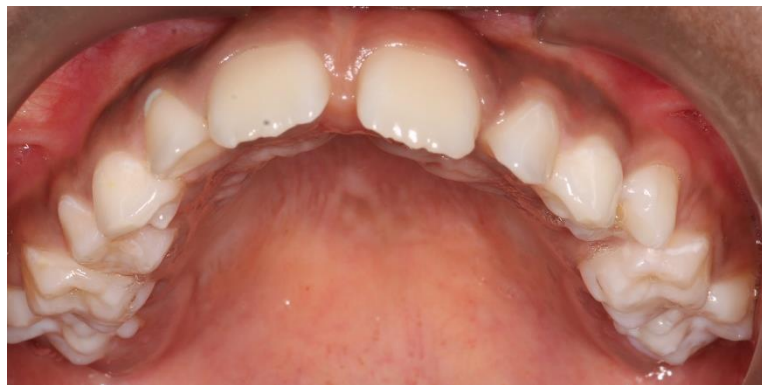*Post-operative imaging (2/2/2015)*

a. Intraoral photographs

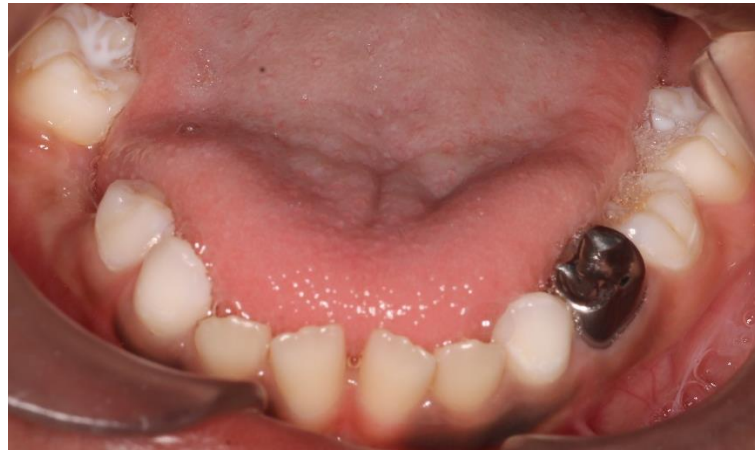Frontal View



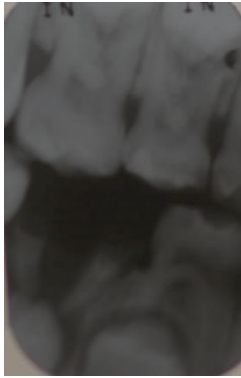Upper Arch



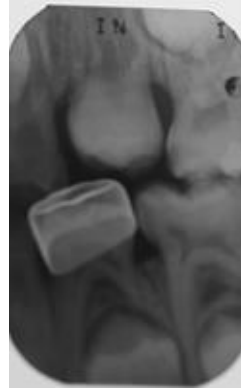Lower Arch



b. Intraoral radiographs



Right Bitewings



Left Bitewings

## Case History

### *Personal data:*

Name: H. J

DOB: 31/08/2006

Age: 7 years

Sex: Male

First attended in: 10/10/2013

### *Reason for attendance:*

Pain and swelling in lower right quadrant.

### *Chief complaint (C/O):*

- Pain and swelling in lower Q
- History of chief complaint:
  - Pain started 1 year ago
  - Had facial swelling and it needed antibiotic therapy
  - swelling, February 2013
  - Fracture of left ramus, May 2013

### *Medical History (MH):*

- Vitamin D deficiency (treated)
- Ontogenesis Imperfecta type 4
- Medications:
  - Calcichew D3 Forte tablets once a day
  - Pamidronate 1 mg/kg per dose per 3 days every 3 months at Croydon University Hospital
  - Paracetamol and Nurofen as required
  - Bisphosphonate, Sept 2013
- No known allergy.
- Full term pregnancy, normal birth.

### *Social and Family History:*

- Older sister also affected
- Likely positive paternal family history
- English is the first language.
- Attends school.



*Dental History:*

- Regular attendee to dentist.
- Had previous check-ups.

*Dietary History:*

- Good appetite.
- Snacks: high sugar intake (chocopops, weat biscuits with honey, chocolate milk, juices).
- Breastfeeding stopped by the age of two.

*Oral Hygiene:*

- Brushes twice daily with adult toothpaste using regular tooth brush on his own.

*Habits:*

- Thumb sucking. Stopped at age of 6.

## Clinical Examination

### Extra-oral Examination:

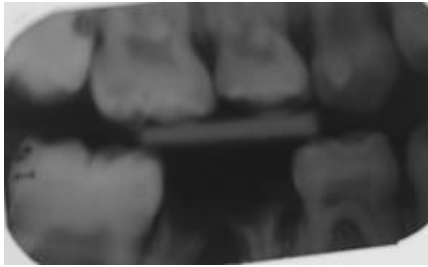
- Maxilla and mandible (NAD).
- Normal TMJ (no tenderness, no clicking, no crepitus).
- No lymphadenopathy.
- No facial asymmetry.

### Intra-oral Examination:

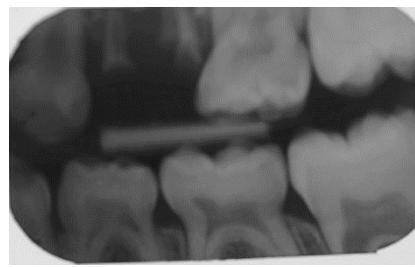
- No sinus tract.
- No evidence of DI.
- Soft tissue (ST):  
Generalised gingivitis with localised gingivitis in areas of ULD and LRE.
- Oral hygiene (OH):  
Fair OH.
- Dentition:
  - Early mixed dentition stage
  - Remaining roots of ULD and LRE
  - First permanent molars are partially erupted in all quadrants
  - Partial eruption of tooth LR2
  - Occlusal caries in upper Es
  - M caries on ULE
- Occlusion:
  - Anterior open bite
  - Slight midline shift to the left side
  - Class I molar relationship

6	E	D	C	B	1	1	B	C	D	E	6
6	E	D	C	2	1	1	B	C	D	E	6

- Pre-operative radiographs:



Right Bitewings



Left Bitewings

- Findings:
  - Furcation radiolucency ULD and LRE
  - Occlusal caries in upper Es and LLD

## Diagnosis and Treatment Planning

### *Diagnosis:*

a. Soft tissue

- Generalised gingivitis

b. Dentition

- Remaining roots of ULD and LRE
- First permanent molars are partially erupted in all quadrants
- Partial eruption of tooth LR2
- Occlusal caries in upper Es
- M caries on ULE
- Caries on LLD

c. Behavior

- Dental anxiety

### *Treatment Objectives*

- To relieve the symptoms associated with primary and permanent teeth
- To promote oral preventive measures.
- To restore function and aesthetic.
- Manage anxiety and enhance positive attitude towards dental care.

## *Provisional Treatment Plan*

### Prevention Treatment:

- OHI.
- Dietary education.
- Fluoride varnish application every 4 months.

### Behaviour Management:

- To use all possible NPBM techniques.
- Acclimatisation to dental environment.

### Restorations and Extractions:

- Extraction of remaining roots ULD and LRE
- Restorative:
  - Restoration of URE, ULE
  - Preformed metal crowns (PMCs) for LLD
  - Restorations of 6's with using fissure sealant

### Maintenance and Follow up:

- Clinical review every 4 months.
- Reinforcement of dietary advice and OHI.
- Monitor composite restoration and F.S 6's.
- Radiographic review if require every 6-12 months.

## Treatment Progress and Dental Management

### First Visit (10/10/2013):

- Patient attended with mother.
- *C/O*: pain in lower right quadrant with history swellings.
- *History of C/O*: episodes started 1 year ago with successive swelling requiring antibiotic therapy.
- *MH*: Osteogenesis Imperfecta
- *Med*: Bisphosphonate since Sept 2013
- *E/O*: Incompetent lips
- *I/O*:
  - Open bite
  - Slight midline shift to the left side
  - Partial eruption of permanent UR1
  - Partially erupted of permanent LR2
  - Partial eruption of 6s
- Complete history taken.
- Clinical and radiographic examination.
- Pre-operative clinical photographs.
- Provisional treatment plan formulated and discussed with both patient and mother. Where type of anesthesia was discussed as LA is the 1<sup>st</sup> choice but if –ve behavior persists after the 1<sup>st</sup> follow-up session then other measures like IS will be undertaken.

### Treatment:

- No treatment due to negative behavior of the patient
- *OHI*:
  - Adult toothpaste with 1350ppm Fluoride or above.
  - Spitting after brushing rather than rinsing.
  - Use mouthwash (0.05% Fluoride) between brushing.
  - Diet advice.

Behaviour: highly negative behavior (uncooperative)

### Second Visit (11/11/2013)

- Patient attended with mother.
- C/O: Patient reported no pain in lower right quadrant with no swelling.

#### Treatment:

- Prophylaxis for all teeth using slow speed hand piece and pumice.
- UL6, LL6 and LR6
  - Cotton roll isolation
  - Itching and boding
  - Pits and fissure sealant placed at occlusal surface
  - Checked after curing using a dental probe
- Partially erupted UR6 couldn't be sealed at this session, left to monitor.
- N.V: Restoration of URE and URD.

Behaviour: slightly cooperative but continuously moving.

### Third Visit (3/3/2014)

- Patient attended with mother.
- C/O: Patient reported pain in lower right quadrant with no swelling.
- MH: updated last February.

#### Treatment:

- J. is highly hyperactive and anxious
- Written informed consent signed by mother
- IS: Introduction to equipment
- URE and ERD:
  - Nitrous Oxide (N<sub>2</sub>O) titrated in increments to 30%N<sub>2</sub>O:70%O<sub>2</sub>.
  - Topical anesthesia (xylocaine gel on dry mucosa)
  - 1 carpule of lignocaine 1:80,000 epinephrine (buccal infiltration)
  - Occlusal caries excavation using 330 bur
  - Itching and boding
  - Pits and fissure sealant placed at occlusal surface
  - Checked after curing using a dental probe
  - 100% O<sub>2</sub> given for 5 min
  - Post operative instructions verbal and written.
- N.V: Restoration of ULE and if pt. cooperative extraction ULD.

Behaviour: cooperative.



### Forth Visit (12/5/2014)

- Patient attended with mother.
- C/O: Patient reported no pain.
- *MH and DH*: No change

#### Treatment:

- ULE:
  - Nitrous Oxide (N<sub>2</sub>O) titrated in increments to 30%N<sub>2</sub>O:70%O<sub>2</sub>.
  - Topical anesthesia (xylocaine gel on dry mucosa)
  - 1 carpule of lignocaine 1:80,000 epinephrine (buccal infiltration)
  - Occlusal and mesial caries excavation using 330 bur
  - Pt kept on moving and talking; clamp jumped, dry dam removed and cotton roll isolation done (I think we remove this)
  - Itching and boding
  - Class II restoration using composite shade A2
  - Finishing and polishing
  - Fissure sealant was placed on top of the restoration.
  - 100% O<sub>2</sub> given for 5 min
  - Post operative instructions verbal and written.
- N.V: extraction of RR ULD under IS and LA.

Behaviour: slightly cooperative but continuously moving.

#### Fifth Visit (17/6/2014)

- Patient attended with mother.
- C/O: Patient reported no pain.

#### Treatment:

- ULD:
  - Written informed consent signed by mother.
  - Nitrous Oxide (N<sub>2</sub>O) titrated in increments to 30%N<sub>2</sub>O:70%O<sub>2</sub>.
  - Topical anesthesia (xylocaine gel on dry mucosa).
  - 1 carpule of lignocaine 1:80,000 epinephrine (Labial infiltration).
  - Extraction of ULD using elevator and forceps
  - Homeostasis achieved
  - 100% O<sub>2</sub> given for 5 min
  - Post operative instructions verbal and written.
- N.V: extraction of RR LRE under IS and LA.

Behaviour: J. was a bit anxious in the beginning but with non-pharmacological behaviour management he behaved well.

After this visit we stopped the treatment for two months because J is going to have leg operation and he needs few weeks to walk properly.

### Sixth Visit (18/8/2014)

- Patient attended with mother.
- C/O: Patient reported no pain.

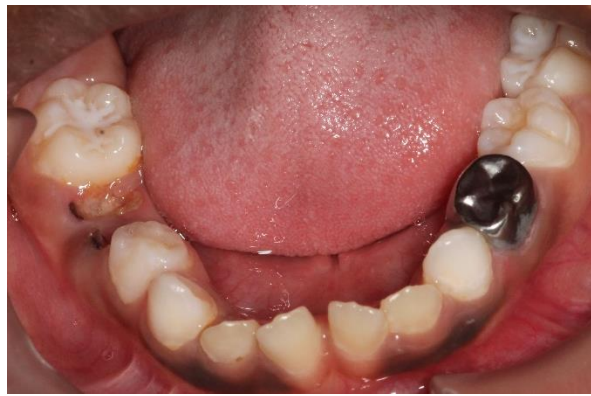#### Treatment:

- Couldn't extract RR LRE due to hyperactivity
- UR6:
  - Cotton roll isolation
  - Itching and boding
  - Pits and fissure sealant placed at occlusal surface
  - Checked after curing using a dental probe
- LLD:
  - Topical anesthesia (xylocaine gel on dry mucosa).
  - PMC size 5 (3M) cemented using GIC luting cement (Hall technique).
- N.V: extraction of RR LRE under IS and LA.

#### Behaviour:

##### Un cooperative

J. was a bit anxious and moves a lot, he refused to put the sedation mask and he was closing his mouth every few seconds.



After this visit mom told us that J had a lot of medical treatment in last few months and he is taking more than one medication. She asked if we can give J few weeks for rest and we agreed.

### Seventh Visit (18/10/2014)

- Patient attended with mother.
- C/O: Patient reported no pain.

#### Treatment:

- LRE:
  - J. refused the happy air and Promised to be cooperative
  - Topical anesthesia (xylocaine gel on dry mucosa).
  - 1 carpule of lignocaine 1:80,000 epinephrine (Labial infiltration).
  - Extraction of LRE using elevator and forceps
  - Homeostasis achieved
  - 100% O<sub>2</sub> given for 5 min.
  - Post operative instructions verbal and written.
- N.V: review
- New intraoral radiographs (BWGs) done

Behaviour: Cooperative

Eight Visit (2/2/2015)

- Patient attended with mother.
- C/O: Patient reported no pain.

Treatment:

- Medical history updated
- Monitor SSC LLD
- Post operative Photographs
- OHI reinforced

Behaviour: Cooperative

## Appraisal and Discussion

The main goals of J's dental care were to get healthy dentition and to induct a helpful dental attitude for persistence of oral hygiene. Therefore, treating his decayed primary teeth was essential to promote good oral health for forthcoming permanent teeth.

When presented he required several invasive treatments. Although his dental history revealed unsuccessful previous experience due to anxious behaviour toward dental environment, she responded well to acclimatisation and inhalation sedation supplemented by NPBMT.

The role of bisphosphonates in children is primarily in the management of osteogenesis imperfecta (OI) to reduce bone pain and fractures. Osteogenesis imperfecta is a congenital abnormality of the gene responsible for producing collagen type 1. This results in fragile bones leading to frequent fractures, hypermobility, short stature, early loss of hearing. It is associated with dental disease including dentinogenesis imperfecta (DI). In the UK, the incidence of OI is reported as 1 in 20,000 live births.

Bisphosphonates significantly improve the well-being of patients with OI by reducing bone resorption and improving bone mineral density (BMD), improving the quality of life for sufferers.

Bisphosphonate-related osteonecrosis of the jaw is defined as exposed, necrotic bone in the maxillofacial region that has persisted for more than 8 weeks, with no history of radiation therapy to the jaws in a person on current or previous treatment with a bisphosphonate. Symptoms of BRONJ include pain, loosening of the teeth, and swelling of gingival tissues. It is usually identified clinically by the appearance of exposed bone in the oral cavity.

Despite extensive adult data, there have been no reported cases of BRONJ in children to date. A number of case series and case reports have suggested there is little risk of BRONJ in paediatric dental patients receiving bisphosphonate therapy.

Where dental treatment is essential on this unique group of children on bisphosphonate therapy, communication with the child's medical team is always essential for the purpose of information sharing as they may have specific guidance with regard to the delivery of dental treatment. Dental extractions and surgical procedures need to be as a traumatic as possible in the presence of good oral hygiene

J did report pain when first presented, and then the pain subsided. On each session, J.H's cooperation and acceptance to the dental environment reassessed constantly.

→ **Behaviour Management:**

Inhalation sedation with nitrous oxide is a conscious sedation technique with high success rate (Blain and Hill, 1998, Lyratzopoulos and Blain, 2003). Thus, it is favoured in managing mild to moderately anxious paediatric dental patient (Hosey, 2002).

Because anxiety has significant impact on treatment, measuring it is essential to accomplish a treatment plan. J's level of anxiety was measured at each visit to assess his general concern, acceptance, and feeling about the dental treatment using the facial image scale (FIS) (Buchanan and Niven, 2002).

### → Prevention:

J was a high caries risk patient in mixed dentition. It is essential to evaluate the caries risk of the patient, as the decision for preventive therapy should be correlated to the risk (Hale, 2003). J's was considered a high caries risk patient that requires special preventive interventions.

### ★ Dietary Advise

J consumed frequent cariogenic snacks in between meal and lots of throughout the day. It was suggested by (Deery and Toumba, 2012) that a positive and effective diet advice should be realistic. He was advised to cut down on sugary intake and have healthy snacks in between meal.

### ★ Tooth Brushing

Tooth brushing is a universal habit for controlling plaque and considered as a method to deliver fluoride. J used to brush unsupervised twice daily with children's toothpaste. He was advised to use adult toothpaste and to be supervised while brushing since this has been shown by (Curnow et al., 2010) to decrease caries level by 56%. He was also instructed to spit instead of rinse in order to increase the effect of the fluoridated tooth paste as recommended by (Pitts et al., 2012). As a result, J's oral hygiene had improved towards the end of treatment.

### ★ Fluoride

The efficacy of fluoride toothpastes in the prevention of dental caries was concluded in 2 systematic reviews (Marinho et al., 2003) and (Ammari et al., 2003). As H.J was a high-risk caries patient, He was advised to use adult toothpaste containing a minimum of 1350 ppm of fluoride, and a professional involvement by fluoride application as a prevention measure 3 times in 12 months, according to the Department of Health toolkit second edition.

### → Fissure sealant:

Fissure sealant application is promoted in high caries risk patients (Beauchamp et al., 2008). A recent systematic review has demonstrated more than 9 years effectiveness and 85% retention after 2 years (Ahovuo-Saloranta et al., 2008) and is recommended in the BSPD guidelines, 2000.

→ **Restorations:** The choice of restoration is established upon:

- The age and the dental development
- Location and extent of the lesion and any related signs and symptoms

Restoring primary molars might seem obvious but surprisingly limited evidence is available and (Tickle et al., 2002, Tickle et al., 2008) was the first to start this debate. However, unrestored primary teeth has adverse effect on the quality of life in children as stated by (Sheiham, 2006).

A systematic review (Yengopal et al., 2009) found that there is no certain recommendation for which filling material to use and therefore this will obviously depend on the clinical scenario. In H.J case his cooperation and the extent of the lesion allowed to the use of composite fillings to restore his teeth without any difficulty or complications.

→ **Stainless steel crown (SSC):**

It was indicated to restore LLD with SSC after pulp therapy as recommended by (Kindelan et al., 2008) at the UK national guidelines. Although, a Cochrane systematic review concluded that there is no evidence available to suggest superiority of SSCs in restoring primary molars (Innes et al., 2007).

Patient anterior open bite doesn't require any intervention since it's not caused by any form of habits. The case must be reviewed at permanent dentition phase. The provisional treatment will include fixed appliance on both upper and lower arches. The mechanics to be used will aim to correct the AOB by intruding the posterior teeth and extruding the anteriors.

If patient growth goes unfavourable relapse can be very high and orthognathic management will be the inevitable treatment option at the age of 16 years.

**In consideration of the treatment outcome, up to now it had been satisfactory. J.H completed the treatment planned established earlier and will be reviewed every 3 months for a year time before being discharged.**



## References:

- AHOVUO-SALORANTA, A., HIIRI, A., NORDBLAD, A., MÄKELÄ, M. & WORTHINGTON, H. V. 2008. Pit and fissure sealants for preventing dental decay in the permanent teeth of children and adolescents. *Cochrane Database Syst Rev*, 4.
- AMMARI, A., BLOCH-ZUPAN, A. & ASHLEY, P. 2003. Systematic review of studies comparing the anti-caries efficacy of children's toothpaste containing 600 ppm of fluoride or less with high fluoride toothpastes of 1,000 ppm or above. *Caries research*, 37, 85-92.
- BEAUCHAMP, J., CAUFIELD, P. W., CRALL, J. J., DONLY, K., FEIGAL, R., GOOCH, B., ISMAIL, A., KOHN, W., SIEGAL, M. & SIMONSEN, R. 2008. Evidence-based clinical recommendations for the use of pit-and-fissure sealants A report of the American Dental Association Council on Scientific Affairs. *The Journal of the American Dental Association*, 139, 257-268.
- BLAIN, K. M. & HILL, F. 1998. The use of inhalation sedation and local anaesthesia as an alternative to general anaesthesia for dental extractions in children. *British dental journal*, 184, 608-611.
- BUCHANAN, H. & NIVEN, N. 2002. Validation of a Facial Image Scale to assess child dental anxiety. *International Journal of Paediatric Dentistry*, 12, 47-52.
- CURNOW, M., PINE, C., BURNSIDE, G., NICHOLSON, J., CHESTERS, R. & HUNTINGTON, E. 2010. A randomised controlled trial of the efficacy of supervised toothbrushing in high-caries-risk children. *Caries Research*, 36, 294-300.
- DAVIES, G. M. & DAVIES, R. M. 2008. Delivering better oral health--an evidence-based toolkit for prevention: a review. *Dental update*, 35, 460-462.
- DEERY, C. & TOUMBA, K. 2012. Diagnosis and prevention of dental caries. *Paediatric dentistry*, 85.
- FRIMAN, P. C., BARONE, V. J. & CHRISTOPHERSEN, E. R. 1986. Aversive taste treatment of finger and thumb sucking. *Pediatrics*, 78, 174-176.
- HALE, K. 2003. Oral health risk assessment timing and establishment of the dental home. *Pediatrics*, 111, 1113.
- HOSEY, M. 2002. Managing anxious children: the use of conscious sedation in paediatric dentistry. *International Journal of Paediatric Dentistry*, 12, 359-372.
- INNES, N., RICKETTS, D. & EVANS, D. 2007. Preformed metal crowns for decayed primary molar teeth. *Cochrane Database Syst Rev*, 1.
- KATYAL, V. 2010. The efficacy and safety of articaine versus lignocaine in dental treatments: a meta-analysis. *Journal of dentistry*, 38, 307.
- KINDELAN, S., DAY, P., NICHOL, R., WILLMOTT, N. & FAYLE, S. 2008. UK National Clinical Guidelines in Paediatric Dentistry: stainless steel preformed crowns for primary molars. *International Journal of Paediatric Dentistry*, 18, 20-28.
- LYRATZOPOULOS, G. & BLAIN, K. 2003. Inhalation sedation with nitrous oxide as an alternative to dental general anaesthesia for children. *Journal of Public Health*, 25, 303-312.
- MARINHO, V., HIGGINS, J., LOGAN, S. & SHEIHAM, A. 2003. Systematic review of controlled trials on the effectiveness of fluoride gels for the prevention of dental caries in children. *Journal of dental education*, 67, 448-458.

- PITTS, N., DUCKWORTH, R., MARSH, P., MUTTI, B., PARNELL, C. & ZERO, D. 2012. Post-brushing rinsing for the control of dental caries: exploration of the available evidence to establish what advice we should give our patients. *British Dental Journal*, 212, 315-320.
- SHEIHAM, A. 2006. Dental caries affects body weight, growth and quality of life in pre-school children. *British dental journal*, 201, 625-626.
- TICKLE, M., BLINKHORN, A. & MILSOM, K. 2008. The Occurrence of Dental Pain and Extractions over a 3-Year Period in a Cohort of Children Aged 3-6 Years. *Journal of public health dentistry*, 68, 63-69.
- TICKLE, M., MILSOM, K., KING, D., KEARNEY-MITCHELL, P. & BLINKHORN, A. 2002. The fate of the carious primary teeth of children who regularly attend the general dental service. *British dental journal*, 192, 219-223.
- WARREN, J. J., SLAYTON, R. L., YONEZU, T., BISHARA, S. E., LEVY, S. M. & KANELLIS, M. J. 2005. Effects of nonnutritive sucking habits on occlusal characteristics in the mixed dentition. *Pediatric dentistry*, 27, 445-450.
- YENGOPAL, V., HARNEKER, S. Y., PATEL, N. & SIEGFRIED, N. 2009. Dental fillings for the treatment of caries in the primary dentition. *Cochrane Database Syst Rev*, 15.

