



**eastman** DENTAL  
INSTITUTE

## **CASE REPORT**

**Complex restorative treatment  
(Managing the developing child)**

**In partial fulfilment of the degree  
Clinical Doctorate in Paediatric Dentistry  
Eastman Dental Institute University  
College London 2013 - 2016**

**Submitted by  
Abdulfatah Alazmah  
BDS (Saudi Arabia)  
Candidate Number: 12092520**

## **Content**

<b>Content</b> .....	<b>1</b>
<b>Case Summery</b> .....	<b>2</b>
Pre-operative Imaging (13/5/2014).....	3
a. <u>Intraoral photographs</u> .....	4
b. <u>Intraoral radiographs</u> .....	4
Post-operative imaging (24/6/2015) .....	5
<b>Case History</b> .....	<b>6</b>
Personal data:.....	6
Reason for attendance: .....	6
Chief complaint (C/O):.....	6
Medical History (MH): .....	6
Social and Family History:.....	6
Dental History:.....	7
Dietary History:.....	7
Oral Hygiene:.....	7
Habits: .....	7
<b>Clinical Examination</b> .....	<b>8</b>
Extra-oral Examination: .....	8
Intra-oral Examination:.....	8
<b>Diagnosis and Treatment Planning</b> .....	<b>10</b>
Diagnosis: .....	10
Treatment Objectives .....	10
Provisional Treatment Plan.....	11
<b>Treatment Progress and Dental Management</b> .....	<b>12</b>
First Visit (13/5/2014).....	10
Second Visit (10/6/2014).....	10
Third Visit (2/2/2015) .....	11
Forth Visit (2/3/2015).....	16
Fifth Visit (24/6/2015) .....	11
<b>Appraisal and Discussion</b> .....	<b>18</b>
<b>References</b> .....	<b>21</b>

## Case Summery

G.K. is a 10 year old young girl who was referred by her general dental practitioner (GDP) to the Eastman Dental Hospital (EDH), Department of Paediatric Dentistry for management of defects that affect her primary and permanent teeth.

Diagnosis of Amelogenesis Imperfecta was made based on the history and clinical examination. She has Class II division I malocclusion with an anterior open bite of 8 mm.

Her main complains when she first presented were the colour of her teeth and the sensitivity associated with her permanent dentition.

She was born prematurely at 8 weeks. G. is medically fit and well with no history of any early childhood illnesses or systemic disorders. She was a regular dental attendee to her GDP and had previous dental treatment but without LA.

Upon examination, she presented with hypoplastic teeth affecting the primary and permanent dentition. The enamel surface of central incisors look yellowish brownish, pitted while the gingival third of the teeth were not affected. However, all teeth were effected equally. The LR6, UL6 and LL6 were partially erupted. There is localised yellowish brown discoloration at the incisal third of her upper and lower central incisors. Radiographic examination was not very clear as the OPG is of less diagnostic value, but it revealed the furcation of the second permanent molars. In addition, the second permanent molars have diminished enamel.

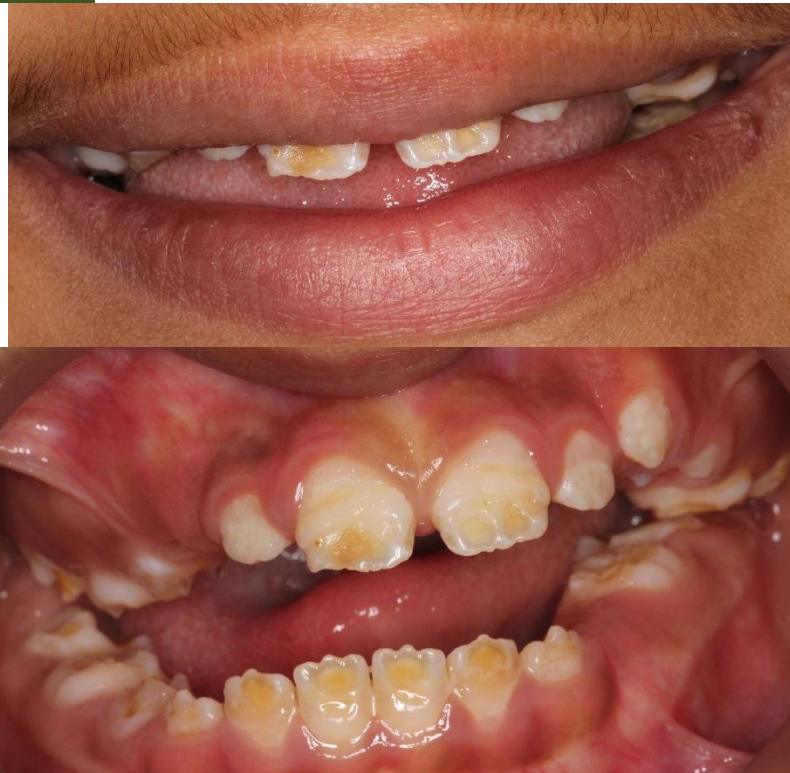Treatment was carried mainly using non-pharmacological behaviour management (NPBM) techniques. Treatment provided:

- Prevention and acclimatization
- Oral hygiene instructions (OHIs).
- Dietary advice.
- Liaison with orthodontic department
- Restorations:
  - Composite veneers on UR2, UR1, UL1, UL2, LR2, LR1, LL1 and LL2.
  - Composite restorations on LR6 and UL6
  - Pre-formed metal crowns (PMCs) on UR6 and LL6 permanent molars.

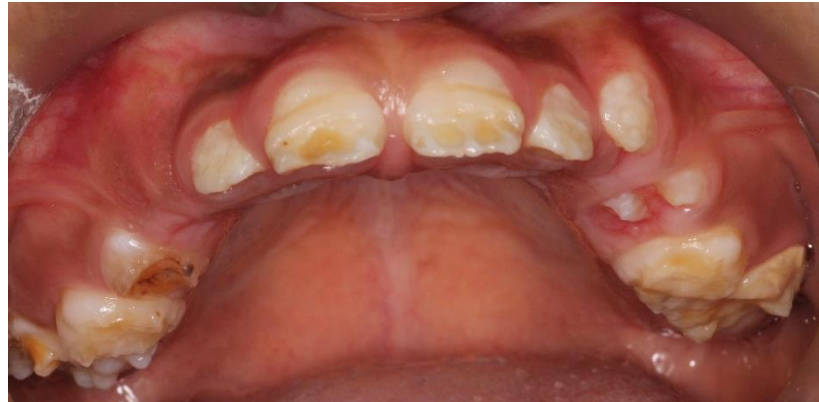*Pre-operative Imaging (13/5/2014)*

a. Intraoral photographs

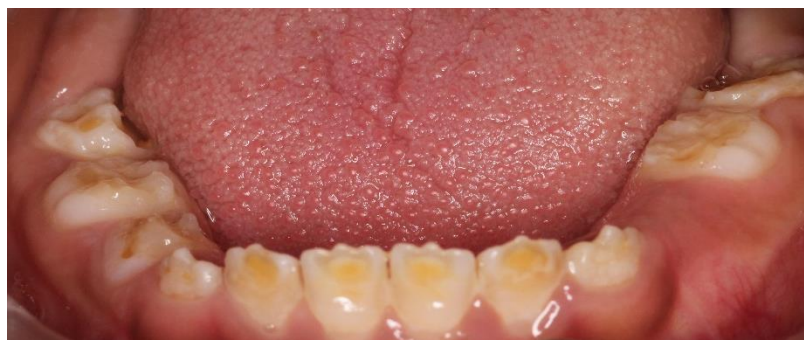Anterior  
View



Upper Arch

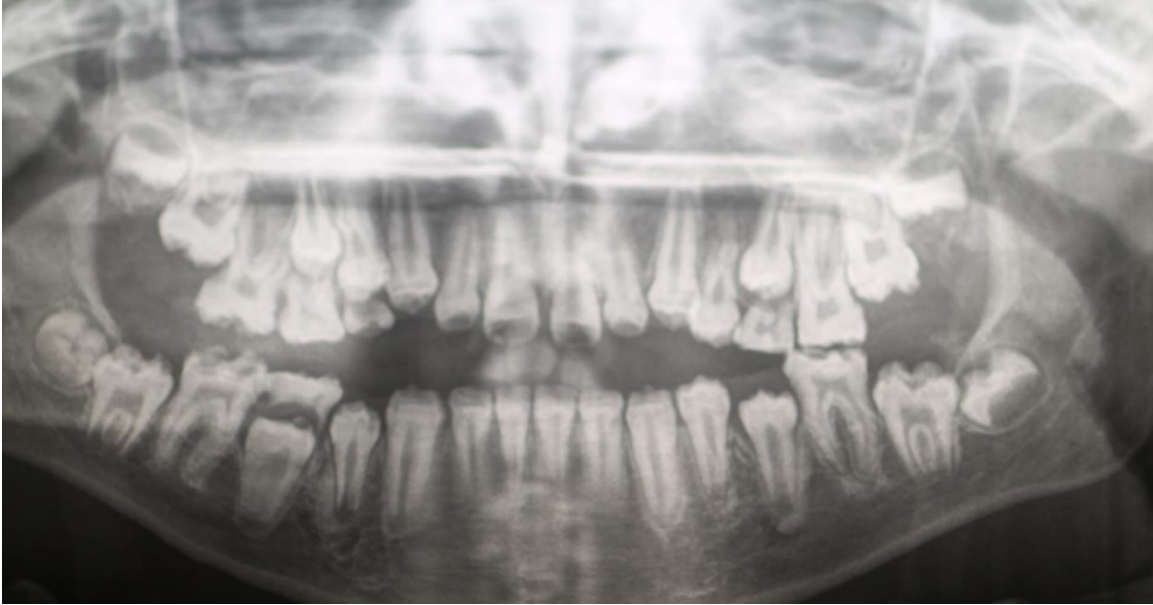


Lower Arch



b. Intraoral radiographs

OPG - DPT

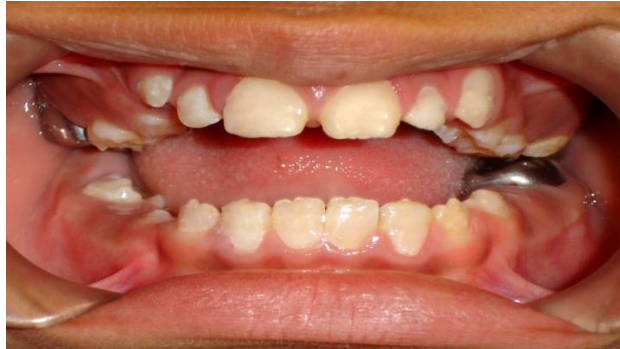

- All permanent teeth showing
- Buds of third molars are present
- Apices of PM and M not completed yet

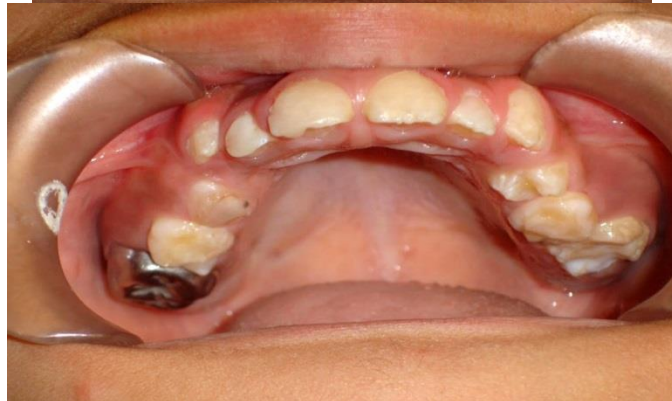*Post-operative imaging (24/06/2014)*

a. Intraoral photographs

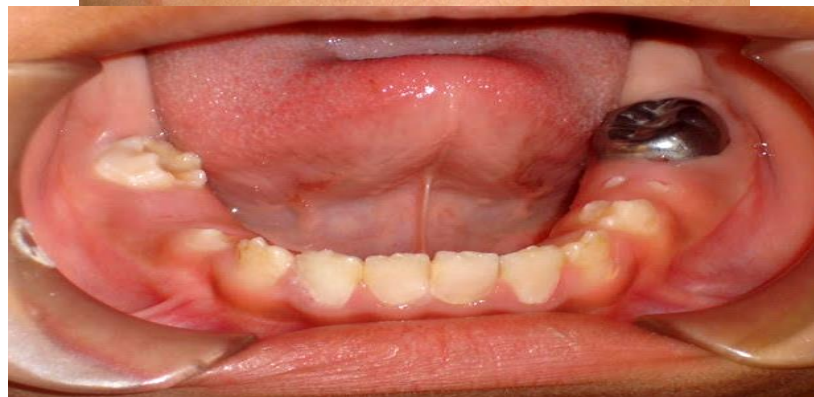Frontal View



Upper Arch



Lower Arch



## Case History

### *Personal data:*

Name: G. K

DOB: 10/07/2004

Age: 10 years

Sex: Female

First attended in: 13/05/2014

### *Reason for attendance:*

She was referred by his GDP to manage the affected permanent teeth.

### *Chief complaint (C/O):*

- G and her father complained of discolored front teeth with sensitivity, and delayed eruption of permanent teeth
- She is also getting teased at school due to the appearance of the teeth.
- History of chief complaint:

G's father noticed the brown discoloration in the newly erupted anterior teeth. Sensitivity in the back teeth:

- Associated with brushing and change in temperature.
- Does not disturb eating and sleeping.
- Does not require pain-killer.
- No previous treatment done.

### *Medical History (MH):*

- Medically fit and well with no relevant medical problems.
- No current medication.
- No known allergy.
- G. was born prematurely at 8 weeks and she was in an incubator for the first 8 weeks of birth.
- No history of severe illness during the first three years of life.
- Immunisations were up-to-date

### *Social and Family History:*

- Has an older brother (19 years old), and a younger sister (6 years old).
- English is the first language.
- No family history of teeth abnormalities.
- Attends school.

### *Dental History:*

- Regular attendee to GDP every 6 month.
- Had previous check-ups.
- History of fillings.
- No history of local anaesthesia (LA), general anaesthesia (GA) or Fluoride supplement use.

### *Dietary History:*

- Good appetite, eats a variety of food.
- Drinks mostly water.
- Limited sugar intake

### *Oral Hygiene:*

- Brushes twice daily with adult toothpaste using regular manual tooth brush.

### *Habits:*

- No bad habits.



## Clinical Examination

### Extra-oral Examination:

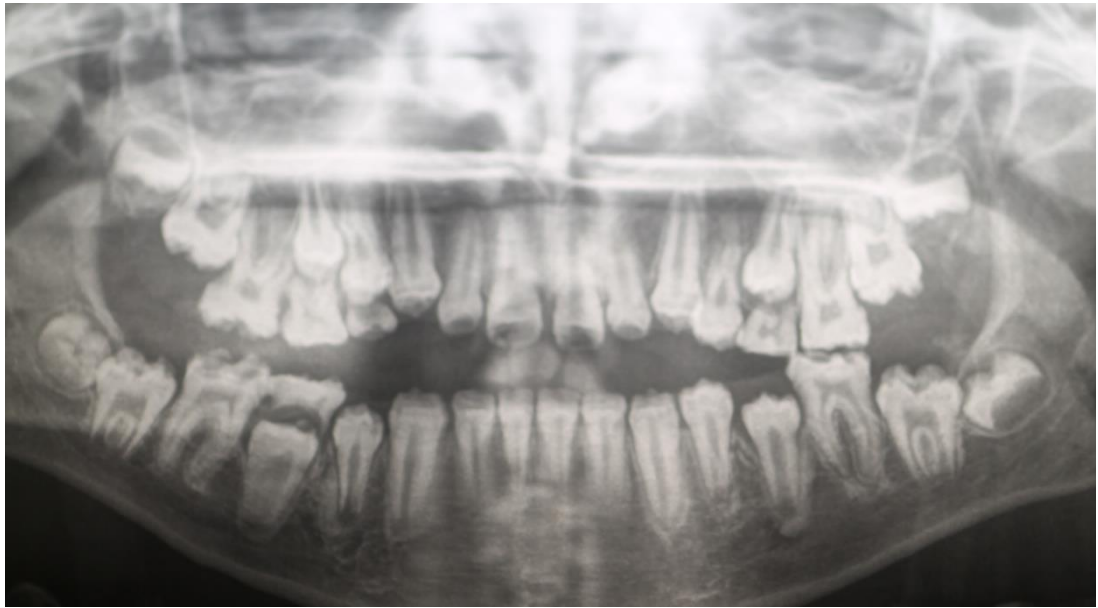
- No facial asymmetry.
- No lymphadenopathy.
- Normal mouth opening with no Temporomandibular joint abnormality

### Intra-oral Examination:

- Incisal edge of UR1 slightly chipped.
- Soft tissue (ST):  
Healthy soft tissue.
- Oral hygiene (OH):  
Good oral hygiene (plaque index (PI): 12%) (*Simplified oral hygiene index by Green and Vermilion 1964*).
- Dentition:
  - Late mixed dentition stage. 

6	E	D	C	2	1		1	2	C	D	E	6
6	E	D	C	2	1		1	2	C	D	E	6
  - Lower canines and upper left canine are partially erupted.
  - Upper right canine is palpable.
  - First permanent molars, upper and lower central and lateral incisors are erupted.
  - Caries free dentition.
- Occlusion:
  - Class II skeletal relation and increased facial proportions.
  - Class II division 1 incisor relationship.
  - Anterior open bite 8mm.
  - Midline shift to the right side.
  - She occludes solely on the left first permanent molar.
- Enamel Defect :  
Hypoplastic phenotype affecting both dentition (more prominent in permanent dentition) with demarcated yellowish brown discolouration at the incisal third of lower incisors.

- Pre-operative radiographs:



## Diagnosis and Treatment Planning

### *Diagnosis:*

- a. Dentition
  - Hypoplastic-type Amelogenesis Imperfecta affecting primary and permanent dentition.
- b. Orthodontic:
  - Class II division I incisor relationship
  - Anterior open bite
  - Midline shift to the right side
  - Class II skeletal type with increase vertical proportion
  - No orthodontic intervention is required at present
  - Future need for orthodontic surgery is required at the age of 18 years to fix present malocclusion
- c. Behavior
  - Dental anxiety

### *Treatment Objectives*

- To relieve the symptoms associated with permanent teeth.
- To stabilise dentition until definitive treatment can be done.
- To promote oral preventive measures.
- To restore function and aesthetic.
- Manage anxiety and enhance positive attitude towards dental care.

## *Provisional Treatment Plan*

### Prevention Treatment:

- OHI.
- Dietary education.
- Fluoride varnish application every 4 months.

### Behaviour Management:

- To use all possible NPBM techniques.
- Acclimatisation to dental environment.

### Restorations and Extractions:

- Referral to Orthodontic department for proper short and long-term treatment planning with regards to the followings;
  - Her malocclusion
  - The need for future orthodontic treatment.
- Restorative:
  - Restorations of 6's with GIC, Composite or Preformed metal crowns (PMCs)
  - Composite veneers UR2, UR1, UL1, UL2, LR2, LR1, LL1 and LL2.

### Maintenance and Follow up:

- Clinical review every 4 months.
- Reinforcement of dietary advice and OHI.
- Monitor composite veneers and restored 6's.
- Radiographic review if require every 6-12 months.

## *Treatment Progress and Dental Management*

### First Visit (13/5/2014):

- Patient attended with father.
- *C/O*: Bad appearance of her teeth and sensitivity.
- *MH*: NAD.
- *E/O*: Incompetent lips.
- *I/O*:
  - Open bite
  - Midline shift to the right side
  - Discolored anterior teeth (both upper and lower)
  - Lower canines and upper left canine are partially erupted.
  - Upper right canine is palpable.
  - Partial eruption of 6s
  - Enamel Hypoplastic of 6s
- Complete history taken.
- Clinical and radiographic examination.
- Pre-operative clinical photographs.
- Provisional treatment plan formulated and discussed with both patient and father.

### Treatment:

- Fluoride varnish (Duraphat2.26%) applied.
- Partially erupted first permanent molars are sealed using flowable composite and left for monitoring.
- Upper central incisors (UR1 & UL1)
  - Dry dam isolation
  - Itching and boding
  - Facial veneering using composite shade A1
  - Finishing and polishing
- Referred to the Orthodontic department for treatment planning (no immediate treatment is needed but at age of 18 patient will need orthodontic surgery to fix malocclusion)

- *OHI:*
  - Adult toothpaste with 1350ppm Fluoride or above (G. was advised to use a toothpaste for sensitive teeth).
  - Spitting after brushing rather than rinsing.
  - Use mouthwash (0.05% Fluoride) between brushing.
  - Diet advice.
- N.V: Facial veneering of lower anterior teeth.

Behaviour: Shy, anxious, potential cooperative.

Second Visit (10/6/2014)

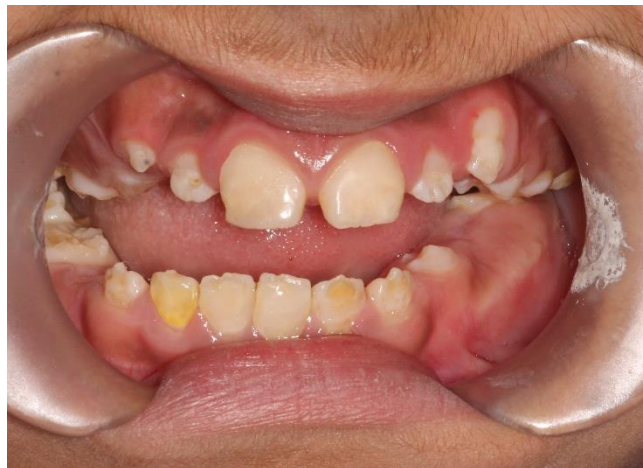- Patient attended with father.
- C/O: patient reported less pain in upper centrals after composite veneering.

Treatment:

- Lower anterior teeth (LR1, LR2, LL1 & LL2)
  - Cotton roll isolation
  - Itching and bonding
  - Facial veneering using composite shade A1
  - Finishing and polishing
- N.V: Review after 3 month, facial veneering of upper laterals.

Behaviour: shy, cooperative.

Post-operative treatment to UR1, UL2, LL1 and LL2



### Third Visit (2/2/2015)

- Patient attended with father.
- C/O: Patient reported less sensitivity.
- I/O:
  - First permanent molars erupted and showed signs of breakdown

### Treatment:

- Upper lateral incisors (UR2 & UL2)
  - Cotton roll isolation
  - Itching and boding
  - Facial veneering using composite shade A1
  - Finishing and polishing
- N.V: SSC for UR6 and LL6

Behaviour: Shy, cooperative.



Forth Visit (2/3/2015)

- Patient attended with father.

Treatment:

- UR6 and LL6:
  - Topical anesthesia (TA)(20% benzocaine)
  - Cotton roll isolation
  - Size 5 SSC chosen
  - Cemented using GIC
  - Excess cement removed
- LR6:
  - Still partially erupted and tilted lingually
  - SSC can't be performed now, need to be done ASAP as soon as the tooth erupts.
  - Etching, bonding and flow able composite used.
- N.V: monitor eruption of LR6, reevaluate composite restorations.

Behaviour: Shy, cooperative.

Fifth Visit (24/6/2015)

- Patient attended with father and younger sister.

Treatment:

- Review appointment.
- Composite restorations are in good condition.
- The patient feels a lot better after performing SSC and eating improved.
- Post-operative photographs.
- LR6 still partially erupted.

N.V: Review after 4 months.

Behaviour: very cooperative.

## Appraisal and Discussion

G.K., a 10 year old female, was born prematurely at 8 weeks and stayed in the incubator for 8 weeks. Pre-mature infant is a baby born before 37 completed weeks of gestation (more than 3 weeks before the "due date"). Prematurity can be classified as mild, when the baby is born between the 35th and 36th weeks of gestation; moderate, if the birth occurs between the 31st and 34th weeks; or extreme, if the gestational age is less than or equal to 30 weeks. Pre-mature and/or low birth weights infants are considered a public health problem due to increased economical, social, family and individual costs. It has been stated that a strong correlation between low gestational age and neonates complications. These complications include rickets, hypocalcemia, infection, anaemia, metabolic, renal, respiratory and homological disorders (Cruvinel, Gravina et al. 2012).

### Dental Outcomes of Preterm Infants

It has been stated that the facial bones and dentition can be affected by premature birth. Many studies revealed a strong relation between preterm births and enamel defects. The most common enamel defect that is diagnosed with those children is enamel hypoplasia which is defined as "deficient quantity of enamel resulting from developmental aberrations, and may occur in the form of pits, grooves, or larger areas of missing enamel". The prevalence of enamel defects of premature infants in both primary and permanent dentitions were 78% and 83%, respectively

Other defects, such as notching of the alveolar ridge, palatal grooving, high arched palate, dental crossbite, and palatal asymmetry, have also been reported with higher frequencies when compared with full-term births. Moreover, delayed eruption and developmental defects of both the primary and permanent dentitions have also been noticed (Seow 1997)

G. was diagnosed with Amelogenesis Imperfecta (AI) based on history, clinical and radiographical examinations with possible hypoplasia associated with premature birth. AI is defined as "hereditary enamel defect affecting the structure and clinical appearance of the enamel of all or nearly all the teeth in a more or less equal manner and which may be associated with morphologic or biochemical changes elsewhere in the body" ( Crawford et al , 2007).

Extensive history was obtained from the father to understand if there are any medical conditions, any medications taken or dental abnormalities in the family. No one else in the family affected with AI.

G had a history of intubation for 8 weeks. Other than this, she didn't suffer any medical problems. G has a very obvious malocclusion which represents itself as Class II division I with an anterior open-bite (AOB) and an over-jet that is equal to around 8 mm. tendency to posterior cross bite were also noticed. According to different studies, it has been stated that an anterior open bite is commonly observed with AI patients. Lots of discussions were made with regards to the aetiology of this association and genetics was the most common factor. It was also suggested that the disturbances of the enamel epithelium can cause a defect in the eruption mechanisms which lead to AOB (Alachioti, Dimopoulou et al. 2014).

### Aims of the treatments

Our treatment aims were to relieve the dental sensitivity and hens, improve the oral hygiene; to maintain the existing permanent dentition; to restore aesthetic; and to shape her attitude

and behaviour towards dentistry. G. and her father were keen to have all the treatment finished. They attended all the appointments and were always on time.

### Behaviour Management

G. was initially anxious to the dental environment as no previous dental treatment has been done. Treatment was planned to be carried out using NPBM techniques as she was willing to sit for dental examination. It has been reported that children with dental problems would exhibit negative behaviour (Wright et al., 1973). Therefore, treatment started with simple procedures (introduction to dental clinic and fluoride application) to reduce the sensitivity and to gain her confidence.

### Prevention

G. was considered a high-risk patient due to the defect on the enamel of her teeth caused by the hypoplasia. It was reported that enamel hypoplasia is linked to plaque accumulation and therefore dental caries (Eastman 2003). Diet analysis showed high sugar consumption rate together with fizzy drinks consumption. Her oral hygiene was good but she used low Fluoride concentration toothpaste. Therefore, a preventive regimen was formulated according to the Department of Health tool kit (Department of Health, 2009).

G. was advised to reduce the amount and frequency of sugary intake during the day and to be limited to mealtimes and to reduce the use of fizzy drinks. Tooth brushing helps in mechanical removal of dental biofilm, which contributes in both gingival disease and caries process. It is also considered a way for Fluoride delivery via toothpaste and had been shown to be effective in dental caries prevention (Marinho et al., 2003). G. used to brush her teeth twice daily under mum's supervision (Chestnutt et al., 1998), and advised to brush for at least 3 minutes (Ashley, 2001) using adult toothpaste containing at least 1350 ppm Fluoride. she was advised to spit without rinsing after brushing which would reduce the caries by 30% (Ashley et al., 1999) and to use Fluoride mouthrinse daily (0.05% NaF) at a different time to brushing. In addition, Fluoride varnish will be applied professionally every 3-4 months. Her oral hygiene had been maintained during the course of treatment specially after covering the sensitive areas.

### Restorations

After consultation with the orthodontic department, they said that there is no orthodontic intervention is required at present. G is going to require orthognathic surgery in order to correct her malocclusion and anterior open bite when she is around 18 years old. At the meantime, Composite veneers were placed in the all upper and lower incisors and composite restorations for the lower right and upper left first permanent molars. It is more conservative, effectively bond to teeth, with good mechanical strength and wear resistant compared to GIC and porcelain veneers (Tyas et al., 2000).

For right upper and left lower first permanent molars, pre-formed metal crowns (PMCs) were used as they offer full coverage of the affected teeth and protect them for as long as possible. PMC's are durable restorations and have been indicated for restoring both primary and permanent teeth with developmental defects in children and adolescents. Onlays are considered an alternative option; however, marginal leakage with associated decay might occur. This type of decay is difficult to detect, therefore this option was not considered (Tahmassebi, et al, 2003).

G. will be reviewed every 3-4 months to reinforce OHI and dietary advice (Department of Health, 2009), to monitor the developing dentition and the composite veneers. In addition, G will be reviewed after 9 months in the orthodontic department. Radiographic review will be every 6-12 months as needed (SDCEP, 2010).

## References

- Ashley, P., 2001. Tooth brushing: why, when and how? *Dental update*, 28(1), pp.36– 40.
- Ashley, P.F. et al., 1999. Tooth brushing Habits and Caries Experience. *Caries Research*, 33(5), pp.401–402.
- Blain, K.M. & Hill, F.J., 1998. The use of inhalation sedation and local anaesthesia as an alternative to general anaesthesia for dental extractions in children. *British Dental Journal*, 184(12), pp.608–611.
- Chestnutt, I.G. et al., 1998. The influence of tooth brushing frequency and post brushing rinsing on caries experience in a caries clinical trial. *Community Dentistry and Oral Epidemiology*, 26(6), pp.406–411.
- Crawford, P., Aldred, M., & Bloch, A. (2007). Amelogenesis Imperfecta. *Orphanet Journal of Rare Diseases*, Volume 2.2:12 doi:10.1186/1172-2-17.
- Department of Health, 2009. *Delivering Better Oral Health An evidence-based toolkit for prevention - second edition*.
- Hosey, M.T., 2002. UK National Clinical Guidelines in Paediatric Dentistry. Managing anxious children: the use of conscious sedation in paediatric dentistry. *International journal of paediatric dentistry / the British Paedodontic Society [and] the International Association of Dentistry for Children*, 12(5), pp.359– 372.
- Marinho, V.C. et al., 2003. Fluoride toothpastes for preventing dental caries in children and adolescents. In *Cochrane Database of Systematic Reviews*. John Wiley & Sons, Ltd.
- Poornima, K. Y. "Supernumerary Teeth-An Overview of Classification, Diagnosis and Management." *Journal of Oral Research & Review*. Vol 2.1 (2010).
- Scottish Dental Clinical Effectiveness Programme, 2010. *Prevention and Management of Dental Caries in Children*.
- Tahmassebi, J. F., P. F. Day, K. J. Toumba, and G. A. Andreadis. "Paediatric dentistry in the new millennium: 6. Dental anomalies in children." *Dental update* 30, no. 10 (2003): 534.
- Tyas, M.J. et al., 2000. Minimal intervention dentistry — a review\*. *International Dental Journal*, 50(1), pp.1–12.
- Veerkamp, J.S. et al., 1993. Dental treatment of fearful children using nitrous oxide. Part 4: Anxiety after two years. *ASDC journal of dentistry for children*, 60(4), pp.372–376.
- Wright, G.Z., Alpern, G.D. & Leake, J.L., 1973. A cross-validation of variables affecting children's cooperative behaviour. *Journal of the Canadian Dental Association*, 39(4), pp.268–273.
- Alachioti, X. S., E. Dimopoulou, et al. (2014). "Amelogenesis imperfecta and anterior open bite: Etiological, classification, clinical and management interrelationships." *Journal of orthodontic science* 3(1): 1.
- Cruvinel, V. R. N., D. B. L. Gravina, et al. (2012). "Prevalence of enamel defects and associated risk factors in both dentitions in preterm and full term born children." *Journal of Applied Oral Science* 20(3): 310-317.
- Eastman, D. L. (2003). "Dental outcomes of preterm infants." *Newborn and Infant Nursing Reviews* 3(3): 93-98. Fadavi, S., S. Adeni, et al. (1991). "The oral effects of orotracheal

intubation in prematurely born preschoolers." ASDC journal of dentistry for children 59(6): 420-424. Seow, W. K. (1997). "Effect of preterm birth on oral growth and development." Australian dental journal 42(2): 85-91.

The early and long-term effects of birth prematurity on the physical and psychological growth and development of the child are subjects of considerable current interest.