

CASE REPORT

Submitted by

ABDULFATAH ALAZMAH

Candidate Number: 12092520

DDS (SAUDI ARABIA)

Case 1:

Management of Caries in A Young Child

**In partial fulfilment of the degree
Clinical Doctorate in Paediatric Dentistry
Eastman Dental Institute
University College London
2013 - 2016**



Table of Contents

Summary	3
Clinical photographs.....	
Pre-operative	
Post-Operative.....	
Case History	4
Pre-Treatment Assessment.....	5
Clinical Examination	6
Extraoral examination	6
Intraoral examination	6
Special Investigations.....	7
Diagnosis and Treatment Planning.....	8
Diagnosis	8
Treatment Objectives.....	8
Treatment Plan	8
Treatment progress and dental management	10
Post-operative Radiographs.....	
Appraisal and Discussion	14
References:.....	17

Summary

M.A, 6 year and 2 months anxious little girl, was referred by her general dental practitioner (GDP) to the Department of Paediatric Dentistry at Eastman Dental Hospital for the management of her carious primary molars complicated by uncooperative behaviour towards dental treatment.

Chief complaint: C.W had a history of abscess related to the LLD when presented to GDP, and only analgesics were prescribed. No further signs or symptoms reported at time of presentation.

Examination: The patient was on a cariogenic diet. She is a regular dental attendee but had no previous experience of dental treatment. She presented with multiple decays affecting her E's and D's. Patient seemed to be anxious towards dental treatment.

Treatment provided up to date:

1. Prevention and acclimatization

- Oral hygiene instruction
- Dietary advise

2. Restorations


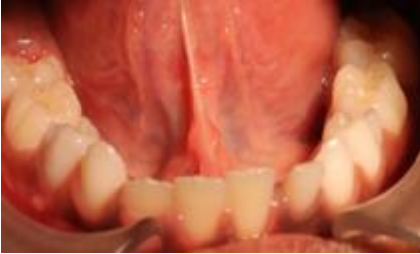




- Fissure sealant on UL6 & LL6
- Duarphat Application for partially erupted LR6
- Composite filling on URD, URE, and ULD
- Pulpotomy and stainless steel crown on LLD
- Extraction of LLD

3. Maintenance and recall/ review

- Monitor permanent teeth eruption
- Monitor all restored primary teeth

Treatment was carried out under local anaesthesia, in conjunction with inhalation sedation (from fourth visit) in order to minimise the risk of loss of cooperation.

Clinical photographs

<i>Pre-Operative</i>		
<i>Maxillary Arch</i>	<i>Mandibular Arch</i>	<i>Frontal View</i>
		
<i>Post operative</i>		
<i>Maxillary Arch</i>	<i>Mandibular Arch</i>	<i>Frontal View</i>
		

Case History

Personal Details

Initials: C.W

DOB: 14/06/2007

Age on presentation: 6 years and 4 months

Age on last appointment: 6 years and 7 months.

Sex: Female

Pre-Treatment Assessment

Referred by: GDP

History of Presenting Complaint: Free of pain but presented with caries affecting upper and lower posterior teeth.

Medical History

- Fit and healthy, no known allergies
- Full term, normal delivery.
- No history of severe illness during the first year of life.

Dental History

- Regular attendee to dentist back
- No history of previous dental treatment

Family and Social History

- No significant family history
- Has younger 3 years baby brother
- Recently moved to UK
- Attends 'Argyle Primary School'.

Diet

- Snacks: Sweets frequently
- Fizzy drinks occasionally
- Breastfeeding stopped by the age of two.

Oral Hygiene

- Brushed twice/day, manual toothbrush
- Children's toothpaste

Habits

- NIL

Clinical Examination

C.W was willing to sit on the chair, however she showed signs of anxiety towards dental treatment earlier.

→ Extra-oral examination

- Symmetrical face, no extra oral swelling
- No regional lymphadenopathy.
- Normal mouth opening.
- No TMJ abnormality noted.

→ Intraoral examination

- Soft tissue: nothing significant.
- Oral hygiene: Poor (Plaque Index 0.7).
- Early mixed dentition as charted

E	D	C	B	A		A	B	C	D	E	6
6	E	D	C	2	1	1	B	C	D	E	6

- Caries

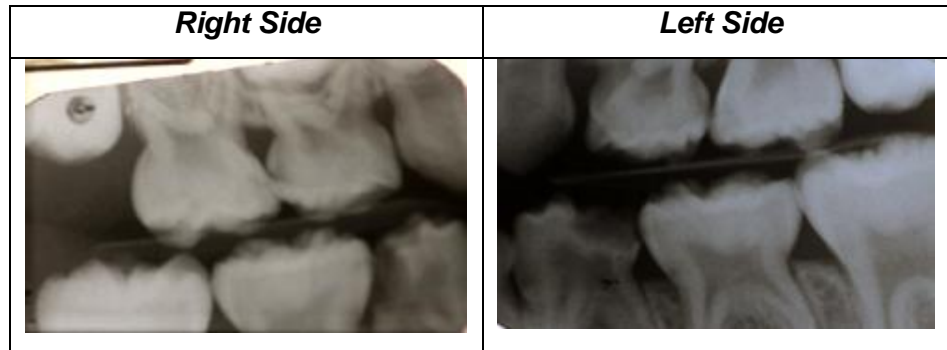
E	D		D	E
	D		D	

- Mobility: LLB.
- LR6: partially erupted.
- UR6: unerupted, palpable
- Soft tissue: Sinus related to LRD
- Occlusion:
 - Class I skeletal relation
 - Class I left molar relation
 - not applicable for right side

Special Investigations

Radiographs

Pre – operative BITWINGS (X-rays taken on 24-Oct-2013)



Radiograph finding: Radiolucencies suggesting caries on all D's and upper E's

Diagnosis and Treatment Planning

Diagnosis

- Dental caries secondary to cariogenic diet.
- Dental anxiety.

Treatment Objectives

- Improve oral hygiene through instructions, fluoride advice, and dietary education.
- Manage anxiety and promote positive attitude towards dental care.
- Restore oral health (function & aesthetics).
- Monitor development of permanent dentition

Treatment Plan

1) *Prevention and Acclimatization*

- Establish a preventive regimen consistent with the Department of Health preventive toolkit (second edition).
- Incorporation of nitrous oxide inhalation sedation as a pharmacological behavioural management technique.

2) *Restoration*

Restorative care through quadrant dentistry:

I. URQ:

- ★ URE and URD- caries removal and composite filling.

II. ULQ:

- ★ UL6- fissure sealant.
- ★ ULE and ULD- caries removal and composite filling.

III. LLQ:

- ★ LL6- fissure sealant.
- ★ LLD- pulpotomy and SSC.

IV. LRQ:

- ★ LRD- extraction.

3) *Maintenance and follow up*

- Clinical review every 3 months.
- Radiological review every 6 -12 months.
- Reinforcement of dietary & oral hygiene advice.

The above restorative treatment was done under local anaesthesia in conjunction with inhalation sedation(during performing SSC and extraction). Her behaviour was assessed in each session using the facial imaging scale (FIS) to monitor her acceptance and attitude to each dental treatment performed.

Treatment progress and dental management

Visit 1: 23/10/2013

- Attended accompanied with mother in new patient clinic.
- No signs or symptoms.
- Complete history taken, with both clinical and radiographical examinations.
- Provisional treatment plan formulated and discussed with mother.
- Inhalation sedation agreed to control anxiety and consent obtained.
- A 3-day diet sheet analysis provided.
- Adult tooth paste (1350 ppm fluoride) and spitting after brushing advised.
- Tell-Show-Do technique used.
- Pre-operative clinical photographs.

Visit 2: 12/11/2013

- Attended with mother.
- C.C: Nil.
- Extra oral: Nil
- Intra oral: Oral hygiene improved (Plaque Index – 0.4).

Treatment:

- Acclimatization.
- Cleaning and polishing of teeth.
- Delton occlusal fissure sealant applied on fully erupted Left side 6's.
- LRD stabilized with zinc oxide Eugenol (IRM®).
- Topical anaesthesia (20% benzocaine gel) and rubber dam introduction.
- Duraphat (2.2% Fluoride) varnish applied on presented teeth.
- Diet advice given based on the patient diet sheet analysis findings.
- Oral hygiene instructions reinforced.
- FIS.

⇒ Next visit: Restore URE, URD under LA.

Visit 3: 06/12/2013

- Attended with mother.
- C.C: Nil.

- Extra oral: Nil
- Intra oral: Nil

Treatment:

- Topical anaesthesia
- Local anaesthesia infiltration administered (2.2 ml of 2% lignocaine hydrochloride with 1:80,000 adrenaline) on URE and URD areas.
- Rubber dam isolation of URE and URD by DW clamp on URE.

URE^(m) and URD^(OD):

- Caries excavation using high-speed hand piece and 330 bur.
- posterior composite filling.
- Finishing and polishing using composite finishing burs and white stone
- OHI and diet advice.
- FIS

⇒ N.V: Restore ULE +ULD under LA.

Visit 4: 27/01/2014

- Attended with mother.
- C.C: Nil.
- Extra oral: Nil.
- Intra oral: Mild improvement in oral hygiene (Plaque Index – 0.33).

Treatment:

- **ULD^(OD)**: Fillings under LA as described last visit.
- **ULE**: Has no caries (direct view after caries removal of ULD), Duraghat application to the mesial surface.

⇒ N.V: restore LLD under LA and IS.

Visit 5: 11/02/2014

- Attended with mother.
- C.C: Nil.
- Extra oral: Nil.
- Intra oral: Improved oral hygiene (Plaque Index – 0.27).

Treatment:

- Inhalation sedation (30% Nitrous oxide and 70% Oxygen in 6 L/min flow)and topical anaesthesia.

- Local anaesthesia (2% Lignocaine) infiltration on LLD.
- Rubber dam isolation of LLD by DW clamp on LLE.

LLD⁽⁰⁾:

- Caries removed – noted close to the pulp.
- Indirect pulp capping with calcium hydroxide.
- Tooth prepared for SSC using diamond burs.
- SSC size 5 (3M) cemented using GIC luting cement.

- 100% Oxygen and Instructions.
- FIS.

⇒ N.V: Extract LRD under IS + LA.

Visit 6: 25/02/2014

- Attended with mother.
- C.C: Nil.
- Extra oral: Nil.
- Intra oral: Improved oral hygiene (Plaque Index – 0.21).

Treatment:

- Inhalation sedation, topical and local anaesthesia (Lignocaine), rubber dam as described last visit.

LRD: Extraction using elevator and forceps.

- Oxygen and Instructions as previous visits.
- FIS.
- Diet sheet given again.

⇒ Next visit: Review of present restorations.

Visit 7: 30/04/2014

- Attended with mother.
- C.C: Nil.
- Extra oral: Nil.
- Intra oral: Nil

Treatment:

- Clinical and radiographical examination to assess present restoration.

- Delton occlusal fissure sealant applied on LR6 under cotton roll isolation and without inhalation sedation.
- Diet sheet discussed and habits compared to previously.
- Previous instructions reinforced.
- Post treatment clinical photos.
- FIS.


⇒ N.V after 3 months:

- Review.
- Fluoride.

Future Treatments and Managements Considerations:

- ❖ Other review appointments to monitor her general oral health and restored teeth before discharging.

Post – operative BITWINGS



Radiograph finding: No significant findings.

Appraisal and Discussion

The main goals of C.W's dental care were to get healthy dentition and to induct a helpful dental attitude for persistence of oral hygiene. Therefore, treating her decayed primary teeth was essential to promote good oral health for forthcoming permanent teeth.

When presented she required several invasive treatments. Although her dental history revealed unsuccessful previous experience due to anxious behaviour toward dental environment, she responded well to acclimatisation and inhalation sedation supplemented by NPBMt.

C.W did not report any pain when first presented, so introduction to dental treatment by prophylaxis and temporization of grossly carious teeth performed to prevent pain and infection till scheduled for extractions. On each session, C.W's cooperation and acceptance to the dental environment was reassessed constantly.

→ Behaviour Management:

Inhalation sedation with nitrous oxide is a conscious sedation technique with high success rate (Blain and Hill, 1998, Lyratzopoulos and Blain, 2003). Thus, it is favoured in managing mild to moderately anxious paediatric dental patient(Hosey, 2002).

Articaine is an amide local anaesthetic, it contains ester and thiophene group to increase lipo solubility. This improves the diffusion of anaesthetic and consequently provides a superior effect. A systematic review compared the efficacy and safety of articaine to lignocaine and concluded that articaine is better than lignocaine in routine dental treatment, yet its use in children bellow 4 years of age not recommended as no evidence to support such usage (Katyal, 2010). Which is inapplicable in C.W's case.

Because anxiety has a significant impact on treatment, measuring it is essential to accomplish a treatment plan. C.W's level of anxiety was measured at each visit to assess her general concern, acceptance, and feeling about the dental treatment using the facial image scale (FIS)(Buchanan and Niven, 2002).

→ **Prevention:**

C.W was a high caries risk patient in mixed dentition. It is essential to evaluate the caries risk of the patient, as the decision for preventive therapy should be correlated to the risk (Hale, 2003) . C.W's was considered a high caries risk patient that requires special preventive interventions.

★ **Dietary Advise**

C.W consumed frequent cariogenic snacks in between meal and lots of throughout the day. It was suggested by (Deery and Toumba, 2012) that a positive and effective diet advice should be realistic. She was advised to cut down on sugary intake and have healthy snacks in between meal.

★ **Tooth Brushing**

Tooth brushing is a universal habit for controlling plaque and considered as a method to deliver fluoride. C.W used to brush unsupervised twice daily with children's toothpaste. She was advised to use adult toothpaste and to be supervised while brushing since this has been shown by (Curnow et al., 2010) to decrease caries level by 56%. She was also instructed to spit instead of rinse in order to increase the effect of the fluoridated tooth paste as recommended by (Pitts et al., 2012). As a result, C.W's oral hygiene had improved towards the end of treatment.

★ **Fluoride**

The efficacy of fluoride toothpastes in the prevention of dental caries was concluded in 2 systematic reviews (Marinho et al., 2003) and (Ammari et al., 2003). As C.W was a high-risk caries patient, she was advised to use adult toothpaste containing a minimum of 1350 ppm of fluoride, and a professional involvement by fluoride application as a prevention measure 3 times in 12 months, according to the Department of Health toolkit second edition.

→ **Fissure sealant:**

Fissure sealant application is promoted in high caries risk patients (Beauchamp et al., 2008). A recent systematic review has demonstrated more than 9 years effectiveness and 85% retention after 2 years (Ahovuo-Saloranta et al., 2008) and is recommended in the BSPD guidelines, 2000.

→ **Restorations:** The choice of restoration is established upon:

- The age and the dental development
- Location and extent of the lesion and any related signs and symptoms

Restoring primary molars might seem obvious but surprisingly limited evidence is available and (Tickle et al., 2002, Tickle et al., 2008) was the first to start this debate. However, un-restored primary teeth has adverse effect on the quality of life in children as stated by (Sheiham, 2006).

A systematic review (Yengopal et al., 2009) found that there is no certain recommendation for which filling material to use and therefore this will obviously depend on the clinical scenario. In M.A case her cooperation and the extent of the lesion allowed to the use of composite fillings to restore her teeth without any difficulty or complications.

- **Indirect Pulp Capping:**

According to a Cochrane systematic review conducted in 2006, it was found that in deep lesions, partial caries removal is preferable to complete caries removal to reduce the risk of carious exposure. Another review done by the British Society of Paediatric Dentistry in 2006 found a clinical success rate higher than 90% after 3 years of follow up for teeth with indirect pulp treatment.

→ **Stainless steel crown (SSC):**

It was indicated to restore LLD with SSC after pulp therapy as recommended by (Kindelan et al., 2008) at the UK national guidelines. Although, a Cochrane systematic review concluded that there is no evidence available to suggest superiority of SSCs in restoring primary molars (Innes et al., 2007).

In consideration of the treatment outcome, up to now it had been satisfactory. C.W completed the treatment planned established earlier and will be reviewed every 3 months for a year time before being discharged.

References:

- AHOVUO-SALORANTA, A., HIIRI, A., NORDBLAD, A., MÄKELÄ, M. & WORTHINGTON, H. V. 2008. Pit and fissure sealants for preventing dental decay in the permanent teeth of children and adolescents. *Cochrane Database Syst Rev*, 4.
- AMMARI, A., BLOCH-ZUPAN, A. & ASHLEY, P. 2003. Systematic review of studies comparing the anti-caries efficacy of children's toothpaste containing 600 ppm of fluoride or less with high fluoride toothpastes of 1,000 ppm or above. *Caries research*, 37, 85-92.
- BEAUCHAMP, J., CAUFIELD, P. W., CRALL, J. J., DONLY, K., FEIGAL, R., GOOCH, B., ISMAIL, A., KOHN, W., SIEGAL, M. & SIMONSEN, R. 2008. Evidence-based clinical recommendations for the use of pit-and-fissure sealants A report of the American Dental Association Council on Scientific Affairs. *The Journal of the American Dental Association*, 139, 257-268.
- BLAIN, K. M. & HILL, F. 1998. The use of inhalation sedation and local anaesthesia as an alternative to general anaesthesia for dental extractions in children. *British dental journal*, 184, 608-611.
- BUCHANAN, H. & NIVEN, N. 2002. Validation of a Facial Image Scale to assess child dental anxiety. *International Journal of Paediatric Dentistry*, 12, 47-52.
- CURNOW, M., PINE, C., BURNSIDE, G., NICHOLSON, J., CHESTERS, R. & HUNTINGTON, E. 2010. A randomised controlled trial of the efficacy of supervised toothbrushing in high-caries-risk children. *Caries Research*, 36, 294-300.
- DAVIES, G. M. & DAVIES, R. M. 2008. Delivering better oral health--an evidence-based toolkit for prevention: a review. *Dental update*, 35, 460-462.
- DEERY, C. & TOUMBA, K. 2012. Diagnosis and prevention of dental caries. *Paediatric dentistry*, 85.
- FRIMAN, P. C., BARONE, V. J. & CHRISTOPHERSEN, E. R. 1986. Aversive taste treatment of finger and thumb sucking. *Pediatrics*, 78, 174-176.
- HALE, K. 2003. Oral health risk assessment timing and establishment of the dental home. *Pediatrics*, 111, 1113.
- H. D. RODD, P. J. WATERHOUSE, A. B. FUKS, S. A. FAYLE & M. A. MOFFAT. 2006 Pulp therapy for primary molars. BSPD and IAPD, *International Journal of Paediatric Dentistry* 16 (Suppl. 1): 15-23
- HOSEY, M. 2002. Managing anxious children: the use of conscious sedation in paediatric dentistry. *International Journal of Paediatric Dentistry*, 12, 359-372.
- INNES, N., RICKETTS, D. & EVANS, D. 2007. Preformed metal crowns for decayed primary molar teeth. *Cochrane Database Syst Rev*, 1.
- KATYAL, V. 2010. The efficacy and safety of articaine versus lignocaine in dental treatments: a meta-analysis. *journal of dentistry*, 38, 307.
- KINDELAN, S., DAY, P., NICHOL, R., WILLMOTT, N. & FAYLE, S. 2008. UK National Clinical Guidelines in Paediatric Dentistry: stainless steel preformed crowns for primary molars. *International Journal of Paediatric Dentistry*, 18, 20-28.
- LYRATZOPOULOS, G. & BLAIN, K. 2003. Inhalation sedation with nitrous oxide as an alternative to dental general anaesthesia for children. *Journal of Public Health*, 25, 303-312.
- MARINHO, V., HIGGINS, J., LOGAN, S. & SHEIHAM, A. 2003. Systematic review of controlled trials on the effectiveness of fluoride gels for the prevention of dental caries in children. *Journal of dental education*, 67, 448-458.

- PITTS, N., DUCKWORTH, R., MARSH, P., MUTTI, B., PARNELL, C. & ZERO, D. 2012. Post-brushing rinsing for the control of dental caries: exploration of the available evidence to establish what advice we should give our patients. *British Dental Journal*, 212, 315-320.
- SHEIHAM, A. 2006. Dental caries affects body weight, growth and quality of life in pre-school children. *British dental journal*, 201, 625-626.
- TICKLE, M., BLINKHORN, A. & MILSOM, K. 2008. The Occurrence of Dental Pain and Extractions over a 3- Year Period in a Cohort of Children Aged 3- 6 Years. *Journal of public health dentistry*, 68, 63-69.
- TICKLE, M., MILSOM, K., KING, D., KEARNEY-MITCHELL, P. & BLINKHORN, A. 2002. The fate of the carious primary teeth of children who regularly attend the general dental service. *British dental journal*, 192, 219-223.
- WARREN, J. J., SLAYTON, R. L., YONEZU, T., BISHARA, S. E., LEVY, S. M. & KANELIS, M. J. 2005. Effects of nonnutritive sucking habits on occlusal characteristics in the mixed dentition. *Pediatric dentistry*, 27, 445-450.
- YENGOPAL, V., HARNEKER, S. Y., PATEL, N. & SIEGFRIED, N. 2009. Dental fillings for the treatment of caries in the primary dentition. *Cochrane Database Syst Rev*, 15.