



**Cochrane**  
**Library**

Cochrane Database of Systematic Reviews

## Diagnostic accuracy of different imaging modalities following computed tomography (CT) scanning for assessing the resectability with curative intent in pancreatic and periampullary cancer (Review)

Tamburrino D, Riviere D, Yaghoobi M, Davidson BR, Gurusamy KS

Tamburrino D, Riviere D, Yaghoobi M, Davidson BR, Gurusamy KS.

Diagnostic accuracy of different imaging modalities following computed tomography (CT) scanning for assessing the resectability with curative intent in pancreatic and periampullary cancer.

*Cochrane Database of Systematic Reviews* 2016, Issue 9. Art. No.: CD011515.

DOI: 10.1002/14651858.CD011515.pub2.

[www.cochranelibrary.com](http://www.cochranelibrary.com)

## TABLE OF CONTENTS

HEADER . . . . .	1
ABSTRACT . . . . .	1
PLAIN LANGUAGE SUMMARY . . . . .	2
BACKGROUND . . . . .	3
Figure 1. . . . .	5
OBJECTIVES . . . . .	6
METHODS . . . . .	6
RESULTS . . . . .	9
Figure 2. . . . .	10
Figure 3. . . . .	12
Figure 4. . . . .	13
Figure 5. . . . .	14
DISCUSSION . . . . .	17
AUTHORS' CONCLUSIONS . . . . .	18
ACKNOWLEDGEMENTS . . . . .	18
REFERENCES . . . . .	18
CHARACTERISTICS OF STUDIES . . . . .	30
DATA . . . . .	44
Test 1. EUS. . . . .	44
ADDITIONAL TABLES . . . . .	44
APPENDICES . . . . .	49
CONTRIBUTIONS OF AUTHORS . . . . .	51
DECLARATIONS OF INTEREST . . . . .	51
SOURCES OF SUPPORT . . . . .	52
DIFFERENCES BETWEEN PROTOCOL AND REVIEW . . . . .	52

[Diagnostic Test Accuracy Review]

# Diagnostic accuracy of different imaging modalities following computed tomography (CT) scanning for assessing the resectability with curative intent in pancreatic and periampullary cancer

Domenico Tamburrino<sup>1</sup>, Deniece Riviere<sup>2</sup>, Mohammad Yaghoobi<sup>3</sup>, Brian R Davidson<sup>4</sup>, Kurinchi Selvan Gurusamy<sup>4</sup>

<sup>1</sup>HPB and Liver Transplant Surgery, Royal Free Hospital, London, UK. <sup>2</sup>Department of Surgery, Radboud University Medical Center Nijmegen, Nijmegen, Netherlands. <sup>3</sup>Division of Gastroenterology, McMaster University and McMaster University Health Sciences Centre, Hamilton, Canada. <sup>4</sup>Department of Surgery, Royal Free Campus, UCL Medical School, London, UK

Contact address: Kurinchi Selvan Gurusamy, Department of Surgery, Royal Free Campus, UCL Medical School, Pond Street, London, NW3 2QG, UK. [k.gurusamy@ucl.ac.uk](mailto:k.gurusamy@ucl.ac.uk).

**Editorial group:** Cochrane Upper GI and Pancreatic Diseases Group.

**Publication status and date:** New, published in Issue 9, 2016.

**Review content assessed as up-to-date:** 5 November 2015.

**Citation:** Tamburrino D, Riviere D, Yaghoobi M, Davidson BR, Gurusamy KS. Diagnostic accuracy of different imaging modalities following computed tomography (CT) scanning for assessing the resectability with curative intent in pancreatic and periampullary cancer. *Cochrane Database of Systematic Reviews* 2016, Issue 9. Art. No.: CD011515. DOI: 10.1002/14651858.CD011515.pub2.

Copyright © 2016 The Cochrane Collaboration. Published by John Wiley & Sons, Ltd.

## ABSTRACT

### Background

Periampullary cancer includes cancer of the head and neck of the pancreas, cancer of the distal end of the bile duct, cancer of the ampulla of Vater, and cancer of the second part of the duodenum. Surgical resection is the only established potentially curative treatment for pancreatic and periampullary cancer. A considerable proportion of patients undergo unnecessary laparotomy because of underestimation of the extent of the cancer on computed tomography (CT) scanning. Other imaging methods such as magnetic resonance imaging (MRI), positron emission tomography (PET), PET-CT, and endoscopic ultrasound (EUS) have been used to detect local invasion or distant metastases not visualised on CT scanning which could prevent unnecessary laparotomy. No systematic review or meta-analysis has examined the role of different imaging modalities in assessing the resectability with curative intent in patients with pancreatic and periampullary cancer.

### Objectives

To determine the diagnostic accuracy of MRI, PET scan, and EUS performed as an add-on test or PET-CT as a replacement test to CT scanning in detecting curative resectability in pancreatic and periampullary cancer.

### Search methods

We searched MEDLINE, Embase, Science Citation Index Expanded, and Health Technology Assessment (HTA) databases up to 5 November 2015. Two review authors independently screened the references and selected the studies for inclusion. We also searched for articles related to the included studies by performing the “related search” function in MEDLINE (OvidSP) and Embase (OvidSP) and a “citing reference” search (by searching the articles that cite the included articles).

---

**Diagnostic accuracy of different imaging modalities following computed tomography (CT) scanning for assessing the resectability with curative intent in pancreatic and periampullary cancer (Review)**

Copyright © 2016 The Cochrane Collaboration. Published by John Wiley & Sons, Ltd.

## Selection criteria

We included diagnostic accuracy studies of MRI, PET scan, PET-CT, and EUS in patients with potentially resectable pancreatic and periampullary cancer on CT scan. We accepted any criteria of resectability used in the studies. We included studies irrespective of language, publication status, or study design (prospective or retrospective). We excluded case-control studies.

## Data collection and analysis

Two review authors independently performed data extraction and quality assessment using the QUADAS-2 (quality assessment of diagnostic accuracy studies - 2) tool. Although we planned to use bivariate methods for analysis of sensitivities and specificities, we were able to fit only the univariate fixed-effect models for both sensitivity and specificity because of the paucity of data. We calculated the probability of unresectability in patients who had a positive index test (post-test probability of unresectability in people with a positive test result) and in those with negative index test (post-test probability of unresectability in people with a positive test result) using the mean probability of unresectability (pre-test probability) from the included studies and the positive and negative likelihood ratios derived from the model. The difference between the pre-test and post-test probabilities gave the overall added value of the index test compared to the standard practice of CT scan staging alone.

## Main results

Only two studies (34 participants) met the inclusion criteria of this systematic review. Both studies evaluated the diagnostic test accuracy of EUS in assessing the resectability with curative intent in pancreatic cancers. There was low concerns about applicability for most domains in both studies. The overall risk of bias was low in one study and unclear or high in the second study. The mean probability of unresectable disease after CT scan across studies was 60.5% (that is 61 out of 100 patients who had resectable cancer after CT scan had unresectable disease on laparotomy). The summary estimate of sensitivity of EUS for unresectability was 0.87 (95% confidence interval (CI) 0.54 to 0.97) and the summary estimate of specificity for unresectability was 0.80 (95% CI 0.40 to 0.96). The positive likelihood ratio and negative likelihood ratio were 4.3 (95% CI 1.0 to 18.6) and 0.2 (95% CI 0.0 to 0.8) respectively. At the mean pre-test probability of 60.5%, the post-test probability of unresectable disease for people with a positive EUS (EUS indicating unresectability) was 86.9% (95% CI 60.9% to 96.6%) and the post-test probability of unresectable disease for people with a negative EUS (EUS indicating resectability) was 20.0% (5.1% to 53.7%). This means that 13% of people (95% CI 3% to 39%) with positive EUS have potentially resectable cancer and 20% (5% to 53%) of people with negative EUS have unresectable cancer.

## Authors' conclusions

Based on two small studies, there is significant uncertainty in the utility of EUS in people with pancreatic cancer found to have resectable disease on CT scan. No studies have assessed the utility of EUS in people with periampullary cancer.

There is no evidence to suggest that it should be performed routinely in people with pancreatic cancer or periampullary cancer found to have resectable disease on CT scan.

## PLAIN LANGUAGE SUMMARY

### Diagnostic accuracy of different scans following a CT scan for assessing whether pancreatic and periampullary cancer is resectable

#### Review question

How well do different scans identify whether pancreatic and periampullary cancer is resectable (can be surgically removed) in patients with pancreatic cancer in whom computed tomography (CT) scan suggests that the cancer can be removed?

CT scan involves a series of X-rays which are combined by a computer to provide detailed images of the area of the body X-rayed.

#### Background

The pancreas is an organ situated in the abdomen close to the junction of the stomach and small bowel. It secretes digestive juices that are necessary for the digestion of all food materials. The digestive juices secreted in the pancreas drain into the upper part of the small bowel via the pancreatic duct. The bile duct is a tube which drains bile from the liver and gallbladder. The pancreatic and bile ducts share a common path just before they drain into the small bowel. This area is called the periampullary region. Surgical removal is the only potentially curative treatment for cancers arising from the pancreatic and periampullary regions. A considerable proportion

of patients undergo unnecessary major open abdominal exploratory operation (laparotomy) because their CT scan has underestimated the spread of cancer. If the cancer is spread within the abdomen as identified during the major open operation, the main treatment is chemotherapy which does not cure the cancer but may improve survival. Thus the major open abdominal operation with its associated risks can be avoided if the spread of cancer within the abdomen is known before the major operation. Determining the extent of cancer is called “staging” the cancer. Usually the minimum test used for staging is the CT scan. However, CT scan can understage the cancer, i.e. it can underestimate the spread of cancer. Various other scans can be used in addition to CT scan in order to find out if pancreatic cancer is resectable (able to be surgically removed). These include the following tests.

1. Magnetic resonance imaging (MRI): use of a powerful magnet to produce images of different tissues of the body.
2. Positron emission tomography (PET scan): small amount of radioactive glucose (sugar) is used to differentiate between different tissues. It utilises the property that cancer cells often use more glucose than normal cells).
3. Endoscopic ultrasound (EUS); the use of an endoscope, a camera introduced into the body cavities to view the inside of the body. An ultrasound (high-energy sound waves) probe at the end of the endoscope is used to differentiate different tissues.

In addition, a combination of PET-CT may be performed instead of CT.

Different studies report different accuracy of these tests in assessing whether the cancer can be removed. In this review, we identified all such studies and used appropriate mathematical methods to identify the average diagnostic accuracy of these tests for staging pancreatic and periampullary cancers considered to be removable after a CT scan.

### Study characteristics

We included two studies with a total of 34 patients in this review. Both studies evaluated the diagnostic performance of EUS. This evidence is current to 5 November 2015.

### Quality of the evidence

Of the two studies, one study was conducted as well as such a study could be conducted. The methodological quality of the other study was poor.

### Key results

The two included studies showed that in those people with pancreatic cancer in whom CT alone showed their cancer was capable of being fully surgically removed, 61% (61 out of 100) would prove to have cancer that was too fully spread to make this possible when a laparotomy was attempted. Due to the small sample size, there is significant uncertainty in the utility of EUS in people with pancreatic cancer found to have resectable disease on CT scan. There is no evidence to suggest that it should be performed routinely in people with pancreatic cancer found to have resectable disease on CT scan.

## BACKGROUND

Please see [Appendix 1](#) for a glossary of terms.

Periampullary cancer develops near the ampulla of Vater ([National Cancer Institute 2014a](#)). Periampullary cancer includes cancer of the head and neck of the pancreas, cancer of the distal end of the bile duct, cancer of the ampulla of Vater, and cancer of the second part of the duodenum. Pancreatic cancer (pancreatic cancer) is the tenth most common cancer in the USA, the fifth most common cause of cancer-related mortality in the east and the fourth most common cause of cancer-related mortality in the west

([Parkin 2001](#); [Parkin 2005](#); [Yamamoto 1998](#)). In 2012, 338,000 new patients were diagnosed with pancreatic cancer and there were 330,000 deaths due to pancreatic cancer globally ([IARC 2014](#)). There is global variation in the incidence of pancreatic cancers, with an age-standardised annual incidence rate of 7.2 per 100,000 population in the more developed regions and an age-standardised annual incidence rate of 2.8 per 100,000 population in the less developed regions ([IARC 2014](#)). A similar trend is noted in the age-standardised annual mortality rates, of 6.8 per 100,000 population in the more developed regions and an age-standardised annual mortality rate of 2.7 per 100,000 population in the less

developed regions due to pancreatic cancer (IARC 2014).

Pancreaticoduodenectomy is the main treatment for cancers that arise in the head of the pancreas, ampulla, and second part of the duodenum. Surgical resection is generally considered the only treatment that can cure pancreatic cancer. However, only 15% to 20% of patients with pancreatic cancers undergo potentially curative resection (Conlon 1996; Engelken 2003; Michelassi 1989; Shahrudin 1997; Smith 2008). The overall five-year survival after radical resection ranges from 7% to 25% (Cameron 1993; Livingston 1991; Niederhuber 1995; Nitecki 1995; Orr 2010; Trede 1990), with a median survival of 11 to 15 months (British Management Guideline 2005). With adjuvant chemotherapy, the median survival after radical resection varies between 14 and 24 months (Liao 2013). In all other patients, the cancers are not resected because of infiltration of local structures, disseminated disease, or because the patient is deemed unfit to undergo major surgery. Computed tomography (CT) scan is generally used for staging pancreatic and periampullary cancers (National Cancer Institute 2014b). Despite undergoing routine CT scanning to stage the disease, a substantial proportion of patients (approximately 40%) undergo unnecessary laparotomy (opening the abdomen using a large incision) with lack of curative resectability identified only during the laparotomy (Allen 2016). Staging laparoscopy or diagnostic laparoscopy may decrease the proportion of patients that undergo unnecessary laparotomy to approximately 17% (Allen 2016). Tests, such as magnetic resonance imaging (MRI), positron emission tomography (PET) scan, or endoscopic ultrasound (EUS), may be used in addition to CT scan to assess resectability with curative intent and decrease the proportion of patients who undergo unnecessary laparotomy.

### Target condition being diagnosed

Inability to perform curative resectability of pancreatic and periampullary cancer (“unresectable” cancers)

### Index test(s)

#### MRI

MRI involves the use of a powerful magnet to produce images of different tissues of the body. This is also called nuclear MRI (NMRI) (National Cancer Institute 2014c). Features, such as extent of the cancer in terms of involvement of adjacent structures and spread of cancer to distant areas (metastases), are taken into

account to assess resectability with curative intent. The radiologist usually interprets the images.

#### PET

PET involves the use of a small amount of radioactive glucose (sugar) to differentiate between different tissues. It utilises the property that cancer cells often use more glucose than normal cells. It is also called PET scan (National Cancer Institute 2014d). This is a form of functional imaging. Cancerous lesions appear as areas of increased uptake. The presence of cancer in different locations and metastases are taken into account to assess resectability with curative intent. The radiologist usually interprets the images.

#### PET-CT scan

PET scan can be combined with CT scan (PET-CT scan), with both tests performed at the same time (National Cancer Institute 2014e). This allows superimposition of the two images by identifying corresponding points of the body in the two scans (coregistration) and allows the combination of the functional imaging (PET scan) with an anatomical imaging (CT scan), which may result in better diagnostic accuracy than either modality alone (National Cancer Institute 2014e). Usually, the radiologist interprets the images.

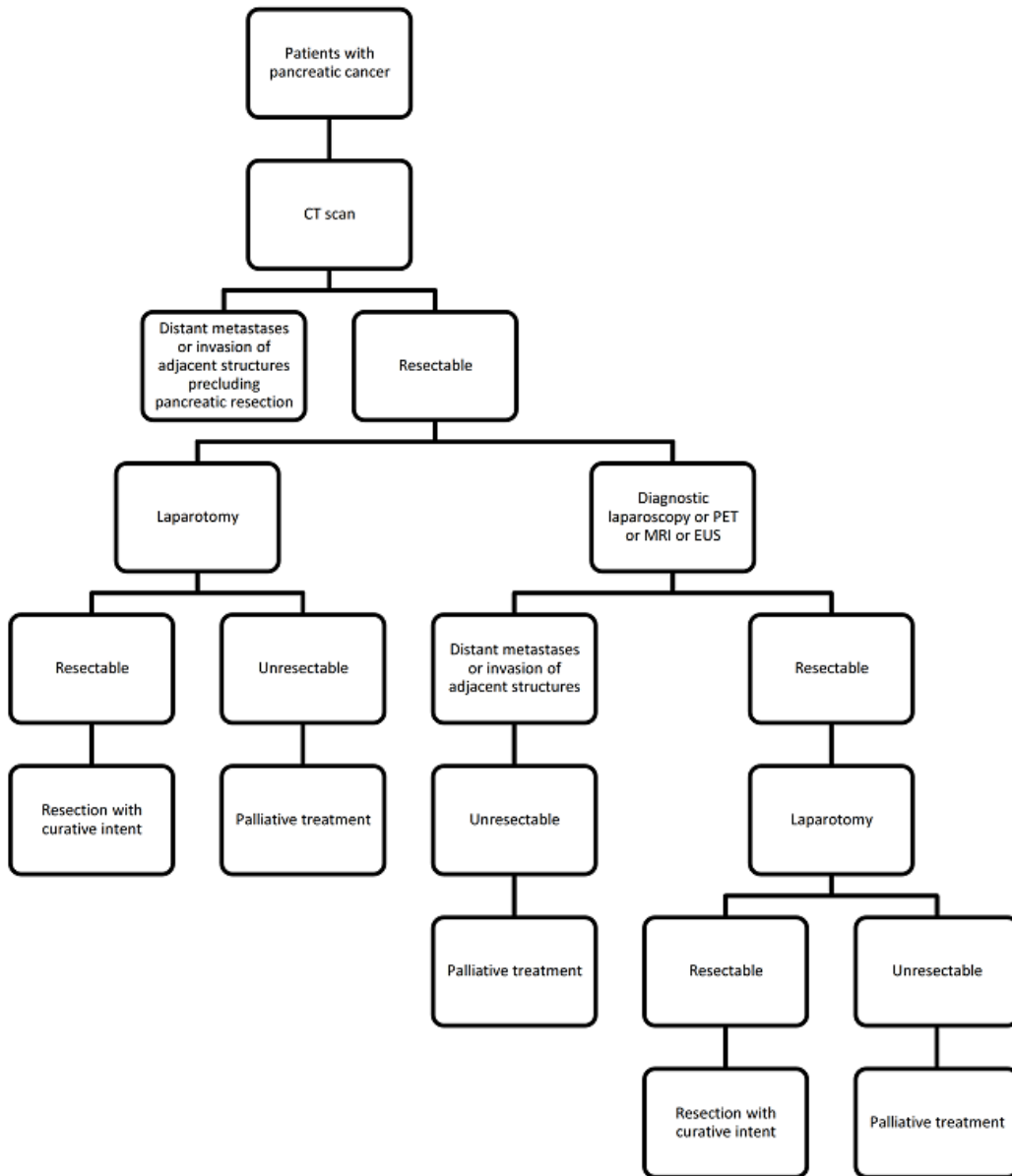
#### EUS

EUS involves the use of an endoscope, a camera introduced into the body cavities to view the inside of the body. An ultrasound (high-energy sound waves) probe at the end of the endoscope is used to differentiate different tissues. This is also called endosonography and EUS (National Cancer Institute 2014f). Local extent and metastases are taken into account to assess resectability with curative intent. The endoscopist usually interprets the images.

### Clinical pathway

There is no standard algorithm currently available to assess the resectability of pancreatic and periampullary cancers, with different clinicians following their own algorithms based on either their clinical experience or what they have been taught. Currently, almost all algorithms include a CT scan as one of the tests (National Cancer Institute 2014b). CT may be the only test performed before laparotomy. Other tests, such as diagnostic laparoscopy, PET (PET scan or PET-CT scan), MRI, or EUS, may be used in addition to CT scan to assess resectability. We have presented the possible clinical pathway in the staging of pancreatic cancers in Figure 1.

**Figure 1. Clinical pathway for the staging of pancreatic cancers.** Abbreviations: PET: positron emission tomography; MRI: magnetic resonance imaging; EUS: endoscopic ultrasound; CT: computed tomography.



### Prior test(s)

The minimum prior test should be CT and the cancer should be resectable with curative intent on the basis of the CT scan. Other imaging modalities, such as MRI, PET scan, PET-CT, or EUS, might be used in addition to CT scanning to assess resectability before performing the imaging modality being assessed.

### Role of index test(s)

MRI, PET scan, and EUS can be considered as add-on tests to the CT scan prior to laparotomy done with the intention of performing a potentially curative resection. PET-CT scan can be considered as a replacement for CT scan prior to laparotomy done with the intention of performing a potentially curative resection. It can also be considered as an add-on test to the CT scan prior to laparotomy. Although it appears strange to use PET-CT scan as an add-on test to CT scan, such an approach is possible if patients are referred to the referral centre with a CT scan. It should be noted that PET and CT scan should be performed simultaneously to allow coregistration. However, the problem with PET-CT scan as a replacement for CT scan is that PET-CT has to be performed without contrasts and hence PET-CT alone may not provide as good an information as PET-CT along with conventional CT scan.

### Alternative test(s)

Diagnostic laparoscopy or laparoscopic ultrasound may be used as an alternative test to these imaging modalities in patients considered to have CT resectable pancreatic and periampullary cancer (Allen 2016; Hariharan 2010). Another Cochrane review has assessed the accuracy of diagnostic laparoscopy (Allen 2016).

### Rationale

The different imaging modalities identify the extent of local spread, including invasion of adjacent blood vessels, and may identify distal metastases (MRI, PET scan, PET-CT scan). If this add-on test (or replacement test in the case of PET-CT scan in patients who are referred without a CT scan) can identify unresectable cancers without laparotomy, it might decrease the costs and morbidity associated with unnecessary laparotomy. Currently there is no Cochrane review that has assessed the diagnostic accuracy of these imaging modalities in the assessment of the curative resectability of pancreatic and periampullary cancers.

To determine the diagnostic accuracy of MRI, PET scan, and EUS performed as an add-on test or PET-CT as an add-on or replacement test to CT scanning in detecting curative resectability in pancreatic and periampullary cancer.

### Secondary objectives

We planned to explore the following sources of heterogeneity.

1. Studies at low risk of bias versus those at unclear or high risk of bias (as assessed by the QUADAS-2 tool, recommended by the Cochrane Diagnostic Test Accuracy Group) (Whiting 2006; Whiting 2011).
2. Full text publications versus abstracts (this can give a clue about publication bias since there may be an association between the results of the study and the study reaching full publication status) (Eloubeidi 2001).
3. Prospective studies versus retrospective studies.
4. Proportion of patients with pancreatic cancer, ampullary cancer, and duodenal cancers (although classified as periampullary cancers they each have a different prognosis) (Klempnauer 1995). The additional value of the imaging modalities may be different because of the extent of spread in these different types of periampullary cancers.
5. Different definitions for resectable cancer on laparotomy. Different surgeons may consider cancer unresectable differently i.e. different surgeons would have different criteria for unresectability on laparotomy (other than the consensus criteria for resectability). For example, one surgeon may judge that the cancer is unresectable on laparotomy because of the involvement of the local vessels (mainly portal vein and superior mesenteric vein) and consider the reference standard to be positive. This would result in a false negative result for the imaging modality. Another surgeon may judge the same cancer to be resectable despite the involvement of the vessel and proceed with resection. The reference standard would be negative in this situation, which would result in a true negative result for the imaging modality. This might have an intrinsic threshold effect.
6. Additional pre-tests performed (besides CT scan). This can alter the pre-test probability of unresectability and can help in the assessment of the additional value of the imaging modality under various situations.

## METHODS

### Criteria for considering studies for this review

## OBJECTIVES



## Types of studies

We only included studies that provided diagnostic test accuracy data (true positive, false positive, false negative, and true negative) on the different imaging modalities mentioned above in the appropriate patient population (see below) irrespective of language, publication status, or whether data were collected prospectively or retrospectively. However, we excluded case reports which do not provide sufficient diagnostic test accuracy data. We also planned to exclude any identified case-control studies because case-control studies are prone to bias (Whiting 2011).

## Participants

Adults considered for curative resection of pancreatic or periampullary cancer on the basis of CT findings, who were fit to undergo major surgery. We included patients in this review irrespective of whether they underwent other imaging modalities prior to imaging modality being assessed.

## Index tests

MRI, PET scan, PET-CT scan, or EUS.

## Target conditions

The target conditions were unresectable pancreatic and periampullary cancers, that is, we considered the imaging modality a positive test if the pancreatic or periampullary cancer is unresectable with curative intent. In these cancers it is not possible to perform curative resectability. Clinically, it may not be easy to distinguish head of pancreas cancers, ampullary cancers, and cancer of the second part of the duodenum. The treatment for these different cancers is the same, i.e. pancreatoduodenectomy and the final confirmation as to the origin of these cancers may be done after resection without definitive diagnosis of the origin of the cancer, as long as the cancers are resectable. So we considered these cancers together. There are no uniform criteria for resectability of pancreatic and periampullary cancer. Consensus exists for the definition of borderline resectable cancers (Abrams 2009). Therefore, where there is less tissue involvement than in a borderline resectable cancer the tumour can be considered as resectable. We accepted any criteria of resectability used by the study authors and acknowledge that this could potentially create a threshold effect. In general, the cancer will not be resected if liver, peritoneal, or distal nodal metastases were noted, or if the cancer had invaded important adjacent blood vessels that are beyond the criteria for borderline resectable cancers (for example, greater than 180° involvement of the superior mesenteric artery) (Abrams 2009).

## Reference standards

Confirmation of liver, peritoneal, or nodal metastatic involvement by histopathological examination of suspicious (liver, peritoneal,

or nodal metastatic) lesions obtained at diagnostic laparoscopy or laparotomy. We accepted only paraffin section histology as the reference standard. In clinical practice, depending on the urgency of the results, a frozen section biopsy may be done to obtain immediate results. However, this is always confirmed by subsequent paraffin section histology (which can take several days) because frozen section biopsy is not as reliable as paraffin section histology. We also accepted the surgeon's judgement of unresectability at laparotomy when biopsy confirmation was not possible as an alternate reference standard. For example, if the tumour has invaded the adjacent blood vessels the surgeon may not resect the tumour because of the danger posed by resecting part of a large blood vessel, and so biopsy confirmation cannot be obtained. However, it should be noted that a surgeon's judgement of unresectability at laparotomy is a subjective decision and is a possible source of error in the reference standard. In the absence of an ethical and true gold standard, we accepted this as a reference standard.

## Search methods for identification of studies

We included all studies irrespective of the language of publication and publication status. We translated any non-English articles we found to assess eligibility.

## Electronic searches

We searched the following databases on 5 November 2015.

1. MEDLINE (In-Process & Non-Indexed Citations) via OvidSP (January 1946 to 5 November 2015; Appendix 2).
2. Embase via OvidSP (January 1947 to 5 November 2015; Appendix 3).
3. Science Citation Index Expanded (including Conference Proceedings Citation Index - Science) via Web of Knowledge (January 1980 to 5 November 2015; Appendix 4).
4. National Institute for Health Research - Health Technology Assessment (NIHR HTA) (November 2015) through the University of York Centre for Reviews and Dissemination ([www.crd.york.ac.uk/CRDWeb/](http://www.crd.york.ac.uk/CRDWeb/)) (Appendix 5).

We included sensitivity maximising diagnostic filters for searching MEDLINE and Embase databases (Haynes 2004; Wilczynski 2005). This is because we retrieved more than 40,000 references when we used the original searches without the filters.

## Searching other resources

We searched the references of the included studies to identify additional studies. We also searched for articles related to the included studies by performing the "related search" function in MEDLINE (OvidSP) and Embase (OvidSP) and a "citing reference" search (by searching the articles which cite the included articles) (Sampson 2008) in Science Citation Index Expanded, MEDLINE (OvidSP), and Embase (OvidSP).

## Data collection and analysis

### Selection of studies

Two review authors (DT and KSG) independently screened the results of the search strategy to identify relevant studies. We obtained the full-text articles of references that at least one of the review authors considered relevant. Two review authors (DT and KSG or DR) independently screened the full-text papers against the inclusion criteria. We did not have any differences in study selection based on our full-text article assessments. If the eligibility of the report was unclear, we attempted to contact the study authors to seek clarification. Since we were unable to contact the study authors, we excluded the reports. We listed all excluded studies and their reasons for exclusion in the [Characteristics of excluded studies](#) table). Also, we constructed a PRISMA diagram to illustrate the study selection process.

### Data extraction and management

Two review authors (DT and KSG) independently extracted the following data from each included study using a data extraction form that KSG designed and piloted. We resolved any differences by discussion.

1. First author.
2. Year of publication.
3. Study design (prospective or retrospective; cross-sectional studies or randomised controlled trials).
4. Inclusion and exclusion criteria for individual studies.
5. Total number of patients.
6. Number of females.
7. Average age of the participants.
8. Type of cancer (i.e. head and neck of pancreas, body and tail of pancreas, ampullary cancers, duodenal cancer).
9. Criteria for unresectability at the index test and at laparotomy (reference standard).
10. Preoperative tests carried out prior to index test.
11. Description of the index test.
12. Reference standard.
13. Number of true positives, false positives, false negatives, and true negatives.

The unit of analysis was the patient, meaning that if multiple metastases or multiple infiltrations of adjacent structures were found in a patient with a negative index test, we planned to consider the number of false negatives to be one. This is because it is the presence, rather than the number of metastases or the number of infiltrations of adjacent structures, that is important in determining the curative resectability of patients. We planned to consider patients with uninterpretable index test results (no matter the reason given for lack of interpretation) as negative for the test since in clinical practice laparotomy would be carried out on these patients. However, we planned to include such patients in the

analysis only if the results of laparotomy were available. We sought further information from the study authors if necessary.

If the same study reported multiple index tests, we planned to extract the number of true positives, false positives, false negatives, and true negatives for each index test. If there was an overlap of participants between multiple reports as suspected by common authors and centres, we planned to contact the study authors to seek clarification about the overlap. If we were unable to contact the authors, we planned to extract the maximum possible information from all the reports. However, we did not find any such reports.

### Assessment of methodological quality

Two review authors (DT and KSG) independently assessed study quality using the QUADAS-2 assessment tool ([Whiting 2006](#); [Whiting 2011](#)). We resolved differences through discussion, based on the criteria published in the protocol ([Gurusamy 2015](#)). We have presented the criteria that we used to classify the different studies in [Table 1](#). We considered studies which are classified as “low risk of bias” and “low concern” in all the domains as studies with high methodological quality. We planned to present the results in a “Risk of bias” summary and graphs, but because there were only two studies, we have presented the “Risk of bias” summary only.

### Statistical analysis and data synthesis

We plotted study estimates of sensitivity and specificity on forest plots and in receiver operating characteristic (ROC) space to explore between study variation in the performance of each test. To estimate the summary sensitivity and specificity of each test, we planned to perform the meta-analysis by fitting the bivariate model ([Chu 2006](#); [Reitsma 2005](#)). This model accounts for between-study variability in estimates of sensitivity and specificity through the inclusion of random effects for the logit sensitivity and logit specificity parameters of the bivariate model. If sparse data results in unreliable estimation of the covariance matrix of the random effects (as indicated by very large variance of logit sensitivity and specificity or if there was lack of convergence), we tried other alternate models including the random-effects model, ignoring the inverse correlation between sensitivities and specificities in the different studies due to intrinsic threshold effect, and the fixed-effect model for either sensitivity or specificity or both after visualising the forest plots and summary receiver operating characteristics (SROC) plots ([Takwoingi 2015](#)). We based our choice between the different models on the distribution of sensitivities and specificities as noted in the forest plots or ROC space. We also planned to use the model fit as indicated by the  $-2$  log likelihood and planned to consider the model with the lower  $-2$  log likelihood to be the better model.

We planned to compare the diagnostic accuracy of the tests by including covariate terms for test type (MRI, PET, PET-CT, or

EUS) in the bivariate model to estimate differences in the sensitivity and specificity of the tests. We planned to allow both the sensitivity and specificity to vary by covariate. In addition, we also planned to permit the variances of the random effects and their covariance to also depend on test type thus allowing the variances to differ between tests. We planned to use likelihood ratio tests to compare the model with and without covariate (test type). We planned to use a P value of less than 0.05 for the likelihood ratio test to indicate differences in the diagnostic accuracy between the tests. If studies that reported different tests in the same study population were available from at least four studies, we planned to perform a direct head-to-head comparison by limiting the test comparison to such studies. We planned to calculate the relative sensitivities and specificities for each pairwise comparison of tests. We performed the meta-analysis using the NLMixed command in SAS version 9.3 (SAS Institute Inc, Cary, North Carolina, USA). We created a graph of pre-test probabilities (using the observed median and range of prevalence from the included studies) against post-test probabilities. We calculated the post-test probabilities using these pre-test probabilities and the summary positive and negative likelihood ratios. We calculated the summary likelihood ratios and their confidence intervals (CIs) from the functions of the parameter estimates from the model that we fitted to estimate the summary sensitivities and specificities. Post-test probability associated with positive test is the probability of having the target condition (unresectability) on the basis of a positive test result (unresectable disease) and is the same as the term “positive predictive value” used in a single diagnostic accuracy study. Post-test probability associated with a negative test is the probability of having the target condition (unresectability) on the basis of a negative test result (resectable disease) and is  $1 -$  “negative predictive value”. Negative predictive value is the term used in a single diagnostic accuracy study to indicate the chance that the patient has no target condition when the test is negative. We planned to report the summary sensitivity, specificity, positive and negative likelihood ratios, and post-test probabilities for the median, lower quartile, and upper quartile of the pre-test probabilities.

### Investigations of heterogeneity

We planned to explore heterogeneity by using the different sources of heterogeneity as covariate(s) in the hierarchical summary receiver operating characteristics (HSROC) model. Of the six sources of heterogeneity we listed in the [Secondary objectives](#) sec-

tion, we planned to deal with all items other than proportion of patients with pancreatic cancer, ampullary cancer, and duodenal cancer as categorical covariates. We planned to use the proportion of patients with pancreatic cancer, ampullary cancer, and duodenal cancer as continuous covariates in the regression model. We planned to employ likelihood ratio tests to compare the model with and without covariate. We planned to use a P value of less than 0.05 for the likelihood ratio test to indicate that the covariate was a potential source of heterogeneity.

### Sensitivity analyses

We did not plan to perform any sensitivity analyses except when the data available from the studies was ambiguous (for example, the numbers in the text differed from the numbers in the figures), in which case we planned to assess the impact of different data used by a sensitivity analysis.

### Assessment of reporting bias

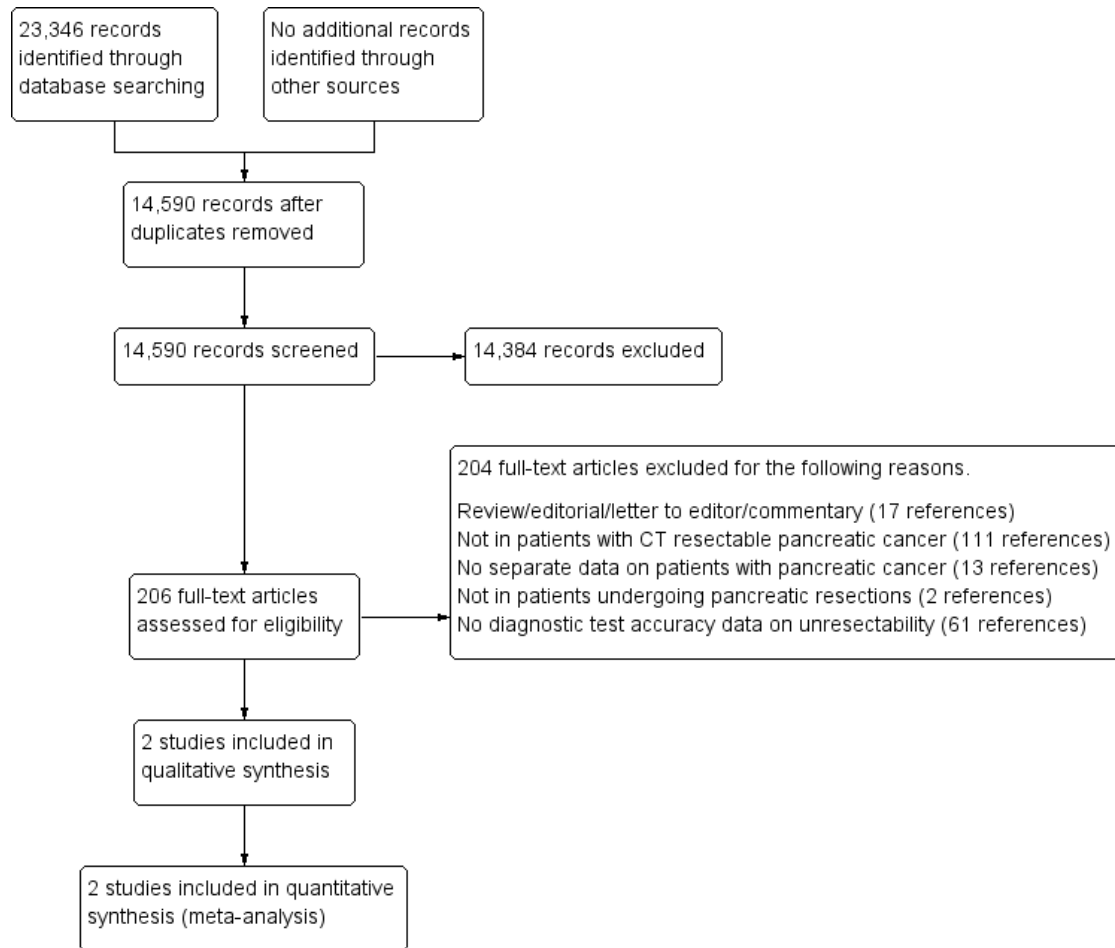
We planned to investigate whether the summary sensitivity and specificity differed between studies published as full texts and those available only as abstracts using the methods we described in the [Investigations of heterogeneity](#) section.

## RESULTS

### Results of the search

We identified a total of 23,346 references through electronic searches of MEDLINE (OvidSP; N = 9763), Embase (OvidSP; N = 8097), Science Citation Index expanded (Web of Knowledge; includes Conference Proceedings Citation Index- Science; N = 5412), and HTA ([Centre for Reviews and Dissemination](#); (N = 74). After we removed duplicate references, there were 14,590 articles remaining. We excluded 14,384 clearly irrelevant references through reading abstracts. We retrieved the full-text publication of 206 references for further detailed assessment. We excluded 204 references for the reasons in the [Characteristics of excluded studies](#) section. Two diagnostic accuracy studies (two references) fulfilled the inclusion criteria (see the [Characteristics of included studies](#) section). We have presented a study flow diagram in [Figure 2](#).

**Figure 2. Study flow diagram.**



### Included studies

Two studies with small sample sizes met the inclusion criteria. One study was a prospective study (Ahmad 2001), while the other was a retrospective study (Ardengh 2003). These two studies included a total of 38 participants with pancreatic cancer. Ardengh 2003 included 17 participants and Ahmad 2001 included 21 participants. The mean age of the participants in the two trials was 61 years and 64 years respectively (Ahmad 2001; Ardengh 2003). The proportion of females in the two trials was 23.8% and 64.7% respectively (Ahmad 2001; Ardengh 2003). The prevalence of unresectability (pre-test probability) was 0.529 in Ardengh 2003 and 0.667 in Ahmad 2001.

The tests that participants underwent prior to endoscopic ultrasound (EUS) were cross-sectional imaging (CT scan in all patients and ultrasound in some patients depending upon the referral centre) in Ahmad 2001, and CT scan and ultrasound in

Ardengh 2003 (on people undergoing pancreatic resection after an ultrasound and a CT scan). Both studies evaluated endoscopic ultrasound (EUS) as the index test. The reference standard was surgeon's judgement of unresectability in both studies. In Ahmad 2001, this was vascular invasion during laparotomy, while Ardengh 2003 did not report the criteria that the surgeon used for assessing unresectability during laparotomy.

We have provided the methodological quality of the included studies in the [Methodological quality of included studies](#) section.

### Excluded studies

We excluded a total of 204 references for the following reasons.

1. Seventeen studies were not primary studies (Barthet 2007; Brugge 1995; Faigel 1996; Fockens 1993; Freeny 2001; García-Cano 2002; Gaspar 2015; Goh 2006; Lévy 2001;

Malfertheiner 2005; Neoptolemos 2005; Pappas 2011; Rösch 1992c; Shin 2013; Snady 1993; Wang 2007a; Wiersema 2000).

2. We excluded 111 studies because participants were not patients with CT resectable pancreatic cancer (Abe 2010; Ahmad 1999; Ahmad 2000a; Ahmad 2000c; Ahmad 2000d; Akahoshi 1998; Anand 2013; Aubertin 1996; Awad 1997; Baair 1998; Bao 2008; Bettini 2005; Broglia 2001; Burge 2015; Carroll 1999; Catalano 1997; Catalano 1998; Chandler 1999; Chhibber 2006; Chiang 2014; Cieslak 2014; Crippa 2013; Crippa 2014; DeWitt 2004; Egorov 2012; Einersen 2013; Farma 2008a; Fischer 2002; Frohlich 1999; Grenacher 2004; Lopez-Hänninen 2002; Hochwald 1999; Howard 1997; Hu 2015; Ichikawa 1997; Iglesias-Garcia 2010; Imazu 2010; Izuishi 2010; Javery 2013; Jemaa 2008; Kala 2007; Karoumpalis 2011; Kim 2001; Kim 2012; Koelblinger 2011; Koranda 2009; Koranda 2010; Kulig 2004; Kysucan 2010; Latronico 2005; Lee 2002; Lee 2010; Lentschig 1996; Makowiec 2000; Maluf-Filho 2004; Mansfield 2008; McFarland 1996; Megibow 1995; Melzer 1996; Mertz 2000; Motosugi 2011; Mukai 1991; Murakami 1996; Nakamoto 1999; Napolitano 2002; Nishiharu 1999; Palazzo 1993; Park 2009; Patel 2002a; Patel 2002b; Paul 2012; Ramsay 2004; Razzaque 2012; Reiser-Erkan 2009; Reiser-Erkan 2010; Ren 2006; Riditid 2015; Rivadeneira 2003; Romijn 2000; Rösch 1992a; Rösch 1992b; Schmidt 2004; Schwarz 2001; Seicean 2008; Shami 2011; Sheng 2012; Smedby 1997; Solodinina 2014b; Soriano 2001; Soriano 2004; Strobel 2008; Tapper 2010; Tian 2008a; Tian 2008b; Tian 2008c; Tierney 2001; Tio 1986; Tio 1988; Tio 1990; Tomić 2005; Trede 1997; Turowska 2009; Valinas 2002; Wakabayashi 2008; Wang 2007b; Wang 2015; Warshaw 1990; Woerlein 2002; Younes 1999; Yusoff 2003; Zhong 2005).

3. Thirteen studies had no separate data on patients with pancreatic cancer (Arabul 2012; Buchs 2007; Casneuf 2007; Cieslak 2012; Cieslak 2013; Dewitt 2003; Ho 2008; Lu 2006; Lytras 2005; Pan 2014; Schima 2002; Takaori 2007; Tomazic 2000).

4. Two studies were not conducted in patients undergoing

pancreatic resections (Agarwal 2005; Xu 2014).

5. In 61 studies diagnostic accuracy data on unresectability was unavailable (Ahmad 2000b; Arslan 2001; Artifon 2009; Asagi 2013; Aslanian 2005; Baghbanian 2014; Brugge 1996; Buscall 1999; Cahn 1996; Chang 1997; Chen 2001a; Chen 2001b; Chen 2009; Chiang 2012; Costilla 2011; Croome 2010; Czako 2009; Delbeke 1999; Egorov 2013; Einersen 2014; Eloubeidi 2006; Eloubeidi 2007; Erickson 2000; Farma 2008b; Gress 1999; Gress 1999; Harrison 1999; Heinrich 2005; Helmreich 2004; Hemmingsson 1982; Hirokawa 2010; Holzapfel 2011; Kadish 1995; Kim 2015; Lakhtakia 2011; Mehmet 2006; Morris-Stiff 2011; Prithviraj 2013; Raj 2013; Rösch 2000; Saif 2008; Shoup 2000; Sironi 1995; Sironi 1996; Skordilis 2002; Snady 1994; Solodinina 2014a; Spencer 1998; Staib 1997; Takayama 2009; Tellez-Avila 2012; Tio 1996; Wang 2008; Wang 2014; Wee 2012; Yao 2012; Yasuda 1988; Yasuda 1993; Yoneyama 2014; Zhang 2012; Zhang 2015).

### Methodological quality of included studies

We have summarised the risk of bias and applicability concerns in the included studies in Figure 3. As shown in Figure 3, there were no applicability concerns in the included studies. However, the risk of bias in the “patient selection” was high in Ardengh 2003 since it excluded pancreatic cancers that were 3 cm or more in diameter. The risk of bias in this domain was low in Ahmad 2001. The risk of bias in the “index test” domain was unclear in Ardengh 2003 since it was unclear whether the index test results were interpreted without knowledge of the results of the reference standard. The risk of bias in this domain was low in Ahmad 2001. As anticipated, both studies used surgeons’ judgement on unresectability as the reference standard and so both studies were at unclear risk of bias in the “reference standard” domain. Ardengh 2003 did not report the interval between EUS and surgery and the participant flow. We considered this study to be at unclear risk of bias in the “flow and timing” domain. The risk of bias in this domain was low in Ahmad 2001.

**Figure 3. Risk of bias and applicability concerns summary: review authors' judgements about each domain for each included study.**

	<u>Risk of Bias</u>				<u>Applicability Concerns</u>		
	Patient Selection	Index Test	Reference Standard	Flow and Timing	Patient Selection	Index Test	Reference Standard
Ahmad 2001	+	+	?	+	+	+	+
Ardengh 2003	-	?	?	?	+	+	+

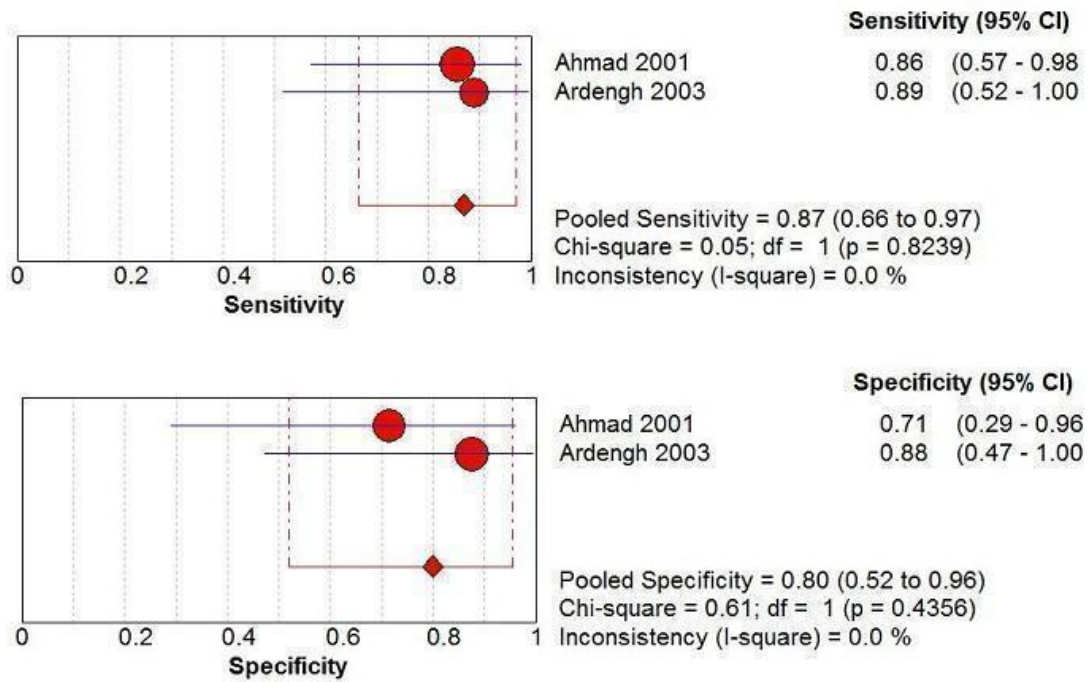
  

<b>- High</b>	<b>? Unclear</b>	<b>+ Low</b>
---------------	------------------	--------------

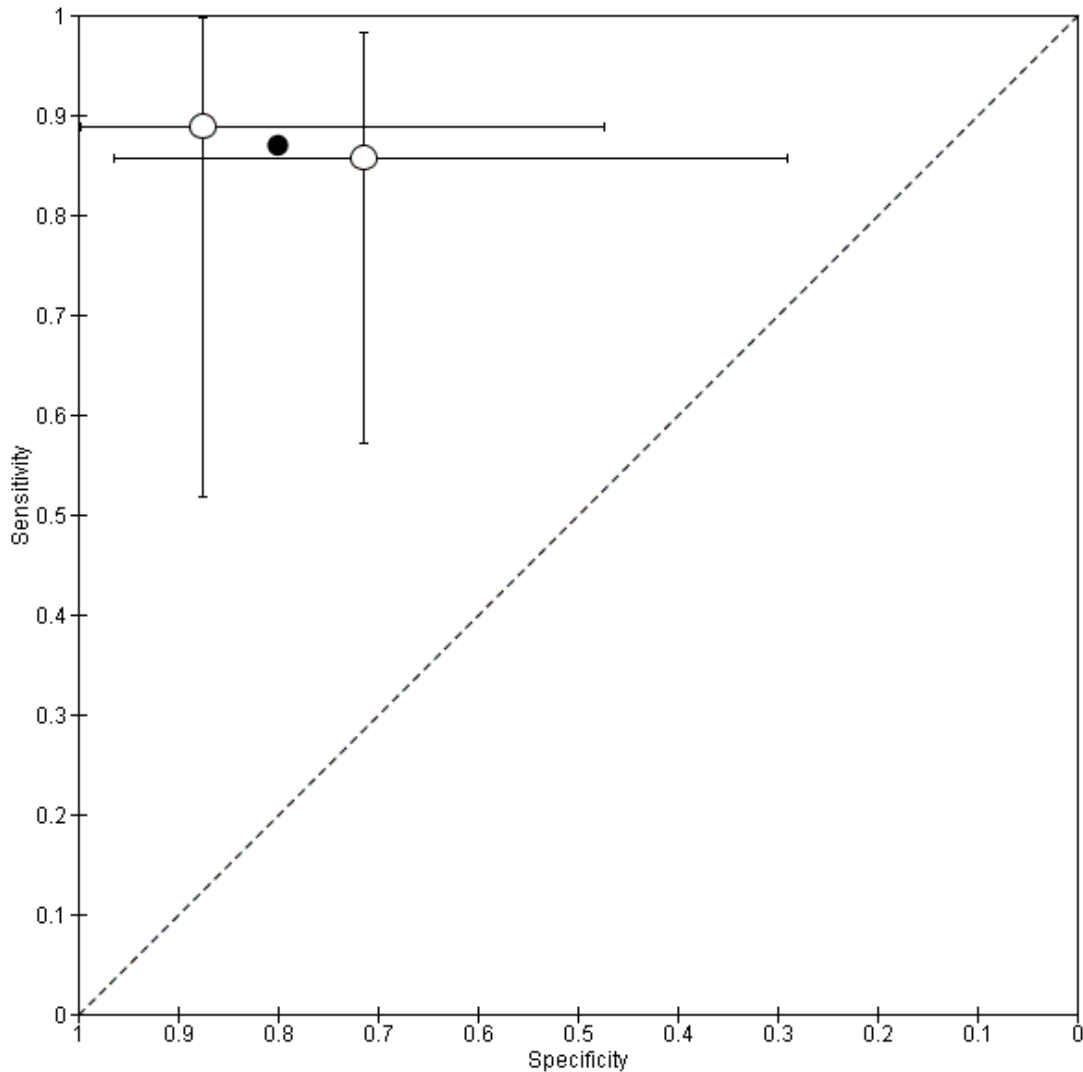
### Findings

There was no heterogeneity in sensitivity as shown by very good overlap of confidence intervals (CIs) in the forest plots, visualisation of the receiver operating characteristic (ROC) plot, and by the values of sensitivity which were almost identical (0.86 in Ahmad 2001 versus 0.89 in Ardengh 2003) (Figure 4; Figure 5). Although we planned to evaluate the use of univariate random-effects model for specificity based on the forest plots (there was good overlap of CIs but the difference in point estimate was more with specificity than sensitivity: 0.71 in Ahmad 2001 versus 0.88 in Ardengh 2003) and ROC plot, the only model that converged was univariate fixed-effect model for both sensitivity and specificity. So, we were unable to choose the best model by comparing the  $-2 \log$  likelihood.

**Figure 4. Pooled sensitivity and specificity of endoscopic ultrasound for assessing the resectability with curative intent in pancreatic and periampullary cancer.** Abbreviations: df: degrees of freedom.



**Figure 5. Summary ROC Plot of endoscopic ultrasound for assessing the resectability of pancreatic and periampullary cancer.**



The summary estimate of sensitivity for unresectability was 0.87 (95% CI 0.54 to 0.97) and the summary estimate of specificity for unresectability was 0.80 (95% CI 0.40 to 0.96). The positive likelihood ratio and negative likelihood ratio were 4.3 (95% CI 1.0 to 18.6) and 0.2 (95% CI 0.0 to 0.8) respectively. Although we planned to calculate the post-test probabilities using the median and quartiles of the pre-test probabilities, we calculated the post-test probabilities using the mean and range of the pre-test probabilities because of the inclusion of two studies only. The mean pre-test probability was 60.5%. At this pre-test probability, the post-

test probability of unresectable disease for people with a positive EUS (EUS indicating unresectability) was 86.9% (95% CI 60.9% to 96.6%) and the post-test probability of unresectable disease for people with a negative EUS (EUS indicating resectability) was 20.0% (5.1% to 53.7%). This means that 13% of people (95% CI 3% to 39%) with positive EUS have potentially resectable cancer and 20% (5% to 53%) of people with negative EUS have unresectable cancer. The “Summary of findings” table shows the post-test probability of unresectable disease at different pre-test probabilities of unresectable disease ([Summary of findings](#)).



Neither of the included studies reported any complications related to EUS. We did not perform any investigation of heterogeneity because only two studies met the inclusion criteria of this review.

## Summary of findings

<b>Population</b>	People with pancreatic cancer found to resectable on computed tomography (CT) scan	
<b>Setting</b>	Secondary or tertiary setting	
<b>Index test</b>	Endoscopic ultrasound (EUS)	
<b>Reference standard</b>	Laparotomy (surgeon's judgement of unresectability)	
<b>Number of studies</b>	2 studies (38 participants)	
<b>Summary sensitivity</b>	0.87 (95% confidence interval (CI) 0.54 to 0.97)	
<b>Summary specificity</b>	0.80 (95% CI 0.40 to 0.96)	
<b>Consistent results</b>	Yes	
<b>Overall risk of bias</b>	Moderate to high	
<b>Other limitations</b>	<ol style="list-style-type: none"> <li>1. Both studies included pancreatic cancers only.</li> <li>2. One study included only participants with pancreatic cancer less than 3 cm.</li> <li>3. We could only perform the univariate fixed-effect model and we were unable to compare the model fit with other models.</li> </ol>	
<b>Pre-test probability of unresectability from included studies</b>	<b>Post-test probability of unresectability in people with positive EUS (EUS indicating unresectability) (95% CI)</b>	<b>Post-test probability of unresectability in people with negative EUS (EUS indicating resectability) (95% CI)</b>
<b>Minimum = 53%</b>	83% (53% to 95%)	16% (4% to 46%)
<b>Mean = 61%</b>	87% (61% to 97%)	20% (5% to 54%)
<b>Maximum = 67%</b>	90% (67% to 97%)	25% (7% to 61%)
<b>Interpretation</b>	There is significant uncertainty in the results because of inadequate data	

We reported all probabilities in the table as percentages.

Abbreviations: CI: confidence interval; EUS: endoscopic ultrasound.

## DISCUSSION

### Summary of main results

Only two studies (38 participants) that evaluated the diagnostic accuracy of EUS in people with CT-resectable pancreatic cancers met the inclusion criteria of this review. The summary estimate of sensitivity was 0.87 (95% CI 0.54 to 0.97) and the summary estimate of specificity was 0.81 (95% CI 0.40 to 0.96). The positive likelihood ratio and negative likelihood ratio were 4.3 (95% CI 1.0 to 18.6) and 0.2 (95% CI 0.0 to 0.8) respectively. At the mean pre-test probability in included studies (60.5%), the post-test probability of unresectable disease for people with a positive EUS (EUS indicating unresectability) was 86.9% (95% CI 60.9% to 96.6%) and the post-test probability of unresectable disease for people with a negative EUS (EUS indicating resectability) was 20.0% (5.1% to 53.7%).

Direct laparotomy after CT resulted in approximately 60% of cancers being unresectable, which appears to be higher than the usual unresectability rates after CT scan of around 30% to 40% (Allen 2016). We are unable to identify why the pre-test probability of unresectability was high in these centres which are specialist centres, considering that they have facilities to perform EUS. When the EUS indicates that the pancreatic cancer is not resectable although CT scan shows that pancreatic cancer is resectable (EUS positive in CT resectable pancreatic cancer), approximately 13% of people (95% CI 3% to 39%) had resectable pancreatic cancer. Since pancreatic resection is the only potentially curative option for pancreatic cancer, omission of laparotomy and resection in these people can have a major negative impact on their survival. We were unable to assess the diagnostic accuracy of MRI, PET, PET-CT and compare their diagnostic accuracy with EUS since none of the studies on MRI or PET were on CT resectable pancreatic cancers and none of the studies on PET-CT indicated the added value of PET clearly.

### Strengths and weaknesses of the review

We used formal search strategies and reported this, so that it is possible to independently verify our results. Two review authors independently identified studies and extracted data, thereby minimising human error in the selection of studies and data extraction. We reached agreement based on the information available in the protocol of this review (Gurusamy 2015). The methodological quality in one included study was as good as can be achieved ethically (Ahmad 2001), and the methodological quality in the second included study was mostly unclear (Ardengh 2003). There were no concerns about applicability in either study. There was no heterogeneity in the diagnostic test accuracy between the studies as indicated by the almost identical sensitivities and good overlap of CIs for specificities. These are the major strengths of this review.

The major limitation of this review was the paucity of data: only two studies met the inclusion criteria and both these studies were on EUS. We had to use univariate fixed-effect models for both sensitivity and specificity since this was the only model that converged. Such models may give reliable and stable results if used in the appropriate situation (Takwoingi 2015). Although we would have liked to compare the model fit of the univariate fixed-effect models that we performed with the model fit of univariate random-effects model for at least specificity, this was not possible because convergence was obtained only for univariate fixed-effect models for both sensitivity and specificity. However, our decision is vindicated to a certain extent by the almost identical sensitivity and good overlap of CIs for specificity and the  $I^2$  statistic values of 0% for both sensitivity and specificity. The alternative was to present the results of studies individually, which would have negated the advantage of meta-analysis, i.e. improved precision, particularly when there was no heterogeneity in the results between the two studies.

Another limitation of this review is that we included sensitivity maximising diagnostic filters for searching MEDLINE and Embase databases (Haynes 2004; Wilczynski 2005). This is because the original searches without the filters retrieved more than 40,000 references. We had to balance the possibility of missing some studies against the risk of being unable to complete the review. We decided that it would be more useful to have evidence from major studies rather than having no information at all. Notably, the diagnostic filters we used have a sensitivity of 98.6% for MEDLINE and 100% for Embase. So, the chances of us missing some relevant diagnostic studies are extremely low. We reduced this further by performing a “related search” and “citing reference search” in which we did not find any studies that we could include in this review.

This is the first systematic review on the topic. EUS is not routinely performed to assess resectability of pancreatic cancers in most centres and the findings from our review would suggest that there is insufficient evidence of clinical benefit to justify its inclusion in the standard diagnostic algorithm.

### Applicability of findings to the review question

The findings of this review are applicable only to people with pancreatic cancer who were found to be resectable after a CT scan. In addition, all the participants included in this review underwent laparotomy; so the findings of this review are applicable only in those who are fit to withstand major surgery. This review assessed the diagnostic accuracy of EUS in assessing the resectability of pancreatic cancer and does not provide the diagnostic accuracy of EUS in diagnosis of pancreatic cancer or finding the tumour, node, and metastasis (TNM) staging of pancreatic cancer.

## AUTHORS' CONCLUSIONS

### Implications for practice

Based on two small studies, there is significant uncertainty in the utility of endoscopic ultrasound (EUS) in people with pancreatic cancer found to have resectable disease on computed tomography (CT) scan. No studies have assessed the utility of EUS in people with periampullary cancer.

There is no evidence to suggest that it should be performed routinely in people with pancreatic cancer or periampullary cancer found to have resectable disease on CT scan.

### Implications for research

1. Well-designed diagnostic test accuracy studies are needed to reliably estimate the accuracy of diagnostic laparoscopy in people with pancreatic and periampullary cancers. Comparison of different imaging modalities with each other and with diagnostic laparoscopy and laparoscopic ultrasound may further demonstrate the value of the different imaging tests in staging pancreatic and periampullary cancers.

2. The conclusion of this systematic review needs regular review as the quality of CT scanning improves and the different imaging tests should be compared with each other and diagnostic laparoscopy and laparoscopic ultrasound in staging pancreatic and periampullary cancers.

3. Cost-effectiveness studies should be undertaken to determine whether EUS alone for EUS-negative CT resectable pancreatic cancer and EUS plus diagnostic laparoscopy for EUS-positive CT resectable pancreatic cancer should be routinely performed in state funded clinical practice.

## ACKNOWLEDGEMENTS

We thank the Cochrane Upper Gastrointestinal and Pancreatic Diseases Group, the UK Support Unit for Diagnostic Test Accuracy (DTA) Reviews, the DTA editorial team, the peer reviewers, and the copy editors for their advice in the preparation of this review.

## REFERENCES

### References to studies included in this review

#### Ahmad 2001 *{published data only}*

Ahmad NA, Kochman ML, Lewis JD, Kadish S, Morris JB, Rosato EF, et al. Endosonography is superior to angiography in the preoperative assessment of vascular involvement among patients with pancreatic carcinoma. *Journal of Clinical Gastroenterology* 2001;**32**(1):54–8.

#### Ardengh 2003 *{published data only}*

Ardengh JC, de Paulo GA, Ferrari AP. Pancreatic carcinomas smaller than 3.0 cm: endosonography (EUS) in diagnosis, staging and prediction of resectability. *HPB* 2003;**5**(4):226–30.

### References to studies excluded from this review

#### Abe 2010 *{published data only}*

Abe S, Takamori H, Tanaka H, Akaboshi S, Nakahara O, Ida S, et al. Preoperative detection of liver metastases secondary to pancreatic cancer: utility of gadolinium-ethoxybenzyl-diethylenetriamine pentaacetic acid-enhanced magnetic resonance imaging (Gd-EOB-DTPA-enhanced MRI). *Pancreatology* 2010;**10**:74–5.

#### Agarwal 2005 *{published data only}*

Agarwal B, Gogia S, Eloubeidi MA, Correa AM, Ho L, Collins BT. Malignant mediastinal lymphadenopathy detected by staging EUS in patients with pancreaticobiliary cancer. *Gastrointestinal Endoscopy* 2005;**61**(7):849–53.

#### Ahmad 1999 *{published data only}*

Ahmad NA, Ginsberg GG, Lewis JD, Rosato EF, Kochman ML. Endoscopic ultrasound and magnetic resonance

imaging staging as predictors of curative resection in patients with pancreatic adenocarcinoma. *Gastrointestinal Endoscopy* 1999;**49**(4):AB85.

#### Ahmad 2000a *{published data only}*

Ahmad NA, Lewis JD, Gineberg GG, Morris JB, Rosato EF, Kochman ML. Endoscopic ultrasound in the preoperative staging of pancreatic cancer. *Gastrointestinal Endoscopy* 2000;**51**(4):AB165.

#### Ahmad 2000b *{published data only}*

Ahmad NA, Lewis JD, Ginsberg GG, Rosato EF, Morris JB, Kochman ML. EUS in preoperative staging of pancreatic cancer. *Gastrointestinal Endoscopy* 2000;**52**(4):463–8.

#### Ahmad 2000c *{published data only}*

Ahmad NA, Lewis JD, Siegelman ES, Rosato EF, Ginsberg GG, Kochman ML. The role of endoscopic ultrasound and magnetic resonance imaging in the preoperative staging of pancreatic cancer. *Gastrointestinal Endoscopy* 2000;**51**(4):AB164.

#### Ahmad 2000d *{published data only}*

Ahmad NA, Lewis JD, Siegelman ES, Rosato EF, Ginsberg GG, Kochman ML. Role of endoscopic ultrasound and magnetic resonance imaging in the preoperative staging of pancreatic adenocarcinoma. *American Journal of Gastroenterology* 2000;**95**(8):1926–31.

#### Akahoshi 1998 *{published data only}*

Akahoshi K, Chijiwa Y, Nakano I, Nawata H, Ogawa Y, Tanaka M, et al. Diagnosis and staging of pancreatic cancer by endoscopic ultrasound. *British Journal of Radiology* 1998;**71**(845):492–6.

- Anand 2013** *{published data only}*  
Anand N, Tran AH, Karabalin N, Wu BU. The utility of endoscopic ultrasound (EUS) in preoperative staging of potentially resectable pancreatic cancer. *Gastroenterology* 2013;**144**(5):S208–9.
- Arabul 2012** *{published data only}*  
Arabul M, Karakus F, Alper E, Kandemir A, Celik M, Karakus V, et al. Comparison of multidetector CT and endoscopic ultrasonography in malignant pancreatic mass lesions. *Hepatogastroenterology* 2012;**59**(117):1599–603.
- Arslan 2001** *{published data only}*  
Arslan A, Buanes T, Geitung JT. Pancreatic carcinoma: MR, MR angiography and dynamic helical CT in the evaluation of vascular invasion. *European Journal of Radiology* 2001;**38**(2):151–9.
- Artifon 2009** *{published data only}*  
Artifon EL, Couto D Jr, Sakai P, da Silveira EB. Prospective evaluation of EUS versus CT scan for staging of ampullary cancer. *Gastrointestinal Endoscopy* 2009;**70**(2):290–6.
- Asagi 2013** *{published data only}*  
Asagi A, Ohta K, Nasu J, Tanada M, Nadano S, Nishimura R, et al. Utility of contrast-enhanced FDG-PET/CT in the clinical management of pancreatic cancer: impact on diagnosis, staging, evaluation of treatment response, and detection of recurrence. *Pancreas* 2013;**42**(1):11–9.
- Aslanian 2005** *{published data only}*  
Aslanian H, Salem R, Lee J, Andersen D, Robert M, Topazian M. EUS diagnosis of vascular invasion in pancreatic cancer: surgical and histologic correlates. *American Journal of Gastroenterology* 2005;**100**(6):1381–5.
- Aubertin 1996** *{published data only}*  
Aubertin JM, Bouillot JL, Bloch F, Petite JP. Endosonography and computed tomography in evaluation of vascular involvement in malignant pancreatic tumors: Comparison with surgery. *Gastroenterology* 1996;**110**(4):A486.
- Awad 1997** *{published data only}*  
Awad SS, Colletti L, Mulholland M, Knol J, Rothman ED, Scheiman J, et al. Multimodality staging optimizes resectability in patients with pancreatic and ampullary cancer. *American Surgeon* 1997;**63**(7):634–8.
- Baarir 1998** *{published data only}*  
Baarir N, Amouyal G, Faintuch JM, Houry S, Huguier M. Comparison of color Doppler ultrasonography and endoscopic ultrasonography for preoperative evaluation of the mesenteric-portal axis in pancreatic lesions. *Chirurgie* 1998;**123**(5):445–9.
- Baghbanian 2014** *{published data only}*  
Baghbanian M, Salmanroghani H, Baghbanian A, Bakhtpour M, Shabazkhani B. Resectability of the pancreatic adenocarcinoma: a study from Iran. *Advanced Biomedical Research* 2014;**3**:265.
- Bao 2008** *{published data only}*  
Bao PQ, Johnson JC, Lindsey EH, Schwartz DA, Arildsen RC, Grzeszczak E, et al. Endoscopic ultrasound and computed tomography predictors of pancreatic cancer resectability. *Journal of Gastrointestinal Surgery* 2008;**12**(1):10–6; discussion 16.
- Barthet 2007** *{published data only}*  
Barthet M, Moutardier V, Marciano S. Pancreatic adenocarcinoma: which assessment to appreciate the resection? [Adénocarcinomes du pancréas: quel bilan pour apprécier la résecabilité?]. *Gastroentérologie Clinique et Biologique* 2007;**31**(2):216–21.
- Bettini 2005** *{published data only}*  
Bettini N, Moutardier V, Turrini O, Bories E, Monges G, Giovannini M, et al. Preoperative locoregional re-evaluation by endoscopic ultrasound in pancreatic ductal adenocarcinoma after neoadjuvant chemoradiation [Réévaluation locorégionale préopératoire par échographie des adénocarcinomes ductulaires pancréatiques après radiochimiothérapie néoadjuvante]. *Gastroentérologie Clinique et Biologique* 2005;**29**(6-7):659–63.
- Brogli 2001** *{published data only}*  
Brogli L, Ambrogi C, Riu P, Huscher C, Mattioli M, Marchese F, et al. Pancreatic neoplasms: preoperative assessment of presence and extension of vascular involvement - MRI, MRA, DSA, and IVUS. *Radiology* 2001;**221**:251–2.
- Brugge 1995** *{published data only}*  
Brugge WR. Pancreatic cancer staging. Endoscopic ultrasonography criteria for vascular invasion. *Gastrointestinal Endoscopy Clinics of North America* 1995;**5**(4):741–53.
- Brugge 1996** *{published data only}*  
Brugge WR, Lee MJ, Kelsey PB, Schapiro RH, Warshaw AL. The use of EUS to diagnose malignant portal venous system invasion by pancreatic cancer. *Gastrointestinal Endoscopy* 1996;**43**(6):561–7.
- Buchs 2007** *{published data only}*  
Buchs NC, Frossard JL, Rosset A, Chilcott M, Koutny-Fong P, Chassot G, et al. Vascular invasion in pancreatic cancer: evaluation of endoscopic ultrasonography, computed tomography, ultrasonography, and angiography. *Swiss Medical Weekly* 2007;**137**(19-20):286–91.
- Burge 2015** *{published data only}*  
Burge ME, O'Rourke N, Cavallucci D, Bryant R, Francesconi A, Houston K, et al. A prospective study of the impact of fluorodeoxyglucose positron emission tomography with concurrent non-contrast CT scanning on the management of operable pancreatic and peri-ampullary cancers. *HPB* 2015;**17**(7):624–31.
- Buscall 1999** *{published data only}*  
Buscall L, Pagès P, Berthélemy P, Fourtanier G, Frexinos J, Escourrou J. Role of EUS in the management of pancreatic and ampullary carcinoma: a prospective study assessing resectability and prognosis. *Gastrointestinal Endoscopy* 1999;**50**(1):34–40.
- Cahn 1996** *{published data only}*  
Cahn M, Chang K, Nguyen P, Butler J. Impact of endoscopic ultrasound with fine-needle aspiration on the

- surgical management of pancreatic cancer. *American Journal of Surgery* 1996;**172**(5):470–2.
- Carroll 1999** *{published data only}*  
Carroll J, Al-Kawas F, Cappadona C, Marino, Groen K, Eisen E, et al. Correlates of EUS and surgery histology in assessing the size and resectability of pancreatic cancers: A prospective study of a pancreatic cancer protocol. *Gastrointestinal Endoscopy* 1999;**49**(4):AB99.
- Casneuf 2007** *{published data only}*  
Casneuf V, Delrue L, Kelles A, Van Damme N, Van Huysse J, Berrevoet F, et al. Is combined 18F-fluorodeoxyglucose-positron emission tomography/computed tomography superior to positron emission tomography or computed tomography alone for diagnosis, staging and restaging of pancreatic lesions?. *Acta Gastro-Enterologica Belgica* 2007;**70**(4):331–8.
- Catalano 1997** *{published data only}*  
Catalano C, Pavone P, Laghi A, Scipioni A, Assael F, Fanelli F, et al. Combined conventional magnetic resonance, magnetic resonance angiography, and magnetic resonance cholangiopancreatography in the diagnosis and staging of pancreatic carcinoma. *Radiologia Medica* 1997;**93**(5):556–60.
- Catalano 1998** *{published data only}*  
Catalano C, Pavone P, Laghi A, Panebianco V, Scipioni A, Fanelli F, et al. Pancreatic adenocarcinoma: combination of MR imaging, MR angiography and MR cholangiopancreatography for the diagnosis and assessment of resectability. *European Radiology* 1998;**8**(3):428–34.
- Chandler 1999** *{published data only}*  
Chandler GS, Aryan HE, Serna DL, Chang KJ, Williams RA. Surgical resectability of pancreatic carcinoma using endoscopic ultrasonography-guided fine-needle aspiration. *Journal of Investigative Medicine* 1999;**47**(2):93A.
- Chang 1997** *{published data only}*  
Chang KJ, Nguyen P, Erickson RA, Durbin TE, Katz KD. The clinical utility of endoscopic ultrasound-guided fine-needle aspiration in the diagnosis and staging of pancreatic carcinoma. *Gastrointestinal Endoscopy* 1997;**45**(5):387–93.
- Chen 2001a** *{published data only}*  
Chen CH, Tseng LJ, Yang CC, Yeh YH. Preoperative evaluation of periampullary tumors by endoscopic sonography, transabdominal sonography, and computed tomography. *Journal of Clinical Ultrasound* 2001;**29**(6):313–21.
- Chen 2001b** *{published data only}*  
Chen CH, Tseng LJ, Yang CC, Yeh YH, Mo LR. The accuracy of endoscopic ultrasound, endoscopic retrograde cholangiopancreatography, computed tomography, and transabdominal ultrasound in the detection and staging of primary ampullary tumors. *Hepato-Gastroenterology* 2001;**48**(42):1750–3.
- Chen 2009** *{published data only}*  
Chen CH, Yang CC, Yeh YH, Chou DA, Nien CK. Reappraisal of endosonography of ampullary tumors: correlation with transabdominal sonography, CT, and MRI. *Journal of Clinical Ultrasound* 2009;**37**(1):18–25.
- Chhibber 2006** *{published data only}*  
Chhibber S, Sharma A, Kumar N, Ghumman S, Puri S. Pancreatic tumors: Prospective evaluation using MR imaging with MR cholangiography and MR angiography. *Indian Journal of Radiology and Imaging* 2006;**16**(4):515–21.
- Chiang 2012** *{published data only}*  
Chiang KC, Yeh CN, Ueng SH, Hsu JT, Yeh TS, Jan YY, et al. Clinicodemographic aspect of resectable pancreatic cancer and prognostic factors for resectable cancer. *World Journal of Surgical Oncology* 2012;**10**:77.
- Chiang 2014** *{published data only}*  
Chiang KC, Lee CH, Yeh CN, Ueng SH, Hsu JT, Yeh TS, et al. A novel role of the tumor size in pancreatic cancer as an ancillary factor for predicting resectability. *Journal of Cancer Research and Therapeutics* 2014;**10**(1):142–6.
- Cieslak 2012** *{published data only}*  
Cieslak KP, van Santvoort HC, Vleggaar FP, van Leeuwen MS, ten Kate FJ, Besselink MG, et al. The role of preoperative EUS in addition to CT in patients suspected of pancreatic or periampullary cancer. *Pancreas* 2012;**41**(8):1354.
- Cieslak 2013** *{published data only}*  
Cieslak KP, van Santvoort HC, Vleggaar FP, van Leeuwen MS, ten Kate FJ, Besselink MG, et al. The role of preoperative EUS in addition to CT in patients suspected of pancreatic or periampullary cancer. *Pancreatology* 2013;**13**(2):e21.
- Cieslak 2014** *{published data only}*  
Cieslak KP, van Santvoort HC, Vleggaar FP, van Leeuwen MS, ten Kate FJ, Besselink MG, et al. The role of routine preoperative EUS when performed after contrast enhanced CT in the diagnostic work-up in patients suspected of pancreatic or periampullary cancer. *Pancreatology* 2014;**14**(2):125–30.
- Costilla 2011** *{published data only}*  
Costilla V, Borad M, Han N, Crowell M, Faigel D, Pannala R, et al. The role of positron emission tomography (PET) in addition to computed tomography (CT) in the staging of pancreatic adenocarcinoma. *American Journal of Gastroenterology* 2011;**106**:S68.
- Crippa 2013** *{published data only}*  
Crippa S, Salgarello M, Laiti S, Partelli S, Zardini C, Castelli P, et al. The value of (18)FDG-PET/CT in patients with resectable pancreatic cancer: a prospective study. *Digestive and Liver Disease* 2013;**45**(Supplement 2):S160.
- Crippa 2014** *{published data only}*  
Crippa S, Salgarello M, Laiti S, Partelli S, Castelli P, Spinelli AE, et al. The role of (18)fluoro-deoxyglucose positron emission tomography/computed tomography in resectable pancreatic cancer. *Digestive and Liver Disease* 2014;**46**(8):744–9.

- Croome 2010** *{published data only}*  
Croome KP, Jayaraman S, Schlachta CM. Preoperative staging of cancer of the pancreatic head: is there room for improvement?. *Canadian Journal of Surgery* 2010;**53**(3): 171–4.
- Czako 2009** *{published data only}*  
Czako L, Szepes A, Baranyai T, Szepes Z, Molnar T, Takacs T, et al. Role of endoscopic ultrasonography in the diagnosis and preoperative staging of pancreatic cancer. *Pancreatology* 2009;**9**(4):518–9.
- Delbeke 1999** *{published data only}*  
Delbeke D, Rose DM, Chapman WC, Pinson CW, Wright JK, Beauchamp RD, et al. Optimal interpretation of FDG PET in the diagnosis, staging and management of pancreatic carcinoma. *Journal of Nuclear Medicine* 1999;**40**(11):1784–91.
- Dewitt 2003** *{published data only}*  
Dewitt J, Ciaccia D, Leblanc J, McHenry L, Sherman S, Imperiale T, et al. Prospective comparison of endoscopic ultrasound (EUS) and dual-phase helical computed tomography (DPHCT) for the preoperative evaluation of known or suspected pancreatic malignancy: Final results. *Gastrointestinal Endoscopy* 2003;**57**(5):AB99.
- DeWitt 2004** *{published data only}*  
DeWitt J, Devereaux B, Chriswell M, McGreevy K, Howard T, Imperiale TF, et al. Comparison of endoscopic ultrasonography and multidetector computed tomography for detecting and staging pancreatic cancer. *Annals of Internal Medicine* 2004;**141**(10):753–63.
- Egorov 2012** *{published data only}*  
Egorov VI, Vishnevsky VA, Karmazanovsky GG, Yashina NI, Starostina NS, Zakharova OP, et al. Does arterial encasement on CT always mean arterial invasion at surgery in pancreatic cancer? If not, how can we assess resectability and what is the strategy?. *Pancreatology* 2012;**12**(6):559.
- Egorov 2013** *{published data only}*  
Egorov VI, Petrov RV, Solodina EN, Karmazanovsky GG, Starostina NS, Kuruschkina NA. Computed tomography-based diagnostics might be insufficient in the determination of pancreatic cancer unresectability. *World Journal of Gastrointestinal Surgery* 2013;**5**(4):83–96.
- Einersen 2013** *{published data only}*  
Einersen P, Epelboym I, Winner M, Leung D, Chabot JA, Allendorf JD. Positron emission tomography (PET) has limited utility in preoperative staging of pancreatic adenocarcinoma. *Gastroenterology* 2013;**1**:S1080.
- Einersen 2014** *{published data only}*  
Einersen P, Epelboym I, Winner MD, Leung D, Chabot JA, Allendorf JD. Positron emission tomography (PET) has limited utility in the staging of pancreatic adenocarcinoma. *Journal of Gastrointestinal Surgery* 2014;**18**(8):1441–4.
- Eloubeidi 2006** *{published data only}*  
Eloubeidi M, Varadarajulu S, Desai S, Shirley R, Heslin M, Mehra M, et al. A prospective evaluation of an algorithm incorporating routine pre-operative endoscopic ultrasound-guided fine needle aspiration in suspected pancreatic cancer patients. *Gastroenterology* 2006;**130**(4):A883.
- Eloubeidi 2007** *{published data only}*  
Eloubeidi MA, Varadarajulu S, Desai S, Shirley R, Heslin MJ, Mehra M, et al. A prospective evaluation of an algorithm incorporating routine preoperative endoscopic ultrasound-guided fine needle aspiration in suspected pancreatic cancer. *Journal of Gastrointestinal Surgery* 2007;**11**(7):813–9.
- Erickson 2000** *{published data only}*  
Erickson RA, Garza AA. Impact of endoscopic ultrasound on the management and outcome of pancreatic carcinoma. *American Journal of Gastroenterology* 2000;**95**(9):2248–54.
- Faigel 1996** *{published data only}*  
Faigel DO, Kochman ML. The role of endoscopic ultrasound in the preoperative staging of pancreatic malignancies. *Gastrointestinal Endoscopy* 1996;**43**(6):626–8.
- Farma 2008a** *{published data only}*  
Farma JM, Melis M, Santillan A, Walker J, Belinc D, Eikman EA, et al. Positron emission tomography/computed tomography fusion scans enhances preoperative treatment planning in patients with pancreatic cancer. *Annals of Surgical Oncology* 2008;**15**:5.
- Farma 2008b** *{published data only}*  
Farma JM, Santillan AA, Melis M, Walters J, Belinc D, Chen DT, et al. PET/CT fusion scan enhances CT staging in patients with pancreatic neoplasms. *Annals of Surgical Oncology* 2008;**15**(9):2465–71.
- Fischer 2002** *{published data only}*  
Fischer U, Vosschenrich R, Horstmann O, Becker H, Salamat B, Baum F, et al. Preoperative local MRI-staging of patients with a suspected pancreatic mass. *European Radiology* 2002;**12**(2):296–303.
- Fockens 1993** *{published data only}*  
Fockens P, Huijbregtse K. Staging of pancreatic and ampullary cancer by endoscopy. *Endoscopy* 1993;**25**(1): 52–7.
- Freeny 2001** *{published data only}*  
Freeny PC. Pancreatic carcinoma: what is the best imaging test?. *Pancreatology* 2001;**1**(6):604–9.
- Frohlich 1999** *{published data only}*  
Frohlich A, Diederichs CG, Staib L, Vogel J, Beger HG, Reske SN. Detection of liver metastases from pancreatic cancer using FDG PET. *Journal of Nuclear Medicine* 1999;**40**(2):250–5.
- García-Cano 2002** *{published data only}*  
García-Cano LJ. Diagnostic approach to Vater's papilla tumours. *Revista Española de Enfermedades Digestivas* 2002;**94**(10):579–84.
- Gaspar 2015** *{published data only}*  
Gaspar J, Shami VM. The role of EUS in ampullary lesions: is the answer black and white?. *Gastrointestinal Endoscopy* 2015;**81**(2):389–90.

- Goh 2006** *{published data only}*  
Goh BKP. Positron emission tomography/computed tomography influences on the management of resectable pancreatic cancer and its cost-effectiveness. *Annals of Surgery* 2006;**243**(5):709–10.
- Grenacher 2004** *{published data only}*  
Grenacher L, Klauss M, Dukic L, Delorme S, Knaebel HP, Düx M, et al. Diagnosis and staging of pancreatic carcinoma: MRI versus multislice-CT - a prospective study. *RöFo: Fortschritte auf dem Gebiet der Röntgenstrahlen und der Nuklearmedizin* 2004;**176**(11):1624–33.
- Gress 1997** *{published data only}*  
Gress F, Savides T, Cummings O, Sherman S, Lehman G, Zaidi S, et al. Radial scanning and linear array endosonography for staging pancreatic cancer: a prospective randomized comparison. *Gastrointestinal Endoscopy* 1997;**45**(2):138–42.
- Gress 1999** *{published data only}*  
Gress FG, Hawes RH, Savides TJ, Ikenberry SO, Cummings O, Kopecky K, et al. Role of EUS in the preoperative staging of pancreatic cancer: a large single-center experience. *Gastrointestinal Endoscopy* 1999;**50**(6):786–91.
- Harrison 1999** *{published data only}*  
Harrison JL, Millikan KW, Prinz RA, Zaidi S. Endoscopic ultrasound for diagnosis and staging of pancreatic tumors. *American Surgeon* 1999;**65**(7):659–65.
- Heinrich 2005** *{published data only}*  
Heinrich S, Goerres GW, Schäfer M, Sagmeister M, Bauerfeind P, Pestalozzi BC, et al. Positron emission tomography/computed tomography influences on the management of resectable pancreatic cancer and its cost-effectiveness. *Annals of Surgery* 2005;**242**(2):235–43.
- Helmreich 2004** *{published data only}*  
Helmreich F, Schniewind B, Biederer J, Heller M, Reuter M. The role of magnetic resonance imaging in the preoperative evaluation of the peripancreatic vasculature in pancreas carcinoma. *RöFo: Fortschritte auf dem Gebiet der Röntgenstrahlen und der Nuklearmedizin* 2004;**176**(2):239–45.
- Hemmingsson 1982** *{published data only}*  
Hemmingsson A, Jacobson G, Lindgren PG, Lönnerholm T, Lörelius LE, Nordgren CE. Radiologic assessment of resectability of carcinoma of the head of the pancreas. *Acta Radiologica: Diagnosis* 1982;**23**(2):127–30.
- Hirokawa 2010** *{published data only}*  
Hirokawa Y, Isoda H, Okada T, Arizono S, Shimada K, Yamamoto A, et al. Improved detection of hepatic metastases from pancreatic cancer using periodically rotated overlapping parallel lines with enhanced reconstruction (PROPELLER) technique after SPIO administration. *Investigative Radiology* 2010;**45**(3):158–64.
- Ho 2008** *{published data only}*  
Ho JM, Eysselein VE, Stabile BE. The value of endoscopic ultrasonography in predicting resectability and margins of resection for periampullary tumors. *The American Surgeon* 2008;**74**(10):1026–9.
- Hochwald 1999** *{published data only}*  
Hochwald SN, Rofsky NM, Dobryansky M, Shamamian P, Marcus SG. Magnetic resonance imaging with magnetic resonance cholangiopancreatography accurately predicts resectability of pancreatic carcinoma. *Journal of Gastrointestinal Surgery* 1999;**3**(5):506–11.
- Holzapfel 2011** *{published data only}*  
Holzapfel K, Reiser-Erkan C, Fingerle AA, Erkan M, Eiber MJ, Rummeny EJ, et al. Comparison of diffusion-weighted MR imaging and multidetector-row CT in the detection of liver metastases in patients operated for pancreatic cancer. *Abdominal Imaging* 2011;**36**(2):179–84.
- Howard 1997** *{published data only}*  
Howard TJ, Chin AC, Streib EW, Kopecky KK, Wiebke EA. Value of helical computed tomography, angiography, and endoscopic ultrasound in determining resectability of periampullary carcinoma. *American Journal of Surgery* 1997;**174**(3):237–41.
- Hu 2015** *{published data only}*  
Hu SP, Zhang J, Zuo CJ, Cheng C, Liu QH, Sun GF. 18F-FDG-PET/CT findings in pancreatic metastasis. *Radiologia Medica* 2015;**120**(10):887–98.
- Ichikawa 1997** *{published data only}*  
Ichikawa T, Haradome H, Hachiya J, Nitatori T, Ohtomo K, Kinoshita T, et al. Pancreatic ductal adenocarcinoma: preoperative assessment with helical CT versus dynamic MR imaging. *Radiology* 1997;**202**(3):655–62.
- Iglesias-Garcia 2010** *{published data only}*  
Iglesias-Garcia J, Alvarez-Castro A, Iglesias-Canle J, Larino-Noia J, Pazos G, Forteza J, et al. Endoscopic ultrasound (EUS) vs helical CT scan for TN staging and evaluation of resectability of pancreatic cancer: a prospective, comparative study using histology of surgical specimens as gold-standard. *Gastroenterology* 2010;**138**(5 Suppl 1):S11.
- Imazu 2010** *{published data only}*  
Imazu H, Uchiyama Y, Matsunaga K, Ikeda K, Kakutani H, Sasaki Y, et al. Contrast-enhanced harmonic EUS with novel ultrasonographic contrast (Sonazoid) in the preoperative T-staging for pancreaticobiliary malignancies. *Scandinavian Journal of Gastroenterology* 2010;**45**(6):732–8.
- Izuishi 2010** *{published data only}*  
Izuishi K, Yamamoto Y, Sano T, Takebayashi R, Masaki T, Suzuki Y. Impact of 18-fluorodeoxyglucose positron emission tomography on the management of pancreatic cancer. *Journal of Gastrointestinal Surgery* 2010;**14**(7):1151–8.
- Javery 2013** *{published data only}*  
Javery O, Shyn P, Morteale K. FDG PET or PET/CT in patients with pancreatic cancer: when does it add to diagnostic CT or MRI?. *Clinical Imaging* 2013;**37**(2):295–301.
- Jemaa 2008** *{published data only}*  
Jemaa Y, Houissa F, Trabelsi S, Moussa A, Belhouchet H, Mouelhi L, et al. Endoscopic ultrasonography versus helical CT in diagnosis and staging of pancreatic cancer. *Tunisie Medicale* 2008;**86**(4):346–9.



**Kadish 1995** *{published data only}*

Kadish SL, Ginsberg GG, Rosato EF, Morris JB, Smith D, Kochman ML. Prospective evaluation of endosonography and surgical/pathologic staging in the evaluation of patients with pancreatic-cancer. *Gastroenterology* 1995;**108**(4): A486–A.

**Kala 2007** *{published data only}*

Kala Z, Válek V, Hlavsa J, Hana K, Vánová A. The role of CT and endoscopic ultrasound in pre-operative staging of pancreatic cancer. *European Journal of Radiology* 2007;**62**(2):166–9.

**Karoumpalis 2011** *{published data only}*

Karoumpalis I, Sigalas P, Salla C, Diakoutou E, Balatsos V, Zografos G, et al. Endoscopic ultrasound staging and guided fine needle aspiration biopsy in patients with resectable pancreatic malignancies: a single-center prospective experience. *Onkologie* 2011;**34**(10):533–7.

**Kim 2001** *{published data only}*

Kim AY, Lee M, Kim T, Kim P, Ha H. Preoperative evaluation of pancreatic carcinoma: the value of combined MR imaging, MR cholangiopancreatography, and contrast-enhanced dual phase 3D MR angiography. *Radiology* 2001;**221**(Supplement S):252.

**Kim 2012** *{published data only}*

Kim MJ, Lee KH, Lee KT, Lee JK, Ku BH, Oh CR, et al. The value of positron emission tomography/computed tomography for evaluating metastatic disease in patients with pancreatic cancer. *Pancreas* 2012;**41**(6):897–903.

**Kim 2015** *{published data only}*

Kim R, Prithviraj G, Kothari N, Springett G, Malafa M, Hodul P, et al. PET/CT fusion scan prevents futile laparotomy in early stage pancreatic cancer. *Clinical Nuclear Medicine* 2015;**40**(11):e501–5.

**Koelblinger 2011** *{published data only}*

Koelblinger C, Ba-Ssalamah A, Goetzing P, Puchner S, Weber M, Sahara K, et al. Gadobenate dimeglumine-enhanced 3.0-T MR imaging versus multiphase 64-detector row CT: Prospective evaluation in patients suspected of having pancreatic cancer. *Radiology* 2011;**259**(3):757–66.

**Koranda 2009** *{published data only}*

Koranda P, Kysucan J, Havlik R, Myslivecek M, Formanek R, Buriánková E, et al. Reliability of contrast-enhanced 18F-FDG PET/CT in preoperative staging of pancreatic cancer. *European Journal of Nuclear Medicine and Molecular Imaging* 2009;**36**:S263.

**Koranda 2010** *{published data only}*

Koranda P, Buriánková E, Formanek R, Kysucan J, Havlik R, Myslivecek M. 18F-FDG PET/CT in pancreatic carcinoma: diagnosis and staging. *Ceska Radiologie* 2010;**64**(3):185–91.

**Kulig 2004** *{published data only}*

Kulig J, Popiela T, Zajac A, Klek S, Kolodziejczyk P. The clinical value of imaging modalities (USG, EUS, CT) in pancreatic carcinoma staging. *Nowotwory* 2004;**54**(6): 555–9.

**Kysucan 2010** *{published data only}*

Kysucan J, Lovecek M, Klos D, Tozzi I, Koranda P, Buriánková E, et al. Benefit of PET/CT in the preoperative staging in pancreatic carcinomas. *Rozhledy v chirurgii* :

*měsíčník Československé chirurgické společnosti* 2010;**89**(7):433–40.

**Lakhtakia 2011** *{published data only}*

Lakhtakia S, Wee E, Gupta R, Anuradha S, Shetty MG, Kalapala R, et al. Diagnostic accuracy & strength of agreement between EUS and histopathology in the staging of ampullary tumor. *Gastrointestinal Endoscopy* 2011;**73**(4 Suppl):AB335.

**Latronico 2005** *{published data only}*

Latronico A, Crosta C, De Fiori E, Carolei A, Ravizza D, Bellomi M. Endoscopic ultrasound and computed tomography in the diagnosis, locoregional staging and assessment of vascular infiltration of pancreatic carcinoma. *La Radiologia Medica* 2005;**109**(5-6):508–15.

**Lee 2002** *{published data only}*

Lee JK, Kim AY, Kim TK, Kim PN, Lee M, Ha HK. Preoperative evaluation of pancreatic carcinoma: comparison of multidetector-row CT vs combined MR imaging, MR cholangiopancreatography and three-dimensional dual-phase MR angiography. *Radiology* 2002;**225**:302.

**Lee 2010** *{published data only}*

Lee JK, Kim AY, Kim PN, Lee MG, Ha HK. Prediction of vascular involvement and resectability by multidetector-row CT versus MR imaging with MR angiography in patients who underwent surgery for resection of pancreatic ductal adenocarcinoma. *European Journal of Radiology* 2010;**73**(2): 310–6.

**Lentschig 1996** *{published data only}*

Lentschig MG, Reimer P, Rummeny E, Grenzheuser C, Daldrup HE, Berns T, et al. The role of spiral computed tomography and magnetic resonance imaging in the preoperative diagnosis of pancreatic carcinoma. *Der Radiologe* 1996;**36**(5):406–12.

**Lévy 2001** *{published data only}*

Lévy P. Resectability of pancreatic head adenocarcinoma. *Gastroentérologie Clinique et Biologique* 2001;**25**(2 Pt 2): C19–23.

**Lopez-Hänninen 2002** *{published data only}*

Lopez-Hänninen EL, Amthauer H, Hosten N, Ricke J, Böhmig M, Langrehr J, et al. Prospective evaluation of pancreatic tumors: accuracy of MR imaging with MR cholangiopancreatography and MR angiography. *Radiology* 2002;**224**(1):34–41.

**Lu 2006** *{published data only}*

Lu ZC, Guo JM, Zhang YL, Tian PL, Zhang L, Yu JP, et al. Comparison of endoscopic ultrasonography with computer-assisted tomography in the determination of preoperative stage and resectability of pancreatic and ampullary cancers. *Zhonghua Zhong Liu Za Zhi [Chinese Journal of Oncology]* 2006;**28**(6):441–4.

- Lytras 2005** *{published data only}*  
Lytras D, Connor S, Bosonnet L, Jayan R, Evans J, Hughes M, et al. Positron emission tomography does not add to computed tomography for the diagnosis and staging of pancreatic cancer. *Digestive Surgery* 2005;**22**(1-2):55–61.
- Makowicz 2000** *{published data only}*  
Makowicz F, Pietsch A, Holle A, Riediger H, Adam U, Liebe S, et al. Preoperative endoscopic ultrasound in pancreatic malignancy. *Gastroenterology* 2000;**118**(4):A1045.
- Malfhertheiner 2005** *{published data only}*  
Malfhertheiner P, Rickes S. Is endoscopic ultrasonography superior to multidetector CT for assessing pancreatic cancer? . *Nature Clinical Practice Gastroenterology & Hepatology* 2005;**2**(4):176–7.
- Maluf-Filho 2004** *{published data only}*  
Maluf-Filho F, Sakai P, Cunha JE, Garrido T, Rocha M, Machado MC, et al. Radial endoscopic ultrasound and spiral computed tomography in the diagnosis and staging of periampullary tumors. *Pancreatology* 2004;**4**(2):122–8.
- Mansfield 2008** *{published data only}*  
Mansfield SD, Scott J, Oppong K, Richardson DL, Sen G, Jaques BC, et al. Comparison of multislice computed tomography and endoscopic ultrasonography with operative and histological findings in suspected pancreatic and periampullary malignancy. *British Journal of Surgery* 2008;**95**(12):1512–20.
- McFarland 1996** *{published data only}*  
McFarland EG, Kaufman JA, Saini S, Halpern EF, Lu DSK, Waitman AC, et al. Preoperative staging of cancer of the pancreas: value of MR angiography versus conventional angiography in detecting portal venous invasion. *American Journal of Roentgenology* 1996;**166**(1):37–43.
- Megibow 1995** *{published data only}*  
Megibow AJ, Zhou XH, Rotterdam H, Francis IR, Zerhouni EA, Balfe DM, et al. Pancreatic adenocarcinoma: CT versus MR imaging in the evaluation of resectability - report of the Radiology Diagnostic Oncology Group. *Radiology* 1995;**195**(2):327–32.
- Mehmet 2006** *{published data only}*  
Mehmet Erturk S, Ichikawa T, Sou H, Saitou R, Tsukamoto T, Motosugi U, et al. Pancreatic adenocarcinoma: MDCT versus MRI in the detection and assessment of locoregional extension. *Journal of Computer Assisted Tomography* 2006;**30**(4):583–90.
- Melzer 1996** *{published data only}*  
Melzer E, Avidan B, Heyman Z, Coret A, Bar-Meir S. Preoperative assessment of blood vessel involvement in patients with pancreatic cancer. *Israel Journal of Medical Sciences* 1996;**32**(11):1086–8.
- Mertz 2000** *{published data only}*  
Mertz HR, Sechopoulos P, Delbeke D, Leach SD. EUS, PET, and CT scanning for evaluation of pancreatic adenocarcinoma. *Gastrointestinal Endoscopy* 2000;**52**(3):367–71.
- Morris-Stiff 2011** *{published data only}*  
Morris-Stiff G, Escofet X, Barry JD, Lewis WG, Puntis MCA, Roberts SA. Selective use of endoscopic ultrasound in the evaluation of carcinomas of the pancreatic head. *Digestive Surgery* 2011;**28**(5-6):373–8.
- Motosugi 2011** *{published data only}*  
Motosugi U, Ichikawa T, Morisaka H, Sou H, Muhi A, Kimura K, et al. Detection of pancreatic carcinoma and liver metastases with gadoteric acid-enhanced MR imaging: comparison with contrast-enhanced multi-detector row CT. *Radiology* 2011;**260**(2):446–53.
- Mukai 1991** *{published data only}*  
Mukai H, Nakajima M, Yasuda K, Cho E, Mizuma Y, Hayakumo T, et al. Preoperative diagnosis and staging of pancreatic cancer by endoscopic ultrasonography (EUS)—a comparative study with other diagnostic tools. *Nippon Shokakibyo Gakkai Zasshi [Japanese Journal of Gastroenterology]* 1991;**88**(9):2132–42.
- Murakami 1996** *{published data only}*  
Murakami T, Tsuda K, Nakamura H, Osuga K, Tomoda K, Hori S, et al. 3DTF-flash MR imaging of pancreatic cancer with gadopentetate dimeglumine. *Acta Radiologica* 1996;**37**(2):190–4.
- Nakamoto 1999** *{published data only}*  
Nakamoto Y, Higashi T, Sakahara H, Tamaki N, Kogire M, Imamura M, et al. Contribution of PET in the detection of liver metastases from pancreatic tumours. *Clinical Radiology* 1999;**54**(4):248–52.
- Napolitano 2002** *{published data only}*  
Napolitano L, Di Donato F, Gargano E. Clinical study of the imaging validity in detecting infiltration of the mesenteric-portal axis in pancreatic carcinoma. *Annali Italiani di Chirurgia* 2002;**73**(4):409–12.
- Neoptolemos 2005** *{published data only}*  
Neoptolemos JP. Is endoscopic ultrasonography superior to multidetector CT for assessing pancreatic cancer?. *Nature Clinical Practice Oncology* 2005;**2**(2):78–9.
- Nishiharu 1999** *{published data only}*  
Nishiharu T, Yamashita Y, Abe Y, Mitsuzaki K, Tsuchigame T, Nakayama Y, et al. Local extension of pancreatic carcinoma: assessment with thin-section helical CT versus with breath-hold fast MR imaging - ROC analysis. *Radiology* 1999;**212**(2):445–52.
- Palazzo 1993** *{published data only}*  
Palazzo L, Roseau G, Gayet B, Vilgrain V, Belghiti J, Fékété F, et al. Endoscopic ultrasonography in the diagnosis and staging of pancreatic adenocarcinoma. Results of a prospective study with comparison to ultrasonography and CT scan. *Endoscopy* 1993;**25**(2):143–50.
- Pan 2014** *{published data only}*  
Pan S, Geng X, Zhao H, Xie K. The value of enhanced CT and 18F-FDG PET/CT in evaluation of resectability of pancreatic cancer. *HPB* 2014;**16**:622.

- Pappas 2011** *{published data only}*  
Pappas S, House M, Lee K, Miller S, Prinz RA. Outcomes after preoperative endoscopic ultrasonography and biopsy in patients undergoing distal pancreatectomy discussion. *Surgery* 2011;**150**(4):844–3.
- Park 2009** *{published data only}*  
Park HS, Lee JM, Choi HK, Hong SH, Han JK, Choi BI. Preoperative evaluation of pancreatic cancer: comparison of gadolinium-enhanced dynamic MRI with MR cholangiopancreatography versus MDCT. *Journal of Magnetic Resonance Imaging* 2009;**30**(3):586–95.
- Patel 2002a** *{published data only}*  
Patel PJ, Khodadadian E, Michael H, Katz D, Sherman S, Lehman G, et al. Is helical CT the superior imaging modality when compared with EUS for preoperative pancreatic cancer staging and determination of tumor resectability?. *Gastrointestinal Endoscopy* 2002;**55**(5):AB244.
- Patel 2002b** *{published data only}*  
Patel PJ, Khodadadian E, Michael H, Katz D, Sherman S, Lehman G, et al. Is helical computed tomography the superior imaging modality when compared with endoscopic ultrasound for preoperative pancreatic cancer staging and determination of tumor resectability?. *Gastrointestinal Endoscopy* 2002;**56**(4):S122–S.
- Paul 2012** *{published data only}*  
Paul N, Donahue TR, Wong JL, Tomlinson JS, Hines OJ, Reber HA, et al. Evolving role of endoscopic ultrasound before surgery after medical down-staging of pancreaticobiliary cancers. *Gastrointestinal Endoscopy* 2012;**75**(4):AB196.
- Prithiviraj 2013** *{published data only}*  
Prithiviraj, Kaman L. Sensitivity and specificity of FDG PET-CT scan in detecting lymph node metastasis in operable periampullary tumours in correlation with the final histopathology after curative surgery. *Indian Journal of Surgical Oncology* 2013;**4**(2):213.
- Raj 2013** *{published data only}*  
Raj P, Kaman L, Singh R, Dahyia D, Bhattacharya A, Bal A. Sensitivity and specificity of FDG PET-CT scan in detecting lymph node metastasis in operable periampullary tumours in correlation with the final histopathology after curative surgery. *Updates in Surgery* 2013;**65**(2):103–7.
- Ramsay 2004** *{published data only}*  
Ramsay D, Marshall M, Song S, Zimmerman M, Edmunds S, Yusoff I, et al. Identification and staging of pancreatic tumours using computed tomography, endoscopic ultrasound and mangafodipir trisodium-enhanced magnetic resonance imaging. *Australasian Radiology* 2004;**48**(2):154–61.
- Razzaque 2012** *{published data only}*  
Razzaque S, Ashraf N, Weber JM, Pimiento JM, Malafa MP, Kim RD. The role of fusion positron emission tomography/computed tomography (PET/CT) scan in patients with resectable pancreatic neoplasms. *Journal of Clinical Oncology* 2012;**30**(4 Supplement 1):322.
- Reiser-Erkan 2009** *{published data only}*  
Reiser-Erkan C, Erkan M, Fingerle A, Holzapfel K, Friess H, Kleeff J. Detection of liver metastases in patients with malignant pancreatic tumors by diffusion-weighted MR imaging. *Pancreas* 2009;**38**(8):1040.
- Reiser-Erkan 2010** *{published data only}*  
Reiser-Erkan C, Erkan M, Fingerle A, Holzapfel K, Gaa J, Friess H, et al. Detection of liver metastases in patients with malignant pancreatic tumors by diffusion-weighted MR imaging. *HPB* 2010;**12**:101.
- Ren 2006** *{published data only}*  
Ren Y, Jin ZY, Xue HD, You H, Feng F. Comparison of multi-slice spiral CT and magnetic resonance imaging in evaluation of the unresectability of blood vessels in pancreatic tumor. *Zhongguo Yi Xue Ke Xue Yuan Xue Bao. Acta Academiae Medicinae Sinicae* 2006;**28**(1):76–9.
- Riditid 2015** *{published data only}*  
Riditid W, Schmidt SE, Al-Haddad MA, Leblanc J, Dewitt JM, McHenry L, et al. Performance characteristics of EUS for locoregional evaluation of ampullary lesions. *Gastrointestinal Endoscopy* 2015;**81**(2):380–8.
- Rivadeneira 2003** *{published data only}*  
Rivadeneira DE, Pochapin M, Grobmyer SR, Lieberman MD, Christos PJ, Jacobson I, et al. Comparison of linear array endoscopic ultrasound and helical computed tomography for the staging of periampullary malignancies. *Annals of Surgical Oncology* 2003;**10**(8):890–7.
- Romijn 2000** *{published data only}*  
Romijn MG, Stoker J, van Eijck CH, van Muiswinkel JM, Torres CG, Laméris JS. MRI with mangafodipir trisodium in the detection and staging of pancreatic cancer. *Journal of Magnetic Resonance Imaging* 2000;**12**(2):261–8.
- Rösch 1992a** *{published data only}*  
Rösch T, Braig C, Gain T, Feuerbach S, Siewert JR, Schusdzarra V, et al. Staging of pancreatic and ampullary carcinoma by endoscopic ultrasonography: comparison with conventional sonography, computed tomography, and angiography. *Gastroenterology* 1992;**102**(1):188–99.
- Rösch 1992b** *{published data only}*  
Rösch T, Dittler HJ, Lorenz R, Braig C, Gain T, Feuerbach S, et al. The endosonographic staging of pancreatic carcinoma. *Deutsche Medizinische Wochenschrift* 1992;**117**(15):563–9.
- Rösch 1992c** *{published data only}*  
Rosch T, Lorenz R, Braig C, Classen M. Endoscopic ultrasonography in diagnosis and staging of pancreatic and biliary tumors. *Endoscopy* 1992;**24** Suppl 1:304–8.
- Rösch 2000** *{published data only}*  
Rosch T, Dittler HJ, Strobel K, Meining A, Schusdzarra V, Lorenz R, et al. Endoscopic ultrasound criteria for vascular invasion in the staging of cancer of the head of the pancreas: a blind reevaluation of videotapes. *Gastrointestinal Endoscopy* 2000;**52**(4):469–77.

- Saif 2008** *{published data only}*  
Saif MW, Cornfeld D, Modarresifar H, Ojha B. 18F-FDG positron emission tomography CT (FDG PET-CT) in the management of pancreatic cancer: initial experience in 12 patients. *Journal of Gastrointestinal and Liver Diseases* 2008; **17**(2):173–8.
- Schima 2002** *{published data only}*  
Schima W, Függer R, Schober E, Oettl C, Wamser P, Grabenwöger F, et al. Diagnosis and staging of pancreatic cancer: Comparison of mangafodipir trisodium-enhanced MR imaging and contrast-enhanced helical hydro-CT. *AJR American Journal of Roentgenology* 2002; **179**(3):717–24.
- Schmidt 2004** *{published data only}*  
Schmidt J, Fraunhofer S, Fleisch M, Zirngibl H. Is peritoneal cytology a predictor of unresectability in pancreatic carcinoma?. *Hepato-Gastroenterology* 2004; **51**(60):1827–31.
- Schwarz 2001** *{published data only}*  
Schwarz M, Pauls S, Sokiranski R, Brambs HJ, Glasbrenner B, Adler G, et al. Is a preoperative multidagnostic approach to predict surgical resectability of periampullary tumors still effective?. *American Journal of Surgery* 2001; **182**(3):243–9.
- Seicean 2008** *{published data only}*  
Seicean A, Badea R, Mocan T, Iancu C, Pop T, Seicean R, et al. Radial endoscopic ultrasonography in the preoperative staging of pancreatic cancer. *Journal of Gastrointestinal and Liver Diseases* 2008; **17**(3):273–6.
- Shami 2011** *{published data only}*  
Shami VM, Mahajan A, Loch MM, Stella AC, Northup PG, White GE, et al. Comparison between endoscopic ultrasound and magnetic resonance imaging for the staging of pancreatic cancer. *Pancreas* 2011; **40**(4):567–70.
- Sheng 2012** *{published data only}*  
Sheng J, Jahromi AH, Takalkar A, Chu Q, D'Agostino H, Zibari GB, et al. The role of positron emission tomography in the diagnosis and staging of pancreatic lesions. *HPB* 2012; **14**:70.
- Shin 2013** *{published data only}*  
Shin EJ, Khashab M. The role of endoscopy in the treatment, management, and personalization of pancreatic cancer. *Current Problems in Cancer* 2013; **37**(5):293–300.
- Shoup 2000** *{published data only}*  
Shoup M, Hodul P, Aranha GV, Choe D, Olson M, Leya J, et al. Defining a role for endoscopic ultrasound in staging periampullary tumors. *American Journal of Surgery* 2000; **179**(6):453–6.
- Sironi 1995** *{published data only}*  
Sironi S, De Cobelli F, Zerbi A, Balzano G, Di Carlo V, DelMaschio A. Pancreatic carcinoma: MR assessment of tumor invasion of the peripancreatic vessels. *Journal of Computer Assisted Tomography* 1995; **19**(5):739–44.
- Sironi 1996** *{published data only}*  
Sironi S, De Cobelli F, Zerbi A, Angeli E, Balzano G, Taccagni G, et al. Pancreatic adenocarcinoma: assessment of vascular invasion with high-field MR imaging and a phased-array coil. *American Journal of Roentgenology* 1996; **167**(4):997–1001.
- Skordilis 2002** *{published data only}*  
Skordilis P, Mouzas IA, Dimoulis PD, Alexandrakis G, Moschandrea J, Kouroumalis E. Is endosonography an effective method for detection and local staging of the ampullary carcinoma? A prospective study. *BMC Surgery* 2002; **2**:1.
- Smedby 1997** *{published data only}*  
Smedby O, Riesenfeld V, Karlson B, Jacobson G, Lofberg A, Lindgren PG, et al. Magnetic resonance angiography in the resectability assessment of suspected pancreatic tumours. *European Radiology* 1997; **7**(5):649–53.
- Snady 1993** *{published data only}*  
Snady H. Clinical utility of endoscopic ultrasonography for pancreatic tumors. *Endoscopy* 1993; **25**(2):182–4.
- Snady 1994** *{published data only}*  
Snady H, Bruckner H, Siegel J, Cooperman A, Neff R, Kiefer L. Endoscopic ultrasonographic criteria of vascular invasion by potentially resectable pancreatic tumors. *Gastrointestinal Endoscopy* 1994; **40**(3):326–33.
- Solodinina 2014a** *{published data only}*  
Solodinina EN, Starkov IuG, Kurushkina NA, Egorov VI. Endosonography in the T-staging of pancreatic cancer. *Khirurgiia* 2014, (8):16–22.
- Solodinina 2014b** *{published data only}*  
Solodinina EN, Starkov YG, Kurushkina NA, Egorov VI. Endoscopic ultrasonography in determining resectability of the pancreatic adenocarcinoma. *Eksperimental'naiia i Klinicheskaia Gastroenterologiya* 2014, (9):56–60.
- Soriano 2001** *{published data only}*  
Soriano A, Ayuso MC, Ayuso JR, De Caralt MT, Gilabert R, Gines A, et al. Preoperative staging and tumor resectability assessment in pancreatic cancer. Prospective study comparing endoscopic ultrasonography (EUS), computed tomography (CT), magnetic resonance imaging (MRI) and angiography. *Gastroenterology* 2001; **120**(5):A760.
- Soriano 2004** *{published data only}*  
Soriano A, Castells A, Ayuso C, Ayuso JR, De Caralt MT, Gines MA, et al. Preoperative staging and tumor resectability assessment of pancreatic cancer: Prospective study comparing endoscopic ultrasonography, helical computed tomography, magnetic resonance imaging, and angiography. *American Journal of Gastroenterology* 2004; **99**(3):492–501.
- Spencer 1998** *{published data only}*  
Spencer JA, Ward J, Guthrie JA, Guillou PJ, Robinson PJ. Assessment of resectability of pancreatic cancer with dynamic contrast-enhanced MR imaging: technique, surgical correlation and patient outcome. *European Radiology* 1998; **8**(1):23–9.
- Staib 1997** *{published data only}*  
Staib L, Diederichs CG, Reske SN, Beger HG. Does positron emission tomography (PET) increase preoperative

- diagnostic efficacy in pancreatic tumors?. *Gastroenterology* 1997;**112**(4):A1476.
- Strobel 2008** *{published data only}*  
Strobel K, Heinrich S, Bhure U, Soyka J, Veit-Haibach P, Pestalozzi BC, et al. Contrast-enhanced 18F-FDG PET/CT: 1-stop-shop imaging for assessing the resectability of pancreatic cancer. *Journal of Nuclear Medicine* 2008;**49**(9):1408–13.
- Takaori 2007** *{published data only}*  
Takaori K, Tanigawa N, Matsuki M, Agui T, Iwamoto M, Miyamoto Y, et al. Ferumoxtran-10-enhanced magnetic resonance imaging for preoperative evaluation of paraaortic lymph node metastasis in patients with pancreatic cancer. *Annals of Surgical Oncology* 2007;**14**(2):98.
- Takayama 2009** *{published data only}*  
Takayama Y. Usefulness of endoscopic ultrasonography for preoperative staging of tumors of the ampulla of Vater. *Gastrointestinal Endoscopy* 2009;**69**(2):S258.
- Tapper 2010** *{published data only}*  
Tapper EB, Martin D, Adsay NV, Kooby D, Kalb B, Sarmiento JM. An MRI-driven practice: a new perspective on MRI for the evaluation of adenocarcinoma of the head of the pancreas. *Journal of Gastrointestinal Surgery* 2010;**14**(8):1292–7.
- Tellez-Avila 2012** *{published data only}*  
Tellez-Avila FI, Chavez-Tapia NC, López-Arce G, Franco-Guzmán AM, Sosa-Lozano LA, Alfaro-Lara R, et al. Vascular invasion in pancreatic cancer: predictive values for endoscopic ultrasound and computed tomography imaging. *Pancreas* 2012;**41**(4):636–8.
- Tian 2008a** *{published data only}*  
Tian YT, Wang CF, Shan Y, Zhao DB, Wang GQ, Zhao XM, et al. Prospective evaluation of ultrasonography, multi-slice spiral CT, endoscopic ultrasonography, and magnetic resonance imaging in assessment of TNM staging and assessment of resectability in pancreatic carcinoma. *Zhonghua Yi Xue Za Zhi* 2008;**88**(40):2829–32.
- Tian 2008b** *{published data only}*  
Tian YT, Wang CF, Wang GQ, Zhao XM, Ouyang H, Hao YZ, et al. Prospective evaluation of the clinical significance of ultrasonography, helical computed tomography, magnetic resonance imaging and endoscopic ultrasonography in the assessment of vascular invasion and lymph node metastasis of pancreatic carcinoma. *Zhonghua Yi Xue Za Zhi* 2008;**30**(9):682–5.
- Tian 2008c** *{published data only}*  
Tian YT, Wang CF, Zhao XM, Wang GQ, Ou YH, Hao YZ, et al. Prospective comparison of ultrasonography, helical computed tomography, magnetic resonance imaging, and endoscopic ultrasonography in assessing locoregional invasion of primary pancreatic carcinoma. *Zhonghua Zhong Liu Za Zhi* 2008;**30**(4):270–3.
- Tierney 2001** *{published data only}*  
Tierney WM, Francis IR, Eckhauser F, Elta G, Nostrant TT, Scheiman JM. The accuracy of EUS and helical CT in the assessment of vascular invasion by peripapillary malignancy. *Gastrointestinal Endoscopy* 2001;**53**(2):182–8.
- Tio 1986** *{published data only}*  
Tio TL, Tytgat GN. Endoscopic ultrasonography in staging local resectability of pancreatic and periampullary malignancy. *Scandinavian Journal of Gastroenterology - Supplement* 1986;**123**:135–42.
- Tio 1988** *{published data only}*  
Tio TL, Houthoff HJ, Tytgat GNJ, Ligidakis N, Vanderheyde. Endoscopic ultrasonography (EUS) in the preoperative staging of pancreatic and papillary carcinoma. *Gastroenterology* 1988;**94**(5):A461.
- Tio 1990** *{published data only}*  
Tio TL, Tytgat GN, Cikot RJ, Houthoff HJ, Sars PR. Ampullopapillary carcinoma: preoperative TNM classification with endosonography. *Radiology* 1990;**175**(2):455–61.
- Tio 1996** *{published data only}*  
Tio TL, Sie LH, Kallimianis G, Luiken GJ, Kimmings AN, Huijbregtse K, et al. Staging of ampullary and pancreatic carcinoma: comparison between endosonography and surgery. *Gastrointestinal Endoscopy* 1996;**44**(6):706–13.
- Tomazic 2000** *{published data only}*  
Tomazic A, Pegan V. Preoperative staging of periampullary cancer with US, CT, EUS and Ca 19-9. *Hepato-Gastroenterology* 2000;**47**(34):1135–7.
- Tomić 2005** *{published data only}*  
Tomić D, Pavlović A, Krstić M, Jesić R, Janković G, Uglješić M, et al. Endoscopic ultrasonography in pancreatic carcinoma. *Acta Chirurgica Iugoslavica* 2005;**52**(1):65–72.
- Trede 1997** *{published data only}*  
Trede M, Rumstadt B, Wendt K, Gaa J, Tesdal K, Lehmann KJ, et al. Ultrafast magnetic resonance imaging improves the staging of pancreatic tumors. *Annals of Surgery* 1997;**226**(4):393–405.
- Turowska 2009** *{published data only}*  
Turowska A, Lebkowska U, Walecki J. Evaluation and treatment decision of pancreatic tumors by use of MRI with MRCP imaging. *Polish Journal of Radiology* 2009;**74**(1):7–15.
- Valinas 2002** *{published data only}*  
Valinas R, Barrier A, Montravers F, Houry S, Talbot JN, Huguier M. 18 F-fluorodeoxyglucose positron emission tomography for characterization and initial staging of pancreatic tumors. *Gastroentérologie Clinique et Biologique* 2002;**26**(10):888–92.
- Wakabayashi 2008** *{published data only}*  
Wakabayashi H, Nishiyama Y, Otani T, Sano T, Yachida S, Okano K, et al. Role of 18F-fluorodeoxyglucose positron emission tomography imaging in surgery for pancreatic cancer. *World Journal of Gastroenterology* 2008;**14**(1):64–9.
- Wang 2007a** *{published data only}*  
Wang CY. Retroactive evaluation of perioperative staging and surgical decision making for patients with pancreatic

- cancer. *Zhonghua Wai Ke Za Zhi [Chinese Journal of Surgery]* 2007;**45**(1):3–5.
- Wang 2007b** *{published data only}*  
Wang DQ, Zeng MS, Jin DY, Lou WH, Ji Y, Rao SX, et al. MRI in the evaluation of peripancreatic vessel invasion and resectability of pancreatic carcinoma. *Zhonghua Zhong Liu Za Zhi [Chinese Journal of Oncology]* 2007;**29**(11):846–9.
- Wang 2008** *{published data only}*  
Wang DQ, Zeng MS, Shi X, Ji Y, Jin DY, Lou WH, et al. Comparison of MRI manifestations and histopathologic findings in pancreatic head carcinoma in vivo ex vivo. *Zhonghua Zhong Liu Za Zhi [Chinese Journal of Oncology]* 2008;**30**(5):347–51.
- Wang 2014** *{published data only}*  
Wang XY, Yang F, Jin C, Guan YH, Zhang HW, Fu DL. The value of 18F-FDG positron emission tomography/computed tomography on the pre-operative staging and the management of patients with pancreatic carcinoma. *Hepato-Gastroenterology* 2014;**61**(135):2102–9.
- Wang 2015** *{published data only}*  
Wang L, Cheng X, Yu P, Du Y, Yang L, Chen L, et al. Resectability assessment of enhanced CT and contrast-enhanced endoscopic ultrasonography for the periampullary neoplasm. *Zhonghua Yi Xue Za Zhi* 2015;**95**(24):1921–4.
- Warshaw 1990** *{published data only}*  
Warshaw AL, Gu ZY, Wittenberg J, Waltman AC. Preoperative staging and assessment of resectability of pancreatic cancer. *Archives of Surgery* 1990;**125**(2):230–3.
- Wee 2012** *{published data only}*  
Wee E, Lakhtakia S, Gupta R, Anuradha S, Shetty M, Kalapala R, et al. The diagnostic accuracy and strength of agreement between endoscopic ultrasound and histopathology in the staging of ampullary tumors. *Indian Journal of Gastroenterology* 2012;**31**(6):324–32.
- Wiersema 2000** *{published data only}*  
Wiersema MJ, Norton ID, Clain JE. Role of EUS in the evaluation of pancreatic adenocarcinoma. *Gastrointestinal Endoscopy* 2000;**52**(4):578–82.
- Woerlein 2002** *{published data only}*  
Woerlein C, Sandhu I. EUS staging of pancreatic cancer compared with LUS aided surgical staging with particular attention to vascular invasion. *Gastrointestinal Endoscopy* 2002;**55**(5):AB243.
- Xu 2014** *{published data only}*  
Xu F, Xi Y, Zhang M, Jiang XF, Guo R, Li B. Added value of 18F-FDG PET/CT for preoperative evaluation of distant metastasis of pancreatic cancer by abdominal contrast-enhanced CT. *Journal of Shanghai Jiaotong University* 2014;**34**(12):1762–6.
- Yao 2012** *{published data only}*  
Yao J, Gan G, Farlow D, Laurence JM, Hollands M, Richardson A, et al. Impact of F18-fluorodeoxyglycose positron emission tomography/computed tomography on the management of resectable pancreatic tumours. *ANZ Journal of Surgery* 2012;**82**(3):140–4.
- Yasuda 1988** *{published data only}*  
Yasuda K, Mukai H, Cho E, Nakajima M, Kawai K. The use of endoscopic ultrasonography in the diagnosis and staging of carcinoma of the papilla of Vater. *Endoscopy* 1988;**20 Suppl 1**:218–22.
- Yasuda 1993** *{published data only}*  
Yasuda K, Mukai H, Nakajima M, Kawai K. Staging of pancreatic carcinoma by endoscopic ultrasonography. *Endoscopy* 1993;**25**(2):151–5.
- Yoneyama 2014** *{published data only}*  
Yoneyama T, Tateishi U, Endo I, Inoue T. Staging accuracy of pancreatic cancer: comparison between non-contrast-enhanced and contrast-enhanced PET/CT. *European Journal of Radiology* 2014;**83**(10):1734–9.
- Younes 1999** *{published data only}*  
Younes Z, Duncan MD, Bender JS, Zayat EN, Regan F, Magnuson TH. Magnetic resonance cholangiopancreatography and angiography with conventional MRI for preoperative evaluation of pancreatic cancer. *Gastroenterology* 1999;**116**(4):A1178.
- Yusoff 2003** *{published data only}*  
Yusoff IF, Mendelson RM, Edmunds SE, Ramsay D, Cullingford GL, Fletcher DR, et al. Preoperative assessment of pancreatic malignancy using endoscopic ultrasound. *Abdominal Imaging* 2003;**28**(4):556–62.
- Zhang 2012** *{published data only}*  
Zhang WJ, Wu N, Zhou CW, Zheng R, Liu Y, Liang Y, et al. Value of 18FDG PET/CT and contrast-enhanced CT in staging of pancreatic cancer. *Chinese Journal of Medical Imaging Technology* 2012;**28**(4):727–30.
- Zhang 2015** *{published data only}*  
Zhang J, Zuo CJ, Jia NY, Wang JH, Hu SP, Yu ZF, et al. Cross-modality PET/CT and contrast-enhanced CT imaging for pancreatic cancer. *World Journal of Gastroenterology* 2015;**21**(10):2988–96.
- Zhong 2005** *{published data only}*  
Zhong L, Li L, Yao QY. Preoperative evaluation of pancreaticobiliary tumor using MR multi-imaging techniques. *World Journal of Gastroenterology* 2005;**11**(24):3756–61.

## Additional references

- Abrams 2009**  
Abrams RA, Lowy AM, O'Reilly EM, Wolff RA, Picozzi VJ, Pisters PW. Combined modality treatment of resectable and borderline resectable pancreas cancer: expert consensus statement. *Annals of Surgical Oncology* 2009;**16**(7):1751–6.
- Allen 2016**  
Allen VB, Gurusamy KS, Takwoingi Y, Kalia A, Davidson BR. Diagnostic accuracy of laparoscopy following computed tomography (CT) scanning for assessing the resectability with curative intent in pancreatic and periampullary cancer. *Cochrane Database of Systematic Reviews* 2016, Issue 7. [DOI: 10.1002/14651858.CD009323.pub3]

**British Management Guideline 2005**

Pancreatic Section British Society of Gastroenterology, Pancreatic Society of Great Britain and Ireland, Association of Upper Gastrointestinal Surgeons of Great Britain and Ireland, Royal College of Pathologists, Special Interest Group for Gastro-Intestinal Radiology. Guidelines for the management of patients with pancreatic cancer periampullary and ampullary carcinomas. *Gut* 2005;**54** (Suppl 5):v1–16.

**Cameron 1993**

Cameron JL, Pitt HA, Yeo CJ, Lillemoe KD, Kaufman HS, Coleman J. One hundred and forty-five consecutive pancreaticoduodenectomies without mortality. *Annals of Surgery* 1993;**217**(5):430-5; discussion 435-8.

**Chu 2006**

Chu H, Cole SR. Bivariate meta-analysis of sensitivity and specificity with sparse data: a generalized linear mixed model approach. *Journal of Clinical Epidemiology* 2006;**59** (12):1331–2.

**Conlon 1996**

Conlon KC, Klimstra DS, Brennan MF. Long-term survival after curative resection for pancreatic ductal adenocarcinoma. Clinicopathologic analysis of 5-year survivors. *Annals of Surgery* 1996;**223**(3):273–9.

**Eloubeidi 2001**

Eloubeidi MA, Wade SB, Provenzale D. Factors associated with acceptance and full publication of GI endoscopic research originally published in abstract form. *Gastrointestinal Endoscopy* 2001;**53**(3):275–82.

**Engelken 2003**

Engelken FJ, Bettschart V, Rahman MQ, Parks RW, Garden OJ. Prognostic factors in the palliation of pancreatic cancer. *European Journal of Surgical Oncology* 2003;**29**(4):368–73.

**Hariharan 2010**

Hariharan D, Constantinides VA, Froeling FE, Tekkis PP, Kocher HM. The role of laparoscopy and laparoscopic ultrasound in the preoperative staging of pancreatico-biliary cancers--A meta-analysis. *European Journal of Surgical Oncology* 2010;**36**(10):941–8.

**Haynes 2004**

Haynes RB, Wilczynski NL. Optimal search strategies for retrieving scientifically strong studies of diagnosis from medline: analytical survey. *BMJ* 2004;**328**(7447):1040.

**IARC 2014**

International Agency for Research on Cancer. GLOBOCAN 2012. <http://globocan.iarc.fr/Default.aspx> (accessed 19 January 2014).

**Klempnauer 1995**

Klempnauer J, Ridder GJ, Pichlmayr R. Prognostic factors after resection of ampullary carcinoma: multivariate survival analysis in comparison with ductal cancer of the pancreatic head. *British Journal of Surgery* 1995;**82**(12):1686–91.

**Liao 2013**

Liao WC, Chien KL, Lin YL, Wu MS, Lin JT, Wang HP, et al. Adjuvant treatments for resected pancreatic

adenocarcinoma: a systematic review and network meta-analysis. *Lancet Oncology* 2013;**14**(11):1095–103.

**Livingston 1991**

Livingston EH, Welton ML, Reber HA. Surgical treatment of pancreatic cancer. The United States experience. *International Journal of Pancreatology* 1991;**9**:153–7.

**Michelassi 1989**

Michelassi F, Erroi F, Dawson PJ, Pietrabissa A, Noda S, Handcock M, et al. Experience with 647 consecutive tumors of the duodenum, ampulla, head of the pancreas, and distal common bile duct. *Annals of Surgery* 1989;**210** (4):544-54; discussion 554-6.

**National Cancer Institute 2014a**

National Cancer Institute (U.S. National Institute of Health). Dictionary of Cancer terms. Periampullary cancer. [www.cancer.gov/dictionary/?CdrID=543930](http://www.cancer.gov/dictionary/?CdrID=543930) (accessed 22 July 2014).

**National Cancer Institute 2014b**

National Cancer Institute (U.S. National Institute of Health). Dictionary of Cancer terms. CT scan. [www.cancer.gov/dictionary/?CdrID=46033](http://www.cancer.gov/dictionary/?CdrID=46033) (accessed 22 July 2014).

**National Cancer Institute 2014c**

National Cancer Institute (U.S. National Institute of Health). Dictionary of Cancer terms. Magnetic resonance imaging. [www.cancer.gov/dictionary/?CdrID=45997](http://www.cancer.gov/dictionary/?CdrID=45997) (accessed 22 July 2014).

**National Cancer Institute 2014d**

National Cancer Institute (U.S. National Institute of Health). Dictionary of Cancer terms. Positron emission tomography scan. [www.cancer.gov/dictionary/?CdrID=46218](http://www.cancer.gov/dictionary/?CdrID=46218) (accessed 22 July 2014).

**National Cancer Institute 2014e**

National Cancer Institute (U.S. National Institute of Health). Dictionary of Cancer terms. PET-CT scan. [www.cancer.gov/dictionary/?CdrID=742485](http://www.cancer.gov/dictionary/?CdrID=742485) (accessed 22 July 2014).

**National Cancer Institute 2014f**

National Cancer Institute (U.S. National Institute of Health). Dictionary of Cancer terms. Endoscopic ultrasound. [www.cancer.gov/dictionary/?CdrID=46602](http://www.cancer.gov/dictionary/?CdrID=46602) (accessed 22 July 2014).

**Niederhuber 1995**

Niederhuber JE, Brennan MF, Menck HR. The National Cancer Data Base report on pancreatic cancer. *Cancer* 1995;**76**(9):1671–7.

**Nitecki 1995**

Nitecki SS, Sarr MG, Colby TV, van Heerden JA. Long-term survival after resection for ductal adenocarcinoma of the pancreas. Is it really improving?. *Annals of Surgery* 1995;**221**(1):59–66.

**Orr 2010**

Orr RK. Outcomes in pancreatic cancer surgery. *Surgical Clinics of North America* 2010;**90**(2):219–34.

**Parkin 2001**

Parkin DM, Bray FI, Devesa SS. Cancer burden in the year 2000. The global picture. *European Journal of Cancer* 2001; **37**(Suppl 8):S4–66.

**Parkin 2005**

Parkin DM, Bray F, Ferlay J, Pisani P. Global cancer statistics, 2002. *CA: A Cancer Journal for Clinicians* 2005; **55**(2):74–108.

**Reitsma 2005**

Reitsma JB, Glas AS, Rutjes AW, Scholten RJ, Bossuyt PM, Zwinderman AH. Bivariate analysis of sensitivity and specificity produces informative summary measures in diagnostic reviews. *Journal of Clinical Epidemiology* 2005; **58**(10):982–90.

**RevMan 2014 [Computer program]**

The Nordic Cochrane Centre, The Cochrane Collaboration. Review Manager (RevMan). Version 5.3. Copenhagen: The Nordic Cochrane Centre, The Cochrane Collaboration, 2014.

**Sampson 2008**

Sampson M, Shojania KG, McGowan J, Daniel R, Rader T, Iansavichene AE, et al. Surveillance search techniques identified the need to update systematic reviews. *Journal of Clinical Epidemiology* 2008; **61**(8):755–62.

**Shahrudin 1997**

Shahrudin MD. Carcinoma of the pancreas: resection outcome at the University Hospital Kuala Lumpur. *International Surgery* 1997; **82**(3):269–74.

**Smith 2008**

Smith RA, Bosonnet L, Ghaneh P, Sutton R, Evans J, Healey P, et al. The platelet-lymphocyte ratio improves the predictive value of serum CA19-9 levels in determining patient selection for staging laparoscopy in suspected periampullary cancer. *Surgery* 2008; **143**(5):658–66.

**Takwoingi 2015**

Takwoingi Y, Guo B, Riley RD, Deeks JJ. Performance of methods for meta-analysis of diagnostic test accuracy with

few studies or sparse data. *Statistical Methods in Medical Research* 2015 Jun 26 [Epub ahead of print]. [DOI: 10.1177/0962280215592269]

**Trede 1990**

Trede M, Schwall G, Saeger HD. Survival after pancreatoduodenectomy. 118 consecutive resections without an operative mortality. *Annals of Surgery* 1990; **211**(4):447–58.

**Whiting 2006**

Whiting PF, Weswood ME, Rutjes AW, Reitsma JB, Bossuyt PN, Kleijnen J. Evaluation of QUADAS, a tool for the quality assessment of diagnostic accuracy studies. *BMC Medical Research Methodology* 2006; **6**:9.

**Whiting 2011**

Whiting PF, Rutjes AW, Westwood ME, Mallett S, Deeks JJ, Reitsma JB, et al. QUADAS-2: a revised tool for the quality assessment of diagnostic accuracy studies. *Annals of Internal Medicine* 2011; **155**(8):529–36.

**Wilczynski 2005**

Wilczynski NL, Haynes RB, Hedges Team. EMBASE search strategies for identifying methodologically sound diagnostic studies for use by clinicians and researchers. *BMC Medicine* 2005; **3**:7.

**Yamamoto 1998**

Yamamoto M, Ohashi O, Saitoh Y. Japan Pancreatic Cancer Registry: current status. *Pancreas* 1998; **16**(3):238–42.

**References to other published versions of this review****Gurusamy 2015**

Gurusamy KS, Davidson BR. Diagnostic accuracy of different imaging modalities following computed tomography (CT) scanning for assessing the resectability with curative intent in pancreatic and periampullary cancer. *Cochrane Database of Systematic Reviews* 2015, Issue 2. [DOI: 10.1002/14651858.CD011515]

\* Indicates the major publication for the study



## CHARACTERISTICS OF STUDIES

### Characteristics of included studies [ordered by study ID]

#### Ahmad 2001

Study characteristics			
Patient sampling	Type of study: prospective study. Consecutive or random sample: unclear.		
Patient characteristics and setting	Sample size: 21. Females: 5 (23.8%). Age: 61 years. Presentation: 1. Patients undergoing potentially curative resection for pancreatic cancer. 2. Deemed to be resectable by previous cross-sectional imaging. Setting: secondary/tertiary centre, USA.		
Index tests	Index test: endoscopic ultrasound (EUS). Further details: Technical specifications: Olympus (model: GF-UM20). Performed by: endoscopists. Criteria for positive diagnosis: vascular involvement as indicated by the loss of the hyperechoic vessel wall/tumour interface, direct visualization of the tumour in the vascular lumen, and nonvisualisation of a major vessel in the presence of collaterals. Preoperative imaging study criteria (by EUS or SVA) for unresectability of pancreatic tumour included encasement or occlusion of the celiac axis, portal vein, hepatic artery, superior mesenteric vein, or superior mesenteric artery		
Target condition and reference standard(s)	Target condition: unresectability. Reference standard: surgical resection. Further details: Technical specifications: not applicable. Performed by: surgeons. Criteria for positive diagnosis: vascular invasion.		
Flow and timing	Number of indeterminates for whom the results of reference standard was available: 0 (0%). Number of patients who were excluded from the analysis: 0 (0%)		
Comparative			
Notes	Cross-sectional imaging used as pre-test (all underwent computed tomography (CT) scan, some underwent ultrasound) The study authors provided additional information regarding "Risk of bias" items and cross-sectional imaging used		
Methodological quality			
Item	Authors' judgement	Risk of bias	Applicability concerns

<b>DOMAIN 1: Patient Selection</b>			
Was a consecutive or random sample of patients enrolled?	Yes		
Was a case-control design avoided?	Yes		
Did the study avoid inappropriate exclusions?	Yes		
		<b>Low</b>	
<b>DOMAIN 2: Index Test All tests</b>			
Were the index test results interpreted without knowledge of the results of the reference standard?	Yes		
		<b>Low</b>	
<b>DOMAIN 3: Reference Standard</b>			
Is the reference standards likely to correctly classify the target condition?	Unclear		
Were the reference standard results interpreted without knowledge of the results of the index tests?	No		
		<b>Low</b>	
<b>DOMAIN 4: Flow and Timing</b>			
Was there an appropriate interval between index test and reference standard?	Yes		
Did all patients receive the same reference standard?	Yes		
Were all patients included in the analysis?	Yes		

## Ardengh 2003

Study characteristics	
Patient sampling	Type of study: retrospective study. Consecutive or random sample: unclear.
Patient characteristics and setting	Sample size: 17. Females: 11 (64.7%). Age: 64 years. Presentation: 1. Patients undergoing potentially curative resection for pancreatic cancer (head of pancreas less than 3 cm in diameter). 2. Deemed to be resectable by previous ultrasound and CT scan. Setting: secondary/tertiary centre, Brazil.
Index tests	Index test: EUS. Further details: Technical specifications: Pentax sectorial scanning echoendoscope (model: FG 32-UA or FG 36-UX). Performed by: endoscopists. Criteria for positive diagnosis: tumour invading portal system or superior mesenteric artery (irregularity of the vessel wall or invasion by tumour or thrombus)
Target condition and reference standard(s)	Target condition: unresectability. Reference standard: surgical resection. Further details: Technical specifications: not applicable. Performed by: surgeons. Criteria for positive diagnosis: not stated.
Flow and timing	Number of indeterminates for whom the results of reference standard was available: not stated. Number of patients who were excluded from the analysis: not stated
Comparative	
Notes	The study used ultrasound and CT scan as a pre-test.

### Methodological quality

Item	Authors' judgement	Risk of bias	Applicability concerns
<b>DOMAIN 1: Patient Selection</b>			
Was a consecutive or random sample of patients enrolled?	Unclear		
Was a case-control design avoided?	Yes		

**Ardengh 2003** (Continued)

Did the study avoid inappropriate exclusions?	No			
				<b>Low</b>
<b>DOMAIN 2: Index Test All tests</b>				
Were the index test results interpreted without knowledge of the results of the reference standard?	Unclear			
				<b>Low</b>
<b>DOMAIN 3: Reference Standard</b>				
Is the reference standards likely to correctly classify the target condition?	Yes			
Were the reference standard results interpreted without knowledge of the results of the index tests?	Unclear			
				<b>Low</b>
<b>DOMAIN 4: Flow and Timing</b>				
Was there an appropriate interval between index test and reference standard?	Unclear			
Did all patients receive the same reference standard?	Yes			
Were all patients included in the analysis?	Unclear			

Abbreviations: CT: computed tomography.

**Characteristics of excluded studies** *[ordered by study ID]*

Study	Reason for exclusion
Abe 2010	Not in patients with computed tomography (CT) resectable pancreatic cancer
Agarwal 2005	Not in patients undergoing pancreatic resections
Ahmad 1999	Not in patients with CT resectable pancreatic cancer
Ahmad 2000a	Not in patients with CT resectable pancreatic cancer
Ahmad 2000b	No diagnostic test accuracy data on unresectability
Ahmad 2000c	Not in patients with CT resectable pancreatic cancer
Ahmad 2000d	Not in patients with CT resectable pancreatic cancer
Akahoshi 1998	Not in patients with CT resectable pancreatic cancer
Anand 2013	Not in patients with CT resectable pancreatic cancer
Arabul 2012	No separate data on patients with pancreatic cancer
Arslan 2001	No diagnostic test accuracy data on unresectability
Artifon 2009	No diagnostic test accuracy data on unresectability
Asagi 2013	No diagnostic test accuracy data on unresectability
Aslanian 2005	No diagnostic test accuracy data on unresectability
Aubertin 1996	Not in patients with CT resectable pancreatic cancer
Awad 1997	Not in patients with CT resectable pancreatic cancer
Baarir 1998	Not in patients with CT resectable pancreatic cancer
Baghbanian 2014	No diagnostic test accuracy data on unresectability
Bao 2008	Not in patients with CT resectable pancreatic cancer
Barthet 2007	Review/editorial/letter to editor/commentary
Bettini 2005	Not in patients with CT resectable pancreatic cancer
Broglia 2001	Not in patients with CT resectable pancreatic cancer

(Continued)

Brugge 1995	Review/editorial/letter to editor/commentary
Brugge 1996	No diagnostic test accuracy data on unresectability
Buchs 2007	No separate data on patients with pancreatic cancer
Burge 2015	Not in patients with CT resectable pancreatic cancer
Buscall 1999	No diagnostic test accuracy data on unresectability
Cahn 1996	No diagnostic test accuracy data on unresectability
Carroll 1999	Not in patients with CT resectable pancreatic cancer
Casneuf 2007	No separate data on patients with pancreatic cancer
Catalano 1997	Not in patients with CT resectable pancreatic cancer
Catalano 1998	Not in patients with CT resectable pancreatic cancer
Chandler 1999	Not in patients with CT resectable pancreatic cancer
Chang 1997	No diagnostic test accuracy data on unresectability
Chen 2001a	No diagnostic test accuracy data on unresectability
Chen 2001b	No diagnostic test accuracy data on unresectability
Chen 2009	No diagnostic test accuracy data on unresectability
Chhibber 2006	Not in patients with CT resectable pancreatic cancer
Chiang 2012	No diagnostic test accuracy data on unresectability
Chiang 2014	Not in patients with CT resectable pancreatic cancer
Cieslak 2012	No separate data on patients with pancreatic cancer
Cieslak 2013	No separate data on patients with pancreatic cancer
Cieslak 2014	Not in patients with CT resectable pancreatic cancer
Costilla 2011	No diagnostic test accuracy data on unresectability
Crippa 2013	Not in patients with CT resectable pancreatic cancer

(Continued)

Crippa 2014	Not in patients with CT resectable pancreatic cancer
Croome 2010	No diagnostic test accuracy data on unresectability
Czako 2009	No diagnostic test accuracy data on unresectability
Delbeke 1999	No diagnostic test accuracy data on unresectability
Dewitt 2003	No separate data on patients with pancreatic cancer
DeWitt 2004	Not in patients with CT resectable pancreatic cancer
Egorov 2012	Not in patients with CT resectable pancreatic cancer
Egorov 2013	No diagnostic test accuracy data on unresectability
Einersen 2013	Not in patients with CT resectable pancreatic cancer
Einersen 2014	No diagnostic test accuracy data on unresectability
Eloubeidi 2006	No diagnostic test accuracy data on unresectability
Eloubeidi 2007	No diagnostic test accuracy data on unresectability
Erickson 2000	No diagnostic test accuracy data on unresectability
Faigel 1996	Review/editorial/letter to editor/commentary
Farma 2008a	Not in patients with CT resectable pancreatic cancer
Farma 2008b	No diagnostic test accuracy data on unresectability
Fischer 2002	Not in patients with CT resectable pancreatic cancer
Fockens 1993	Review/editorial/letter to editor/commentary
Freeny 2001	Review/editorial/letter to editor/commentary
Frohlich 1999	Not in patients with CT resectable pancreatic cancer
García-Cano 2002	Review/editorial/letter to editor/commentary
Gaspar 2015	Review/editorial/letter to editor/commentary
Goh 2006	Review/editorial/letter to editor/commentary

(Continued)

Grenacher 2004	Not in patients with CT resectable pancreatic cancer
Gress 1997	No diagnostic test accuracy data on unresectability
Gress 1999	No diagnostic test accuracy data on unresectability
Harrison 1999	No diagnostic test accuracy data on unresectability
Heinrich 2005	No diagnostic test accuracy data on unresectability
Helmreich 2004	No diagnostic test accuracy data on unresectability
Hemmingsson 1982	No diagnostic test accuracy data on unresectability
Hirokawa 2010	No diagnostic test accuracy data on unresectability
Ho 2008	No separate data on patients with pancreatic cancer
Hochwald 1999	Not in patients with CT resectable pancreatic cancer
Holzapfel 2011	No diagnostic test accuracy data on unresectability
Howard 1997	Not in patients with CT resectable pancreatic cancer
Hu 2015	Not in patients with CT resectable pancreatic cancer
Ichikawa 1997	Not in patients with CT resectable pancreatic cancer
Iglesias-Garcia 2010	Not in patients with CT resectable pancreatic cancer
Imazu 2010	Not in patients with CT resectable pancreatic cancer
Izuishi 2010	Not in patients with CT resectable pancreatic cancer
Javery 2013	Not in patients with CT resectable pancreatic cancer
Jemaa 2008	Not in patients with CT resectable pancreatic cancer
Kadish 1995	No diagnostic test accuracy data on unresectability
Kala 2007	Not in patients with CT resectable pancreatic cancer
Karoumpalis 2011	Not in patients with CT resectable pancreatic cancer
Kim 2001	Not in patients with CT resectable pancreatic cancer



(Continued)

Kim 2012	Not in patients with CT resectable pancreatic cancer
Kim 2015	No diagnostic test accuracy data on unresectability
Koelblinger 2011	Not in patients with CT resectable pancreatic cancer
Koranda 2009	Not in patients with CT resectable pancreatic cancer
Koranda 2010	Not in patients with CT resectable pancreatic cancer
Kulig 2004	Not in patients with CT resectable pancreatic cancer
Kysucan 2010	Not in patients with CT resectable pancreatic cancer
Lakhtakia 2011	No diagnostic test accuracy data on unresectability
Latronico 2005	Not in patients with CT resectable pancreatic cancer
Lee 2002	Not in patients with CT resectable pancreatic cancer
Lee 2010	Not in patients with CT resectable pancreatic cancer
Lentschig 1996	Not in patients with CT resectable pancreatic cancer
Lopez-Hänninen 2002	Not in patients with CT resectable pancreatic cancer
Lu 2006	No separate data on patients with pancreatic cancer
Lytras 2005	No separate data on patients with pancreatic cancer
Lévy 2001	Review/editorial/letter to editor/commentary
Makowiec 2000	Not in patients with CT resectable pancreatic cancer
Malferteiner 2005	Review/editorial/letter to editor/commentary
Maluf-Filho 2004	Not in patients with CT resectable pancreatic cancer
Mansfield 2008	Not in patients with CT resectable pancreatic cancer
McFarland 1996	Not in patients with CT resectable pancreatic cancer
Megibow 1995	Not in patients with CT resectable pancreatic cancer
Mehmet 2006	No diagnostic test accuracy data on unresectability

(Continued)

Melzer 1996	Not in patients with CT resectable pancreatic cancer
Mertz 2000	Not in patients with CT resectable pancreatic cancer
Morris-Stiff 2011	No diagnostic test accuracy data on unresectability
Motosugi 2011	Not in patients with CT resectable pancreatic cancer
Mukai 1991	Not in patients with CT resectable pancreatic cancer
Murakami 1996	Not in patients with CT resectable pancreatic cancer
Nakamoto 1999	Not in patients with CT resectable pancreatic cancer
Napolitano 2002	Not in patients with CT resectable pancreatic cancer
Neoptolemos 2005	Review/editorial/letter to editor/commentary
Nishiharu 1999	Not in patients with CT resectable pancreatic cancer
Palazzo 1993	Not in patients with CT resectable pancreatic cancer
Pan 2014	No separate data on patients with pancreatic cancer
Pappas 2011	Review/editorial/letter to editor/commentary
Park 2009	Not in patients with CT resectable pancreatic cancer
Patel 2002a	Not in patients with CT resectable pancreatic cancer
Patel 2002b	Not in patients with CT resectable pancreatic cancer
Paul 2012	Not in patients with CT resectable pancreatic cancer
Prithiviraj 2013	No diagnostic test accuracy data on unresectability
Raj 2013	No diagnostic test accuracy data on unresectability
Ramsay 2004	Not in patients with CT resectable pancreatic cancer
Razzaque 2012	Not in patients with CT resectable pancreatic cancer
Reiser-Erkan 2009	Not in patients with CT resectable pancreatic cancer
Reiser-Erkan 2010	Not in patients with CT resectable pancreatic cancer

(Continued)

Ren 2006	Not in patients with CT resectable pancreatic cancer
Riditid 2015	Not in patients with CT resectable pancreatic cancer
Rivadeneira 2003	Not in patients with CT resectable pancreatic cancer
Romijn 2000	Not in patients with CT resectable pancreatic cancer
Rösch 1992a	Not in patients with CT resectable pancreatic cancer
Rösch 1992b	Not in patients with CT resectable pancreatic cancer
Rösch 1992c	Review/editorial/letter to editor/commentary
Rösch 2000	No diagnostic test accuracy data on unresectability
Saif 2008	No diagnostic test accuracy data on unresectability
Schima 2002	No separate data on patients with pancreatic cancer
Schmidt 2004	Not in patients with CT resectable pancreatic cancer
Schwarz 2001	Not in patients with CT resectable pancreatic cancer
Seicean 2008	Not in patients with CT resectable pancreatic cancer
Shami 2011	Not in patients with CT resectable pancreatic cancer
Sheng 2012	Not in patients with CT resectable pancreatic cancer
Shin 2013	Review/editorial/letter to editor/commentary
Shoup 2000	No diagnostic test accuracy data on unresectability
Sironi 1995	No diagnostic test accuracy data on unresectability
Sironi 1996	No diagnostic test accuracy data on unresectability
Skordilis 2002	No diagnostic test accuracy data on unresectability
Smedby 1997	Not in patients with CT resectable pancreatic cancer
Snady 1993	Review/editorial/letter to editor/commentary
Snady 1994	No diagnostic test accuracy data on unresectability

(Continued)

Solodinina 2014a	No diagnostic test accuracy data on unresectability
Solodinina 2014b	Not in patients with CT resectable pancreatic cancer
Soriano 2001	Not in patients with CT resectable pancreatic cancer
Soriano 2004	Not in patients with CT resectable pancreatic cancer
Spencer 1998	No diagnostic test accuracy data on unresectability
Staib 1997	No diagnostic test accuracy data on unresectability
Strobel 2008	Not in patients with CT resectable pancreatic cancer
Takaori 2007	No separate data on patients with pancreatic cancer
Takayama 2009	No diagnostic test accuracy data on unresectability
Tapper 2010	Not in patients with CT resectable pancreatic cancer
Tellez-Avila 2012	No diagnostic test accuracy data on unresectability
Tian 2008a	Not in patients with CT resectable pancreatic cancer
Tian 2008b	Not in patients with CT resectable pancreatic cancer
Tian 2008c	Not in patients with CT resectable pancreatic cancer
Tierney 2001	Not in patients with CT resectable pancreatic cancer
Tio 1986	Not in patients with CT resectable pancreatic cancer
Tio 1988	Not in patients with CT resectable pancreatic cancer
Tio 1990	Not in patients with CT resectable pancreatic cancer
Tio 1996	No diagnostic test accuracy data on unresectability
Tomazic 2000	No separate data on patients with pancreatic cancer
Tomić 2005	Not in patients with CT resectable pancreatic cancer
Trede 1997	Not in patients with CT resectable pancreatic cancer
Turowska 2009	Not in patients with CT resectable pancreatic cancer

(Continued)

Valinas 2002	Not in patients with CT resectable pancreatic cancer
Wakabayashi 2008	Not in patients with CT resectable pancreatic cancer
Wang 2007a	Review/editorial/letter to editor/commentary
Wang 2007b	Not in patients with CT resectable pancreatic cancer
Wang 2008	No diagnostic test accuracy data on unresectability
Wang 2014	No diagnostic test accuracy data on unresectability
Wang 2015	Not in patients with CT resectable pancreatic cancer
Warshaw 1990	Not in patients with CT resectable pancreatic cancer
Wee 2012	No diagnostic test accuracy data on unresectability
Wiersema 2000	Review/editorial/letter to editor/commentary
Woerlein 2002	Not in patients with CT resectable pancreatic cancer
Xu 2014	Not in patients undergoing pancreatic resections
Yao 2012	No diagnostic test accuracy data on unresectability
Yasuda 1988	No diagnostic test accuracy data on unresectability
Yasuda 1993	No diagnostic test accuracy data on unresectability
Yoneyama 2014	No diagnostic test accuracy data on unresectability
Younes 1999	Not in patients with CT resectable pancreatic cancer
Yusoff 2003	Not in patients with CT resectable pancreatic cancer
Zhang 2012	No diagnostic test accuracy data on unresectability
Zhang 2015	No diagnostic test accuracy data on unresectability
Zhong 2005	Not in patients with CT resectable pancreatic cancer

Abbreviations: CT: computed tomography.

## DATA

Presented below are all the data for all of the tests entered into the review.

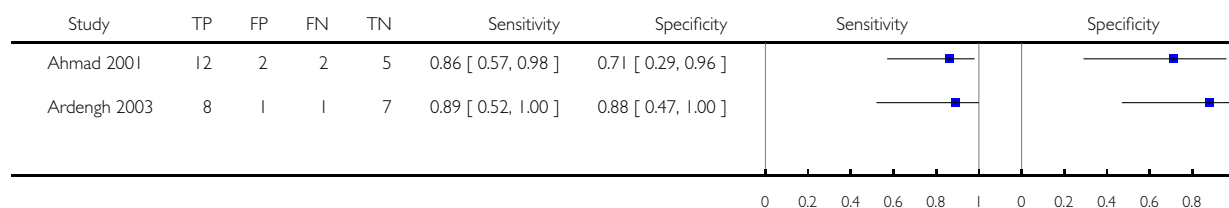
### Tests. Data tables by test

Test	No. of studies	No. of participants
1 EUS	2	38

#### Test 1. EUS.

Review: Diagnostic accuracy of different imaging modalities following computed tomography (CT) scanning for assessing the resectability with curative intent in pancreatic and periampullary cancer

Test: 1 EUS



## ADDITIONAL TABLES

Table 1. QUADAS-2 classification

<b>Domain 1: patient selection</b>	Patient sampling	Patients with pancreatic and periampullary cancer considered eligible for surgical resection following a computed tomography (CT) scan
	Was a consecutive or random sample of patients enrolled?	Yes: if the study included a consecutive sample or a random sample of patients with pancreatic and periampullary cancer eligible for surgical resection after CT scan. No: if the study did not include a consecutive sample or a random sample of patients with pancreatic and periampullary cancer

**Table 1. QUADAS-2 classification** (Continued)

		eligible for surgical resection after CT scan. Unclear: if this information was unavailable.
	Was a case-control design avoided?	Yes: if the study assessed a cohort of patients about to undergo surgical resection. No: if the study compared patients who underwent unsuccessful laparotomy (cases) with patients who underwent successful surgical resection (controls). We planned to exclude such studies but did not find any case-control studies that met the other inclusion criteria. Unclear: as anticipated, we were able to determine whether the design was case-control
	Did the study avoid inappropriate exclusions?	Yes: if the study included all patients with pancreatic and periampullary cancer eligible for surgical resection. No: if the study excluded patients based on high probability of resectability (for example, small tumours). Unclear: if this information was unavailable.
	Could the selection of patients have introduced bias?	Low risk of bias: if “yes” classification for all the above 3 questions High risk of bias: if “no” classification for any of the above 3 questions Unclear risk of bias: if “unclear” classification for any of the above 3 questions but without a “no” classification for any of the above 3 questions
	Patient characteristics and setting	Yes: we included only patients with pancreatic and periampullary cancer who were considered eligible for surgical resection following a CT scan. So, we anticipated that we would classify all the included studies as “yes”. No: we excluded studies that considered patients unsuitable for surgery after a CT scan. So, we did not use this classification. Unclear: we excluded studies in which it is unclear whether the patients had undergone CT scan following which they were still considered suitable for surgical resection. So, we classified all studies included

**Table 1. QUADAS-2 classification** (Continued)

		in the review as “yes” for this item, as anticipated
	Are there concerns that the included patients and setting do not match the review question?	Considering the inclusion criteria of this review, as anticipated, we classified all the included studies as “low concern”
<b>Domain 2: index test</b>	Index test(s)	Magnetic resonance imaging (MRI), positron emission tomography (PET), PET-CT, endoscopic ultrasound (EUS)
	Were the index test results interpreted without knowledge of the results of the reference standard?	The index test would always be conducted though not interpreted before the reference standard Yes: if the index test was conducted and interpreted without the knowledge of the results of the reference standard. No: if the index test was interpreted with the knowledge of the results of the reference standard. Unclear: if it was unclear whether the index test was interpreted without the knowledge of the results of the reference standard
	If a threshold was used, was it prespecified?	Not applicable.
	Could the conduct or interpretation of the index test have introduced bias?	Low risk of bias: if “yes” classification for the only relevant question in this domain High risk of bias: if “no” classification for the only relevant question in this domain Unclear risk of bias: if “unclear” classification for the only relevant question in this domain
	Are there concerns that the index test, its conduct, or interpretation differ from the review question?	Low concern: if the criteria for positive index test was clearly stated High concern: if the criteria for positive index test was not stated
<b>Domain 3: target condition and reference standard</b>	Target condition and reference standard(s)	Unresectability. The reasons for unresectability include involvement of adjacent structures or distant metastases. There is currently no universal criteria for unresectability. Consensus exists for the definition of borderline resectable cancers (Abrams 2009). Therefore, where there is less tissue involvement than in a borderline resectable cancer the tumour can be con-



**Table 1. QUADAS-2 classification** (Continued)

		<p>sidered as resectable</p> <p>Positive reference standard: confirmation of liver or peritoneal involvement by histopathological examination of suspicious (liver or peritoneal) lesions (irrespective of how the tissues were obtained for histopathological examination). We accepted only paraffin section histology as the reference standard. We also accepted the surgeon's judgement of unresectability on laparotomy when biopsy confirmation was not possible (for example, the surgeon may not resect the tumour if it invaded the adjacent blood vessels but would not obtain a biopsy confirmation of this because of the danger posed by resecting a part of a large blood vessel). However, it should be noted that surgeon's judgement of unresectability at laparotomy is a subjective decision and is a possible source of error in the reference standard but in the absence of an ethical and true gold standard, we accepted this as a reference standard</p> <p>Negative reference standard: cancer was fully resected i.e. clear resection margins on histology</p>
	<p>Is the reference standards likely to correctly classify the target condition?</p>	<p>Yes: if histological confirmation of distant spread or local infiltration of adjacent structures making the cancer unresectable was obtained. The report on the resection margins shows clearly that the cancer had been completely resected. As anticipated, none of the included studies met these criteria because of the danger that biopsy of infiltration of adjacent structures poses.</p> <p>No: if resection margins were not clear of cancer.</p> <p>Unclear: if surgeons' judgement was used to assess unresectability or if the information about the resection margins was unavailable. As anticipated, we classified both included studies as "unclear" because the studies used the surgeons' judgement as a criterion for unresectability</p>
	<p>Were the reference standard results interpreted without knowledge of the results of the index tests?</p>	<p>Yes: if the reference standard was interpreted without the knowledge of the results of the index test.</p>

**Table 1. QUADAS-2 classification** (Continued)

		<p>No: if the reference standard was interpreted with the knowledge of the results of the index test.</p> <p>Unclear: it was unclear if the reference standard was interpreted without the knowledge of the results of the index test However, the results of the index test are unlikely to influence the results of the reference standard. So, we did not take the answer to this question into account to determine the risk of bias</p>
	Could the reference standard, its conduct, or its interpretation have introduced bias?	We determined the risk of bias as “low” if the answer to the first question was “yes”, “high” if the answer to the first question was “no”, and “unclear” if the answer to the first question was “unclear”
	Are there concerns that the target condition as defined by the reference standard does not match the question?	Considering the inclusion criteria for this review, we classified all the included studies as “low concern”, as anticipated
<b>Domain 4: flow and timing</b>	Flow and timing	The cancer may progress if there is a long time interval between index test and laparotomy. So, we chose an arbitrary time interval of 2 months as an acceptable time interval between index test and laparotomy
	Was there an appropriate interval between index test and reference standard?	<p>Yes: if the time interval between index test and laparotomy was less than 2 months.</p> <p>No: if the time interval between index test and laparotomy was more than 2 months.</p> <p>Unclear: if the time interval between index test and laparotomy was unclear</p>
	Did all patients receive the same reference standard?	<p>Yes: if all the patients received the same reference standard (we classified all the included studies as “yes”, as anticipated).</p> <p>No: if different patients received different reference standards</p> <p>Unclear: if this information was unclear.</p>
	Were all patients included in the analysis?	<p>Yes: if the study included all the patients in the analysis irrespective of whether the results were uninterpretable.</p> <p>No: if the study excluded some patients from the analysis because of uninterpretable results.</p> <p>Unclear: if this information was unclear.</p>

**Table 1. QUADAS-2 classification** (Continued)

	<p>Could the patient flow have introduced bias?</p>	<p>Low risk of bias: if “yes” classification for all the above 3 questions            High risk of bias: if “no” classification for any of the above 3 questions            Unclear risk of bias: if “unclear” classification for any of the above 3 questions but without a “no” classification for any of the above 3 questions</p>
--	---	---

Abbreviations: CT: computed tomography; EUS: endoscopic ultrasound; MRI: magnetic resonance imaging; PET: positron emission tomography.

## APPENDICES

### Appendix I. Glossary of terms

Adjuvant: treatment provided in addition to another treatment with an aim to improve the effectiveness of another treatment.

Algorithm: order in which diagnostic tests are performed and actions taken depending upon their results (in this context).

Ampulla of Vater: area where the pancreatic duct and common bile duct meet.

Chemotherapy: medication used to treat or control cancer (in this context).

Disseminated: spread of cancer (in this context).

Distal: left side of pancreas (in this context).

Duodenum: first part of the small intestine.

Histology: examination of tissues under a microscope.

Lesions: abnormal changes in the structure of all or part of an organ due to disease or injury.

Mortality: death.

Paraffin: wax.

Peritoneal: relating to the membrane that lines the walls of the abdominal and pelvic cavities.

Resection: removal of part of an organ (in this context, the pancreas).

### Appendix 2. MEDLINE (OvidSP) search strategy

(In-Process & Other Non-Indexed Citations and Ovid MEDLINE)

1. (ampulla vateri or ampullovateric or papilla vateri or vater papilla or vater ampulla or periampull\* or peri-ampull\* or choledoch\* or alcholedoch\* or bile duct\* or biliary or cholangio\* or gall duct or duoden\* or small bowel or small intestin\* or enter\* or pancrea\*).ti,ab.

2. exp “Ampulla of Vater”/su [Surgery]

3. 1 or 2

4. (carcin\* or cancer\* or neoplas\* or tumour\* or tumor\* or cyst\* or growth\* or adenocarcin\* or malign\*).ti,ab.

5. 3 and 4

6. Duodenal Neoplasms/su [Surgery]

7. exp Pancreatic Neoplasms/su [Surgery]

8. Common Bile Duct Neoplasms/su [Surgery]

9. 5 or 6 or 7 or 8

10. (surger\* or surgical\* or operat\* or resection\* or preoperative).ti,ab.

11. exp Surgical Procedures, Operative/ or General Surgery/
12. 10 or 11
13. 9 and 12
14. (pancreat\* or pancreaticojejunost\* or pancreaticogastros\* or pancreaticoduodenect\* or duodenopancreat\* or pancreato-biliary).ti,ab.
15. pancreatotomy/ or pancreaticoduodenectomy/ or pancreaticojejunostomy/
16. 13 or 14 or 15
17. (PET or MRI or NMRI or zeugmatogra\* or ((emission or positron or magneti\* or MR or NMR or proton or acoustic or ARFI) and (tomogra\* or scan or scans or imaging))).ti,ab.
18. Positron-Emission Tomography/
19. exp Magnetic Resonance Imaging/
20. 17 or 18 or 19
21. Endosonography/
22. (endosonogra\* or EUS).ti,ab.
23. (echogra\* or ultrason\* or ultrasound).ti,ab.
24. exp Ultrasonography/
25. 23 or 24
26. endoscop\*.ti,ab.
27. exp Endoscopy/
28. 26 or 27
29. 25 and 28
30. 20 or 21 or 22 or 29
31. 16 and 30
32. sensitiv:.mp. OR diagnos:.mp. OR di.fs.
33. 31 and 32

### Appendix 3. Embase (OvidSP) search strategy

1. ((ampulla vateri or ampullovateric or papilla vateri or vater papilla or vater ampulla or periampull\* or peri-ampull\* or choledoch\* or alcholedoch\* or bile duct\* or biliary or cholangio\* or gall duct or duoden\* or small bowel or small intestine\* or pancrea\*) and (carcin\* or cancer\* or neoplas\* or tumour\* or tumor\* or cyst\* or growth\* or adenocarcin\* or malign\*)).ti,ab.
2. exp duodenum cancer/su [Surgery]
3. Vater papilla tumor/su [Surgery]
4. exp pancreas cancer/su [Surgery]
5. exp bile duct tumor/su [Surgery]
6. 1 or 2 or 3 or 4 or 5
7. (surger\* or surgical\* or operat\* or resection\* or preoperative).ti,ab.
8. exp Surgery/
9. 7 or 8
10. 6 and 9
11. (pancreat\* or pancreaticojejunost\* or pancreaticogastros\* or pancreaticoduodenect\* or duodenopancreat\* or pancreato-biliary).ti,ab.
12. exp pancreas surgery/
13. 10 or 11 or 12
14. (PET or MRI or NMRI or zeugmatogra\* or ((emission or positron or magneti\* or MR or NMR or proton or acoustic or ARFI) and (tomogra\* or scan or scans or imaging))).ti,ab.
15. positron emission tomography/di
16. exp nuclear magnetic resonance imaging/di
17. 14 or 15 or 16
18. endoscopic echography/
19. (endosonogra\* or EUS).ti,ab.
20. (echogra\* or ultrason\* or ultrasound).ti,ab.

21. exp ultrasound/
22. 20 or 21
23. endoscop\*.ti,ab.
24. exp gastrointestinal endoscopy/
25. 23 or 24
26. 22 and 25
27. 17 or 18 or 19 or 26
28. 13 and 27
29. di.fs. OR predict.tw. OR specificity.tw.
30. 28 and 29

#### **Appendix 4. Science Citation Index (Web of Knowledge) search strategy**

(Includes: Conference Proceedings Citation Index- Science)

#1 TS=(((ampulla Vateri or ampullovateric or papilla Vateri or Vater papilla or Vater ampulla or periampull\* or peri-ampull\* or choledoch\* or alcholedoch\* or bile duct\* or biliary or cholangio\* or gall duct or duoden\* or small bowel or small intestine\* or pancrea\*) and (carcin\* or cancer\* or neoplas\* or tumour\* or tumor\* or cyst\* or growth\* or adenocarcin\* or malign\*)))

#2 TS=(operat\* OR surger\* OR surgical\* OR resection\* OR preoperative)

#3 #1 AND #2

#4 TS=(pancreatect\* OR pancreaticojejunost\* OR pancreaticogastros\* OR pancreaticoduodenect\* OR duodenopancreatectom\* OR pancreato-biliary)

#5 #3 OR #4

#6 TS=(PET OR MRI OR NMRI OR zeugmatogra\* OR ((emission OR positron OR magneti\* OR MR OR NMR OR proton OR acoustic OR ARFI) AND (tomogra\* OR scan OR scans OR imaging)) OR endosonogra\* OR EUS OR ((echogra\* OR ultrason\* OR ultrasound) AND endoscop\*))

#7 #5 AND #6

#### **Appendix 5. National Institute for Health Research - Health Technology Assessment (Centre for Reviews and Dissemination)**

pancrea\* Or periampullary

### **CONTRIBUTIONS OF AUTHORS**

DT selected studies for inclusion, extracted data, and entered data into Review Manager (RevMan) ([RevMan 2014](#)).

DR selected studies for inclusion.

MY and BRD commented critically on the review.

KSG selected studies for inclusion, performed data extraction, analysed and interpreted the data, and wrote the review.

## DECLARATIONS OF INTEREST

This report is independent research funded by the National Institute for Health Research (NIHR Cochrane Programme Grants, 13/89/03 - Evidence-based diagnosis and management of upper digestive, hepato-biliary, and pancreatic disorders). The views expressed in this publication are those of the review authors and not necessarily those of the NHS, the NIHR, or the Department of Health.

DT: none known.

DR: none known.

MY: none known.

BRD: none known.

KSG: none known.

## SOURCES OF SUPPORT

### Internal sources

- University College London, UK.

### External sources

- National Institute for Health Research (NIHR), UK.

This project was supported by the NIHR, via Cochrane Infrastructure, Cochrane Programme Grant or Cochrane Incentive funding to the Cochrane Upper Gastrointestinal and Pancreatic Diseases Group and the Cochrane Hepato-Biliary Group. The views and opinions expressed therein are those of the review authors and do not necessarily reflect those of the Systematic Reviews Programme, the NIHR, the NHS, or the Department of Health.

## DIFFERENCES BETWEEN PROTOCOL AND REVIEW

1. We included sensitivity maximising diagnostic filters for searching MEDLINE and Embase databases ([Haynes 2004](#); [Wilczynski 2005](#)). This is because the original searches without the filters retrieved more than 40,000 references. We had to balance the possibility of missing some studies against the risk of being unable to complete the review at all. We decided that it is useful to have evidence from major studies rather than having no information at all.
2. We performed the related search function through MEDLINE (OvidSP) rather than MEDLINE (Pubmed), and also performed a cited reference search in MEDLINE (via OvidSP).
3. We simplified the analysis in the presence of sparse data based on [Takwoingi 2015](#).
4. We revised the plan to investigate heterogeneity by using a hierarchical summary receiver operating characteristics (HSROC) model rather than a bivariate model. This would allow the inclusion of studies with different thresholds in the model, and potentially overcome the problem with sparse data.