

1 **A Comparison of Accuracy of Image- versus Hardware-based Tracking Technologies**
2 **in 3D Fusion in Aortic Endografting**

3
4
5 Alexander E. Rolls^{1,2}, Blandine Maurel¹, Meryl Davis¹, Jason Constantinou¹, George
6 Hamilton¹, Tara M. Mastracci^{1,2}

7
8 ¹ Aortic Team, Department of Vascular Surgery, Royal Free London Foundation Trust,
9 Pond Street, London NW3 2QG

10
11 ² University College London

12
13
14 **Corresponding Author:** Tara Mastracci, Aortic Team, Royal Free London NHS
15 Foundation Trust, NW3 2QG

16 Email: tara.mastracci@nhs.net

17
18
19 **Key Words:** Fusion, Aneurysms, Image-Based Tracking, Accuracy, Automatic,
20 Registration, Endovascular

21
22 **Category:** original article

23
24
25 Short Statement of Influence in Clinical Practice.

26 Fusion imaging is recognized as an important tool in complex aneurysm repair to
27 improve the success of implantation and decrease radiation dose and contrast use.
28 It has been previously impossible to compare accuracy of fusion systems because
29 they require fixed hardware, but a new cloud-based system is now available. We
30 compare the accuracy of two different types of fusion imaging. If confirmed, these
31 preliminary results could change clinical practice by encouraging further
32 development of automated image base tracking fusion process.

34

35 **ABSTRACT**

36 Objectives

37 Fusion of three-dimensional (3D) computed tomography (CT) and intra-operative 2D
38 imaging in endovascular surgery relies on manual rigid co-registration of bony
39 landmarks and tracking of hardware to provide a 3D overlay (Hardware based
40 tracking, HWT). An alternative technique (Imaged based tracking, IMT) uses image
41 recognition to register and place the fusion mask. We present preliminary
42 experience with an agnostic fusion technology that uses IMT, with the aim of
43 comparing the accuracy of overlay for this technology with HWT.

44

45 Method

46 Data was collected prospectively for 12 patients. All devices were deployed using
47 both IMT and HWT fusion-assistance concurrently. Post operative analysis of both
48 systems was performed by 3 blinded expert observers, from selected time-points
49 during the procedures, using the displacement of fusion rings, the overlay of vascular
50 markings and the true ostia of renal arteries. Mean overlay error as well as deviation
51 from mean error was derived using image analysis software. Comparison of mean
52 overlay error was made between IMT and HWT. Validity of the point-picking
53 technique was assessed.

54

55 Results

56 IMT was successful in all of the first 12 cases, whereas technical learning curve
57 challenges thwarted HWT in four cases. When independent operators assessed the
58 degree of accuracy of the overlay, the median error for IMT was 3.9 mm (IQR; 2.89-
59 6.24, max 9.5), versus 8.64 mm (IQR; 6.1-16.8, max 24.5) for HWT ($p=0.001$).
60 Variance per observer was 0.69 mm^2 and 95% limit of agreement ± 1.63 .

61

62 Conclusion

63 In this preliminary study, the error of magnitude of displacement from 'true
64 anatomy' during image overlay in IMT was less than for HWT. This confirms that

65 ongoing manual re-registration, as recommended by the manufacturer, should be
66 performed for HWT systems to maintain accuracy. The error in position of the fusion
67 markers for IMT was consistent, thus may be considered predictable.
68

69

70 *INTRODUCTION*

71

72 Endovascular interventions have expanded the treatment opportunities available to
73 patients with aortic disease and have become progressively complex.¹⁻³ When repair
74 includes coverage of the visceral aortic segment, accurate device deployment and
75 efficient catheterization of target vessels is critical. Fluoroscopic techniques require
76 frequent contrast administration and high quality image recording (DSA) to visualize
77 key structures, resulting in exposure of the patient and surgeon to considerable
78 radiation,⁴ and may be associated with deterioration in renal function.^{5,6}

79

80 Endovascular image fusion refers to the process of merging pre-operative imaging
81 with intra-operative imaging to provide a 3D vascular mask.^{7,8} Several studies using
82 commercially available devices have documented variable reduction in radiation
83 exposure, and significant reduction in contrast usage.⁹⁻¹² All commercially available
84 systems to date use hardware based tracking to position the mask on the
85 fluoroscopic image. Not all fixed imaging systems require cone beam CT (CBCT) to
86 perform fusion imaging, but at our institution, CBCT is used to create an
87 intraoperative 3D volume that is co-registered with pre-operative imaging. The CBCT
88 data provides the basis for a 3D co-ordinate reference frame that is automatically
89 registered with fluoroscopic imaging, but also incorporates positional data for the
90 vascular landmarks acquired on pre-operative imaging. By combining both soft and
91 bony landmarks for registration, this technique should be superior to those using
92 registration of bony landmarks alone. The position of the image intensifier and
93 operating table are tracked with respect to the co-ordinate reference frame,
94 allowing for appropriate vascular landmark representation when the fluoroscopic
95 image is changed.^{13,14} The reliability of this technique depends on the accuracy of
96 “hardware tracking” and the stability of the patient’s position on the table once rigid
97 co-registration has been performed.¹⁵ Furthermore, considerable user interaction is
98 required to define the vascular landmarks on a workstation pre-operatively,

99 manually register the images, and correct registration errors intra-operatively that
100 may arise from patient movement.

101

102 A fully automated, image-based 2D-3D registration system that is independent of
103 imaging system manufacturer has been proposed by Carrell et al, and its initial use
104 was described in 2010.¹⁶ This system provides several advantages including being
105 suitable for any theatre even those equipped with mobile C-arm; it is radiation and
106 contrast free for the initial registration; and being fully automated makes it “user
107 friendly” for the operator. The drawback of IMT is that it can only perform fusion on
108 +/-30 degree angles from a standard AP view, and it does require additional
109 equipment to be installed in theatre.

110

111 The aim of this study is to compare the accuracy of the fusion overlay between two
112 systems that use different mechanisms to maintain accurate overlay of vascular
113 markings: hardware tracking, and image-based tracking. Because most fusion
114 systems are brand-specific, there has been no previous simultaneous comparison of
115 accuracy between systems on the same patient in the same conditions. Thus, we
116 sought to compare the accuracy of an initial manual registration, followed by
117 hardware tracking using a commercially available device, against continuously
118 updated image-based matching in an investigative device.

119

120 ***MATERIALS AND METHODS***

121 All patients undergoing aortic repair between July 2015 and September 2015 by the
122 Aortic Team at Royal Free London were included in this study. These patients were
123 enrolled in a pre-market trial of CYDAR software and signed consent for
124 involvement. The study was approved by NHS England (IRAS ID 158839) and was
125 closed on September 30, 2015 in accordance with the approved protocol.

126

127 All patients with aneurysms underwent pre-operative high-resolution computed
128 angiography (CTA) as standard of care. All patients received stent-graft deployments
129 with fusion assistance using two different systems: a pragmatic application of a

130 commercially available device that uses hardware tracking (Siemens Artis Zeego,
131 Siemens Healthcare, Erlangen, Germany) and a novel image-based device the Cydar
132 EV system (Cydar Medical, Cambridge, UK) in order to allow for a comparison
133 between the two systems. Fusion would be considered successful if the initial
134 images were available and assisted the surgical procedure. Fusion would be
135 considered a failure if no mask appeared on the screen, or if the position of the mask
136 was so far removed from reality that it was not helpful in the opinion of the
137 operating team.

138

139 Hardware-Tracking Fusion Protocol

140 A hardware-tracking fusion protocol for complex aortic repair has been used at Royal
141 Free London since October 2014. Prior to CBCT, the surgical team imports the pre-
142 operative CTA onto the theatre-based workstation and marked the target vessels by
143 drawing rings at the level of the vessel ostia using Syngo™ (Siemens Healthcare,
144 Erlangen, Germany) software. After induction of general anaesthetic and after all
145 adjustments are made to the patient's position, the patients are fully prepared and
146 draped to minimize any extraneous patient movement after registration. All staff
147 retreat to a shielded and sterile control room prior to CBCT. A 5sDR (5 second
148 acquisition, taking 133 frames at 30 frames/sec) is used for all procedures. Rigid co-
149 registration of the pre-operative CTA with the bony CBCT volume is then performed
150 by the surgeon or an expert radiographer through a manual process. Target vessel
151 rings are assessed intra-operatively on the fluoroscopy screen. Manual re-
152 adjustments of the fusion overlay was not performed since we sought to compare
153 the accuracy of automatic image overlay in both systems after initial co-registration.

154

155 Image-based Tracking Fusion Protocol

156 For each patient the Cydar EV system was also used to generate vascular landmarks
157 which were viewable on an additional screen. Segmentation of the aorta and
158 relevant visceral vessels was performed from the DICOM data of CTA using a semi-
159 automatic method (thresholding followed by region growing), and then rings were
160 manually drawn on the rendered surface by the software provider prior to the day of
161 surgery. The software provider requires 24 hours to prepare the overlay mask. The

162 software then applies a computational algorithm on pre-operative CT volume to
163 generate a series of images (digitally reconstructed radiographs, [DRRs]) that mimic
164 fluoroscopic images across a range of C-arm rotations and magnifications to match
165 vertebral bodies in both images. An intensity-based registration algorithm then
166 scans the DRR series for images with similar pixel distributions, and automatically
167 matches the most appropriate DRRs to the live fluoroscopic images throughout the
168 procedure. During each fluoroscopic position, the tracking software analyzes the
169 visualized field and attempts to identify vertebrae. If two or more vertebrae are
170 identified, the vascular overlay image created from CT angiography is projected. The
171 algorithm assumes there is a rigid relationship between CT and fluoroscopy, since
172 registration is based on vertebral bodies, and does not adjust for changes in spinal
173 position.¹⁷ The system works when the C-arm is angulated within 30° craniocaudally
174 and 40° in an anterior-oblique direction, which is a range chosen by the
175 manufacturer that represents a balance between working range of the system and
176 speed of registration.

177

178 Error Analysis

179 Evaluation of error in terms of displacement of fusion rings, or overlaid vascular
180 markings, and the true ostia of the renal arteries on the fluoroscopy screen was the
181 principal measure in this study, which required expert assessment of the true
182 anatomy. We enlisted the observations of three blinded expert observers to identify
183 the location of true renal arteries in each projection. For each case, fluoroscopic
184 screen shots containing representations of renal artery fusion markers for each
185 fusion system were saved and loaded for post-hoc analysis into RView image-
186 analysis software (<https://www.doc.ic.ac.uk/~dr/software/>; Imperial College
187 London) which was provided to us by the engineers at CYDAR. In order to provide
188 data in millimetres, calibration was performed in each case against longitudinal rigid
189 landmarks on either a calibrated catheter or between two gold markers on a
190 fenestration. For patients receiving fenestrated grafts, conversion of pixels into
191 millimetres was performed using known diameters of fenestrations (either 6 or 8
192 mm), by measuring the number of pixels against this known dimension (figure 1a).

193

194 For patients receiving standard infra-renal grafts conversion was performed in the
195 same manner using the longitudinal markings of a standard measuring pig-tail
196 catheter (distance between each marker: 10 mm). In both scenarios, fluoroscopic
197 images were chosen with measurement markings close to the centre of the screen.
198 Since soft tissues are not visible on fluoroscopy, observers were asked to pick their
199 best estimate of the centre of the renal ostia using images of the fully deployed graft
200 with bridging stents in situ (figure 1b). They were then asked to pick the centre of
201 the fusion markers derived from both the hardware-tracking (figure 1c) and image-
202 based matching (figure 1d) systems. This process was performed for both renal
203 arteries in each case. For the standard infra-renal endovascular aneurysm repair
204 (EVAR) cases, three endovascular observers independently selected the centre of the
205 renal vessel ostium on the basis of the pre-deployment digital-subtraction
206 angiogram. They then selected the centre of the fusion marker. This point picking
207 procedure was repeated with three different observers to provide three error
208 recordings. The RView analysis software provides positional data in the form of pixel
209 co-ordinates for each selected point (x and y). Euclidean principles were used to
210 calculate the distance, in pixels, between the centre of the renal ostia and the fusion
211 markers (as selected by the observers), and was referred to as “error”. After
212 conversion to millimetres, each case therefore contained data for two renal arteries,
213 each of which was comprised of three error recordings per fusion system used, that
214 was averaged to give a single mean error value per renal artery, for each fusion
215 system used.

216

217 Statistical Analysis

218 Analysis was performed on SPSS 22.0 (IBM corporation, Chicago, Ill). Data was
219 treated in the following manner: For each renal fusion marker (hardware- and
220 image-tracked), mean values for error in ‘x’ and ‘y’ dimensions and error magnitude
221 were calculated across the three observers. Additionally, the difference to mean
222 error magnitude (for all three observers) for each renal was calculated for each
223 observer. Analysis using Pearson’s second skewness coefficient found the data to be
224 not-normally distributed. Therefore, in order to compare the distributions in mean
225 error magnitude between the two groups, a non-parametric test was used for un-

226 paired continuous variables (Mann-Whitney U). To determine if there were any
227 significant differences between the expert “point-pickers”, or observers, a Kruskal
228 Wallis test was performed comparing all recorded errors grouped according to
229 expert observer. To determine inter-observer variance and limits of agreement, a
230 Bland Altman-type analysis was used,¹⁸ plotting the mean magnitude of error across
231 the three observers against difference to mean magnitude for each observer. P
232 values of less than 0.05 were considered significant. Calculation of measurement
233 variations were performed with the assistance of engineers at CYDAR imaging.

234

235 **RESULTS**

236

237 Between July 2015 and September 2015, twelve patients underwent endovascular
238 repair under general anaesthesia for aortic aneurysms of varying morphology (Table
239 1) and consented to inclusion in this trial. Seven patients underwent fenestrated
240 endovascular aneurysm repair (FEVAR). Of these patients, four were group IV
241 thoracoabdominal and three were juxtarenal aneurysms. Five patients received
242 infrarenal EVAR, of which three also received iliac branched devices for iliac artery
243 aneurysms. Two patients received coil embolization of the internal iliac on the
244 contralateral side to the branched device. One patient had an isolated iliac aneurysm
245 treated in the presence of a previous endograft with type Ib failure. Mean age for
246 the cohort was 71.9 years (Standard Deviation (SD) 9.7 years). Median aneurysm sac
247 size (aortic or iliac as appropriate) was 6.1 cm (SD 1.1cm). Details of preoperative
248 demographics and intraoperative variables are described in Table 1

249

250 All patients underwent successful aneurysm exclusion. Mean procedure time from
251 first entering theatre to leaving theatre was 373 minutes (SD 92m) for fenestrated
252 cases and 220 minutes (SD 45m) for iliac branch cases. The best estimate of
253 procedure time collected at our institution is time from first dose of heparin and first
254 dose of protamine, and for fenestrated cases was 192 minutes (SD 63m); this data
255 was not available for iliac branch cases.

256

257 Image Fusion Reliability

258 The simultaneous overlay of image- and hardware-based tracking in the same
259 patient was feasible in most patients included in the study, and a representative
260 example is shown in figure 2. In the twelve patients included in this study, image-
261 based tracking was successful in all cases and hardware-based tracking was
262 successful in 8 patients. In two patients for which hardware-based tracking was
263 unsuccessful, no fusion overlay appeared intra-operatively, whilst in a further patient
264 the fusion markers were grossly misaligned, and rotated by 90° in relation to the true
265 orientation of the aorta. This required manual re-adjustment of the hardware-
266 tracked overlay, and the data was therefore excluded from final statistical analysis.
267 In these cases, failure of hardware-based tracking was due to operator error, and not
268 manufacturing defect, during the workflow of manual registration. In a fourth
269 patient, hardware-based tracking was not possible due to a concurrent update in the
270 hospital's picture archiving and communication system (PACS), preventing image
271 transfer of the pre-operative CTA necessary for 3D rendering and drawing of fusion
272 markers. For IMT cases, all had successful overlay masks projected, and the delay for
273 each different projection was less than 10 seconds for 55% of registrations, and was
274 less than 14 seconds for 92% of registrations.

275

276 The mean magnitude of error (figure 3) for the hardware-based tracking system was
277 8.64 mm (IQR; 6.1-16.8, max 24.5), compared with 3.9 mm (IQR; 2.89-6.24, max 9.5)
278 for the image-based system ($p=0.001$). Figure 4 gives a positional representation of
279 the distribution of overlay errors registered on the coordinate system described in
280 the methods section. The symbols indicate the direction in which the overlay needs
281 to move in order to match the intra-operative renal position. The image-based
282 overlay markers were consistently located below and mostly on the right side of the
283 true vessel ostium. In contrast, the hardware-tracking based overlay errors were of a
284 greater magnitude, particularly in lateral directions, and located above and below
285 the true vessel ostium. The inter-observer reliability of the blinded "point-picking"
286 technique used by expert observers was good, with the variance per observer in this
287 study being 0.69 mm and the 95% limit of agreement being ± 1.63 mm, as
288 indicated in the Bland Altman-type plot in figure 5.

289 **DISCUSSION**

290 This is the first preliminary study to compare accuracy of two different types of
291 fusion imaging techniques applied to the same patient undergoing aortic repair. We
292 observe a significant reduction in fusion overlay error (3.9 mm (IQR; 2.89-6.24, max
293 9.5) compared with 8.64 mm (IQR; 6.1-16.8, max 24.5) ($p=0.001$)) using a technique
294 that relies on image, rather than hardware for tracking in complex and simple
295 endovascular aortic procedures. The agreement between observers for this error
296 was good.

297

298 The use of a similarity-based measure to match digitally reconstructed radiographs
299 to real radiographs, using lumbar vertebrae as a means for rigid 2D-3D image
300 registration was initially proposed by Penney et al in 1998,¹⁹ but was not used
301 clinically due to limitations in fluoroscopic imaging techniques. A more recent study
302 describes the use of a prototype version of the Cydar EV system in a series of
303 retrospective registrations of pre-operative CT-angiograms with archived
304 fluoroscopic images, again using lumbar vertebrae as anchor-points for rigid 2D-3D
305 image registration.¹⁶ The authors observed a mean error of 4.5 +/- 2.8 mm across a
306 total of 98 registrations. Using a newer iteration of the software in this study, we
307 observed a median error of 3.99 mm across 21 renal targets, which was superior to
308 hardware-based image tracking in a pragmatic trial. In the current market place,
309 both GE and Phillips now have proprietary methods for performing 2D-3D fusion
310 without use of a CBCT. In contrast, the routine use of CBCT-based fusion in complex
311 aneurysm repair began as early as 2009 at the Cleveland Clinic, and has enjoyed
312 clinical use in many centres since that time.⁹ Removing the CBCT from the process of
313 fusion imaging may have the benefit of decreasing radiation dose while continuing to
314 provide accurate image guidance, however all systems still base tracking on
315 hardware which is subject to inaccuracy if the patient moves.

316

317 There was a consistency to errors in image-based tracking that did not appear in
318 hardware-based tracking. All errors appear to portray a slightly lower level of renal
319 arteries. This observation is consistent with findings by Maurel et al, who evaluated
320 the displacement of key visceral arteries by comparing pre-operative CTA with intra-

321 operative contrast enhanced CBCT, and found that both renal arteries were
322 predominantly displaced in a superior and left direction following the introduction of
323 stiff endovascular instruments.²⁰ This seems to be true independent of the side of
324 large sheath access, which was different between Maurel et al's experience and our
325 own.. The impact of endovascular tools on soft tissue deformation was suggested by
326 Carrell et al as a possible reason for increased error during image-based registration
327 when the aortic neck was angulated beyond 30⁰, since these relatively inflexible
328 devices tend to "straighten out" the aorta.¹⁶ Parallax or differences in body position
329 compared with CT scan protocol could also account for this error. By comparison,
330 inaccuracies due to respiratory movement are thought to be of lesser significance,
331 particularly at the vessel origin.^{21,22}

332

333 We observed errors of greater magnitudes during hardware-tracked fusion,
334 particularly in lateral directions, as well as errors occurring above and below the
335 intra-operative renal artery origin. These may be accounted for by the fundamental
336 differences in registration technique utilized by the two systems. In theory, the
337 continued and automated image-based matching ought to prevent errors relating to
338 patient movement from occurring, since the system corrects for this by
339 automatically overlaying the most appropriate DRR matched directly to the patient.
340 In contrast, the hardware-tracked system adjusts its representation of fusion
341 markers according to tracked movement of the C-arm and table in a 3D coordinate
342 system, on the assumption that the patient has remained static within that
343 coordinate system after initial rigid co-registration of bony landmarks on has taken
344 place. Our practice was to perform CBCT and the initial registration prior to
345 performing open surgical groin cut-downs, thereby minimizing the risk of
346 contamination. It is plausible that patient movement during this phase and during
347 other manoeuvres that move the patient, such as brachial punctures, may have
348 contributed to the broader distribution of registration errors. Where possible, the
349 team was cautious to maintain the position of the patient throughout the procedure,
350 but despite this attention to detail, the movement was still observed. The authors of
351 this study acknowledge that instructions for use for the Artis Zeego clearly
352 recommend manual adjustment of the overlay following any manipulation or

353 movement of the patient. In practice, this would require a surgeon to leave the
354 operating theatre and sterile field to use the workstation, or the continued presence
355 of a trained radiographer with experience of using the system, which is not
356 pragmatic in our practice. The work flow for such a protocol is less intuitive and may
357 introduce greater error. The intention of the study was to evaluate the overlay
358 accuracy of both systems when a “hands-off” protocol was applied during the
359 procedure, and to describe the impact of insensible movement on the accuracy of
360 fusion. The finding that patient movement did likely effect hardware based tracking
361 to a greater extent than imaged based tracking suggests that image based tracking
362 may be more resistant to the patient movement in a non-anesthetized patient,
363 which will be a point for future research.

364

365 Hardware-tracked fusion failed in 4 patients, which is due to user error, but reflects
366 the multistep process entailed in this technique. In two instances, fusion markers did
367 not appear on the fluoroscopic screen, whilst in a third case the markers were
368 grossly rotated by 90° in relation to the orientation of the aorta. In the fourth
369 patient, loss of communication of the PACS system rendered the overlay
370 inaccessible. These failures reflect the cumbersome process that hardware-based
371 tracking currently involves, with many different variables that might impact the
372 workflow. Registration in these cases was performed by senior radiographers who
373 had received intensive training on two separate sessions, each of two days in length.
374 Despite adequate training, the complexity of the registration work-flow seemingly
375 requires operators with a large amount of experience and regular exposure for it to
376 run seamlessly.

377

378 It is possible to compare these systems on factors other than accuracy. Certainly in
379 its current form, the HWT system has a larger working range and uses proprietary
380 software which precludes the installation of additional hardware into the operating
381 theatre. Drawbacks of the image-tracked system include the time the registration
382 process takes intra-operatively: each change in C-arm rotation requires a new match
383 to be made between the fluoroscopic image and a DRR which takes several seconds.
384 In some instances this matching cycle needs to be repeated, resulting in a delay

385 between the change in view and an appropriate overlay of up to 14 seconds. At
386 present, the system does not automatically register when the C-arm is angulated
387 beyond 30⁰ and 40⁰ in cranio-caudal and anterior-oblique directions, respectively.
388 Whilst sufficient for visualization and cannulation of renal targets, cannulation of
389 mesenteric and coeliac vessels using lateral views and fusion guidance is not possible
390 with the present iteration of the software. Work is presently in progress to expand
391 the scope of available DRRs to enable registration during more angulated
392 fluoroscopic acquisitions. Until that time, use of both systems to augment data
393 available intraoperative seems most prudent.

394

395 This is one centre's first attempt at use of image-based tracking, and comprises very
396 early experience. As such, there are a number of limitations to this study. Small
397 numbers of patients in this study could have adversely affected the level of
398 significance observed, and a larger study may provide a more accurate evaluation of
399 the true benefit of this technology. Defining the true centre of the vessel ostia in the
400 fenestrated cases presented a challenge, since it is our practice not to perform pre-
401 deployment DSA and to minimize the use of contrast injections when cannulating
402 the target vessels. We relied instead on using three expert observers to make best
403 estimates with the fenestrated piece fully deployed and the bridging stents in situ,
404 since this provided the most accurate representation of the position of the renal
405 arteries. However, placement of the device could have contributed to the
406 movement of the vessel ostia. Analysis of the distribution of recorded errors in
407 relation to mean error, however, demonstrated a small amount of variance between
408 observers and narrow limits of agreement, suggesting reliability of this method. The
409 lack of data describing patient movement during the procedure is an unfortunate
410 weakness, since the affect of patient movement on the magnitude and direction of
411 overlay inaccuracies in both systems cannot be fully determined. We used as a
412 reference distance the known diameters of the fenestrations for the fenestrated
413 cases, and the calibrated pigtail catheter for the infrarenal cases. We believe in most
414 cases these were perpendicular to the angle of the beam. However, this technique
415 could have a lack of precision and be slightly shorter than expected. For instance for
416 the infrarenal cases if the pigtail catheter is not strictly vertical; or for the

417 fenestrated cases if the lateral anterior and posterior markers are not on an
418 horizontal line, then the distance between the top and the bottom markers of the
419 window may not correspond to the highest and the lowest points. Finally, we did not
420 take into account neck angulation and renal ostia position on a clockwise that could
421 modify displacement after the insertion of the delivery system and consequently the
422 measurements.

423 **CONCLUSION**

424 Synchronous fusion using two different techniques was feasible, and allowed for a
425 direct comparison of overlay accuracy for image-based and hardware tracking
426 systems. In this very preliminary study, errors in fusion overlay associated with
427 image-based tracking seem predictable and are of a smaller magnitude compared
428 with those observed in a pragmatic application of a hardware-tracked device.
429 Additionally, a major benefit from the image-based fusion is that it does not require
430 a pre-operative CBCT and could help in decreasing the radiation exposure. Further
431 investigation with a larger series is warranted

432 **ACKNOWLEDGEMENTS**

433 We are grateful for the assistance of Dr. Graeme Penney from CYDAR imaging for
434 introducing us to the comparative software and assisting with the measurement
435 technique. Representatives from either fusion system were not consulted for the
436 final draft of this paper.

437

438 **Conflict of Interest**

439 TMM is a proctor and consults for Cook Medical, as well as speaking arrangements
440 with Maquet Getinge Group. JC has spoken on behalf of Maquet Getinge Group.
441 The CYDAR team helped facilitate the measurements performed.

442

443

444 **REFERENCES**

445

- 446 1. Mastracci TM, Eagleton MJ, Kuramochi Y, Bathurst S, Wolski K. Twelve-year results
447 of fenestrated endografts for juxtarenal and group IV thoracoabdominal
448 aneurysms. *J Vasc Surg* 2015; 61:355–364 .
- 449 2. Haulon S, D'Elia P, O'Brien N, Sobocinski J, Perrot C, Lerussi G, et al. Endovascular
450 repair of thoracoabdominal aortic aneurysms. *Eur J Vasc Endovasc Surg* 2010;
451 39:171–178.
- 452 3. Bicknell CD, Cheshire NJ, Riga CV, Bourke P, Wolfe JH, Gibbs RG, et al. Treatment
453 of complex aneurysmal disease with fenestrated and branched stent grafts. *Eur J*
454 *Vasc Endovasc Surg* 2009; 37(2):175–181.
- 455 4. Kirkwood ML, Arbique GM, Guild JB, Timaran C, Chung J, Anderson JA, et al.
456 Surgeon education decreases radiation dose in complex endovascular procedures
457 and improves patient safety. *J Vasc Surg* 2013; 58(3):715–721.
- 458 5. Kristmundsson T, Sonesson B, Dias N, Törnqvist P, Malina M, Resch T. Outcomes
459 of fenestrated endovascular repair of juxtarenal aortic aneurysm. *J Vasc Surg*
460 2014; 59(1):115–120.
- 461 6. Martin-Gonzalez T, Pinçon C, Maurel B, Hertault A, Sobocinski J, Spear R, et al.
462 Renal Outcomes Following Fenestrated and Branched Endografting. *Eur J Vasc*
463 *Endovasc Surg* 2015; 50(4):420-30.
- 464 7. Kaladji A, Dumenil A, Castro M, Haigron P, Heautot JF, Haulon S. Endovascular
465 aortic repair of a postdissecting thoracoabdominal aneurysm using intraoperative
466 fusion imaging. *J Vasc Surg* 2013; 57(4):1109–1112.
- 467 8. Kobeiter H, Nahum J, Becquemin JP. Zero-contrast thoracic endovascular aortic
468 repair using image fusion. *Circulation* 2011; 124(11):e280–282.
- 469 9. Dijkstra ML, Eagleton MJ, Greenberg RK, Mastracci TM, Hernandez A.
470 Intraoperative C-arm cone-beam computed tomography in fenestrated/branched
471 aortic endografting. *J Vasc Surg* 2011; 53(3):583–590.
- 472 10. Hertault A, Maurel B, Sobocinski J, Martin Gonzalez T, Le Roux M, Azzaoui R, et
473 al. Impact of hybrid rooms with image fusion on radiation exposure during
474 endovascular aortic repair. *Eur J Vasc Endovasc Surg* 2014; 48(4):382–390.
- 475 11. Sailer AM, de Haan MW, Peppelenbosch AG, Jacobs MJ, Wildberger JE, Schurink
476 GW. CTA with fluoroscopy image fusion guidance in endovascular complex aortic
477 aneurysm repair. *Eur J Vasc Endovasc Surg* 2014; 47(4):349–356.

- 478 12. McNally MM, Scali ST, Feezor RJ, Neal D, Huber TS, Beck AW. Three-dimensional
479 fusion computed tomography decreases radiation exposure, procedure time, and
480 contrast use during fenestrated endovascular aortic repair. *J Vasc Surg* 2015;
481 61(2):309-16.13. Tacher V, Lin M, Desgranges P, Deux JF, Grünhagen T, Becquemin
482 JP, et al. Image guidance for endovascular repair of complex aortic aneurysms:
483 comparison of two-dimensional and three-dimensional angiography and image
484 fusion. *J Vasc Interv Radiol* 2013; 24(11):1698-1706.
- 485 14. Abi-Jaoudeh N, Kobeiter H, Xu S, Wood BJ. Image Fusion During Vascular and
486 Nonvascular Image-Guided Procedures. *Tech Vasc Interv Radiol* 2013; 16(3):168-
487 76.
- 488 15. Varnavas A, Carrell T, Penney G. Increasing the automation of a 2D-3D
489 registration system. *IEEE Trans Med Imaging* 2013; 32(2):387–399.
- 490 16. Carrell TWG, Modarai B, Brown JRI, Penney GP. Feasibility and limitations of an
491 automated 2D-3D rigid image registration system for complex endovascular aortic
492 procedures. *J Endovasc Ther* 2010; 17(4):527-33.
- 493 17. Penney GP, Batchelor PG, Hill DL, Hawkes DJ, Weese J. Validation of a two- to
494 three-dimensional registration algorithm for aligning preoperative CT images and
495 intraoperative fluoroscopy images. *Med Phys* 2001; 28(6):1024–1032.18. Jones M,
496 Dobson A, O’Brian S. A graphical method for assessing agreement with the mean
497 between multiple observers using continuous measures. *Int J Epidemiol* 2011;
498 40(5):1308–1313.19. Penney GP, Weese J, Little JA, Desmedt P, Hill DL, Hawkes DJ.
499 A comparison of similarity measures for use in 2-D-3-D medical image registration.
500 *IEEE Trans Med Imaging* 1998; 17(4):586–595.
- 501 20. Maurel B, Hertault A, Gonzalez TM, Sobocinski J, Le Roux M, Delaplace J, et al.
502 Evaluation of visceral artery displacement by endograft delivery system insertion.
503 *J Endovasc Ther* 2014; 21(2):339-47.
- 504 21. Draney MT, Zarins CK, Taylor CA. Three-dimensional analysis of renal artery
505 bending motion during respiration. *J Endovasc Ther* 2005; 12(3):380-6.
- 506 22. Fukuda T, Matsuda H, Doi S, Sugiyama M, Morita Y, Yamada M, et al. Evaluation
507 of automated 2D-3D image overlay system utilizing subtraction of bone marrow
508 image for EVAR: feasibility study. *Eur J Vasc Endovasc Surg* 2013; 46(1):75-81.
509

510 **Figures and Tables**

511

512 Table 1: Demographics for included patients. (SD: standard deviation; HTN:
 513 Hypertension; DM: diabetes mellitus; CCF: congestive cardiac failure; BMI: body mass
 514 index ; GFR: glomerular filtration rate; DAP: dose area product; CAK: cumulative air
 515 kerma)

516

| | N (12) |
|---------------------------------|------------------------------------|
| Age | 71.9 years (SD 9.7 yrs) |
| Male | 11/12 |
| Medical Comorbidities | |
| HTN | 12/12 |
| Dyslipidemia | 11/12 |
| Current Smoker | 2/12 |
| DM | 4/12 |
| CCF | 2/12 |
| BMI | 26.6 (SD 4.9) |
| Pre op GFR | 67.7 (SD 24.7) |
| Post op GFR | 64.8 (SD 23.9) |
| Aneurysm Characteristics | |
| Aneurysm sac size | 6.1cm (SD 1.08 cm) |
| Infrarenal Aneurysm | 2/12 |
| Iliac Artery Aneurysm | 3/12 |
| Juxtarenal aneurysm | 3/12 |
| Type IV TAAA | 4/12 |
| Intraoperative Variables | |
| DAP | 91.7 Gy.cm ² (SD 67.92) |
| KAP | 0.78 mGy (SD 0.69) |
| Volume of Contrast | 46cc (SD 14.9) |

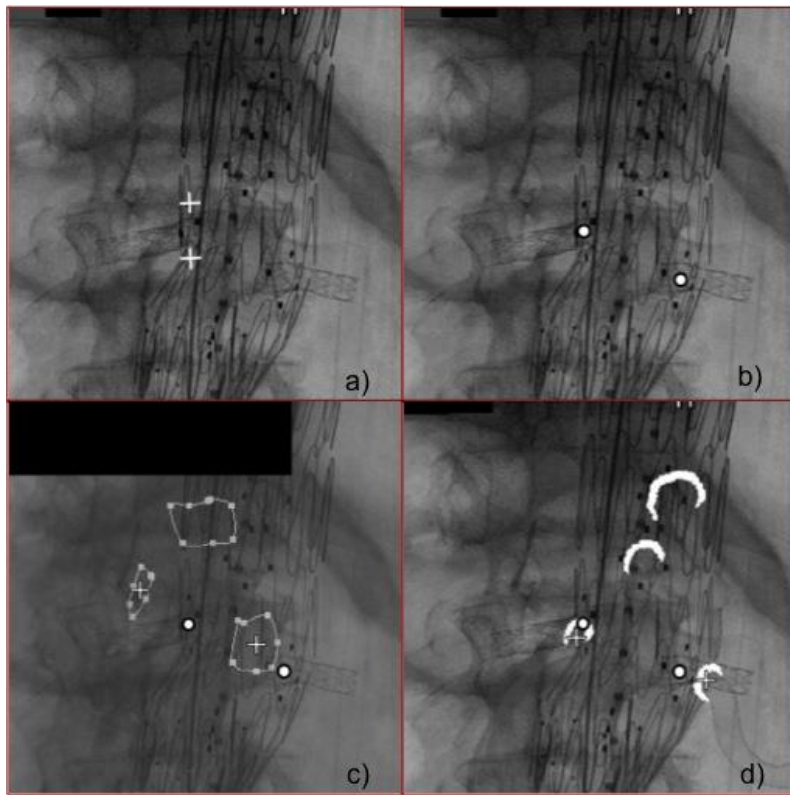
517

518

519

520

521



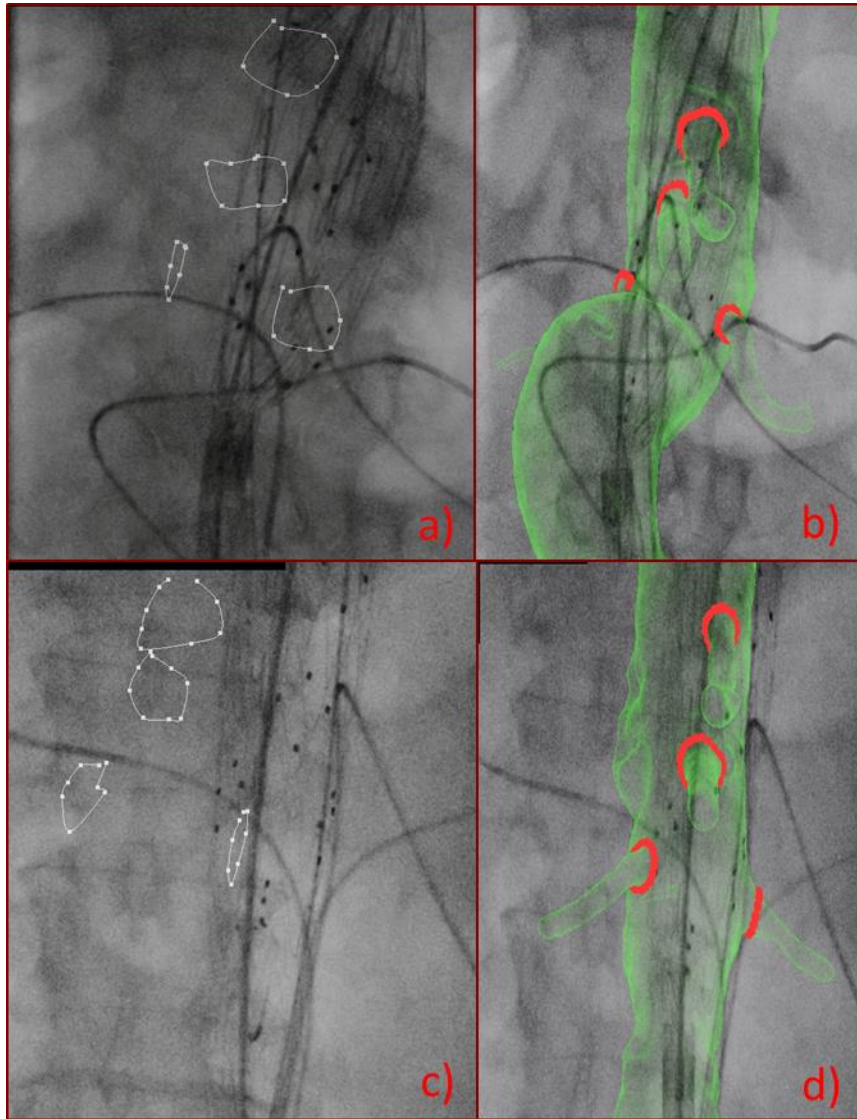
522

523 Figure 1

524

525

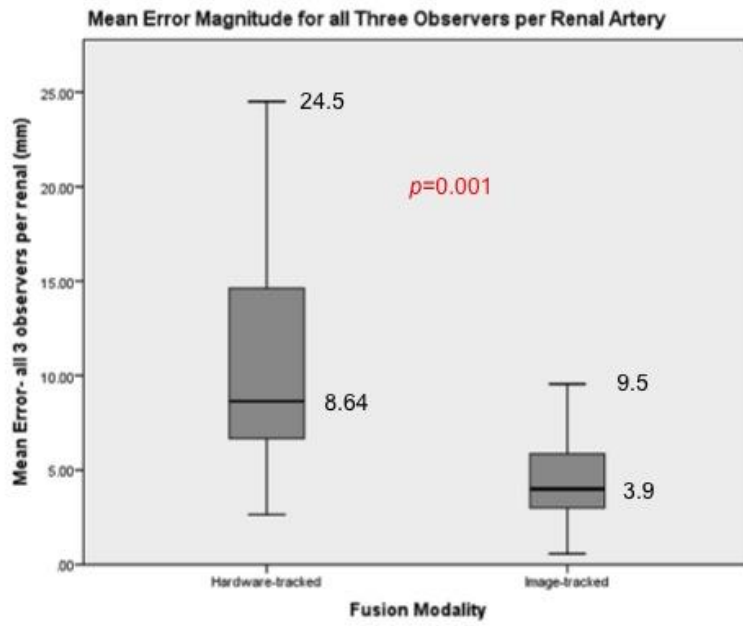
526



527

528

529 Figure 2



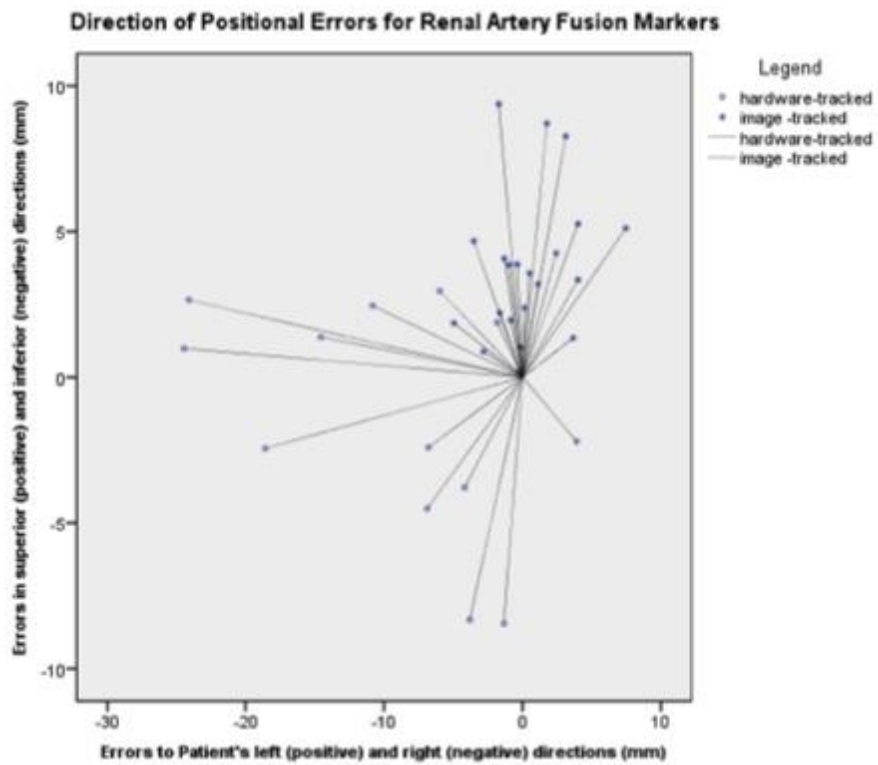
530

531 Figure 3

532

533

534

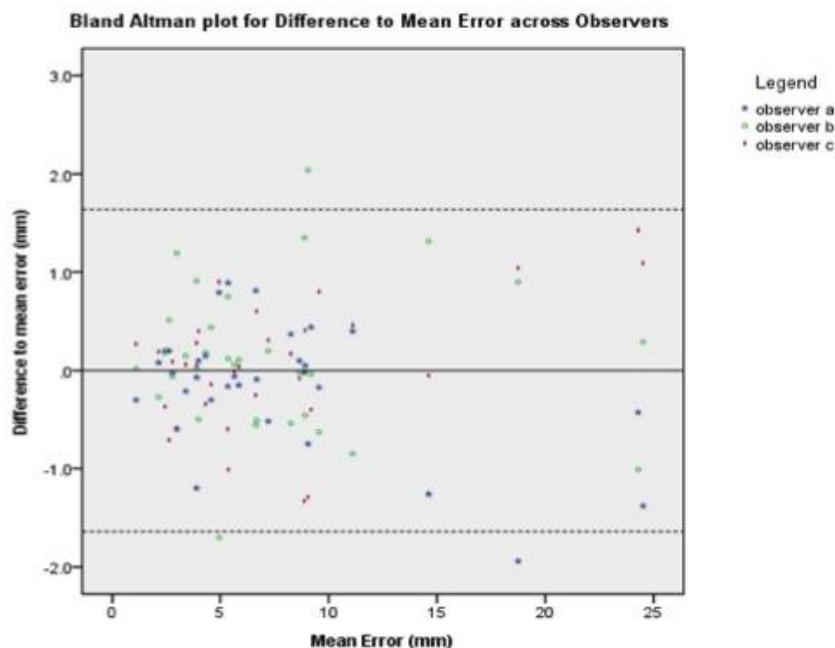


535

536 Figure 4

537

538



539

540 Figure 5

541

542

543

544

545

546 **Table and Figure Legend**

547 Table 1: Patient demographics and aneurysm morphology. IA- Iliac artery. IRAAA-
548 infrarenal abdominal aortic aneurysm. EVAR- endovascular aneurysm repair. FEVAR-
549 fenestrated endovascular aneurysm repair. IBD- iliac branched device. Results are
550 expressed in mean and standard deviation (SD). (*SD: standard deviation; HTN:*
551 *Hypertension; DM: diabetes mellitus; CCF: congestive cardiac failure; BMI: body mass*
552 *index ; GFR: glomerular filtration rate; DAP: dose area product; CAK: cumulative air*
553 *kerma)*

554

555

556 Figure 1: Calibration and Point-selection a) Conversion of pixels into mm, in this case
557 the known dimensions of a fenestration. b) Centre of the renal ostium is selected. c)

558 Centre of the hardware-tracked fusion marker is selected d) Centre of the image-
559 tracked fusion marker is selected

560

561 Figure 2: Hardware-based tracking and Image-based tracking fusion systems applied
562 to two cases, with each row representing the same case. a) and c)- hardware-based
563 tracking. b) and d)- image-based tracking

564

565 Figure 3: Comparison of mean error magnitude for all three observers per renal
566 artery, by fusion system used.

567

568 Figure 4: Scatter-plot showing mean error per renal artery in x and y coordinates.
569 The symbols pointing away from the origin represent the direction in which the
570 overlay would have to be moved to match the actual vessel ostium.

571

572

573 Figure 5: Bland Altman-type plot showing deviation from the mean error for each
574 renal artery. Each data point represents the difference between an observer's
575 recorded overlay error during point selection to the mean overlay error recorded for
576 all three observers for a given renal artery. The dotted lines represent the 95% limits
577 of agreement.

578

579

580

581

582

583