

Running Head: Lesions Affecting Motor and Body Awareness

**Motor Versus Body Awareness: Voxel-based Lesion Analysis in Anosognosia for Hemiplegia and Somatoparaphrenia Following Right Hemisphere Stroke**

Valentina Moro<sup>1\*</sup>, Simone Pernigo<sup>1\*</sup>, Manos Tsakiris<sup>2</sup>, Renato Avesani<sup>3</sup>, Nicola M. J. Edelstyn<sup>4</sup>, Paul M. Jenkinson<sup>5</sup> & Aikaterini Fotopoulou<sup>6</sup>

<sup>1</sup> NPSY.Lab-VR, Department of Human Sciences, University of Verona, Italy.

<sup>2</sup> Department of Psychology, Royal Holloway, UK.

<sup>3</sup> Department of Rehabilitation, Sacro Cuore Hospital, Negrar, Verona, Italy.

<sup>4</sup> School of Psychology, Keele University, UK.

<sup>5</sup> School of Life and Medical Sciences, University of Hertfordshire, UK.

<sup>6</sup> Clinical, Educational & Health Psychology, Division of Psychology & Language Sciences, University College London, UK.

\* These authors shared the first authorship

Correspondence concerning this article should be addressed to:

Aikaterini (Katerina) Fotopoulou  
CEHP Research Department  
University College London  
1-19 Torrington Place  
London WC1E 7HJ  
Tel: (+44) 020 7679 3079  
Fax: (+44) 020 7916 8502  
Email: a.fotopoulou@ucl.ac.uk.

and

Valentina Moro  
Department of Human Sciences  
University of Verona  
Lungadige Porta Vittoria 17  
37129 Verona  
Tel (+39) 045 8028370  
Fax: (+39) 045 8028039  
Email: valentina.moro@univr.it

## Abstract

1 Anosognosia for hemiplegia (AHP) is informative about the neurocognitive basis of motor  
2 awareness. However, it is frequently associated with concomitant symptoms, such as hemispatial  
3 neglect and disturbances in the sense of body ownership (DSO). Although double dissociations  
4 between these symptoms have been reported, there is ongoing debate about whether they are  
5 manifestations of independent abnormalities, or a single neurocognitive deficit. We aimed to  
6 investigate the specificity of lesions associated with AHP by surpassing four, existing  
7 methodological limitations: (a) recruit a relatively large sample of patients (total N = 70) in a multi-  
8 centre study; (b) identify lesions associated with AHP in grey and white matter using voxel-based  
9 methods; (c) take into account the duration of AHP and concomitant neglect symptoms; and (d)  
10 compare lesions against a control hemiplegic group, patients suffering from AHP and DSO, and a  
11 few, rare patients with selective DSO. Results indicated that acute AHP is associated with a wide  
12 network, mainly including: (1) the Rolandic operculum, (2) the insula and (3) the superior temporal  
13 gyri. Subcortically, damage mainly involved the basal ganglia and white matter, mostly the  
14 superior corona radiate, arcuate fasciculus and the part of the ventral, superior longitudinal  
15 fasciculus. Persistent symptoms were linked with wider damage involving fronto-temporal cortex  
16 and long white matter tracts. A shift in the latero-medial direction (mainly involving the basal  
17 ganglia and surrounding white matter) emerged when DSO was taken accounted for. These results  
18 suggest that while bodily awareness is processed by areas widely distributed across the brain,  
19 intact subcortical structures and white matter tracts may be necessary to support basic feelings of  
20 owning and controlling contralateral body parts. An accurate and 'up-to-date' awareness of our  
21 motor abilities, however, may rely also on intact processing in cortical areas which presumably  
22 allow higher-order inferences about the current state of the body.  
23  
24  
25  
26  
27  
28  
29  
30  
31  
32  
33  
34  
35  
36  
37  
38  
39  
40  
41  
42  
43  
44  
45  
46  
47

48 **Keywords:** Motor Awareness; Body Awareness; Anosognosia for hemiplegia; Sense of Body  
49 ownership; Voxel-Based Lesion Mapping.  
50  
51  
52  
53

## Introduction

54 Human bodily awareness entails the processing, integration and re-representation of one's  
55 sensorimotor states as one's *own bodily states*. However, bodily awareness is as vulnerable as it is  
56 complex, as demonstrated by the variety of disturbances caused by a range of clinical (e.g.  
57  
58  
59  
60  
61  
62  
63  
64  
65

1 amputation, deafferentation, brain damage) and experimental (multisensory conflicts) factors  
2 (Fletcher & Fotopoulou, 2015; Pernigo et al., 2012; Ramachandran & Rogers-Ramachandran, 2000;  
3 Scandola et al., 2014). In terms of central neurological damage, right hemisphere stroke can cause  
4 severe disorders of bodily awareness, such as anosognosia (from the Greek,  $\alpha$  = without, νόσος =  
5 disease, γνώσις = knowledge) for hemiplegia (AHP). AHP has been described as the denial of motor  
6 paralysis contralateral to a brain lesion (Babinski, 1914). In this condition, hemiplegic patients may  
7 state that they are able to move their paralysed limbs, to walk, or carry out daily life activities  
8 without needing help. Sometimes they also behave or attempt to act as if they really can move  
9 their body normally (e.g. Moro, Pernigo, Zapparoli, & Cordioli, 2011). Not surprisingly, AHP in the  
10 acute stages following stroke is associated with poor long-term functional outcome (Gialanella &  
11 Mattioli, 1992; Hartman-Maeir, Soroker, & Katz, 2001), even if in most cases it resolves  
12 spontaneously, days or weeks post-stroke (Pia, Neppi-Modona, Ricci, & Berti, 2004; Vocat, Staub,  
13 Stroppini, & Vuilleumier, 2010).

14 Although the syndrome includes several clinical forms and many concomitant symptoms,  
15 such as personal and visuospatial neglect (Jenkinson, Preston, & Ellis, 2011), there is ongoing  
16 debate about whether these are manifestations of independent abnormalities, a single primary  
17 deficit, or a combination of deficits (see Jenkinson & Fotopoulou, 2014). Recent, integrated  
18 clinical, experimental and neuroimaging approaches (Cocchini, Beschin, Fotopoulou, & Della Sala,  
19 2010; Fotopoulou, Pernigo, Maeda, Rudd, & Kopelman, 2010; Gandola et al., 2014; Moro et al.,  
20 2011; Vocat et al., 2010) have shown the limits of theories which explain AHP as the result of  
21 single deficits such as sensory, spatial, attentional or metacognition abnormalities (see also  
22 Prigatano, 2010 for a review). Indeed, recent multifactorial theories suggest that AHP is a multi-  
23 component syndrome that may be caused by a collection of disturbances (Davies, Davies, &  
24 Coltheart, 2005; Marcel, Tegnér, & Nimmo-Smith, 2004; Mograbi & Morris, 2013; Vuilleumier,  
25 2004) and their dynamic relations (Fotopoulou, 2014; Fotopoulou, 2012; Jenkinson & Fotopoulou,  
26 2014).

27 This perspective is consistent with the fact that, apart from a more frequent occurrence  
28 after right than left-hemisphere damage (e.g. Cocchini, Beschin, Cameron, Fotopoulou, & Della  
29 Sala, 2009 for left hemisphere cases; Jehkonen, Laihosalo, & Kettunen, 2006), recent  
30 neuroimaging studies have not identified a consistent pattern of brain lesion or dysfunction  
31 selectively associated with AHP. Specifically, some studies have highlighted the potential role of  
32 cortical areas such as the right insula in AHP (Berti et al., 2005; Fotopoulou et al., 2010; Karnath,  
33  
34  
35  
36  
37  
38  
39  
40  
41  
42  
43  
44  
45  
46  
47  
48  
49  
50  
51  
52  
53  
54  
55  
56  
57  
58  
59  
60  
61  
62  
63  
64  
65

1  
2  
3  
4  
5  
6  
7  
8  
9  
10  
11  
12  
13  
14  
15  
16  
17  
18  
19  
20  
21  
22  
23  
24  
Baier, & Nägele, 2005; Vocat et al., 2010). The insular cortex has been more generally implicated in body ownership, perceived agency and interoceptive representations of body states (Craig, 2009; Karnath et al., 2005; Tsakiris, Hesse, Boy, Haggard, & Fink, 2007). Other cortical areas selectively associated with AHP are the right premotor and the inferior frontal cortex, in particular Brodmann's areas 6, 44/45 and 47 (Berti et al., 2005; Fotopoulou et al., 2010; Korte et al., 2015), which are involved in motor initiation, preparation and monitoring. However, there are conflicting results between these studies regarding which areas of the frontal operculum are implicated in AHP (Berti et al., 2005; Korte et al., 2015) and other studies fail to find a selective role for premotor areas and the inferior frontal gyrus in AHP (Karnath et al., 2005). In addition, some but not all studies report that lesions involving subcortical structures such as the thalamus, the basal ganglia and the amygdala-hippocampal complex may relate to certain behavioural facets of AHP (Fotopoulou et al., 2010; Moro et al., 2011; Vocat et al., 2010, **see Table 4 for a review of previous studies**).

25  
26  
27  
28  
29  
30  
31  
32  
33  
34  
35  
36  
37  
38  
39  
40  
41  
42  
43  
44  
45  
46  
47  
48  
49  
50  
51  
52  
53  
54  
55  
56  
57  
58  
59  
60  
61  
62  
63  
64  
65  
In addition to intrinsic limitations of lesion mapping studies (Rorden, Fridriksson, & Karnath, 2009; Rorden & Karnath, 2004), part of the aforementioned differences between studies may be attributed to different sample sizes and selection criteria, including criteria for diagnosis, subtype of anosognosia, age, lesion size, perfusion patterns, white matter involvement, and the time interval since stroke for both diagnosis and neuroimaging examination (Karnath et al., 2005; Korte et al., 2015; Vocat et al., 2010). Unfortunately, addressing all these limitations in a single study is currently unfeasible for most labs. Accordingly, in the current study we wished to address at least four of these considerations. Specifically, we aimed to: (a) recruit a relatively large sample of patients with a clear diagnosis of severe AHP (verified by two, separate interviews); (b) examine identifiable lesions in *grey and white matter*, while (c) also taking into account the duration of AHP and concomitant neglect symptoms. Finally, we aimed to (d) compare the lesions of AHP patients not only to a control group showing hemiplegia without anosognosia (HP group) but also to another group of patients whose anosognosia was accompanied by body ownership disturbances. Clinical dissociations between AHP and body ownership disturbances have been described since Gerstmann's seminal paper (1942) on the topic. The critical difference seems to be that while AHP affects patients' awareness of action, right hemisphere stroke can also cause abnormalities in awareness of one's body parts as one's own. For example, patients with asomatognosia show a lack of recognition regarding the existence or ownership of their limbs (Vallar & Ronchi, 2009). Sometimes these abnormalities are accompanied by delusions about the affected limbs

1 (somatoparaphrenias; Gerstmann, 1942), such as the belief that the affected limb belongs to  
2 another person, including friends, relatives or even the examiner. Typically, somatoparaphrenia is  
3 regarded as a positive or productive variant of asomatognosia (in the Jacksonian sense; Jackson,  
4 1932), and it may take several clinical forms (reviewed by Vallar & Ronchi, 2009), but the particular  
5 application of terms like asomatognosia and somatoparaphrenia remains debated. To escape this  
6 terminological ambiguity in this paper, we follow Karnath and colleagues (Baier & Karnath, 2008)  
7 in classifying all abnormal feelings and beliefs regarding the existence and ownership of one's  
8 limbs as 'disturbed sensation of limb ownership' (DSO).  
9

10 AHP and DSO have been found to co-occur frequently (Vallar & Ronchi, 2009) and previous  
11 studies have suggested a strong link between the sense of limb ownership and action awareness,  
12 and common critical lesions in the posterior insular cortex (Baier & Karnath, 2008). However,  
13 more recent, in depth neuropsychological examinations have demonstrated the possibility of  
14 behavioural and neural dissociations between AHP and DSO (Gandola et al., 2012; Invernizzi et al.,  
15 2013; Vallar & Ronchi, 2009a). Specifically, certain 'pure' cases of DSO (i.e. patients that did not  
16 show any indications of AHP) have been identified and their lesions have been compared with  
17 cases of pure AHP (Invernizzi et al., 2013; albeit the AHP patients were recruited as part of a  
18 previous study, Berti et al., 2005), or mixed AHP (Gandola et al., 2012). These studies have  
19 revealed that, contrary to AHP (Berti et al., 2005; Kortte et al., 2015), DSO is not selectively  
20 associated with damage to the inferior frontal gyrus, including the lateral premotor cortex and  
21 instead it seems to involve critical lesions to grey subcortical structures and white matter bundles  
22 (see also Zeller, Gross, Bartsch, Johansen-Berg, & Classen, 2011). Taken together, the conflicting  
23 results of previous studies, as well as the frequent co-occurrence of AHP and DSO, warrant a  
24 specific examination of the relation between DSO and AHP. In the current study we used a voxel-  
25 based, lesion comparison approach (Kimberg, Coslett, & Schwartz, 2007; Rorden & Karnath, 2004;  
26 Rorden, Karnath, & Bonilha, 2007) to test the hypothesis that at least partially segregated  
27 networks are damaged in AHP and DSO, involving more cortical premotor and insular grey matter  
28 areas in the former, and subcortical white and grey matter structures (basal ganglia and white  
29 matter tracts around them) in the latter.  
30  
31  
32  
33  
34  
35  
36  
37  
38  
39  
40  
41  
42  
43  
44  
45  
46  
47  
48  
49  
50  
51  
52  
53  
54  
55

## 56 **2. Materials and Methods**

### 57 *2.1. Patients*

58  
59  
60  
61  
62  
63  
64  
65

1 A total of 70 patients with damage to the right hemisphere were consecutively recruited (in each  
2 center) from three different, collaborating centers: the acute, stroke rehabilitation unit at the St.  
3 Thomas's Hospital in London, acute stroke and stroke rehabilitation wards at the (former)  
4 University Hospital of North Staffordshire, and the Rehabilitation Ward of the Sacro Cuore Hospital  
5 (Negrar, Verona, Italy) over a period of 5 years (from 2006 to 2011). Behavioural, experimental  
6 data for 31 of the current anosognosic patients and 23 of the controls have been previously  
7 described in case studies (Besharati, Kopelman, Avesani, Moro, & Fotopoulou, 2015; Fotopoulou  
8 et al., 2011; Jenkinson, Haggard, Ferreira, & Fotopoulou, 2013), or small sample group studies  
9 (Jenkinson, Edelstyn, Drakeford, & Ellis, 2009, AHP N = 10; Jenkinson, Edelstyn, & Ellis, 2009, AHP  
10 N = 8; Fotopoulou et al., 2010, AHP N = 7; Moro et al., 2011, AHP N = 12). In this study, the clinical  
11 and anatomical data of 70 patients were analyzed. Unfortunately, further screening data is not  
12 available/informative for our sample, due to the practical and ethical considerations regarding  
13 recruitment and the time intervals involved (see also below). For instance, as stated above,  
14 patients were recruited from units that admitted and cared for patients at different intervals and  
15 durations post stroke. In addition, in one of the three centres the researchers did not have access  
16 to the medical records but rather it was the responsibility of clinicians to refer patients meeting  
17 the inclusion criteria below, based on their clinical observations.

18 Patients were eligible if they had (i) a stroke-induced right-hemisphere lesion as confirmed  
19 by clinical neuroimaging; (ii) contralateral upper limb plegia (they were unable to move their left  
20 arm). Exclusion criteria were: (i) previous history of neurological or psychiatric illness; (ii)  
21 medication with severe cognitive or mood side-effects; (iii) severe language, general cognitive  
22 impairment, or mood disturbance that precluded completion of the study assessments.

23 For all recruitment centres, the presence or absence of AHP and DSO was diagnosed by  
24 means of the same criteria (scores of 1 or 2 on the Berti AHP interview; clear clinical indications of  
25 anosognosia, and clear indications of DSO in a body ownership interview, see below for details).  
26 Based on these assessments, patients were categorized into four different groups: 1. Patients with  
27 Anosognosia for Hemiplegia (AHP Group, N = 25 patients); 2. AHP patients that also showed DSO  
28 (AHP+DSO Group, N = 13 patients); 3. pure DSO patients (DSO Group, N = 4 patients); 4. Control  
29 patients with hemiplegia but no body awareness symptoms (HP Control Group, N = 28 patients).  
30 When possible (for 36 out of 42 target patients), unaware patients were examined in a follow-up  
31 assessment in order to investigate the persistence of AHP and DSO in sub-acute and chronic stages  
32 (Table 1). Since the exact moment of this follow-up changed between patients due to practical  
33  
34  
35  
36  
37  
38  
39  
40  
41  
42  
43  
44  
45  
46  
47  
48  
49  
50  
51  
52  
53  
54  
55  
56  
57  
58  
59  
60  
61  
62  
63  
64  
65

considerations, we conducted lesion comparisons (see below) on the basis of a single time cut-off: i) AHP patients who recovered awareness within 40 days (AHP<sub>acute only</sub> subgroup, N = 6) and ii) those who continued to show body unawareness symptoms after 40 days from stroke (AHP<sub>chronic</sub> subgroup, N = 14). These analyses were exploratory as the two groups of chronic and 'acute only' patients were unequal in number. Most papers typically refer to anosognosia as a transient phenomenon that tends to recover spontaneously days or weeks after onset. However, the available data in the literature on the evolution of AHP are actually mixed; less than 20% of published studies involve follow-up assessments and there is no specification of optimal timeframes for the characterization of patients as acute versus chronic. Most studies consider the presence of AHP to be chronic if it is present at a post onset interval greater than one month, 40 days, three months or six months (see Nurmi & Jehkonen, 2014 for the most recent and systematic review on the issue). Our selection was therefore within this range, based on our experience of the time intervals that patients are likely to be admitted and remain available for testing and follow-up assessments in the various clinical units involved. The ratio between acute and chronic patients therefore reflects merely this fact. Furthermore, we found that DSO was still present after 40 days in 11 AHP+DSO patients, and in all the pure DSO patients. Therefore, we did not further sub-divide these groups. All patients gave written informed consent and the research was conducted in accordance with the guidelines of the Declaration of Helsinki (2013) and approved by the Local Ethical Committees of each centre.

## 2.2. Assessment of AHP and DSO

The diagnosis of AHP was ascertained by means of a structured interview (Berti, Làdavas, & Della Corte, 1996), including general questions regarding the consequences of stroke (e.g., 'How is your left arm? Can you move it?') and confrontation questions (e.g. 'Please, touch my hand with your left hand. Have you done it?'). In this interview full acknowledgement of paralysis is scored as '0', while denial of the paralysis despite acknowledging not having reached for the examiner's hand is scored as '1'; and a score of '2' is given when patients denied both motor impairments and the failure in reaching for the examiner's hand. We considered patients as anosognosic when they scored 1 or 2, as in previous studies (e.g. Berti et al., 1996; Fotopoulou et al., 2008, 2010).

We also used a second measure of AHP, namely the frequently used scale by Bisiach and colleagues (Bisiach, Vallar, Perani, Papagno, & Berti, 1986). In this 4-point scale, if the disorder is spontaneously reported by the patient following a general question about their complaints the

1 score is '0' = no anosognosia; '1' is scored if the disorder is reported only following a specific  
2 question about the strength of the patient's limbs; '2' is scored if the disorder is acknowledged  
3 only after demonstration; and finally '3' is scored if no acknowledgement of the disorder can be  
4 obtained. We considered patients as anosognosic when they scored 2 or 3 (Karnath et al., 2005;  
5 Orfei et al., 2007).  
6

7  
8  
9 This double assessment of AHP allowed us to repeat the assessment, and in this way to  
10 take into account the potential variability of AHP symptoms in time and in relation to the context  
11 of the questioning (Marcel et al., 2004; Vocat & Vuilleumier 2010; Fotopoulou et al., 2010; Moro  
12 et al., 2011). Examining patients' diagnosis in this manner, we found no discrepancies in the  
13 classification of patients based on these two assessments, thus confirming the validity of our  
14 classification. For the purposes of behavioural analyses of neuropsychological performance (see  
15 below), each patient's scores on the two scales were converted into percentages and averaged to  
16 form a composite index of anosognosia. This composite score further allowed us a range of scores  
17 that could better capture the clinical variability of AHP and thus be better suited to further  
18 analyses with other behavioural deficits that are multicomponent and determined by more than  
19 one assessment (e.g. neglect).  
20  
21  
22  
23  
24  
25  
26  
27  
28  
29  
30

31 Somatoparaphrenia (DSO) was assessed by means of a standardized, ad-hoc procedure.  
32 Patients were preliminary asked to identify their right and left hands. If they failed to identify their  
33 left hand spontaneously, they were asked to look at their left hand and respond to a series of  
34 questions: "What is this? Who does this hand belong to? How many hands do you have? Is this  
35 your hand? Where is your left hand? Finally, the 'One-item test' was administered; we asked  
36 patients to reach and touch their left hand with the right one (Bisiach et al., 1986). Patients were  
37 included in the groups of DSO or AHP+DSO when presented with delusional beliefs about the  
38 contralesional side of their body, in particular when they denied that the arm belonged to them  
39 and/or attributed it to somebody else in at least two of these questions. Bizarre, persistent and  
40 refractory-to-correction explanations of patients delusion were recorded (Feinberg, Venneri,  
41 Simone, Fan, & Northoff, 2010). In the AHP+ DSO group these symptoms were associated with  
42 denial of arm paralysis as identified with interviews described above. By contrast, the 'pure DSO'  
43 patients, although insisting that the left arm did not belong to them, were able to describe its  
44 paralysis accurately in the above interviews and they never claimed being able to move 'their own  
45 left arm', or behaved accordingly.  
46  
47  
48  
49  
50  
51  
52  
53  
54  
55  
56  
57  
58  
59  
60  
61  
62  
63  
64  
65



### 2.3. Neurological and neuropsychological assessment

Motor deficits were assessed by means of a standardised evaluation (Bisiach et al., 1986) which score ranges from 0 (no deficit) to 3 (severe deficit), and all patients showed a severe contralesional hemiplegia (score 3/3 for both upper and lower limbs). Hand-dominance was assessed by a questionnaire (Oldfield, 1971). Abstract reasoning was assessed by ‘Similarities’ tasks (Italian version: Appollonio et al., 2005; British version: Wechsler, 1997; sub-test of Wechsler Adult Intelligent Scale, WAIS-III; statistical comparisons for each target group were performed only with regards to the HP group patients tested with each version). Extrapersonal neglect was assessed by the line cancellation, star cancellation, figure and shape copying subtest of the Behavioural Inattention Test ((Wilson, Cockburn, & Halligan, 1987). The scores of all patients on each test were then calculated in percentages and averaged to form a composite index of neglect (see also Vocat et al., 2010). The ‘Comb/Razor test’ (McIntosh, Brodie, Beschin, & Robertson, 2000) was used for the assessment of personal neglect.

### 2.4. Lesion Analysis

#### 2.4.1. Lesion Mapping and Voxel-based Comparisons

The cerebral lesions were documented in 49 subjects via computerised tomography (CT) and in 21 subjects via magnetic resonance imaging (MRI). Lesions from these scans were segmented and co-registered using a manual procedure. Lesions were outlined by two of us (SP and VM) who were blind to each scan’s group classification. In the case of disagreement of two lesion plots, the opinion of a third, expert anatomist was requested. Scans were registered to the T1-weighted MRI scan template (ICBM152) of the Montreal Neurological Institute, furnished with the MRICron software (ch2, <http://www.cabiatl.com/mricro/mricron/index.html>).

First, the standard template (size: 181 × 217 × 181 mm, voxel resolution: 1 mm<sup>2</sup>) was rotated on the three planes in order to match the orientation of the patient’s MRI or CT scan. Lesions were outlined on the axial slices of the rotated template. The resulting lesion volumes were then rotated back into the canonical orientation, in order to align the lesion volumes of each patient to the same stereotaxic space. Finally, in order to exclude voxels of lesions outside white and gray matter brain tissue, lesion volumes were filtered by means of custom masks based on the ICBM152 template.

1 The lesion volumes of the different groups were compared by using Rorden's Non-  
2 Parametric Mapping (NPM) software (Rorden et al., 2007). Voxel-based lesion comparisons were  
3 performed in order to contrast the lesion patterns of the various clinical groups. In all these  
4 comparisons of lesions between groups (with the exception of neglect comparisons, see below),  
5 we used non-parametric analyses with dichotomic data. This was necessary as data on DSO were  
6 dichotomous (i.e. evidence of disturbances of somatic ownership or not) and the distribution of  
7 scores in control patients is by definition very limited.

8 We used a non-parametric implementation (based on the Lieberman (L) measure) of a  
9 two-group comparison on a binary variable that has proved to be more sensitive than chi-squared  
10 or Fisher's Exact test in situations without fixed marginals (Phipps, 2003; Rorden et al., 2007). Only  
11 voxels lesioned in at least 30% of the patients were included in the analysis, in order to maximize  
12 the power of analysis and avoid spurious results (Kimberg et al., 2007; Medina, Kimberg,  
13 Chatterjee, & Coslett, 2010). This means that lesioned voxels that overlapped in at least 8 patients  
14 for the comparison of the two larger groups (HP vs. AHP groups), and at least 4 patients for the  
15 comparison of AHP+DSO with HP patients were included. No thresholds were used for the DSO  
16 group because of the small number of patients (i.e., 4 patients; this limitation is acknowledged in  
17 the interpretation of the results). The binomial voxel-based lesion mapping test was then  
18 subjected to permutation by using the NPM software, in order to determine a critical L cut-off (at  
19  $p < .05$ ), based on 5000 random permutations of the data (Kimberg et al., 2007). Finally, maps of  
20 voxels with L-score intensity were generated and only the voxels that survived to the critical L  
21 value for each group comparison were considered. In the statistical group comparisons that  
22 involved the single, small group of pure DSO patients, results were corrected for multiple  
23 comparisons using a 1% false discovery rate (FDR).

24 For each main lesion comparison a power map was generated and only voxels with power  
25 enough to detect a significant result were considered (Kimberg et al., 2007). For each significant

voxel of the power map, area under ROC curve (AUROC) scores were provided, ranging between 0.5 (minimum power) to 1 (maximum discrimination power).

In addition to the above main analyses, as aforementioned we also conducted exploratory analyses on patients with ‘acute only’ versus ‘chronic’ AHP and we also conducted a separate, Voxel Lesion Symptom Mapping Analysis (VLSM, Rorden et al., 2007) on the continuous scores of the composite index for the spatial neglect. This t-test based analysis allowed us to explore the lesion sites associated with hemispatial neglect, irrespective of group classification (see Kimberg et al., 2007 for rationale of this approach). However, as our behavioural results revealed that patients with AHP had more neglect than control patients, we also conducted the same analysis only in patients with AHP to examine the patterns of lesions associated with neglect specifically in this population. In these t-test statistics, only voxels lesioned in more than 20% of the patients were used, the critical cut-off for the t-test being set at  $p=0.5$ , correcting for FDR. The results of these analyses are reported in the Supplementary Materials.

#### 2.4.2. Brain regions and tracts classification

Three anatomical templates furnished with MRICron served to identify gray and white matter region labels: the “automated anatomical labeling” (AAL) template (Tzourio-Mazoyer et al., 2002), the JHU white-matter tractography atlas, (Mori, Wakana, Zijl, & Nagae-Poetscher, 2005), and the “NatBrainLab” template of the “tractography based Atlas of human brain connections Projection Network” (Natbrainlab, Neuroanatomy and Tractography Laboratory) (Catani & Thiebaut de Schotten, 2012; Thiebaut de Schotten et al., 2011). The results regarding the superior fronto-occipital fasciculus that emerged from the JHU atlas have not been reported, because, according to current understanding, this fasciculus does not exist in humans. The JHU atlas predated this debate and wrongly indicated this structure (see debate Schmahmann et al., 2006 vs. Forkel et al., 2014). Voxel intensity values of the Natbrainlab templates (<http://www.natbrainlab.com>) were converted to 16 bit when different, and thresholded at a probability > 50% (i.e., voxels in which more than 50% of the population studied have the same tract) in order to consider only the almost invariable anatomical core of each single tract and not its periphery (Thiebaut de Schotten et al., 2011). By superimposing the significant lesion patterns on the anatomical templates we calculated the number of lesioned voxels (i.e., the amount of volume in  $\text{mm}^3$ ) and the centre of gravity (centre of mass) for each region.

### 3. Results

#### 3.1. Behavioural Results

##### 3.1.1. Demographics and Neuropsychological Performance

Socio-demographic characteristics and scores on neurological and neuropsychological tests are shown in Table 1. By means of independent samples t-test and Mann-Whitney statistics (Bonferroni corrected for multiple comparison), demographics and the composite scores on neuropsychological tests of the target groups were compared to each other and to those of the controls. Spearman correlation coefficients were used to examine potential associations between neglect scores and degree of anosognosia within each group. Results are summarised in Table 1 (demographics and comparisons with the control group) and in the text below. Due to the small sample of the DSO group (N = 4; 2 men and 2 women, mean age  $63 \pm 3$  years) only exploratory comparisons have been performed; results of the later comparisons are described in the text below.

Mean age was 66 years ( $\pm 12$ ). Patients were examined either in the acute (< 10 days, 19 patients), subacute (from 11 to 40 days, 23 patients) or the chronic phase (> 40 days, 28 patients) (see Table 1). The groups did not differ in age, interval from onset, gender (but AHP vs. HP,  $p = .04$ ), chronicity and handedness ratios.

-----  
*Table 1 about here*  
 -----

##### 3.1.2. Anosognosia for hemiplegia.

All control subjects and all the DSO patients scored 0 (no anosognosia) in the anosognosia composite index. By contrast, as expected anosognosia scores in the AHP and the AHP+DSO groups were significantly higher than zero (Table 1; Wilcoxon signed-rank test, both  $ps < 0.01$ ).

Noteworthy, even though the AHP+DSO scored higher on average on the anosognosia index score

than 'pure' AHP patients (i.e. they showed more anosognosia), this difference did not reach significant levels (see Table 1).

### 3.1.3. Neglect

For extrapersonal neglect the analysis of the composite index (0%: no neglect, 100%: maximum neglect) indicates the presence of more neglect in both AHP and AHP+DSO groups with respect to HP group (All  $ps < 0.01$ ; see Table 1). Nevertheless, the degree of anosognosia did not correlate with extrapersonal neglect ( $r_{(36)} = -0.08, p = 0.67$ ) in the AHP group ( $r_{(24)} = -0.17, p = 0.45$ ) or the AHP+DSO group ( $r_{(12)} = 0.32, p = 0.3165$ ). There was no significant difference between the AHP and AHP+DSO groups (see Table 1). Finally, the pure DSO patients (Mdn = 59%; Interquartile Range = 18%) showed less symptoms of neglect than AHP and AHP+DSO patients ( $U_{(38)} = 31, Z = 1.87, p < 0.031$ ), with an average performance comparable to HP patients ( $U_{(30)} = 36, Z = 1.17, p = 0.12$ ).

The groups showed a similar pattern of results on personal neglect. Personal neglect was significantly worse in the AHP+DSO group with respect to HP controls (all  $ps < 0.01$ ; see Table 1), while there was no difference between AHP and HP controls and between the AHP and AHP+DSO groups (see Table 1). Personal neglect did not correlate with the degree of anosognosia ( $r_{(31)} = -0.07, p = 0.69$ ) in the AHP ( $r_{(23)} = -0.19, p = 0.38$ ), nor in the AHP+DSO group ( $r_{(8)} = 0.43, p = 0.29$ ). Although the difference was not statistically significant, DSO patients (Mdn = 0; Interquartile Range = 0.56) tended to perform better relative to AHP+DSO patients ( $U = 27, Z = 1.87, p = 0.07$ ). There was no statistically significant difference between the DSO group and AHP patients ( $U = 63, Z = 1.1, p = 0.27$ ), or the control HP group ( $U = 58, Z = 0.11, p = 0.93$ ).

### 3.1.4. Executive functions

The AHP and the AHP+DSO groups performed worse in comparison to the HP group (all  $ps < 0.05$ ; see Table 1) on the Similarities task, but there was no difference between the two target groups (see Table 1).

## 3.2. Lesions Associated with Anosognosia

### 3.2.1. 'Pure' Anosognosia in acute phase: AHP vs. HP Group Comparisons

1  
2  
3  
4  
5  
6  
7  
8  
9  
10  
11  
12  
13  
14  
15  
16  
17  
18  
19  
20  
21  
22  
23  
24  
25  
26  
27  
28  
29  
30  
31  
32  
33  
34  
35  
36  
37  
38  
39  
40  
41  
42  
43  
44  
45  
46  
47  
48  
49  
50  
51  
52  
53  
54  
55  
56  
57  
58  
59  
60  
61  
62  
63  
64  
65

In order to find lesions specifically associated with AHP in the acute phase (irrespective of whether the symptoms would spontaneously recover or not – see below), we compared the lesions of the AHP group (25 patients) with the lesions of the HP group (28 patients; see Table 2, first column). A lesion cluster was centered on the subcentral gyrus (Naidich et al., 2004), reaching the dorsal part of the right insula (Figure 1.A, axial plane Z=19) and extended cortically to the adjacent ventral premotor cortex, involving a small part of both the parietal and frontal operculum. It also encompassed the Heschl and temporal superior gyrus, but spared the primary somatosensory and primary motor cortex. Subcortically, it extended to the tracts of the superior corona radiata and external capsule, and reached the more dorsal part of the caudate nucleus. Significant voxels were also found in the superior longitudinal fasciculus (SLF). According to the white matter atlas of the Natbrainlab laboratory (Catani & Thiebaut de Schotten, 2012; Thiebaut de Schotten et al., 2011), significant voxels were present on the cortico-spinal tract, internal capsule, and the arcuate fasciculus, in particular in the anterior segment. This segment is known to run next to the ventral part of the superior longitudinal fasciculus (or SLF III) and connects parietal with frontal regions (Martino et al., 2013; Thiebaut de Schotten et al., 2011).

-----  
*Figure 1 and Table 2 about here*  
 -----

### 3.2.2. Transient versus lasting anosognosia: $AHP_{acute\ only}$ and $AHP_{chronic}$ vs HP

In order to investigate the differences in lesions between patients who showed anosognosia in both the acute and chronic stages (>40 days;  $AHP_{chronic}$ ;  $N = 14$ ) with those who recovered awareness within 40 days ( $AHP_{acute\ only}$ ;  $N = 6$ ), we compared the lesions of the two groups of AHP patients ( $AHP_{acute\ only}$  and  $AHP_{chronic}$  separately) with all the HP controls, using the same criteria and statistical methods as for the other main comparisons (as described in Methods). As shown in Table 2 (middle and right columns) results indicate that patients who remain anosognosic in the chronic phase present with more cortical lesions, involving ventral premotor cortex and the temporal superior cortex. Nevertheless, lesions also extend to the subcortical white matter, in particular to the cortico-spinal tract (corresponding to superior corona radiata in JHU atlas), anterior arcuate fasciculus (corresponding to SLF in JHU atlas) and part of the body of corpus callosum (not detected in the JHU atlas).

### 3.3. Lesions associated with Anosognosia versus with Body Ownership Disturbances

In 13 out of our 28 AHP patients, anosognosia was concomitant with disturbed sensations of limb ownership (DSO). This gave us the opportunity to investigate potential different lesional correlates of the two syndromes in two ways. Firstly, by means of indirect comparisons, we compared patients with both AHP and DSO (AHP+DSO) against the HP control group to examine qualitatively how this difference compared with the one above between the pure AHP patients and the HP controls (section 3.2.1). In a separate analysis of the same rationale, we also added the four “pure” DSO patients into the AHP+DSO group to see how their difference from controls compared with the results of section 3.2.1. Secondly, by means of direct comparisons, we then compared the patients with AHP+DSO against the pure AHP group. This set of analyses allowed us to explore the potential patterns of lesions differently correlated to the two syndromes and in relation to control hemiplegic patients.

#### 3.3.1. Indirect Comparisons

##### 3.3.1.1. AHP+DSO vs. HP

When compared to HP controls, AHP+DSO was associated only with subcortical lesions in basal ganglia and white matter (Table 3, first column). Significant voxels were located in the putamen, the caudate (only one voxel), and surrounding tracts of the internal capsule. Similarly, the NatBrainLab atlas showed significant voxels in the internal capsule, with additional significant voxels in the cortico-spinal and cortico-pontine tracts, and a small cluster in the arcuate fasciculus.

-----  
*Table 3 about here*  
 -----

##### 3.3.1.2. AHP+DSO and DSO vs. HP

When we add the four patients affected by pure DSO to the above lesion analysis (i.e. AHP+DSO, DSO vs. HP), we find a similar pattern of results (Table 3 second column, and Figure 2), with significance in all the regions of the previous comparison (AHP+DSO vs. HP). In addition, the

amount of significant voxels increases, in particular in the caudate nucleus. In the JHU atlas the superior corona radiate emerges while in the Natbrainlab atlas an additional significant cluster of lesion emerges in the white matter tracts of the corpus callosum.

-----  
*Figure 2 about here*  
 -----

### 3.3.2 Direct comparisons between pure AHP and mixed AHP and DSO groups (AHP vs. AHP+DSO)

The direct comparison of lesions involved in AHP vs. the AHP+DSO Groups (and vice versa) did not show any significant results in our sample. Therefore, in explorative analyses with limited explanatory power (please see Discussion), we investigated the results of the same voxel-based lesion comparisons by using less restrictive criteria. All voxels were included in the comparison (not only voxels lesioned in at least 30% of the patients), and a less restrictive correction criteria was used (1% False Discovery Rate).

We found that AHP+DSO patients showed lesions in the thalamus, caudate and pallidum more frequently than AHP. Moreover, the subcortical damage, especially in the posterior white matter tracts, appeared more evident (Figure 3A, Table 3, third column), with the JHU atlas reporting significant voxels in the anterior capsule and in two small clusters in superior longitudinal fasciculus and posterior thalamic radiations, and the Natbrainlab atlas reporting significant voxels in the cortico-spinal tract, the corpus callosum and the fornix. On the other hand, patients with isolated AHP showed more frequent lesions only in 16 voxels in the amygdala in comparison to patients with AHP+DSO (Figure 3B, Table 3, last column). This minimal result and the absence of any higher order cortical areas is not surprising given the fact that both groups in this comparison showed AHP, and the additional presence of DSO seems to be associated mostly with subcortical lesions (see above). Finally, according to the JHU, but not to the Natbrainlab atlas, there was a significant cluster in the capsule. Natbrainlab atlas indicated the involvement of the anterior commissure, the inferior longitudinal fasciculus, the inferior occipito frontal fasciculus, the optic radiations and the uncinata.

-----  
*Figure 3 about here*  
 -----



1  
2 Taken together, indirect and exploratory direct comparisons of lesions involved in anosognosia  
3 (AHP) versus disturbed sensations of limbs ownership (DSO) indicate a shift of damage from more  
4 cortical regions (mainly involved in AHP) towards subcortical structures, such as basal ganglia and  
5 thalamus, and the surrounding white matter, which are principally involved in DSO.  
6  
7  
8  
9

### 10 3.3.3. *Supplementary Lesion Analyses*

11  
12 Further analyses regarding: 1) the comparison of all patients suffering from body awareness  
13 disorders (AHP and AHP+DSO) versus HP; 2) the explorative analyses of the 'pure' DSO small group  
14 versus all the other groups (AHP, AHP+DSO and HP); and 3) the lesional correlates of neglect are  
15 reported in the Supplementary Materials. In brief, the first two sets of these analyses provided  
16 further support for the finding that the lesions associated with pure AHP are more cortical and  
17 lateral than those associated with either pure DSO, or a combination of body awareness disorders.  
18 Finally, the third analyses showed that the critical set of lesions associated with visuospatial  
19 neglect differs from that associated with AHP, DSO and their combination.  
20  
21  
22  
23  
24  
25  
26  
27  
28  
29  
30

## 31 4. Discussion

32  
33 The main purpose of the study was to investigate in a relatively large sample of patients (N = 70)  
34 the patterns of lesions associated with anosognosia for hemiplegia (AHP) and their potential  
35 specificity in relation to the lesions associated with the hemiplegia itself, as well as with  
36 concomitant disordered feelings of body ownership (DSO). In addition, we were interested in  
37 exploring the pattern of lesions associated with other manifestations of the syndrome such as  
38 symptom duration and neglect.  
39  
40  
41  
42  
43

44 Our results indicate that while acute AHP is associated with damage to several cortical and  
45 subcortical areas, there is specific involvement of three principal cortical areas **around the**  
46 **subcentral gyrus**: (1) the Rolandic operculum (ventral premotor cortex), (2) the insula and (3) the  
47 Heschl and superior temporal gyri. In addition, damage was observed subcortically, mainly in the  
48 basal ganglia, while white matter lesions seemed to affect mostly the superior corona radiata, and  
49 the external capsule. According to the white matter atlas of the Natbrainlab laboratory (Catani &  
50 Thiebaut de Schotten, 2012; Thiebaut de Schotten et al., 2011), significant lesions were present on  
51 the cortico-spinal tract and the **anterior segment of the arcuate fasciculus, in a region next to the**  
52 **ventral superior longitudinal fasciculus of the perisylvian network** (SFLIII) (Thiebaut de Schotten et  
53  
54  
55  
56  
57  
58  
59  
60  
61  
62  
63  
64  
65

al., 2011; Martino et al., 2013). Furthermore, in acute AHP, damage to the insula and basal ganglia seemed crucial, but for the persistence of the symptom beyond 40 days, wider damage involving fronto-temporal cortex and long white matter tracts seemed necessary. A shift in the latero-medial direction (and mainly involving the basal ganglia) emerged when DSO co-occurred with AHP (relative to HP controls), although direct comparisons between the pure AHP and the mixed AHP+DSO groups did not reveal any significant differences, possibly due to the smaller samples involved. However, the potential role of the basal ganglia and their connections with cortical areas in DSO was confirmed by exploratory (i.e. using less restrictive criteria) direct comparisons between the pure and the mixed AHP groups, as well as the lesion patterns of four rare patients suffering from pure DSO. These results are discussed in turn below.

#### 4.1. Lesion Patterns Associated with Anosognosia for Hemiplegia

The large sample of anosognosic patients analysed in this study (N = 38) permits us to confirm and expand the crucial role that certain cerebral structures and tracts have in motor awareness (see table 4). Specifically, our study confirms the involvement of both the insular cortex (Berti et al., 2005; Fotopoulou et al., 2010; Karnath et al., 2005; Moro et al., 2011; Vocat et al., 2010) and the lateral premotor cortex (Berti et al., 2005; Fotopoulou et al., 2010; Kortte et al., 2015; Moro et al., 2011; Vocat et al., 2010) in AHP. Nevertheless, contrary to earlier claims, AHP does not seem to be associated with isolated lesions in the insula (Karnath et al., 2005). Instead, our results confirm the involvement of both of these regions (see also Berti et al., 2005; Kortte et al., 2015) and furthermore, point to a wider network of areas including perisylvian areas of the frontal, temporal and parietal cortices (Heschl gyrus, rolandic operculum and anterior temporal superior gyrus) and the underlying white matter, as well as subcortical involvement of the basal ganglia (see below). These results are thus consistent with other, recent studies finding similar involvement of cortical and subcortical areas and tracts in smaller samples (Besharati et al., 2014; 2016; Fotopoulou et al., 2010; Moro et al., 2011; Romano, Gandola, Bottini, & Maravita, 2014; Vocat et al., 2010).

Table 4 near here

Functionally, this wider pattern of lesions suggests that AHP is not the result of a pure deficit of sensorimotor monitoring (Berti et al., 2005), or multisensory body representation (Karnath et al., 2005). These results can instead be interpreted as supporting recent multifactorial

1 theories of AHP that propose the syndrome is caused by a collection of heterogeneous  
2 disturbances (Davies et al., 2005; Marcel et al., 2004; Mograbi & Morris, 2013; Vuilleumier, 2004).  
3 For example, our anosognosic patients were more impaired than hemiplegic control patients both  
4 in neglect and executive functions. This is in line with previous reports that indicate a role of  
5 visuospatial neglect and spatiotemporal disorientation in determining AHP in the sub-acute phase  
6 (Vocat et al., 2010). Nevertheless, we did not find any correlations between severity of AHP and  
7 these symptoms. In addition, the lesion analysis of the neuroanatomical correlates of spatial  
8 neglect in the AHP group (see Supplementary Materials) indicates that this is selectively associated  
9 with temporo-parieto-occipital areas. These lesions are more cortical and posterior compared to  
10 those involved in AHP. Thus, a causative role of these symptoms in the syndrome appears unlikely,  
11 but future studies should study their combination (see also below), as well as explore their  
12 combined effects with other deficits, such as proprioception that we did not have the chance to  
13 explore in this study.  
14  
15  
16  
17  
18  
19  
20  
21  
22  
23  
24

25         Alternatively, our findings could be interpreted as the result of a functional disconnection  
26 between top-down, premorbidly learned predictions regarding one's body and the processing of  
27 bottom-up 'prediction errors' regarding its current state (Fotopoulou, 2012, 2014, 2015). These  
28 disconnections may occur at different levels of the neurocognitive hierarchy. For example, the  
29 observed damage to the premotor cortex, as well as the ventral part of the superior longitudinal  
30 fasciculus may have resulted in a disconnection between somatosensory areas in the parietal  
31 cortex and ventral premotor and the prefrontal regions, resulting in impaired ability to detect and  
32 monitor incongruent sensorimotor feedback (Enriquez-Geppert, Huster, Figge, & Herrmann,  
33 2014), as previous studies have suggested (Berti et al., 2005; Korte et al., 2015). Similar inability  
34 in processing prediction errors (Magno, Foxe, Molholm, Robertson, & Garavan, 2006; Taylor,  
35 Stern, & Gehring, 2007) in the domain of multisensory integration may have influenced the  
36 behavior of patients with damage to the insula (Karnath et al., 2005). Unfortunately, there are  
37 currently only a handful of mostly small sample studies that have included direct comparisons  
38 between lesion and experimental results in AHP. Although mostly underpowered, the results of  
39 such studies indeed suggest that the different behavioural variants of AHP are associated with  
40 distinct lesion patterns (Besharati et al., 2015; Fotopoulou et al., 2010; Valentina Moro et al.,  
41 2011). Unfortunately, unlike the present study, such studies cannot control for the precise  
42 influence of other factors such as neglect, time from onset and the presence of DSO.  
43  
44  
45  
46  
47  
48  
49  
50  
51  
52  
53  
54  
55  
56  
57  
58  
59  
60  
61  
62  
63  
64  
65

1  
2  
3  
4  
5  
6  
7  
8  
9  
10  
11  
12  
13  
14  
15  
16  
17  
18  
19  
20  
21  
22  
23  
24  
25  
26  
27  
28  
29  
30  
31  
32  
33  
34  
35  
36  
37  
38  
39  
40  
41  
42  
43  
44  
45  
46  
47  
48  
49  
50  
51  
52  
53  
54  
55  
56  
57  
58  
59  
60  
61  
62  
63  
64  
65

In addition, in the present study, although we did not find specific lesions associated with AHP in the right temporo-parietal junction, we found that the anterior temporal superior gyrus is damaged selectively in AHP as compared to the HP controls. This area has been linked previously with deficits of perspective-taking and mentalisation in AHP (Besharati et al., 2015), potentially explaining why patients cannot update their anosognosic beliefs based on third-person feedback (Fotopoulou, 2015; Moro et al., 2011). Furthermore, the involvement of the arcuate fasciculus and the superior longitudinal fasciculus (SLF III) in AHP, suggests a further possibility of functional disconnection between temporo-parietal and premotor areas. In order to investigate such hypotheses and possibilities, future large-sample studies will need to correlate lesion patterns with findings from several well-controlled behavioral experiments tested on the same sample.

#### 4.2. Lesion Patterns Associated with Chronic Anosognosia

In our study, exploratory analyses of the differences between patients who showed anosognosia in both the sub-acute and chronic stages (>40 days), with those who recovered awareness within 40 days, revealed that AHP in acute stage is more correlated to lesions involving the insula, caudate, putamen, internal and external capsule and the inferior occipito-frontal fasciculus. By contrast, patients who remain unaware show more lesions in the ventral premotor cortex, thalamus, Heschl, temporal superior cortex, the cortico-spinal tract, the arcuate anterior segment and the corpus callosum. Lesions common to both groups were in the insula, external and internal capsule and superior corona radiate. Thus, our findings are in line with and extend previous findings from the only existing study to investigate the evolution of AHP over time (Vocat et al., 2010), showing that chronic AHP is correlated with greater cortical damage compared with short-lasting AHP.

#### 4.3. Lesion Patterns Associated with Disturbances of Body Ownership

Disturbances of body ownership (DSO) have been found to co-occur frequently with AHP (for a review see Vallar & Ronchi, 2009). Initial studies suggested common critical lesions in the insular cortex underlying disorders of limb ownership and action awareness (Baier & Karnath, 2008); however, more recent investigations argued in favor of behavioural and neural dissociations between AHP and DSO (Gandola et al., 2012; Invernizzi et al., 2013; Vallar & Ronchi, 2009). DSO was found to be associated with more grey subcortical structures and white matter bundles, while damage to the inferior frontal gyrus may critically relate only to AHP and not DSO (Zeller et al.,

1  
2  
3  
4  
5  
6  
7  
8  
9  
10  
11  
12  
13  
14  
15  
16  
17  
18  
19  
20  
2011). Our study involved a number of critical direct and indirect (i.e. in relation to the HP control group) comparisons between AHP and DSO. Although direct comparisons seemed underpowered to detect any differences between these groups, exploratory analyses with less conservative thresholds, as well as qualitative comparisons between pure and mixed groups against the hemiplegic controls, revealed that DSO is associated with less cortical damage, particularly in the insular cortex and rolandic operculum compared with AHP. Conversely, the damage appears more evident in the basal ganglia and in the surrounding white matter. Taken together our results suggest that the presence of DSO in either pure cases or concomitantly with AHP is associated with lesion patterns that are more medial and subcortical than those associated with pure AHP. In particular the lesion of thalamus and fornix, although not statistically significant, may suggest a role of memory and learning in DSO symptoms.

21  
22  
23  
24  
25  
26  
27  
28  
29  
30  
31  
32  
33  
34  
35  
36  
37  
38  
39  
40  
41  
42  
43  
44  
45  
46  
47  
48  
49  
50  
51  
52  
53  
54  
55  
56  
57  
58  
59  
60  
61  
62  
63  
64  
65  
These findings thus contradict the results of studies proposing a cortical system of multimodal areas (including insula, lateral premotor cortex, the inferior parietal lobe and the right posterior temporal cortex; Baier & Karnath, 2008; Ehrsson, Spence, & Passingham, 2004; Feinberg, Haber, & Leeds, 1990; Feinberg et al., 2010; Tsakiris et al., 2007; Vallar & Ronchi, 2009) as the main neural locus of the sense of body ownership. Instead, in agreement with more recent lesion studies on DSO (Gandola et al., 2012; Invernizzi et al., 2013; Romano et al., 2014), our results suggest that subcortical grey areas and related white matter tracks may be necessary for rudimentary feelings of limb ownership, which are then presumably re-represented at the above higher cortical areas to integrate them with other aspects of self-awareness, such as self-other distinction, spatial and temporal self-awareness, as well as the sense of action awareness and agency (Blanke, 2012; Tsakiris, Longo, & Haggard, 2010).

#### 4.4. Limitations

Our study is subject to common limitations of current voxel-based, lesion analyses methods in stroke research (Geva, Baron, Jones, Price, & Warburton, 2012; Rorden et al., 2007; Volle, Gonen-Yaacovi, de Lacy Costello, Gilbert, & Burgess, 2011), including suboptimal characterization of dynamic brain processes following stroke (e.g., diaschisis). Moreover, although we did examine lesions to white matter tracts on the basis of clinical scans, specific white matter investigation techniques, such as tractography, may offer a significant improvement to our conclusions. It should be noted that our lesion analyses were based on dichotomous data (binomial comparisons between two groups) without a continuous variable, and therefore we were not able to control for

1 nuisance covariates in the statistical software (e.g. time since symptom onset). Although we were  
2 able to overcome limitations of the Bonferroni and FDR corrections by means of the permutation  
3 tests (Kimberg et al., 2007), the use of this statistical model in the software further limits the use  
4 of covariates. Similar considerations apply to our exploratory lesion comparison between acute  
5 only vs. chronic cases (dichotomous data depended on a cut-off), in which the difference between  
6 scanning time and assessment time was not controlled for.

7  
8  
9  
10  
11 Furthermore, although we combined previous data to form a large sample that would  
12 allow better localisation of function in AHP and related pathologies, the characteristics of the  
13 scans used in the study differed depending on the centre they were collected. Similarly, there  
14 were also a limited number of behavioural assessments that all three centers have used to test the  
15 variables of interest, and future studies could provide further neuropsychological, as well as  
16 experimental, characterization of the symptoms under consideration. Finally, the number of  
17 patients in each subgroup were not equal, rendering some of our behavioural and lesion analyses  
18 merely exploratory.

#### 28 *4.5. Conclusions*

29 We believe that our results, taken together, are consistent with a number of conclusions  
30 generated in previous research with smaller samples and, importantly, they are able to  
31 disentangle some of the ambiguities generated by such smaller studies. In brief, they suggest that  
32 anosognosia for hemiplegia does not seem to be associated only with isolated lesions to the insula  
33 and the lateral premotor cortex, but rather to a wider network of areas including perisylvian areas  
34 of the frontal, temporal and parietal cortices (Heschl gyrus, rolandic operculum and anterior  
35 temporal superior gyrus) and the underlying white matter, as well as subcortical involvement of  
36 the basal ganglia. More extensive cortical damage seems to lead to more chronic anosognosia,  
37 while the subcortical involvement appears to be mostly associated with concomitant disturbances  
38 in body ownership.

#### 53 **Acknowledgements**

54 We will like to help Sahba Besharati, Laura Crucianelli and Cristina Bulgarelli for their help with  
55 data organisation and entry. This study was supported by a European Research Council Starting  
56 Investigator Award [ERC-2012-STG GA313755] to A.F., by the Italian Ministry of Health (and RF-  
57  
58  
59  
60  
61  
62  
63  
64  
65

2010-2312912) and University of Verona to V.M., and by the Fondazione Cariverona (Neuroscience Project- Prot. N. 1855) to S.P.

1  
2  
3  
4  
5  
6  
7  
8  
9  
10  
11  
12  
13  
14  
15  
16  
17  
18  
19  
20  
21  
22  
23  
24  
25  
26  
27  
28  
29  
30  
31  
32  
33  
34  
35  
36  
37  
38  
39  
40  
41  
42  
43  
44  
45  
46  
47  
48  
49  
50  
51  
52  
53  
54  
55  
56  
57  
58  
59  
60  
61  
62  
63  
64  
65

## References

- 1  
2 Appollonio, I., Leone, M., Isella, V., Piamarta, F., Consoli, T., Villa, M. L., ... Nichelli, P. (2005). The  
3  
4 Frontal Assessment Battery (FAB): normative values in an Italian population sample.  
5  
6  
7 *Neurological Sciences: Official Journal of the Italian Neurological Society and of the Italian*  
8  
9 *Society of Clinical Neurophysiology*, 26(2), 108–116. <http://doi.org/10.1007/s10072-005->  
10  
11 0443-4  
12  
13  
14 Babinski, J. (1914). Contribution to the study of mental disorders in organic cerebral hemiplegia  
15  
16 (anosognosia). *Rev Neurol (Paris)*, 27, 845–848.  
17  
18  
19  
20 Baier, B., & Karnath, H.-O. (2008). Tight link between our sense of limb ownership and self-  
21  
22 awareness of actions. *Stroke*, 39(2), 486–488.  
23  
24  
25 Berti, A., Bottini, G., Gandola, M., Pia, L., Smania, N., Stracciari, A., ... Paulesu, E. (2005). Shared  
26  
27 Cortical Anatomy for Motor Awareness and Motor Control. *Science*, 309(5733), 488–491.  
28  
29 <http://doi.org/10.1126/science.1110625>  
30  
31  
32 Berti, A., Làdavas, E., & Della Corte, M. (1996). Anosognosia for hemiplegia, neglect dyslexia, and  
33  
34 drawing neglect: clinical findings and theoretical considerations. *Journal of the*  
35  
36 *International Neuropsychological Society: JINS*, 2(5), 426–440.  
37  
38  
39  
40 Besharati, S., Kopelman, M., Avesani, R., Moro, V., & Fotopoulou, A. (2015). Another perspective  
41  
42 on anosognosia: Self-observation in video replay improves motor awareness.  
43  
44  
45 *Neuropsychological Rehabilitation*, 25(3), 319–352.  
46  
47  
48 Bisiach, E., Vallar, G., Perani, D., Papagno, C., & Berti, A. (1986). Unawareness of disease following  
49  
50 lesions of the right hemisphere: anosognosia for hemiplegia and anosognosia for  
51  
52 hemianopia. *Neuropsychologia*, 24(4), 471–482.  
53  
54  
55  
56 Blanke, O., (2012). Multisensory brain mechanisms of bodily self-consciousness. *Nature Reviews*  
57  
58 *Neuroscience*, 12, 556-571.  
59  
60  
61  
62  
63  
64  
65



1  
2  
3  
4  
5  
6  
7  
8  
9  
10  
11  
12  
13  
14  
15  
16  
17  
18  
19  
20  
21  
22  
23  
24  
25  
26  
27  
28  
29  
30  
31  
32  
33  
34  
35  
36  
37  
38  
39  
40  
41  
42  
43  
44  
45  
46  
47  
48  
49  
50  
51  
52  
53  
54  
55  
56  
57  
58  
59  
60  
61  
62  
63  
64  
65

Catani, M., & Thiebaut de Schotten, M. (2012). *Atlas of human brain connections*. Oxford: Oxford University Press.

Cocchini G., Beschin N., Della Sala S. (2002) Chronic anosognosia: a case report and theoretical account. *Neuropsychologia*, 40, 2030-2038.

Cocchini, G., Beschin, N., Cameron, A., Fotopoulou, A., & Della Sala, S. (2009). Anosognosia for motor impairment following left brain damage. *Neuropsychology*, 23(2), 223.

Cocchini, G., Beschin, N., Fotopoulou, A., & Della Sala, S. (2010). Explicit and implicit anosognosia or upper limb motor impairment. *Neuropsychologia*, 48(5), 1489–1494.

Cocchini G. & Della Sala S.,(2010) Assessing Anosognosia for motor and language impairments. In : Prigatano, G. P. (2010). *The study of anosognosia*. Oxford University Press

Craig, A. D. (2009). How do you feel—now? The anterior insula and human awareness. Retrieved from <http://psycnet.apa.org/psycinfo/2009-00363-005>

Davies, M., Davies, A. A., & Coltheart, M. (2005). Anosognosia and the Two-factor Theory of Delusions. *Mind & Language*, 20(2), 209–236.

Ehrsson, H. H., Spence, C., & Passingham, R. E. (2004). That's my hand! Activity in premotor cortex reflects feeling of ownership of a limb. *Science*, 305(5685), 875–877.

Enriquez-Geppert, S., Huster, R. J., Figge, C., & Herrmann, C. S. (2014). Self-regulation of frontal-midline theta facilitates memory updating and mental set shifting. *Frontiers in Behavioral Neuroscience*, 8. Retrieved from <http://www.ncbi.nlm.nih.gov/pmc/articles/PMC4257088/>

Feinberg, T. E., Haber, L. D., & Leeds, N. E. (1990). Verbal asomatognosia. *Neurology*, 40(9), 1391–1391.

Feinberg, T. E., Venneri, A., Simone, A. M., Fan, Y., & Northoff, G. (2010). The neuroanatomy of asomatognosia and somatoparaphrenia. *Journal of Neurology, Neurosurgery, and Psychiatry*, 81(3), 276–281. <http://doi.org/10.1136/jnnp.2009.188946>

1 Fletcher, P., & Fotopoulou, A. (2015). Sense of agency and its disruption: Clinical and  
 2 computational perspectives. In P. Haggard & B. Eitam (eds.) , *The sense of agency* (pp. 347-  
 3 370). New York: Oxford University Press.  
 4  
 5

6  
 7 Forkel, S. J., Thiebaut de Schotten, M., Kawadler, J. M., Dell'Acqua, F., Danek, A., & Catani, M.  
 8 (2014). The anatomy of fronto-occipital connections from early blunt dissections to  
 9 contemporary tractography. *Cortex*, 56, 73–84.  
 10  
 11 <http://doi.org/10.1016/j.cortex.2012.09.005>  
 12  
 13  
 14  
 15  
 16  
 17

18 Fotopoulou, A. (2014). Time to get rid of the “Modular” in neuropsychology: A unified theory of  
 19 anosognosia as aberrant predictive coding. *Journal of Neuropsychology*, 8(1), 1–19.  
 20  
 21  
 22

23 Fotopoulou, A. (2015). The virtual bodily self: Mentalisation of the body as revealed in  
 24 anosognosia for hemiplegia. *Consciousness and Cognition*, 33, 500–510.  
 25  
 26  
 27

28 Fotopoulou, A., Jenkinson, P. M., Tsakiris, M., Haggard, P., Rudd, A., & Kopelman, M. D. (2011).  
 29 Mirror-view reverses somatoparaphrenia: dissociation between first-and third-person  
 30 perspectives on body ownership. *Neuropsychologia*, 49(14), 3946–3955.  
 31  
 32  
 33  
 34  
 35

36 Fotopoulou, A. K. (2012). Illusions and delusions in anosognosia for hemiplegia: from motor  
 37 predictions to prior beliefs. *Brain*, 135(5), 1344–1346.  
 38  
 39  
 40

41 Fotopoulou, A., Pernigo, S., Maeda, R., Rudd, A., & Kopelman, M. A. (2010). Implicit awareness in  
 42 anosognosia for hemiplegia: unconscious interference without conscious re-  
 43 representation. *Brain*, 133(12), 3564–3577. <http://doi.org/10.1093/brain/awq233>  
 44  
 45  
 46  
 47  
 48

49 Fotopoulou, A., Tsakiris, M., Haggard, P., Vagopoulou, A., Rudd, A., & Kopelman, M. (2008). The  
 50 role of motor intention in motor awareness: an experimental study on anosognosia for  
 51 hemiplegia. *Brain*, 131(12), 3432–3442.  
 52  
 53  
 54  
 55  
 56  
 57  
 58  
 59  
 60  
 61  
 62  
 63  
 64  
 65

- 1  
2  
3  
4  
5  
6  
7  
8  
9  
10  
11  
12  
13  
14  
15  
16  
17  
18  
19  
20  
21  
22  
23  
24  
25  
26  
27  
28  
29  
30  
31  
32  
33  
34  
35  
36  
37  
38  
39  
40  
41  
42  
43  
44  
45  
46  
47  
48  
49  
50  
51  
52  
53  
54  
55  
56  
57  
58  
59  
60  
61  
62  
63  
64  
65
- Gandola, M., Bottini, G., Zapparoli, L., Invernizzi, P., Verardi, M., Sterzi, R., ... Paulesu, E. (2014). The physiology of motor delusions in anosognosia for hemiplegia: Implications for current models of motor awareness. *Consciousness and Cognition*, *24*, 98–112.
- Gandola, M., Invernizzi, P., Sedda, A., Ferrè, E. R., Sterzi, R., Sberna, M., ... Bottini, G. (2012). An anatomical account of somatoparaphrenia. *Cortex*, *48*(9), 1165–1178.
- Geva, S., Baron, J.-C., Jones, P. S., Price, C. J., & Warburton, E. A. (2012). A comparison of VLSM and VBM in a cohort of patients with post-stroke aphasia. *NeuroImage: Clinical*, *1*(1), 37–47.
- Gialanella, B., & Mattioli, F. (1992). Anosognosia and extrapersonal neglect as predictors of functional recovery following right hemisphere stroke. *Neuropsychological Rehabilitation*, *2*(3), 169–178.
- Hartman-Maeir, A., Soroker, N., & Katz, N. (2001). Anosognosia for hemiplegia in stroke rehabilitation. *Neurorehabilitation and Neural Repair*, *15*(3), 213–222.
- Invernizzi, P., Gandola, M., Romano, D., Zapparoli, L., Bottini, G., & Paulesu, E. (2013). What is mine? Behavioral and anatomical dissociations between somatoparaphrenia and anosognosia for hemiplegia. *Behavioural Neurology*, *26*(1-2), 139–150.
- Jackson, J. H. (1998). *Evolution and dissolution of the nervous system*. Thoemmes Press.
- Jehkonen, M., Laihosalo, M., & Kettunen, J. (2006). Anosognosia after stroke: assessment, occurrence, subtypes and impact on functional outcome reviewed. *Acta Neurologica Scandinavica*, *114*(5), 293–306.
- Jenkinson, P. M., Edelstyn, N. M., Drakeford, J. L., & Ellis, S. J. (2009). Reality monitoring in anosognosia for hemiplegia. *Consciousness and Cognition*, *18*(2), 458–470.
- Jenkinson, P. M., Edelstyn, N. M., & Ellis, S. J. (2009). Imagining the impossible: motor representations in anosognosia for hemiplegia. *Neuropsychologia*, *47*(2), 481–488.

- 1  
2  
3  
4  
5  
6  
7  
8  
9  
10  
11  
12  
13  
14  
15  
16  
17  
18  
19  
20  
21  
22  
23  
24  
25  
26  
27  
28  
29  
30  
31  
32  
33  
34  
35  
36  
37  
38  
39  
40  
41  
42  
43  
44  
45  
46  
47  
48  
49  
50  
51  
52  
53  
54  
55  
56  
57  
58  
59  
60  
61  
62  
63  
64  
65
- Jenkinson, P. M., & Fotopoulou, A. (2014). Understanding Babinski's anosognosia: 100 years later. *Cortex*, *61*, 1–4.
- Jenkinson, P. M., Haggard, P., Ferreira, N. C., & Fotopoulou, A. (2013). Body ownership and attention in the mirror: Insights from somatoparaphrenia and the rubber hand illusion. *Neuropsychologia*, *51*(8), 1453–1462.
- Jenkinson, P. M., Preston, C., & Ellis, S. J. (2011). Unawareness after stroke: a review and practical guide to understanding, assessing, and managing anosognosia for hemiplegia. *Journal of Clinical and Experimental Neuropsychology*, *33*(10), 1079–1093.  
<http://doi.org/10.1080/13803395.2011.596822>
- Karnath, H.-O., Baier, B., & Nägele, T. (2005). Awareness of the Functioning of One's Own Limbs Mediated by the Insular Cortex? *The Journal of Neuroscience*, *25*(31), 7134–7138.  
<http://doi.org/10.1523/JNEUROSCI.1590-05.2005>
- Kimberg, D. Y., Coslett, H. B., & Schwartz, M. F. (2007). Power in Voxel-based lesion-symptom mapping. *Journal of Cognitive Neuroscience*, *19*(7), 1067–1080.  
<http://doi.org/10.1162/jocn.2007.19.7.1067>
- Kortte, K. B., McWhorter, J. W., Pawlak, M. A., Slentz, J., Sur, S., & Hillis, A. E. (2015). Anosognosia for hemiplegia: The contributory role of right inferior frontal gyrus. *Neuropsychology*, *29*(3), 421.
- Magno, E., Foxe, J. J., Molholm, S., Robertson, I. H., & Garavan, H. (2006). The anterior cingulate and error avoidance. *The Journal of Neuroscience*, *26*(18), 4769–4773.
- Marcel, A. J., Tegnér, R., & Nimmo-Smith, I. (2004). Anosognosia for plegia: Specificity, extension, partiality and disunity of bodily unawareness. *Cortex*, *40*(1), 19–40.
- Martino, J., De Witt Hamer, P. C., Berger, M. S., Lawton, M. T., Arnold, C. M., de Lucas, E. M., & Duffau, H. (2013). Analysis of the subcomponents and cortical terminations of the

perisylvian superior longitudinal fasciculus: a fiber dissection and DTI tractography study.

*Brain Structure & Function*, 218(1), 105–121. <http://doi.org/10.1007/s00429-012-0386-5>

McIntosh, R. D., Brodie, E. E., Beschin, N., & Robertson, I. H. (2000). Improving the clinical diagnosis of personal neglect: a reformulated comb and razor test. *Cortex; a Journal Devoted to the Study of the Nervous System and Behavior*, 36(2), 289–292.

Medina, J., Kimberg, D. Y., Chatterjee, A., & Coslett, H. B. (2010). Inappropriate usage of the Brunner-Munzel test in recent voxel-based lesion-symptom mapping studies. *Neuropsychologia*, 48(1), 341–343. <http://doi.org/10.1016/j.neuropsychologia.2009.09.016>

Mograbi, D. C., & Morris, R. G. (2013). Implicit awareness in anosognosia: Clinical observations, experimental evidence, and theoretical implications. *Cognitive Neuroscience*, 4(3-4), 181–197.

Mori, S., Wakana, S., Zijl, P. C. M. van, & Nagae-Poetscher, L. M. (2005). *MRI Atlas of Human White Matter*. Elsevier.

Moro, V., Pernigo, S., Zapparoli, P., & Cordioli, Z. (2011). Phenomenology and neural correlates of implicit and emergent motor awareness in patients with anosognosia for hemiplegia. *Behavioural Brain ...*. Retrieved from <http://www.sciencedirect.com/science/article/pii/S0166432811005250>

Moro, V., Pernigo, S., Zapparoli, P., Cordioli, Z., & Aglioti, S. M. (2011). Phenomenology and neural correlates of implicit and emergent motor awareness in patients with anosognosia for hemiplegia. *Behavioural Brain Research*, 225(1), 259–269.

Naidich, T. P., Kang, E., Fatterpekar, G. M., Delman, B. N., Gultekin, S. H., Wolfe, D., ... Yousry, T. A. (2004). The Insula: Anatomic Study and MR Imaging Display at 1.5 T. *American Journal of Neuroradiology*, 25(2), 222–232.

Nurmi L.M.E., Jehkonen M. (2014) Assessing anosognosias after stroke: a review of the methods used and developed over the past 35 years. *Cortex*, 61: 43-63.

Oldfield, R. C. (1971). The assessment and analysis of handedness: the Edinburgh inventory. *Neuropsychologia*, 9(1), 97–113.

Orfei, M. D., Robinson, R. G., Prigatano, G. P., Starkstein, S., Rüşch, N., Bria, P., ... Spalletta, G. (2007). Anosognosia for hemiplegia after stroke is a multifaceted phenomenon: a systematic review of the literature. *Brain*, 130(12), 3075–3090.

Pernigo, S., Moro, V., Avesani, R., Miatello, C., Urgesi, C., & Aglioti, S. M. (2012). Massive somatic deafferentation and motor deafferentation of the lower part of the body impair its visual recognition: a psychophysical study of patients with spinal cord injury. *The European Journal of Neuroscience*. <http://doi.org/10.1111/j.1460-9568.2012.08266.x>

Phipps, M. C. (2003). Inequalities Between Hypergeometric Tails. *Journal of Applied Mathematics and Decision Sciences*, 7(3), 165–174. [http://doi.org/10.1207/S15327612JAMD0703\\_03](http://doi.org/10.1207/S15327612JAMD0703_03)

Pia, L., Neppi-Modona, M., Ricci, R., & Berti, A. (2004). The anatomy of anosognosia for hemiplegia: a meta-analysis. *Cortex*, 40(2), 367–377.

Prigatano, G. P. (2010). *The study of anosognosia*. Oxford University Press. Retrieved from <https://books.google.it/books?hl=it&lr=&id=d4S-T0NboMQC&oi=fnd&pg=PR9&dq=prigatano+anosognosia&ots=Pf586qlAJK&sig=tXDaFSO8WtFTgyLkczcQROBtF7c>

Ramachandran, V. S., & Rogers-Ramachandran, D. (2000). Phantom limbs and neural plasticity. *Archives of Neurology*, 57(3), 317–320.

Romano, D., Gandola, M., Bottini, G., & Maravita, A. (2014). Arousal responses to noxious stimuli in somatoparaphrenia and anosognosia: clues to body awareness. *Brain*, awu009.

- 1  
2  
3  
4  
5  
6  
7  
8  
9  
10  
11  
12  
13  
14  
15  
16  
17  
18  
19  
20  
21  
22  
23  
24  
25  
26  
27  
28  
29  
30  
31  
32  
33  
34  
35  
36  
37  
38  
39  
40  
41  
42  
43  
44  
45  
46  
47  
48  
49  
50  
51  
52  
53  
54  
55  
56  
57  
58  
59  
60  
61  
62  
63  
64  
65
- Rorden, C., Fridriksson, J., & Karnath, H.-O. (2009). An evaluation of traditional and novel tools for lesion behavior mapping. *NeuroImage*, *44*(4), 1355–1362.  
<http://doi.org/10.1016/j.neuroimage.2008.09.031>
- Rorden, C., & Karnath, H.-O. (2004). Using human brain lesions to infer function: a relic from a past era in the fMRI age? *Nature Reviews Neuroscience*, *5*(10), 812–819.  
<http://doi.org/10.1038/nrn1521>
- Rorden, C., Karnath, H.-O., & Bonilha, L. (2007). Improving lesion-symptom mapping. *Journal of Cognitive Neuroscience*, *19*(7), 1081–1088. <http://doi.org/10.1162/jocn.2007.19.7.1081>
- Scandola, M., Tidoni, E., Avesani, R., Brunelli, G., Aglioti, S. M., & Moro, V. (2014). Rubber hand illusion induced by touching the face ipsilaterally to a deprived hand: evidence for plastic “somatotopic” remapping in tetraplegics. *Frontiers in Human Neuroscience*, *8*. Retrieved from <http://www.ncbi.nlm.nih.gov/pmc/articles/PMC4050649/>
- Schmahmann, J. D., & Pandya, D. N. (2007). The complex history of the fronto-occipital fasciculus. *Journal of the History of the Neurosciences*, *16*(4), 362–377.
- Spalletta, G., Serra, L., Fadda, L., Ripa, A., Bria, P., Caltagirone C. (2007). Unawareness of motor impairment and emotions in right hemispheric stroke: a preliminary investigation. *International Journal of Geriatric Psychiatry*, *22*, 1241-1246.
- Taylor, S. F., Stern, E. R., & Gehring, W. J. (2007). Neural systems for error monitoring recent findings and theoretical perspectives. *The Neuroscientist*, *13*(2), 160–172.
- Thiebaut de Schotten, M., Ffytche, D. H., Bizzi, A., Dell’Acqua, F., Allin, M., Walshe, M., ... Catani, M. (2011). Atlasing location, asymmetry and inter-subject variability of white matter tracts in the human brain with MR diffusion tractography. *NeuroImage*, *54*(1), 49–59.  
<http://doi.org/10.1016/j.neuroimage.2010.07.055>

- 1 Tsakiris, M., Hesse, M. D., Boy, C., Haggard, P., & Fink, G. R. (2007). Neural signatures of body  
2 ownership: a sensory network for bodily self-consciousness. *Cerebral Cortex*, *17*(10), 2235–  
3 2244.  
4  
5  
6
- 7 Tsakiris, M., Longo, M. R., & Haggard, P. (2010). Having a body versus moving your body: neural  
8 signatures of agency and body-ownership. *Neuropsychologia*, *48*(9), 2740–2749.  
9  
10 <http://doi.org/10.1016/j.neuropsychologia.2010.05.021>  
11  
12  
13
- 14 Tzourio-Mazoyer, N., Landeau, B., Papathanassiou, D., Crivello, F., Etard, O., Delcroix, N., ... Joliot,  
15 M. (2002). Automated anatomical labeling of activations in SPM using a macroscopic  
16 anatomical parcellation of the MNI MRI single-subject brain. *NeuroImage*, *15*(1), 273–289.  
17  
18 <http://doi.org/10.1006/nimg.2001.0978>  
19  
20  
21
- 22 Vallar, G., & Ronchi, R. (2009). Somatoparaphrenia: a body delusion. A review of the  
23 neuropsychological literature. *Experimental Brain Research*, *192*(3), 533–551.  
24  
25  
26
- 27 Vocat, R., Staub, F., Stroppini, T., & Vuilleumier, P. (2010). Anosognosia for hemiplegia: a clinical-  
28 anatomical prospective study. *Brain*, *133*(12), 3578–3597.  
29  
30  
31
- 32 Volle, E., Gonen-Yaacovi, G., de Lacy Costello, A., Gilbert, S. J., & Burgess, P. W. (2011). The role of  
33 rostral prefrontal cortex in prospective memory: A voxel-based lesion study.  
34  
35 *Neuropsychologia*, *49*(8), 2185–2198.  
36  
37  
38
- 39 Vuilleumier, P. (2004). Anosognosia: the neurology of beliefs and uncertainties. *Cortex*, *40*(1), 9–  
40 17.  
41  
42  
43
- 44 Wechsler, D. (1997). Wechsler Adult Intelligence Scale® - Third Edition (WAIS®-III). *San Antonio, TX:*  
45 *The Psychological Corporation.*  
46  
47  
48
- 49 Wilson, B., Cockburn, J., & Halligan, P. (1987). Development of a behavioral test of visuospatial  
50 neglect. *Archives of Physical Medicine and Rehabilitation*, *68*(2), 98–102.  
51  
52  
53  
54  
55  
56  
57  
58  
59  
60  
61  
62  
63  
64  
65



Zeller, D., Gross, C., Bartsch, A., Johansen-Berg, H., & Classen, J. (2011). Ventral premotor cortex  
may be required for dynamic changes in the feeling of limb ownership: a lesion study. *The  
Journal of Neuroscience*, 31(13), 4852–4857.

1  
2  
3  
4  
5  
6  
7  
8  
9  
10  
11  
12  
13  
14  
15  
16  
17  
18  
19  
20  
21  
22  
23  
24  
25  
26  
27  
28  
29  
30  
31  
32  
33  
34  
35  
36  
37  
38  
39  
40  
41  
42  
43  
44  
45  
46  
47  
48  
49  
50  
51  
52  
53  
54  
55  
56  
57  
58  
59  
60  
61  
62  
63  
64  
65

## Captions to Tables and Figures

**Table 1.** Demographic variables and scores on the neuropsychological tasks. For each experimental group, mean scores ( $\pm$  standard deviation) of demographic variables and medians ( $\pm$  interquartile range) of neuropsychological measures are reported.

**Table 2.** Significant voxels resulting from the comparison of lesions of all AHP patients (first column), patients who recovered awareness within 40 days from onset (central column), and patients who did not recover awareness within 40 days of onset (column on the right), compared to the HP controls. The amount of voxels for each region indicated in the brain atlas of gray (AAL) and white matter (JHU) are reported.

**Table 3.** Number of significant voxels (atlas of gray matter – AAL - and white matter –JHU - and NatBrainLab’s atlas) resulting from the comparison of the lesions of AHP+DSO (first column) and AHP+DSO plus DSO patients (second column) compared to HP (indirect comparisons:  $p < 0.05$ , 5000 permutation). The results of the direct comparison between AHP+DSO versus AHP and vice versa are shown in the two columns on the right of the table ( $p < 0.01$ , FDR correction). In each column the numbers indicate the regions significantly more lesioned in the first with respect to the second group.

**Table 3.** Number of significant voxels (atlas of gray matter – AAL - and white matter –JHU - and NatBrainLab’s atlas) resulting from the comparison of the lesions of AHP+DSO (first column) and AHP+DSO plus DSO patients (second column) compared to HP (indirect comparisons:  $p < 0.05$ , 5000 permutation). The results of the direct comparison between AHP+DSO versus AHP and vice versa are shown in the two columns on the right of the table ( $p < 0.01$ , FDR correction). In each column the numbers indicate the regions significantly more lesioned in the first with respect to the second group.

**Table 4.** The results of previous studies of lesional analysis in AHP are reported. In this review, patients suffering from crossed anosognosia are excluded. In addition, the single case study, where the AHP patient's lesion was not compared with controls were not reported. \*\* = these

patients' lesions were not compared with controls. In *Italic* previous studies involving some of the patients of this study sample.

**Figure 1.** Lesions associated with 'pure' AHP patients as compared to HP patients. A = The areas significantly associated with AHP in the AHP vs. HP comparison. The numbers above the brain slices indicates the corresponding MNI axial coordinates. L = left; R = Right; B = Heat map of the voxels with power enough to detect a significant results. Different colors represent area under ROC curve (AUROC) scores, ranging between 0.5 (minimum power) to 1 (maximum discrimination power); C = Sagittal cut in which three cortical clusters in the subcentral gyrus and around the insula are indicated by dark blue circles. These touch the Rolandic operculum (ventral premotor cortex) (1), the Insula (2), the Heschl and superior temporal gyri (3); D = Side view of the clusters of lesions overlapped on a 3D reproduction of the JHU atlas.; E = DTI tractography reconstruction of the anterior segment of the SLF (1) and the arcuate fasciculus (3) (figure from Martino et al.,2013). The same tracts are depicted in light blue and in green in the JHU atlas (panel D) and Natbrainlab atlas (panel F), respectively; F = Rear, side and front views of the clusters of lesions overlapped on a 3D reproduction of the Natbrainlab atlas.

**Figure 2.** The lesional comparison with the damage in HP patients shows the lesions significantly associated to somatoparaphrenia in AHP+DSO and DSO patients (in dark blue). In the figure these are shown together with lesions involved in AHP (in red). Below is represented a heat map of the voxels with enough power to detect a significant result; different colors represent area under ROC curve (AUROC) scores, ranging between 0.5 (minimum power, in green) to 1 (maximum discrimination power, in red). Numbers above the brain slices indicate the MNI axial coordinates. L = left. R = right.

**Figure 3.** The comparison between lesions significantly associated with AHP+DSO vs. isolated AHP and vice versa. A. Regions more involved in AHP+DSO than in AHP are shown. B. Lesions in amygdala are marginally more frequent in AHP than in AHP+DSO. Numbers above the brain slices indicate the MNI axial coordinates. L = left. R = right. Below each comparison is represented a heat map of the voxels with enough power to detect a significant result, different colors represent area

under ROC curve (AUROC) scores, ranging between 0.5 (minimum power) to 1 (maximum discrimination power).

1  
2  
3  
4  
5  
6  
7  
8  
9  
10  
11  
12  
13  
14  
15  
16  
17  
18  
19  
20  
21  
22  
23  
24  
25  
26  
27  
28  
29  
30  
31  
32  
33  
34  
35  
36  
37  
38  
39  
40  
41  
42  
43  
44  
45  
46  
47  
48  
49  
50  
51  
52  
53  
54  
55  
56  
57  
58  
59  
60  
61  
62  
63  
64  
65

Figure1  
[Click here to download high resolution image](#)

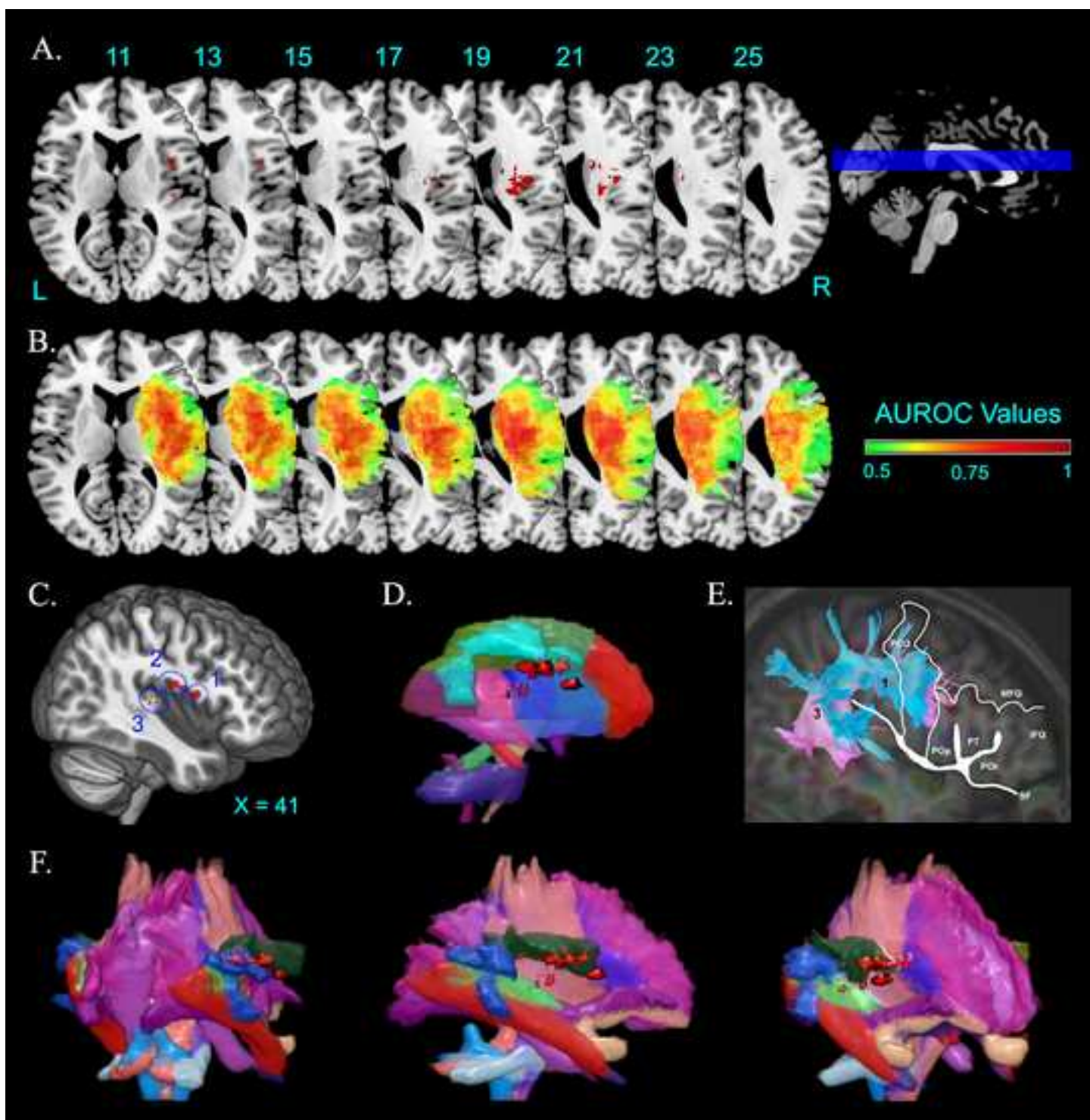


Figure2  
[Click here to download high resolution image](#)

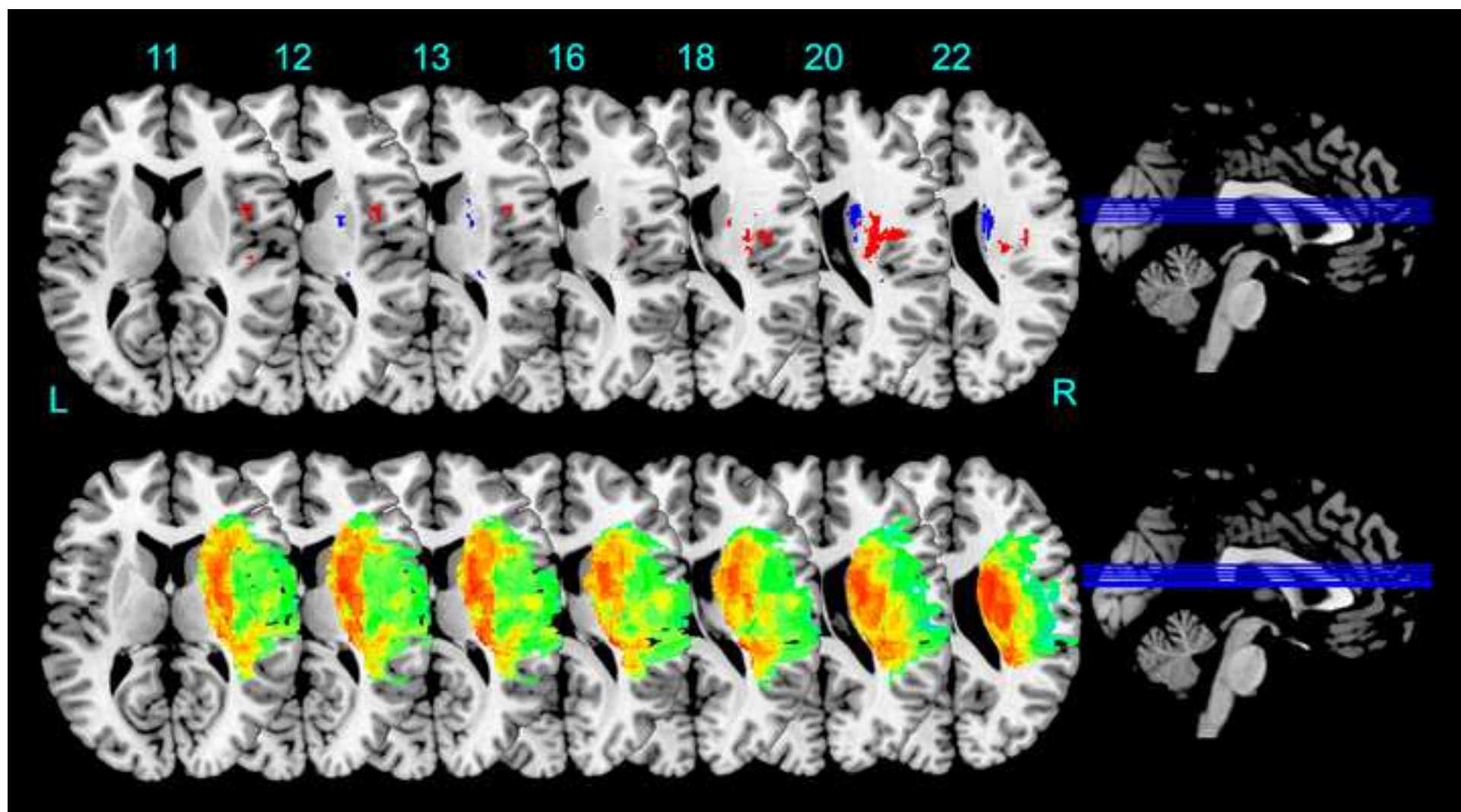




Figure3  
[Click here to download high resolution image](#)

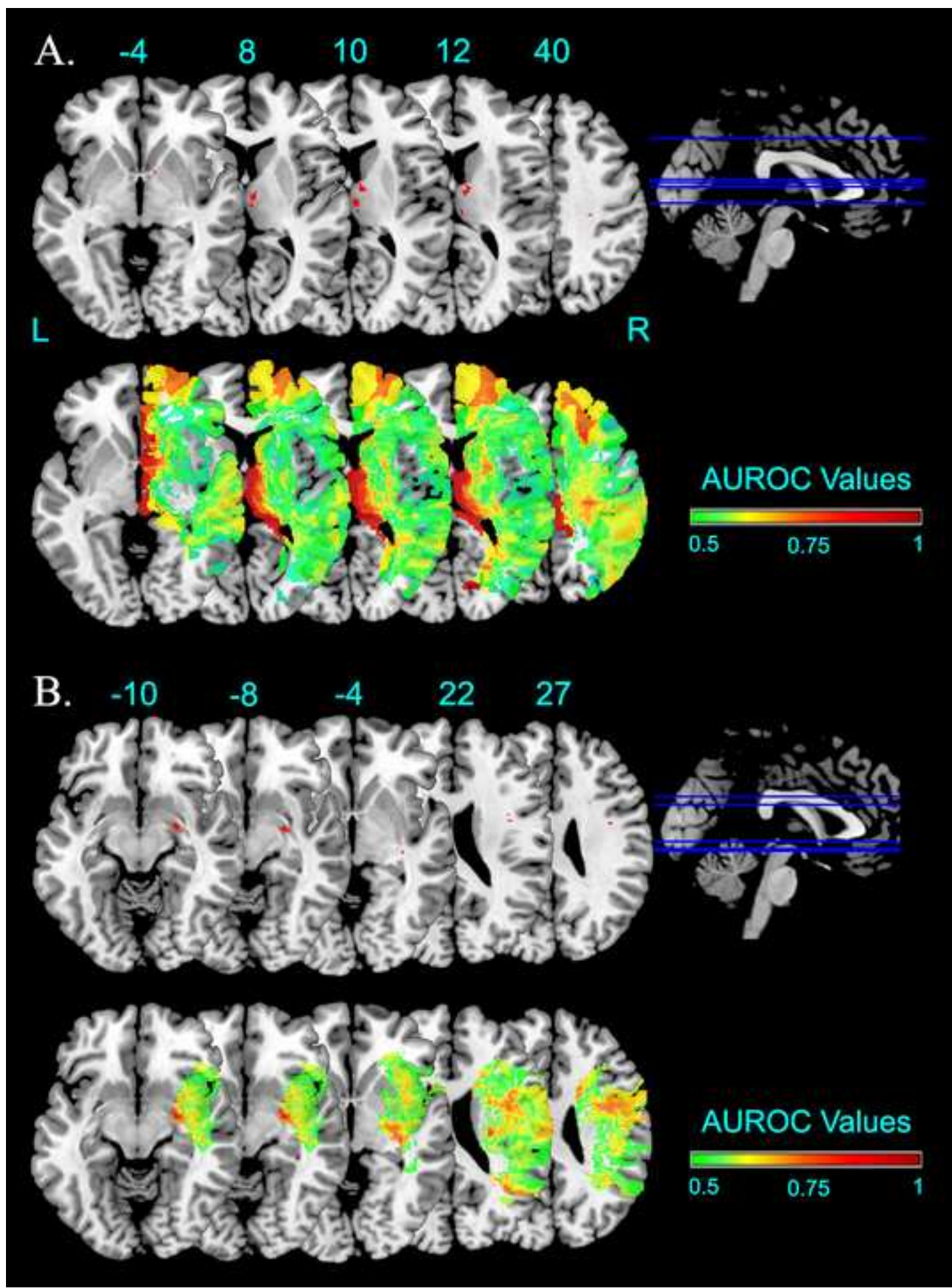


Table1

	<b>AHP</b> (N = 25)	<b>AHP+DSO</b> (N = 13)	<b>HP Controls</b> (N = 28)	<b>AHP VS HP</b>	<b>AHP+DSO VS HP</b>	<b>AHP VS AHP+DSO</b>
<b>Socio-demographic</b>						
Gender	F=12, M=13	F=3, M=10	F=6, M=22	$\chi^2(1, N = 53) = 4.16,$ $P = 0.04$	$\chi^2(1, N = 41) = 0.01,$ $P = 0.91$	$\chi^2(1, N = 38) = 2.22,$ $P = 0.14$
Age	68 ± 11	67 ± 13	64 ± 13	$t_{(51)} = 1.32, P = 0.19$	$t_{(39)} = 0.67, P = 0.51$	$t_{(36)} = 0.35, P = 0.72$
Handedness	R	R	R			
<b>Lesion Onset Interval</b>						
Test onset (days)	34 ± 26	49 ± 42	48 ± 53	$t_{(51)} = 1.52, P = 0.13$	$t_{(39)} = 0.1, P = 0.92$	$t_{(36)} = 1.8, P = 0.08$
Chronic Ahp/Dso (>40 days)	14/20 (70%)	11/12 (92%)				$\chi^2(1, N = 57) = 0.25,$ $P = 0.62$
<b>Anosognosia</b>						
Bisiach (0-3)	2 ± 1	3 ± 0	0			
Berti LUL	1.33 ± 0.94	1 ± 0.75	0			
Berti LLL	1.88 ± 1	2 ± 0.25	0			
Composite score (%)	72% ± 17.6	89% ± 33.3	0%	$U_{(51)} = 101, z = 4.22,$ $P < 0.0001$	$U_{(39)} = 21, z = 3.19,$ $P = 0.003$	$U_{(36)} = 109, z = 1.28,$ $P = 0.4$
<b>Neglect</b>						
Line Canc. (36, omissions)	17 ± 11	23 ± 9	12 ± 8			
Star Canc. (56, omissions)	31 ± 20	38 ± 11	13 ± 18			
Copy	1.1 ± 1.4	1.4 ± 1.6	2.4 ± 1.3			
Composite score (%)	65% ± 47.6	68% ± 25.5	31% ± 34.8	$U_{(50)} = 139, z = 3.44,$ $P = 0.0011$	$U_{(38)} = 56, z = 3.11,$ $P = 0.0038$	$U_{(34)} = 141, z = 1.4,$ $P = 1$
<b>Personal Neglect</b>						
Comb & Razor	-0.13 ± 0.5	-0.51 ± 0.44	-0.04 ± 0.21	$U_{(49)} = 225, z = 1.51,$ $P = 0.26$	$U_{(34)} = 46, z = 2.26,$ $P = 0.048$	$U_{(29)} = 69, z = 0.53,$ $P = 1$
<b>Executive functions</b>						
Similarities	3 ± 5	6 ± 5	16 ± 6.9	$U_{(29)} = 21.5, z = 3.72,$ $P < 0.001$	$U_{(21)} = 13, z = 2.65,$ $P = 0.016$	$U_{(20)} = 48.5, z = 0.77,$ $P = 1$



Table2

	AHP vs HP alls (25 VS 28)		AHP <sub>acute</sub> vs HP (6 VS 28)		AHP <sub>chronic</sub> vs HP (14 VS 28)		
	N > 0	(x, y, z)	N > 0	(x, y, z)	N > 0	(x, y, z)	
AAL	Frontal Inf Opercularis	3	(39,9,11)				
	Rolandic Operculum	164	(38,-6,20)		44	(39,-10,21)	
	Insula	237	(29,-16,19)	127	(34,26,6)	27	(29,-19,19)
	Caudate	24	(22,3,21)	3	(22,3,21)		
	Putamen			109	(28,9,9)		
	Thalamus					4	(20,-19,13)
	Heschl	15	(41,-20,6)			17	(43,-20,7)
	Temporal Sup.	6	(42,-24,6)			21	(42,-31,15)
JHU	Body of corpus callosum				2	(17,8,29)	
	Anterior limb of int capsule	10	(20,-2,18)				
	Post. limb of internal capsule				7	(20,-19,13)	
	Ant. corona radiate			8	(24,15,11)		
	Sup. corona radiate	268	(29,-16,19)	3	(22,3,21)	103	(29,-14,19)
	Post. corona radiate					17	(26,-34,21)
	External capsule	25	(30,-10,18)	50	(28,9,9)	5	(32,-41,16)
	Sup. longitudinal fasciculus	37	(31,0,19)			17	(40,-30,-6)
	Sup. fronto-occipital fasciculus	34	(21,0,20)	2	(21,0,20)		
Nat Brain Lab	Internal Capsule	66	(30,-12,19)	25	(25,13,11)	12	(30,-12,19)
	Cortico Spinal Tract	235	(29,-16,19)			108	(29,-14,19)
	Cortico_Ponto_Cerebellum	7	(27,-11,20)			23	(20,-19,13)
	Arcuate_Anterior_Segment	302	(38,-8,20)			68	(33,-31,21)
	Long_Segment	3	(31,-15,22)			1	(33,-31,22)
	Arcuate_Posterior_Segment	2	(35,-45,24)			1	(33,-32,21)
	Corpus_Callosum	2	(20,3,24)			30	(16,-1,28)
	Inf._Occipito_Frontal_Fasciculus			49	(31,14,-5)		

Table3

	AHP+DSO VS HP (13 VS 28) N > 0 (x, y, z)	AHP+DSO, DSO VS HP (17 VS 28) N > 0 (x, y, z)	AHP+DSO VS AHP (13 VS 25) N > 0 (x, y, z)	AHP VS AHP+DSO (25 VS 13) N > 0 (x, y, z)
AAL	<i>Frontal Inf Opercularis</i>			
	<i>Rolandic Operculum</i>			
	<i>Insula</i>			
	<i>Amygdala</i>			16 (25, -6, -10)
	<i>Caudate</i>	1 (20, 11, 14)	215 (20, 2, 22)	6 (9, 1, 15)
	<i>Pallidum</i>			6 (13, 5, 0)
	<i>Thalamus</i>			213 (4, -9, 8)
	<i>Putamen</i>	15 (21, 0, 12)	16 (23, -2, 12)	
	<i>Heschl</i>			
	<i>Temporal Superior</i>			
JHU	<i>Anterior limb of int capsule</i>	13 (20, 2, 12)	27 (21, 1, 13)	9 (13, 5, 1)
	<i>Retrolenticular part of int capsule</i>	3 (27, -30, 13)	15 (27, -30, 13)	3 (34, -22, -3)
	<i>Superior corona radiate</i>		25 (22, 2, 21)	
	<i>Posterior corona radiate</i>			1 (21, -29, 27)
	<i>External capsule</i>			1 (31, -19, -3)
	<i>Sup longitudinal fasciculus</i>			3 (27, -23, 40)
	<i>Post. thalamic radiation</i>			3 (28, -45, 17)
	<i>Sup fronto occipital fasciculus</i>	-	168 (21, 0, 19)	
NatBrainLab	<i>Internal Capsule</i>	6 (26, -29, 13)	46 (26, -29, 13)	2 (28, -45, 16)
	<i>Cortico Spinal Tract</i>	35 (20, 2, 12)	54 (21, -3, 12)	11 (13, 5, 1)
	<i>Cortico Ponto Cerebellum</i>	2 (27, -30, 13)	4 (27, -30, 13)	
	<i>Anterior Commissure</i>			2 (9, 7, -3)
	<i>Arcuate Anterior Segment</i>	1 (33, -32, 20)	2 (33, -32, 20)	
	<i>Long Segment</i>			
	<i>Arcuate Posterior Segment</i>	3 (33, -32, 21)	1 (33, -32, 21)	
	<i>Corpus Callosum</i>		54 (14, 4, 20)	11 (28, -45, 17)
	<i>Inferior Longitudinal Fasciculus</i>			17 (26, -7, -9)
	<i>Inferior Occipito Frontal Fasciculus</i>			6 (29, -7, -9)
	<i>Optic radiations</i>			3 (31, -19, -3)
	<i>Uncinate</i>			4 (26, -5, -9)
	<i>Fornix</i>			155 (7, 1, 2)

Table4

	n. patient	n. AHP	time int.	lesion sites associated with AHP
Besharati et al., 2016	30	15	<30 d	Inf Front Gyrus; Mid Front Gyrus; Sup Temporal Gyrus
Piedimonte et al., 2016	6	1	12 m	Mid. Sup Temporal gyrus; Post Insula Periventricular temporal WM
		1	2 m	Hippocampus;Thalamus; Putamen; Ant. Post. Insula Periventricular temporal WM
Kortte et al., 2015	35	8	48h	Pars Orbitalis; Broca; Pars Trinagularis
Moro et al., 2015 **	4	4	>72 d	Frontal Inf.; Rolandic Operc.; Insula; Hippocampus; Parahip Cortex; Amigdala; Sup. Mid. Inf Temporal; Basal Ganglia; Int. Capsule; Corona Radiate; Sagittal Stratum; Ext Capsule; Sup. Longitudinal Fasc.; Sup Fronto-occipital Fasc. Uncinate Fasciculus
Besharati et al., 2014	15	8	<7 d	Ant Post Insula Ribbon; Post Basal Ganglia; Dorsal Pericentral Areas
Saj et al., 2014	10	5	<15 d	Temporo-Parietal J.; Insula
Gandola et al., 2014	11	5	<12 d	Basal ganglia; Thalamus; Ventral Premotor; Insula
Vocat et al., 2013	9	4	not specified	Parieto-Temporal J Subcortical WM
Pia et al., 2013	6	1	71 d	Ventral Premotor Cortex
Garbarini et al., 2012**	10	1	62 d	Temporo-Parietal Cortex; Thalamus: Post Insula; Periventricular temporo-parietal WM Inf. Mid. Sup Temporal G.; Angular G; Supramarginal G; Lateral Premotor;
		1	32 d	Ant. Post Insula; Precentral G; Post Central G.; Thalamus, Putamen; Int. Ext Capsule; F-T-P-O WM
		1	28 d	Mid. Sup Occipital G.; Mid. Sup. Temporal G.; Angular G; Sup Parietal Lobe; Post Insula; Internal Capsule
<i>Moro et al., 2011</i>	24	12	22-177 d	Rolandic Operculum; Insula; Sup Temporal gyrus; Fusiform G.; Cingulum; Hippocampus; Caudate; Thalamus sub-cortical WM
Vocat et al., 2010	58	32%	3 d	Insula; Ant Int Caps.; Ant Periventricular WM
		18%	7 d	Insula; Ant Int Caps.; Premotor C; Dorsal Cingulate; P-T Cortex; Hyppocampus; Amigdala Ant Periventricular WM
<i>Fotopoulou et al., 2010</i>	14	7	<40 d	Rolandic Operculum; Insula; Temporal Sup. Pole; Amigdala; Basal ganglia

Baier & Karnath 2008	22	11 (+DSO)	<10 d	Post Insula
Karnath et al., 2005	27	14	<14 d	Post Insula; Temporo-Parietal C.; Basal Ganglia; Subcortical WM
Berti et al., 2005	30	17	not specified	Dorsal Premotor C.; Inf. Mid. Front. G.; Somatosensory C.; Primary Motor C., Insula.

Table 4. The results of previous studies of lesional analysis in AHP are reported. In this review, patients suffering from crossed anosognosia are excluded. In addition, the single case study, where the AHP patient's lesion was not compared with controls were not reported. \*\* = these patients' lesions were not compared with controls In *italic* previous studies involving some of the patients of this study sample.

**Suppl. material for online publication only**

[Click here to download Suppl. material for online publication only: Revised\\_\\_Supplementary\\_Materials\\_Moro & Pernigo et al., 2018](#)



Università degli Studi di Verona  
Dipartimento di Filosofia, Pedagogia e Psicologia

Verona, December, 30th, 2015

Formatted: English (United States)

Prof. M. Catani,  
Clinical Neuroanatomy Editor  
Centre for Neuroimaging Sciences,  
Department of Psychological Medicine, Institute of Psychiatry  
PO89, De Crespigny Park, London SE5 8AF, UK

Dear Prof. Catani,

Please find in attachment the manuscript “Motor Versus Body Awareness: Voxel-based Lesion Analysis in Anosognosia for Hemiplegia and Somatoparaphrenia Following Right Hemisphere Stroke” by Valentina Moro & Simone Pernigo, Manos Tsakiris, Renato Avesani, Nicola M. J. Edelstyn, Paul M. Jenkinson & Aikaterini Fotopoulou, which we would like to submit for consideration for publication in “Cortex - Clinical Neuroanatomy”.

The article includes the largest ever clinical sample of patients (N = 70) used to address the ongoing debate regarding the neural substrate of motor and body awareness. Moreover, to our knowledge this is the first study comparing the pattern of brain lesions selectively associated with anosognosia for hemiplegia (AHP) as compared to disturbances in the sense of body ownership (DSO) and other concomitant symptoms, such as hemispatial neglect, with the aim of revealing whether these are manifestations of independent abnormalities, or a single, primary neurocognitive deficit.

Specifically, in a multi-centre study we recruited patients with a clear diagnosis of severe AHP and examined identifiable lesions in grey and white matter using state-of-the-art voxel-based lesion comparison methods, while also taking into account the duration of AHP and concomitant neglect symptoms. In addition, we compared the lesions of AHP patients not only to a control group showing hemiplegia without anosognosia, but also to another group of patients whose anosognosia was accompanied by DSO, as well as a small group of rare patients with selective DSO. Our results indicated that acute AHP is associated with a wide distribution of lesioned areas, including the Rolandic operculum (ventral premotor cortex), the insula and the Heschl and superior temporal gyri. In addition, damage was observed subcortically, mainly in the basal ganglia and white matter lesions affecting mostly the superior corona radiata and the ventral part of the superior longitudinal



# Università degli Studi di Verona

---

## Dipartimento di Filosofia, Pedagogia e Psicologia

fasciculus. Persistence of the AHP symptoms, beyond 40 days post-stroke, were linked with wider damage involving fronto-temporal cortex and long white matter tracts. A shift in the latero-medial direction (and mainly involving the basal ganglia and surrounding white matter lesions) emerged when DSO was taken into account in various analyses. Thus, our results suggest that while bodily awareness is processed by areas widely distributed across the brain, intact subcortical structures and white matter tracts may be necessary to support basic feelings of owning and controlling contralateral body parts. An accurate and 'up-to-date' awareness of our motor abilities, however, may rely also on intact processing in cortical areas, which presumably allow higher order inferences about the current state of the body.

We believe that our findings would appeal to the readership of *Cortex – Clinical Anatomy* for their interest in knowledge concerning the specificity of cerebral networks involved in different expressions of body awareness.

We confirm that this manuscript has not been published elsewhere and is not under consideration by another journal.

We look forward to hearing from you at your earliest convenience.

Sincerely,

Aikaterini Fotopoulou & Valentina Moro

Some potential reviewers expert in this topic are:

Patrick Vuilleumier

Department of Neurology Institution University Hospital & Department of Neurosciences, 1 rue Michel-Servet, 1211 GENEVA 4, Switzerland,  
Email: [Patrik.Vuilleumier@unige.ch](mailto:Patrik.Vuilleumier@unige.ch)

for his experience in anosognosia for hemiplegia and in lesional studies

Mervi Jehkonen

Department of Psychology, University of Tampere, 33014 Tampere, Finland.  
E-mail: [mervi.jehkonen@uta.fi](mailto:mervi.jehkonen@uta.fi)

For her wide experience in neuropsychology of Anosognosia for Hemiplegia

**Roberta Ronchi**, PhD, Laboratory of Cognitive Neuroscience, Ecole Polytechnique Fédérale de Lausanne  
Office AI 2101 (Bâtiment AI), Station 19, CH-1015 Lausanne, Phone: +41 216931771  
Email: [roberta.ronchi@epfl.ch](mailto:roberta.ronchi@epfl.ch)



# Università degli Studi di Verona

---

## Dipartimento di Filosofia, Pedagogia e Psicologia

For her wide knowledge on the scientific literature regarding Anosognosia for hemiplegia

Daniele Romano, PhD  
Dott. Daniele Luigi Romano Studente di Dottorato Università degli Studi di Milano - Bicocca . Edificio U6,  
Stanza 3170c Piazza dell'Ateneo Nuovo 1, 20126 Milano, Italia  
Email [daniele.romano@unimib.it](mailto:daniele.romano@unimib.it)

For his recent studies on patients suffering from Anosognosia for Hemiplegia and Disownership of  
Upper limbs.