



## Short Report

## Ipilimumab and Bevacizumab in Glioblastoma

T. Carter<sup>\*</sup>, H. Shaw<sup>†</sup>, D. Cohn-Brown<sup>‡</sup>, K. Chester<sup>\*</sup>, P. Mulholland<sup>†§</sup><sup>\*</sup> UCL Cancer Institute, University College London, London, UK<sup>†</sup> University College London Hospital, London, UK<sup>‡</sup> Harley Street at University College Hospital, London, UK<sup>§</sup> Mount Vernon Cancer Centre, Northwood, Middlesex, UK

Received 29 September 2015; received in revised form 7 March 2016; accepted 22 March 2016

## Abstract

The median survival in glioblastoma is just over a year, with no standard second-line therapy. Ipilimumab is an immune checkpoint inhibitor that activates the anti-tumour immune response by cytotoxic T-lymphocyte antigen-4 blockade. There is significant evidence supporting its role in the treatment of malignant melanoma, including in patients with brain metastases. The addition of the anti-angiogenesis agent, bevacizumab, seems to offer additional benefit and limit the immune-related side-effects of ipilimumab in melanoma. To date there have been no clinical trials investigating this combination in glioblastoma. In this single practice case series, 20 patients with glioblastoma were consented for and treated with ipilimumab and bevacizumab in combination. Safety, tolerability and the response to treatment were reviewed for all patients. Three patients were treated after palliative first-line radiotherapy, one patient after first-line chemoradiation and 16 patients were treated with recurrent disease. Sixty-five per cent of patients completed four cycles of 3 weekly ipilimumab therapy, administered with 2 weekly bevacizumab. Radiographic responses for patients with recurrent disease were evaluated by Response Assessment in Neuro-oncology (RANO) criteria; 31% of patients showed a partial response, 31% had stable disease and 38% had disease progression. The treatment combination was well tolerated, with treatment terminated before completion due to adverse events in two patients. Autoimmune toxicity was manageable with systemic corticosteroid therapy. Ipilimumab and bevacizumab in combination show promising activity with a predictable and manageable toxicity profile, warranting further clinical studies.

© 2016 The Royal College of Radiologists. Published by Elsevier Ltd. This is an open access article under the CC BY-NC-ND license (<http://creativecommons.org/licenses/by-nc-nd/4.0/>).

**Key words:** Bevacizumab; glioblastoma; high grade glioma; immunotherapy; ipilimumab

## Introduction

Glioblastoma is the most commonly occurring primary brain tumour. It remains associated with a very poor prognosis and a median survival of just over a year [1]. First-line treatment is surgical resection followed by radiotherapy and temozolomide chemotherapy [2]. There is no standard second-line therapy and most patients either receive a lomustine-containing chemotherapy regimen or enter clinical trials.

Ipilimumab is a fully humanised IgG1 monoclonal antibody that potentiates the anti-tumour T-cell response by blocking the cytotoxic T-lymphocyte antigen-4, a critical

negative regulator (checkpoint) of T-cells. To date, the majority of clinical experience and efficacy data for ipilimumab are in the setting of metastatic malignant melanoma [3], for which it has become an established treatment leading to durable long-term survival in a subset of patients with advanced disease [4]. Ipilimumab has also shown responses in patients with malignant melanoma and brain metastases [5], highlighting efficacy within the central nervous system.

Ipilimumab has been administered safely alongside bevacizumab in melanoma, with evidence of synergistic efficacy and manageable toxicity when compared with ipilimumab alone [6]. Bevacizumab is a humanised monoclonal antibody that targets vascular endothelial growth factor. Studies have shown bevacizumab to be well tolerated in both newly diagnosed and recurrent glioblastoma, with evidence of anti-tumour and anti-oedema activity [7]. Although the addition of bevacizumab to standard therapy in newly diagnosed glioblastoma shows no improvements

Author for correspondence: P. Mulholland, Cancer Division, University College London Hospital, First Floor Central, 250 Euston Road, Fitzrovia, London NW1 2PG, UK.

E-mail address: [paul.mulholland@nhs.net](mailto:paul.mulholland@nhs.net) (P. Mulholland).

in overall survival [8], there is some evidence that it can preserve quality of life and performance status [9]. To date, there have been no clinical trials investigating the combination of ipilimumab and bevacizumab in glioblastoma. We describe here the safety and tolerability of a treatment regimen containing ipilimumab and bevacizumab.

## Patients and Methods

Twenty patients with glioblastoma who had previously received treatment with first-line therapy as tolerated were consented for treatment with an off-label regimen combining ipilimumab and bevacizumab; granulocyte-colony stimulating factor was included to boost peripheral white cell counts, reduce chemotherapy-induced myelosuppression and potentiate anti-tumour immunity [10]. Treatment was given either in place of or alongside oral palliative chemotherapy. Nineteen patients had confirmed World Health Organization grade IV disease and one patient had a recurrent astrocytoma (grade II), radiologically consistent with grade IV disease. Sixteen patients were treated after disease progression; two of these patients had completed first-line chemoradiotherapy within 3 months. Three of the remaining patients were treated after first-line short-course radiotherapy, and one was treated after standard chemoradiotherapy. All patients who began treatment with the regimen were included in the analysis. Patient demographics and biomarkers including methylguanine

methyltransferase promoter methylation and isocitrate dehydrogenase-1 mutation status are shown in Table 1.

Ipilimumab was dosed at 3 mg/kg body weight every 3 weeks for four cycles followed by maintenance therapy every 12 weeks. Each ipilimumab dose was followed by granulocyte-colony stimulating factor within 24 h. Bevacizumab was dosed at 10 mg/kg, administered every 2 weeks. Patients were assessed before each treatment with a full clinical review and standard blood tests, including thyroid function. Interim 6 weekly magnetic resonance imaging scans were carried out to determine disease response. Adverse event data were recorded and analysed to determine safety and tolerability. Radiographic responses were assessed using the Response Assessment in Neuro-oncology (RANO) criteria [11].

## Results

Between January 2014 and April 2015, 20 patients began treatment with four 3 weekly cycles of ipilimumab in addition to 2 weekly bevacizumab. Of these patients, 13 patients (65%) completed all four cycles. In the seven patients who did not complete four cycles, the reasons were dose-limiting toxicity (two patients) and clinical deterioration (five patients). Of the 13 patients who completed all four standard cycles, nine (69%) proceeded to maintenance therapy. All patients underwent interim magnetic resonance imaging 6 and 12 weeks after the start of treatment to determine the response to treatment, with responses

**Table 1**  
Patient demographics, first-line treatment and biomarkers

Patient	Histological diagnosis	MGMT methylation status	IDH-1 mutation status	Gender	Age at treatment	First-line treatment received
First-line treatment						
1	Glioblastoma	10%	Negative	Female	54	Short-course radiotherapy
2	Glioblastoma	Methylated	Negative	Female	46	Short-course radiotherapy
3	Glioblastoma	Not available	Negative	Male	60	Short-course radiotherapy
4	Glioneuronal Tumour	Unmethylated	Negative	Male	23	Radiotherapy with TMZ
Recurrent disease						
5	Astrocytoma	10%	Negative	Female	31	Radiotherapy alone 7 cycles TMZ
6	Gliosarcoma	Unmethylated	Negative	Female	38	Chemoradiotherapy 5 cycles TMZ
7	Glioblastoma	Unmethylated	Negative	Female	48	Chemoradiotherapy 2 cycles TMZ
8	Glioblastoma	Methylated	Negative	Male	55	Chemoradiotherapy 6 cycles TMZ
9	Glioblastoma	10%	Negative	Male	45	Chemoradiotherapy 12 cycles TMZ
10	Glioblastoma	Unmethylated	Negative	Male	23	Chemoradiotherapy 6 cycles TMZ
11	Glioblastoma	Unmethylated	Negative	Male	35	Chemoradiotherapy 8 cycles TMZ
12	Glioblastoma	Unmethylated	Negative	Female	28	No radiotherapy
13	Glioblastoma	Unmethylated	Negative	Female	52	Chemoradiotherapy 4 cycles TMZ
14	Glioblastoma	5%	Negative	Male	58	Chemoradiotherapy 6 cycles TMZ
15	Glioblastoma	Unmethylated	Negative	Male	40	Chemoradiotherapy 0 cycles TMZ
16	Glioblastoma	10%	Negative	Male	69	Chemoradiotherapy 9 cycles TMZ
17	Glioblastoma	Not available	Not available	Male	66	Chemoradiotherapy 6 cycles TMZ
18	Glioblastoma	10%	Negative	Male	69	Chemoradiotherapy 7 cycles TMZ
19	Glioblastoma	Methylated	Negative	Female	46	Chemoradiotherapy 6 cycles TMZ
20	Glioblastoma	Not available	Not available	Male	55	Chemoradiotherapy 6 cycles TMZ

MGMT, methylguanine methyltransferase; IDH-1, isocitrate dehydrogenase-1; TMZ, temozolomide.

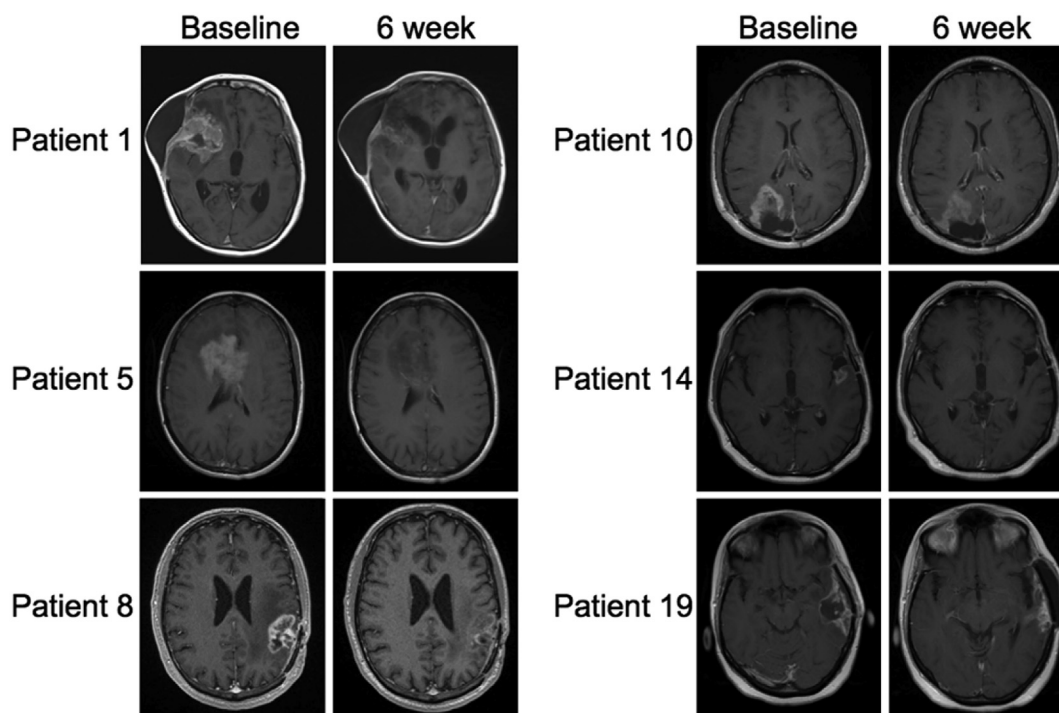
recorded based on RANO criteria for those patients with recurrent disease. Five patients (31%) had a partial response to treatment, two of whom had over a 90% reduction (Figure 1). Five patients (31%) had stable disease; the remaining six patients (38%) had disease progression. One patient treated after palliative short-course radiotherapy also had a greater than 90% response to treatment (Figure 1, Patient 1). Performance status was maintained or improved during treatment for 12 of the 14 patients (85%) who either responded or had stable disease. Table 2 shows the number of cycles of treatment received by patients, together with the reported radiographic responses. Steroid doses were also collected (data not shown) to assist with reporting treatment responses to RANO criteria. For those patients with recurrent disease, 11 patients (69%) remained alive, four of whom (25%) were progression-free 6 months after treatment start date. Survival data continue to be collected for all patients.

Adverse events are shown in Table 3. The most commonly seen adverse events were fatigue (40%, eight patients) and diarrhoea (30%, six patients). One patient suffered an intracerebral bleed and two further patients were diagnosed with pulmonary emboli, events attributable to disease. There were no grade 4 adverse events observed. Treatment was terminated early due to grade 2 rash (one patient) and grade 2 arthritis (one patient). Three patients experienced grade 3 abscess formation (dental, uterine, diverticular), all of whom were managed surgically. Although six patients experienced diarrhoea, none stopped treatment early and symptoms were manageable with corticosteroids. There were no diagnoses of endocrinopathies.

## Discussion

Our observations on 20 patients showed that a combination of ipilimumab and bevacizumab is well tolerated in patients with glioblastoma. To the best of our knowledge this is the largest glioblastoma patient series reported to date with this treatment regimen. The manageable toxicities reported are supported by the results of a phase I trial of 46 patients with metastatic malignant melanoma [6]. Our results are also supported by two abstracts published by other groups reporting use of ipilimumab in glioblastoma. In these small studies, all patients (5/5) experienced toxicity when treated with ipilimumab alone [12], whereas the combination of ipilimumab and bevacizumab was less toxic, with 1/10 patients experiencing significant immune toxicity events [13].

The rationale behind the co-administration of bevacizumab with ipilimumab in our patients was to preserve quality of life, limit corticosteroid requirements and modulate toxicity. However, there may also be additional benefit from bevacizumab due to its positive effects in modulation of the immune response to tumours. Vascular endothelial growth factor downregulates the immune system by inhibiting the maturation of dendritic cells and T-cells, and controlling the endothelial trafficking of T-cells; processes that are reversed by bevacizumab [14]. There is also an increasing body of pre-clinical work supporting a role for immune checkpoint inhibitors in the treatment of glioblastoma [15,16]. A number of *in vivo* studies have shown the efficacy of ipilimumab alone [17] and in combination with other treatments [18], including other checkpoint inhibitors [19].



**Fig 1.** Corresponding images from baseline and 6 week scan for those patients with partial radiographic responses based on Response Assessment in Neuro-oncology (RANO) criteria.

**Table 2**

Number of treatment cycles received, number of months after diagnosis to the start of treatment and radiographic responses seen at 6 and 12 weeks

Patient	Months from diagnosis to treatment with ipilimumab and bevacizumab	Number of standard cycles	Commenced maintenance therapy?	Concurrent therapy?	Radiographic response at 6 weeks	Radiographic response at 12 weeks
First-line treatment						
1	2	4	Yes	Temozolomide	Partial response*	Partial response*
2	2	2	No	None	Stable disease*	Stable disease*
3	3	4	No	Temozolomide	Stable disease*	Stable disease*
4	3	4	Yes	Temozolomide	Stable disease*	Stable disease*
Recurrent disease						
5	1 <sup>†</sup>	2	No	Lomustine	Partial response	Stable disease
6	12	2	No	Lomustine	Progression	Not done
7	4	4	Yes	Temozolomide	Stable disease	Stable disease
8	32	4	Yes	Lomustine	Partial response	Partial response
9	15	4	No	None	Progression	Progression
10	14	4	Yes	None	Partial response	Stable disease
11	9	4	Yes	None	Stable disease	Progression
12	3	4	Yes	None	Stable disease	Stable disease
13	8	4	Yes	Temozolomide	Stable disease	Stable disease
14	17	4	Yes	None	Partial response	Stable disease
15	4	4	No	Temozolomide	Progression	Progression
16	18	4	Yes	Lomustine	Stable disease	Stable disease
17	19	2	No	Lomustine	Progression	Progression
18	10	2	No	Lomustine	Progression	Not done
19	34	2	No	Lomustine	Partial response	Stable disease
20	11	1	No	Lomustine	Stable disease	Not done

\* Although scan responses are reported for those patients treated immediately after standard therapy, these data were excluded from the overall analysis as they had not progressed at the time of starting this regimen.

<sup>†</sup> Patient 5 was treated within 1 month of a radiological diagnosis of glioblastoma, after previous treatment for grade II disease.

In parallel with the increasing pre-clinical data on ipilimumab in glioblastoma, clinical experience with the drug continues to develop. Ipilimumab has been investigated in combination with a second checkpoint inhibitor nivolumab, which targets the programmed death receptor 1. Although there is evidence that these two drugs show synergy in melanoma [20,21], this has so far not been found in glioblastoma (NCT02017717) [22], where the combination conferred no additional benefit and greatly increased the incidence of immune toxicity when compared with nivolumab alone. A second phase I safety study is planned investigating ipilimumab and nivolumab in combination with temozolomide for glioblastoma (NCT02311920). As a monotherapy, nivolumab shows efficacy in melanoma [23], lung

cancer [24] and renal cell carcinoma [25] and is currently being investigated in a phase III trial in glioblastoma (NCT02017717). A second anti-programmed death receptor 1 checkpoint inhibitor, pembrolizumab, is clinically approved for use in melanoma [26,27] and clinical trials in a variety of tumours are either open or registered, including investigating pembrolizumab in combination with bevacizumab for recurrent glioblastoma (NCT02337491).

Ipilimumab, nivolumab and pembrolizumab have established immune checkpoint inhibition in clinical practice, and there are more immune checkpoint inhibitors in pre-clinical development. The potential for targeting immune checkpoints continues to grow [28,29] and on-going research into the mechanisms of action of these drugs suggest that they could also augment the effect of radiotherapy in some cancers [30], including glioblastoma [31].

**Table 3**

Observed adverse events in all patients (regardless of causality)

Adverse event	Grade			Total number (% patients)
	1	2	3	
Fatigue	8	0	0	8 (40%)
Diarrhoea	2	3	1	6 (30%)
Abscess formation	0	0	3	3 (15%)
Rash	0	1	0	1 (5%)
Arthritis	0	1	0	1 (5%)
Perianal fistula	0	1	0	1 (5%)
Intracerebral bleed	0	0	1	1 (5%)
Pulmonary embolism	0	0	2	2 (10%)

## Conclusions

The results shown here show that 31% of patients with recurrent disease had a partial radiographic response to treatment based on RANO criteria, and a further 31% had stable disease. Treatment was well tolerated, with treatment terminated before completion due to adverse events in two patients. Five other patients experienced toxicities at grade 2 or above, which could be attributed to the drug combination. All immune-related toxicities were manageable with corticosteroids.

The data presented in this patient series is non-randomised and involves small patient numbers. However, the results warrant investigation in formal prospective clinical trials, both in newly diagnosed and recurrent disease. The recently reported immunotherapy-RANO (iRANO) guidelines may usefully contribute to future analysis in clinical trials [32]. In addition, there remains a need for further pre-clinical research towards a better understanding of the biological basis for response to checkpoint inhibition. Data from current and future work in pre-clinical and clinical settings will be vital to stratify patients to the most appropriate therapy for this devastating condition.

## Acknowledgements

Work supported by the EU Seventh Framework Programme (FP7) (Dartrix EC GRANT: 278580), the University College Hospital/University College London (UCH/UCL) Biomedical Research Centre and The National Brain Appeal.

## References

- [1] Stupp R, Mason WP, van den Bent MJ, et al. Radiotherapy plus concomitant and adjuvant temozolomide for glioblastoma. *New Engl J Med* 2005;352:987–996.
- [2] Stupp R, Hegi ME, Mason WP, et al. Effects of radiotherapy with concomitant and adjuvant temozolomide versus radiotherapy alone on survival in glioblastoma in a randomised phase III study: 5-year analysis of the EORTC-NCIC trial. *Lancet Oncol* 2009;10:459–466.
- [3] Hodi FS, O'Day SJ, McDermott DF, et al. Improved survival with ipilimumab in patients with metastatic melanoma. *New Engl J Med* 2010;363:711–723.
- [4] Schadendorf D, Hodi FS, Robert C, et al. Pooled analysis of long-term survival data from phase II and phase III trials of ipilimumab in unresectable or metastatic melanoma. *J Clin Oncol* 2015;56:736.
- [5] Margolin K, Ernstoff MS, Hamid O, et al. Ipilimumab in patients with melanoma and brain metastases: an open-label, phase 2 trial. *Lancet Oncol* 2012;13:459–465.
- [6] Hodi FS, Lawrence D, Lezcano C, et al. Bevacizumab plus ipilimumab in patients with metastatic melanoma. *Cancer Immunol Res* 2014;2(7):632–642.
- [7] Norden A, Young G, Setayesh K, et al. Bevacizumab for recurrent malignant gliomas. Efficacy, toxicity, and patterns of recurrence. *Neurology* 2008;70:779–787.
- [8] Gilbert MR, Dignam JJ, Armstrong TS, et al. A randomized trial of bevacizumab for newly diagnosed glioblastoma. *New Engl J Med* 2014;370:699–708.
- [9] Chinot OL, Wick W, Mason W, et al. Bevacizumab plus radiotherapy–temozolomide for newly diagnosed glioblastoma. *New Engl J Med* 2014;370:709–722.
- [10] Vacchelli E, Aranda F, Obrist F, et al. Trial watch: immunostimulatory cytokines in cancer therapy. *Oncoimmunology* 2014;3:e29030.
- [11] Wen PY, Macdonald DR, Reardon DA, et al. Updated response assessment criteria for high-grade gliomas: response assessment in neuro-oncology working group. *J Clin Oncol* 2010;28:1963–1972.
- [12] Hu JL, Sharma P, Yu J, Black KL, Rudnick JD. *Ipilimumab for recurrent glioblastoma: a single-institution case series*. ASCO Annual Meeting Proceedings 2014, e13010.
- [13] Schaff LR, Lassman AB, Goldlust SA, et al. Ipilimumab for recurrent glioblastoma (GBM). *Neuro-oncology* 2014;16:v90.
- [14] Elamin YY, Rafee S, Toomey S, Hennessy BT. Immune effects of bevacizumab: killing two birds with one stone. *Cancer Microenvironment* 2014;8(1):1–7.
- [15] Klein S, Gokhale P, Jones K, et al. Immune checkpoint blockade activates effective anti-tumor immunity in an orthotopic model of glioblastoma (VAC12P.1119). *J Immunol* 2015;194:213.
- [16] Reardon D, Gokhale P, Ligon K, et al. Immune checkpoint blockade for glioblastoma: preclinical activity of single agent and combinatorial therapy. *Neuro-oncology* 2014;16:v116.
- [17] Fecci PE, Ochiai H, Mitchell DA, et al. Systemic CTLA-4 blockade ameliorates glioma-induced changes to the CD4+ T cell compartment without affecting regulatory T-cell function. *Clin Cancer Res* 2007;13:2158–2167.
- [18] Vom Berg J, Vrohligs M, Haller S, et al. Intratumoral IL-12 combined with CTLA-4 blockade elicits T cell–mediated glioma rejection. *J Exp Med* 2013;210:2803–2811.
- [19] Wainwright DA, Chang AL, Dey M, et al. Durable therapeutic efficacy utilizing combinatorial blockade against IDO, CTLA-4, and PD-L1 in mice with brain tumors. *Clin Cancer Res* 2014;20:5290–5301.
- [20] Wolchok JD, Kluger H, Callahan MK, et al. Nivolumab plus ipilimumab in advanced melanoma. *New Engl J Med* 2013;369:122–133.
- [21] Larkin J, Chiarion-Sileni V, Gonzalez R, et al. Combined nivolumab and ipilimumab or monotherapy in untreated melanoma. *New Engl J Med* 2015;373:23–34.
- [22] Sampson J, Vlahovic G, Desjardins A, et al. Randomized phase IIb study of nivolumab (anti-PD-1; BMS-936558, ONO-4538) alone or in combination with ipilimumab versus bevacizumab in patients (pts) with recurrent glioblastoma (GBM). *J Clin Oncol* 2014;32:TPS2101.
- [23] Topalian SL, Sznol M, McDermott DF, et al. Survival, durable tumor remission, and long-term safety in patients with advanced melanoma receiving nivolumab. *J Clin Oncol* 2014;32:1020–1030.
- [24] Brahmer JR, Horn L, Gandhi L, et al. Nivolumab (anti-PD-1, BMS-936558, ONO-4538) in patients (pts) with advanced non-small-cell lung cancer (NSCLC): survival and clinical activity by subgroup analysis. ASCO Annual Meeting Proceedings 2014, 8112.
- [25] Motzer R, Escudier B, McDermott D, et al. Nivolumab versus everolimus in advanced renal-cell carcinoma. *N Engl J Med* 2015;373(19):1803–1813.
- [26] Robert C, Schachter J, Long GV, et al. Pembrolizumab versus ipilimumab in advanced melanoma. *N Engl J Med* 2015;372(26):2521–2532.
- [27] NICE. *Pembrolizumab for treating advanced melanoma after disease progression with ipilimumab*. National Institute for Health and Care Excellence (NICE) technology appraisal guidance. TA357. Available at: <http://www.nice.org.uk>; 2015.
- [28] Pennock GK, Chow LQ. The evolving role of immune checkpoint inhibitors in cancer treatment. *Oncologist* 2015;20:812–822.
- [29] Webster RM. The immune checkpoint inhibitors: where are we now? *Nat Rev Drug Disc* 2014;13(12):883–884.
- [30] Pilonis KA, Vanpouille-Box C, Demaria S. Combination of radiotherapy and immune checkpoint inhibitors. *Semin Radiat Oncol* 2015;25:28–33.
- [31] Belcaid Z, Phallen JA, Zeng J, et al. Focal radiation therapy combined with 4-1BB activation and CTLA-4 blockade yields long-term survival and a protective antigen-specific memory response in a murine glioma model. *PLoS One* 2014;9(7):e101764.
- [32] Okada H, Weller M, Huang R, et al. Immunotherapy response assessment in neuro-oncology: a report of the RANO working group. *Lancet Oncol* 2015;16:e534–e542.