

Use of Caval Subtraction 2D Phase-Contrast MR Imaging to Measure Total Liver and Hepatic Arterial Blood Flow: Preclinical Validation and Initial Clinical Translation¹

Manil D. Chouhan, MRCS, FRCR, PhD
 Rajeshwar P. Mookerjee, FRCR, PhD
 Alan Bainbridge, PhD
 Simon Walker-Samuel, PhD
 Nathan Davies, PhD
 Steve Halligan, MRCP, FRCR, MD
 Mark F. Lythgoe, PhD
 Stuart A. Taylor, MRCP, FRCR, MD

Purpose:

To validate caval subtraction two-dimensional (2D) phase-contrast magnetic resonance (MR) imaging measurements of total liver blood flow (TLBF) and hepatic arterial fraction in an animal model and evaluate consistency and reproducibility in humans.

Materials and Methods:

Approval from the institutional ethical committee for animal care and research ethics was obtained. Fifteen Sprague-Dawley rats underwent 2D phase-contrast MR imaging of the portal vein (PV) and infrahepatic and suprahepatic inferior vena cava (IVC). TLBF and hepatic arterial flow were estimated by subtracting infrahepatic from suprahepatic IVC flow and PV flow from estimated TLBF, respectively. Direct PV transit-time ultrasonography (US) and fluorescent microsphere measurements of hepatic arterial fraction were the standards of reference. Thereafter, consistency of caval subtraction phase-contrast MR imaging-derived TLBF and hepatic arterial flow was assessed in 13 volunteers (mean age, 28.3 years \pm 1.4) against directly measured phase-contrast MR imaging PV and proper hepatic arterial inflow; reproducibility was measured after 7 days. Bland-Altman analysis of agreement and coefficient of variation comparisons were undertaken.

Results:

There was good agreement between PV flow measured with phase-contrast MR imaging and that measured with transit-time US (mean difference, -3.5 mL/min/100 g; 95% limits of agreement [LOA], ± 61.3 mL/min/100 g). Hepatic arterial fraction obtained with caval subtraction agreed well with those with fluorescent microspheres (mean difference, 4.2%; 95% LOA, $\pm 20.5\%$). Good consistency was demonstrated between TLBF in humans measured with caval subtraction and direct inflow phase-contrast MR imaging (mean difference, -1.3 mL/min/100 g; 95% LOA, ± 23.1 mL/min/100 g). TLBF reproducibility at 7 days was similar between the two methods (95% LOA, ± 31.6 mL/min/100 g vs ± 29.6 mL/min/100 g).

Conclusion:

Caval subtraction phase-contrast MR imaging is a simple and clinically viable method for measuring TLBF and hepatic arterial flow.

Published under a CC BY 4.0 license.

Online supplemental material is available for this article.

¹From the University College London Centre for Medical Imaging (M.D.C., S.H., S.A.T.), Institute for Liver and Digestive Health (R.P.M., N.D.), and Centre for Advanced Biomedical Imaging (S.W.S., M.F.L.), Division of Medicine, University College London, 250 Euston Rd, 3rd Floor East, London NW1 2PG, England; and Department of Medical Physics, University College London Hospitals NHS Trust, London, England (A.B.). Received August 7, 2015; revision requested October 15; revision received November 17; accepted December 23; final version accepted January 13, 2016. Address correspondence to S.A.T. (e-mail: csytaylor@yahoo.co.uk).

The study was supported by the National Institute for Health Research, University College London Hospitals Biomedical Research Centre. S.H. and S.A.T. are senior investigators for the National Institute for Health Research, and M.D.C. is a clinical lecturer for the National Institute for Health Research. M.D.C. was supported by the Wellcome Trust (grant WT092186).

Published under a CC BY 4.0 license.

The dual portal venous (PV) and hepatic arterial blood supply to the liver makes it difficult to assess hemodynamic complications of liver disease. To date, invasive methods still remain the standard of reference. Imaging-based hepatic hemodynamic assessment has the potential to yield useful and meaningful biomarkers of portal hypertension and chronic liver disease (1).

Two-dimensional (2D) phase-contrast magnetic resonance (MR)

Advances in Knowledge

- In a rodent model, portal venous flow measurement obtained with two-dimensional (2D) phase-contrast MR imaging demonstrates good agreement with invasive transit-time US (mean difference, -3.5 mL/min/100 g; Bland-Altman 95% limits of agreement [LOA], ± 61.3 mL/min/100 g).
- In a rodent model, hepatic arterial fraction measurement obtained with caval subtraction 2D phase-contrast MR imaging demonstrates good agreement with an invasive microsphere standard of reference (mean difference, 4.2%; 95% LOA, $\pm 20.5\%$).
- In human volunteers, total liver blood flow (TLBF) estimated with caval subtraction 2D phase-contrast MR imaging shows good agreement with that calculated from direct inflow phase-contrast MR imaging (mean difference, -1.3 mL/min/100 g; 95% LOA, ± 23.1 mL/min/100 g).
- In human volunteers, caval subtraction TLBF and directly measured inflow phase-contrast MR imaging TLBF at 7 days were similar (95% LOA, ± 31.6 mL/min/100 g vs ± 29.6 mL/min/100 g).
- Caval subtraction 2D phase-contrast MR imaging is a noninvasive, simple, and rapid technique for measuring total liver and hepatic arterial blood flow.

imaging is an established, widely available, and validated method for the noninvasive measurement of large-vessel bulk flow (2–5). Several investigators have used phase-contrast MR imaging to study PV flow, although few have reported data from the proper hepatic artery (6–9) because evaluation is challenging in routine clinical practice, primarily because of small vessel size, tortuosity, and anatomic variation. Furthermore, low signal-to-noise ratio, vessel orthogonality, partial volume averaging errors, intravoxel phase dispersion, and spatial misregistration can confound estimation of pulsatile flow in small arteries and have impeded both research and clinical use of phase-contrast MR imaging for the measurement of total liver blood flow (TLBF).

Recognizing these challenges, we propose an alternative application of 2D phase-contrast MR imaging to measure TLBF and proper hepatic arterial flow by using caval subtraction. TLBF and hepatic arterial flow fraction could be valuable hemodynamic biomarkers of liver disease. The purpose of this study was to validate caval subtraction 2D phase-contrast MR imaging measurements of TLBF and hepatic arterial fraction in a preclinical animal model and evaluate consistency and reproducibility in humans.

Materials and Methods

Background Theory

From the application of the principle of conservation of mass to flow (Q), for a fixed tissue volume:

$$Q_{in} = Q_{out}, \quad (1)$$

where Q_{in} is blood flow into the organ and Q_{out} is blood flow out of the organ. On the basis of the anatomic configuration of the liver, the intrahepatic inferior vena cava (IVC) receives blood entirely from the hepatic venous system. Outflow TLBF (Q_{out} , equivalent to Q_{TLBF}) can therefore be estimated by measuring bulk flow in the suprahepatic subcardiac portion of the IVC ($Q_{suprahepatic}$) and then subtracting flow from the

intrahepatic, suprarenal portion of the IVC ($Q_{intrahepatic}$) (Fig E1a [online]), as follows:

$$Q_{TLBF} = Q_{suprahepatic} - Q_{intrahepatic}. \quad (2)$$

Hepatic arterial flow (Q_{HA}) can then be estimated by subtracting directly measured PV flow (Q_{PV}) from the outflow TLBF (Fig E1b [online]), as follows:



$$Q_{HA} = Q_{TLBF} - Q_{PV}. \quad (3)$$

Preclinical Validation

Subjects and preparation.—All experiments were conducted according to the home office guidelines under the U.K. Animals in Scientific Procedures Act (1986) after approval from the Animal Care Ethical Committee of University College London. Experiments were performed between September 12 and October 17, 2013, on healthy male Sprague-Dawley rats (Charles River UK, Margate, England) with normal liver function (weight, 250–300 g).

The study cohort consisted of 15 healthy animals treated with sham laparotomy ($n = 11$) or bile duct ligation (BDL) ($n = 4$). The latter group was included to test the feasibility of performing phase-contrast MR imaging in an

Published online before print

10.1148/radiol.2016151832 Content codes:  

Radiology 2016; 000:1–8

Abbreviations:

BDL = bile duct ligation
IVC = inferior vena cava
LOA = limits of agreement
PV = portal vein
TLBF = total liver blood flow
2D = two-dimensional
 V_{enc} = velocity encoding

Author contributions:

Guarantors of integrity of entire study, M.D.C., R.P.M., S.A.T.; study concepts/study design or data acquisition or data analysis/interpretation, all authors; manuscript drafting or manuscript revision for important intellectual content, all authors; manuscript final version approval, all authors; agrees to ensure any questions related to the work are appropriately resolved, all authors; literature research, M.D.C., R.P.M., A.B., M.F.L., S.A.T.; clinical studies, M.D.C., A.B.; experimental studies, M.D.C., R.P.M., A.B., S.W.S., N.D., M.F.L.; statistical analysis, M.D.C., A.B.; and manuscript editing, all authors

Conflicts of interest are listed at the end of this article.

animal model of portal hypertension. BDL and sham surgery were conducted as described previously (10). After recovery, animals were maintained for 4–5 weeks before undergoing the experimental protocol. All procedures were performed by the study coordinator (M.D.C., a radiology research fellow qualified in animal handling with 4 years of experience).

Standards of reference.—For rats that underwent sham operation ($n = 11$), laparotomy was performed and a 2-mm transit-time US probe (Transonic Systems, Ithaca, NY) was placed around the PV. PV flow readings were obtained with transit-time US after 10–15 minutes, once the animal was stable. Extensive adhesions around the porta hepatis and associated high risk of traumatic vessel injury precluded transit-time US validation in the BDL group.

After transit-time US measurement, 15- μm polystyrene fluorescent microspheres (FluoSpheres; Life Technologies, Warrington, England) suspended in heparinized saline were administered transcatheterously into the left ventricle over approximately 10 seconds under US guidance (Terason; Teratech, Burlington, Mass) (Fig E2 [online]). Animals were then transferred to the imager for phase-contrast MR imaging. The animal was then sacrificed and organs were explanted for microsphere processing using an adapted protocol (11), as summarized in Appendix E1 (online). To ensure adequate central mixing of microspheres, data exceeding 20% difference in microsphere content between right and left kidneys were excluded.

Two-dimensional cine phase-contrast MR imaging.—Temperature was monitored with a rectal probe (SA Instruments, New York, NY), with core body temperature maintained between 36°C and 38°C. Cardiac monitoring was undertaken by using a triple-electrode single-lead system (SA Instruments). Imaging was performed by using a 9.4-T unit (Agilent Technologies, Oxford, England), with sequence parameters listed in the Table. Axial and angled coronal gradient-echo images

Parameter	Preclinical Examination (9.4 T)		Clinical Examination (3.0 T)	
	Anatomic Imaging*	Phase-Contrast MR Imaging†	Anatomic Imaging‡	Phase-Contrast MR Imaging‡
TR/TE (msec)	8.2/5.6	10/1.2	2.47/1.23	8.70/5.22
Flip angle (degrees)	20	10	45	10
Matrix size (pixels)	128 × 128	192 × 192	352 × 352	336 × 336
Field of view (mm)	80 × 80	40 × 40	350 × 350	271 × 210
Spatial resolution (mm ²)	0.625 × 0.625	0.208 × 0.208	0.994 × 0.994	0.808 × 0.625
Section thickness (mm)	2	2	5	5
Section gap (mm)	4.5	...	5.5	...
Cardiac cycle phases	...	12–15	...	7

Note.—TR/TE = repetition time/echo time.
 * Performed with a gradient-echo sequence.
 † Performed with a gradient-echo sequence with additional bipolar phase contrast gradients.
 ‡ Performed with steady-state free precession.

were used to identify the IVC and PV, and phase-contrast image planes were planned to ensure orthogonality with the subcardiac portion of the suprahepatic IVC, suprarenal portion of the infrahepatic IVC, and PV.

Cardiac- and respiratory-gated 2D cine phase-contrast MR imaging was performed with 2-mm-thick sections, a 10° flip angle, and a 192 × 192 (frequency encoding × phase encoding) acquisition matrix. On the basis of initial pilot work in four animals (not presented in this study), velocity encoding (V_{enc}) settings of 33 cm/sec for PV and infrahepatic IVC flows and 66 cm/sec for suprahepatic IVC flows were applied (Table). Phase maps were acquired at each V_{enc} setting with opposite flow-encoding directions. Correction for background phase errors was achieved by subtracting phase maps with opposing flow-encoding directions, with the assumption that the phase of stationary spins was identical in each image. Acquisition time for each phase-contrast MR imaging measurement was usually less than 10 minutes. Regions of interest were positioned manually by the study coordinator on each vessel for each frame of the cardiac cycle, and flow quantification was performed by using in-house-developed Matlab code (MathWorks, Natick, Mass) on the

basis of established algorithms (12). All PV flow, estimated TLBF, and hepatic arterial flow measurements were normalized to explanted liver weight.

Human Translation

Two aspects of the caval subtraction technique were then tested in healthy volunteers: (a) consistency with directly measured phase-contrast MR imaging PV and hepatic arterial inflow and (b) measurement reproducibility after 7 days.

Subjects and preparation.—University College London Ethics Committee approval was obtained, and participants provided informed written consent. Volunteers were recruited by means of advertisement within the university campus and were eligible if they (a) had no contraindications to MR imaging, (b) were not taking any long-term medication (excluding the oral contraceptive pill), and (c) had no documented history of previous liver or gastrointestinal disease. Fourteen volunteers were screened, one of whom was excluded because of claustrophobia. The final cohort consisted of seven men (mean age \pm standard deviation, 26.5 years \pm 1.36) and six women (mean age, 31.2 years \pm 2.62) who underwent imaging between June 14 and July 25, 2013. Participants fasted for 6 hours before MR imaging and avoided caffeinated fluids.

Two-dimensional cine phase-contrast MR imaging.—Phase-contrast MR imaging was performed with a 3.0-T unit (Achieva; Philips Healthcare, Best, the Netherlands) and a 16-channel body coil (SENSE XL-Torso, Philips Healthcare). Imaging parameters are given in the Table.

Coronal (upper abdomen), sagittal (abdominal great vessels), and oblique (PV) breath-hold balanced steady-state free precession images were acquired. Two-dimensional phase-contrast MR imaging with expiratory breath hold and retrospective cardiac gating was planned in two planes by the study coordinator to ensure orthogonality to the target vessel. Studies were performed through the PV ($V_{enc} = 40$ cm/sec), proper hepatic artery ($V_{enc} = 60$ cm/sec), infrahepatic IVC (above the renal veins, below the hepatic IVC; $V_{enc} = 60$ cm/sec), and suprahepatic IVC (above the hepatic venous inflow, below the right atrial junction; $V_{enc} = 80$ cm/sec). Where hepatic arterial anatomy varied ($n = 2$), measurements were made as close as possible to the origin of the hepatic artery. Images were reviewed for aliasing and V_{enc} settings increased by 20 cm/sec when appropriate. Data were acquired by using the unit's clinical flow quantification implementation. Phase maps were acquired at each V_{enc} setting with opposite flow-encoding directions. Correction for background phase errors was achieved by subtracting phase maps with opposing flow-encoding directions, with the assumption that the phase of stationary spins was identical in each image. A local phase-correction filter was also applied to correct for phase errors induced by eddy currents. The acquisition time for each measurement was less than 20 seconds. Each phase-contrast MR imaging study was repeated three times. Flow quantification was performed by using freely available software (Segment; Medviso, Lund, Sweden) and the mean of triplicate measurements used for analysis. Caval subtraction TLBF, PV flow, hepatic arterial flow, and hepatic arterial fraction were calculated

(Eqq [2, 3]) and compared with direct phase-contrast MR imaging of PV and hepatic arterial inflow.

Liver volume was estimated by using steady-state free precession coronal images with 5-mm-thick sections. Segmentation was performed manually by the study coordinator using software (Amira Resolve RT; Visage Imaging, Berlin, Germany). A tissue density of 1.0 g/mL was assumed (13).

Seven days after the original study, subjects underwent repeat imaging with identical preparation and MR imaging protocol at a comparable time of the day. All analyses and quantification were performed by the study coordinator (M.D.C., with 5 years of experience in abdominal imaging).

Statistical Analysis

Data normality was confirmed with Kolmogorov-Smirnov testing. All bulk flow measurements obtained at phase-contrast MR imaging were normalized to liver weight or volume. Comparison between measurements derived from caval subtraction phase-contrast MR imaging and standards of reference (transit-time US, microspheres, direct inflow phase-contrast MR imaging) and 7-day reproducibility studies were assessed by using Bland-Altman analysis of agreement, with calculation of 95% limits of agreement (LOA). Coefficients of variation were also calculated and compared by using methods described by Forkman (14). Because of the small number of animals in the sham and BDL groups that underwent validation with microsphere analysis, validation analysis was pooled across both cohorts and the Mann-Whitney U test used for comparison of PV and relative hepatic arterial flow. Data are expressed as means \pm standard errors, and $P < .05$ was indicative of a statistically significant difference.

Results

Preclinical Cohort

Across 15 animals, the mean body weight was 451.7 g \pm 9.0 and the wet liver mass was 24.7 g \pm 2.0. All animals

in the BDL group had evidence of cirrhosis at histopathologic examination.

Technical feasibility of caval subtraction phase-contrast MR imaging.—Electrocardiographically and respiratory-gated cine phase-contrast MR imaging flow studies through the cardiac cycle demonstrated physiologic flow profiles through the PV and infrahepatic and suprahepatic IVC (Fig E3 [online]).

Validation of PV and relative hepatic arterial flow.—Comparing phase-contrast MR imaging versus transit-time US ($n = 11$), the mean difference between PV flow directly measured with phase-contrast MR imaging (mean, 182.8 mL/min/100 g \pm 9.9) and transit-time US (mean, 186.3 mL/min/100 g \pm 11.9) was -3.5 mL/min/100 g \pm 9.4, with 95% LOA of ± 61.3 mL/min/100 g (Fig 1a). The coefficient of variation for PV flow was similar for transit-time US (21.2%) compared with phase-contrast MR imaging (17.9%) ($F_{10,10} = 1.38$, $P = .31$).

In the comparison of phase-contrast MR imaging with microspheres, seven animals had inadequate central mixing of microspheres and were excluded, leaving eight for analysis (sham, $n = 4$; BDL, $n = 4$). The mean difference between relative hepatic arterial flow derived from phase-contrast MR imaging with caval subtraction (Eq [3]; mean, 35.3% \pm 11.6) and that calculated from the microsphere distribution analysis (mean, 31.1% \pm 9.8) was 4.2% \pm 3.7, with 95% LOA of $\pm 20.5\%$ (Fig 1c). The coefficient of variation was similar for caval subtraction phase-contrast MR imaging (93.0%) and microsphere analysis (89.2%) ($F_{7,7} = 0.95$, $P = .52$). Relative hepatic arterial flow was greater and PV flow was lower in animals with cirrhosis and portal hypertension (relative hepatic arterial flow: 50.3% \pm 13.5 in BDL group vs 11.8% \pm 4.3 in sham group; PV flow: 94.3 mL/min/100 g \pm 28.8 in BDL group vs 167.0 mL/min/100 g \pm 20.3 in sham group), but these differences were not statistically significant (hepatic arterial fraction, $P = .0571$; PV flow, $P = .200$).

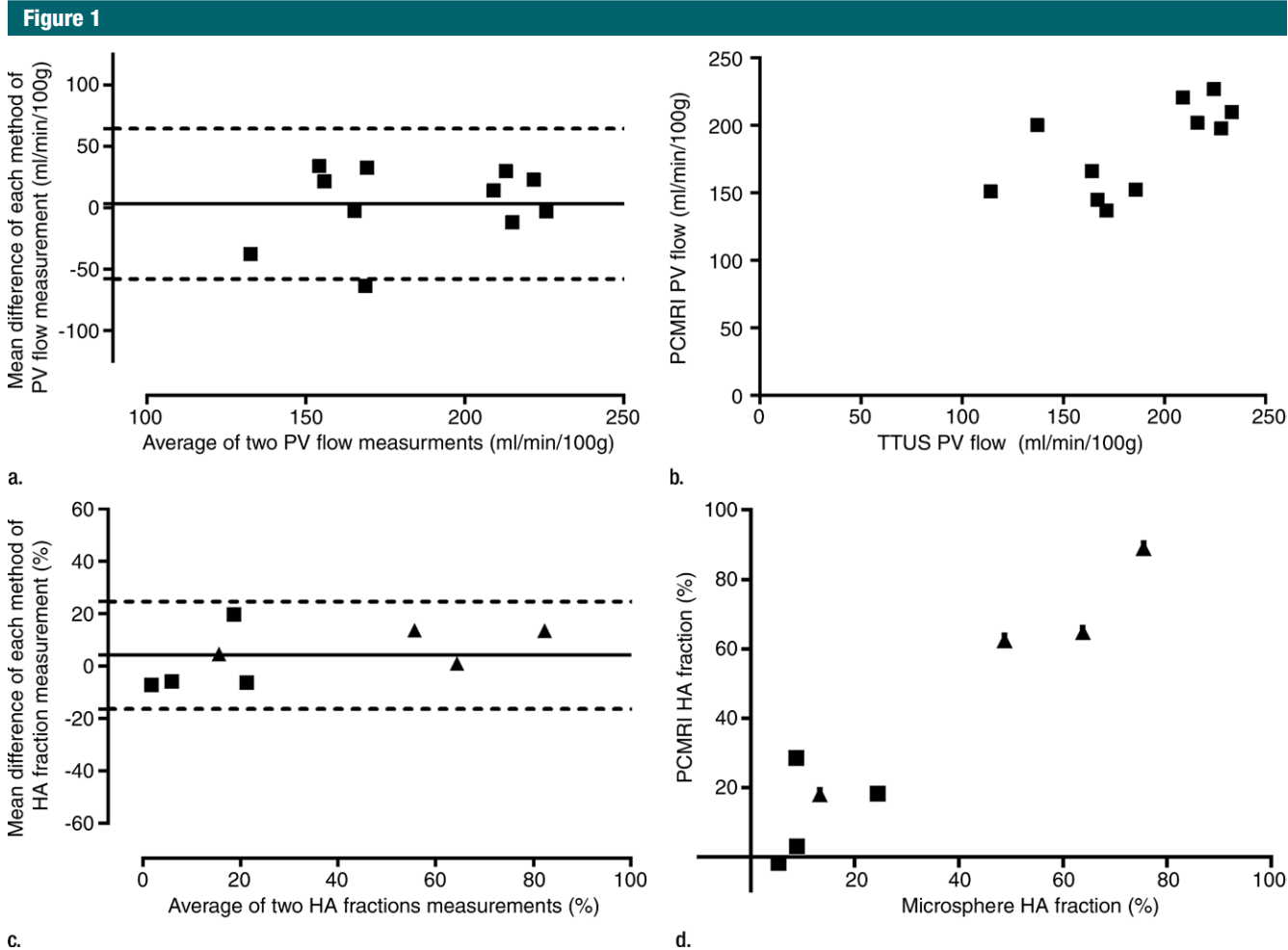


Figure 1: Validation of phase-contrast MR imaging PV flow and caval subtraction phase-contrast MR imaging–derived hepatic arterial (HA) fraction in sham-operated (■) and BDL (▲) rats. (a, c) Bland-Altman plots and (b, d) scatterplots show agreement between (a, b) PV flow at phase-contrast MR imaging and transit-time US (TTUS) and (c, d) hepatic arterial fraction at caval subtraction phase-contrast MR imaging and fluorescent microspheres.

Clinical Cohort

The mean liver volume was 1211.0 mL ± 52.9. Two subjects declined subsequent examination, leaving 11 in the reproducibility cohort.

Technical feasibility of caval subtraction phase-contrast MR imaging.—Electrocardiographically and respiratory-gated cine phase-contrast MR imaging flow studies through the cardiac cycle demonstrated physiologic flow profiles through the PV, infrahepatic IVC, and suprahepatic IVC (Fig E4 [online]).

Caval subtraction phase-contrast MR imaging versus direct phase-contrast MR imaging.—The mean difference between

TLBF measured with caval subtraction phase-contrast MR imaging (mean, 71.1 mL/min/100 g ± 3.3) and that measured with direct phase-contrast MR imaging (sum of PV and common hepatic arterial flow; mean, 72.5 mL/min/100 g ± 3.3) and between calculated hepatic arterial flow (Eq [3]; mean, 14.0 mL/min/100 g ± 3.5) and direct phase-contrast MR imaging measured hepatic arterial flow (mean, 15.3 mL/min/100 g ± 2.4) was -1.3 mL/min/100 g ± 2.4. The 95% LOA for caval subtraction versus direct inflow phase-contrast MR imaging were ±23.1 mL/min/100 g for both TLBF and hepatic arterial flow (range, 40.5–100.9 mL/min/100 g and -20.7 to 54.9 mL/

min/100 g, respectively) (Fig 2a, 2c). The coefficient of variation for caval subtraction phase-contrast MR imaging TLBF (23.0%) was similar to that for direct inflow TLBF (22.2%) ($F_{23,23} = 0.94, P = .56$). Hepatic arterial flow with caval subtraction phase-contrast MR imaging (123.2%) was higher than that with direct phase-contrast MR imaging (75.6%), although this did not reach statistical significance ($F_{23,23} = 1.68, P = .11$).

Seven-day reproducibility.—The mean differences between TLBF measured with caval subtraction phase-contrast MR imaging and hepatic arterial flow measurements obtained 7 days apart were -8.5 mL/min/100 g ± 4.9

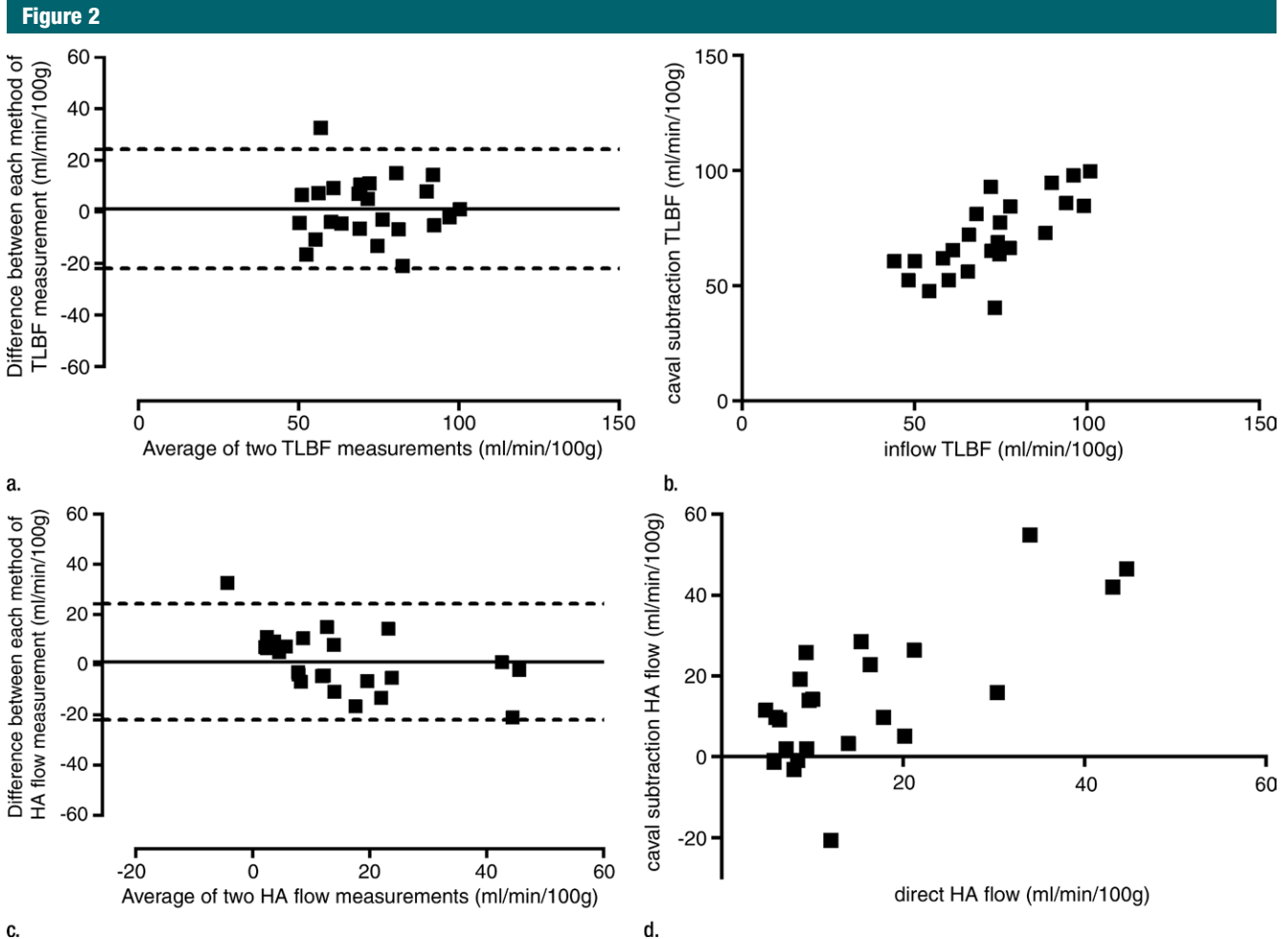


Figure 2: Consistency of caval subtraction phase-contrast MR imaging. Caval subtraction phase-contrast MR imaging TLBF and hepatic arterial flow in healthy volunteers were compared with contemporaneous inflow phase-contrast MR imaging measurements. Data were pooled from baseline and 7-day reproducibility studies. (a, c) Bland-Altman plots and (b, d) scatterplots show agreement between (a, b) TLBF estimated at caval subtraction imaging and that determined at inflow phase-contrast MR imaging and between (c, d) hepatic arterial flow estimated at caval subtraction imaging and proper hepatic arterial flow at inflow phase-contrast MR imaging.

and $7.3 \text{ mL/min/100 g} \pm 4.4$, respectively. The 95% LOA were $\pm 31.6 \text{ mL/min/100 g}$ for TLBF and $\pm 28.8 \text{ mL/min/100 g}$ for hepatic arterial flow. The mean difference between directly measured phase-contrast MR imaging TLBF and hepatic arterial flow measurements obtained 7 days apart were $-2.3 \text{ mL/min/100 g} \pm 4.5$ and $1.1 \text{ mL/min/100 g} \pm 3.0$, respectively. The caval subtraction 95% LOA were $\pm 31.6 \text{ mL/min/100 g}$ for TLBF and $\pm 28.8 \text{ mL/min/100 g}$ for hepatic arterial flow. The 95% LOA were $\pm 29.6 \text{ mL/min/100 g}$ for TLBF and $\pm 19.5 \text{ mL/min/100 g}$ (range, 4.9–44.6 mL/min/100 g) for hepatic arterial flow.

Discussion

Accurate assessment of proper hepatic arterial flow (and, consequently, TLBF) with use of phase-contrast MR imaging is challenging in both preclinical and clinical contexts. In rodents, the vessel itself is extremely small—less than 1 mm in diameter (15–17)—which introduces measurement errors, even at high field strengths. Technical challenges have confounded attempts to measure proper hepatic arterial flow in humans with clinical systems (6–9). Adequate signal-to-noise ratio is less of an issue because the vessel is larger, but partial

voluming and spatial resolution remain problematic, particularly at 1.5 T (7). Furthermore, frequent anatomic variation (18–20) complicates measurement and requires costly radiologic expertise for planning, which substantially impedes clinical implementation.

We have demonstrated that caval subtraction phase-contrast MR imaging provides a relatively simple strategy for overcoming these limitations in both rodents and humans. We found that phase-contrast MR imaging is technically feasible in animals (even in a cirrhotic BDL model), and phase-contrast MR imaging PV flow estimates showed

encouraging agreement with directly measured transit-time US flow (21). Thereafter, with the caval subtraction technique, reasonable agreement was obtained for hepatic arterial fraction against a microsphere standard of reference. Unfortunately, quantification of absolute hepatic arterial flow was not undertaken because simultaneous peripheral arterial sampling proved unreliable in pilot experiments.

For human translation, we chose not to use transcutaneous Doppler US measurements of PV and hepatic arterial flow because reported reproducibility is poor (8,22–24). Instead, direct phase-contrast MR imaging measurements of PV and hepatic arterial flow were used to test consistency of the caval subtraction phase-contrast MR imaging technique. Good agreement for TLBF was demonstrated between the two methods, and although hepatic arterial flow agreement was less impressive, the level of disagreement was not contingent on measurement value (ie, there was no systematic bias). Hepatic arterial flow measurements suffer from error propagation as inaccuracies in IVC and PV flow are summated during subtraction. This can result in nonphysiologic results such as negative estimates of hepatic arterial flow (particularly when true hepatic arterial flow is low, as would be expected in healthy volunteers).

Measurements obtained with caval subtraction phase-contrast MR imaging were, however, reassuringly similar to the direct measurements obtained with inflow phase-contrast MR imaging, although variable for both techniques, likely due to natural variation in vessel flow rates contingent on differing subject hydration, for example.

To place the levels of agreement for caval subtraction technique with standards of reference into clinical context, it is known that TLBF can vary by as much as 58% between health and disease (16,25,26), which is much greater than the expected error range found in the current study.

Our study has limitations. Although hepatic venous pressure gradient and portal venous pressure are clinically useful hepatic hemodynamic

parameters for determining both management and prognosis (27), the value of absolute flow parameters in clinical practice remains unclear. Caval subtraction phase-contrast MR imaging may also have limitations in the assessment of some patients with chronic liver disease: The presence of large extrahepatic portosystemic shunts (eg, recanalized umbilical vein or gastric varices), retrograde PV flow, or venous outflow obstruction (Budd-Chiari syndrome) are likely to compromise simple caval subtraction assessment of TLBF or hepatic arterial flow. In addition, gating to a specific phase of respiration can potentially introduce (systematic) errors, particularly if caval blood flow at different levels is variably influenced by respiration phase, a phenomenon that was not investigated in this study. Finally, studies in anesthetized animals and healthy volunteers represent ideal conditions to test the technique given the compliance with imaging protocols. Studies translating this method into potentially less compliant, unwell patients with chronic liver disease are planned and are necessary to determine the value of caval subtraction phase-contrast MR imaging in clinical practice.

Caval subtraction phase-contrast MR imaging is a simple and rapid technique, amenable to technologist-led phase-contrast MR imaging planning in clinical practice. It could also be used for noninvasive validation of more complex methods such as four-dimensional phase-contrast MR imaging. In summary, we have demonstrated that caval subtraction phase-contrast MR imaging is technically feasible and may offer a reproducible and clinically viable method for measuring TLBF and hepatic arterial flow.

Acknowledgments: We are grateful for the assistance of Raj Ramasawmy, PhD, and Tom Roberts, PhD, in the development and post-processing of preclinical phase-contrast MR imaging sequences and Abe Habtieson, MSc, for preparing rats for sham treatment and bile duct ligation. Finally, we are very grateful for the assistance of the clinical MR radiographers who conducted imaging of healthy volunteers.

Disclosures of Conflicts of Interest: M.D.C. disclosed no relevant relationships. R.P.M. disclosed no relevant relationships. A.B. disclosed

no relevant relationships. S.W.S. disclosed no relevant relationships. N.D. disclosed no relevant relationships. S.H. Activities related to the present article: disclosed no relevant relationships. Activities not related to the present article: received money as an expert witness in the field of gastrointestinal radiology; institution received multiple grants from research funders; received payment for lectures including service on speakers bureaus from Bracco. Other relationships: disclosed no relevant relationships. M.F.L. disclosed no relevant relationships. S.A.T. Activities related to the present article: disclosed no relevant relationships. Activities not related to the present article: received personal fees from Robarts PLC. Other relationships: disclosed no relevant relationships.

References

- Pandharipande PV, Krinsky GA, Rusinek H, Lee VS. Perfusion imaging of the liver: current challenges and future goals. *Radiology* 2005;234(3):661–673.
- Lotz J, Meier C, Leppert A, Galanski M. Cardiovascular flow measurement with phase-contrast MR imaging: basic facts and implementation. *RadioGraphics* 2002;22(3):651–671.
- Gouya H, Vignaux O, Sogni P, et al. Chronic liver disease: systemic and splanchnic venous flow mapping with optimized cine phase-contrast MR imaging validated in a phantom model and prospectively evaluated in patients. *Radiology* 2011;261(1):144–155.
- Jajamovich GH, Dyvorne H, Donnerhack C, Taouli B. Quantitative liver MRI combining phase contrast imaging, elastography, and DWI: assessment of reproducibility and postprandial effect at 3.0 T. *PLoS One* 2014;9(5):e97355.
- Stankovic Z, Frydrychowicz A, Csatar J, et al. MR-based visualization and quantification of three-dimensional flow characteristics in the portal venous system. *J Magn Reson Imaging* 2010;32(2):466–475.
- Jin N, Lewandowski RJ, Omary RA, Larson AC. Respiratory self-gating for free-breathing abdominal phase-contrast blood flow measurements. *J Magn Reson Imaging* 2009;29(4):860–868.
- Wilson DJ, Ridgway JP, Evans JA, Robinson P. Measurement of hepatic arterial flow using phase contrast magnetic resonance imaging. *Phys Med Biol* 2009;54(19):N439–N449.
- Yzet T, Bouzerar R, Allart JD, et al. Hepatic vascular flow measurements by phase contrast MRI and Doppler echography: a comparative and reproducibility study. *J Magn Reson Imaging* 2010;31(3):579–588.

9. Yzet T, Bouzerar R, Baledent O, et al. Dynamic measurements of total hepatic blood flow with phase contrast MRI. *Eur J Radiol* 2010;73(1):119–124.
10. Harry D, Anand R, Holt S, et al. Increased sensitivity to endotoxemia in the bile duct-ligated cirrhotic rat. *Hepatology* 1999;30(5):1198–1205.
11. Van Oosterhout MF, Willigers HM, Reneman RS, Prinzen FW. Fluorescent microspheres to measure organ perfusion: validation of a simplified sample processing technique. *Am J Physiol* 1995;269(2 Pt 2):H725–H733.
12. Haacke EM. *Magnetic resonance imaging: physical principles and sequence design*. New York, NY: Wiley, 1999.
13. Kuo PC, Li K, Alfrey EJ, Jeffrey RB, Garcia G, Dafoe DC. Magnetic resonance imaging and hepatic hemodynamics: correlation with metabolic function in liver transplantation candidates. *Surgery* 1995;117(4):373–379.
14. Forkman J. Estimator and tests for common coefficients of variation in normal distributions. *Commun Stat Theory Methods* 2009;38(2):233–251.
15. Lutt WW, Legare DJ, d'Almeida MS. Adenosine as putative regulator of hepatic arterial flow (the buffer response). *Am J Physiol* 1985;248(3 Pt 2):H331–H338.
16. Richter S, Mücke I, Menger MD, Vollmar B. Impact of intrinsic blood flow regulation in cirrhosis: maintenance of hepatic arterial buffer response. *Am J Physiol Gastrointest Liver Physiol* 2000;279(2):G454–G462.
17. Richter S, Olinger A, Hildebrandt U, Menger MD, Vollmar B. Loss of physiologic hepatic blood flow control (“hepatic arterial buffer response”) during CO₂-pneumoperitoneum in the rat. *Anesth Analg* 2001;93(4):872–877.
18. Covey AM, Brody LA, Maluccio MA, Getrajdman GI, Brown KT. Variant hepatic arterial anatomy revisited: digital subtraction angiography performed in 600 patients. *Radiology* 2002;224(2):542–547.
19. Hiatt JR, Gabbay J, Busuttil RW. Surgical anatomy of the hepatic arteries in 1000 cases. *Ann Surg* 1994;220(1):50–52.
20. Song SY, Chung JW, Yin YH, et al. Celiac axis and common hepatic artery variations in 5002 patients: systematic analysis with spiral CT and DSA. *Radiology* 2010;255(1):278–288.
21. D'Almeida MS, Cailmail S, Lebrec D. Validation of transit-time ultrasound flow probes to directly measure portal blood flow in conscious rats. *Am J Physiol* 1996;271(6 Pt 2):H2701–H2709.
22. Gauthier TP, Muhammad A, Wasan HS, Abel PD, Leen EL. Reproducibility of quantitative assessment of altered hepatic hemodynamics with dynamic contrast-enhanced ultrasound. *J Ultrasound Med* 2012;31(9):1413–1420.
23. Hübner GH, Steudel N, Reissmann A, et al. Hepatic arterial Doppler sonography in patients with cirrhosis and controls: observer and equipment variability with use of the ultrasonic contrast agent SHU 508A. *Z Gastroenterol* 2005;43(7):639–645.
24. Vermeulen MA, Ligthart-Melis GC, Buijsman R, et al. Accurate perioperative flow measurement of the portal vein and hepatic and renal artery: a role for preoperative MRI? *Eur J Radiol* 2012;81(9):2042–2048.
25. Mehta G, Mookerjee RP, Sharma V, Jalan R. Systemic inflammation is associated with increased intrahepatic resistance and mortality in alcohol-related acute-on-chronic liver failure. *Liver Int* 2015;35(3):724–734.
26. Iwasa M, Nakamura K, Nakagawa T, et al. Single photon emission computed tomography to determine effective hepatic blood flow and intrahepatic shunting. *Hepatology* 1995;21(2):359–365.
27. Thalheimer U, Mela M, Patch D, Burroughs AK. Targeting portal pressure measurements: a critical reappraisal. *Hepatology* 2004;39(2):286–290.