

# Accepted Manuscript



Her aching bones: atypical parathyroid adenoma

Filipe Brogueira Rodrigues, MD, Catarina Bekerman, MD, Joana Briosas Neves, MD, João Sousa, MD, Joana Vieira, MD, António Alves, MD, Ana Palha, MD, José Rocha, MD, Victor Ramalhinho, MD

PII: S0002-9343(15)01102-X

DOI: [10.1016/j.amjmed.2015.11.007](https://doi.org/10.1016/j.amjmed.2015.11.007)

Reference: AJM 13261

To appear in: *The American Journal of Medicine*

Received Date: 27 July 2015

Revised Date: 10 November 2015

Accepted Date: 10 November 2015

Please cite this article as: Rodrigues FB, Bekerman C, Neves JB, Sousa J, Vieira J, Alves A, Palha A, Rocha J, Ramalhinho V, Her aching bones: atypical parathyroid adenoma, *The American Journal of Medicine* (2015), doi: 10.1016/j.amjmed.2015.11.007.

This is a PDF file of an unedited manuscript that has been accepted for publication. As a service to our customers we are providing this early version of the manuscript. The manuscript will undergo copyediting, typesetting, and review of the resulting proof before it is published in its final form. Please note that during the production process errors may be discovered which could affect the content, and all legal disclaimers that apply to the journal pertain.

**Title page****Title**

Her aching bones: atypical parathyroid adenoma

**Authors' names and affiliations**

Filipe Brogueira Rodrigues, MD<sup>a,b,c</sup>, Catarina Bekerman, MD<sup>a</sup>, Joana Briosas Neves, MD<sup>a</sup>, João Sousa<sup>a</sup>, MD, Joana Vieira<sup>a</sup>, MD, António Alves<sup>d</sup>, MD, Ana Palha<sup>d</sup>, MD, José Rocha, MD<sup>e</sup>, Victor Ramalhinho, MD<sup>a</sup>

<sup>a</sup> Department of Medicine

Hospital de Santa Maria, Centro Hospitalar Lisboa Norte

Av. Prof. Egas Moniz

1649-035 Lisboa

Portugal

<sup>b</sup> Laboratory of Clinical Pharmacology and Therapeutics

Faculty of Medicine, University of Lisbon

Av. Prof. Egas Moniz

1649-035 Lisboa

Portugal

<sup>c</sup> Clinical Pharmacology Unit

Instituto de Medicina Molecular

Av. Prof. Egas Moniz

1649-035 Lisboa

Portugal

<sup>d</sup> Department of Pathology

Hospital de Santa Maria, Centro Hospitalar Lisboa Norte

Av. Prof. Egas Moniz

1649-035 Lisboa

Portugal

<sup>e</sup> Department of Surgery

Hospital de Santa Maria, Centro Hospitalar Lisboa Norte

Av. Prof. Egas Moniz

1649-035 Lisboa

Portugal

**Corresponding author**

Filipe Brogueira Rodrigues

Clinical Pharmacology Unit

Instituto de Medicina Molecular

Av. Prof. Egas Moniz

1649-035 Lisboa

Portugal

filipebrodrigues@gmail.com

+351 918786682

**Authors' e-mails**

FBR: filipebrodrigues@gmail.com;

CB: catarinabncarneiro@gmail.com;

JBN: jbriosaneves@gmail.com;

JS: jooadriano92@gmail.com;

JV: jvieira1@campus.ul.pt;

AA: antoniotalves@gmail.com;

AP: aopalha@gmail.com;

JR: jec.rocha@sapo.pt

VR: ramalhinho@mail.telepac.pt.

**Funding sources**

None.

**Conflicts of interest**

None.

**Contributions**

AP and VR were the guarantors. FBR, JBN and CB developed the first draft. JS, JV and AA conducted the revision of the first draft and built the final draft. FBR and CB gathered and edited Figures 1,2 and 3. AA and AP retrieved and edited Figure 4. AP, JR and VR provided expertise on pathology, endocrinal surgery and endocrinology, respectively. All authors read, provided feedback and approved the final manuscript.

**Article type**

Images in Radiology

**Key words**

Osteitis Fibrosa Cystica; Hyperparathyroidism; Tomography, X-Ray Computed; Magnetic Resonance Imaging

**Running head**

Lytic bone lesions with fluid-fluid levels

## Images in Radiology

Her aching bones: atypical parathyroid adenoma

Robert G. Stern, MD, Images in Radiology Editor

Filipe Brogueira Rodrigues, MD,<sup>a,d,e</sup> Catarina Bekerman, MD,<sup>a</sup> Joana Briosa Neves, MD,<sup>a</sup> João Sousa, MD,<sup>a</sup> Joana Vieira, MD,<sup>a</sup> António Alves, MD,<sup>b</sup> Ana Palha, MD,<sup>b</sup> José Rocha, MD,<sup>c</sup> Victor Ramalinho, MD<sup>a</sup>

Departments of <sup>a</sup>Medicine, <sup>b</sup>Pathology, and <sup>c</sup>Surgery, Hospital de Santa Maria, Centro Hospitalar Lisboa Norte, the <sup>d</sup>Laboratory of Clinical Pharmacology and Therapeutics, Faculty of Medicine, University of Lisbon, and the <sup>e</sup>Clinical Pharmacology Unit, Instituto de Medicina Molecular, Lisbon, Portugal.

Requests for reprints should be addressed to Filipe Brogueira Rodrigues, MD, Clinical Pharmacology Unit, Instituto de Medicina Molecular, Av. Prof. Egas Moniz, 1649-035 Lisboa, Portugal.

Email address: filipebrodrigues@gmail.com

**PRESENTATION**

A radiologic investigation of lower back pain captured something unusual: multiple osteolytic lesions with fluid-fluid levels. The patient was a 34-year-old Portuguese woman of Romani ethnicity. Previously healthy, she presented to our emergency department with a 6-month history of lumbar pain. Her medical history was unremarkable aside from 2 cesarean sections and a bilateral tubal ligation. She had been smoking 1 cigarette daily since she was 15 years old (0.95 pack year), denied taking medications on a regular basis, and was unemployed.

The pain was localized to the right lumbar area and was referred to the posterior aspect of her right thigh and leg. It had a continuous character, worsening with active lower limb movements and lessening with rest. Over the preceding 2 weeks, the severity had increased to an intensity that the patient rated as 8 out of 10

on a visual analogue pain scale. She was admitted to our department for a diagnostic work-up and pain control.

## ASSESSMENT

Physical examination revealed grade 1 arterial hypertension, an enlarged thyroid gland with a right-sided mobile elastic lump, tender iliac crests, painful passive and active bilateral lower limb movements despite full strength (Medical Research Council Scale for Testing Muscle Strength grade, 5 out of 5), and normal sensation in all 4 limbs.

Electrocardiography showed sinus rhythm. Conventional radiography in an anteroposterior view revealed an osteolytic lesion on the anterior aspect of the seventh right rib. The cervical, thoracic, lumbar, and abdominal views were unremarkable. An anteroposterior pelvic view disclosed multiple well-defined osteolytic lesions in both iliac bones and femoral heads.

Pelvic computed tomography (CT) and magnetic resonance imaging depicted multiple iliac and sacral osteolytic lesions with fluid-fluid levels (Figures 1 and 2). Furthermore, a right retrothyroid heterogeneous vascularized mass was evident on cervical ultrasound and CT images (Figure 3).

Blood serum analysis identified increased levels of calcium (12.7 mg/dL after correction for albumin), parathyroid hormone (1264.4 pg/mL), and alkaline phosphatase (614 U/L). Hypophosphatemia (2 mg/dL) was noted as well.

## DIAGNOSIS

In summary, our patient had multiple osteolytic lesions with fluid-fluid levels, hyperparathyroidism, and a vascularized heterogeneous retrothyroid mass. Bone lytic lesions with fluid-fluid levels—and especially, multiple lesions—are an infrequent finding rarely reported in the medical literature. Possible causes include metastatic carcinoma, Langerhans cell histiocytosis, and brown tumors associated with hyperparathyroidism.<sup>1-3</sup>

The combination of a retrothyroid mass and hyperparathyroidism suggested the existence of a benign or malignant lesion of the parathyroid gland with autonomous parathyroid hormone production. A presumptive diagnosis of primary hyperparathyroidism and multiple brown tumors due to a functional parathyroid mass was considered. At this point, parathyroid carcinoma could not be excluded. The

patient was referred to the endocrine surgery team, and a right-sided hemithyroidectomy and isthmectomy with central cervical lymphadenectomy was performed, per the recommendation of international oncologic guidelines.<sup>4</sup> A pathology examination showed an atypical parathyroid adenoma (Figure 4).

## MANAGEMENT

Atypical parathyroid adenomas are benign lesions with some features that are characteristic of parathyroid carcinoma, such as band fibrosis and high mitotic rate. However, unlike malignant parathyroid lesions, neither vascular nor neural invasion is present at histological analysis.<sup>5</sup> The treatment is surgery, which is often curative. Still, it is uncertain whether atypical parathyroid adenomas can degenerate into carcinoma, so patients should be closely followed.<sup>4,6</sup>

Brown tumors, also known as osteitis fibrosa cystica, occur in response to hyperparathyroidism. Increased serum levels of parathyroid hormone lead to high bone turnover followed by tissue fibrosis. In certain areas, well-circumscribed osteolytic lesions, or brown tumors, are formed. Some of these tumors are hemorrhagic.<sup>7</sup> The serial intralesional deposition of blood creates the radiologic effect of fluid-fluid levels seen on CT and MRI, as was noted on our patient's images.<sup>8</sup>

The treatment of brown tumors requires resolution of hyperparathyroidism and increased oral intake of calcium and vitamin D. This therapeutic strategy is designed to enhance the overall bone mass and to recalcify osteolytic lesions.<sup>9</sup> However, despite this effort to build bone, fracture risk remains high.<sup>10</sup>

Our patient's pain was adequately controlled 2 days after admission. During the perioperative period, her parathyroid hormone level was closely monitored, and calcium was administered to prevent hungry bone syndrome, where sudden severe hypocalcemia may ensue due to an acute drop in parathyroid hormone.<sup>11</sup> After an uneventful postoperative period, she was discharged home with a normal parathyroid hormone level. She was instructed to continue taking oral calcium and vitamin D. Unfortunately, she missed her clinical appointments and was lost to follow-up.

## References

1. Frenzel L, Javier RM, Eichler F, Zollner G, Sibia J. Multiple fluid-filled bone metastases. *Joint Bone Spine*. 2010;77:171-173.

2. Hindman BW, Thomas RD, Young LW, Yu L. Langerhans cell histiocytosis: unusual skeletal manifestations observed in thirty-four cases. *Skeletal Radiol.* 1998;27:177-181.
3. Hong WS, Sung MS, Chun KA, et al. Emphasis on the MR imaging findings of brown tumor: a report of five cases. *Skeletal Radiol.* 2011;40:205-213.
4. Wei CH, Harari A. Parathyroid carcinoma: update and guidelines for management. *Curr Treat Options Oncol.* 2012;13:11-23.
5. DeLellis RA. Parathyroid tumors and related disorders. *Mod Pathol.* 2011;24 Suppl 2:S78-93.
6. McCoy KL, Seethala RR, Armstrong MJ, et al. The clinical importance of parathyroid atypia: is long-term surveillance necessary? *Surgery.* 2015;158:929-936.
7. Davies AM, Evans N, Mangham DC, Grimer RJ. MR imaging of brown tumour with fluid-fluid levels: a report of three cases. *Eur Radiol.* 2001;11(8):1445-1449.
8. Hudson TM, Hamlin DJ, Fitzsimmons JR. Magnetic resonance imaging of fluid levels in an aneurysmal bone cyst and in anticoagulated human blood. *Skeletal Radiol.* 1985;13:267-270.
9. Agarwal G, Mishra SK, Kar DK, et al. Recovery pattern of patients with osteitis fibrosa cystica in primary hyperparathyroidism after successful parathyroidectomy. *Surgery.* 2002;132:1075-1083.
10. Khosla S, Melton LJ, 3rd, Wermers RA, Crowson CS, O'Fallon W, Riggs BI. Primary hyperparathyroidism and the risk of fracture: a population-based study. *J Bone Miner Res.* 1999;14(10):1700-1707.
11. Witteveen JE, van Thiel S, Romijn JA, Hamdy NA. Hungry bone syndrome: still a challenge in the post-operative management of primary hyperparathyroidism: a systematic review of the literature. *Eur J Endocrinol.* 2013;168:R45-53.

### [Figure captions]

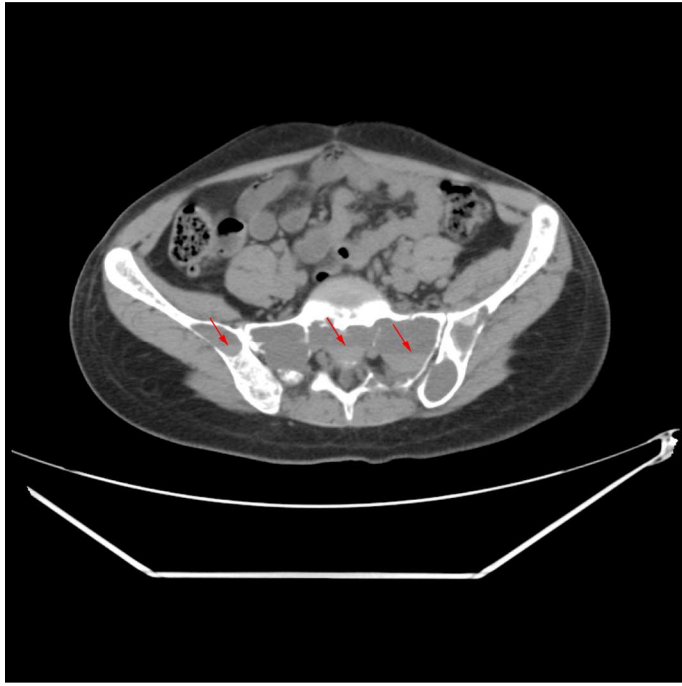
Figure 1. This unenhanced axial computed tomography (CT) image of the pelvis showed multiple lytic bone lesions with fluid-fluid levels (arrows).



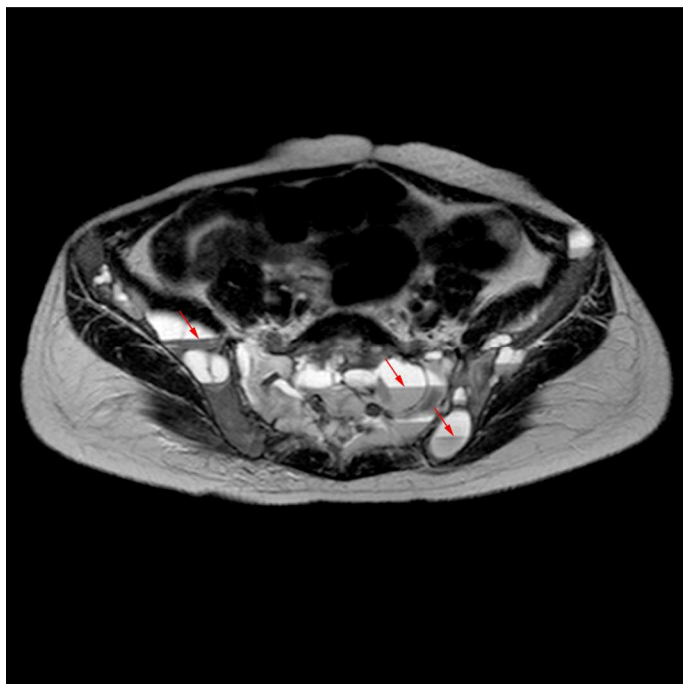
Figure 2. Multiple lytic bone lesions with fluid-fluid levels (arrows) were also evident in this unenhanced axial magnetic resonance image of the pelvis.

Figure 3. A contrast-enhanced coronal cervicothoracic CT image revealed a vascularized heterogeneous and well-circumscribed right retrothyroid mass (arrow).

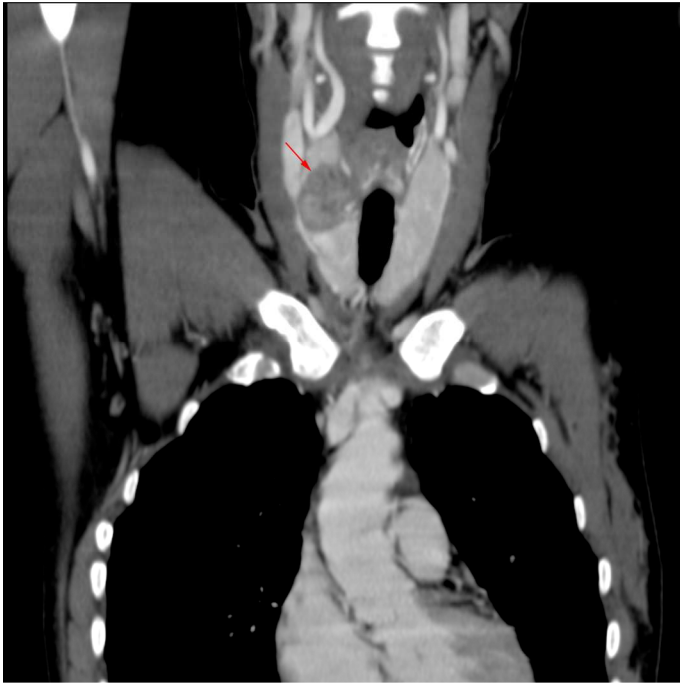Figure 4. The patient had an atypical adenoma of the parathyroid gland (A). Banding fibrosis (B) adhered to the tumor, adjacent soft tissues, and the thyroid (C) (hematoxylin and eosin, 20x).



ACCEPTED MANUSCRIPT



ACCEPTED MANUSCRIPT



ACCEPTED MANUSCRIPT

