



## **Health Effects of Patagial Wing Tags in Red Kites (*Milvus milvus*) in the UK**

Authors: Vecchiato, Marco, Sentenac, Hugo, Jaffe, Jenny E., and Sainsbury, Anthony W.

Source: Journal of Wildlife Diseases, 60(3) : 714-720

Published By: Wildlife Disease Association

URL: <https://doi.org/10.7589/JWD-D-23-00011>

---

BioOne Complete ([complete.BioOne.org](https://complete.BioOne.org)) is a full-text database of 200 subscribed and open-access titles in the biological, ecological, and environmental sciences published by nonprofit societies, associations, museums, institutions, and presses.

Your use of this PDF, the BioOne Complete website, and all posted and associated content indicates your acceptance of BioOne's Terms of Use, available at [www.bioone.org/terms-of-use](https://www.bioone.org/terms-of-use).

Usage of BioOne Complete content is strictly limited to personal, educational, and non - commercial use. Commercial inquiries or rights and permissions requests should be directed to the individual publisher as copyright holder.

---

BioOne sees sustainable scholarly publishing as an inherently collaborative enterprise connecting authors, nonprofit publishers, academic institutions, research libraries, and research funders in the common goal of maximizing access to critical research.

## Health Effects of Patagial Wing Tags in Red Kites (*Milvus milvus*) in the UK

Marco Vecchiato,<sup>1,2,4</sup> Hugo Sentenac,<sup>1,2,3</sup> Jenny E. Jaffe,<sup>1</sup> and Anthony W. Sainsbury<sup>1</sup> <sup>1</sup>Institute of Zoology, Zoological Society of London, Regent's Park, Outer Circle, London NW1 4RY, UK; <sup>2</sup>Royal Veterinary College, Hawkshead Lane, Hatfield, Hertfordshire AL9 7TA, UK; <sup>3</sup>Centre de Recherche sur la Biodiversité et l'Environnement (CRBE), Université de Toulouse, CNRS, IRD, Toulouse INP, Université Toulouse 3—Paul Sabatier (UT3), 118 route de Narbonne, 31062 Toulouse Cedex 9, France; <sup>4</sup>Corresponding author (email: mvecchiato@hotmail.com)

**ABSTRACT:** Patagial wing tags are commonly used for identification of Red Kites (*Milvus milvus*) for postrelease monitoring, as they are easy to apply, affordable, permanent, and are apparently safe. The Red Kite was successfully reintroduced in the UK in the second half of the 20th century and postrelease health surveillance has been achieved through radio and satellite tracking, monitoring nest sites, and pathologic investigation of Red Kites found dead. This study reports on pathologic findings associated with the use of patagial wing tags in three of 142 (2.1%) wing-tagged Red Kites examined postmortem since the beginning of the reintroduction project in 1989. In these three Red Kites the presence of the patagial wing tags was associated with inflammatory lesions. Further surveys of the potential short- and longer-term negative effects of patagial wing tags on Red Kites and other birds are advocated; the future use of patagial wing tags in raptors should be carefully monitored.

**Key words:** Free-ranging wildlife, marking device, passive surveillance, patagium, Red Kite, skin lesion.

The Red Kite (*Milvus milvus*) is a diurnal member of the Accipitridae recently reclassified from Near Threatened to Least Concern by the International Union for Conservation of Nature Red List as the decline of the European metapopulation has been compensated in recent years (BirdLife International 2015, 2021). At the end of the 19th century, the Red Kite became extinct in England and Scotland because of human persecution (Smart et al. 2010). A successful collaborative reintroduction program initiated in 1989 has revived the species (Mattsson et al. 2022). The Disease Risk Analysis and Health Surveillance (DRAHS) team at the Institute of Zoology (IoZ), Zoological Society of London (ZSL) conducted postrelease health surveillance through postmortem examinations (PMEs) of Red Kites found dead, a recommended component of work to assess the success of reintroductions.

The patagial (wing) tag used for Red Kite monitoring in the UK is a piece of waterproof textile wrapped around the leading edge of the wing and fastened to the patagium by piercing the skin and securing the tag with a plastic eyelet and plastic rivet (Wallace et al. 1980; Stiehl 1983; Fig. 1). This type of marking is preferred among many others used on free-living wild birds (Murray and Fuller 2000; Varland et al. 2007) as these tags are inexpensive, easily applied, and long lasting (Kochert et al. 1983). More important, they have proved to be a valuable tool for scientists to identify birds and to monitor their behavior and biology for long-term studies and surveillance programs (Smallwood and Natale 1998; Murray and Fuller 2000; Varland et al. 2007). The existing guidelines should be followed with great care in applying these wing tags, as piercing bones, muscles, tendons, and blood vessels must be avoided (Smallwood and Natale 1998; Varland et al. 2007).

Some studies have previously linked patagial tags with skin abrasion (Calvo and Furness 1992; Varland et al. 2007), increased mortality (Martin and Major 2010), and other adverse effects at a population level, such as mating and breeding interference (Smallwood 2016). Other studies have reported no negative effects (Kochert et al. 1983; Smallwood and Natale 1998). In raptors, these tags have been associated with open wounds in Peregrine Falcons (*Falco peregrinus*) and Prairie Falcons (*Falco mexicanus*; Sherrod et al. 1982; Kochert et al. 1983). A recent study reported mild to severe skin abrasions and inability to fly in Cape Vultures (*Gyps coprotheres*) after improper placement of patagial tags and provided precise guidelines to ensure safe tagging in this species by avoiding all vital structures of the wing (Hirschauer et al. 2019). Clearly the use of patagial markers needs careful consideration as these markers

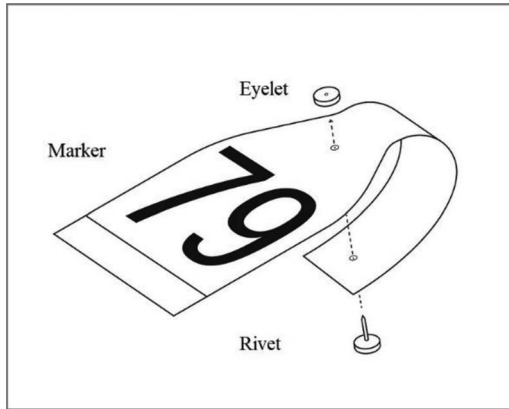


FIGURE 1. Technical drawing of a wraparound wing tag such as the ones used for marking Red Kites (*Milvus milvus*) in the UK.

may affect the health and welfare of individual birds (Kochert et al. 1983; Calvo and Furness 1992; Murray and Fuller 2000; Varland et al. 2007). No adverse effects associated with wing tags have previously been reported in Red Kites.

After observing a suspected chronic necrotic dermatitis associated with patagial tags in Red Kite 1 (case 188/19), found dead in 2018, we reviewed the pathologic findings from 335 Red Kites found dead and submitted to DRAHS and ZSL, 1989–2019 inclusive. Postmortem examinations were conducted following a standardized protocol, including systematic inspection of external and internal organs, combined with routine sampling and additional diagnostic tests depending on gross findings (Molenaar et al. 2017). Tissues of lesions suitable for histopathology (case 188/19) were fixed in 10% buffered formalin. After fixation, the specimen was sectioned and stained with hematoxylin and eosin for microscopic examination. Of 142 Red Kites with patagial wing tags, two individuals had associated wing lesions.

Red Kite 1, which had been tagged as a fledgling in 2004, was found dead on a footpath on 31 August 2018 in Deene, Northamptonshire, received at IoZ on 11 September 2018, and immediately frozen at  $-20\text{ C}$  until examination on 13 September 2018. This adult female was carrying a patagial tag on each wing (Fig. 2). The carcass weighed 918.6 g (adult female range 800–1,300 g; Snow et al. 1998) and was deemed



FIGURE 2. Patagial wing tags removed from left wing (white) and right wing (yellow) of a Red Kite (*Milvus milvus*) designated Red Kite 1, found in Deene, Northamptonshire, UK, September 2018.

“fresh.” Feathers located between the patagial tags and the skin on the dorsal surface of both wings were matted with dried serosanguinous fluids. On the dorsal and ventral skin surfaces of both wings, between the patagial tag and skin, there were locally extensive, poorly demarcated, dark green to black malodorous friable skin lesions; the texture of the skin in these areas was wet and slimy. The lesions extended along the right wing from the proximal third of the radius–ulna to the carpal joint for approximately 130 mm, and along approximately 65 mm of the proximal shaft of the radius–ulna on the left wing. On the latter area, the skin was ruptured, and hundreds to thousands of dipterous eggs were present in the underlying tissue, which also appeared black (Fig. 3). The skull showed a complete, semicircular fracture of the parietal bone extending from the left to the right orbit. Internally, the orbital wall was fractured, and the subcutaneous tissues overlying the skull fracture were hemorrhagic. The esophagus contained organic material resembling the intestines and a claw of a small bird.

Histopathology of the lesioned skin of both wings was hindered by a moderate to severe

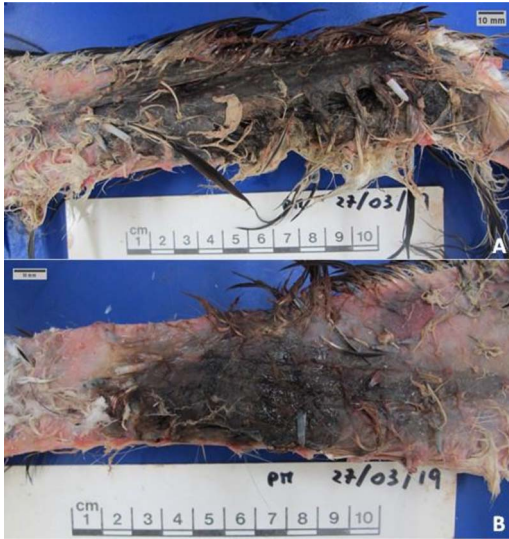

FIGURE 3. Red Kite 1 (*Milvus milvus*) found in Deene, Northamptonshire, UK, September 2018. (A) Dorsal view of the right wing showing poorly demarcated and friable skin lesions under the patagial wing tag, extending from the distal third of the radius-ulna to the carpal joint on the dorsal aspect of the right wing. The tag was removed from the wing and the feathers plucked. (B) Dorsal view of left wing showing a skin lesion under the patagial wing tag on the dorsal aspect of the left wing. The tag was removed from the wing and the feathers plucked.

degree of autolysis and many degenerated parasites (interpreted as the fly larvae seen on gross pathology). Areas of skin with only moderate autolysis showed a nonspecific mild mononuclear inflammatory infiltrate.

The organic content found in the upper gastrointestinal tract indicated that the animal had eaten shortly before death, whereas the skull fracture is consistent with an acute, severe, fatal traumatic event. Collision is the probable etiology and is commonly described as a cause of mortality in Red Kites (Wildman et al 1998; BirdLife International 2021). The marked macroscopic changes to the wings in contrast with the condition of the other organs and tissues suggested that the wing lesions had developed before death. The black coloration and the presence of serosanguinous fluids on the left wing are suggestive of inflammation, recent hemorrhage, and potentially a necrotic process (King et al. 2013). It is unclear whether this suspected disease process may have affected the bird's

ability to escape from a potentially dangerous situation, such as an imminent collision.

Red Kite 2 (case 112/03) was found entangled in a wire fence on 1 February 2003 in Harewood Yard, Harewood, near Leeds, Yorkshire, UK. According to the submitter—a project officer of the Yorkshire Red Kite project—the bird had flown into the wire-mesh fencing (a “pig wire” with a mesh of around 100–120 mm<sup>2</sup>) while flying out and low from a piece of woodland, and the right wing tag appeared to have been caught in the fence. The carcass was submitted on 3 February 2003 and was refrigerated at IoZ until PME on 5 February 2003. It was then archived at –20 C and defrosted for re-examination on 25 June 2019. This juvenile bird, of undetermined sex because of autolysis, was carrying patagial tags on both wings. It weighed 755 g and was emaciated. The reviewed PME report described a wing laceration approximately 100 mm long on the leading edge of the right patagium, with the wound and the related flank covered in dried blood. This was believed to have been associated with death, possibly in addition to shock and dehydration. During the re-examination, the feathers surrounding this lesion were plucked, revealing a locally extensive, poorly demarcated severe black skin lesion, and suspected subcutaneous hemorrhage both dorsally and ventrally. On the dorsal aspect, the lesion extended on the right wing for approximately 41 mm on the distal third of the radius-ulna. Ventrally, the right wing showed a similar focal area of suspected necrosis, measuring 28 × 15 mm. On the left wing, the tag covered a locally extensive, firm, raised black skin lesion surrounding the identified piercing wound from the patagial tag's rivet pin, which extended for approximately 25 × 14.5 mm on the dorsal aspect and had a diameter of 10 mm ventrally (Fig. 4).

On the first examination, no clear evidence was found that suggested a link between the presence of the wing tag and the laceration, and it remained uncertain whether the poor body condition might have contributed to hitting the fence and being unable to escape, or whether the injuries contributed to death. The laceration was in the same area of the right wing as the



FIGURE 4. Red kite 2 (*Milvus milvus*) found at Harewood, near Leeds, Yorkshire, UK, February 2003. (A) Ventral view of the leading edge of the right patagium on the right wing. On the left, the white textile of the tag secured on the wing by the plastic rivet; centrally, an accumulation of dried blood overlying the apparent recent skin laceration. (B) Site of the laceration on the leading edge of the patagium on the dorsal aspect of the right wing after removal of the patagial wing tag and plucking of the feathers. Centrally, an accumulation of dried blood. (C) Focal dark-black skin lesion, suspected subcutaneous hemorrhage (thick arrow) and reddening skin (thin arrow) on the ventral aspect of the patagium of the right wing. The wing tag was displaced laterally on the left of the picture and the feathers plucked. (D) Locally extensive firm black skin lesion (double arrow) below the piercing hole (single arrow) of the patagial wing tag, dorsally on the left wing. The tag was removed and the feathers plucked. (E) Locally extensive skin lesion around the piercing hole (arrow) of the patagial wing tag, ventrally on the left wing. The tag was removed and the feathers plucked.

apparently chronic lesion associated with the patagial tag, but it was not known if the pre-existing lesion increased the susceptibility of the Red Kite to develop the laceration.

Red Kite 3 (case 52/11) was found dead on 16 January 2011 in a grazed field near Sawrey (Cumbria, UK) with nothing suspicious at the site. The carcass arrived at IoZ on 26 January

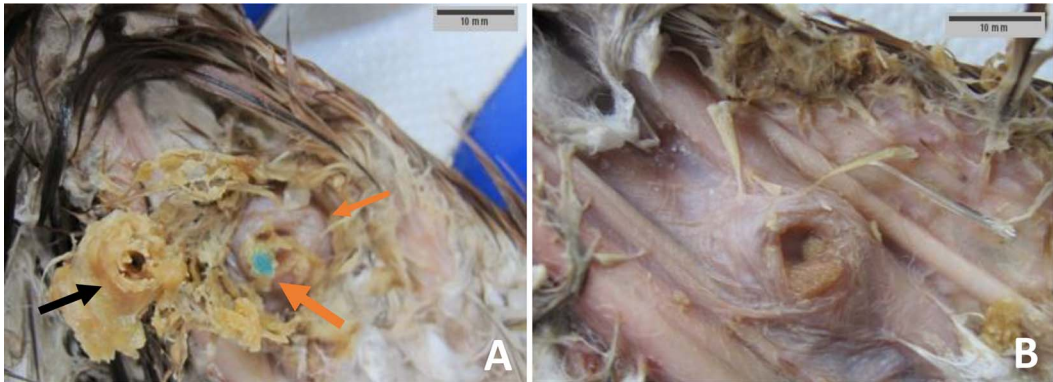


FIGURE 5. Red Kite 3 (*Milvus milvus*) found near Sawrey (Cumbria, UK), January 2011. (A) Ventral aspect of the right wing after the accumulation of dry, paste-like yellowish material (black arrow) was dislodged from the underlying skin and the segment of the patagial wing tag (thick orange arrow), revealing focal circular raised area of pink-colored skin (thin orange arrow) surrounding the piercing hole for the tag. (B) Focal circular raised and marked pink-colored lesion surrounding the piercing hole of the patagial wing tag on the ventral aspect of the right wing after removal of all paste-like yellow material.

2011 and the PME was performed on the same day. This subadult Red Kite was in good body condition, weighed 1,020 g, and had severe signs of autolysis, which hindered sex determination. A re-examination was performed on 25 June 2019 because the PME report included a note regarding missing feathers and evidence of skin excoriation over the right lateral aspect of the midright ulna.

On re-examination, the feathers on the ventral surface of the right wing between the wing tag and the skin were matted with dry, paste-like yellowish material. The skin in this area showed a focal, circular, raised, demarcated pink lesion surrounding the area where the patagium was pierced by the tag's rivet (Fig. 5). The factors contributing to death were undetermined.

The macroscopic findings in these three cases were suggestive of localized inflammation of the wing tissues, probably causing a certain degree of discomfort. The noted accumulation of exudate commonly derives from a proliferative response of the immune system (Smits et al. 1999; Martin et al. 2006) that in birds may clinically show with the presence of dried yellow, caseous debris (Montali 1988; Huchzermeyer and Cooper 2000; Schmidt et al. 2003). Similarly, any tissue trauma, such as that caused by a plastic rivet piercing the wing web of a raptor, may result in chemotaxis of leukocytes.

The wing tag-associated lesions that we describe were not considered the primary cause of death in any of the three cases, although they would have been painful and a stressor for the kites and therefore are of concern. In Red Kite 1 the black coloration of the left-wing skin and presence of serosanguinous fluids were suggestive of inflammation associated with the wing tag, as confirmed on histopathology. In Red Kite 2 there were gross signs of inflammation associated with the wing tag that appeared to have predated the laceration of the patagial skin. In Red Kite 3 there was an accumulation of caseous exudate on the skin in association with the patagial wing tag.

Although negative effects of patagial tags appear to be rare in Red Kites—we detected lesions associated with the use of patagial tags in three of 142 (2.1%) reintroduced Red Kites fitted with these marking devices in England, and no such lesions have been reported previously—some cases may go unnoticed because the scanning surveillance method adopted cannot detect all Red Kites that die. It may be possible to gain a better understanding of the magnitude of the effects of these markers by collaborating with stakeholders in the avian health and management fields, using existing networks more effectively to gather long-term information on the health effects of tags in live birds. Hazard-specific surveillance (Hoinville

et al. 2013) might improve early detection of lesions, reducing stress and avoidable pain, improving the welfare of Red Kites, and we would encourage those commencing new wing-tagging projects in Red Kites to investigate options. Monitoring data on wing-tagged versus ringed Red Kites might help determine if life expectancy differs significantly between birds tagged in the different manners and may also help clarify if deployment length is a risk factor for developing wing tag-related lesions, as is the case for harness-mounted radiotransmitters (Peniche et al. 2011).

This work was undertaken as part of a partnership between Natural England and the ZSL. We thank Julia Rodriguez-Ramos Fernandez for the histopathologic examination performed and helpful comments on the lesions. Thanks to Inez Januszczak for her assistance in the pathologic examinations of the Red Kites and the upkeep of the database used for this review. Thanks to all the concerned individuals who took the trouble to submit the Red Kites found dead. In particular, we thank Doug Simpson for the detailed submission of the Red Kite 2 and to the East Midlands Red Kite Monitoring Group who submitted Red Kite 1, which led to this study. A component of this study (findings relative to Red Kite 1) was carried out in fulfilment of the Wild Animal Health MSc degree (H.S.) at the Royal Veterinary College and the ZSL.

#### LITERATURE CITED

- BirdLife International. 2015. *European Red List of birds*. Office for Official Publications of the European Communities. [https://datazone.birdlife.org/userfiles/file/Species/erlob/EuropeanRedListOfBirds\\_June2015.pdf](https://datazone.birdlife.org/userfiles/file/Species/erlob/EuropeanRedListOfBirds_June2015.pdf). Accessed January 2024.
- BirdLife International. 2021. *European Red List of birds*. Office for Official Publications of the European Communities. <https://www.birdlife.org/wp-content/uploads/2022/05/BirdLife-European-Red-List-of-Birds-2021.pdf.pdf>. Accessed January 2024.
- Calvo B, Furness RW. 1992. A review of the use and the effects of marks and devices on birds. *Ringing Migr*. 13:129–151.
- Hirschauer MT, Wolter K, Forbes NA. 2019. A review of vulture wing anatomy and safe proapatagial tag application methods, with case studies of injured vultures. *J Wildl Rehabil* 39:7–13.
- Hoinville LJ, Alban L, Drew JA, Gibbens JC, Gustafson L, Häslner B, Saegerman C, Salman M, Stärk KDC. 2013. Proposed terms and concepts for describing and evaluating animal-health surveillance systems. *Preve Vet Med* 112:1–12.
- Huchzermeyer FW, Cooper JE. 2000. Fibrinosis, not abscess, resulting from a localised inflammatory response to infection in reptiles and birds. *Vet Rec* 147:515–517.
- King JM, Roth-Johnson L, Dodd DC, Newsom ME. 2013. *The necropsy book: A guide for veterinary students, residents, clinicians, pathologists and biological researcher*. 7th Ed. Cornell University, Ithaca, New York, 248 pp.
- Kochert MN, Steenhof K, Moritsch MQ. 1983. Evaluation of patagial markers for raptors and ravens. *Wildl Soc Bull* 11:271–281.
- Martin LB II, Han P, Lewittes J, Kuhlman JR, Klasing KC, and Wikelski M. 2006. Phytohemagglutinin-induced skin swelling in birds: Histological support for a classic immunoeological technique. *Funct Ecol* 20:290–299.
- Martin JM, Major RE. 2010. The use of cattle ear-tags as patagial markers for large birds—A field assessment on adult and nestling Australian White Ibis. *Waterbirds* 33:264–268.
- Mattsson BJ, Mateo-Tomás P, Aebischer A, Rösner S, Kunz F, Schöll EM, Åkesson S, De Rosa D, Orr-Ewing D, et al. 2022. Enhancing monitoring and transboundary collaboration for conserving migratory species under global change: The priority case of the red kite. *J Environ Manage* 317:115345.
- Molenaar FM, Jaffe JE, Carter I, Barnett EA, Shore RF, Rowcliffe MJ, Sainsbury AW. 2017. Poisoning of reintroduced red kites (*Milvus Milvus*) in England. *Eur J Wildl Res* 63:94.
- Montali RJ. 1988. Comparative pathology of inflammation in the higher vertebrates (reptiles, birds and mammals). *J Comp Pathol* 99:1–26.
- Murray DL, Fuller MR. 2000. A critical review of the effects of marking on the biology of vertebrates. In: *Research techniques in animal ecology: Controversies and consequences*. Boitani L, Todd KF, editors. Columbia University Press, New York, New York, pp. 15–64.
- Peniche G, Vaughan-Higgins R, Carter I, Pocknell A, Simpson D, Sainsbury AW. 2011. Long-term health effects of harness mounted radio transmitters in red kites (*Milvus milvus*) in England. *Vet Rec* 169:311.
- Schmidt RE, Reavill DR, Phalen DN. 2003. *Pathology of pet and aviary birds*. 1st Ed. Iowa State Press, Ames, Iowa, pp. 177–195.
- Sherrod SK, Heinrich WR, Burnham WA, Barclay JH, Cade TJ. 1982. *Hacking: A method for releasing peregrine falcons and other birds of prey*. 2nd Ed. The Peregrine Fund, Inc., Fort Collins, Colorado, 52 pp.
- Smallwood JA. 2016. Effects of researcher-induced disturbance on American kestrels breeding in nest boxes in Northwestern New Jersey. *J Raptor Res* 50:54–59.
- Smallwood JA, Natale C. 1998. The effect of patagial tags on breeding success in American kestrels. *North Am Bird Bander* 23:73–78.
- Smart J, Amar A, Sim IMW, Etheridge B, Cameron D, Christie G, Wilson JD. 2010. Illegal killing slows population recovery of a reintroduced raptor of high conservation concern—The red kite *Milvus milvus*. *Biol Conserv* 143:1278–1286.

- Smits JE, Bortolotti GR, Tella JL. 1999. Simplifying the phytohaemagglutinin skin-testing technique in studies of avian immunocompetence. *Funct Ecol* 13:567–572.
- Snow DW, Perrins CM, Gillmor R. 1998. *The birds of the Western Palearctic, Concise Edition*. Oxford University Press, Oxford, UK, 1740 pp.
- Stiehl RB. 1983. A new attachment method for patagial tags. *J Field Ornithol* 54:326–328.
- Varland D, Smallood JA, Young LS, Kochert MN. 2007. Marking techniques. In: *Raptor research and management techniques*. Bird DM, Bildstein KL, editors. Hancock House Publishers Ltd., Surrey, British Columbia, Canada, pp. 221–236.
- Wallace MP, Parker PG, Temple SA. 1980. An evaluation of patagial markers for cathartid vultures. *J Field Ornithol* 51:309–428.
- Wildman L, O'Toole L, Summers RW. 1998. The diet and foraging behaviour of the red kite in northern Scotland. *Scot Birds* 19:134–140.
- Submitted for publication 26 January 2023.*  
*Accepted 15 January 2024.*