Ophthalmol Ther
https://doi.org/10.1007/s40123-024-00902-5

ORIGINAL RESEARCH

Additional Guidance on the Use of the PRESERFLO™ MicroShunt in the Treatment of Glaucoma: Insights from a Second Delphi Consensus Panel

Anthony P. Khawaja · Luís Abegão Pinto · Ingeborg Stalmans · Florent Aptel · Anna Barkander · Keith Barton · Henny Beckers · Milko Iliev · Thomas Klink · Giorgio Marchini · Jose Martínez de la Casa · Karin R. Pillunat · Jan H. Simonsen · Clemens Vass

Received: November 16, 2023 / Accepted: January 29, 2024

ABSTRACT

Introduction: The PRESERFLO™ MicroShunt (PMS) has been proven to significantly lower intraocular pressure (IOP) in patients with glaucoma and has been available for use since 2019. With increasing published evidence and growing experience of glaucoma surgeons, the aim of this modified Delphi panel was to build on the findings of a previous Delphi panel conducted in 2021 and provide further guidance on the role of the PMS to treat patients with glaucoma in Europe.

Methods: Thirteen European glaucoma surgeons experienced in the PMS procedure participated in a 3-round modified Delphi panel. A targeted literature review and expert steering committee guided Round 1 questionnaire development. Consensus was pre-defined at a threshold of ≥ 70% of panellists selecting 'strongly agree'/'agree' or 'strongly disagree'/

Supplementary Information The online version contains supplementary material available at https://doi.org/10.1007/s40123-024-00902-5.

A. P. Khawaja (✉) · K. Barton
NIHR Biomedical Research Centre, Moorfields Eye Hospital NHS Foundation Trust and UCL Institute of Ophthalmology, London, UK
e-mail: anthony.khawaja@ucl.ac.uk

L. Abegão Pinto
Department of Ophthalmology, Hospital Santa Maria, Lisbon, Portugal

I. Stalmans
Department of Ophthalmology, University Hospitals UZ Leuven, Leuven, Belgium

I. Stalmans
Research Group Ophthalmology, Catholic University KU Leuven, Leuven, Belgium

F. Aptel
Clinique Universitaire d'Ophtalmologie, CHU de Grenoble-Alpes, Grenoble, France

A. Barkander
Department of Ophthalmology, Östersund Hospital, Östersund, Sweden

H. Beckers
University Eye Clinic, Maastricht University Medical Center+, Maastricht, The Netherlands

M. Iliev
Ophthalmology Department, University of Bern, Inselspital, Bern, Switzerland

T. Klink
Herzog Carl-Theodor Eye Hospital, Munich, Germany

G. Marchini
Department of Neurosciences, Biomedicine and Movement, Eye Clinic and UOC Oculistica, University Hospital and AOUI, Verona, Italy

J. Martínez de la Casa
Hospital Universitario Clinico San Carlos, Madrid, Spain

Published online: 08 April 2024

'disagree' for 6-point Likert scale questions or ≥ 70% selecting the same option for multiple or single-choice questions. Questions not reaching consensus were restated/revised for the next round, following guidance from free-text responses/scoping questions.

Results: In total, 28% (n = 9/32), 52% (n = 16/31) and 91% (n = 10/11) of statements reached consensus in Rounds 1, 2 and 3, respectively. There was agreement that the PMS may be used in patients with pigmentary, post-trauma or post-vitrectomy glaucoma and for patients with uveitic glaucoma without active inflammation. The PMS may be more suitable for patients with contact lenses than other subconjunctival filtering surgeries, without eliminating bleb-associated risks. Consensus was reached that combining PMS implantation and phacoemulsification may be as safe as standalone PMS surgery, but further efficacy data are required. Following a late rise in IOP ≥ 4 months post-surgery, topical aqueous suppressant drops or bleb revision may be suitable management options.

Conclusions: This Delphi panel builds on the considerations explored in the 2021 Delphi panel and provides further detailed guidance for glaucoma surgeons on the use of the PMS, reflecting the availability of novel evidence and surgical experience.Videos are available for this article.

Keywords: Consensus; MIGS; Glaucoma; MicroShunt; PRESERFLO™; Intraocular pressure; Glaucoma surgery

Key Summary Points

Why carry out this study?

The implantation of the PRESERFLO™ MicroShunt (PMS) device has been shown to significantly lower intraocular pressure (IOP) in patients with glaucoma, with fewer follow-up appointments and instances of hypotony compared with trabeculectomy.

An original Delphi panel conducted in 2021 sought to establish consensus on the use of the PMS, providing initial overarching guidance and comparison of approach to trabeculectomy.

Based on the availability of new evidence and increased real-world experience with the PMS, it is important to revisit statements that did not previously reach consensus to provide more detailed guidance on the use of the PMS.

What was learned from the study?

The expert panel of glaucoma surgeons were largely aligned on further guidance for the use of the PMS for patients with glaucoma in Europe.

Consensus was reached on additional types of glaucoma in which the PMS may be suitable for use, in addition to providing additional information on best practice approaches. The Delphi panel also highlights areas for future research to further strengthen the evidence base for the PMS.

K. R. Pillunat
Department of Ophthalmology, Medical Faculty Carl Gustav Carus, Technical University, Dresden, Germany

J. H. Simonsen
Department of Ophthalmology, Aalborg University Hospital, Aalborg, Denmark

C. Vass
Department of Ophthalmology and Optometry, Medical University Vienna, Vienna, Austria

DIGITAL FEATURES

This article is published with digital features, including videos, to facilitate understanding of the article. To view digital features for this article, go to https://doi.org/10.6084/m9.figshare.25055621.

INTRODUCTION

Glaucoma is the leading cause of irreversible blindness worldwide [1]. Lowering intraocular pressure (IOP) remains the only proven treatment for glaucoma [1]. While IOP-lowering medication or laser trabeculoplasty represent first-line treatment for glaucoma, surgery is typically performed when these approaches fail to sufficiently lower IOP or prevent disease progression [2]. Common surgeries to lower IOP include trabeculectomy and aqueous shunt insertion; however, these techniques are often associated with a high burden of postoperative follow-up care [2]. Within the last decade, new surgical approaches have been developed as less invasive alternatives to lower IOP and reduce postoperative risk of adverse events [3]. However, due to the novelty of these procedures, established clinical guidance is often lacking; therefore, consensus among experienced surgeons on best surgical practice is required.

One such approach utilises the PRESERFLO™ MicroShunt (PMS; formerly known as the InnFocus MicroShunt; Santen SA), a subconjunctival glaucoma drainage device for the treatment of glaucoma, which has been available for clinical practice since 2019 [4, 5]. The PMS device may be offered when IOP-lowering medication and/or laser therapy does not, or is unlikely to achieve the target pressure [3]. The ab externo implantation of the PMS facilitates aqueous humour outflow to a filtering bleb, which collects the drained aqueous humour under the conjunctiva [6]. Research by Beckers et al. (n = 81) and Bhayani et al. (n = 91) have shown that the PMS is effective at lowering IOP [7, 8], with Pillunat et al. (n = 52) and Jamke et al. (n = 60) noting that fewer follow-up appointments are required when using the PMS compared with trabeculectomy [9, 10].

An initial Delphi panel, conducted in 2021, evaluated best practice considerations among a group of 11 surgeons with experience using the PMS for the treatment of patients with glaucoma in Europe, with the primary focus of the consensus obtained to provide useful guidance for surgeons unfamiliar with the device [11]. Since the 2021 Delphi panel was conducted, further evidence on the efficacy and safety of the device has become available. For example, recent research has suggested that the short-term efficacy and safety outcomes of the PMS are similar across primary open-angle glaucoma (POAG), pseudoexfoliative and uveitic glaucoma, and patients who are pseudophakic [8]. Studies also suggest that combining cataract surgery with PMS implantation may have similar efficacy and safety outcomes to a stand-alone PMS procedure [12]. Further evidence supports the notion that the rate of needling or bleb revision as a second surgery may be low following the PMS, providing additional data on postoperative care with the device [13].

With further PMS implantations carried out, real-world clinical experience with the PMS has progressed, allowing the opportunity to revisit and build upon previous findings to obtain further consensus on best practice recommendations for the PMS. In addition, with increasing uptake of the PMS amongst glaucoma surgeons, there is the opportunity to conduct a Delphi panel with improved representation across Europe to develop more representative consensus guidance. The aim of this Delphi panel was to leverage the latest published evidence and collective expertise of a panel of European glaucoma surgeons to expand upon the consensus reached in the 2021 Delphi panel. The results from this Delphi panel will provide more comprehensive guidance on the use of the PMS to treat patients with glaucoma.

METHODS

Delphi Panellists

Invitation to participate in the Delphi panel was sent by the sponsor (Santen SA) via email and panellists were asked to respond with confirmation of their willingness to participate. Panellists were required to be based in Europe with extensive experience treating patients with the PMS. Ten panellists from the 2021 Delphi panel and 3 additional panellists were invited to further extend representation across Europe. One panellist from the 2021 panel no longer

met the eligibility criteria because of relocation outside of Europe.

The steering committee (SC) consisted of 3 panellists (Luís Abegão Pinto, Ingeborg Stalmans, Clemens Vass) and the moderator (Anthony P. Khawaja) who were invited by the sponsor to guide the development of the statements included in each round of the Delphi panel. In addition, the moderator critically reviewed questionnaire results and supported the development of subsequent rounds, but did not vote on the consensus statements to avoid potential bias. The sponsor reviewed statements to ensure technical accuracy and regulatory compliance but did not participate in the consensus process. Ethical approval was not required as no patients were involved in the study.

Study Design

This study followed the methodology of the 2021 Delphi panel [11], consisting of 3 questionnaire rounds and a virtual consensus meeting held following Round 2 of the Delphi panel. The virtual consensus meeting enabled discussion among panellists regarding statements that had not yet reached consensus and provided additional context for statements that had already reached consensus. A bespoke web application designed to facilitate Delphi panels was used to deliver each round, enforcing key Delphi panel methodological requirements, such as anonymising participant responses and preventing retrospective amendments to a questionnaire round once opened.

Question types included Likert scale, yes-no, multiple-choice and scoping questions. Panellists were asked in Round 1 to provide free-text responses to scoping questions, which were used to gather insight and provide context that could be used to generate more specific questions in subsequent rounds. Likert statements used a 6-point scale: strongly agree, agree, slightly agree, slightly disagree, disagree or strongly disagree. For each Likert scale question, 'do not wish to answer' or 'insufficient expertise' options were also included. Panellists could further contextualise their responses by providing a free-text comment and/or suggesting a change to the statement for subsequent rounds.

Statement Development and Analysis

An updated targeted literature review (TLR) was conducted in October 2022 to collate articles on the PMS published since the 2021 Delphi panel. Literature searches were carried out in MEDLINE and Embase (simultaneously via Ovid SP). The Cochrane Library database was also searched. Searches were date-limited from 2021 (the year of the initial TLR) to present. The list of electronic databases and search terms used are presented in Supplementary Table 1. Targeted grey literature searches of professional society websites and non-peer-reviewed ophthalmology-specific websites were also carried out to identify relevant guidelines or expert opinion on the use of the PMS.

The findings from the TLR were used as a framework for the scoping call, held with the SC to determine the key objectives of the overall Delphi panel and inform the development of statements for Round 1. To build on the findings of the 2021 Delphi panel, statements were grouped into the same topics: patient selection and preoperative considerations, perioperative considerations and postoperative considerations.

All rounds were completed through the bespoke web-based application and exported directly from the platform to be analysed in Microsoft Excel.

Consensus was met when $\geq$ 70% of respondents selected 'strongly agree/agree' or 'strongly disagree/disagree' for Likert scale statements or when $\geq$ 70% of panellists selected the same option for single-choice statements. Any 'slightly agree' or 'slightly disagree' responses to Likert scale responses were considered neutral so were not included in the overall calculation of percentage of 'agreement' or 'disagreement'. Consensus for multiple-choice questions was calculated as $\geq$ 70% of panellists selecting a single response. Consensus was not measured for scoping questions or free-text responses.

Statements not achieving consensus were either removed from subsequent rounds or

rephrased following analysis and discussions with the SC. In subsequent rounds, any statements that were rephrased or restated were presented in the web-based application alongside anonymised, aggregated responses and the individual's response to the relevant statements from the previous round. In line with modified Delphi panel methodology, a virtual consensus meeting was convened following Round 2, and further guidance from the moderator and SC informed the progression of statements to Round 3 following the above approach.

RESULTS

Delphi Panel Results

The 13 panellists included in this Delphi panel had a minimum of 2 years of experience with the PMS and had completed at least 80 PMS implantations. Further information on panellists' experience with the PMS is detailed in Supplementary Table 2.

The Round 1 questionnaire was open from 31 March–13 April 2023; Round 2 was open from 26 April–3 May 2023; the virtual consensus meeting took place on 11 May 2023; Round 3 was open from 24 May–1 June 2023 (Fig. 1). All 13 panellists, including 3 members of the SC, completed each round. The moderator did not vote on the consensus statements to avoid potential bias.

A total of 57 statements were included in Round 1, of which 25 were scoping questions used to gather free-text responses from participants; consensus was not calculated for scoping questions. Of the 32 questions designed to test consensus, 9 (28%) reached consensus and 23 (72%) did not reach the consensus threshold. Round 2 included 31 statements, of which 16 (52%) reached consensus and 15 (48%) did not reach consensus. In total, 11 statements were included in Round 3, of which 10 (91%) reached consensus and 1 (9%) did not reach consensus. A summary of the key areas of consensus for patient selection and preoperative, perioperative and postoperative considerations can be found in Fig. 2.

Statements reaching consensus for patient selection and preoperative considerations are presented in Table 1; statements reaching consensus for perioperative and postoperative considerations are presented in Tables 2 and 3, respectively. The flowcharts of statement progression can be found in Supplementary

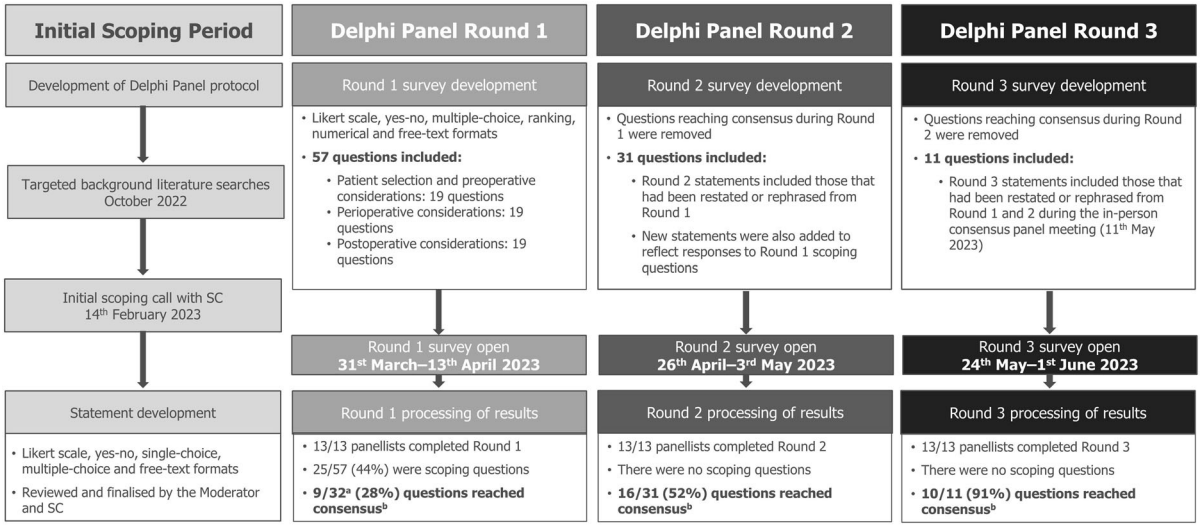

Fig. 1 Delphi panel study design. [a]The number of questions which could have possibly reached consensus in Round 1, excluding scoping questions. [b]Consensus threshold: ≥ 70% agreement or ≥ 70% disagreement for Likert statements and ≥ 70% of participants selecting the same answer for single-choice, yes-no or multiple-choice questions. *SC* steering committee

This modified Delphi panel included a group of 13 panellists experienced with the use of the PMS from across Europe, with 12 countries represented.

Participants had a minimum of two years of experience and had completed at least 80 PMS implantations

Glaucoma types	The PMS may be suitable for the following: • Pigmentary glaucoma • Post-trauma glaucoma • Post-vitrectomy glaucoma • Uveitic glaucoma without active inflammation (further evidence is required)
Patient selection and suitability	The PMS may be suitable for patients: • With POAG who have undergone a failed trabeculectomy at least six months prior • With hypermetropia (or hyperopia) provided there is sufficient anterior chamber depth (e.g. when pseudophakic) Although patient compatibility should be considered on a case-by-case basis, the PMS may be more beneficial compared with other subconjunctival drainage surgeries for patients who: • Would benefit from fewer follow-up appointments • Wear contact lenses[a] The implantation technique of the PMS may influence the decision of the surgeon to use the device, alongside the following: • A prior assessment of patient anatomical characteristics (such as anterior chamber depth or state of the conjunctiva) and preference (for instance if the patient is risk-adverse) should be carried out • Assessing the state of the conjunctiva (e.g. mobility) is especially important in patients who have undergone a failed trabeculectomy performed at least six months prior
Preoperative preparation	Preoperative medication should be prescribed on a case-by-case basis, although the following may be beneficial for a typical patient: • A course of preoperative topical steroids for 1–3 weeks (especially if the conjunctiva is hyperaemic) • Alteration of systemic anti-coagulant and anti-aggregant therapy on an individual basis, although the risks should be considered before doing so
Surgical approach	An ab externo approach in filtering surgery is important for a successful outcome Perioperative bleeding should be managed carefully: • Diathermy should be considered if persistent bleeding is present • Vasoconstrictors may be used to control bleeding in patients with hyperaemia When using the scleral marker, measurement should be taken from the blue-white transition zone for implantation Stenting of the PMS may be considered to minimise the risk of postoperative hypotony The PMS may be sutured to the sclera, especially if the PMS is not lying flat, to ensure the distal end of the PMS remains free from the Tenon's capsule The Tenon's may be sutured anteriorly either at the limbus together with the conjunctiva, or slightly posterior to the limbus as a separate closure to ensure the distal end of the PMS remains free from the Tenon's capsule A spatula may be swept posteriorly underneath the Tenon's capsule to ensure that the distal end of the PMS is not trapped The MMC concentration, duration of application and number of sponges should be used at the discretion of the surgeon and following assessment of the patient
Combined surgery	Implantation of the PMS may be combined with cataract surgery with comparable safety outcomes to a standalone PMS procedure • However, further evidence is required as to the efficacy of the combined procedure
Recovery and adverse events	The PMS allows for rapid visual recovery post-implantation The posterior position of the bleb minimises the risk of erosion of the PMS over time Corneal endothelial decompensation is an uncommon side effect one-year following implantation
Postoperative management	Postoperative medication should be prescribed on a case-by-case basis, although treatment with the following may be beneficial for a typical patient: • Steroids for at least 10 weeks or longer • Antibiotic drops Postoperative cycloplegic treatment may be considered in patients with a shallow anterior chamber If the PMS implantation does not yield the expected results in an eye with little remnant of the bleb, the next surgery of choice would be revision of the existing device • Revision surgery involves opening up of the conjunctiva and the removal or release of scar tissue to ensure the PMS is not blocked • PMS Implantation may be considered in the fellow eye of the same patient only if the factor(s) influencing the initial failure has been identified and can be avoided • Following a late rise in IOP (≥4 months after implantation), restarting topical aqueous suppressant drops or bleb revision (especially if the bleb is flat) may be suitable management choices

Fig. 2 Summary of consensus on key aspects on treating patients with glaucoma with the PMS. [a]Although suitability will be influenced by bleb morphology and require postoperative reassessment. In addition, as with all subconjunctival surgeries, there are risks associated with wearing contact lenses postoperatively. *IOP* intraocular pressure, *PMS* PRESERFLO™ MicroShunt, *POAG* primary open-angle glaucoma

Table 3, Supplementary Table 7 and Supplementary Table 10 for patient selection and preoperative, perioperative and postoperative considerations, respectively. Tables of statements deprioritised following Round 1 are captured in Supplementary Table 4, Supplementary Table 8 and Supplementary Table 11, corresponding to patient selection and preoperative, perioperative and postoperative considerations.

Patient Selection and Preoperative Considerations

Panellists agreed that treatment with the PMS may be suitable for pigmentary, post-trauma and post-vitrectomy glaucoma. In addition, the PMS may be suitable for patients with hypermetropia (or hyperopia), providing there is sufficient anterior chamber depth (e.g. when pseudophakic). Furthermore, the PMS may be suitable for patients with uveitic glaucoma without active inflammation, but further evidence is needed. When assessing patient suitability for PMS implantation, it is important to complete a technical assessment (e.g. anterior chamber depth), assess the state of the conjunctiva and determine personal preferences of the patient (e.g. aversion to risk).

Panellists agreed that implantation of the PMS is suitable for patients with POAG who have undergone a failed trabeculectomy performed at least 6 months prior and that the state of the conjunctiva plays an important role when assessing patient suitability following a failed trabeculectomy. For a typical patient undergoing PMS implantation, topical steroids prescribed 1–3 weeks prior to surgery may be beneficial, especially if the conjunctiva is hyperaemic. No consensus was reached on the optimum steroid regimen for use prior to surgery; an overview of the responses gathered is provided in Supplementary Table 5. Systemic anti-coagulant and anti-aggregant therapy may be altered prior to PMS implantation, but the risks and benefits of doing so should be considered on an individual basis. In addition, the PMS may be considered for those patients who require fewer follow-up appointments in the early postoperative period compared to traditional subconjunctival drainage surgeries for patients.

For patients who require contact lenses, panellists agreed that the PMS may be more suitable than other subconjunctival drainage surgeries because of the more posterior diffuse nature of the bleb; however, suitability will be influenced by bleb morphology and will require postoperative reassessment. It should be noted that, as with all subconjunctival drainage surgeries, there are risks associated with the patient wearing contact lenses postoperatively. Panellists agreed that the PMS implantation technique influenced their decision to use the device, with some panellists indicating that the approach is well defined, standardised and less invasive than other incisional surgeries. No consensus was reached on the regimen for pupil constrictors for typical patients undergoing PMS implantation. An overview of the responses gathered is provided in Supplementary Table 6.

Perioperative Considerations

Within the context of PMS implantation, consensus was obtained that using an ab externo approach in filtering surgery may be important for a successful outcome. Panellists also agreed that careful management of bleeding during PMS implantation is important for a successful outcome. Although there was no consensus on the frequency with which diathermy should be used during surgery, more than half of participants noted that they would always use diathermy. No participants stated that diathermy should never be used. As such, the frequency of diathermy utilisation is at the surgeon's discretion. However, consensus was obtained that diathermy should be considered when persistent bleeding is present. Furthermore, panellists agreed that vasoconstrictors may be considered for patients with hyperaemia to reduce the probability of bleeding.

In patients who are at risk of hypotony, stenting the PMS during implantation may be considered to minimise the risk of postoperative adverse events. To avoid interaction between the distal end of the PMS and Tenon's capsule, panellists agreed that the following approaches

Table 1 Statements reaching consensus on patient selection and preoperative considerations

Likert scale	Consensus agreement/ disagreement	Percentage agree/ disagree (%)	Delphi questionnaire round
Implantation of the PRESERFLO™ MicroShunt is suitable for patients with primary open-angle glaucoma who have undergone a failed trabeculectomy performed at least 6 months prior	Agreement	Agree (77) Disagree (8)	Round 1
The PRESERFLO™ MicroShunt may be suitable for patients with uveitic glaucoma without active inflammation, but further evidence is needed	Agreement	Agree (77) Disagree (0)	Round 2
The PRESERFLO™ MicroShunt may be more suitable than other subconjunctival glaucoma drainage surgeries for patients who typically wear contact lenses, but this suitability will be influenced by bleb morphology and requires postoperative reassessment[a]	Agreement	Agree (75) Disagree (0)	Round 2
The state of the conjunctiva (e.g. mobility) plays an important role in assessing patient suitability for PRESERFLO™ MicroShunt implantation following a previous trabeculectomy (performed at least 6 months prior)	Agreement	Agree (92) Disagree (8)	Round 2
For a typical patient undergoing PRESERFLO™ MicroShunt implantation, a 1–3-week course of preoperative topical steroids may be beneficial, especially if the conjunctiva is hyperaemic	Agreement	Agree (100) Disagree (0)	Round 2
The PRESERFLO™ MicroShunt may be considered for patients with hypermetropia (or hyperopia), providing there is sufficient anterior chamber depth (e.g. when pseudophakic)	Agreement	Agree (92) Disagree (0)	Round 3
The PRESERFLO™ MicroShunt may be considered for those patients who would benefit from fewer follow-up appointments in the early postoperative period compared to other subconjunctival glaucoma drainage surgeries	Agreement	Agree (77) Disagree (0)	Round 3
For patients who require contact lenses, the PRESERFLO™ MicroShunt may be more compatible than other subconjunctival glaucoma drainage surgeries due to the more posterior diffuse nature of the bleb, although suitability will be influenced by bleb morphology and require postoperative reassessment. However, as with all subconjunctival surgeries, there are risks associated with wearing contact lenses postoperatively	Agreement	Agree (85) Disagree (0)	Round 3
For a typical patient undergoing PRESERFLO™ MicroShunt implantation, systemic anti-coagulant and anti-aggregant therapy may be altered prior to surgery, but the risks and benefits of doing so should be considered on an individual basis	Agreement	Agree (85) Disagree (8)	Round 3

Table 1 continued

Likert scale	Consensus agreement/ disagreement	Percentage agree/ disagree (%)	Delphi questionnaire round
The PRESERFLO™ MicroShunt may be suitable for patients if their preoperative pressure is at the high end of the normal range[a]	Agreement	Agree (75) Disagree (0)	Round 3
Multiple choice	**Consensus**	**Percentage (%)**	**Delphi questionnaire round**
In which other forms of glaucoma would you regard the PRESERFLO™ MicroShunt to be suitable?	Pigmentary glaucoma Post-trauma glaucoma Post-vitrectomy glaucoma	Pigmentary glaucoma (92) Post-trauma glaucoma (92) Post-vitrectomy glaucoma (77) Other—please specify (31)	Round 1
Which of the following patient characteristics do you assess when determining suitability for PRESERFLO™ MicroShunt implantation?	Technical assessment Patient preference	Technical assessment (85) Patient preference (77) Age (69) Sex (0) Comorbidities (62) Wearing of contact lenses (38) Anticoagulants (69) Patient location (31) Other—please specify (31)	Round 1

Table 1 continued

Multiple choice	Consensus	Percentage (%)	Delphi questionnaire round
Which aspects of the PRESERFLO™ MicroShunt influence your decision to use the device?	Implantation technique	Implantation technique (77)	Round 1
		Material properties (54)	
		Design (38)	
		These characteristics do not influence my decision (23)	
		Other—please specify (31)	

[a]Twelve panellists' responses. Consensus was met when ≥ 70% of respondents selected 'strongly agree/agree' or 'strongly disagree/disagree' for Likert scale statements, or when ≥ 70% of panellists selected the same option for single-choice statements. Any 'slightly agree' or 'slightly disagree' responses to Likert scale statements were considered neutral and did not contribute to the categories of 'agreement' or 'disagreement'. Consensus for multiple-choice questions was calculated as ≥ 70% of panellists selecting a single response. Consensus was not measured for scoping questions or free-text responses

may be used: performing a posterior sweep of Tenon's capsule using a spatula (in addition to creating a deep pocket), suturing the implant to the sclera, especially if the PMS is not lying flat, and/or suturing Tenon's capsule anteriorly, either at the limbus together with the conjunctiva or slightly posterior to the limbus as a separate closure.

For patients with POAG who have undergone a failed trabeculectomy performed at least 6 months prior, the PMS may be implanted in the supero-temporal or supero-nasal quadrant, depending upon the conjunctival status. However, consensus was not obtained as to whether the PMS may be implanted inferiorly when no other suitable quadrants are available following a failed trabeculectomy. No consensus was reached on the mitomycin C (MMC) concentration, method of application and/or treatment duration used by panellists for a typical patient undergoing initial implantation of the PMS; however, an overview of responses is provided in Supplementary Table 9.

Panellists agreed that when using the scleral marker provided with the PMS, measurement should be taken from the blue/white transition zone, as shown in Fig. 3. Additionally, consensus was obtained that implantation of the PMS device may be combined with cataract surgery, with comparable safety to a standalone procedure. However, further evidence is required as to the efficacy of this combined procedure.

Postoperative Considerations

Panellists agreed that for postoperative management following PMS implantation in a typical patient, it may be beneficial to prescribe topical steroids for at least 10 weeks or longer and include a course of antibiotic drops. No consensus was reached on the type, frequency or exact duration of postoperative steroid or antibiotic regimens for typical patients following PMS implantation; further details on the postoperative steroid/antibiotic regimens used by the panellists can be found in Supplementary Table 12 and Supplementary Table 13, respectively. Consensus was reached that

Table 2 Statements reaching consensus on perioperative considerations

Likert scale	Consensus agreement/ disagreement	Percentage agree/ disagree (%)	Delphi questionnaire round
Using an ab externo approach in filtering surgery is important for a successful outcome	Agreement	Agree (77) Disagree (0)	Round 1
In a patient with primary open-angle glaucoma who has previously undergone a failed trabeculectomy (performed at least 6 months prior), the PRESERFLO™ MicroShunt may be implanted in the supero-temporal or supero-nasal quadrant, depending on the conjunctival status	Agreement	Agree (92) Disagree (8)	Round 2
During PRESERFLO™ MicroShunt implantation, careful management of bleeding is important for a successful surgical outcome	Agreement	Agree (92) Disagree (0)	Round 2
During PRESERFLO™ MicroShunt implantation, diathermy should be considered if persistent bleeding is present	Agreement	Agree (100) Disagree (0)	Round 2
During PRESERFLO™ MicroShunt implantation in patients with hyperaemia, vasoconstrictors may be used to reduce the probability of bleeding	Agreement	Agree (77) Disagree (8)	Round 2
Stenting of the PRESERFLO™ MicroShunt may be considered for patients at risk of hypotony to minimise postoperative adverse events	Agreement	Agree (77) Disagree (0)	Round 2
In addition to creating a deep pocket, a posterior sweep of Tenon's capsule using a spatula may be performed to ensure that the distal end of the PRESERFLO™ MicroShunt is not trapped in Tenon's capsule	Agreement	Agree (85) Disagree (0)	Round 2
As one possible measure to ensure the PRESERFLO™ MicroShunt's distal end remains free from Tenon's capsule during implantation, the implant may be sutured to the sclera, especially if the PRESERFLO™ MicroShunt is not lying flat	Agreement	Agree (92) Disagree (8)	Round 3
As one possible measure to ensure the PRESERFLO™ MicroShunt's distal end remains free from Tenon's capsule, Tenon's capsule should be sutured anteriorly either at the limbus together with conjunctiva, or slightly posterior to the limbus as a separate closure	Agreement	Agree (100) Disagree (0)	Round 3

Table 2 continued

Likert scale	Consensus agreement/ disagreement	Percentage agree/ disagree (%)	Delphi questionnaire round
It is feasible to perform cataract surgery in conjunction with PRESERFLO™ MicroShunt implantation, with comparable safety to a standalone procedure. However, further evidence is required as to the efficacy of this combined procedure	Agreement	Agree (100) Disagree (0)	Round 3
When using the scleral marker during PRESERFLO™ MicroShunt implantation, measurement should be taken from the blue-white transition zone[a]	Agreement	Agree (100) Disagree (0)	Round 3

Single choice—other	Consensus	Percentage (%)	Delphi Questionnaire Round
Do you implant an Ologen collagen matrix (OCM) alongside the PRESERFLO™ MicroShunt? If an OCM is sometimes used, please indicate what factors influence your decision to use an OCM alongside the PRESERFLO™ MicroShunt	Never	Always (0) Sometimes (15) Never (85)	Round 1

[a]Twelve panellists' responses. Consensus was met when ≥ 70% of respondents selected 'strongly agree/agree' or 'strongly disagree/disagree' for Likert scale statements, or when ≥ 70% of panellists selected the same option for single-choice statements. Any 'slightly agree', or 'slightly disagree' responses to Likert scale statements were considered neutral and did not contribute to the categories of 'agreement' or 'disagreement'. Consensus for multiple-choice questions was calculated as ≥ 70% of panellists selecting a single response. Consensus was not measured for scoping questions or free-text responses

OCM Ologen collagen matrix

Table 3 Statements reaching consensus on postoperative considerations

Likert scale	Consensus agreement/ disagreement	Percentage agree/ disagree (%)	Delphi questionnaire round
The PRESERFLO™ MicroShunt allows for rapid visual recovery post-implantation	Agreement	Agree (77) Disagree (8)	Round 1
The posterior position of the bleb minimises the risk of erosion of the PRESERFLO™ MicroShunt over time	Agreement	Agree (77) Disagree (15)	Round 1
Following PRESERFLO™ MicroShunt implantation, a prolonged course of postoperative steroids is beneficial, for at least 10 weeks or longer for a typical patient	Agreement	Agree (92) Disagree (0)	Round 2
Antibiotic drops should be included as part of a postoperative regimen for a typical patient following PRESERFLO™ MicroShunt implantation	Agreement	Agree (85) Disagree (15)	Round 2
Corneal endothelial decompensation is an uncommon side effect 1-year post-PRESERFLO™ MicroShunt implantation	Agreement	Agree (100) Disagree (0)	Round 2
If the PRESERFLO™ MicroShunt implantation does not yield the expected results postoperatively in an eye with little remnant of the bleb, your next surgery of choice would be revision of the existing device	Agreement	Agree (77) Disagree (8)	Round 2
Revision surgery involves opening up of the conjunctiva, and the removal or release of scar tissue to ensure that the PRESERFLO™ MicroShunt is not blocked	Agreement	Agree (92) Disagree (0)	Round 2
If PRESERFLO™ MicroShunt implantation does not yield the expected results, implantation of the PRESERFLO™ MicroShunt may be considered in the fellow eye of the same patient, only if the factor(s) influencing the initial failure of the device has been identified and can be avoided	Agreement	Agree (77) Disagree (0)	Round 3

Table 3 continued

Multiple choice	Consensus	Percentage (%)	Delphi Questionnaire Round
In which situations do you include postoperative cycloplegic treatment?	In the case of a shallow anterior chamber	In the case of a shallow anterior chamber (77)	Round 1
		In the case of choroidal folds (46)	
		In the case of numerical hypotony (8)	
		Always at the end of surgery (8)	
		Never (15)	
		Other—please specify (23)	
In case of a late rise in IOP ≥ 4 months after PRESERFLO™ MicroShunt implantation, which of the following are suitable management choices:	Restarting topical aqueous suppressant drops Bleb revision, especially if the bleb is flat	Bleb revision, especially if the bleb is flat (85)	Round 2
		Restarting topical aqueous suppressant drops (77)	
		Needling (if the bleb is not flat) (15)	
		Other—please specify (0)	

Consensus was met when ≥ 70% of respondents selected 'strongly agree/agree' or 'strongly disagree/disagree' for Likert scale statements or when ≥ 70% of panellists selected the same option for single-choice statements. Any 'slightly agree' or 'slightly disagree' responses to Likert scale statements were considered neutral, and did not contribute to the categories of 'agreement' or 'disagreement'. Consensus for multiple-choice questions was calculated as ≥ 70% of panellists selecting a single response. Consensus was not measured for scoping questions or free-text responses

IOP intraocular pressure

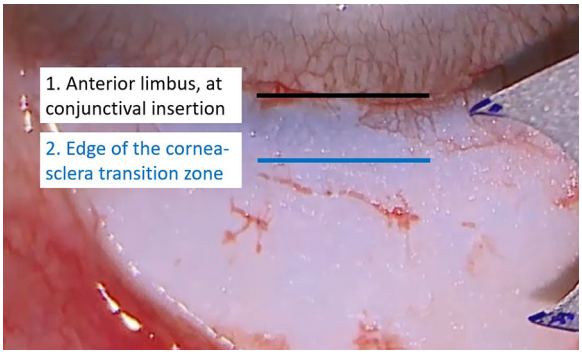

Fig. 3 Diagram to show the blue/white (sclera) transition zone for use with the scleral marker

postoperative cycloplegic treatment may be used in the case of a shallow anterior chamber.

The panellists agreed that the PMS allows for rapid visual recovery post-implantation. Corneal endothelial decompensation was regarded as an uncommon side effect 1-year post-implantation. Panellists agreed that the posterior position of the bleb minimises the risk of erosion of the PMS over time. There was agreement that revision surgery involves opening up of the conjunctiva and the removal or release of scar tissue to ensure that the device is not blocked. All panellists noted in free-text responses that they used MMC with their revision surgeries, but the concentration and duration of application differed between individuals.

The panellists agreed that following a rise in IOP $\geq$ 4 months after PMS implantation, restarting topical aqueous suppressant drops and bleb revision, especially if the bleb is flat, are suitable management choices. However, a small proportion of the group indicated that needling would be a suitable management choice in cases where the bleb is encapsulated.

In situations where the eye may have little remnant of the bleb postoperatively, panellists agreed that their next choice of surgery would be a surgical revision of the existing PMS. Where implantation of the PMS does not yield the expected results postoperatively, PMS implantation may be considered in the fellow eye of the same patient only if the factor(s) influencing failure of the device have been identified and can be avoided.

DISCUSSION

As the PMS remains a relatively novel device to treat patients with glaucoma, key guidance and optimal approaches to its use are primarily guided by the real-world experience of surgeons. This modified Delphi panel successfully built on the results of the previous Delphi panel [11], achieving consensus from a group of glaucoma surgeons with extensive experience of the PMS to provide further detailed guidance on the use of the device to treat patients with glaucoma.

Patient Selection and Preoperative Considerations

Consensus was achieved in this Delphi panel that pigmentary, post-trauma and post-vitrectomy glaucoma may be suitable indications for the use of the PMS. This adds to the consensus achieved during the previous Delphi panel that the PMS could be used in patients with high myopia (following satisfactory assessment of the conjunctiva) or off-label diagnoses of pigment dispersion, pseudoexfoliative glaucoma [11].

In the previous Delphi panel, consensus was achieved that a deep anterior chamber is an important prerequisite for implantation of the PMS in patients with hyperopia [11], with the results of this Delphi panel further supporting this finding. It is important to note that aqueous misdirection may occur after filtering surgery in patients with hyperopia, with increased risk linked to a shorter axial length [14]. Although not directly addressed during this Delphi panel, an assessment of the axial length in patients with hyperopia may be important to identify the risk of aqueous misdirection.

Regarding the IOP-lowering effect of the PMS, there was some disagreement as to whether the PMS may be suitable for patients with relatively low preoperative IOP (e.g. in the upper normal range). Panellists emphasised the importance of considering the target postoperative IOP when determining patient suitability for treatment with the PMS, as the odds of achieving a single-digit postoperative IOP value

may be more likely following trabeculectomy. However, the PMS may be considered for those with a low preoperative IOP in situations where a reduced risk of postoperative complications is especially important. Further evidence is required to demonstrate the efficacy of the PMS in achieving low postoperative IOP.

As part of their preoperative management strategy, panellists noted that they may alter systemic anti-coagulant and anti-aggregant therapy; however, panellists also discussed at the consensus meeting that this change in treatment may place some patients at an increased risk of stroke or heart attack. As such, altering these medications should be carefully considered on a case-by-case basis. Using pupil constrictors, such as pilocarpine, prior to surgery may be beneficial for some patients; the doses used by panellists are outlined in Supplementary Table 6. However, participants noted during the consensus meeting that pilocarpine may cause side effects including conjunctival hyperaemia and, as such, may be necessary to combine with vasoconstrictors (e.g. apraclonidine), to alleviate conjunctival hyperaemia prior to surgery. It was also discussed that treatment with topical vasoconstrictors may need to be altered in patients of a non-white background, as the desired effect may take longer to achieve and/or require increased dosage.

The previous Delphi panel achieved consensus that the PMS requires fewer follow-up appointments compared with trabeculectomy [11], with additional studies further supporting this finding [9, 10]. The findings from this Delphi panel further suggest that the PMS may be considered for patients requiring fewer follow-up appointments in the early postoperative period (e.g. those who live some distance away from the clinic or have reduced mobility). However, the number of follow-up appointments for traditional subconjunctival drainage surgeries will be influenced by the postoperative response of each patient.

Perioperative Considerations

Stenting (defined here as partial occlusion of the lumen) of the PMS may be considered during implantation to minimise the risk of hypotony, using either a 9.0 or 10.0 monofilament suture (e.g. prolene or nylon), based on the preference of the surgeon [15]. While the decision to stent the PMS should be made independently for each patient, further information on the characteristics of patients who may benefit from stenting is presented in Supplementary Table 14. Variations in the stenting procedure, as demonstrated by the panellists, can be viewed in Videos 1–6 (see Supplementary Material). Recent studies have shown that stenting the PMS is effective at reducing instances of hypotony and other adverse events, such as choroidal detachment, with a similar reduction in IOP at 6 months compared with a non-stented approach [15]. To avoid interaction between Tenon's capsule and the distal end of the PMS, consensus was obtained that the PMS may be sutured to the sclera or either anteriorly at the limbus together with conjunctiva or slightly posterior to the limbus as a separate closure. However, panellists agreed that the technique for doing so may vary. Video 7 (Supplementary Material) demonstrates the placement of a distal cross-stich over the PMS to avoid entrapment in Tenon's capsule during closure. Videos 8–10 (Supplementary Material) present variations in the closure of Tenon's capsule and conjunctiva.

It was noted in the previous Delphi panel that further evidence was required to assess the suitability of the PMS following a failed trabeculectomy [11]. Aligning with novel evidence, it was agreed that the PMS could be used in patients following a failed trabeculectomy when the trabeculectomy had been performed at least 6 months prior [16]. However, it was noted that scarred tissue resulting from the failed surgery would be a potential risk factor for subsequent failure of the PMS implantation. Therefore, the PMS should preferably be implanted away from the trabeculectomy location but within the supero-temporal or superonasal quadrant if possible (depending on conjunctival status). Studies have shown an

increased risk of infection and leakage related to inferior filtering blebs following subconjunctival drainage surgeries requiring MMC application [17–19]. Despite a lack of research on the risk of infection associated with inferior implantation of the PMS specifically, it is currently unadvisable to implant the PMS inferiorly in situations where no other suitable quadrants are available following a failed trabeculectomy.

The previous Delphi panel obtained consensus that although combined phacoemulsification surgery and PMS implantation is feasible, further evidence is required on the safety and efficacy [11]. Recent results from a 12-month, open-label, retrospective study demonstrated no significant difference in lowering of IOP or use of medication between patients with POAG in the combined and PMS-only surgery groups [12]. Other studies have identified that combined surgery is a risk factor for surgical failure and the need for postoperative needling [20]. However, data on adverse events following the combined procedure show that most are mild in severity and resolve without medical treatment [12, 21]. As such, the panellists determined that further data on the efficacy of the combined procedure are required before recommendations are made. Consensus was also obtained in the previous Delphi panel that if the PMS is to be implanted in an eye that previously underwent phacoemulsification, this should ideally be carried out > 6 months before PMS implantation to ensure the best chance of a successful implantation [11].

Measurement using the scleral marker to make the first incision during implantation was approached differently by the panellists and may be partly dependent on the training that surgeons received when learning the procedure. Panellists agreed that it may be beneficial to measure from the blue/white transition zone because of its more posterior location, which results in a shorter portion of the PMS being housed in the anterior chamber.

Implanting the PMS alongside an Ologen collagen matrix (OCM) is a technique not currently used by most panellists because of the cost and limited evidence of efficacy. This technique is emerging in the literature, with studies demonstrating that there is no significant difference in reduction of IOP when using an OCM versus the standalone PMS procedure, although further evidence is required [22].

Postoperative Considerations

The panellists agreed that there is rapid recovery of vision following implantation of the PMS. Although the reasons for this observation were not explored in further detail, it was noted that this may be due to the less invasive nature of the PMS, especially compared to other approaches such as trabeculectomy.

Participants noted that while corneal endothelial decompensation was regarded as an uncommon side effect 1 year following PMS implantation, overall risk would be influenced by the placement of the PMS. Specifically, more posterior placement of the PMS (away from the endothelium) may reduce the likelihood of developing endothelial decompensation, although further research is required to confirm this [23].

When treatment with the PMS does not yield the expected postoperative results, decisions regarding follow-up management depend on a range of factors such as bleb morphology and target IOP, with common approaches including revision surgery or aqueous suppressant drops. In addition, it was noted during the previous Delphi panel that, in situations when target IOP is not sustained following PMS implantation or in the case of bleb failure, revision surgery is preferable to bleb needling (except in the case of cystic blebs) [11].

It was observed during this Delphi panel that there is no established definition for the procedures included under the term revision surgery, which may influence how statements regarding revision surgery might be perceived. While in this Delphi panel it was agreed that a typical approach to revision surgery would involve opening up the conjunctiva and removing scar tissue, the procedures that panellists may include in revision surgery are documented in Supplementary Table 15. Furthermore, as needling may fall under the definition of revision surgery for some surgeons, this may influence their interpretation of statements on needling. Panellist definitions of needling are outlined in

Supplementary Table 16. Videos 11 and 12 (Supplementary Material) present examples of standard PMS revisions.

Strengths and Limitations

The modified Delphi panel is a systematic methodology to gather expert consensus [24]. The robust methodology of Delphi panels was further enforced with the use of the bespoke Delphi application, ensuring adherence to the key methodological characteristics such as panellist anonymity. An increased number of individuals participated in this Delphi panel compared with the 2021 Delphi panel, allowing for greater representation across Europe. While this Delphi panel is still focused on the use of the PMS in Europe, future studies may wish to incorporate surgeons from other countries and continents as the PMS becomes more widely utilised. Due to the timing of the two Delphi panels, the second Delphi panel allowed for the panellists to obtain even more experience to draw on when participating and providing their responses. In addition, there was no panellist drop-off across rounds, ensuring a robust process. One limitation of the Delphi panel is that since the PMS is a relatively new device, there are still several areas where panellists indicated that further published data would be needed before a consensus could be reached. As such, this study showed the importance of revisiting consensus statements regularly to ensure that novel published evidence and changing expert experience are continuously reflected in the set of consensus statements provided on a certain topic.

CONCLUSION

This Delphi panel builds upon recently published evidence and the combined experience of a panel of European glaucoma surgeons, providing consensus on the best practice use of the PMS. The statements that reached consensus provide detailed clinical practice guidance that can be applied by glaucoma surgeons as uptake of the PMS continues to increase across Europe. Statements that did not obtain consensus represent key areas where future research is needed to facilitate a more informed understanding of the use of the PMS.

ACKNOWLEDGEMENTS

The authors acknowledge Pascal Renner and Claire Lea from Santen SA for publication coordination.

Medical Writing/Editorial Assistance. Medical writing and editorial assistance in the preparation of this article was provided by James Doorbar, MSc, Noa Chapman, MSc, and Marielle Brown, PhD, from Costello Medical, UK. Support was funded by Santen SA in accordance with Good Publication Practice (GPP 2022) guidelines (https://www.ismpp.org/gpp-2022).

Author Contributions. Substantial contributions to study conception and design: Anthony P. Khawaja, Luís Abegão Pinto, Ingeborg Stalmans, Florent Aptel, Anna Barkander, Keith Barton, Henny Beckers, Milko Iliev, Thomas Klink, Giorgio Marchini, Jose Martínez de la Casa, Karin R. Pillunat, Jan H. Simonsen, Clemens Vass; substantial contributions to analysis and interpretation of the data: Anthony P. Khawaja, Luís Abegão Pinto, Ingeborg Stalmans, Florent Aptel, Anna Barkander, Keith Barton, Henny Beckers, Milko Iliev, Thomas Klink, Giorgio Marchini, Jose Martínez de la Casa, Karin R. Pillunat, Jan H. Simonsen, Clemens Vass; drafting the article or revising it critically for important intellectual content: Anthony P. Khawaja, Luís Abegão Pinto, Ingeborg Stalmans, Florent Aptel, Anna Barkander, Keith Barton, Henny Beckers, Milko Iliev, Thomas Klink, Giorgio Marchini, Jose Martínez de la Casa, Karin R. Pillunat, Jan H. Simonsen, Clemens Vass; final approval of the version of the article to be published: Anthony P. Khawaja, Luís Abegão Pinto, Ingeborg Stalmans, Florent Aptel, Anna Barkander, Keith Barton, Henny Beckers, Milko Iliev, Thomas Klink, Giorgio Marchini, Jose Martínez de la Casa, Karin R. Pillunat, Jan H. Simonsen, Clemens Vass.

Funding. This study was sponsored by Santen SA. All associated publication costs, including the Rapid Service Fee, were funded by Santen SA. Anthony P. Khawaja is supported by a UKRI Future Leaders Fellowship, a Lister Institute Fellowship, and an Alcon Research Institution Young Investigator Award.

Data Availability. All data generated or analysed during this study are included in this published article/as supplementary information files.

Declarations

Conflict of Interest. Anthony P. Khawaja: Consultant: AbbVie, Aerie, Google Health, Novartis, Reichert, Santen, Théa; Luís Abegão Pinto: Consultant: Allergan, Eyetechcare, NIDEK, Santen, Théa; Ingeborg Stalmans: Cofounder and Shareholder: MONA; Consultant: Alcon, Allergan/AbbVie, Bausch & Lomb, Elios Vision, EyeD Pharma, MONA, Horus Pharma, Omikron Pharma, Santen, Théa Pharma; Florent Aptel: Consultant: Alcon, Allergan, Eyetechcare, Glaukos, Horus, Novartis, Santen, Théa; Anna Barkander: Advisory board member for Santen and iStar; Lecture fees: New World Medical; Keith Barton: Consultant: Advanced Ophthalmic Innovations, Alcon, Allergan, Alimera Science, Carl Zeiss Meditec, C-Mer Holdings, ELTSight, EyeD Pharma, Glaukos, iStar, Ivantis, Kowa, Laboratoires Théa, PhPharma, Radiance Therapeutics, Santen Pharmaceutical Co. Ltd, Sight Sciences, Shifamed; Honorarium Recipient: Alcon, Allergan, Carl Zeiss Meditec., EyeTechCare, JamJoom Pharmaceuticals, Laboratoires Théa, Santen Pharmaceutical Co. Ltd; Stock Shareholder: Aquesys, International Glaucoma Surgery Registry Ltd., MedEther Ophthalmology (Hong Kong) Ltd, Vision Futures Ltd, Vision Medical Events Ltd; Patent: National University of Singapore; Henny Beckers: Consultant: Glaukos, Santen, Elios; Lecture fees: Glaukos, Novartis, Santen; Funding: Glaukos, InnFocus Inc., a Santen company, Nova Eye Medical; Milko Iliev: Consultant/Advisor: Théa, Allergan/AbbVie, Santen, iStar; Lecture Fees Thomas Klink: Consultant/Advisor: Allergan/AbbVie, Aerie, Santen; Lecture Fees: Alcon, Allergan/AbbVie, Glaukos, Ivantis, Novartis, Santen; Giorgio Marchini: Consultant/Advisor: AbbVie, Alcon, Allergan, Dompé, GSK, Omikron, Santen; Jose Martínez de la Casa: Consultant: Alcon, AbbVie, B&L, Glaukos, Viatris, Santen, Théa, Visufarma; Grants/research: AbbVie, Glaukos, Viatris, Santen, Théa; Speaker: Alcon, AbbVie, B&L, Glaukos, ICare, Viatris, Santen, Théa; Karin R. Pillunat: Lecture fees: Allergan/AbbVie, Santen, Novartis, Théa; Jan H. Simonsen: Consultant: AbbVie, Santen; Lecture fees: AbbVie, Santen; Speaker and advisory board member for Santen; Clemens Vass: Consultant: Allergan, iStar, Santen; Honorarium Recipient: Allergan, Carl Zeiss Meditec, Santen, Théa.

Ethical Approval. Ethical approval was not required as no patients were involved in the study.

REFERENCES

1. Stein JD, Khawaja AP, Weizer JS. Glaucoma in adults—screening, diagnosis, and management: a review. JAMA. 2021;325(2):164–74.

2. Kerr NM, Wang J, Barton K. Minimally invasive glaucoma surgery as primary stand-alone surgery

for glaucoma. Clin Experiment Ophthalmol. 2016;45(4):393–400.

3. Sadruddin O, Pinchuk L, Angeles R, Palmberg P. Ab externo implantation of the MicroShunt, a poly (styrene-block-isobutylene-block-styrene) surgical device for the treatment of primary open-angle glaucoma: a review. Eye Vis (Lond). 2019;6:36.

4. Pinchuk L, Riss I, Batlle JF, et al. The use of poly(-styrene-block-isobutylene-block-styrene) as a microshunt to treat glaucoma. Regen Biomater. 2016;3(2):137–42.

5. Pinchuk L, Riss I, Batlle JF, et al. The development of a micro-shunt made from poly(styrene-block-isobutylene-block-styrene) to treat glaucoma. J Biomed Mater Res B Appl Biomater. 2017;105(1): 211–21.

6. Batlle JF, Corona A, Albuquerque R. Long-term results of the PRESERFLO MicroShunt in patients with primary open-angle glaucoma from a single-center nonrandomized study. J Glaucoma. 2021;30(3):281–6.

7. Beckers HJM, Aptel F, Webers CAB, et al. Safety and effectiveness of the PRESERFLO® MicroShunt in primary open-angle glaucoma: results from a 2-year multicenter study. Ophthalmol Glaucoma. 2022;5(2):195–209.

8. Bhayani R, Martínez de la Casa JM, Figus M, et al. Short-term safety and efficacy of Preserflo™ Microshunt in glaucoma patients: a multicentre retrospective cohort study. Eye. 2023;37(4):644–9.

9. Pillunat KR, Herber R, Haase MA, et al. PRESERFLO™ MicroShunt versus trabeculectomy: first results on efficacy and safety. Acta Ophthalmol. 2022;100(3):e779–90.

10. Jamke M, Herber R, Haase MA, et al. PRESERFLO™ MicroShunt versus trabeculectomy: 1-year results on efficacy and safety. Graefe's Arch Clin Exp Ophthalmol. 2023;261:2901–15.

11. Khawaja AP, Stalmans I, Aptel F, et al. Expert consensus on the use of the PRESERFLO™ MicroShunt device in the treatment of glaucoma: a modified Delphi panel. Ophthalmol Ther. 2022;11(5): 1743–66.

12. Martínez-de-la-Casa JM, Saenz-Francés F, Morales-Fernandez L, et al. Clinical outcomes of combined Preserflo Microshunt implantation and cataract surgery in open-angle glaucoma patients. Sci Rep. 2021;11(1):15600.

13. Saeed E, Gołaszewska K, Dmuchowska DA, Zalewska R, Konopińska J. The PreserFlo MicroShunt in the context of minimally invasive glaucoma surgery: a narrative review. Int J Environ Res Public Health. 2023;20(4):2904.

14. Grzybowski A, Kanclerz P. Acute and chronic fluid misdirection syndrome: pathophysiology and treatment. Graefes Arch Clin Exp Ophthalmol. 2018;256:135–54.

15. Lupardi E, Laffi GL, Moramarco A, Barboni P, Fontana L. Systematic Preserflo MicroShunt intraluminal stenting for hypotony prevention in highly myopic patients: a comparative study. J Clin Med. 2023;12(4):1677.

16. Quaranta L, Micheletti E, Carassa R, et al. Efficacy and safety of PreserFlo® MicroShunt after a failed trabeculectomy in eyes with primary open-angle glaucoma: a retrospective study. Adv Ther. 2021;38: 4403–12.

17. Soltau JB, Rothman RF, Budenz DL, et al. Risk factors for glaucoma filtering bleb infections. Arch Ophthalmol. 2000;118(3):338–42.

18. Yassin SA. Bleb-related infection revisited: a literature review. Acta Ophthalmol. 2016;94(2):122–34.

19. Wallin Ö, Al-ahramy AM, Lundström M, Montan P. Endophthalmitis and severe blebitis following trabeculectomy. Epidemiology and risk factors; a single-centre retrospective study. Acta Ophthalmol. 2014;92(5):426–31.

20. Burgos-Blasco B, García-Feijóo J, Perucho-Gonzalez L, et al. Evaluation of a novel αb εxterno MicroShunt for the treatment of glaucoma. Adv Ther. 2022;39(9):3916–32.

21. Pawiroredjo SS, Bramer WM, Pawiroredjo ND, et al. Efficacy of the PRESERFLO MicroShunt and a meta-analysis of the literature. J Clin Med. 2022;11(23): 7149.

22. Vastardis I, Fili S, Perdikakis G, et al. Preliminary results of Preserflo Microshunt versus Preserflo Microshunt and Ologen implantation. Eye Vis. 2021;8(1):1–14.

23. Ibarz-Barberá M, Morales-Fernández L, Corroto-Cuadrado A, et al. Corneal endothelial cell loss after PRESERFLO™ MicroShunt implantation in the anterior chamber: anterior segment OCT tube location as a risk factor. Ophthalmol Ther. 2022;11: 293–310.

24. Hsu C, Sandford B. The Delphi technique: making sense of consensus. Pract Asess Res Eval. 2007;12: 1–8.