

Zrinzo Ludvic (Orcid ID: 0000-0002-6013-4946)
Foltynie Thomas (Orcid ID: 0000-0003-0752-1813)

Title

Brain Oedema Associated with Deep Brain Stimulation Through a Single Directional Contact

Authors

Christine Girges PhD ^{1,2}, Marie T. Krüger PhD ^{1,2,3}, San San Xu PhD ^{1,2}, Harith Akram PhD ^{1,2},
Jonathan Hyam PhD ^{1,2}, Patricia Limousin PhD ^{1,2}, Ludvic Zrinzo PhD ^{1,2}, Thomas Foltynie PhD
^{1,2}

Affiliations

1. Department of Clinical and Movement Neurosciences, University College London,
London, UK
2. UCL Functional Neurosurgery Unit, National Hospital for Neurology and Neurosurgery,
London, UK
3. Department of Neurosurgery, University Medical Centre Freiburg, Faculty of Medicine,
University of Freiburg, Germany

Corresponding Author

Professor Thomas Foltynie
National Hospital for Neurology and Neurosurgery
Unit of Functional Neurosurgery, Box 146
Queen Square
London, WC1N 3BG

This article has been accepted for publication and undergone full peer review but has not been through the copyediting, typesetting, pagination and proofreading process which may lead to differences between this version and the [Version of Record](https://doi.org/10.1002/mdc3.13871). Please cite this article as doi: [10.1002/mdc3.13871](https://doi.org/10.1002/mdc3.13871)

This article is protected by copyright. All rights reserved.

Word Count

799

Article Type

Letters to the Editor: Neuromodulation

Running Title

Brain Oedema Associated with Directional Deep Brain Stimulation

Key Words

Deep brain stimulation, subthalamic nucleus, directional electrodes, stimulation-induced side effects, impulse control disorders.

Accepted Article

The efficacy of deep brain stimulation (DBS) can be limited by stimulation-induced side effects, occurring when current spreads to adjacent brain structures (1). Directional electrodes were designed, in part, to overcome this issue. Segmented contacts allow horizontal and vertical current steering to spatially refine the stimulation field, increasing the therapeutic window (2). We describe a patient with Parkinson Disease (PD) who experienced right peri-electrode oedema and behavioural changes four years post-implantation, coinciding with a period when high density current was delivered through a single segment on a directional lead in the relevant hemisphere.

A 50-year-old male was diagnosed with idiopathic PD including DaTSCAN imaging demonstrating a left presynaptic dopaminergic deficit. He responded well to levodopa for approximately five years.

At age 59, severe motor fluctuations and dystonic left leg posturing developed. His UPDRS-III was 31 OFF-medication and 10 ON-medication (68% improvement), cognitive examination was satisfactory, and brain MRI showed moderate small vessel disease.

Medication comprised co-beneldopa 200/50mg five times a day, co-beneldopa controlled release 100/25mg nocte, entacapone 200mg five times a day, rasagiline 1mg, and rotigotine 6mg/24 hrs.

Subthalamic nucleus DBS (STN-DBS) was performed in 2018, at age 60 (Vercise Gevia DB-1200 and Cartesia Directional Leads, Boston Scientific). Immediate post-operative MRI revealed excellent lead location within the STN without radiological complications. Initial stimulation parameters employed ring-mode (left STN contact 2-, 3-, 4-, 1.3mA, 60 μ s,

130Hz; right STN contact 1-, 1.2mA, 60 μ s, 130Hz). Delayed ON-stimulation induced dysarthria was managed by the combined use of short pulse width (30 μ s), low frequency stimulation (60Hz), and directional steering. In 2019, stimulation was further adjusted with current steering in the right STN directed through a single segment (left STN contact 2- (75%), 4- (25%), 6.1mA, 30 μ s, 60Hz and right STN contact 2- (100%), 5.8mA, 30 μ s, 60Hz).

Four years after implantation (2022), he was involved in a minor road traffic accident followed by severe neck and shoulder pain. Facial numbness and jawline dysesthesia were reported, but he was systemically well. A brain MRI 6-weeks later, revealed significant increase in T2 signal with mass effect, around the right STN electrode tip that appeared to track along white matter pathways, suggestive of vasogenic oedema (Figures 1A & B). Minor degenerative changes, noted on cervical spine MRI, were not considered relevant to his pain (controlled using opiates and pregabalin). Somatosensory evoked potential studies were unremarkable. Electrode impedances were within normal limits.

It emerged that significant hypersexuality and secretive extra-marital liaisons had occurred over the past 2-4 years. The rotigotine patch 6mg/24 hrs was withdrawn and we explored whether high current density contributed to the oedema and behavioural changes. The right STN stimulation parameters were modified to contact 2- (54%), 3- (23%), 4- (23%), 5.5mA, 30 μ s, 60Hz. He continued to take co-beneldopa 200/50mg six to seven times a day and co-beneldopa controlled release 100/25mg nocte. No other treatment or intervention for the oedema was administered. A brain MRI 6-months later showed complete resolution of the signal abnormality (Figures 1C & D). This coincided with a significant improvement in impulsive behaviours and pain, without the need for further analgesia.

Peri-electrode oedema is now considered a common post-operative complication of DBS (3,4). It typically develops within three months post-implantation and most patients remain asymptomatic. It may be caused by mechanical trauma during surgery, accumulation of cerebrospinal fluid in the surgical tract or immunological hypersensitivity to implant materials (3).

To our knowledge, we are the first to report a case of non-infectious peri-electrode oedema, discovered four years post-implantation. This could potentially reflect either a detection delay (since interval imaging following the immediate post-implant MRI was not available) or a chronic inflammatory reaction to the materials used (5,6). It is theoretically possible that the traumatic oedema was also caused by the accident. An excessive electrical charge concentration through a single directional contact could have further exacerbated oedema in tissue that was already made fragile.

We feel that the subsequent temporal sequence of events, however, renders these speculations unlikely. The observed signal change resolved after DBS parameter modification to allow reduction in current density with distribution across all three contacts at one level. The behavioural changes, whether associated or not, also resolved within this period. While this could be related to withdrawing from the dopamine agonist, stimulation related psychiatric effects have been reported within the literature (7,8). They are attributed to involvement of limbic structures, provoked by stimulating anteromedial neurons within the STN (7). Reducing stimulation intensity or shifting to a more superior and lateral electrode contact is known to minimise this issue (9).

Further investigation is needed to fully understand whether these clinical and imaging abnormalities were a side effect of high current density during unidirectional stimulation. Peri-electrode oedema could be an intermediate state occurring prior to permanent tissue damage caused by exceeding charge density (10), which has important implications for DBS programming.

Author Roles

(1) Research Project: A. Conception, B. Organization, C. Execution; (2) Statistical Analysis: A. Design, B. Execution, C. Review and Critique; (3) Manuscript Preparation: A. Writing of the first draft, B. Review and Critique.

CG: 1B, 1C, 3A, 3B

MK: 1C, 3A, 3B

SX: 1C, 3A, 3B

HA: 1C, 3A, 3B

JH: 1C, 3A, 3B

PL: 1C, 3A, 3B

LZ: 1A, 1B, 1C, 3A, 3B

TF: 1A, 1B, 1C, 3A, 3B

Funding Sources and Conflicts of Interest

No specific funding was received for this work.

CG reports no conflicts of interest.

MK is a consultant for Brainlab, Boston Scientific and Elekta.

SX reports no conflicts of interest.

HA reports no conflicts of interest.

JH reports no conflicts of interest.

PL acts as consultant for Boston Scientific, Medtronic, Aleva and INBRAIN.

LZ acts as consultant for Boston Scientific, BrainLab, Medtronic.

TF has served on advisory boards for Voyager Therapeutics, Handl therapeutics, Living Cell Technologies, Bial, Profile Pharma.

Financial Disclosures for the Previous 12 Months

CG reports no financial disclosures.

MK has received travel funding and consultancy fees from Medtronic.

SX reports no financial disclosures.

HA reports no financial disclosures.

JH reports no financial disclosures.

PL has received honoraria for educational activities with Boston Scientific, Medtronic, Aleva and INBRAIN.

LZ has received honoraria for educational activities with Boston Scientific, BrainLab, Medtronic.

TF has received grants from National Institute of Health Research, Michael J Fox Foundation, John Black Charitable Foundation, Cure Parkinson's Trust, Innovate UK, Van Andel Research Institute and Defeat MSA. He has received honoraria for talks sponsored by Bial, Profile Pharma, Boston Scientific.

Ethical Compliance Statement

The authors confirm that the approval of an institutional review board was not required for this work. We confirm that we have read the journal's position on issues involved in ethical publication and affirm that this work is consistent with those guidelines. Informed consent was not needed as identifiable patient information/characteristics were not reported.

Acknowledgements

The UCL Functional Neurosurgery Unit is supported by the National Institute for Health Research University College London Hospitals Biomedical Research Centre.

References

1. Limousin P, Foltynie T. Long-term outcomes of deep brain stimulation in Parkinson disease. *Nat Rev Neurol* [Internet]. 2019 Apr 18;15(4):234–42. Available from: <http://www.nature.com/articles/s41582-019-0145-9>
2. Dayal V, De Roquemaurel A, Grover T, Ferreira F, Salazar M, Milabo C, et al. Novel Programming Features Help Alleviate Subthalamic Nucleus Stimulation-Induced Side Effects. *Movement Disorders* [Internet]. 2020 Dec 26;35(12):2261–9. Available from: <https://doi.org/10.1002/mds.28252>
3. Tian Y, Wang J, Jiang L, Feng Z, Shi X, Hao Y. The need to be alert to complications of peri-lead cerebral edema caused by deep brain stimulation implantation: A systematic literature review and meta-analysis study. *CNS Neurosci Ther* [Internet]. 2022 Mar 19;28(3):332–42. Available from: <https://onlinelibrary.wiley.com/doi/10.1111/cns.13802>
4. Borellini L, Ardolino G, Carrabba G, Locatelli M, Rampini P, Sbaraini S, et al. Peri-lead edema after deep brain stimulation surgery for Parkinson's disease: a prospective magnetic resonance imaging study. *Eur J Neurol* [Internet]. 2019 Mar 18;26(3):533–9. Available from: <https://onlinelibrary.wiley.com/doi/abs/10.1111/ene.13852>
5. Arocho-Quinones E V., Pahapill PA. Non-Infectious Peri-Electrode Edema and Contrast Enhancement Following Deep Brain Stimulation Surgery. *Neuromodulation: Technology at the Neural Interface* [Internet]. 2016 Dec;19(8):872–6. Available from: <https://doi.org/10.1111/ner.12432>

6. Morsi O, Lopez J, Jimenez J, Fuentes L, Valero G, Baidez AE, et al. Spontaneous peri-electrode edema, 7 years after subthalamic nucleus deep brain stimulation (STN-DBS) in a patient with Parkinson's disease (PD): A case report. In: *Movement Disorders*. 2018. p. 33 (suppl 2).
7. Somma T, Esposito F, Scala MR, Scelzo A, Baiano C, Patti S, et al. Psychiatric Symptoms in Parkinson's Disease Patients before and One Year after Subthalamic Nucleus Deep Brain Stimulation Therapy: Role of Lead Positioning and Not of Total Electrical Energy Delivered. *J Pers Med*. 2022 Oct 1;12(10).
8. Scherrer S, Smith AH, Gowatsky J, Palmese CA, Jimenez-Shahed J, Kopell BH, et al. Impulsivity and Compulsivity After Subthalamic Deep Brain Stimulation for Parkinson's Disease. Vol. 14, *Frontiers in Behavioral Neuroscience*. Frontiers Media S.A.; 2020.
9. Dayal V, Limousin P, Foltynie T. Subthalamic nucleus deep brain stimulation in Parkinson's disease: The effect of varying stimulation parameters. Vol. 7, *Journal of Parkinson's Disease*. IOS Press; 2017. p. 235–45.
10. Cogan SF, Ludwig KA, Welle CG, Takmakov P. Tissue damage thresholds during therapeutic electrical stimulation. *J Neural Eng*. 2016 Apr;13(2):21001.

Figure Legend

Figure 1

Top Row: T2 weighted MRI during single contact stimulation (activated contact in pink on far left of figure). A and A'. Image through midbrain. B and B'. Image through anterior commissure – posterior commissure (AC-PC) plane. High signal denotes oedema that involves the area between right STN and red nucleus with medial displacement of the red nucleus and third ventricle wall. Oedema also extends posteriorly towards the medial lemniscus, anteriorly into the ansa lenticularis, laterally through the lenticular fasciculus, and encases the posterior limb of the internal capsule. **Bottom Row:** T2 weighted MRI during stimulation across all three contacts at one level (activated contacts in pink on far left of figure). C, C': images through midbrain. D and D': Image through AC-PC plane. Oedema has resolved. Subthalamic nucleus (green); lead (orange); orientation of the activated directional contact derived from fused post implantation CT images (small orange arrow); simulated stimulation field (red).

Accepted Article

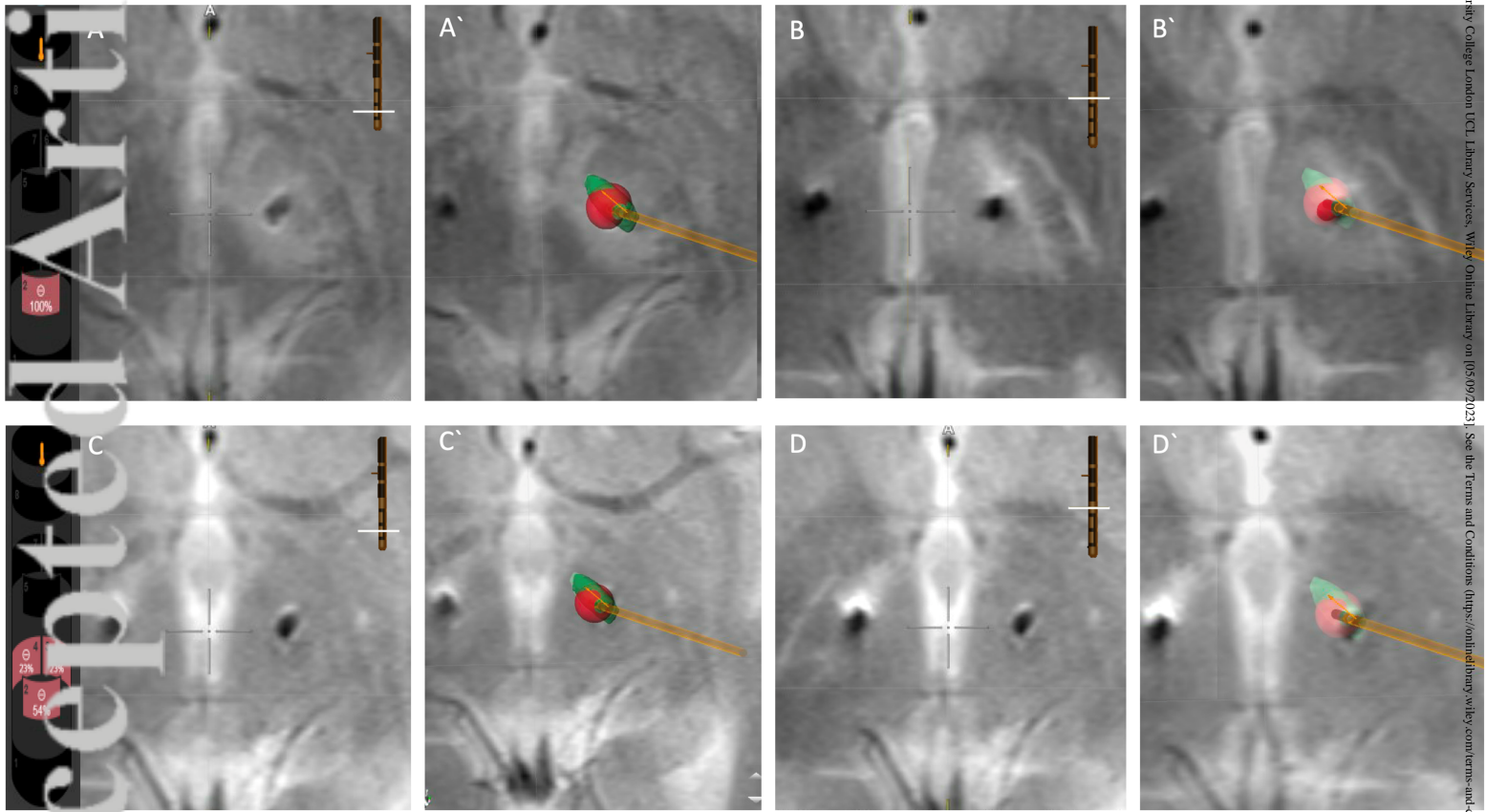


Figure 1 - High Resolution.tif