

# Custom 3D-Printed Implants for Acetabular Reconstruction

## Intermediate-Term Functional and Radiographic Results

Anna Di Laura, PhD, Johann Henckel, MD, and Alister Hart, FRCSG(Orth)

*Investigation performed at the Royal National Orthopaedic Hospital NHS Trust, Stanmore, United Kingdom, and University College London, London, United Kingdom*

**Background:** The management of massive acetabular defects at the time of revision hip surgery is challenging. Severe pelvic bone loss and the heterogeneity and quality of the remaining bone stock can compromise the fixation and mechanical stability of the implant.

**Methods:** We reviewed a database of consecutive patients who had undergone acetabular reconstruction with the use of a custom 3D-printed implant with a dual-mobility bearing for the treatment of Paprosky type-3B defects between 2016 and 2019. Functional and radiological outcomes were assessed.

**Results:** A total of 26 patients (17 women and 9 men) with a minimum follow-up of 36 months (median, 53 months; range, 36 to 77 months) were identified. The median age at surgery was 69 years (range, 49 to 90 years), and 4 patients had pelvic discontinuity. The cumulative implant survivorship was 100%. The median Oxford Hip Score improved significantly from 8 (range, 2 to 21) preoperatively to 32 (range, 14 to 47) postoperatively ( $p = 0.0001$ ). One patient had a transient sciatic nerve palsy, 1 hip dislocated 6 months postoperatively and was managed nonoperatively, and 1 infection recurred. No patient had a fracture. Radiographic evaluation showed bone ingrowth at the bone-implant interface in 24 patients (92%) at  $\geq 12$  months of follow-up and showed no evidence of implant loosening or migration at the latest follow-up (3 to 6 years).

**Conclusions:** Excellent functional improvement, implant survivorship, and osseointegration were recorded in the patient cohort. Accurate preoperative planning and the adoption of custom 3D-printed implants showed promising results in complex revision hip surgery.

**Level of Evidence:** Therapeutic Level IV. See Instructions for Authors for a complete description of levels of evidence.

Primary total hip arthroplasty (THA) is widely recognized as a successful surgical intervention that is associated with high quality-adjusted life years (QALYs), with 1 systematic review indicating that that approximately 75% of hip replacements last 15 to 20 years<sup>1</sup>. Despite the success of this procedure, a number of hip arthroplasties eventually require revision, and, once the initial implant has failed, subsequent revisions are even less successful<sup>2-4</sup>.

The most common causes of failure are aseptic loosening, instability, and periprosthetic joint infection, each of which can lead to mild or advanced acetabular bone loss<sup>5,6</sup>. Patterns of bone loss vary depending on the clinical history. Classification systems have been designed to define the extent of the remaining bone<sup>7-9</sup>. The Paprosky system is an established method

that is widely used for the classification of defects according to the presence or absence of intact acetabular walls and the ability of the anterior and posterior columns to support an implant. The Paprosky classification ranges from type 1 (minimal bone loss) to type 3, with type 3B (>60% bone loss with substantial superomedial migration of the hip center) being the most severe<sup>8,10,11</sup>. The successful management of complex acetabular defects and pelvic discontinuities requires accurate surgical planning, specific operative techniques, and highly specialized implant design and tools<sup>5</sup>. There is no consensus regarding the best option for the reconstruction of Paprosky type-3B defects.

In the past, antiprotrusio cages have been the preferred choice for the management of type-3B defects<sup>12</sup>; however, their use has been associated with high failure rates<sup>13</sup>. The

**Disclosure:** The **Disclosure of Potential Conflicts of Interest** forms are provided with the online version of the article (<http://links.lww.com/JBJSOA/A512>).

Copyright © 2023 The Authors. Published by The Journal of Bone and Joint Surgery, Incorporated. All rights reserved. This is an open-access article distributed under the terms of the [Creative Commons Attribution-Non Commercial-No Derivatives License 4.0](https://creativecommons.org/licenses/by-nc-nd/4.0/) (CCBY-NC-ND), where it is permissible to download and share the work provided it is properly cited. The work cannot be changed in any way or used commercially without permission from the journal.

severity of bone loss and the quality of the remaining bone greatly affect the stability of the components used for revision THA<sup>14</sup>. The first re-revision rates of the acetabular component have ranged from 20% to 36% at 10 years following the initial revision<sup>15,16</sup>.

The purpose of the present study was to assess the early clinical results, at a minimum of 36 months, associated with the use of custom-made 3D-printed acetabular cups for the treatment of type-3B defects. Our primary objective was the assessment of functional outcomes. Our secondary objective was the assessment of radiographic outcomes.

### Materials and Methods

This was a single-center study. We retrospectively reviewed our database to identify all consecutive patients who had undergone acetabular reconstruction with a custom-made 3D-printed titanium implant for the management of a Paprosky type-3B defect, with or without pelvic discontinuity, between 2016 and 2019.

The inclusion criteria were (1) a failed acetabular implant following either a primary THA or 1 or multiple previous revisions and (2) a Paprosky type-3B defect with or without discontinuity. The patients in the present study had been referred to the Royal National Orthopaedic Hospital NHS (National Health Service) Trust in London, United Kingdom, for the treatment of a defect that had been classified as “un-reconstructible” by other hospitals and/or surgeons. Patients who did not undergo acetabular reconstruction because they were unfit for a major surgical procedure were excluded.

Consent was obtained from each patient in accordance with local ethical guidelines. Operative treatment and follow-up evaluations were performed by the senior author (A.H.).

The outcome measures were (1) implant survivorship, (2) preoperative and postoperative Oxford Hip Score (OHS), (3) complications (i.e., dislocation, neurovascular injury, infection, iatrogenic fracture), (4) radiographic evidence of implant loosening, and (5) radiographic evidence of migration.

### Surgical Planning and Procedure

Acetabular revisions were performed with the use of a ProMade implant (LimaCorporate) with a dual-mobility bearing. Preoperatively, the patients underwent computed tomography (CT) scanning of the pelvis. The data were used by the implant manufacturer, which provides a dedicated engineering design service for the accurate assessment of the center of rotation of the failed hip, the study of the morphology of the remaining host bone, the design of the implant, and the strategy for implantation. Designing the custom implant involved filling the defect with porous titanium, ensuring fixation with structural titanium and screw holes, and determining the optimal location of the center of rotation. The surgeon reviewed all surgical plans prior to final approval and provided feedback to further tune the design, especially with regard to the feasibility of component insertion and the number and position of screws. Once approved, the custom implants were produced using electron-beam additive manufacturing with regions of trabecular titanium to promote osseointegration<sup>17</sup>. Three-dimensional printing enables the production of prosthetic components that feature complex shapes and porous structures without compromising the mechanical properties. The rationale for the use of 3D-printed implants rather than conventional implants is to promote and enhance bone ingrowth and biological implant fixation<sup>18</sup>. The surgeon used 3D-printed anatomical models to evaluate the size and position of the defect, to assist with surgical exposure, and to guide surgical orientation for bone preparation.

The surgical procedure was performed via a posterior approach by 1 senior orthopaedic surgeon who was occasionally accompanied by a vascular surgeon, depending on the proximity of the failed implant to the neurovascular structures (Fig. 1). Following the removal of the acetabular component, the osseous acetabulum was exposed and areas of nonviable bone were removed. Fixation of the 3D-printed titanium implant was achieved with both press-fit and screw fixation using patient-specific drill guides.

The femoral stem was retained if it was well fixed. In cases of infection, a 2-stage procedure was adopted. The hip

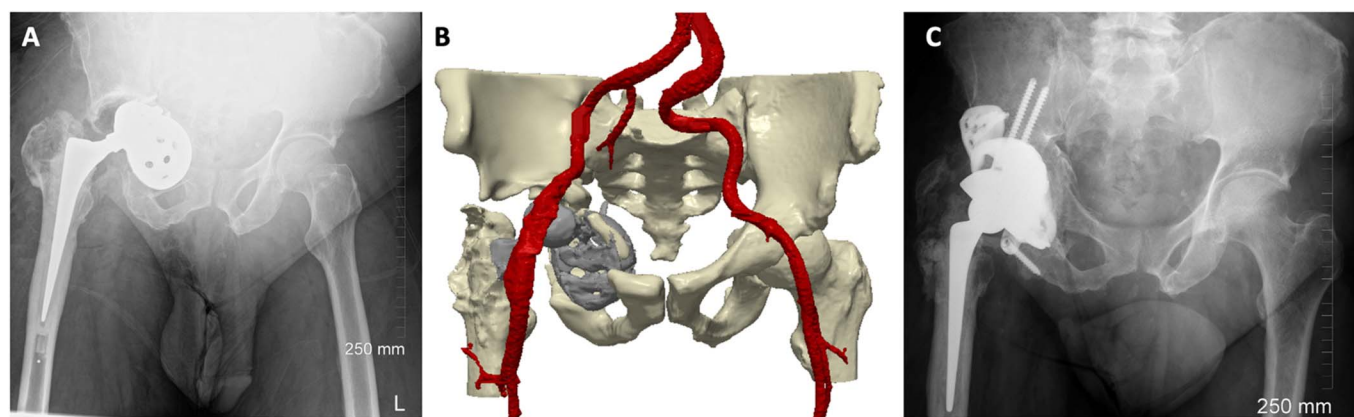


Fig. 1

**Fig. 1-A** Anteroposterior radiograph showing collapse of the acetabular bone around the cup, with intrapelvic cup migration. **Fig. 1-B** Three-dimensional reconstruction of CT angiography delineating the intrapelvic vasculature in relation to the acetabular component and screws. **Fig. 1-C** Postoperative radiograph, made at the time of the latest follow-up (4 years after surgery), showing stability of the implant.

TABLE 1 Characteristics of the Cohort

No. of patients	26
Age (yr)	
Mean	69
Median	69
Range	49-90
Sex (no. of patients)	
Female	17 (65%)
Male	9 (35%)
Body mass index (kg/m <sup>2</sup> )	
Mean	28
Median	26
Range	22-42
Side (no. of patients)	
Right	17 (65%)
Left	9 (35%)
Pelvic discontinuity (no. of patients)	4 (15%)
Contralateral hip replacement* (no. of patients)	13 (50%)
Clinical follow-up (mo)	
Mean	55
Median	53
Range	36-77

\*In all 26 patients, only 1 of the 2 hips was treated with a custom 3D-printed implant. Contralateral hip replacements were conventional replacements for which a custom implant was not utilized.

joint was accessed via a posterior approach, often utilizing the existing scar. Dissection through the gluteal muscles was dependent on the type of exposure required.

### Clinical Outcome Assessment

Implant survivorship was calculated with use of the Kaplan-Meier method, with all-cause re-revision as the end point. Failure was defined as revision or replacement of the index implant for any reason.

The operating surgeon closely monitored the patient for early complications. Patient-reported outcomes were measured with the OHS<sup>19</sup>. The OHS ranges from 0 to 48 points, with 48 representing the best possible outcome. Functional outcomes were assessed by comparing preoperative and postoperative scores.

The database was reviewed for the number and type of complications, including dislocation, neurovascular injury, infection, and iatrogenic fracture. Patients undergoing acetabular reconstruction are at risk for dislocation because of repeated hip operations and limited abductor function. To minimize the risk of dislocation, a dual-mobility bearing, featuring an ultra-high molecular weight polyethylene (UHMWPE) liner and a ceramic head, was used in all cases; a face-changing liner was adopted in a subset of patients. To reduce the risk of neurovascular injury, a CT angiogram was performed preoperatively. If the

failed implant component or a pseudotumor was adjacent to the iliac blood vessels, then a cardiovascular surgeon assisted the main surgeon with intraoperatively isolating the anatomical structures. Patients with infection were treated with a 2-stage procedure.

### Radiographic Outcome Assessment

Radiographs and CT images were evaluated immediately after the operation, at 6 months, and annually thereafter. The imaging studies were reviewed for signs of radiolucency, implant stability, and congruency.

A radiolucent line was defined as a dark line of demarcation between the acetabular component and the cancellous bone<sup>20</sup>. The areas of bone ingrowth (i.e., struts or “spot welds”) are recognized on radiographs and CT images by the presence of trabecular bone that extends to the metal component surface<sup>21,22</sup>.

Radiographs and triplanar CT reconstructions were evaluated for component integrity, evidence of new bone formation at the bone-implant interface, and migration. These evaluations were performed by an orthopaedic surgeon and an engineer with expertise in implant imaging. In some cases, the CT images were rendered to produce 3D reconstructions of the patient’s osseous pelvis for relative comparison of images taken at different time points. Bone-to-bone CT registration allowed for the assessment of implant movement over time (Simpleware ScanIP Medical, version 2021.6; Synopsis).

Acetabular migration (>5 mm) was assessed according to the criteria described by Massin et al.<sup>23</sup>. Loosening was determined according to the Kosashvili modification of the criteria described by Gill et al.<sup>24,25</sup>. The implant was considered to be loose if at least 1 of 3 radiographic findings was detected: (1) horizontal or vertical migration of >5 mm, (2) a complete and progressive radiolucent line medially and superiorly or around the screws, and/or (3) broken components such as flanges or screws.

### Statistical Analysis

Statistical analysis was performed with use of GraphPad Prism (version 9.4; GraphPad Software). Graphs were produced with the same software for MacOS. Univariate analysis was achieved with use of the Wilcoxon test. The level of significance was set at  $p \leq 0.05$ .

### Source of Funding

This work did not receive grants from funding agencies in the public, commercial, or nonprofit sectors.

### Results

Twenty-six patients with a minimum follow-up of 36 months were identified. Of those, 17 (65%) were women. The median age at surgery was 69 years (range, 49 to 90 years). Four patients (15%) had pelvic discontinuity. The median follow-up was 53 months (range, 36 to 77 months). All patients had a Paprosky type-3B defect. Pelvic discontinuity was detected preoperatively with use of radiography and was confirmed intraoperatively by the senior author following the removal of the failed acetabular component. All revisions were performed because of cup loosening. Seven patients (27%) had an infection and were

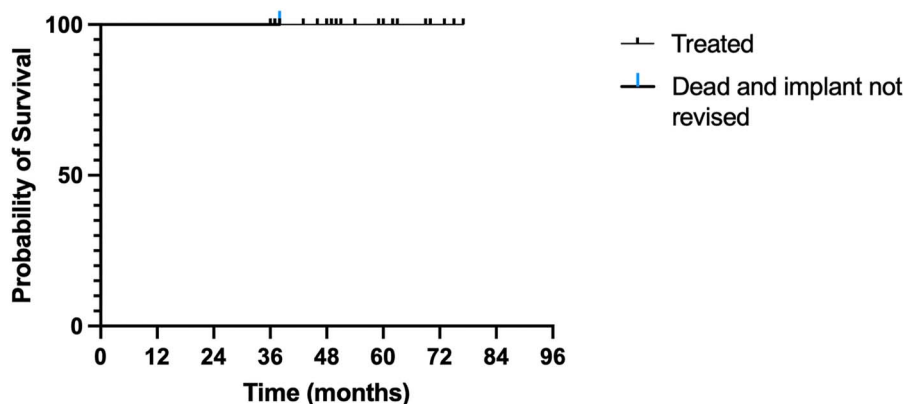


Fig. 2 Kaplan-Meier survival curve for the custom-made 3D-printed titanium implants, with revision for any cause as the end point.

treated with a 2-stage revision. The infectious organisms included both gram-positive and gram-negative bacteria such as Staphylococcus, Streptococcus, and Pseudomonas. In 4 patients (15%), the vascular surgeon accompanied the main surgeon intraoperatively. The femoral stem was retained in 16 patients (62%).

Characteristics of the study cohort are summarized in Table I.

**Clinical Outcomes**

With clinical failure resulting from any cause as the end point, the overall Kaplan-Meier survival rate for the custom implant was 100%, with 25 hips remaining at risk. One patient died 38 months after hip surgery for reasons unrelated to the hip (Fig. 2).

The median OHS improved from 8 (IQR [interquartile range], 4.5 to 13.5; overall range, 2 to 21) preoperatively to 32 (IQR, 28.5 to 37; overall range, 14 to 47) postoperatively. The difference was significant (p = 0.0001) (Fig. 3). The OHS improved significantly for patients with extremely severe disability preoperatively (Fig. 4).

No new episodes of infection were recorded. Infection recurred in 1 patient who had a long history of infection, suggesting that the infection had not been eradicated. At the time of writing, the patient was being treated with antibiotics and wound care and the implant remained in situ.

One patient had a transient sciatic nerve palsy with a dropfoot deformity that resolved over time. The OHS was 30 at the time of the latest follow-up visit, and the patient was able to walk unaided.

One hip dislocated 6 months postoperatively. The dislocation was successfully treated with closed reduction.

No fractures occurred in the patient group.[fx1][fx2]

**Radiographic Outcomes**

Radiographs and tri-planar CT reconstructions were evaluated for component integrity, evidence of new bone formation at the bone-implant interface, and migration (Fig. 5).

Bone ingrowth at the bone-implant interface was observed in 24 patients (92%). The ingrowth was visible at ≥12 months of follow-up and was observed in areas of the acetabular wall and roof (areas of maximum implant porosity) as well as around the flanges. The remaining 2 patients had no obvious bone ingrowth on either radiographs or CT scans.

No sign of implant loosening, breakage, or migration was observed in any patient at ≥3 years of follow-up (Fig. 6).

**Discussion**

Revision hip surgery becomes more challenging when further revisions are required. Subsequent revisions often involve the management of acetabular bone loss<sup>26</sup>, which serves as a potential indication for the use of custom-made implants<sup>27</sup>.

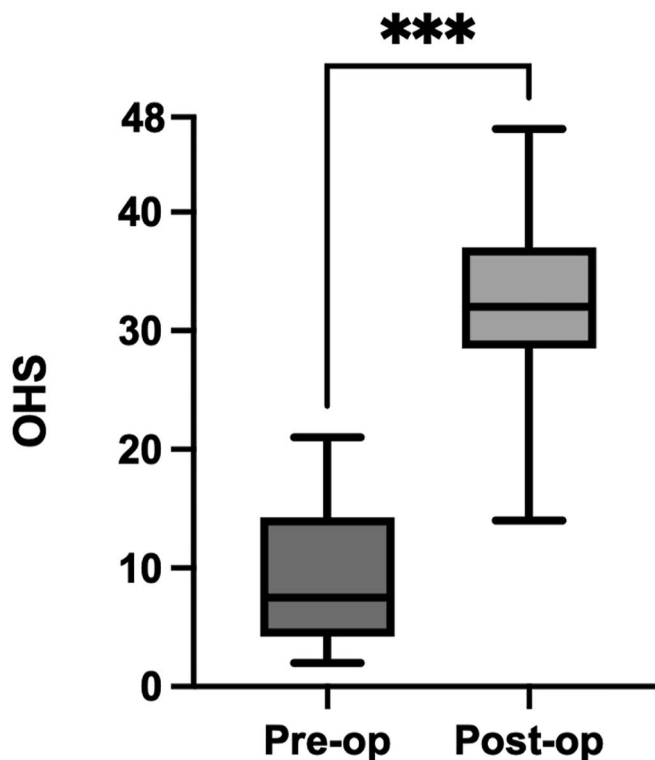


Fig. 3 Box plots showing the median preoperative and postoperative OHS values. The boxes represent the IQR, the horizontal lines within the boxes represent the median values, and the whiskers represent minimum and maximum values. \*\*\*P = 0.0001.

Downloaded from http://journals.lww.com/jbjs by BhdMfsePhkav1zEum1IQIN4a+KJLhEZgshHo4XMM0i0nCwCX1AWNYQpI0IHd33D00dRy7iTVSf14C3V4/OAVpDa8KKGKVOYmy+78= on 06/14/2023

## Pre- and post-op OHS by severity of disability

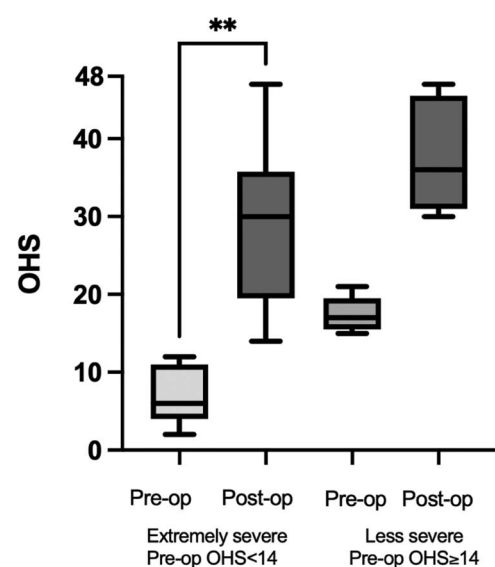


Fig. 4  
Box plots showing the median preoperative and postoperative OHS values for patients with a preoperative OHS of <14 and  $\geq 14$  ("extremely severe" and "less severe" disability, respectively). The boxes represent the IQR, the horizontal lines within the boxes represent the median values, and the whiskers represent minimum and maximum values.  $**P = 0.002$ .

Custom-made 3D-printed titanium cups enable surgeons to treat traditionally unreconstructible massive acetabular defects and thereby restore the ability of patients to walk. Monitoring custom-made implants is challenging because of the heterogeneity of implant designs, materials, manufacturers, and surgical techniques and tools.

In the present study, we reviewed the minimum 3-year results associated with the use of custom-made 3D-printed ProMade implants for the treatment of massive acetabular

defects. Our study indicates that these acetabular implants are a good option for the treatment of such defects, with a cumulative survival rate of 100%, a significant increase in the OHS overall, and excellent osseointegration. Our intermediate-term results are encouraging and provide a rationale for the use of these implants.

In a previous study, we demonstrated the accuracy and feasibility of surgical planning for patients with massive acetabular defects by comparing the planned and achieved positioning and orientation of custom 3D-printed implants in 6 degrees of freedom<sup>28</sup>. In another study, we found that, while challenging to treat, limb-length discrepancies and gait abnormalities in patients with large acetabular defects can be greatly improved with the aid of an accurate surgical plan, even when there is substantial preoperative superior migration of the failed implant component<sup>29</sup>. Other groups also have reported positive results in association with the use of these custom implants<sup>10,30</sup>. Here, in what we believe to be the largest such study to date, we have presented the minimum 3-year clinical and radiographic results associated with the use of 3D-printed implants for the treatment of Paprosky type-3B defects with or without pelvic discontinuity.

Radiography is the initial imaging modality for evaluating symptomatic hips for potential implant-related complications; however, it can obscure or simulate disease. When optimized to reduce metal artifacts, CT is superior to radiography for detecting, localizing, and quantifying osteolysis around the acetabulum as well as for measuring prosthetic component placement and migration, and therefore it is an excellent supplement to radiography for the evaluation of a reconstructed hip<sup>5,21</sup>.

It has been shown that small degrees of component migration can occur until satisfactory osseous ingrowth takes place without resulting in the eventual failure of the construct<sup>5,24,31</sup>. The present analysis of sequential radiographs, supplemented by cross-sectional images made  $>3$  years after reconstructive surgery, showed new bone formation at the interface of the implant with partial or total infilling of the residual defects over time. Moreover, no

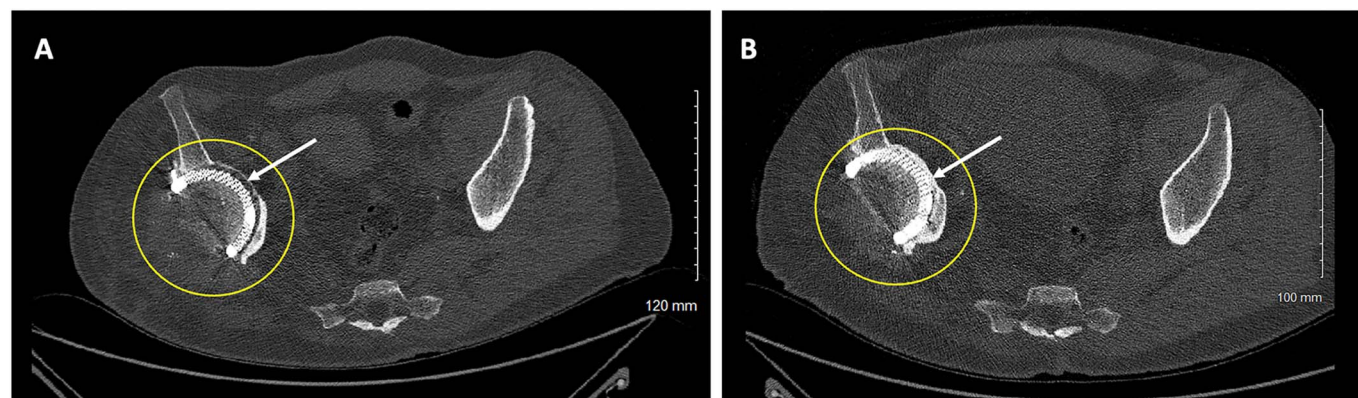
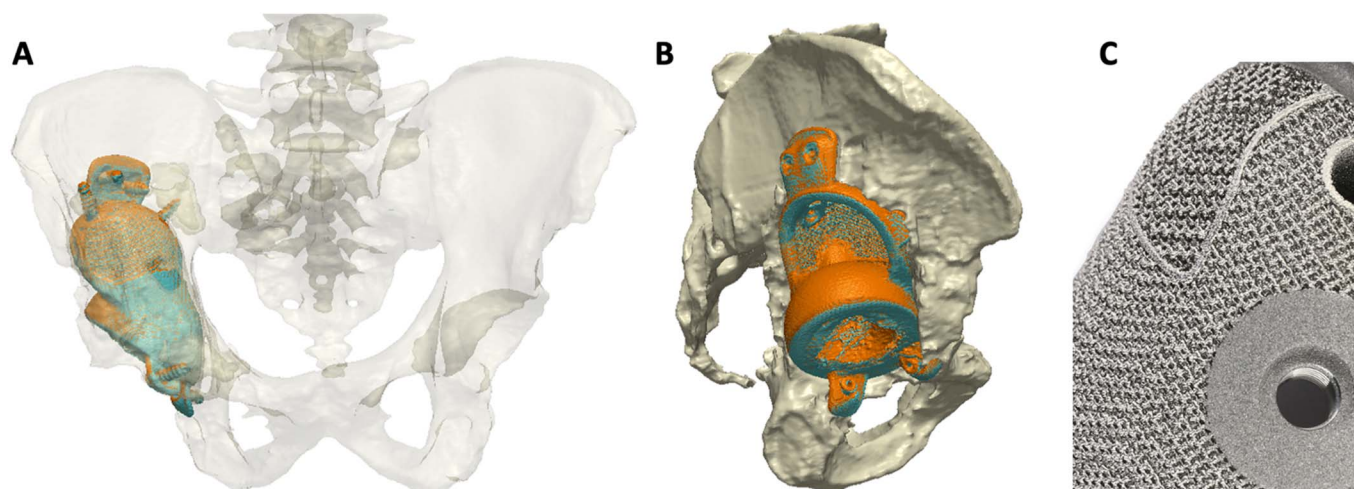


Fig. 5  
Axial CT scans, made 1 week postoperatively (Fig. 5-A) and 5 years postoperatively (Fig. 5-B), showing new bone formation at the site of the residual defect in the medial acetabular wall. Whereas space is seen between the implant and the bone in the left image (Fig. 5-A, arrow), direct contact between the implant and the adjacent bone is seen in the right image (Fig. 5-B, arrow).



**Fig. 6**  
**Figs. 6-A and 6-B** Anteroposterior (**Fig. 6-A**) and lateral (**Fig. 6-B**) CT scans showing the same implant at 1 and 5 years postoperatively. The scans from 2 distinct time points are overlaid to quantify the implant migration. The images show good alignment of the implant at both 1 year (blue) and 5 years (orange), confirming that no migration occurred between the 2 time points. **Fig. 6-C** Photograph showing the appearance of the trabecular titanium. The implants are made with use of electron beam sintering, which means that the structure is continuous. Research has shown that the pores within the material encourage osseous ingrowth.

implant migration was documented in this patient cohort, confirming the stability of these constructs at a follow-up of 3 to 6 years.

The survivorship of acetabular components used during revision THA is still considered unsatisfactory<sup>16</sup>. Acetabular component failure is the most common cause for a second revision<sup>32</sup>. The number of revision THAs, and therefore the number of acetabular component failures, is expected to increase in the future as a result of an increase in the number of primary THAs<sup>33,34</sup> and in the number of patients who are younger and more active<sup>35,36</sup>. Multiple treatment options have been proposed, including porous tantalum acetabular components with or without structural allograft or metal augments, standard cage reconstruction, cup-cage constructs, and custom-made implants. Cages, rings, or cup-cage constructs with acetabular structural allografts have had unsatisfactory results and high rates (12.5% to 37.5%) of short- and intermediate-term mechanical failure<sup>37,38</sup>. The literature on custom implants has shown that it can be difficult to achieve accurate acetabular implant positioning<sup>39-41</sup> and that high complication rates<sup>41-43</sup> can occur, especially when pelvic discontinuity is present. Chiarlone et al., in a systematic review of studies on the use of custom-made acetabular implants for revision THA, concluded that the intermediate-term clinical and radiographic outcomes have been satisfactory overall and that such implants represent a good option for the treatment of severe defects<sup>38</sup>. Accurate surgical planning on a case-by-case basis is crucial<sup>44</sup>.

Goriainov et al., in a recent study, reported favorable functional and radiographic outcomes in association with use of the aMace (Materialise) 3D-printed triflange implant with dual-mobility bearings for the treatment of massive acetabular defects<sup>45</sup>. That study included 19 patients with a mean follow-up of 53 months (range, 17 to 88 months). The authors reported significant functional improvement and 100% implant survivorship. They also noted that the application of autologous skeletal

stem cells on the backside of the implant may have enhanced bone formation as seen on radiographs. Our findings are comparable and provide evidence that the design, structure, and surface topography (such as porosity, pore size, and distribution) of ProMade custom implants are adequate for promoting the new bone formation and implant osseointegration necessary to lead to stable constructs over time without the use of skeletal stem cells.

We acknowledge that the present study had limitations. First, it was a retrospective series with a relatively small number of patients, although only the most complex acetabular revisions were selected for inclusion. Second, the heterogeneity of the morphology, bone stock, and bone quality of the acetabular defects made evaluation difficult and these factors could potentially affect the long-term results. However, the heterogeneity of the patient cohort was representative of the clinical reality. Third, bone stock and quality are challenging to study with use of CT imaging, with the main limitation being the metal artifacts created by the failed metal components during image creation. However, the segmentation of the CT scans was performed by experienced engineers.

### Conclusions

In the present study, we investigated the clinical and radiographic results associated with the use of a custom 3D-printed titanium implant with a dual-mobility bearing for the treatment of Paprosky type-3B defects with or without pelvic discontinuity. Our study showed good intermediate-term results after 3 to 6 years of follow-up, with an excellent implant survival rate, good clinical outcomes, and a low complication rate. On the basis of our findings, we believe that this type of implant is a viable option for the treatment of severe acetabular defects with or without pelvic discontinuity, offering substantial improvement in terms of both symptoms and quality of life. ■

NOTE: Our institution receives funding from the Arthroplasty for Arthritis Charity, The Maurice Hatter Foundation, the Royal National Orthopaedic Hospital Charity, the Rosetrees Trust, the Stonegate Trust, and the University College London Hospitals Biomedical Research Centre. No specific funding was received in support of this project.

Anna Di Laura, PhD<sup>1,2</sup>  
Johann Henckel, MD<sup>1</sup>  
Alister Hart, FRCSG(Orth)<sup>1,3</sup>

<sup>1</sup>Royal National Orthopaedic Hospital NHS Trust, Stanmore, United Kingdom

<sup>2</sup>Department of Mechanical Engineering, University College London, London, United Kingdom

<sup>3</sup>Institute of Orthopaedics and Musculoskeletal Science, University College London, London, United Kingdom

Email for corresponding author: a.hart@ucl.ac.uk

## References

- Evans JT, Evans JP, Walker RW, Blom AW, Whitehouse MR, Sayers A. How long does a hip replacement last? A systematic review and meta-analysis of case series and national registry reports with more than 15 years of follow-up. *Lancet*. 2019 Feb 16;393(10172):647-54.
- Collins JE. The long and winding road of revision hip replacement. *Lancet Rheumatol*. 2022;4(7):e452-3.
- Garellick G, Kärrholm J, Rogmark C, Herberts P. Swedish Hip Arthroplasty Register: Annual Report, 2012. 2012. Accessed 2023 Mar 9. <https://registercentrum.blob.core.windows.net/shpr/r/Annual-report-2012-HJBqtLpig.pdf>
- Gross AE, Goodman S. The current role of structural grafts and cages in revision arthroplasty of the hip. *Clin Orthop Relat Res*. 2004 Dec;(429):193-200.
- Sculco PK, Wright T, Malahias MA, Gu A, Bostrom M, Haddad F, Jerabek S, Bolognesi M, Fehring T, Gonzalez DellaValle A, Jiranek W, Walter W, Paprosky W, Garbuz D, Sculco T. The Diagnosis and Treatment of Acetabular Bone Loss in Revision Hip Arthroplasty: An International Consensus Symposium. *HSS J*. 2022 Feb;18(1):8-41.
- Bayliss LE, Culliford D, Monk AP, Glyn-Jones S, Prieto-Alhambra D, Judge A, Cooper C, Carr AJ, Arden NK, Beard DJ, Price AJ. The effect of patient age at intervention on risk of implant revision after total replacement of the hip or knee: a population-based cohort study. *Lancet*. 2017 Apr 8;389(10077):1424-30.
- D'Antonio JA, Capello WN, Borden LS, Bargar WL, Bierbaum BF, Boettcher WG, Steinberg ME, Stulberg SD, Wedge JH. Classification and management of acetabular abnormalities in total hip arthroplasty. *Clin Orthop Relat Res*. 1989 Jun;(243):126-37.
- Paprosky WG, Perona PG, Lawrence JM. Acetabular defect classification and surgical reconstruction in revision arthroplasty. A 6-year follow-up evaluation. *J Arthroplasty*. 1994 Feb;9(1):33-44.
- Di Laura A, Henckel J, Wescott R, Hothi H, Hart AJ. The effect of metal artefact on the design of custom 3D printed acetabular implants. *3D Print Med*. 2020 Aug 26;6(1):23.
- Aprato A, Giachino M, Bedino P, Mellano D, Piana R, Massè A. Management of Paprosky type three B acetabular defects by custom-made components: early results. *Int Orthop*. 2019 Jan;43(1):117-22.
- Sheth NP, Nelson CL, Springer BD, Fehring TK, Paprosky WG. Acetabular bone loss in revision total hip arthroplasty: evaluation and management. *J Am Acad Orthop Surg*. 2013;21(3):128-39.
- Barlow BT, Oi KK, Lee YY, Carli AV, Choi DS, Bostrom MP. Outcomes of Custom Flange Acetabular Components in Revision Total Hip Arthroplasty and Predictors of Failure. *J Arthroplasty*. 2016 May;31(5):1057-64.
- Berry DJ, Müller ME. Revision arthroplasty using an anti-protrusion cage for massive acetabular bone deficiency. *J Bone Joint Surg Br*. 1992 Sep;74(5):711-5.
- Solomon LB, Abrahams JM, Callary SA, Howie DW. The stability of the porous tantalum components used in revision THA to treat severe acetabular defects: a radiostereometric analysis study. *J Bone Joint Surg Am*. 2018;100(22):1926-33.
- Deere K, Whitehouse MR, Kunutsor SK, Sayers A, Mason J, Blom AW. How long do revised and multiply revised hip replacements last? A retrospective observational study of the National Joint Registry. *Lancet Rheumatol*. 2022 Jun 23;4(7):e468-79.
- Abrahams JM, Callary SA, Munn Z, Jang SW, Huang Q, Howie DW, Solomon LB. Acetabular Component Migration Measured Using Radiostereometric Analysis Following Revision Total Hip Arthroplasty: A Scoping Review. *JBJS Rev*. 2020 Apr;8(4):e0170.
- Marin E, Fusi S, Pressacco M, Paussa L, Fedrizzi L. Characterization of cellular solids in Ti6Al4V for orthopaedic implant applications: Trabecular titanium. *J Mech Behav Biomed Mater*. 2010 Jul;3(5):373-81.
- Majumdar T, Eisenstein N, Frith JE, Cox SC, Birbilis N. Additive manufacturing of titanium alloys for orthopedic applications: a materials science viewpoint. *Adv Eng Mater*. 2018;20(9):1800172.
- Dawson J, Fitzpatrick R, Carr A, Murray D. Questionnaire on the perceptions of patients about total hip replacement. *J Bone Joint Surg Br*. 1996 Mar;78(2):185-90.
- Abrahams JM, Kim YS, Callary SA, De Ieso C, Costi K, Howie DW, Solomon LB. The diagnostic performance of radiographic criteria to detect aseptic acetabular component loosening after revision total hip arthroplasty. *Bone Joint J*. 2017 Apr;99-B(4):458-64.
- Roth TD, Maertz NA, Parr JA, Buckwalter KA, Choplin RH. CT of the hip prosthesis: appearance of components, fixation, and complications. *Radiographics*. 2012 Jul-Aug;32(4):1089-107.
- Nakashima Y, Mashima N, Imai H, Mitsugi N, Taki N, Mochida Y, Owan I, Arakaki K, Yamamoto T, Mawatari T, Motomura G, Ohishi M, Doi T, Kanazawa M, Iwamoto Y. Clinical and radiographic evaluation of total hip arthroplasties using porous tantalum modular acetabular components: 5-year follow-up of clinical trial. *Mod Rheumatol*. 2013 Jan;23(1):112-8.
- Massin P, Schmidt L, Engh CA. Evaluation of cementless acetabular component migration. An experimental study. *J Arthroplasty*. 1989 Sep;4(3):245-51.
- Kosashvili Y, Backstein D, Safir O, Lakstein D, Gross AE. Acetabular revision using an anti-protrusion (ilio-ischial) cage and trabecular metal acetabular component for severe acetabular bone loss associated with pelvic discontinuity. *J Bone Joint Surg Br*. 2009 Jul;91(7):870-6.
- Gill TJ, Sledge JB, Müller ME. The Burch-Schneider anti-protrusion cage in revision total hip arthroplasty: indications, principles and long-term results. *J Bone Joint Surg Br*. 1998 Nov;80(6):946-53.
- De Martino I, Strigelli V, Cacciola G, Gu A, Bostrom MP, Sculco PK. Survivorship and clinical outcomes of custom triflange acetabular components in revision total hip arthroplasty: a systematic review. *J Arthroplasty*. 2019 Oct;34(10):2511-8.
- Kremers HM, Howard JL, Loechler Y, Schleck CD, Harmsen WS, Berry DJ, et al. Comparative long-term survivorship of uncemented acetabular components in revision total hip arthroplasty. *J Bone Joint Surg Am*. 2012;94(12):e82.
- Durand-Hill M, Henckel J, Di Laura A, Hart AJ. Can custom 3D printed implants successfully reconstruct massive acetabular defects? A 3D-CT assessment. *J Orthop Res*. 2020 Dec;38(12):2640-8.
- Di Laura A, Henckel J, Dal Gal E, Monem M, Moralidou M, Hart AJ. Reconstruction of acetabular defects greater than Paprosky type 3B: the importance of functional imaging. *BMC Musculoskelet Disord*. 2021 Feb 20;22(1):207.
- Angelini A, Trovarelli G, Berizzi A, Pala E, Breda A, Ruggieri P. Three-dimension-printed custom-made prosthetic reconstructions: from revision surgery to oncologic reconstructions. *Int Orthop*. 2019 Jan;43(1):123-32.
- Amenabar T, Rahman WA, Hetaimish BM, Kuzyk PR, Safir OA, Gross AE. Promising mid-term results with a cup-cage construct for large acetabular defects and pelvic discontinuity. *Clin Orthop Relat Res*. 2016 Feb;474(2):408-14.
- Avci S, Connors N, Petty W. 2- to 10-year follow-up study of acetabular revisions using allograft bone to repair bone defects. *J Arthroplasty*. 1998 Jan;13(1):61-9.
- Kurtz S, Ong K, Lau E, Mowat F, Halpern M. Projections of primary and revision hip and knee arthroplasty in the United States from 2005 to 2030. *J Bone Joint Surg Am*. 2007;89(4):780-5.
- Kurtz S, Mowat F, Ong K, Chan N, Lau E, Halpern M. Prevalence of primary and revision total hip and knee arthroplasty in the United States from 1990 through 2002. *J Bone Joint Surg Am*. 2005;87(7):1487-97.
- Polkowski GG, Callaghan JJ, Mont MA, Clohisy JC. Total hip arthroplasty in the very young patient. *J Am Acad Orthop Surg*. 2012;20(8):487-97.
- Skyttä ET, Jarkko L, Antti E, Huhtala H, Ville R. Increasing incidence of hip arthroplasty for primary osteoarthritis in 30- to 59-year-old patients. *Acta Orthop*. 2011 Feb;82(1):1-5.
- Marx A, Beier A, Richter A, Lohmann CH, Halder AM. Major acetabular defects treated with the Burch-Schneider antiprotrusion cage and impaction bone allograft in a large series: a 5- to 7-year follow-up study. *Hip Int*. 2016 Nov 10;26(6):585-90.
- Chiarlone F, Zanirato A, Cavagnaro L, Alessio-Mazzola M, Felli L, Burastero G. Acetabular custom-made implants for severe acetabular bone defect in revision total

hip arthroplasty: a systematic review of the literature. *Arch Orthop Trauma Surg.* 2020 Mar;140(3):415-24.

**39.** Citak M, Kochsiek L, Gehrke T, Haasper C, Mau H. The 3D-printed patient-specific acetabular component in the management of extensive acetabular defect with combined bilateral pelvic discontinuity. *Seminars in Arthroplasty.* 2016;27(4):272-276.

**40.** Citak M, Kochsiek L, Gehrke T, Haasper C, Suero EM, Mau H. Preliminary results of a 3D-printed acetabular component in the management of extensive defects. *Hip Int.* 2018 May;28(3):266-71.

**41.** Myncke I, van Schaik D, Scheerlinck T. Custom-made triflanged acetabular components in the treatment of major acetabular defects. Short-term results and clinical experience. *Acta Orthop Belg.* 2017 Sep;83(3):341-50.

**42.** Wind MA Jr, Swank ML, Sorger JI. Short-term results of a custom triflange acetabular component for massive acetabular bone loss in revision THA. *Orthopedics.* 2013 Mar;36(3):e260-5.

**43.** DeBoer DK, Christie MJ, Brinson MF, Morrison JC. Revision total hip arthroplasty for pelvic discontinuity. *J Bone Joint Surg Am.* 2007;89(4):835-40.

**44.** Weber M, Witzmann L, Wieding J, Grifka J, Renkawitz T, Craiovan B. Customized implants for acetabular Paprosky III defects may be positioned with high accuracy in revision hip arthroplasty. *Int Orthop.* 2019 Oct;43(10):2235-43.

**45.** Goriainov V, King LJ, Oreffo ROC, Dunlop DG. Custom 3D-Printed Triflange Implants for Treatment of Severe Acetabular Defects, with and without Pelvic Discontinuity: Early Results of Our First 19 Consecutive Cases. *JB JS Open Access.* 2021 Oct 21;6(4):e21.00057.