Current and Future Advances in Surgical Therapy for Pituitary Adenoma

Authors:

Danyal Z Khan[1, 2], John G Hanrahan[1, 2], Stephanie E Baldeweg[3, 4], Neil L Dorward[1], Danail Stoyanov PhD[2,5], Hani J Marcus[1, 2].

Affiliations:

[1] Department of Neurosurgery, National Hospital for Neurology and Neurosurgery, London, UK.

[2] Wellcome / EPSRC Centre for Interventional and Surgical Sciences, University College London, London, UK.

[3] Department of Diabetes & Endocrinology, University College London Hospitals NHS Foundation Trust, London, UK.

[4] Centre for Obesity and Metabolism, Department of Experimental and Translational Medicine, Division of Medicine, University College London, London, UK.

[5] Digital Surgery Ltd, Medtronic, London, UK.

Corresponding author:

Hani J Marcus
National Hospital for Neurology and Neurosurgery & Wellcome / EPSRC Centre for Interventional and Surgical Sciences, University College London
London, United Kingdom
Email: h.marcus@ucl.ac.uk

Keywords:

Pituitary adenoma, transsphenoidal, artificial intelligence, robotics, augmented reality, digital health.

Counts:

Abstract: 289
Manuscript: 5637 words (excluding references, tables, and figures)
Number of references: 141

Running head:

Advances in Pituitary Adenoma Surgery

Abbreviations

eTSA: Endoscopic transsphenoidal approach
AI: Artificial Intelligence
ML: Machine learning
CV: Computer vision
NLP: Natural Language Processing
IDEAL: Idea, Development, Exploration, Assessment, Long-term study
CSF: Cerebrospinal fluid
MRI: Magnetic resonance imaging
US: Ultrasound
CT: Computed tomography
AR: Augmented reality
VR: Virtual reality
GRE: Gradient response echo
PET: Positron emission tomography
FDG: Fluorodeoxyglucose

Funding:

No specific funding was received for this piece of work. JGH, DZK, DS and HJM are supported by the Wellcome (203145Z/16/Z) EPSRC (NS/A000050/1) Centre for Interventional and Surgical Sciences, University College London. DZK is supported by an NIHR Academic Clinical Fellowship and a Cancer Research UK Predoctoral Fellowship. JGH is supported by an NIHR Academic Clinical Fellowship. HJM is also funded by the NIHR Biomedical Research Centre at University College London. This research was funded in whole, or in part, by the Wellcome Trust. For the purpose of Open Access, the authors have applied a CC BY public copyright license to any Author Accepted Manuscript version arising from this submission.

Conflict of Interest:

All authors certify that they have no affiliations with or involvement in any organization or entity with any financial interest (such as honoraria; educational grants; participation in speakers' bureaus; membership, employment, consultancies, stock ownership, or other equity interest; and expert testimony or patent-licensing arrangements), or non-financial interest (such as personal or professional relationships, affiliations, knowledge or beliefs) in the subject matter or materials discussed in this manuscript.

Abstract

The vital physiological role of the pituitary gland, alongside its proximal critical neurovascular structures means pituitary adenomas cause significant morbidity or mortality. Whilst enormous advancements have been made in the surgical care of pituitary adenomas, treatment failure and recurrence remain challenges. To meet these clinical challenges, there has been an enormous expansion of novel medical technologies (e.g. endoscopy, advanced imaging, artificial intelligence). These innovations have the potential to benefit each step of the patient journey, and ultimately, drive improved outcomes.

Earlier and more accurate diagnosis addresses this in part. Analysis of novel patient data sets, such as automated facial analysis or natural language processing of medical records holds potential in achieving an earlier diagnosis. After diagnosis, treatment decision-making and planning will benefit from radiomics and multimodal machine learning models. Surgical safety and effectiveness will be transformed by smart simulation methods for trainees. Next-generation imaging techniques and augmented reality will enhance surgical planning and intraoperative navigation. Similarly, the future armamentarium of pituitary surgeons, including advanced optical devices, smart instruments and surgical robotics, will augment the surgeon's abilities. Intraoperative support to team members will benefit from a surgical data science approach, utilising machine learning analysis of operative videos to improve patient safety and orientate team members to a common workflow. Postoperatively, early detection of individuals at risk of complications and prediction of treatment failure through neural networks of multimodal datasets will support earlier intervention, safer hospital discharge, guide follow-up and adjuvant treatment decisions.

Whilst advancements in pituitary surgery hold promise to enhance the quality of care, clinicians must be the gatekeepers of technological translation, ensuring systematic assessment of risk and benefit. In doing so, the synergy between these innovations can be leveraged to drive improved outcomes for patients of the future.

1. Background

Pituitary adenomas are among the most common intracranial tumours, with an estimated prevalence of up to 20% [1, 2]. They are slow-growing tumours, with numerous subtypes, broadly divided into non-functioning adenomas and functioning adenomas[1, 2]. They may present incidentally, through mass effect (e.g. visual decline) or hormone imbalance (e.g. Cushing's disease), therefore potentially causing significant morbidity, quality of life reduction and death if left untreated[1-3].

Management paradigms for pituitary adenomas have been dynamic, with advances in imaging, hormone therapies and surgical technology impacting guidelines significantly[4-6]. Recently, numerous practice variations were adapted in light of the COVID-19 virus, including alterations in interventional procedures, hormonal therapy and monitoring for safe service delivery to pituitary patients[7, 8]. The foundation of this agile and advancing treatment landscape is the collaboration of the multidisciplinary team caring for patients with pituitary adenomas in concert[7, 8]. A further example of this is the emergence of Pituitary Centres of Excellence, consolidating the necessary expertise into fewer, but resultantly higher volume, specialist centres – to drive improvement in patient outcomes[9]. This is particularly relevant for surgical management of these tumours – which has the potential to offer cure, and thus, is the cornerstone of treatment for the majority of symptomatic pituitary adenomas[9-12]. Transsphenoidal surgery is technically demanding with steep learning curves, and thus, service streamlining to maximise surgical team experience and the resulting creation of dedicated subspecialty training programmes has helped to improve operative outcomes[9-12].

Despite these organizational and technological improvements in management, many series describe high rates of treatment failure and recurrence - in functioning adenomas (e.g. up to 20% in Cushing's Disease) and non-functioning adenomas (e.g. up to 50% on long term follow-up)[13, 14]. This is influenced by significant challenges across the patient pathway from diagnosis to follow-up. To meet these clinical challenges, there have been numerous advances in the surgical treatment of pituitary adenomas, with the field benefiting from the recent enormous expansion of novel medical technologies, such as endoscopy, advanced imaging and artificial intelligence, as well as advances in medical therapies[15, 16]. These innovations have the potential to benefit each step of the patient journey, and ultimately, drive improved outcomes.

Thus, we aim to explore the scope of existing challenges and potential technological advances in pituitary adenoma surgery – distilling the patient pathway of the future from 1) diagnosis and preoperative planning, 2) surgical proficiency and 3) postoperative monitoring.

2. Advances in Preoperative Care

The pituitary adenoma patient pathway starts with a timely and accurate diagnosis, followed by an individualized assessment of suitability for treatment. Despite best efforts, there exist numerous barriers to the multidisciplinary team achieving consistent and universal early diagnosis and treatment. Technological innovations may hold the solution to many of these barriers, and herein we provide examples with potential translational value (Table 1).

2.1 Diagnosis

2.1.1 Challenges

The question of a diagnosis of pituitary adenoma is usually raised by general practitioners, ophthalmologists, neurologists, and endocrinologists at the first line[17]. However, the often incidental, insidious and non-specific presentation of many pituitary adenomas means this is often a challenging diagnosis to make[18]. Ultimately, diagnosis requires the unification of a wide array of heterogeneous manifestations from various clinicians of differing specialist backgrounds to raise suspicion of the underlying tumour. Thus, diagnostic delay is common, considerable, for example, up to 5-10 years in acromegaly, and compounded by socio-economic and cultural factors[17, 18]. During this lag, the tumour grows, making surgical resection more difficult, particularly if there is invasion into the cavernous sinus, whilst in functioning tumours systemic complications of hormone imbalance accumulate[19]. This in turn can result in irreversible morbidity and socioeconomic decline, further perpetuating issues with healthcare access and diagnostic delay[20]. Thus, earlier diagnosis can maximise the chance of cure, and reduce the socio-economic impact, systemic morbidity and mortality associated with pituitary adenomas.

2.1.2 Potential solutions

Computer-aided diagnosis allows high throughput analysis of large amounts of data (e.g. symptoms and signs), detection of otherwise hidden relationships, and is allegedly free of many human cognitive biases (although subject to an alternative set of biases). These systems are particularly useful in identifying subtle deviations from the norm, and analysis of image or video data. One example is computer-based facial analysis, which has the potential to detect subtle and slowly evolving changes in facial morphology which would otherwise be missed by patients, families and clinicians [21-24]. Growth hormone-producing functioning adenomas causing acromegaly may be an ideal candidate for its use; facial and acral features are not only the most common symptoms but are typical and tend to manifest early in the disease course [17, 25-27].

Such analysis involves the identification of key facial landmarks; analysis of landmark relationships in space and their changes across time; and association of these changes with disease states[27]. The software has displayed accuracies >80% in recognizing patients with acromegaly and controls – often exceeding the diagnostic performance of generalist and expert physicians [21, 27-29]. Some software particularly performs well in milder forms of the disease, with more subtle facial changes, again outperforming clinicians [21]. The principal limitation of facial analysis is the manual landmark and feature extraction, which is labour-intensive and resource-heavy [21]. Advances in artificial intelligence, specifically machine learning (ML) and computer vision (CV), have allowed the automation of facial analysis to a granular level [23, 27]. Similarly, there have been advances in smartphone technology, with high-quality 2D digital cameras now almost ubiquitous. According to a recent Ofcom report, it is estimated that >80% of UK households own a smartphone with 71% of those in the lowest socioeconomic bracket still owning a smartphone [30]. The prevalence of these devices has resulted in a massive and growing volume of facial photographic data. This data, combined with emerging deep learning approaches to image analysis, provides an opportunity to better characterize the dynamic facial phenotype of acromegaly [27]. Its applications are widespread, for example, in passport renewal or government identity services, where it could prompt individuals to attend an early medical review based on facial analysis alone. This offers the potential for widespread population screening (e.g. via smartphone self-photos), particularly in populations that may have faced disproportionate difficulties in accessing healthcare (e.g. ethnic minorities).

Another example of computer-aided diagnosis is the use of natural language processing (NLP), which has the ability to analyse and integrate large volumes of unstructured text data from various data sources, for example, GP records, specialist letters and recent discharge summaries. NLP has the potential to automatically analyse medical documentation for clusters of features associated with undiagnosed pituitary adenomas, and flag patients for further review and potential earlier diagnosis[31, 32]. There is a wide range of accompanying utilities, including economic benefits (e.g. reducing the time and resource burden of searching individual medical files) and clinical decision support via predicting clinical outcomes using further integration with ML algorithms[33].

2.2. Surgical Decision Making

2.2.1 Challenge

The natural history of pituitary tumours even within subtypes is considerably variable. The prediction of the recovery of endocrine and neurological deficits, particular after the intervention, remains difficult. These factors influence the decision on when or when not to operate, and the optimal timing of this intervention, often requiring discussion at multidisciplinary meetings. This is particularly the case for the growing elderly population, who often have a narrower window for intervention owing to accumulating co-morbidities, and are at higher risk for intervention, but are similarly higher risk for decompensation if left without treatment[17]. Similarly, for medical therapies, for example, dopamine agonists for prolactinomas, identification of those at risk of medication side effects or those with partial or non-response is important for minimising disease progression and further treatment planning.

2.2.2 Potential solutions

Similar to computer-aided diagnosis, the risk modelling and prognostication for the individual patient involves the assimilation of complex multimodal data with a high number of variables[34-36]. Machine learning models, particularly neural networks, outperform the traditional statistical methods by leveraging their ability to utilise complex non-linear relationships between these prediction variables[34-36]. There is emerging evidence of the potential benefit and advantage of this technology in the oncology setting – with some ML models being able to perform risk stratification prior to intervention more accurately than risk calculators based on traditional statistical models[37]. Similarly, through the integration of multiple data types (e.g. histopathological, imaging and electronic health record notes), ML models have been able to push the boundaries of treatment response prediction, and even discover new features of prognostic significance[38].

Within pituitary adenoma research, numerous models have been developed to predict complications, gross total resection and postoperative hyponatraemia[39-41]. ML prediction of resistance to somatostatin analogues in acromegaly holds promise in guiding more personalized treatment regimes, relying on an array of input variables from patient characteristics, imaging findings, biochemistry, and genetic factors[42-45]. Similarly, radiomics modelling using MRI has identified biomarkers of non-responsiveness to dopamine agonists to treat prolactinoma, indicating the potential to determine groups for earlier consideration of surgical resection[46]. Similarly, radiomics have been demonstrated to aid response to radiotherapy, offering novel means of selecting and counselling patients[47].

However, many of these studies have been based on unidimensional text/numeric data only or imaging data only, and the next steps involve the integration of multimodal granular biomarkers into these models. This dataset would ideally be standardised to establish a core set of preoperative (demographics, co-morbidities, functional status, visual function, endocrine status, histopathology, imaging), operative, and outcome data. Such standardisation has been achieved through Delphi consensus processes and will be important for the pooling of data across centres, thus improving ML model performance and generalisability[35, 48, 49]. The curation of high-quality and high-volume clinical datasets (e.g. national registries) will build on this, with concurrent optimisation of electronic medical record systems for efficient data harvesting[35, 48]. Finally, model development and reporting must also be standardised, and guidelines such as the TRIPOD framework (transparent reporting of a multivariable prediction model for individual prognosis or diagnosis) must be used for model reproducibility and interpretability[50]. Clinicians must lead this data stewardship, ensuring it is representative of their treating population, so that the resulting models provide an accurate individualised guide to surgical counselling and decision-making[36].

2.3. Surgical Planning

2.3.1 Challenge:

Preparation for pituitary adenoma surgery involves a decision regarding objectives (e.g., total resection, or debulking to decompress surrounding structures), which informs a surgical plan, which must then be executed effectively and safely. In certain cases, surgical planning is particularly challenging, for example in Cushing's disease, the ACTH -producing microadenoma can sometimes be difficult or impossible to visualise preoperatively and intraoperatively[3]. Here, our ability to visualise the tumour is central to an effective surgical resection that spares surrounding normal tissues. Despite advances in imaging and the use of auxiliary investigations (e.g. petrosal sinus sampling), failure of a planned lesionectomy is not uncommon, and progression to more radical surgery (e.g. hemi- or total hypophysectomy) is required, or medical or radiation therapy if this fails. Furthermore, in cases where lesion visualisation generation of an operative plan is more straightforward, building the surgical proficiency to remove the lesion is challenging – owing to the technically demanding, steep learning curve and comparatively low volume nature of this operation[9, 51]. For surgeons in training, the pandemic has made the acquisition of the necessary surgical skills, particularly challenging[52].

2.3.2 Potential solutions:

Tumour visualisation and the surgical strategy that follows will be revolutionised by advances in imaging technology and our ability to analyse the data this generates. Next-generation advanced imaging may allow better lesion detection preoperatively. For example, advances in gradient echo sequences and 7-tesla MRI allow higher resolution imaging, and may highlight otherwise undetectable microadenomas[53, 54]. Similarly, molecular imaging techniques have improved lesion detection by leveraging the metabolic properties of these tumours, for example, FDG and Methionine PET imaging for Cushing's disease[55-57]. The application of machine learning has demonstrated the ability to augment the data generated by these imaging modalities, using scene reconstruction to generate thinner slices with noise reduction, improving target area resolution[58, 59]. Machine learning can also improve our ability to analyse this data, particular when a data-driven voxel-by-voxel radiomics approach is used. This is a powerful combination of technologies, potentially allowing highly accurate detection of even the most challenging microadenomas, fine delineation of tumour invasiveness, or prediction of intra-tumoral characteristics, for example, histological subtypes and proliferative index[60-62].

Once the surgical plan is generated, the precise execution of this, particularly for surgeons in training, is a formidable beast. Surgical simulation may be a pandemic-proof answer to this problem. The spectrum of simulators available for pituitary surgery is wide, from low-fidelity physical simulators using bell-peppers, to high-fidelity simulators utilising 3D-printed advanced materials, sometimes to patient-specific design[63, 64]. Virtual and augmented reality platforms often require less surgical equipment, can be dynamic (i.e. incorporate fluid pulsations), and have been generated at a patient-specific level, but are limited by their general lack of sufficient haptic feedback[65, 66]. Next-generation models will combine advanced materials more representative of human tissue with augmented reality and artificial intelligence for smart simulation – which track and react to surgical actions (e.g. bleed or leak CSF), and automatically assess surgical skills.

3. Improving Operative Efficiency, Effectiveness & Safety

After work-up, a decision for operative management and the careful planning of tumour resection; comes the execution of the operation. The operating *theatre* is aptly named, and represents the coordinated *performance* by surgeons (often from multiple specialities), anaesthetists and nurses to achieve a singular goal, an efficient, effective and safe operation. The Royal College of Surgeons Future of Surgery report highlights the technologies likely to be most impactful – advanced endoscopes, robotics, augmented reality, virtual reality, and artificial intelligence – integrated together, as we move into the era of "smart" operating theatres[67]. Pituitary surgery is no exception, and there are numerous unmet clinical needs which may benefit from these innovations. It is worth noting that most introduction of technology is not systemically assessed, this stands true for many technologies used in endoscopic endonasal surgery [68]. The IDEAL (Idea, Development, Exploration, Assessment and Long-term follow-up) framework provides a structured pathway to guide the proportionate evaluation of medical devices (based on their risk profile) and safe stepwise clinical assessment of benefit[69-71]. Pituitary adenoma surgery has potentially serious complications, and the introduction of any technology must be carefully assessed using such a framework and encompass operating team human factors[69-71].

3.1. Navigation

3.1.1 Challenges

Pituitary adenomas are located in an anatomically rich area, with life-sustaining vessels (e.g. carotids) and other critical structures (e.g. optic nerves) located within a densely packed region. This anatomy is distorted and sometimes encased by tumours. Intraoperative navigation helps to guide surgeons as to where the tumour and these structures are. This is most commonly done using image-guided systems which require specialised scans, and preoperative registration. They provide guidance through the placement of a probe in the field and cross-referencing the position of this probe with its predicted position on the preoperative imaging. Whilst this technology has revolutionised neurosurgery, including pituitary surgery, particularly during challenging/non-standard cases, it has numerous issues. These include interruption to the surgical workflow, for example, the need for registration preoperatively and for intraoperative pauses to use the navigation probe. Additionally, the relative inaccuracy after structures shift intraoperatively (e.g. after tumour debulking) limits the utility of the navigation as the operation progresses.

3.1.2 Potential solutions

Real-time navigation, that is, a system that provides navigation data which is representative of the surgical field at that moment in time, has been explored using various technologies. Intraoperative MRI is the most studied modality and integrates with existing image guidance systems to update the imaging on which it is based, so that intraoperative tissue shifts are accounted for. Newer high-field MR systems are proposed to particularly highlight the "resectable residuum" – tumour remnants which are removable safely, without a high risk of damage to surrounding neurovascular structures[72]. Numerous studies suggest it resultantly improves the extent of resection and assists in the assessment of neurovascular decompression, for example, chiasmal decompression in those with visual loss[73-75]. Similarly, it provides immediate feedback and quality control to surgeons, which may have benefits in training and flattening of operative learning curves[72, 76]. However, intraoperative MRI is resource-heavy, requiring changes to most of the operating room infrastructure, for example, magnetic shielding and acquiring MR-compatible equipment[72]. Furthermore, it significantly interrupts operative workflow, which has to cease for imaging to take place and thus prolongs both surgical and anaesthetic time[72, 77].

Intraoperative ultrasound addresses some of the disadvantages of intraoperative MRI – being less disruptive to workflow, less time-consuming, and significantly cheaper. Unlike intraoperative micro-Doppler (used for internal carotid artery identification), it seeks to assist with tumour identification (e.g. Cushing's disease microadenoma) and delineation of the tumour gland interface[78]. Initial issues highlighted with this technology included large probe size, image resolution quality and operator dependency. Recent improvements in probe miniaturization and image quality have made this technology a candidate for translation, with first-in-human studies (IDEAL Stage 1) suggesting the feasibility and safety of this device[79].

Synergy with augmented reality (AR) platforms is proposed to improve the efficiency of these navigation systems even further, allowing the integration of information from imaging modalities such as MRI onto surgical display fields (e.g. endoscopic video) via overlay[80-82]. These systems do not require probes, or extra monitors, and build 3D models directly onto the surgical field for more intuitive navigation with improved 3-dimensional perception and minimal disruption to operative workflow[80-82]. Studies suggest this may help achieve more tumour resection with less collateral neurovascular damage, particularly in revision cases with distorted anatomical landmarks[80-82]. For this AR to be real-time, i.e. accounting for intraoperative tissue shifts, then up-to-date information must be fed into the system via intraoperative imaging as above, or alternatively, through a combination of preoperative imaging and computer vision-based analysis of intraoperative video (e.g. to detect intraoperative anatomy and events), which is discussed in detail later.

3.2 Visualisation

3.2.1 Challenges

Pituitary tumours, housed in an anatomically complex region of the skull base, at the end of a long and narrow surgical corridor, command rich visualisation during attempts at surgical resection. This is compounded by the fact that many tumours can distort this anatomy, and be composed of various consistencies and subcomponents, making distinguishment of tumour margins and extent difficult. Additionally, many tumours can be too small to distinguish macroscopically from normal tissue[72]. It is no surprise that the advent of endoscopy is regarded by many as the greatest technological advance in modern pituitary surgery, boosting a surgeon's visualisation intraoperatively, with a wider and more illuminated field of view. However, most endoscopes are 2D, requiring depth perception estimation by surgeons through anatomical and motion cues. Similarly, tumour-normal tissue interface is often challenging, particularly for microadenomas, invasive tumours and revision surgeries.

3.2.2 Solutions

Augmentation of surgical visualisation technology is a rapidly expanding space, with improvements in image quality, ergonomics, and synergy with complementary technologies among the principal drivers for this expansion. High definition (including 4k Ultra HD), like in our living rooms, affords state-of-the-art image resolution, and in the context of pituitary surgery, allows better discrimination of tumour and gland with a potential for reducing unexpected tumour residuals (when compared to standard definition cameras)[83, 84]. Similarly, 3D endoscopes seek to improve the appreciation of depth through the added shape and contour information provided to surgeons. Whilst in many endoscopes, this is simulated digital depth perception rather than the binocular stereopsis of the microscope, numerous studies support its utility in complex or extended endonasal procedures, although there are notable issues such as motion sickness for some users and potential disruption to workflow due to the need for increased intraoperative cleaning of the endoscope (e.g. nasal mucosa blood may block one of the two cameras within the endoscope required for 3D vision)[85, 86]. However, the translation of these intraoperative benefits into postoperative outcomes, when compared with 2D endoscopy, is less well established and calls for further systematic, structured assessment (i.e. via the IDEAL pathway)[70, 87].

Nevertheless, these advances have the potential for synergy with complementary innovations. For example, 3D endoscopy may provide a richer foundation for a more detailed AR overlay in the future. Similarly, high-definition scopes may potentiate the benefits of intraoperative tracers and dyes. Numerous chemicals have been tested, such as 5-ALA (no demonstrated benefit in pituitary adenoma tumour identification), ICG (may help in identifying functional adenomas and internal carotid arteries), OTL38 with near-infrared imaging (may help in identifying non-functioning adenomas with high folate receptor expression) and fluorescein (may help in identifying functional adenomas)[88-90] Innovation in advanced optical imaging is particularly exciting and builds on the use of these tracers and dyes. For example, probe-based confocal endomicroscopy, allowing granular tissue characterisation based on microstructural features, can be used with fluorescein to digital diagnostic biopsies of pituitary tumours[91-93]. Similarly, hyperspectral imaging leverages the ability to analyse the chemical composition of tissue to allow more precise tumour delineation[72, 93, 94].

Recently, there has been increasing awareness of the need to incorporate surgical ergonomics into device development[70, 95]. One example is the use of exoscopes, which when compared to microscopes, allow a more comfortable posture during surgery, with a smaller operating room footprint, both optical and digital magnification, and the potential for integration with concurrent endoscope use via a split screen. However, concerns with the resolution (when compared with a microscope) and the width of visualisation (when compared with the endoscope) have hampered their routine uptake[96, 97] Furthermore, ergonomics-orientated robotic devices such as endoscope holders and surgical armrests (for the endoscope holding arm) have been developed to reduce surgeon's fatigue and stabilized the surgeon's hand during pituitary surgery[98]. Similarly, robotic endoscopes with adjustable viewing angles (15-90 degrees) have the potential to allow wider visualization without the need for switching between multiple scopes[99].

3.3 Instruments

3.3.1 Challenges

The narrow nasal surgical corridor which has challenged visualisation also tests the capabilities of contemporary surgical instruments. Limitations imposed by this restrictive space and the fulcrum effect results in restricted instrument reach, and co-axial movement of the instruments with challenging surgical triangulation[95]. This not only contributes to the steep learning curve of pituitary surgery but also makes invasive tumours, for example, those extending into the cavernous sinus very difficult to access. More generally, the forces used in neurosurgery, including pituitary tumour resection, are amongst the lowest of all surgical specialities[100]. Thus, not only must these surgical tools be small enough the pass through the nasal passage and dextrous enough to provide bimanual control, but they must also be particularly precise with sensitive haptic feedback so that tool tissue forces are carefully controlled[95].

3.3.2 Potential solutions

Recent advances in engineering and materials have allowed miniaturisation whilst retaining precise kinematic control, careful force control and haptic feedback in surgical robotics, and will herald a new era of devices capable of meeting the needs of neurosurgical procedures. Surgical robotics can be categorised into supervisory controlled (pre-programmed to carry out a specific task), telesurgical (surgeon remotely controls the robot in real-time) and shared control (surgeon physically controls the robot in real-time). The most successful robotic system, the Da Vinci (Intuitive Surgical) is a telesurgical system, and despite efforts to miniaturise the system, the endonasal approach presents too narrow of a corridor for its use, although some surgeons have used the system transorally[101]. Numerous other tele-surgical systems are in development but only preclinically. For example, systems with flexible tubular shafts which fit within the nose and move using tendon pulley systems with concentric tubes, contorting the tubular shaft and bringing the end effector (i.e. grasper) to the surgical target with 6 degrees of freedom[102]. Flexible robots are the cornerstone of soft robotics, a sub-field which uses bio-inspired design and non-rigid materials to create systems which are more manoeuvrable (e.g. snake-like) and less damaging to surrounding tissue[103]. Conceptually, these devices are well suited to the delicate nature of neurosurgery, but issues with the controllability and sterilizability of current technology are barriers to development and adoption[103].

More recently, there has been an explosion in the development of "smart instruments" (i.e. shared control robotic systems) which are wielded by the surgeon and augment their abilities[95]. One example is the use of articulated instruments which increase surgical access beyond the straight axes of the nasal corridor, with joystick-like control of the end-effector[104, 105]. Pre-clinical (IDEAL Stage 0) validation of these instruments is promising, outperforming standard rigid surgical instruments in terms of dexterity, control and ergonomics, whilst having the added ability to gather important surgical data through sensors (e.g. force applied) which could be feedback to surgeons in real-time[106, 107].

Ultimately, whether these instruments are rigid or soft, telesurgical or shared-control, as invasive and potentially high-risk devices they must undergo proportionate rigorous and systematic assessment for effectiveness, safety and cost-benefit, prior to integration into operating theatres of the future[70].

3.4 Team Decision Support

3.4.1 Challenges

Pituitary surgery is technically challenging, and has steep learning curves, with practice variations across centres and countries[11, 108-110]. This leads to varying surgical outcomes along the learning curve and from centre to centre. This presents significant training challenges and raises the question as to which aspects of practice (i.e. surgical steps) are optimum and how best to learn them. However, no two surgeries are the same, and therefore interrogating differences in the performance of surgeries and generating comparative evidence between surgical techniques and technologies is challenging. Intraoperative decisions are therefore often via expert apprenticeship or reactively via trial and error. Historically, the resources required to extract the necessary data from surgical procedures to a granular level, and the number of variables and volume of data needed for meaningful analysis, meant answering these training and practice challenges was almost totally infeasible.

3.4.2 Potential solutions

The first step to answering many training and practice challenges in pituitary surgery and providing guidance to surgeons of the future is surgical workflow analysis[108]. This involves systematically breaking down operations into key phases and steps, codifying surgery into its fundamental building blocks. There is international consensus on the key phases and steps of pituitary surgery, but analysing surgeries in this fashion, for example, via review of operative videos, is very time and labour-intensive when done manually[108, 111, 112]. By applying machine learning and computer vision to operative videos, we can perform this workflow analysis automatically and accurately[111-113].

This AI-driven analysis has numerous potential benefits. Firstly, it generates a library of annotated videos and performance metrics (e.g., step duration and order) which can be reviewed by trainees and used for individualized coaching on surgical technique (i.e., directing training to particular steps of concern)[113, 114]. Secondly, this technology can be used in real-time and presented to the surgical team using intraoperative displays with the AI predicting current and future steps. This may improve operational efficiency during surgery, orchestrating the entire team to a common workflow, for example, highlighting the instruments needed next to the scrub technician or upcoming critical steps to the anaesthetists[113].

Furthermore, this technology provides the foundation for numerous avenues of further analysis. For example, computer vision-based detection of anatomical structures (e.g. optic nerves or carotid arteries) is triangulated to particular surgical steps, such as high-risk steps during tumour resection where the risk of neurovascular injury is highest. This information can again be used for educational retrospective review for trainees or in real-time, to guide surgeons intraoperatively. Through recognition of the normal pituitary gland, delineating tumour margins may be easier. Similarly, the recognition and tracking of surgical instrument use and movement across critical operative steps may provide useful feedback for surgical trainees on their economy of movement and optimal kinematics[115]. This data could be integrated with "smart" instrument force data and anatomical data (using videos and navigation technology) and displayed using augmented reality to guide surgeons on the optimum manoeuvres (instrument use), at the optimum time (step) and place (anatomy). Future operating theatres will host these technologies and other innovations (e.g. wearable cardiorespiratory and neurosensory monitoring for staff) in concert, connecting them and all members of the operative team. If and when these smart theatres are widespread, and our performance is linked to postoperative outcomes, this technology may go further than simply orientating the team, and may provide outcome-driven guidance to surgeons in real-time - heralding the era of truly "information-guided" surgery[67, 116].

4. Optimizing Postoperative Care

Once the surgical challenge of resecting the pituitary lesion has been surmounted, the post-operative phase commences. Postoperative care can be divided into inpatient and outpatient stages which have distinct challenges. The inpatient phase involves recovery from surgery, monitoring for surgical complications and initial outcomes. Whilst in the outpatient phase the suspected diagnosis is confirmed, and surveillance begins. Both look to risk stratify patients, however, achieving such foresight consistently remains a challenge.

4.1 Inpatient Outcome Modelling

4.1.1 Challenges

Predicting outcomes is notoriously difficult after pituitary surgery, this includes the most common complications such as sodium abnormalities and cerebrospinal fluid rhinorrhoea[109, 117-119]. This results in the need for extended monitoring of patients postoperatively, and some groups have trialled prophylactic therapies on a blanket basis to prevent these common complications, for example, fluid restriction for SIADH or bed rest for CSF rhinorrhoea[120]. The core issue is our ability to accurately predict, and risk stratify patients postoperatively.

4.1.2 Potential solutions

Traditional methods have likely failed due to the need for multimodal datasets, containing a large number of variables with complex non-linear relationships to answer this particular unmet need. However, ML, especially neural networks, have the ability to analyse these datasets[36]. For example, intraoperative workflow analysis can be integrated into multimodal AI models with preoperative and postoperative data, such that the patients can be classified into high and low-risk groups for each surgical complication[121].

High-risk groups may benefit from extended monitoring with closer attention to potential complications or prophylactic treatments, whilst low-risk groups may benefit from early discharge and fast-track protocols (sparing risks of nosocomial disease and streamlining resource allocation)[117, 122].

Furthermore, the development of novel biomarkers may supplement the above datasets or stand as independent predictors for patient outcomes. Many of these biomarkers have been diagnosis-orientated, and there is a growing appreciation for the clinical need for these biomarkers in the postoperative care phase. For example, novel imaging techniques such as OCT angiography provide a rapid non-invasive assessment of retinal microvasculature changes and may predict those who have structural retina improvements and functional vision recovery after surgery[123]. Similarly, digital biomarkers may be generated using active self-reporting of symptoms by patients via smartphone applications[122, 124]. When combined with a validated set of patient-reported outcome measures , which has recently been developed for patients undergoing pituitary surgery, this may generate a digital dataset otherwise unrepresented in traditional outcome reporting[125]. However, as the age of big data continues its growth, careful interrogation of the bias within the data-driven analysis is paramount. If a subset of patients (e.g. those with severe visual or functional disability) are unable to access and contribute to these biomarker datasets, resulting predictive models will not be valid in these populations. In the era of innovation, basic principles stand true, and the multidisciplinary pituitary team must ensure translated technologies are fair, equitable and accessible to the patients they care for.

4.2. Outpatient Recurrence Monitoring

4.2.1 Challenges

For patients and clinicians and health systems, remission is an important treatment goal. It is challenging to define in functioning tumours, owing to the limitations of present methods of defining remission and the variances in an individual's response to treatment[108, 126]. The importance of achieving remission differs depending upon the diagnosis - because adjuvant interventions (radiotherapy, gamma knife surgery, medication) mean, for example, in acromegaly remission can still be achieved after surgery[127, 128]. Deciding upon remission is fundamental for Cushing's disease, as it aids neurosurgical decision-making with regard to more aggressive surgical resection of suspected lesions, gland, or even total removal of the pituitary gland[129-131]. In acromegaly, reliance on medication postoperatively leaves the patient vulnerable to treatment resistance. From a systems perspective, medical management of acromegaly is costly meaning remission provides gains for the wider health system, alongside the many individual benefit to the patient[132].

4.2.2 Potential solutions

Again, a data-driven machine learning approach has shown promise in outpatient surveillance, for example, it has been shown to outperform present prognostic biomarkers in determining remission in acromegaly, computing arrays of established variables in new ways to predict outcomes[42, 133, 134]. Single-centre studies show promise in determining surgical success and endocrine outcomes, offering tailored treatment and follow-up approaches according to the likelihood of remission. Identifying treatment failures sooner will support definitive treatment decision-making, showing value in producing reliable and accurate prediction models of remission. Early identification of remission supports earlier discharge and outpatient monitoring. Pre-, intra- and day 1 postoperative variables have been used to model early remission, outperforming established prognostic factors. Similarly, prognostic factors in Cushing's disease have been identified to associate with recurrence or remission[135-138]. Preoperative variables can be used to estimate immediate remission, supporting enhanced recovery pathways and reductions in length-of-stay[117, 139]. In patients with delayed remission, decision-making remains a challenge, considering the outcome uncertainty and urge to achieve remission, placing value on prediction models identifying this subgroup of patients[140]. More generally, risk stratification can aid medical or radiotherapeutic adjuncts with earlier consultation of endocrinologists or oncologists in patients expected to respond poorly to surgery. Accurate prediction of remission could influence established treatment paradigms. First-line surgery for prolactinomas remains controversial, as medical therapies are easily available, however, means of predicting surgical success and remission, coupled with increasing surgical safety may become more accepted as a treatment option[141].

5. Conclusions

We have the potential to significantly improve the lives of patients with pituitary adenomas with our recent advances in surgical, medical and radiological therapies. However, treatment failure is still a common problem and is influenced by significant challenges across the patient pathway – including screening, diagnosis, preoperative planning, surgical proficiency and postoperative care. The patient pathway of the future will integrate novel medical technologies - working in synergy with each other and in harmony with the multidisciplinary team. Clinicians must be the gatekeepers of technological translation, ensuring systematic assessment of risk and benefit, and leveraging these innovations to drive improved outcomes for patients of the future.

References:

1. Ezzat S, Asa SL, Couldwell WT, et al. The prevalence of pituitary adenomas: a systematic review. *Cancer: Interdisciplinary International Journal of the American Cancer Society*. 2004;101(3):613-619.

2. Asa SL. Practical pituitary pathology: what does the pathologist need to know? *Arch Pathol Lab Med*. 2008;132(8):1231-1240.

3. Buchfelder M, Schlaffer S. Pituitary surgery for Cushing's disease. *Neuroendocrinology*. 2010;92(Suppl. 1):102-106.

4. Excellence TNIfHaC. Endoscopic transsphenoidal pituitary adenoma resection. 2022. https://www.nice.org.uk/guidance/ipg32/evidence

5. Excellence TNIfHaC. Human growth hormone (somatropin) in adults with growth hormone deficiency - Technology appraisal guidance. 2022. https://www.nice.org.uk/guidance/ta64

6. Jho H-D, Carrau RL, Ko Y, Daly MA. Endoscopic pituitary surgery: an early experience. *Surg Neurol*. 1997;47(3):213-22; discussion 222.

7. Fleseriu M, Dekkers OM, Karavitaki N. Endocrinology in the time of COVID-19: Management of pituitary tumours. *Eur J Endocrinol*. Jul 2020;183(1):G17-g23. doi:10.1530/eje-20-0473

8. Fleseriu M, Buchfelder M, Cetas JS, et al. Pituitary society guidance: pituitary disease management and patient care recommendations during the COVID-19 pandemic-an international perspective. *Pituitary*. Aug 2020;23(4):327-337. doi:10.1007/s11102-020-01059-7

9. McLaughlin N, Laws ER, Oyesiku NM, Katznelson L, Kelly DF. Pituitary centers of excellence. *Neurosurgery*. 2012;71(5):916-926.

10. Snyderman C, Kassam A, Carrau R, Mintz A, Gardner P, Prevedello DM. Acquisition of surgical skills for endonasal skull base surgery: a training program. *The Laryngoscope*. 2007;117(4):699-705.

11. Leach P, Abou-Zeid AH, Kearney T, Davis J, Trainer PJ, Gnanalingham KK. Endoscopic Transsphenoidal Pituitary Surgery: Evidence of an Operative Learning Curve. *Neurosurgery*. Nov 2010;67(5):1205-1212. doi:10.1227/NEU.0b013e3181ef25c5

12. Ivan C, Ann R, Craig B, Debi P. Complications of transsphenoidal surgery: results of a national survey, review of the literature, and personal experience. *Neurosurgery*. 1997;40(2):225-237.

13. Roelfsema F, Biermasz NR, Pereira AM. Clinical factors involved in the recurrence of pituitary adenomas after surgical remission: a structured review and meta-analysis. *Pituitary*. Mar 2012;15(1):71-83. doi:10.1007/s11102-011-0347-7

14. Chen W, Wang M, Duan C, et al. Prediction of the Recurrence of Non-Functioning Pituitary Adenomas Using Preoperative Supra-Intra Sellar Volume and Tumor-Carotid Distance. Original Research. *Front Endocrinol (Lausanne)*. 2021-September-30 2021;12doi:10.3389/fendo.2021.748997

15. Williams S, Layard Horsfall H, Funnell JP, et al. Artificial Intelligence in Brain Tumour Surgery-An Emerging Paradigm. *Cancers (Basel)*. Oct 7 2021;13(19)doi:10.3390/cancers13195010

16. Saha A, Tso S, Rabski J, Sadeghian A, Cusimano MD. Machine learning applications in imaging analysis for patients with pituitary tumors: a review of the current literature and future directions. *Pituitary*. 2020;23(3):273-293.

17. Varlamov EV, Niculescu DA, Banskota S, Galoiu SA, Poiana C, Fleseriu M. Clinical features and complications of acromegaly at diagnosis are not all the same: data from two large referral centers. *Endocrine Connections*. 2021;1(aop)

18. Melmed S. Acromegaly. *N Engl J Med*. 2006;355(24):2558-2573.

19. Kauppinen-Mäkelin R, Sane T, Reunanen A, et al. A nationwide survey of mortality in acromegaly. *The Journal of Clinical Endocrinology & Metabolism*. 2005;90(7):4081-4086.

20. Dal J, Nielsen EH, Rasmussen U-F, et al. Disease control and gender predict the socioeconomic effects of acromegaly: a nationwide cohort study. *The Journal of Clinical Endocrinology & Metabolism*. 2020;105(9):2975-2982.

21. Kosilek R, Frohner R, Würtz R, et al. Diagnostic use of facial image analysis software in endocrine and genetic disorders: review, current results and future perspectives. *European journal of endocrinology*. 2015;173(4):M39-M44.

22. Baynam G, Bauskis A, Pachter N, et al. 3-Dimensional facial analysis—facing precision public health. *Frontiers in public health*. 2017;5:31.

23. Chen S, Pan Z-x, Zhu H-j, et al. Development of a computer-aided tool for the pattern recognition of facial features in diagnosing Turner syndrome: comparison of diagnostic accuracy with clinical workers. *Sci Rep*. 2018;8(1):1-9.

24. Hadj-Rabia S, Schneider H, Navarro E, et al. Automatic recognition of the XLHED phenotype from facial images. *American Journal of Medical Genetics Part A*. 2017;173(9):2408-2414.

25. Caron P, Brue T, Raverot G, et al. Signs and symptoms of acromegaly at diagnosis: the physician's and the patient's perspectives in the ACRO-POLIS study. *Endocrine*. 2019;63(1):120-129.

26. Meng T, Guo X, Lian W, et al. Identifying facial features and predicting patients of acromegaly using three-dimensional imaging techniques and machine learning. *Front Endocrinol (Lausanne)*. 2020;11:492.

27. Kong X, Gong S, Su L, Howard N, Kong Y. Automatic detection of acromegaly from facial photographs using machine learning methods. *EBioMedicine*. 2018;27:94-102.

28. Miller RE, Learned-Miller EG, Trainer P, Paisley A, Blanz V. Early diagnosis of acromegaly: computers vs clinicians. *Clin Endocrinol (Oxf)*. 2011;75(2):226-231.

29. Schneider HJ, Kosilek RP, Günther M, et al. A novel approach to the detection of acromegaly: accuracy of diagnosis by automatic face classification. *The Journal of Clinical Endocrinology & Metabolism*. 2011;96(7):2074-2080.

30. Ofcom. Communications Market Report. Accessed 01/08/21, https://www.ofcom.org.uk/__data/assets/pdf_file/0027/219096/technology-tracker-2021-cati-omnibus-survey-data-tables.pdf

31. Yim W-w, Yetisgen M, Harris WP, Kwan SW. Natural language processing in oncology: a review. *JAMA oncology*. 2016;2(6):797-804.

32. Jackson R, Kartoglu I, Stringer C, et al. CogStack - experiences of deploying integrated information retrieval and extraction services in a large National Health Service Foundation Trust hospital. *BMC Med Inform Decis Mak*. 2018/06/25 2018;18(1):47. doi:10.1186/s12911-018-0623-9

33. Rumshisky A, Ghassemi M, Naumann T, et al. Predicting early psychiatric readmission with natural language processing of narrative discharge summaries. *Translational Psychiatry*. 2016/10/01 2016;6(10):e921-e921. doi:10.1038/tp.2015.182

34. Buchlak QD, Esmaili N, Leveque J-C, et al. Machine learning applications to clinical decision support in neurosurgery: an artificial intelligence augmented systematic review. *Neurosurg Rev*. 2020;43(5):1235-1253.

35. Hashimoto DA, Rosman G, Rus D, Meireles OR. Artificial Intelligence in Surgery: Promises and Perils. *Ann Surg*. 2018;268(1):70-76. doi:10.1097/SLA.0000000000002693

36. Lammers DT, Eckert CM, Ahmad MA, Bingham JR, Eckert MJ. A Surgeon's Guide to Machine Learning. *Annals of Surgery Open*. 2021;2(3)

37. Elfiky AA, Pany MJ, Parikh RB, Obermeyer Z. Development and application of a machine learning approach to assess short-term mortality risk among patients with cancer starting chemotherapy. *JAMA network open*. 2018;1(3):e180926-e180926.

38. Boehm KM, Aherne EA, Ellenson L, et al. Multimodal data integration using machine learning improves risk stratification of high-grade serous ovarian cancer. *Nature Cancer*. 2022/06/01 2022;3(6):723-733. doi:10.1038/s43018-022-00388-9

39. Staartjes VE, Serra C, Muscas G, et al. Utility of deep neural networks in predicting gross-total resection after transsphenoidal surgery for pituitary adenoma: a pilot study. *Neurosurg Focus*. 2018;45(5):E12.

40. Voglis S, van Niftrik CH, Staartjes VE, et al. Feasibility of machine learning based predictive modelling of postoperative hyponatremia after pituitary surgery. *Pituitary*. 2020;23(5):543-551.

41. Hollon TC, Parikh A, Pandian B, et al. A machine learning approach to predict early outcomes after pituitary adenoma surgery. *Neurosurg Focus*. 2018;45(5):E8.

42. Sulu C, Bektaş AB, Şahin S, et al. Machine learning as a clinical decision support tool for patients with acromegaly. *Pituitary*. 2022:1-10.

43. Gil J, Marques-Pamies M, Sampedro M, et al. Data mining analyses for precision medicine in acromegaly: a proof of concept. *Sci Rep*. 2022;12(1):1-14.

44. Galm BP, Buckless C, Swearingen B, et al. MRI texture analysis in acromegaly and its role in predicting response to somatostatin receptor ligands. *Pituitary*. 2020;23(3):212-222.

45. Kocak B, Durmaz ES, Kadioglu P, et al. Predicting response to somatostatin analogues in acromegaly: machine learning-based high-dimensional quantitative texture analysis on T2-weighted MRI. *Eur Radiol*. 2019;29(6):2731-2739.

46. Park YW, Eom J, Kim S, et al. Radiomics with ensemble machine learning predicts dopamine agonist response in patients with prolactinoma. *The Journal of Clinical Endocrinology & Metabolism*. 2021;106(8):e3069-e3077.

47. Fan Y, Jiang S, Hua M, Feng S, Feng M, Wang R. Machine learning-based radiomics predicts radiotherapeutic response in patients with acromegaly. *Front Endocrinol (Lausanne)*. 2019;10:588.

48. Topol EJ. High-performance medicine: the convergence of human and artificial intelligence. *Nat Med*. 2019;25(1):44-56.

49. Davies BM, Khan DZ, Mowforth OD, et al. RE-CODE DCM (RE search Objectives and C ommon D ata E lements for D egenerative C ervical M yelopathy): A Consensus Process to Improve Research Efficiency in DCM, Through Establishment of a Standardized Dataset for Clinical Research and the Definition of the Research Priorities. *Global spine journal*. 2019;9(1_suppl):65S-76S.

50. Collins GS, Reitsma JB, Altman DG, Moons KGM. Transparent Reporting of a Multivariable Prediction Model for Individual Prognosis or Diagnosis (TRIPOD) The TRIPOD Statement. *Circulation*. 2015;131(2):211-219.

51. Khalafallah AM, Liang AL, Jimenez AE, et al. Trends in endoscopic and microscopic transsphenoidal surgery: a survey of the international society of pituitary surgeons between 2010 and 2020. *Pituitary*. May 21 2020;doi:10.1007/s11102-020-01054-y

52. White EM, Shaughnessy MP, Esposito AC, Slade MD, Korah M, Yoo PS. Surgical education in the time of COVID: understanding the early response of surgical training programs to the novel coronavirus pandemic. *J Surg Educ*. 2021;78(2):412-421.

53. Rutland JW, Loewenstern J, Ranti D, et al. Analysis of 7-tesla diffusion-weighted imaging in the prediction of pituitary macroadenoma consistency. *J Neurosurg*. 2020;134(3):771-779.

54. Chatain GP, Patronas N, Smirniotopoulos JG, et al. Potential utility of FLAIR in MRI-negative Cushing's disease. *J Neurosurg*. 2017;129(3):620-628.

55. MacFarlane J, Bashari WA, Senanayake R, et al. Advances in the imaging of pituitary tumors. *Endocrinology and Metabolism Clinics*. 2020;49(3):357-373.

56. Feng Z, He D, Mao Z, et al. Utility of 11C-methionine and 18F-FDG PET/CT in patients with functioning pituitary adenomas. *Clin Nucl Med*. 2016;41(3):e130-e134.

57. Koulouri O, Steuwe A, Gillett D, et al. A role for 11C-methionine PET imaging in ACTH-dependent Cushing's syndrome. *European Journal of Endocrinology*. 2015;173(4):M107-M120.

58. Kim M, Kim HS, Kim HJ, et al. Thin-Slice Pituitary MRI with Deep Learning–based Reconstruction: Diagnostic Performance in a Postoperative Setting. *Radiology*. 2021/01/01 2020;298(1):114-122. doi:10.1148/radiol.2020200723

59. Lee DH, Park JE, Nam YK, et al. Deep learning-based thin-section MRI reconstruction improves tumour detection and delineation in pre-and post-treatment pituitary adenoma. *Sci Rep*. 2021;11(1):1-10.

60. Wang H, Zhang W, Li S, Fan Y, Feng M, Wang R. Development and evaluation of deep learning-based automated segmentation of pituitary adenoma in clinical task. *The Journal of Clinical Endocrinology & Metabolism*. 2021;106(9):2535-2546.

61. Rui W, Qiao N, Wu Y, et al. Radiomics analysis allows for precise prediction of silent corticotroph adenoma among non-functioning pituitary adenomas. *Eur Radiol*. 2022;32(3):1570-1578.

62. Ugga L, Cuocolo R, Solari D, et al. Prediction of high proliferative index in pituitary macroadenomas using MRI-based radiomics and machine learning. *Neuroradiology*. 2019;61(12):1365-1373.

63. Gomar-Alba M, Parrón-Carreño T, Narro-Donate JM, et al. Neuroendoscopic training in neurosurgery: a simple and feasible model for neurosurgical education. *Childs Nerv Syst*. 2021/08/01 2021;37(8):2619-2624. doi:10.1007/s00381-021-05190-z

64. Tai BL, Wang AC, Joseph JR, et al. A physical simulator for endoscopic endonasal drilling techniques: technical note. *Journal of Neurosurgery JNS*. 01 Mar. 2016 2016;124(3):811-816. doi:10.3171/2015.3.Jns1552

65. Rosseau G, Bailes J, del Maestro R, et al. The development of a virtual simulator for training neurosurgeons to perform and perfect endoscopic endonasal transsphenoidal surgery. *Neurosurgery*. 2013;73(suppl_1):S85-S93.

66. Wolfsberger S, Forster M-T, Donat M, et al. Virtual endoscopy is a useful device for training and preoperative planning of transsphenoidal endoscopic pituitary surgery. *min-Minimally Invasive Neurosurgery*. 2004;47(04):214-220.

67. Nakamura T, Ogiwara T, Goto T, et al. Clinical Experience of Endoscopic Endonasal Approach in the Innovative, Newly Developed Operating Room “Smart Cyber Operating Theater (SCOT)”. *World Neurosurg*. 2020/02/01/ 2020;134:293-296. doi:https://doi.org/10.1016/j.wneu.2019.11.021

68. Ota HC, Smith BG, Alamri A, et al. The IDEAL framework in neurosurgery: a bibliometric analysis. *Acta Neurochir (Wien)*. 2020;162(12):2939-2947.

69. Dimick JB, Sedrakyan A, McCulloch P. The IDEAL framework for evaluating surgical innovation: how it can be used to improve the quality of evidence. *Jama Surgery*. 2019;154(8):685-686.

70. Marcus HJ, Bennett A, Chari A, et al. IDEAL-D framework for device innovation: a consensus statement on the preclinical stage. *Ann Surg*. 2022;275(1):73.

71. Hirst A, Philippou Y, Blazeby J, et al. No surgical innovation without evaluation: evolution and further development of the IDEAL framework and recommendations. *Ann Surg*. 2019;269(2):211-220.

72. Swearingen B. Update on pituitary surgery. *The Journal of Clinical Endocrinology & Metabolism*. 2012;97(4):1073-1081.

73. Zaidi HA, De Los Reyes K, Barkhoudarian G, et al. The utility of high-resolution intraoperative MRI in endoscopic transsphenoidal surgery for pituitary macroadenomas: early experience in the advanced multimodality image guided operating suite. *Neurosurg Focus*. 2016;40(3):E18.

74. Hlaváč M, Knoll A, Mayer B, et al. Ten years' experience with intraoperative MRI-assisted transsphenoidal pituitary surgery. *Neurosurg Focus*. 2020;48(6):E14.

75. Berkmann S, Fandino J, Zosso S, Killer HE, Remonda L, Landolt H. Intraoperative magnetic resonance imaging and early prognosis for vision after transsphenoidal surgery for sellar lesions. *J Neurosurg*. 2011;115(3):518-527.

76. Tandon V, Raheja A, Suri A, et al. Randomized trial for superiority of high field strength intra-operative magnetic resonance imaging guided resection in pituitary surgery. *J Clin Neurosci*. 2017/03/01/ 2017;37:96-103. doi:https://doi.org/10.1016/j.jocn.2016.10.044

77. Gerlach R, de Rochemont RdM, Gasser T, et al. Feasibility of Polestar N20, an ultra-low-field intraoperative magnetic resonance imaging system in resection control of pituitary macroadenomas: lessons learned from the first 40 cases. *Neurosurgery*. 2008;63(2):272-285.

78. Marcus HJ, Vercauteren T, Ourselin S, Dorward NL. Intraoperative Ultrasound in Patients Undergoing Transsphenoidal Surgery for Pituitary Adenoma: Systematic Review. *World Neurosurg*. 2017/10/01/ 2017;106:680-685. doi:https://doi.org/10.1016/j.wneu.2017.07.054

79. Cabrilo I, Delaunay R, Heaysman CL, et al. A Novel Intraoperative Ultrasound Probe for Transsphenoidal Surgery: First-in-human study. *Surg Innov*. 2022/04/01 2021;29(2):282-288. doi:10.1177/15533506211031091

80. Carl B, Bopp M, Voellger B, Saß B, Nimsky C. Augmented Reality in Transsphenoidal Surgery. *World Neurosurg*. 2019/05/01/ 2019;125:e873-e883. doi:https://doi.org/10.1016/j.wneu.2019.01.202

81. Sun G-c, Wang F, Chen X-l, et al. Impact of Virtual and Augmented Reality Based on Intraoperative Magnetic Resonance Imaging and Functional Neuronavigation in Glioma Surgery Involving Eloquent Areas. *World Neurosurg*. 2016/12/01/ 2016;96:375-382. doi:https://doi.org/10.1016/j.wneu.2016.07.107

82. Cabrilo I, Sarrafzadeh A, Bijlenga P, Landis BN, Schaller K. Augmented reality-assisted skull base surgery. *Neurochirurgie*. 2014;60(6):304-306.

83. D'Alessandris QG, Rigante M, Mattogno PP, et al. Impact of 4K ultra-high definition endoscope in pituitary surgery: analysis of a comparative institutional case series. *J Neurosurg Sci*. 2020/02// 2020;doi:10.23736/s0390-5616.20.04875-4

84. Linsler S, Szameitat N, Senger S, Oertel J. Visualization and Identification of the Pituitary Gland Tissue in Endonasal Pituitary Surgery: Is There a Difference Between High-Definition Endoscopy and Microscopy? *World Neurosurg*. 2018/08/01/ 2018;116:e921-e928. doi:https://doi.org/10.1016/j.wneu.2018.05.129

85. Uvelius E, Siesjö P. 3-D endoscopy in surgery of pituitary adenomas, prospective evaluation of patient gain using basic outcome parameters. *J Clin Neurosci*. 2020;76:166-170.

86. Nassimizadeh A, Muzaffar S, Nassimizadeh M, Beech T, Ahmed S. Three-dimensional hand-to-gland combat: the future of endoscopic surgery? *Journal of Neurological Surgery Reports*. 2015;76(02):e200-e204.

87. Kari E, Oyesiku NM, Dadashev V, Wise SK. Comparison of traditional 2-dimensional endoscopic pituitary surgery with new 3-dimensional endoscopic technology: intraoperative and early postoperative factors. *International Forum of Allergy & Rhinology*. 2012;2(1):2-8. doi:https://doi.org/10.1002/alr.20036

88. Chang SW, Donoho DA, Zada G. Use of optical fluorescence agents during surgery for pituitary adenomas: current state of the field. *J Neurooncol*. 2019;141(3):585-593.

89. Sandow N, Klene W, Elbelt U, Strasburger CJ, Vajkoczy P. Intraoperative indocyanine green videoangiography for identification of pituitary adenomas using a microscopic transsphenoidal approach. *Pituitary*. 2015/10/01 2015;18(5):613-620. doi:10.1007/s11102-014-0620-7

90. Riley CA, Soneru CP, Tabaee A, Kacker A, Anand VK, Schwartz TH. Technological and ideological innovations in endoscopic skull base surgery. *World Neurosurg*. 2019;124:513-521.

91. Belykh E, Ngo B, Farhadi DS, et al. Confocal laser endomicroscopy assessment of pituitary tumor microstructure: a feasibility study. *Journal of clinical medicine*. 2020;9(10):3146.

92. Wang KK, Carr-Locke DL, Singh SK, et al. Use of probe-based confocal laser endomicroscopy (pCLE) in gastrointestinal applications. A consensus report based on clinical evidence. *United European gastroenterology journal*. 2015;3(3):230-254.

93. Shapey J, Xie Y, Nabavi E, et al. Intraoperative multispectral and hyperspectral label-free imaging: A systematic review of in vivo clinical studies. *Journal of biophotonics*. 2019;12(9):e201800455.

94. Eljamel MS, Leese G, Moseley H. Intraoperative optical identification of pituitary adenomas. *J Neurooncol*. 2009;92(3):417-421.

95. Aylmore H, Dimitrakakis E, Carmichael J, et al. Specialised Surgical Instruments for Endoscopic and Endoscope-Assisted Neurosurgery: A Systematic Review of Safety, Efficacy and Usability. *Cancers (Basel)*. 2022;14(12):2931.

96. Rotermund R, Regelsberger J, Osterhage K, Aberle J, Flitsch J. 4K 3-dimensional video microscope system (orbeye) for transsphenoidal pituitary surgery. *Acta Neurochir (Wien)*. 2021/08/01 2021;163(8):2097-2106. doi:10.1007/s00701-021-04762-x

97. Rossini Z, Cardia A, Milani D, Lasio GB, Fornari M, D'Angelo V. VITOM 3D: Preliminary Experience in Cranial Surgery. *World Neurosurg*. 2017/11/01/ 2017;107:663-668. doi:https://doi.org/10.1016/j.wneu.2017.08.083

98. Ogiwara T, Goto T, Nagm A, Hongo K. Endoscopic endonasal transsphenoidal surgery using the iArmS operation support robot: initial experience in 43 patients. *Neurosurg Focus*. 2017;42(5):E10.

99. Friedrich DT, Sommer F, Scheithauer MO, Greve J, Hoffmann TK, Schuler PJ. An innovate robotic endoscope guidance system for transnasal sinus and skull base surgery: proof of concept. *Journal of Neurological Surgery Part B: Skull Base*. 2017;78(06):466-472.

100. Golahmadi AK, Khan DZ, Mylonas GP, Marcus HJ. Tool-tissue forces in surgery: A systematic review. *Annals of Medicine and Surgery*. 2021/05/01/ 2021;65:102268. doi:https://doi.org/10.1016/j.amsu.2021.102268

101. Chauvet D, Hans S. Robot-Assisted Pituitary Surgery. *Neurosurgical Robotics*. Springer; 2021:145-159.

102. Farooq MU, Baek H, Seung S, et al. A Stiffness Adjustable 6-DOF Robotic System for Pituitary Tumor Resection Under MRI. *IEEE Access*. 2020;8:192557-192568. doi:10.1109/ACCESS.2020.3032384

103. Runciman M, Darzi A, Mylonas GP. Soft robotics in minimally invasive surgery. *Soft robotics*. 2019;6(4):423-443.

104. Dimitrakakis E, Lindenroth L, Dwyer G, et al. An intuitive surgical handle design for robotic neurosurgery. *Int J Comput Assist Radiol Surg*. 2021;16(7):1131-1139.

105. Dimitrakakis E, Dwyer G, Lindenroth L, et al. A spherical joint robotic end-effector for the expanded endoscopic endonasal approach. *Journal of Medical Robotics Research*. 2020;5(03n04):2150002.

106. Marcus HJ, Payne CJ, Kailaya-Vasa A, et al. A “smart” force-limiting instrument for microsurgery: laboratory and in vivo validation. *PLoS One*. 2016;11(9):e0162232.

107. Dimitrakakis E, Aylmore H, Lindenroth L, et al. Robotic Handle Prototypes for Endoscopic Endonasal Skull Base Surgery: Pre-clinical Randomised Controlled Trial of Performance and Ergonomics. *Ann Biomed Eng*. 2022;50(5):549-563.

108. Marcus HJ, Khan DZ, Borg A, et al. Pituitary society expert Delphi consensus: operative workflow in endoscopic transsphenoidal pituitary adenoma resection. *Pituitary*. 2021:1-15.

109. CRANIAL-Consortium. CSF Rhinorrhoea After Endonasal Intervention to the Skull Base (CRANIAL) - Part 1: Multicenter Pilot Study. *World Neurosurg*. 2021/05/01/ 2021;149:e1077-e1089. doi:https://doi.org/10.1016/j.wneu.2020.12.171

110. CRANIAL-Consortium. CSF Rhinorrhea After Endonasal Intervention to the Skull Base (CRANIAL) — Part 2: Impact of COVID-19. *World Neurosurg*. 2021/05/01/ 2021;149:e1090-e1097. doi:https://doi.org/10.1016/j.wneu.2020.12.169

111. Garrow CR, Kowalewski K-F, Li L, et al. Machine Learning for Surgical Phase Recognition: A Systematic Review. *Ann Surg*. 2020;

112. Hashimoto DA, Rosman G, Witkowski ER, et al. Computer Vision Analysis of Intraoperative Video: Automated Recognition of Operative Steps in Laparoscopic Sleeve Gastrectomy. *Ann Surg*. 2019;270(3)

113. Khan DZ, Luengo I, Barbarisi S, et al. Automated operative workflow analysis of endoscopic pituitary surgery using machine learning: Development and preclinical evaluation (IDEAL stage 0). *J Neurosurg*. 2021; Accepted & In press

114. Greenberg CC, Dombrowski J, Dimick JB. Video-based surgical coaching: an emerging approach to performance improvement. *JAMA surgery*. 2016;151(3):282-283.

115. Harbison RA, Li Y, Berens AM, Bly RA, Hannaford B, Moe KS. An automated methodology for assessing anatomy-specific instrument motion during endoscopic endonasal skull base surgery. *Journal of Neurological Surgery Part B: Skull Base*. 2017;38(03):222-226.

116. Lam A. Review of the Future of Surgery: Technology Enhanced Surgical Training report. *The Bulletin of the Royal College of Surgeons of England*. 2022;104(6):308-309.

117. Hughes MA, Culpin E, Darley R, et al. Enhanced recovery and accelerated discharge after endoscopic transsphenoidal pituitary surgery: safety, patient feedback, and cost implications. *Acta Neurochir (Wien)*. Jun 2020;162(6):1281-1286. doi:10.1007/s00701-020-04282-0

118. Dorward NL. Endocrine outcomes in endoscopic pituitary surgery: a literature review. *Acta Neurochir (Wien)*. 2010;152(8):1275-1279.

119. Khan DZ, Ali AM, Koh CH, et al. Skull base repair following endonasal pituitary and skull base tumour resection: a systematic review. *Pituitary*. 2021:1-16.

120. Perez-Vega C, Tripathi S, Domingo RA, et al. Fluid Restriction After Transsphenoidal Surgery for Prevention of Delayed Hyponatremia: A Systematic Review and Meta-Analysis. *Endocr Pract*. 2021;

121. Marcus AP, Marcus HJ, Camp SJ, Nandi D, Kitchen N, Thorne L. Improved Prediction of Surgical Resectability in Patients with Glioblastoma using an Artificial Neural Network. *Sci Rep*. 2020/03/20 2020;10(1):5143. doi:10.1038/s41598-020-62160-2

122. Lobatto DJ, Vliet Vlieland TPM, van den Hout WB, et al. Feasibility, safety, and outcomes of a stratified fast-track care trajectory in pituitary surgery. *Endocrine*. 2020;69(1):175-187.

123. Cennamo G, Solari D, Montorio D, et al. Early vascular modifications after endoscopic endonasal pituitary surgery: The role of OCT-angiography. *PLoS One*. 2020;15(10):e0241295.

124. Gvozdanovic A, Mangiapelo R, Patel R, et al. Implementation of the Vinehealth application, a digital health tool, into the care of patients living with brain cancer. Wolters Kluwer Health; 2021.

125. Karvandi E, Hanrahan JG, Khan DZ, et al. A patient-reported outcome measure for patients with pituitary adenoma undergoing transsphenoidal surgery. *Pituitary*. 2022;25(4):673-683.

126. Swearingen B, Wu N, Chen S-Y, Pulgar S, Biller BM. Health care resource use and costs among patients with cushing disease. *Endocr Pract*. 2011;17(5):681-690.

127. Patt H, Jalali R, Yerawar C, et al. High-precision conformal fractionated radiotherapy is effective in achieving remission in patients with acromegaly after failed transsphenoidal surgery. *Endocr Pract*. 2016;22(2):162-172.

128. Castinetti F, Morange I, Dufour H, Regis J, Brue T. Radiotherapy and radiosurgery in acromegaly. *Pituitary*. 2009;12(1):3-10.

129. Alexandraki KI, Kaltsas GA, Isidori AM, et al. Long-term remission and recurrence rates in Cushing's disease: predictive factors in a single-centre study. *Eur J Endocrinol*. 2013;168(4):639-648.

130. Andereggen L, Mariani L, Beck J, et al. Lateral one-third gland resection in Cushing patients with failed adenoma identification leads to low remission rates: long-term observations from a small, single-center cohort. *Acta Neurochir (Wien)*. 2021;163(11):3161-3169.

131. Besser G, Burman P, Daly A. Predictors and rates of treatment-resistant tumor growth in acromegaly. *European Journal of Endocrinology*. 2005;153(2):187-193.

132. Elbaum M, Mizera Ł, Bolanowski M. The real costs of acromegaly: analysis of different therapies [Rzeczywiste koszty akromegalii: analiza różnych terapii]. *Endokrynol Pol*. 2019;70(1):74-85.

133. Qiao N, Yu D, Wu G, et al. Low-rank fusion convolutional neural network for prediction of remission after stereotactic radiosurgery in patients with acromegaly: a proof-of-concept study. *The Journal of Pathology*. 2022;258(1):49-57.

134. Cardinal T, Collet C, Wedemeyer M, et al. Postoperative GH and degree of reduction in IGF-1 predicts postoperative hormonal remission in acromegaly. *Front Endocrinol (Lausanne)*. 2021;12

135. Qiao N, Shen M, He W, et al. Machine learning in predicting early remission in patients after surgical treatment of acromegaly: a multicenter study. *Pituitary*. 2021;24(1):53-61.

136. Moreno-Moreno P, Ibáñez-Costa A, Venegas-Moreno E, et al. Integrative Clinical, Radiological, and Molecular Analysis for Predicting Remission and Recurrence of Cushing Disease. *The Journal of Clinical Endocrinology & Metabolism*. 2022;

137. Wang F, Catalino MP, Bi WL, et al. Postoperative day 1 morning cortisol value as a biomarker to predict long-term remission of Cushing disease. *The Journal of Clinical Endocrinology & Metabolism*. 2021;106(1):e94-e102.

138. Zachariah MA, Cua SG, Otto BA, et al. A Highly Sensitive and Specific ACTH-Based Predictor of Long-Term Remission after Surgery for Cushing's Disease. *Journal of Neurological Surgery Part B: Skull Base*. 2020;81(S 01):A004.

139. Sarris CE, Brigeman ST, Doris E, et al. Effects of a transsphenoidal surgery quality improvement program on patient outcomes and hospital financial performance. *J Neurosurg*. 2021;1(aop):1-10.

140. Fan Y, Li Y, Bao X, et al. Development of machine learning models for predicting postoperative delayed remission in patients with cushing's disease. *The Journal of Clinical Endocrinology & Metabolism*. 2021;106(1):e217-e231.

141. Huber M, Luedi MM, Schubert GA, et al. Machine Learning for Outcome Prediction in First-Line Surgery of Prolactinomas. *Front Endocrinol (Lausanne)*. 2022;13

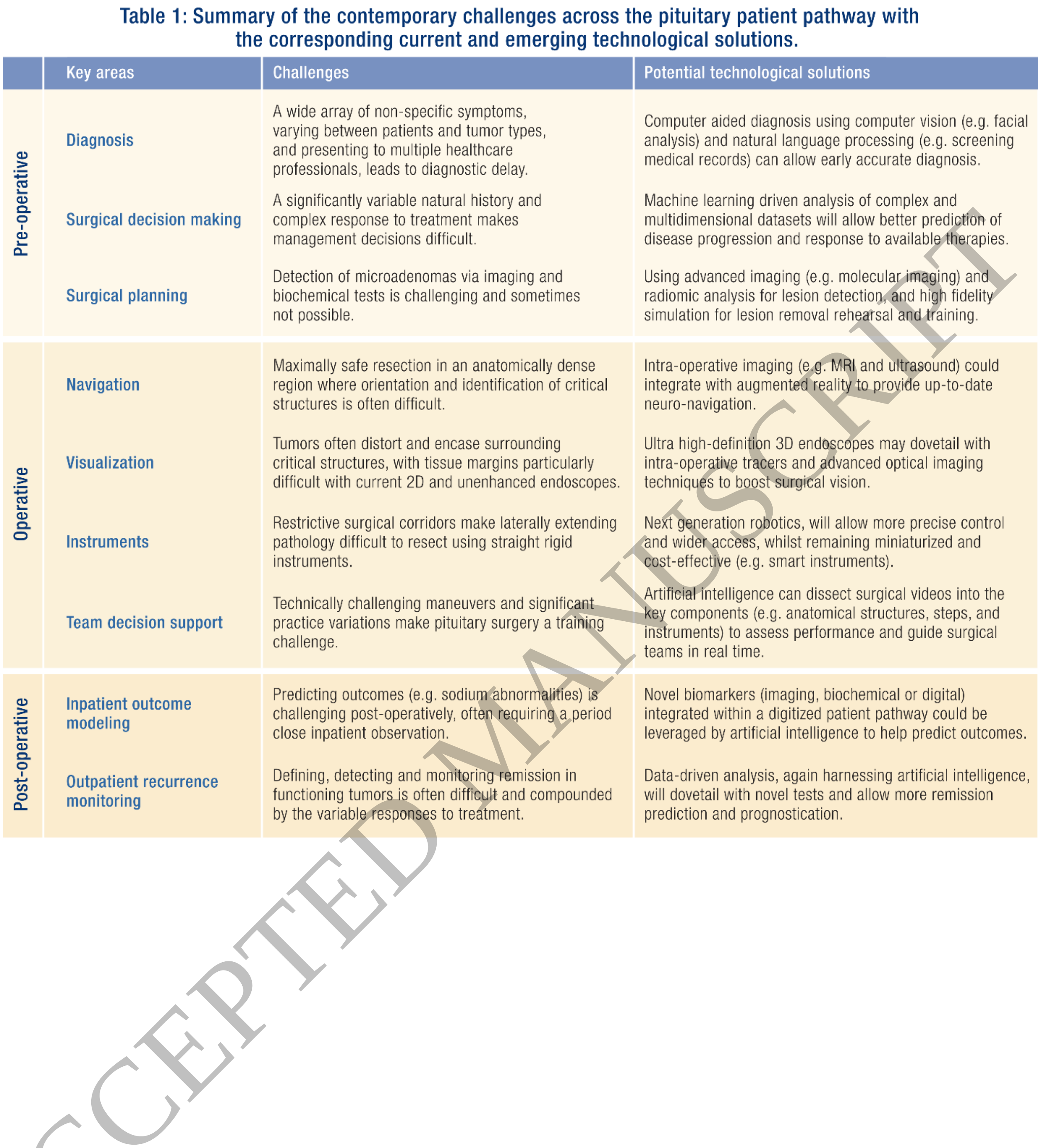

Table 1: Summary of the contemporary challenges across the pituitary patient pathway with the corresponding current and emerging technological solutions.

	Key areas	Challenges	Potential technological solutions
Pre-operative	Diagnosis	A wide array of non-specific symptoms, varying between patients and tumor types, and presenting to multiple healthcare professionals, leads to diagnostic delay.	Computer aided diagnosis using computer vision (e.g. facial analysis) and natural language processing (e.g. screening medical records) can allow early accurate diagnosis.
	Surgical decision making	A significantly variable natural history and complex response to treatment makes management decisions difficult.	Machine learning driven analysis of complex and multidimensional datasets will allow better prediction of disease progression and response to available therapies.
	Surgical planning	Detection of microadenomas via imaging and biochemical tests is challenging and sometimes not possible.	Using advanced imaging (e.g. molecular imaging) and radiomic analysis for lesion detection, and high fidelity simulation for lesion removal rehearsal and training.
Operative	Navigation	Maximally safe resection in an anatomically dense region where orientation and identification of critical structures is often difficult.	Intra-operative imaging (e.g. MRI and ultrasound) could integrate with augmented reality to provide up-to-date neuro-navigation.
	Visualization	Tumors often distort and encase surrounding critical structures, with tissue margins particularly difficult with current 2D and unenhanced endoscopes.	Ultra high-definition 3D endoscopes may dovetail with intra-operative tracers and advanced optical imaging techniques to boost surgical vision.
	Instruments	Restrictive surgical corridors make laterally extending pathology difficult to resect using straight rigid instruments.	Next generation robotics, will allow more precise control and wider access, whilst remaining miniaturized and cost-effective (e.g. smart instruments).
	Team decision support	Technically challenging maneuvers and significant practice variations make pituitary surgery a training challenge.	Artificial intelligence can dissect surgical videos into the key components (e.g. anatomical structures, steps, and instruments) to assess performance and guide surgical teams in real time.
Post-operative	Inpatient outcome modeling	Predicting outcomes (e.g. sodium abnormalities) is challenging post-operatively, often requiring a period close inpatient observation.	Novel biomarkers (imaging, biochemical or digital) integrated within a digitized patient pathway could be leveraged by artificial intelligence to help predict outcomes.
	Outpatient recurrence monitoring	Defining, detecting and monitoring remission in functioning tumors is often difficult and compounded by the variable responses to treatment.	Data-driven analysis, again harnessing artificial intelligence, will dovetail with novel tests and allow more remission prediction and prognostication.

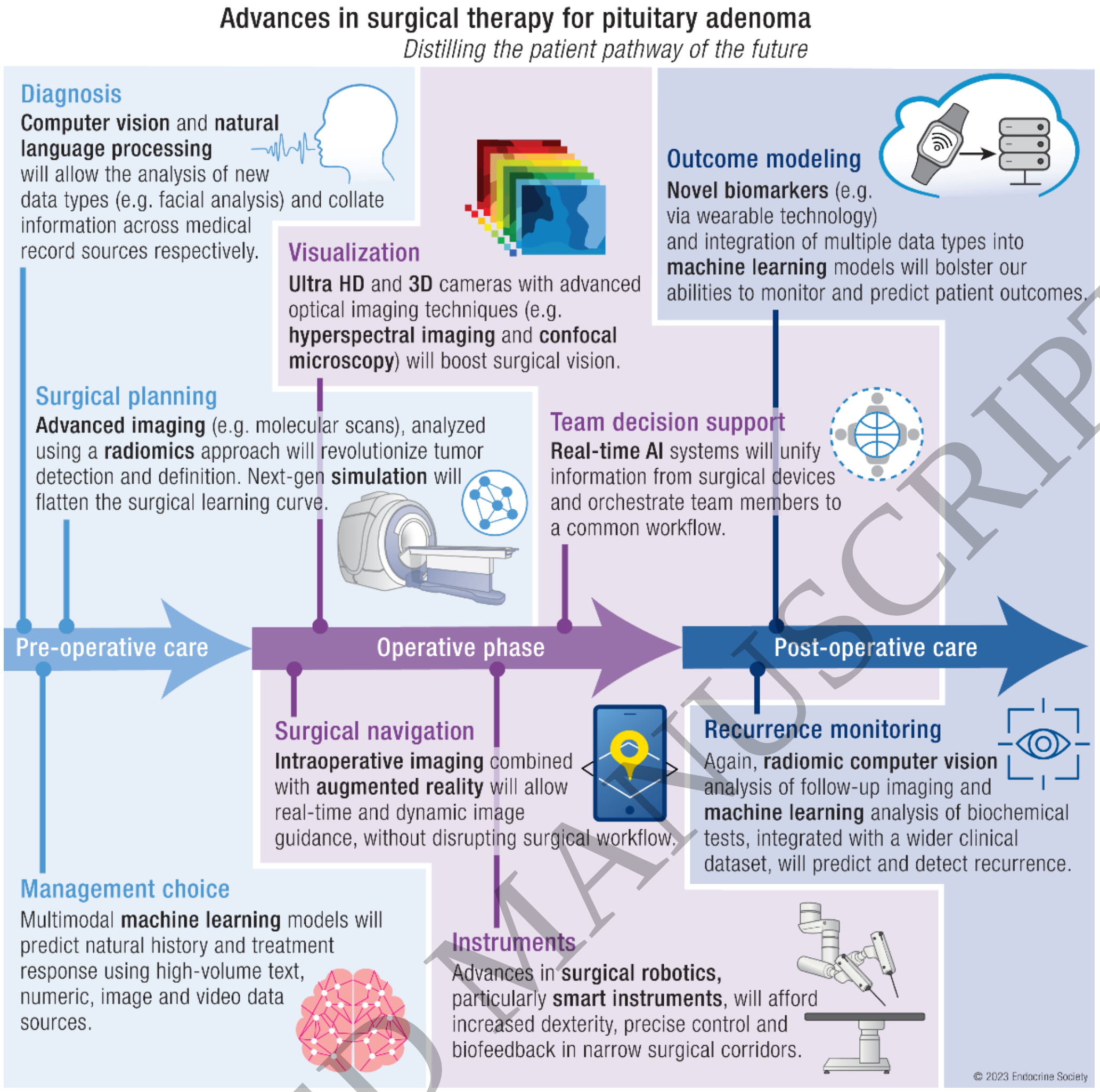

Advances in surgical therapy for pituitary adenoma

Distilling the patient pathway of the future

Diagnosis
Computer vision and **natural language processing** will allow the analysis of new data types (e.g. facial analysis) and collate information across medical record sources respectively.

Visualization
Ultra HD and **3D** cameras with advanced optical imaging techniques (e.g. **hyperspectral imaging** and **confocal microscopy**) will boost surgical vision.

Outcome modeling
Novel biomarkers (e.g. via wearable technology) and integration of multiple data types into **machine learning** models will bolster our abilities to monitor and predict patient outcomes.

Surgical planning
Advanced imaging (e.g. molecular scans), analyzed using a **radiomics** approach will revolutionize tumor detection and definition. Next-gen **simulation** will flatten the surgical learning curve.

Team decision support
Real-time AI systems will unify information from surgical devices and orchestrate team members to a common workflow.

Surgical navigation
Intraoperative imaging combined with **augmented reality** will allow real-time and dynamic image guidance, without disrupting surgical workflow.

Recurrence monitoring
Again, **radiomic computer vision** analysis of follow-up imaging and **machine learning** analysis of biochemical tests, integrated with a wider clinical dataset, will predict and detect recurrence.

Management choice
Multimodal **machine learning** models will predict natural history and treatment response using high-volume text, numeric, image and video data sources.

Instruments
Advances in **surgical robotics**, particularly **smart instruments**, will afford increased dexterity, precise control and biofeedback in narrow surgical corridors.

Graphical Abstract
135x135 mm (x DPI)

Essential Points

- Contemporary challenges, and their solutions, have been identified and segmented into three phases of the pituitary patient pathway: the preoperative, intraoperative and postoperative phases.
- Medical image computing, computer vision and natural language processing will harness novel data sets to achieve an earlier and more accurate diagnosis.
- Decision-making will be enhanced through advanced preoperative imaging and next-generation surgical simulation and training, alongside multi-modal machine learning predicting treatment responses and tailoring treatment plans.
- Surgical safety will be improved by novel intraoperative imaging and augmented reality providing new means of surgical navigation.
- The next generation of tools to equip the pituitary surgeon, including advanced visualisation, surgical robotics and smart instruments will push the limits of safe surgical resection extent.
- A surgical data science approach, using real-time AI systems will improve operative workflow, safety and team performance.
- Novel biomarkers, computer vision and machine learning will provide early-warning systems for complications, identify recurrence and predict remission to reshape the postoperative care of this patient group.