






Original research

# Multidisciplinary consensus guideline for the diagnosis and management of spontaneous intracranial hypotension

Sanjay Cheema <sup>1,2</sup>, Jane Anderson,<sup>3</sup> Heather Angus-Leppan <sup>4</sup>, Paul Armstrong,<sup>5</sup> David Butteriss,<sup>6</sup> Lalani Carlton Jones,<sup>7,8</sup> David Choi,<sup>1,9</sup> Amar Chotai,<sup>6</sup> Linda D'Antona <sup>1,9</sup>, Indran Davagnanam,<sup>1,10</sup> Brendan Davies,<sup>11</sup> Paul J Dorman,<sup>12</sup> Callum Duncan,<sup>13</sup> Simon Ellis,<sup>11</sup> Valeria Iodice,<sup>1,14</sup> Clare Joy,<sup>15</sup> Susie Lagrata,<sup>2</sup> Sarah Mead,<sup>15</sup> Danny Morland,<sup>16</sup> Justin Nissen,<sup>17</sup> Jenny Pople,<sup>15</sup> Nancy Redfern,<sup>16</sup> Parag P Sayal,<sup>9</sup> Daniel Scoffings,<sup>18</sup> Russell Secker,<sup>15</sup> Ahmed K Toma,<sup>1,9</sup> Tamsin Trevarthen,<sup>15</sup> James Walkden,<sup>19</sup> Jürgen Beck,<sup>20</sup> Peter George Kranz,<sup>21</sup> Wouter Schievink,<sup>22</sup> Shuu-Jiun Wang,<sup>23,24</sup> Manjit Singh Matharu <sup>1,2</sup>

► Additional supplemental material is published online only. To view, please visit the journal online (<http://dx.doi.org/10.1136/jnnp-2023-331166>).

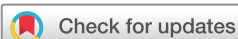For numbered affiliations see end of article.

## Correspondence to

Dr Manjit Singh Matharu, UCL Queen Square Institute of Neurology, London WC1N 3BG, UK; [manjit.matharu@ucl.ac.uk](mailto:manjit.matharu@ucl.ac.uk)

Received 27 January 2023

Accepted 21 April 2023



© Author(s) (or their employer(s)) 2023. Re-use permitted under CC BY-NC. No commercial re-use. See rights and permissions. Published by BMJ.

**To cite:** Cheema S, Anderson J, Angus-Leppan H, et al. *J Neurol Neurosurg Psychiatry* Epub ahead of print: [please include Day Month Year]. doi:10.1136/jnnp-2023-331166

## ABSTRACT

**Background** We aimed to create a multidisciplinary consensus clinical guideline for best practice in the diagnosis, investigation and management of spontaneous intracranial hypotension (SIH) due to cerebrospinal fluid leak based on current evidence and consensus from a multidisciplinary specialist interest group (SIG).

**Methods** A 29-member SIG was established, with members from neurology, neuroradiology, anaesthetics, neurosurgery and patient representatives. The scope and purpose of the guideline were agreed by the SIG by consensus. The SIG then developed guideline statements for a series of question topics using a modified Delphi process. This process was supported by a systematic literature review, surveys of patients and healthcare professionals and review by several international experts on SIH.

**Results** SIH and its differential diagnoses should be considered in any patient presenting with orthostatic headache. First-line imaging should be MRI of the brain with contrast and the whole spine. First-line treatment is non-targeted epidural blood patch (EBP), which should be performed as early as possible. We provide criteria for performing myelography depending on the spine MRI result and response to EBP, and we outline principles of treatments. Recommendations for conservative management, symptomatic treatment of headache and management of complications of SIH are also provided.

**Conclusions** This multidisciplinary consensus clinical guideline has the potential to increase awareness of SIH among healthcare professionals, produce greater consistency in care, improve diagnostic accuracy, promote effective investigations and treatments and reduce disability attributable to SIH.

## INTRODUCTION

### Background

Spontaneous intracranial hypotension (SIH) is a highly disabling syndrome secondary to spinal cerebrospinal fluid (CSF) leak caused by a dural tear, leaking meningeal diverticulum, or CSF-venous fistula (CVF).<sup>1</sup> The estimated annual incidence of

## WHAT IS ALREADY KNOWN ON THIS TOPIC

⇒ There is currently a lack of consistency and established treatment pathways for the investigation and management of patients with suspected spontaneous intracranial hypotension (SIH) due to cerebrospinal fluid (CSF) leak, and most of the published literature on SIH is from single centres with a dedicated service for patients with CSF leak and may be biased by local factors.

## WHAT THIS STUDY ADDS

⇒ To the best of our knowledge this is the first multidisciplinary consensus-based guideline for SIH. It covers all aspects of the patient pathway from point of first presentation with suspected SIH to follow-up after treatment.

## HOW THIS STUDY MIGHT AFFECT RESEARCH, PRACTICE OR POLICY

⇒ This will directly influence clinical practice, produce greater consistency in care, improve diagnostic accuracy, promote effective investigations and treatments and thereby reduce disability related to SIH.

SIH is 3.7 per 100 000.<sup>2</sup> The symptoms of SIH resemble intracranial hypotension from other causes such as postdural puncture, postsurgical and post-traumatic CSF leaks, but in SIH the leak occurs spontaneously in the spine at a site which is unknown at the time of presentation. SIH is typically characterised by orthostatic headache and a variety of other neurological symptoms, and in approximately 80% of cases there are MRI features of intracranial hypotension.<sup>3–5</sup>

SIH can present in a variety of settings and to a variety of healthcare professionals and requires coordinated care between multiple medical specialties. Recent evidence suggests that the majority of patients with SIH respond to treatment with

non-targeted epidural blood patches (EBPs), and in the majority of patients with persistent symptoms, the leak can be localised with myelography in order to plan targeted patching, transvenous embolisation or surgery.<sup>3</sup> Despite this, several misconceptions exist in the investigation and management of SIH,<sup>6</sup> and SIH is often misdiagnosed or diagnosed and treated late prolonging a potentially treatable condition.<sup>7,8</sup>

**Scope and purpose of the guideline**

We aimed to create a multidisciplinary consensus clinical guideline describing best practice in the diagnosis, investigation and management of SIH due to spinal CSF leak, based on current evidence and consensus from a multidisciplinary specialist interest group (SIG), with representation from patients.

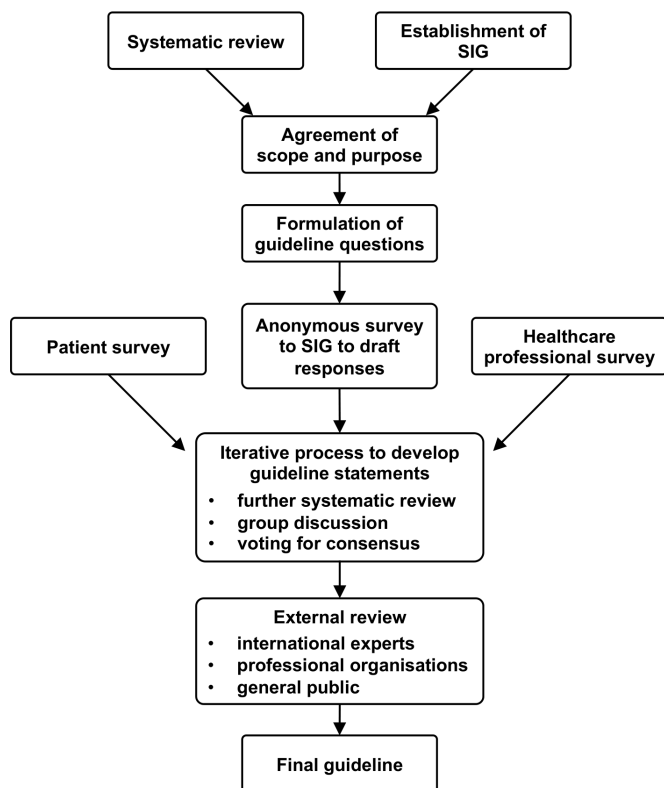
This document is intended to increase awareness of SIH among healthcare professionals, produce greater consistency in care, improve diagnostic accuracy, promote effective investigation and treatment and reduce disability related to SIH.

The guideline aims to address all aspects of the usual patient pathway from initial presentation with suspected SIH to follow-up after treatment, as well as several specific situations. The guideline does not apply to cranial CSF leaks, postdural puncture headache, post-traumatic or postsurgical spinal CSF leaks.

The intended target audience includes general practitioners, neurologists, radiologists, neurosurgeons, anaesthetists, pain specialists, emergency medicine specialists, physicians and other healthcare professionals who are involved in the care of patients with SIH.

**METHODS**

The guideline was developed and written in accordance with the international Appraisal of Guidelines, Research and Evaluation II instrument.<sup>9</sup> Figure 1 summarises the overall guideline



**Figure 1** Flow diagram of guideline development process. SIG, specialist interest group.

**Table 1** List of guideline question topics formulated by the SIG

Question No	Question
1	What key clinical features should lead to the diagnosis of SIH being considered?
2	What clinical mimics of SIH should be considered and how should the diagnosis be confirmed?
3	What predisposing conditions should be considered?
4	When and where should patients with SIH be referred?
5	What first-line investigations should be performed in patients with suspected SIH?
6	How should patients in whom there is a high clinical suspicion of SIH with normal brain and spine MRI be managed?
7	When should myelography be used in the investigation of SIH?
8	What myelographic strategies should be used in the investigation of SIH?
9	What is the role of intracranial pressure monitoring in the diagnosis of SIH?
10	What are the conservative and pharmacological management strategies that should be considered and for how long?
11	When should non-targeted epidural blood patches (EBP) be performed in the management of SIH?
12	How should non-targeted EBPs be performed?
13	What aftercare is recommended following epidural blood or fibrin sealant patching?
14	When and how should targeted patches be performed?
15	When and how should surgical management of a CSF leak be considered?
16	How should patients with imaging signs of SIH, but who are asymptomatic, be managed?
17	How should complications of SIH be identified and managed?
18	What is the best approach for headache management in SIH?
19	How should post-treatment rebound headache be identified and managed?
20	How should neurological symptoms other than headache in patients with SIH be identified and managed?
21	Is there a role for 'orthostatic rehabilitation' in the long-term management of patients with symptoms of SIH?
22	How should patients be followed up?

CSF, cerebrospinal fluid; SIG, specialist interest group; SIH, spontaneous intracranial hypotension.

development process. The guideline development process was initiated on the recommendation of the chief medical officer for England.

The SIG who developed the guideline consisted of nine neurologists, six neuroradiologists, six neurosurgeons, two anaesthetists, one headache nurse specialist and five patient representatives (members of the UK-based CSF Leak Association charity). All medical professionals involved had regular clinical experience in the management of SIH, and all were asked to disclose any relevant conflicts of interest.

The scope and purpose of the guideline, and a series of question topics which the guideline was to address were agreed by the SIG by consensus (see table 1).

A systematic literature review was conducted for each of the questions, according to methods described by D'Antona *et al*,<sup>3</sup> and was updated to include studies published until November 2022, and to include question topics which had not been investigated in the previous publication. Patients were surveyed about their experience of diagnosis and management of SIH in the UK. A survey was also conducted of healthcare professionals outside of the SIG who were expected to be the target audience of the

**Table 2** GRADE system for grading recommendations

Strength of the recommendation	Quality of the evidence
1=strongly recommended 2=weakly recommended	A=high quality: RCT(s) B=moderate quality: downgraded RCT(s) or upgraded observational study(s) C=low quality: observational study(s) D=very low quality: downgraded observational study(s)
Factors determining the strength of recommendations: ▶ Balance between desirable and undesirable effects ▶ Quality of evidence ▶ Values and preferences ▶ Costs of the intervention	Factors that may decrease QoE: ▶ Study limitations ▶ Inconsistency of results ▶ Indirectness of evidence ▶ Imprecision ▶ Publication bias Factors that may increase QoE: ▶ Large magnitude of effect ▶ Plausible confounding factors would reduce any demonstrated effect ▶ Dose–response gradient
GRADE, Grading of Recommendations, Assessment, Development and Evaluations; QoE, quality of the evidence; RCT, randomised controlled trial.	

guideline. The results of both surveys were used to inform the guideline development process, and the results are published elsewhere.<sup>8 10</sup>

A modified Delphi process was used to develop recommendations for each question topic as follows: SIG members were initially asked to return anonymous draft responses to all guideline questions relevant to their area of expertise with relevant supporting evidence from the literature. Questions were then addressed in a series of five virtual meetings by presenting the anonymous responses, drafting proposed guideline statements based on these, discussion, anonymous voting on any area which did not meet consensus and, finally, voting by the whole SIG on each aspect of the proposed guideline statements. Where statements did not achieve consensus when first presented, they were discussed further among the SIG refined and voted on again. Guideline statements were only accepted for inclusion in the guideline if greater than 70% consensus was reached. The percentage of the SIG who accepted each included statement is shown in online supplemental material 1.

The strength of recommendations and quality of evidence for interventions were graded according to the Grading of Recommendations, Assessment, Development and Evaluations system (table 2).<sup>11</sup> Good clinical practice statements based on face validity and expert opinion (EO), where there is little available direct evidence but a high level of certainty that the recommendation would do more good than harm, were not graded but marked as EO. The evidence supporting each of the guideline statements and areas of uncertainty are also outlined for each question in online supplemental material 1.

Auditing and monitoring criteria were developed to assess rates of guideline implementation and adherence to recommendations (see online supplemental materials 2 and 3).

The first draft of the guideline was reviewed by several international experts (JB, PGK, WS, S-JW) and several UK-based professional bodies of relevant specialties, and underwent a publication consultation. Following this, further discussion and voting was held by the SIG members about any suggested changes before the final series of guideline statements were finalised. The final guideline was approved by the Association of British Neurologists and endorsed by the Royal College of Physicians.

**Table 3** Commonly associated symptoms and rare presentations of SIH\*

Commonly associated symptoms	Rare presentations
Dizziness or vertigo (50.5%)	Interscapular pain (10.9%)
Nausea and vomiting (49.0%)	Dysgeusia (7.4%)
Disequilibrium (42.6%)	Hyperacusis (5.9%)
Muffled hearing or aural fullness (37.1%)	Behavioural variant frontotemporal dementia syndrome (2.5%)
Posterior neck pain (34.2%)	Reverse orthostatic headache (2%)
Cognitive impairment† (31.7%)	Bibrachial amyotrophy (1.5%)
Tinnitus (27.7%)	Superficial siderosis (1.5%)
Hypoacusis (26.2%)	Cerebral venous thrombosis (1%)
Fatigue (24.3%)	Abducens nerve palsy (1%)
Photophobia or phonophobia (20.3%)	Spinal cord herniation (1%)
Visual blurring (17.8%)	Coma (0.5%)
Facial numbness, paraesthesia or pressure (15.8%)	Syringomyelia (0.5%)
	Hemifacial spasm (0.5%)

\*Adapted from Schievink [4].  
†Most commonly non-specific problems with concentration and word finding.<sup>4</sup>  
SIH, spontaneous intracranial hypotension.

## GUIDELINE STATEMENTS

### Q1. What key clinical features should lead to the diagnosis of SIH being considered?

SIH should be considered in any patient presenting with orthostatic headache (other than following iatrogenic dural puncture or major trauma); ‘end of the day’ or ‘second half of the day’ headache with improvement of the headache on lying flat (as defined below); thunderclap headache which is followed by orthostatic headache; and new daily persistent headache with an initial orthostatic quality. The presence of associated symptoms (see table 3) should increase the suspicion of SIH.

We recommend a working definition of orthostatic headache as headache which meets the following criteria:

- ▶ Absent or only mild (1–3/10 on verbal rating scale (VRS)) on waking or after prolonged lying flat.
- ▶ The onset of the headache occurs within 2 hours of becoming upright.
- ▶ After lying flat, the headache should have a ‘good’ improvement in severity (>50% on VRS) within 2 hours.
- ▶ The timing of headache onset and offset is consistent.

### Q2. What differential diagnoses of SIH should be considered and how should the diagnoses be confirmed?

Differential diagnoses of SIH include postural tachycardia syndrome (PoTS), orthostatic hypotension, cervicogenic headache and migraine.

PoTS and orthostatic hypotension are diagnosed from a detailed autonomic history and haemodynamic autonomic responses to formal standing tests to document objective evidence of postural tachycardia (increase in heart rate by >30 beats per minute) or orthostatic hypotension (fall of >20 mm Hg in systolic blood pressure and/or >10 mm Hg in diastolic blood pressure).<sup>12</sup> A negative standing test does not exclude the diagnosis of PoTS and if clinical suspicion is high consider additional autonomic testing.

Cervicogenic headache (in the presence of cervical pathology) can be diagnosed with a history confirming that the headache is provoked by cervical movement rather than posture, reduced cervical range of motion and associated myofascial tenderness.

Migraine can be diagnosed with a history confirming that the headache is provoked by movement rather than posture, establishing migrainous biology, including history and trajectory

of episodes, presence of aura and vertigo (rather than hearing impairment and tinnitus).

Thunderclap headache presentations are most likely to be related to acute subarachnoid haemorrhage and its wider differential, of which SIH should be considered.

**Q3. What predisposing conditions should be considered?**

There may be no predisposing conditions to the development of SIH. The evidence identifying possible predisposing conditions is limited but enquiry may be made about connective tissue disorders and joint hypermobility disorders; and spinal pathology including osteophytes, disc herniation and discogenic microspurs in direct relation to the site of the spinal leak.

**Q4. When and where should patients with SIH be referred?**

Patients with suspected SIH should be referred to their local neurologist. If the patient is able to care for his or her self, the urgency of the referral should be 2–4 weeks, depending on the severity of clinical features including mental health impact. If the patient is not able to care for his or her self but has help, the urgency should be within 48 hours; and if they are not able to care for themselves and do not have help there should be an emergency admission. If the local neurologist does not have access to a practitioner skilled in performing EBPs they should be referred urgently to a regional centre with this expertise.

Patients should have early referral to a specialist centre if the diagnosis is in doubt, first-line treatments fail or there is a rapid clinical deterioration or serious complications such as subdural haematoma with mass effect (urgent referral to a tertiary neuroscience centre). For reasons other than rapid clinical deterioration, the time to assessment in a specialist neuroscience centre with expertise in SIH management should be within 1 month.

A specialist neuroscience centre should have the following services:

- ▶ Neuroradiological investigations and expertise including CT myelography (CTM) and/or digital subtraction myelography (DSM).
- ▶ Specialist clinical opinion, familiar and skilled in diagnosis and treatment of SIH.
- ▶ Practitioners skilled in epidural blood patching.
- ▶ Multidisciplinary team (MDT) meeting where patients with SIH are discussed.
- ▶ Expertise in performing targeted patching.
- ▶ Local guidelines for the use of fibrin sealant.
- ▶ Surgical expertise to repair a spinal CSF leak.

**Q5. What first-line investigation(s) should be performed in patients with suspected SIH?**

Ideally, MRI of the brain with intravenous contrast and MRI whole spine should be performed as first-line investigations. If not possible to achieve both at the same time, MRI of the brain with contrast should be performed as the first-line investigation.

MRI of the brain with contrast is essential to look for imaging signs that confirm the diagnosis of SIH (see figure 2). MRI of the whole spine is not always necessary for the diagnosis and is unlikely to locate the site of the CSF leak, but it can be helpful to identify the presence of findings that may direct subsequent invasive myelography.

If MRI is unavailable or if it is contraindicated, CT of the brain may show some of the findings supportive of the diagnosis.

Lumbar puncture should not routinely be performed for the sole purpose of confirming the diagnosis of SIH. If lumbar puncture is being performed for other reasons, such as to exclude alternative diagnoses, a CSF opening pressure should be measured at the time.

MRI of the brain protocol should include:

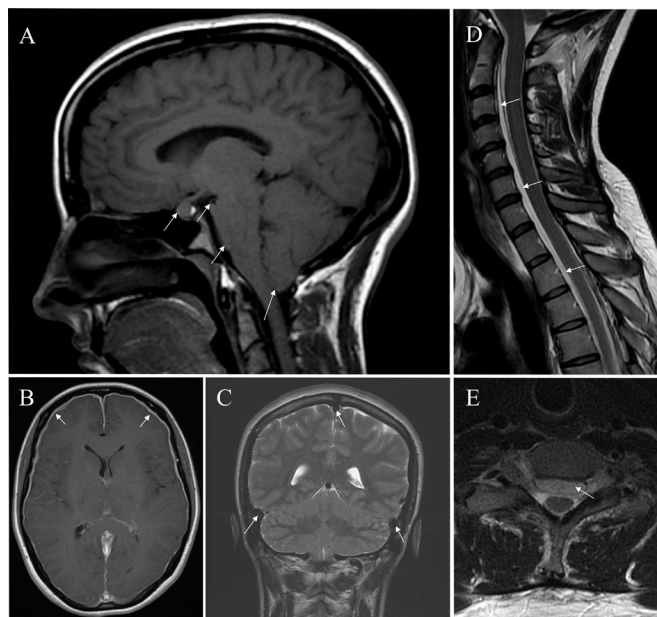
- ▶ T2 weighted (any plane) at 4–5 mm thickness or isotropic volume.
- ▶ Fluid-attenuated inversion recovery (axial or coronal) at 4–5 mm thickness or isotropic volume.
- ▶ T2\*-weighted gradient echo (GRE) or susceptibility-weighted imaging (SWI) (axial) at 2–5 mm thickness.
- ▶ Precontrast and postcontrast 3D isotropic volumetric T1-weighted acquisitions OR T1-weighted spin echo at 4–5 mm thickness in the sagittal and one other plane.

Spine MRI protocol should include:

- ▶ Fat-suppressed T2-weighted sequence such as short-tau inversion recovery (STIR) or other similar alternative.
- ▶ T2 weighted (sagittal) at 3–4 mm thickness in three parts.
- ▶ T2 weighted (axial) at 3–4 mm thickness of select segments of the spine.
- ▶ High-resolution steady-state or equivalent heavily T2-weighted 3D sequence (eg, constructive interference in steady state (CISS), fast imaging employing steady-state acquisition (FIESTA), balanced fast field echo (bFFE), Cube, or sampling perfection with application optimized contrast using different flip angle evolution (SPACE)) at a minimum isotropic resolution of 1 mm in three parts to cover the whole spine.

**Q6. How should patients in whom there is a high clinical suspicion of SIH with normal brain and spine MRI be managed?**

The presence of normal brain and spine MRI does not rule out SIH but is a recognised rare finding in patients with subsequently confirmed SIH. Ensure imaging has been reviewed by



**Figure 2** Typical MRI findings of spontaneous intracranial hypotension (SIH). (A) Sagittal T1 image showing enlargement of the pituitary, decreased mamillopontine distance, sagging of the brainstem and cerebellar tonsillar descent. (B) Axial T1 postcontrast image showing diffuse smooth dural thickening and pachymeningeal contrast enhancement. (C) Coronal T2 image showing distension of the dural venous sinuses. (D) Sagittal T2 image showing extensive ventral spinal longitudinal epidural collection (SLEC) extending from the upper cervical to thoracic regions. (E) Axial T2 image showing ventral SLEC.

a neuroradiologist and differential diagnoses have been considered. If a high clinical suspicion remains after consideration of the differential diagnosis and the imaging is confirmed as normal, then the patient should be referred to a specialist centre for MDT discussion and further management. Although there is limited evidence regarding the efficacy of performing empirical EBP in this context, up to two high-volume non-targeted lumbar EBPs could be considered.

#### Q7. When should myelography be used in the investigation of SIH?

The purpose of myelography in SIH is to locate the site of a spinal CSF leak in order to plan the targeted treatment.

It should be considered in any of the following scenarios:

- ▶ Patients who have at least one brain or spine MRI finding of SIH and have derived no benefit or only temporary benefit from one or more non-targeted EBPs.
- ▶ Patients who have normal brain and spine MRI, with meningeal diverticula, in whom the clinical suspicion of finding a CVF is high, and who have derived no benefit or only temporary benefit from one or more non-targeted EBPs.
- ▶ Patients who have normal brain and spine MRI, without meningeal diverticula, in whom the clinical suspicion is high and in whom myelography has been recommended after MDT discussion.
- ▶ If a patient is already under the care of a specialist MDT where myelography is available, and has not yet had a non-targeted EBP, the MDT may decide based on individual patient factors to proceed directly to myelography.

#### Q8. What myelographic strategies should be used in the investigation of SIH?

Myelography for spinal CSF leaks should be undertaken by a neuroradiologist with appropriate expertise and working as part of an MDT. The choice of myelographic technique (see [table 4](#)) depends on a number of factors, including whether a spinal longitudinal epidural collection (SLEC) is present or not, and the suspected underlying cause of the leak.

In patients with high clinical suspicion but normal brain and spine MRI, a CVF is the most likely cause of SIH. The likelihood of finding a leak in such patients is low, but decubitus CTM or lateral decubitus DSM are the recommended options.

Intrathecal gadolinium MR myelography lacks the temporal resolution of CTM and DSM and is not recommended as a first-line or second-line technique. It may sometimes be useful in cases of a suspected slowly leaking meningeal diverticulum when CTM or DSM has been negative. The use of intrathecal gadolinium is off-label and informed consent should be sought from patients for this.

Radionuclide cisternography has poor spatial and temporal resolutions and is not recommended as a tool for localising leaks.

**Table 4** Selection of myelographic technique based on spinal MRI findings

SLEC	Likely cause of leak	Patient position	Technique
Present	Discogenic microspur Lateral or dorsal dural tear	Depends on distribution of SLEC	CTM, DSM, UFCTM
Absent	CSF-venous fistula	Lateral decubitus	CTM, DSM

CSF, cerebrospinal fluid; CTM, CT myelography; DSM, digital subtraction myelography; SLEC, spinal longitudinal epidural collection; UFCTM, ultrafast CT myelography.

It may rarely have a role in confirming the presence of a CSF leak in patients with normal brain and spine MRI in whom there is a high clinical suspicion of SIH but the above methods have all been negative.

#### Q9. What is the role of intracranial pressure monitoring in the diagnosis of SIH?

It is unclear whether intraparenchymal intracranial pressure monitoring has a role in SIH and it is not recommended as part of the standard clinical pathway.

#### Q10. What are the conservative and pharmacological management strategies that should be considered and for how long?

Conservative management should be discussed with all patients with suspected SIH and implemented for up to 2 weeks from symptom onset, while offering non-targeted EBP as soon as possible, if symptoms do not resolve with conservative management alone. Conservative measures recommended should include bed rest and hydration (2.0–2.5 L daily). Other strategies which may be recommended are use of abdominal binders and avoidance of Valsalva manoeuvres.

Measures to reduce the risk of deconditioning and risk of deep vein thrombosis should be advocated during the period of bed rest.

Though evidence for use of medication is sparse, oral caffeine or intravenous caffeine could be considered but this should not delay investigations or definitive treatment.

#### Q11. When should non-targeted EBPs be performed in the management of SIH?

A non-targeted EBP should be offered in all patients with a clinical and/or imaging diagnosis of SIH, after no more than 2 weeks of conservative management.

If there is no response or a transient response to the first EBP, a second EBP could be considered before proceeding to myelography.

The recommended time interval between EBPs (or following symptom recurrence in those with a transient response) should be 2–4 weeks.

#### Q12. How should non-targeted EBPs be performed?

Non-targeted EBPs should be performed by an experienced practitioner; under local anaesthetic; with the option of using conscious sedation; and with the option of using fluoroscopic or CT guidance to access the epidural compartment. A full discussion of the rationale for epidural blood patching including potential risks and complications must be held and the patient's informed consent must be documented. The practitioner should consider adjunctive preprocedural and/or periprocedural analgesia. Chlorhexidine skin preparation above 0.5% concentration should not be used.

As much blood as possible should be administered up to 40 mL, ideally at a minimum total volume of 20 mL. The administration of autologous blood should cease when the patient experiences back pain/pressure, headaches or radicular symptoms that they can no longer tolerate.

#### Q13. What aftercare is recommended following epidural blood or fibrin sealant patching?

Following targeted or non-targeted EBP or fibrin sealant patch, patients should be monitored in a recovery area and undergo basic physiological observations (heart rate, blood pressure and pulse oximetry) as well as spinal observations. A period of 2–24 hours bed rest and observation is recommended.

Following non-targeted blood patches patients should be either in the supine or Trendelenburg position. Following targeted patches patients should be in the supine position with head elevated as comfortable.

Thromboprophylaxis should be considered during immobilisation following EBP, according to local institution venous thromboembolism policy.

The patient should have a clinical review prior to discharge. If not admitted overnight, patients should be contacted the following day to exclude the presence of concerning features.

Patients should be advised to seek urgent medical attention should they develop any of the following: new-onset severe back or leg pain, lower limb motor weakness or sensory disturbance, urinary or faecal incontinence, urinary retention, perineal sensory disturbance, nausea and vomiting or fever. Advice regarding the possible symptoms of post-treatment rebound headache should be provided, including a change in the nature and site of headache.

Patients should not drive themselves home. Patients should be advised to lie flat as much as possible for 1–3 days after procedure. Patients should be advised to minimise the following for 4–6 weeks: bending, straining, stretching, twisting, closed-mouth coughing, sneezing, heavy lifting, strenuous exercise and constipation.

### Q14. When and how should targeted patches be performed?

Targeted patches should be performed in patients who remain symptomatic following appropriate conservative management and/or non-targeted EBPs, in whom a causative lesion has been identified on DSM or CTM which is safely accessible via an image-guided transcutaneous approach.

The risks and benefits of image-guided patching should be discussed with the patient. Discussion may include risks/benefits of surgical management where appropriate.

Targeted patching should be performed by a consultant radiologist with appropriate training and experience in image-guided spinal interventional techniques in a neurosciences centre with local guidelines for the use of percutaneous fibrin sealant patching (off-label use/new procedure). This will usually be the neuroradiologist who has performed the myelography that demonstrated the spinal CSF leak/CVF. Exact technique will vary according to specific requirements of the leak type/site.

### Q15. When and how should surgical management of a CSF leak be considered?

Surgical management of SIH should be considered in patients who remain symptomatic following appropriate conservative management and/or non-targeted EBPs in whom a causative lesion has been identified on DSM or CTM. The decision to offer surgery should consider the response to previous treatments, severity of symptoms, site and type of the leak or CVF, feasibility and risk of surgery and patient preference. The decision to undertake surgery (vs targeted patching) should be made after discussion involving the neurosurgeon, neurologist, neuroradiologist and patient.

Surgery should be performed by a neurosurgeon with expertise in managing spinal CSF leaks. Exact technique will vary according to specific requirements of the leak type/site.

If a CVF is shown on myelography, then endovascular treatment may also be considered as a first-line treatment (along with targeted patching and surgery).

### Q16. How should patients with imaging signs of SIH, but who are asymptomatic, be managed?

Asymptomatic patients with radiological evidence of SIH should be referred to a specialist neuroscience centre and discussed in an MDT.

There is emerging evidence of potential significant long-term sequelae (particularly superficial siderosis) from persistent ventral spinal CSF leaks. This information should be discussed with asymptomatic patients.

Clinicians should discuss with patients and offer to investigate and treat asymptomatic spinal CSF leak with SLEEC, in light of the potential long-term risks, particularly of superficial siderosis.

Patients who opt for a conservative approach should be offered a clinical review and repeat neuroimaging (MRI of the brain including SWI or GRE sequence and spine MRI) every 1–2 years.

### Q17. How should complications of SIH be identified and managed?

#### Subdural haematoma

MRI of the brain with contrast and whole spine should be performed to investigate the possibility of spinal CSF leak in patients with subdural haematoma/hygromas where there is a high index of suspicion such as supportive history of orthostatic headache, or absence of trauma/coagulopathy/alcohol misuse.

Small or asymptomatic haematomas should be managed conservatively while treating the CSF leak. Symptomatic haematomas with significant mass effect may need burr hole drainage in conjunction with treating the leak.

#### Cerebral venous thrombosis

CT or MR venography should be considered in any sudden change in headache pattern or neurological examination in the context of SIH.

EBP should be prioritised as initial treatment of SIH with cerebral venous thrombosis. Addition of anticoagulation may be considered balancing the risks of bleeding complications on an individual basis.

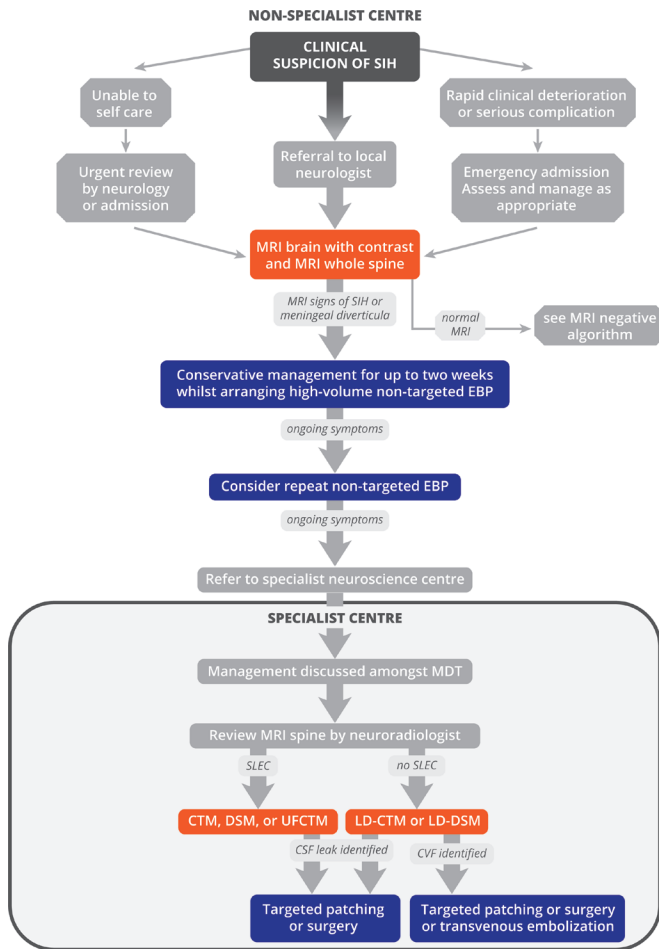
#### Superficial siderosis

Patients with SIH undergoing MRI should have MRI of the brain and spine with blood-sensitive sequences which can detect superficial siderosis. A higher index of suspicion is needed in patients with SIH who develop ataxia, hearing loss or myelopathic features. CSF ferritin levels and xanthochromia may be measured.

Patients with SIH with siderosis should be managed in a specialist centre of expertise for this disorder. Symptomatic patients with superficial siderosis should be offered non-targeted EBP, or targeted treatment of the CSF leak site if detected on imaging. Deferiprone may be considered in symptomatic patients where the underlying CSF leak is unable to be found or treated.

### Q18. What is the best approach for headache management in SIH?

Treatment of headache in SIH should focus primarily on management of the CSF leak, in tandem with best symptomatic management. Appropriate pain relief should be given as part of best symptom management. Paracetamol and/or non-steroidal anti-inflammatory drugs can be considered. Opioid medication may be required to provide adequate pain relief, but should be avoided in the routine long-term management of headache in SIH.



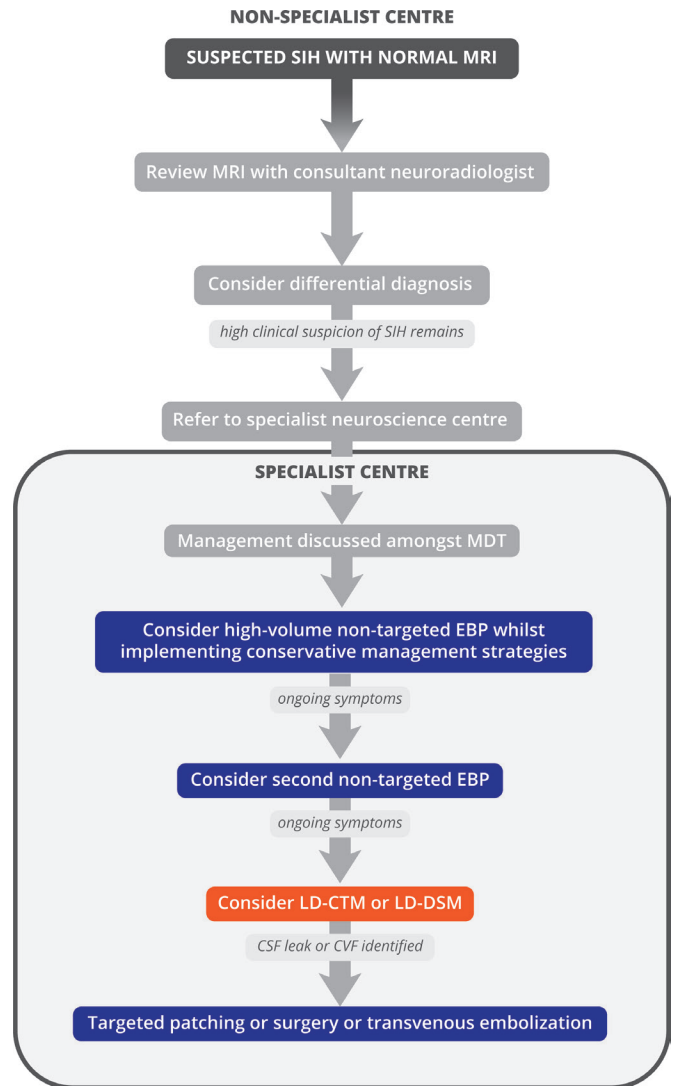
**Figure 3** Algorithm for MRI-positive patients. This algorithm is designed to show the recommended pathway for most patients rather than capture every single possible situation which may occur in the management of a patient with spontaneous intracranial hypotension (SIH). CSF, cerebrospinal fluid; CTM, CT myelography; CVF, CSF-venous fistula; DSM, digital subtraction myelography; EBP, epidural blood patch; LD-CTM, lateral decubitus CT myelography; LD-DSM, lateral decubitus digital subtraction myelography; MDT, multidisciplinary team; SLEC, spinal longitudinal epidural collection; UFCTM, ultrafast CT myelography.

In patients not responding to initial management of SIH, it is important to look for comorbid primary headache and treat as per phenotype, and important to consider and warn patients about the risk of medication overuse headache. For management of associated primary headache, drugs that potentially lower CSF pressure such as topiramate and indomethacin, and migraine preventives that can reduce blood pressure such as candesartan and beta blockers should be used with caution, as they may exacerbate the postural symptoms of SIH.

**Q19. How should post-treatment rebound headache be identified and managed?**

Before an EBP, fibrin sealant patch or surgical repair of spinal CSF leak, patients should be informed about the entity of post-treatment rebound headache.

When rebound headache after treatment of SIH occurs, patients need to be evaluated for secondary intracranial hypertension. If very severe or worsening continues after 1–2 weeks further clinical review may be indicated. The development of rebound headache after treatment for SIH may indicate



**Figure 4** Algorithm for MRI-negative patients. CSF, cerebrospinal fluid; CVF, CSF-venous fistula; EBP, epidural blood patch; LD-CTM, lateral decubitus CT myelography; LD-DSM, lateral decubitus digital subtraction myelography; MDT, multidisciplinary team; SIH, spontaneous intracranial hypotension.

postprocedural intracranial hypertension which is self-limiting in most individuals and can often be managed without medical treatment.

There is anecdotal use of acetazolamide, topiramate and diuretics for rebound intracranial hypertension but these agents are not well tolerated and recommended treatment duration is not well defined in SIH treatment-related rebound headache.

**Q20. How should neurological symptoms other than headache in patients with SIH be identified and managed?**

Treatment of non-headache symptoms in SIH should focus primarily on management of the CSF leak, in tandem with best symptomatic management, for example, antiemetics for nausea and vomiting and encouragement of adequate hydration. Symptomatic management and advice on ways of coping with symptoms should be discussed with patients, while attempting treatment for CSF leak, but the evidence base for their use is lacking.

### Q21. Is there a role for 'orthostatic rehabilitation' in the long-term management of orthostatic intolerance in patients with SIH?

Orthostatic rehabilitation should be considered for patients who have been bedbound, in particular those who have developed symptoms of orthostatic intolerance and patients with pre-existing PoTS and/or hypermobility syndromes. The rehabilitation programme should address both deconditioning affecting skeletal muscle and deconditioning affecting autonomic postural responses.

### Q22. How should patients be followed up?

All patients (all types of blood patch, surgery, any person who has had therapeutic intervention) should be followed up clinically and should be given contact details for their responsible clinical team. We recommend follow-up at the following intervals:

- ▶ Early review for complications (following any intervention): 24–48 hours.
- ▶ Intermediate follow-up after EBP: 10–14 days.
- ▶ Intermediate follow-up after surgery: 3–6 weeks.
- ▶ Late follow-up (after any intervention): 3–6 months.

We recommend assessing for the following during follow-up:

- ▶ Peak headache severity on 0–10 scale.
- ▶ Time to severe headache onset after becoming upright.
- ▶ Severity of other symptoms, for example, audiovestibular/cognitive.
- ▶ Time able to spend upright before needing to lie down.
- ▶ Cumulative hours able to spend upright per day.
- ▶ Headache disability and quality of life outcome scores may be used; however, they are not validated for SIH.

In cases where there is no clinical improvement, or initial improvement with subsequent relapse following any intervention, it is recommended the patient is referred back to the MDT/specialist for discussion. Further imaging or intervention may be required.

In cases where there is a sustained long-term improvement, no further specialist/MDT involvement may be necessary. Further follow-up imaging to act as a baseline for any further imaging/treatment is at the discretion of the specialist who performed the procedure.

Repeat invasive imaging techniques should not be performed for the purpose of determining a baseline in patients who are asymptomatic or significantly improved.

## DISCUSSION

We hope that this multidisciplinary consensus clinical guideline will lead to improved and more uniform pathways in the investigation and management of SIH in the UK, and potentially internationally, stimulating interest in the topic and highlighting future research questions. The guideline recommendations are supported by algorithms (figures 3 and 4) summarising the recommended pathway suitable for most patients. The guideline is intended to guide non-experts on the principles of management rather than serve as mandatory recommendations. Suggested auditing and monitoring criteria to aid implementation and adherence to the guideline are included as online supplemental materials 2 and 3.

To our knowledge a multidisciplinary consensus-based guideline for SIH has not previously been produced. Previously published algorithms for management of SIH are from single centres which may be biased by local factors, or do not cover the whole patient pathway.<sup>13–16</sup> We have also included aspects of SIH which were identified as especially important to patients

including differential diagnosis, identification of comorbidities and symptom management.

Potential barriers to implementation of this guidance include the lack of provision for non-targeted EBPs, advanced myelographic techniques and targeted patching. However, we anticipate that the publication of this guidance will stimulate training and establishment of more widespread local services for these procedures. Non-targeted EBPs are commonly performed by obstetric anaesthetists for postdural puncture headache using the same technique which is employed in SIH. Myelography and targeted patching are limited to the smaller subset of patients who do not respond to first-line treatments and are provided by a small number of clinicians in specialist centres.

We recognise the limited evidence base for some of the recommendations. Hence, a modified Delphi method was used to develop the consensus guideline statements, and the guideline was reviewed by several international experts and professional bodies. We also recognise the recently expanding volume of SIH publications in the literature. Therefore, we plan to update the guideline regularly, with the next revision planned in 3 years' time.

### Author affiliations

<sup>1</sup>Department of Brain Repair and Rehabilitation, UCL Queen Square Institute of Neurology, London, UK

<sup>2</sup>Headache and Facial Pain Group, National Hospital for Neurology and Neurosurgery, London, UK

<sup>3</sup>Neurology Department, Addenbrooke's Hospital, Cambridge, UK

<sup>4</sup>Neurology Department, Royal Free London NHS Foundation Trust, London, UK

<sup>5</sup>Neuroradiology Department, Institute of Neurological Sciences, Glasgow, UK

<sup>6</sup>Department of Neuroradiology, Newcastle Upon Tyne Hospitals NHS Foundation Trust, Newcastle Upon Tyne, UK

<sup>7</sup>Neuroradiology Department, Guy's and St Thomas' Hospitals NHS Trust, London, UK

<sup>8</sup>Neuroradiology Department, King's College Hospital NHS Foundation Trust, London, UK

<sup>9</sup>Victor Horsley Department of Neurosurgery, National Hospital for Neurology and Neurosurgery, London, UK

<sup>10</sup>Department of Neuroradiology, National Hospital for Neurology and Neurosurgery, London, UK

<sup>11</sup>Neurology Department, University Hospitals of North Midlands NHS Trust, Stoke-on-Trent, UK

<sup>12</sup>Department of Neurology, Newcastle Upon Tyne Hospitals NHS Foundation Trust, Newcastle Upon Tyne, UK

<sup>13</sup>Department of Neurology, NHS Grampian, Aberdeen, UK

<sup>14</sup>Autonomic Unit, National Hospital for Neurology and Neurosurgery, London, UK

<sup>15</sup>CSF Leak Association, Strathpeffer, UK

<sup>16</sup>Department of Anaesthesia, Newcastle Upon Tyne Hospitals NHS Foundation Trust, Newcastle Upon Tyne, UK

<sup>17</sup>Neurosurgery Department, Newcastle Upon Tyne Hospitals NHS Foundation Trust, Newcastle Upon Tyne, UK

<sup>18</sup>Department of Radiology, Addenbrooke's Hospital, Cambridge, UK

<sup>19</sup>Neurosurgery Department, NHS Grampian, Aberdeen, UK

<sup>20</sup>Department of Neurosurgery, Medical Center-University of Freiburg, Freiburg, Germany

<sup>21</sup>Department of Radiology, Duke University Medical Center, Durham, North Carolina, USA

<sup>22</sup>Neurosurgery Department, Cedars-Sinai Medical Center, Los Angeles, California, USA

<sup>23</sup>Neurology Department, Taipei Veterans General Hospital, Taipei, Taiwan

<sup>24</sup>Brain Research Center, National Yang Ming Chiao Tung University School of Medicine, Taipei, Taiwan

**Twitter** Amar Chotai @AmarChotai, Sarah Mead @realsarahmead and Manjit Singh Matharu @manjit\_matharu

**Acknowledgements** The authors acknowledge the following: Anthony Ordman and Dr Alok Tyagi, both of whom contributed to early stages of the guideline development process; patients and healthcare professionals outside the SIG who responded to the surveys and/or the public consultation of the draft guideline; Deborah Ogg who attended as an additional patient representative during some of the SIG meetings; Clare Sargeant and Shena Carrick who helped with administration and planning of SIG meetings; Prashant Shah (PDGraphics) who designed the algorithm graphics; and the Association of British Neurologists Headache and Pain



Advisory Group, the British Association for the Study of Headache, the Royal College of Physicians, the Royal College of Edinburgh, the Royal College of Anaesthetists, the Association of Anaesthetists, and the Obstetric Anaesthetists Association, all of whom gave feedback on the first draft of the guidelines.

**Contributors** SC: study design; administration of SIG meetings; SIG member responsible for drafting, discussing and voting on the guideline statements; drafting and revision of manuscript. JA, HA-L, PA, DJAB, LCJ, DC, AC, LD'A, ID, BD, PJD, CD, SE, VI, SL, DM, JN, JP, NR, PPS, DS, AKT, JW: SIG members responsible for drafting, discussing and voting on the guideline statements; revision of manuscript. SM, RS, TT: non-voting patient members of the SIG who took part in the discussion of guideline statements; helped with administration of SIG meetings. CJ: conception and design of the study; administration of SIG meetings; SIG member responsible for drafting, discussing and voting on the guideline statements; revision of manuscript. JB, PGK, WS, S-JW: international experts who reviewed and gave feedback on the first draft and final draft of the guideline statements; revision of manuscript. MSM: conception and design of the study; administration of SIG meetings; SIG member responsible for drafting, discussing and voting on the guideline statements; revision of manuscript. MSM is responsible for the overall content as guarantor.

**Funding** The authors have not declared a specific grant for this research from any funding agency in the public, commercial or not-for-profit sectors.

**Competing interests** JA: remuneration for consultancy advice and education provision from Allergan/AbbVie and TEVA. HA-L: lectures and education paid by International Medical Press, Sanofi and Eisai. LCJ: lecture fees received from Radiopaedia. SC: research fellowship sponsored by Abbott. LD'A: supported by an NIHR Academic Clinical Fellowship and was the recipient of a research fellowship sponsored by B Braun. BD: remuneration for consultancy advice and education provision from TEVA, Allergan and Lilly. PJD: shareholding in BMS, Regeneron and Ionis Pharma. SE: owns the North Midlands Neurosciences. VI: reports speaker fees and honoraria from Theravance Biopharma and Jensen, outside of the present work; supported by the National Institute for Health and Care Research University College London Hospitals Biomedical Research Centre. SL: received fees for attending advisory meetings, presentations and preparing presentation materials from Allergan, TEVA, Eli Lilly and Novartis. MSM: chair of the medical advisory board of the CSF Leak Association, serves on the advisory board for Abbott, Allergan, Novartis, Eli Lilly, Medtronic, Autonomic Technologies and TEVA, and has received payment for the development of educational presentations from Allergan, electroCore, Eli Lilly, Novartis and TEVA. CJ, SM, JP, RS, TT: members of CSF Leak Association. S-JW: received honoraria as a moderator from AbbVie, Pfizer, Eli Lilly and Biogen, and has been the PI in trials sponsored by AbbVie, Novartis and Lundbeck. He has received research grants from the Taiwan Minister of Technology and Science (MOST), Brain Research Center, National Yang Ming Chiao Tung University from The Featured Areas Research Center Program within the framework of the Higher Education Sprout Project by the Ministry of Education (MOE) in Taiwan, Taipei Veterans General Hospital, Taiwan Headache Society and Taiwan branches of Eli Lilly and Novartis.

**Patient consent for publication** Not applicable.

**Provenance and peer review** Not commissioned; externally peer reviewed.

**Data availability statement** All data relevant to the study are included in the article or uploaded as supplementary information.

**Supplemental material** This content has been supplied by the author(s). It has not been vetted by BMJ Publishing Group Limited (BMJ) and may not have been peer-reviewed. Any opinions or recommendations discussed are solely those of the author(s) and are not endorsed by BMJ. BMJ disclaims all liability and responsibility arising from any reliance placed on the content. Where the content

includes any translated material, BMJ does not warrant the accuracy and reliability of the translations (including but not limited to local regulations, clinical guidelines, terminology, drug names and drug dosages), and is not responsible for any error and/or omissions arising from translation and adaptation or otherwise.

**Open access** This is an open access article distributed in accordance with the Creative Commons Attribution Non Commercial (CC BY-NC 4.0) license, which permits others to distribute, remix, adapt, build upon this work non-commercially, and license their derivative works on different terms, provided the original work is properly cited, appropriate credit is given, any changes made indicated, and the use is non-commercial. See: <http://creativecommons.org/licenses/by-nc/4.0/>.

#### ORCID iDs

Sanjay Cheema <http://orcid.org/0000-0002-5438-6549>  
Heather Angus-Leppan <http://orcid.org/0000-0001-7004-3848>  
Linda D'Antona <http://orcid.org/0000-0001-9918-5225>  
Manjit Singh Matharu <http://orcid.org/0000-0002-4960-2294>

#### REFERENCES

- Schievink WI, Maya MM, Jean-Pierre S, *et al*. A classification system of spontaneous spinal CSF leaks. *Neurology* 2016;87:673–9.
- Schievink WI, Maya MM, Moser FG, *et al*. Incidence of spontaneous intracranial hypotension in a community: Beverly Hills, California, 2006–2020. *Cephalalgia* 2022;42:312–6.
- D'Antona L, Jaime Merchan MA, Vassiliou A, *et al*. Clinical presentation, investigation findings, and treatment outcomes of spontaneous intracranial hypotension syndrome: a systematic review and meta-analysis. *JAMA Neurol* 2021;78:329–37.
- Schievink WI. Spontaneous intracranial hypotension. *N Engl J Med* 2021;385:2173–8.
- Wang SJ. Spontaneous intracranial hypotension. *CONTINUUM* 2021;27:746–66.
- Kranz PG, Gray L, Amrhein TJ. Spontaneous intracranial hypotension: 10 myths and misperceptions. *Headache* 2018;58:948–59.
- Schievink WI. Misdiagnosis of spontaneous intracranial hypotension. *Arch Neurol* 2003;60:1713–8.
- Cheema S, Joy C, Pople J, *et al*. Patient experience of diagnosis and management of spontaneous intracranial hypotension: a cross-sectional online survey. *BMJ Open* 2022;12:e057438.
- Brouwers MC, Kho ME, Browman GP, *et al*. Agree II: advancing Guideline development, reporting and evaluation in health care. *CMAJ* 2010;182:E839–42.
- Cheema S, Anderson J, Duncan C, *et al*. Survey of healthcare professionals' knowledge, attitudes and practices regarding spontaneous intracranial hypotension. *BMJ Neurol Open* 2022;4:e000347.
- Guyatt GH, Oxman AD, Vist GE, *et al*. Grade: an emerging consensus on rating quality of evidence and strength of recommendations. *BMJ* 2008;336:924–6.
- Mathias CJ, Low DA, Iodice V, *et al*. *Investigation of autonomic disorders. Autonomic failure a textbook of clinical disorders of the autonomic nervous system*. 5th ed. Oxford: Oxford University Press, 2013.
- Davidson B, Nassiri F, Mansouri A, *et al*. Spontaneous intracranial hypotension: a review and introduction of an algorithm for management. *World Neurosurg* 2017;101:343–9.
- Medina JH, Abrams K, Falcone S, *et al*. Spinal imaging findings in spontaneous intracranial hypotension. *AJR Am J Roentgenol* 2010;195:459–64.
- Mokri B. Spontaneous intracranial hypotension. *Continuum (Minneapolis)* 2015;21:1086–108.
- Callen AL, Timpone VM, Schwertner A, *et al*. Algorithmic multimodality approach to diagnosis and treatment of spinal CSF leak and venous fistula in patients with spontaneous intracranial hypotension. *AJR Am J Roentgenol* 2022;219:292–301.

## Supplementary material 1. Consensus levels, grading of evidence and evidence base for guideline statements

### Q1. What key clinical features should lead to the diagnosis of SIH being considered?

Guideline statements	Consensus level	GRADE
SIH should be considered in any patient presenting with:		
<ul style="list-style-type: none"> <li>• Orthostatic headache (other than following iatrogenic dural puncture or major trauma).</li> </ul>	100%	1B
<ul style="list-style-type: none"> <li>• “End of the day” or “second half of the day” headache with improvement of the headache on lying flat (as defined below).</li> </ul>	91.7%	1C
<ul style="list-style-type: none"> <li>• Thunderclap headache which is followed by orthostatic headache.</li> </ul>	86.9%	1C
<ul style="list-style-type: none"> <li>• New daily persistent headache with an initial orthostatic quality.</li> </ul>	91.7%	1C
The presence of associated symptoms (see Table 3) should increase the suspicion of SIH.	100%	1C
We recommend a working definition of orthostatic headache as headache which meets the following criteria:		
<ul style="list-style-type: none"> <li>• Absent or only mild (1-3/10 on verbal rating scale (VRS)) on waking or after prolonged lying flat.</li> </ul>	75%	2C
<ul style="list-style-type: none"> <li>• The onset of the headache occurs within 2 hours of becoming upright.</li> </ul>	71.4%	2C
<ul style="list-style-type: none"> <li>• After lying flat, the headache should have a “good” improvement in severity (&gt;50% on verbal rating scale) within 2 hours.</li> </ul>	83.3%	2C
<ul style="list-style-type: none"> <li>• The timing of headache onset and offset is consistent.</li> </ul>	100%	2C

Orthostatic headache is the most common and reliable presenting symptom in patients with subsequently confirmed SIH. A meta-analysis of 33 open label studies and case series estimated that headache was present in 97% of patients with SIH, and the headache was orthostatic in 92% of cases (1). In addition to the classical orthostatic headache, headache can take many hours to develop on assuming an upright posture (“second half of the day headache”), and headache can be of thunderclap onset resembling subarachnoid haemorrhage

(2, 3). It is recognised that over time the orthostatic quality of the headache due to SIH can attenuate or even disappear completely (4). It is therefore important to enquire about an orthostatic quality at the time of onset of a new daily persistent headache (5). Several associated symptoms are commonly present in patients with confirmed SIH (see Table S1). Clinicians should also be aware of several rare presentations of SIH (see Table S1), in which, particularly if there is a postural component to the symptoms and supportive imaging features, SIH should be considered (6, 7).

**Table S1. Commonly associated symptoms and rare presentations of SIH\***

Commonly associated symptoms	Rare presentations
Dizziness or vertigo (50.5%)	Interscapular pain (10.9%)
Nausea and vomiting (49.0%)	Dysgeusia (7.4%)
Disequilibrium (42.6%)	Hyperacusis (5.9%)
Muffled hearing or aural fullness (37.1%)	Behavioural variant frontotemporal dementia syndrome (2.5%)
Posterior neck pain (34.2%)	Reverse orthostatic headache (2%)
Cognitive impairment <sup>#</sup> (31.7%)	Bibrachial amyotrophy (1.5%)
Tinnitus (27.7%)	Superficial siderosis (1.5%)
Hypoacusis (26.2%)	Cerebral venous thrombosis (1%)
Fatigue (24.3%)	Abducens nerve palsy (1%)
Photophobia or phonophobia (20.3%)	Spinal cord herniation (1%)
Visual blurring (17.8%)	Coma (0.5%)
Facial numbness, paraesthesia, or pressure (15.8%)	Syringomyelia (0.5%)
	Hemifacial spasm (0.5%)

\*Adapted from Schievink, 2021 (7)

<sup>#</sup> most commonly non-specific problems with concentration and word finding (7)

Current definitions of orthostatic headache are vague and risk both over and under-diagnosing SIH. In most studies of SIH, the orthostatic characteristics of the headache are

poorly defined. Two small studies have attempted to quantify the time for the headache to begin after becoming upright. In the smaller study, all 30 patients reported the onset was within 5 minutes (8). In the larger study of 90 patients, the onset was within 15 minutes in 53 (59%), between 15 minutes and 2 hours in 14 (16%), and longer than 2 hours or non-orthostatic in 22 (24%) (9). The International Classification of Headache Disorders 3<sup>rd</sup> edition (ICHD-3) criteria for headache attributed to SIH (see Table S2) do not include information on headache characteristics (10). Headache characteristics were defined in the previous ICHD-II criteria (see Table S2), but by restricting the onset of orthostatic headache to 15 minutes the criteria are likely to be too restrictive (11). In an attempt to improve consistency, the working definition of orthostatic headache given above was agreed by consensus. Individuals who report troublesome orthostatic headache with onset taking more than 2 hours should be evaluated for additional features of SIH if the clinical suspicion of SIH is well-founded.

**Table S2. International Headache Society criteria for headache attributed to SIH**

<b>ICHD-2 criteria(11)</b>	
A	Diffuse and/or dull headache that worsens within 15 minutes after sitting or standing, with at least one of the following: <ol style="list-style-type: none"> <li>1. neck stiffness</li> <li>2. tinnitus</li> <li>3. hypoacusia</li> <li>4. photophobia</li> <li>5. nausea</li> </ol>
B	At least one of the following: <ol style="list-style-type: none"> <li>1. evidence of low CSF pressure on MRI</li> <li>2. evidence of CSF leakage on conventional myelography, CT myelography, or cisternography</li> <li>3. CSF opening pressure &lt;60 mm H<sup>2</sup>O in the sitting position</li> </ol>
C	No history of dural puncture or other cause of CSF fistula
D	Headache resolves within 72 hours after epidural blood patching
<b>ICHD-3 criteria(10)</b>	

A	Any headache fulfilling criterion C
B	Absence of a procedure or trauma known to be able to cause CSF leakage; and either of both of the following: <ol style="list-style-type: none"> <li>1. low CSF pressure (&lt;60 mm CSF)</li> <li>2. evidence of CSF leakage on imaging</li> </ol>
C	Headache has developed in temporal relation to the low CSF pressure or CSF leakage, or has led to its discovery
D	Not better accounted for by another ICHD-3 diagnosis

### *Uncertainty*

The evidence for the time to onset of orthostatic headache on assuming an upright posture is limited, and there is currently no systematic evidence for the presence of a mild headache on lying flat, the time to offset of pain after lying flat, and the level to which pain improves on lying flat. The working definition of orthostatic headache may therefore be revised if further evidence becomes available.

### **Q2. What differential diagnoses of SIH should be considered and how should the diagnosis be confirmed?**

<b>Guideline statements</b>	<b>Consensus level</b>	<b>GRADE</b>
Differential diagnoses of SIH include: <ul style="list-style-type: none"> <li>• Postural tachycardia syndrome (PoTS)</li> <li>• Orthostatic hypotension</li> <li>• Cervicogenic headache</li> <li>• Migraine</li> </ul>	100%	2C
	78.3%	EO
	92.6%	EO
	87.5%	EO
PoTS and orthostatic hypotension are diagnosed by detailed autonomic history and haemodynamic autonomic responses to formal standing tests to document objective evidence of postural tachycardia (increase of heart rate by >30 beats per minute) or orthostatic hypotension (fall of >20mmHg in systolic and/or	90.9%	EO

<p>&gt;10mmHg in diastolic blood pressure). Blood pressure (BP) and heart rate (HR) should be measured with the subject lying supine at 1, 3, and 5 minutes. Ten minutes of standing is then performed with BP and HR recorded at 1, 3, 5, 7 and 10 minutes for interrogation of PoTS, with up to five minutes required to capture orthostatic hypotension.(12)A negative standing test does not exclude the diagnosis of PoTS and if clinical suspicion is high consider additional autonomic testing.</p>		
<p>Cervicogenic headache (in the presence of cervical pathology) can be diagnosed by history to confirm if headache is provoked by cervical movement rather than posture, reduced cervical range of motion and associated myofascial tenderness.</p>	91.7%	EO
<p>Migraine can be diagnosed by history to confirm that headache is provoked by movement rather than posture, establishing migrainous biology, including history and trajectory of episodes, presence of aura, and vertigo (rather than hearing impairment and tinnitus).</p>	95.8%	EO
<p>Thunderclap headache presentations are most likely to be related to acute subarachnoid haemorrhage and its wider differential, of which SIH should be considered.</p>	73.9%	EO

The clinical differential diagnoses of SIH are those syndromes with overlapping symptoms including orthostatic headache, neck and back pain and stiffness, and vestibular symptoms. PoTS, cervicogenic headache, and migraine are recognised in the literature and by consensus view to be the most relevant differentials (13, 14). It is important to note that these conditions can co-exist with SIH and a positive diagnosis of one should not preclude the consideration and investigation of SIH (15).

Although not differential diagnoses, it is important to recognise that patients may present de novo with complications of SIH including atraumatic bilateral subdural haematomas (especially in those less than 60 years of age), cerebral venous sinus thrombosis, and infratentorial superficial siderosis, which should prompt consideration of underlying SIH (16, 17).

*Uncertainty*

There are no high-quality studies that assess in clinical practice the validity of the differentials outlined. Cervicogenic headache would include headache related to cranio-cervical hypermobility, which is a consideration in patients with joint hypermobility disorders, although there is limited evidence of this presenting with orthostatic headache.

**Q3. What predisposing conditions should be considered?**

<b>Guideline statements</b>	<b>Consensus level</b>	<b>GRADE</b>
There may be no predisposing conditions to the development of SIH. The evidence identifying possible predisposing conditions is limited but enquiry may be made about the following:	82.4%	EO
Connective tissue disorders and joint hypermobility disorders.	94.1%	2C
Spinal pathology including osteophytes, disc herniation, and discogenic micro-spurs in direct relation to the site of the spinal leak.	87.5%	2C

There are no known universal predisposing factors for the development of SIH. Connective tissue disorders may be linked to an increased susceptibility to SIH. This is based on several case series and case reports of SIH in patients, most of whom have either Marfan's syndrome or hypermobile Ehlers-Danlos Syndrome, and the suspicion that systemic connective tissue disorders are associated with dural weakness. In a prospective study of 50 patients with SIH, heritable connective tissue disorders were identified in 18% (18). Whilst case series and reports on spinal pathology are fewer, it is clear that in some patients spinal pathology may be the cause of the dural breach resulting in spinal CSF leak itself (19).

*Uncertainty*

Features of connective tissue disorder are not uncommon in the general population, and a case control study in Taiwan has questioned the association with SIH. The authors found no increased rate of joint hypermobility, skin features of EDS, or skeletal features of Marfan (other than disproportionately long limbs) between those with and without SIH (20). Further control matched studies reviewing the prevalence of connective tissue disorders in those with and without SIH are needed to understand this further.

Bariatric surgery as a potential predisposition to SIH has been reported in the literature by a single centre (21). However, by consensus agreement this was not included in the guideline. It remains a single centre observation and, given the lack of clarity about preceding idiopathic intracranial hypertension and lack of conservative weight loss control, further studies are needed.

#### Q4. When and where should patients with SIH be referred?

Guideline statements	Consensus level	GRADE
Patients with suspected SIH should be referred to their local neurologist.	100%	EO
If the patient is able to care for themselves, the urgency of the referral should be 2-4 weeks, depending on the severity of clinical features including mental health impact.	96%	EO
If the patient is not able to care for themselves but has help, the urgency should be within 48 hours; and if they are not able to care for themselves and does not have help there should be an emergency admission.	100%	EO
If the local neurologist does not have access to a practitioner skilled in performing EBPs they should be referred urgently to a regional centre with this expertise.	100%	EO
Patients should have early referral to a specialist centre if: <ul style="list-style-type: none"> <li>• the diagnosis is in doubt,</li> <li>• first-line treatments fail, or</li> <li>• there is a rapid clinical deterioration or serious complications including subdural haematoma with mass effect (urgent referral to a tertiary neuroscience centre).</li> </ul>	100%	EO
For reasons other than rapid clinical deterioration, the time to assessment in a specialist neuroscience centre with expertise in SIH management should be within one month.	75%	EO
A specialist neuroscience centre should have the following		



services:		
<ul style="list-style-type: none"> <li>• Neuroradiological investigations and expertise including CT myelography and/or digital subtraction myelography.</li> </ul>	100%	EO
<ul style="list-style-type: none"> <li>• Specialist clinical opinion, familiar and skilled in diagnosis and treatment of SIH.</li> </ul>	100%	EO
<ul style="list-style-type: none"> <li>• Practitioners skilled in epidural blood patching.</li> </ul>	100%	EO
<ul style="list-style-type: none"> <li>• Multi-disciplinary team (MDT) meeting where SIH patients are discussed.</li> </ul>	95%	EO
<ul style="list-style-type: none"> <li>• Expertise in performing targeted patching.</li> </ul>	100%	EO
<ul style="list-style-type: none"> <li>• Local guidelines for the use of fibrin sealant.</li> </ul>	80%	EO
<ul style="list-style-type: none"> <li>• Surgical expertise to repair a spinal CSF leak.</li> </ul>	95%	EO

The recommendation to refer to a local neurologist is based on face validity and consensus opinion. Neurologists should be equipped to make a diagnosis of SIH, initiate investigations and direct the management pathway. There is a need for updated resources and ongoing education to ensure best practice. Initial diagnosis and treatment with non-targeted EBP should be possible to implement in most local hospitals, and should not be delayed by referral to specialist centre for all patients with suspected SIH. Delay in treatment will increase patient suffering, and potentially worsen prognosis as there is some evidence that time to treatment is the best predictor of response (22). Some patients may improve with conservative measures before being seen and their appointments can then be modified.

A neurosciences centre needs the appropriate diagnostic imaging modalities and neuroradiological skills as well as clinical diagnostic skills to confirm the diagnosis. A skilled clinician is required to perform large volume EBPs. An MDT meeting provides a forum for resolving difficult diagnostic and therapeutic dilemmas. Skilled surgical intervention, targeted blood or fibrin sealant patching will be required in the minority of patients who do not respond to non-targeted EBPs.

#### *Uncertainty*

A recent systematic review identifies the investigations and treatments necessary for the management of SIH (1). There are no randomised studies of the outcomes of hyperacute, early or late intervention for SIH, and there is limited evidence to base the assertion that delayed treatment will worsen the prognosis, in fact Wu et al. found no association between outcome from EBP and delay in diagnosis (23). However, the potential of delay allowing the

development of a chronic daily headache pattern and deconditioning related to prolonged bed rest is recognised (24).

**Q5. What first line investigation(s) should be performed in patients with suspected SIH?**

<b>Guideline statements</b>	<b>Consensus level</b>	<b>GRADE</b>
Ideally MRI brain with intravenous contrast and MRI whole spine should be performed as first line investigations.	94.7%	1B
If not possible to achieve both at the same time, MRI brain with contrast should be performed as the first line investigation.	94.7%	1B
MRI of the brain with contrast is essential to look for imaging signs that confirm the diagnosis of SIH.	100%	1B
MRI of the whole spine is not always necessary for the diagnosis and is unlikely to locate the site of the CSF leak, but it can be helpful to identify the presence of findings that may direct subsequent invasive myelography.	95.5%	1B
If MRI is unavailable or if it is contraindicated, computed tomography (CT) of the brain may show some of the findings supportive of the diagnosis.	90.1%	1C
Lumbar puncture should not routinely be performed for the sole purpose of confirming the diagnosis of SIH.	100%	1C
If lumbar puncture is being performed for other reasons, such as to exclude other diagnoses, an opening pressure should be taken at the time.	85.7%	1B
Recommended MRI brain protocol: <ul style="list-style-type: none"> <li>• T2-weighted (any plane) at 4mm-5mm thickness or isotropic volume.</li> <li>• FLAIR (axial or coronal) at 4mm-5mm thickness or isotropic volume.</li> <li>• T2*-weighted gradient echo or Susceptibility Weighted (SWI) imaging (axial) at 2-5 mm thickness.</li> <li>• Pre- and post-contrast 3D isotropic volumetric T1-</li> </ul>	100%	1B

<p>weighted acquisitions OR T1-weighted spin echo at 4-5 mm thickness in the sagittal and one other plane.</p> <p>Recommended MRI spine protocol:</p> <ul style="list-style-type: none"> <li>• T2-weighted (sagittal) at 3-4 mm thickness in 3-parts.</li> <li>• T2-weighted (axial) at 3-4 mm thickness of select segments of the spine.</li> <li>• High-resolution steady-state or equivalent heavily T2-weighted 3D sequence (e.g., CISS/FIESTA/bFFE/Cube/SPACE) at a minimum isotropic resolution of 1 mm in 3 parts to cover the whole spine.</li> <li>• Fat-suppressed T2-weighted sequence such as STIR or other similar alternative.</li> </ul>	100%	1B
---	------	----

Contrast-enhanced MRI of the brain is the most sensitive imaging investigation for the radiological signs of SIH, which include diffuse smooth dural thickening, subdural fluid collections, distension of the dural venous sinuses, enlargement of the pituitary, and sagging of the brainstem (see Figure 2) (25-27). Depending on the duration of the condition some or all of these findings may variably be present, and if the MRI scan is performed very early after symptom onset it may be appropriate to repeat it a few weeks later (27, 28). For the purposes of this guideline, we have defined a positive MRI brain as having at least one sign of SIH, and a negative MRI brain as having no signs of SIH. MRI may also show complications of SIH such as subdural haematoma, cerebral venous sinus thrombosis, and infratentorial superficial siderosis (see Question 17). Approximately 20% of patients with a subsequently confirmed spinal CSF leak have a normal brain MRI, therefore the diagnosis should not be discounted on this basis (1).

MRI of the spine may show findings that support a diagnosis of SIH, including dural thickening and enhancement, and distension of epidural veins but its primary utility is in determining the presence or absence of a spinal epidural collection, either focal or longitudinally extensive, which can aid in the selection of future myelographic technique, if needed (see Question 10) (29). Knowledge of the presence or absence of a SLEC also informs the future risk of superficial siderosis and therefore if MRI spine is not performed as a first line investigation it should be performed at a later date when possible. MRI can also demonstrate spinal meningeal diverticula (which although a relatively common incidental finding are also associated with CSF-venous fistulas) spinal cord herniation, or potentially significant disc herniation or osteophytes.

Some patients may undergo CT because MRI is contraindicated or as part of an initial assessment in the emergency department. CT is less sensitive than MRI for the detection of features of SIH but may show subdural fluid collections and with sagittal reformatting can demonstrate pituitary enlargement and brain sagging (30).

Opening pressure from a lumbar puncture is not a reliable way of diagnosing SIH (25, 31). If the opening pressure is <6cm of H<sub>2</sub>O, this is diagnostic of SIH, however a normal or raised pressure does not exclude the diagnosis.

#### *Uncertainty*

The sensitivity of heavily T2-weighted 3D steady state with free precession sequences for directly demonstrating dural defects is not known.

### **Q6. How should patients in whom there is a high clinical suspicion of SIH with normal brain and spine MRI be managed?**

<b>Guideline statements</b>	<b>Consensus level</b>	<b>GRADE</b>
Ensure imaging has been reviewed by a neuroradiologist and differential diagnoses have been considered.	100%	EO
The presence of normal brain and spine MRI does not rule out SIH but is a recognised rare finding in patients with subsequently confirmed SIH. If a high clinical suspicion remains after consideration of the differential diagnosis and the imaging is confirmed as normal, then the patient should be referred to a specialist centre for MDT discussion and further management.	100%	EO
Although there is limited evidence regarding the efficacy of performing empirical EBP in this context, up to two high volume non-targeted lumbar EBPs could be considered.	100%	2C

Clinical experience has demonstrated that MRI signs of low pressure may be unrecognised by general radiologists, therefore neuroradiology assessment is important to determine whether the imaging is truly negative.

Normal brain and spine imaging is known to occur in patients with subsequently confirmed SIH, and some brain signs may not be present if imaging is done soon after symptom onset

(28). In an observational study of patients with orthostatic headaches and normal MRI imaging in a specialist SIH centre, CSF venous fistula (CVF) was found in 10% of cases, all of whom had temporarily or partially responded to EBP and had spinal meningeal diverticula (32). However, another study found no cases of CSF leak on lateral decubitus digital subtraction myelography in nine patients with normal MRI (33) Few studies have reported outcomes of EBPs specifically for MRI negative patients, therefore the recommendation to consider up to two EBPs has been extrapolated from evidence in MRI positive patients (1, 34, 35).

*Uncertainty:*

There is a lack of high-quality evidence to guide management of patients with a high clinical suspicion of SIH with normal brain and spine MRI, hence why it is currently recommended for individual patient decisions to be made following MDT discussion in a specialist centre.

**Q7. When should myelography be used in the investigation of SIH?**

<b>Guideline statements</b>	<b>Consensus level</b>	<b>GRADE</b>
The purpose of myelography in SIH is to locate the site of a spinal CSF leak in order to plan targeted treatment.	95.8%	EO
It should be considered in any of the following scenarios:		
<ul style="list-style-type: none"> <li>• Patients who have brain or spine MRI findings of SIH and have derived no benefit or only temporary benefit from one or more non-targeted EBPs.</li> </ul>	100%	2C
<ul style="list-style-type: none"> <li>• Patients who have normal brain and spine MRI, with meningeal diverticula, in whom the clinical suspicion is high and who have derived no benefit or only temporary benefit from two non-targeted EBPs.</li> </ul>	100%	2C
<ul style="list-style-type: none"> <li>• Patients who have normal brain and spine MRI, without meningeal diverticula, in whom the clinical suspicion is high and in whom myelography has been recommended after MDT discussion.</li> </ul>	100%	EO
<ul style="list-style-type: none"> <li>• If a patient is already under the care of a specialist MDT</li> </ul>	95.2%	EO

where myelography is available, and has not yet had a non-targeted EBP, the MDT may decide, based on individual patient factors to proceed directly to myelography.		
---	--	--

High volume non-targeted EBP can cause remission of symptoms in over half of patients with SIH, without needing to localise the site of the leak (36, 37). In patients in whom EBP does not produce any sustained benefit, myelography is recommended in order to localise and characterise the type of spinal CSF leak and thereby plan targeted treatment.

Patients who have MRI evidence supporting the diagnosis of SIH are likely to have a spinal CSF leak and myelography is therefore recommended whether EBP is completely ineffective, or temporarily or partially effective at relieving symptoms.

Patients who have normal brain MRI and whose spine MRI does not show epidural fluid are unlikely to have a dural tear and, if they do have SIH, are most likely to have a CSF-venous fistula (CVF) as the cause. As CVFs are often associated with spinal meningeal diverticula, myelography should be considered in this group if meningeal diverticula are present on MRI, whether EBP is completely ineffective, temporarily, or partially relieves symptoms (32).

If brain and spine MRI are normal, with no spinal meningeal diverticula, the yield of myelography is likely to be extremely low but it may be recommended after discussion at a MDT meeting (32).

In some situations, in a specialist centre where myelography is easily available, the MDT may decide that non-targeted EBP is unlikely to be successful and myelography could be performed first. However, given the published response rates to EBP and that EBP is more widely available, bypassing EBP is not recommended as the main patient pathway.

*Uncertainty:*

The optimum number of non-targeted EBPs that should be tried before proceeding to myelography is not known.

**Q8. What myelographic strategies should be used in the investigation of SIH?**

Guideline statements	Consensus level	GRADE

Myelography for spinal CSF leaks should be undertaken by a neuroradiologist with appropriate expertise and working as part of a multidisciplinary team.	100%	EO
The choice of myelographic technique (see Table 4) depends on a number of factors, including:		
<ul style="list-style-type: none"> <li>• whether a spinal longitudinal epidural collection (SLEC) is present or not.</li> </ul>	95.7%	1C
<ul style="list-style-type: none"> <li>• the suspected underlying cause of the leak.</li> </ul>	100%	1C
In patients with high clinical suspicion but normal brain and spine MRI, a CSF-venous fistula is the most likely cause of SIH. The likelihood of finding a leak in such patients is low, but decubitus CT myelography (CTM) or lateral decubitus digital subtraction myelography (DSM) are the recommended options.	90%	1C
Intrathecal gadolinium MR myelography lacks the temporal resolution of CTM and DSM and is not recommended as a first line or second line technique.	100%	1C
Intrathecal gadolinium MR myelography may sometimes be useful in cases of a suspected slowly leaking meningeal diverticulum when CTM or DSM has been negative.	95%	2C
The use of intrathecal gadolinium is off-label and informed consent should be sought from patients for this.	100%	EO
Radionuclide cisternography has poor spatial and temporal resolution and is not recommended as a tool for localising leaks.	100%	EO
Radionuclide cisternography may rarely have a role in confirming the presence of a CSF leak in patients with normal brain and spine MRI in whom there is a high clinical suspicion of SIH but the above methods have all been negative.	90%	2C

**Table 4. Selection of myelographic technique based on spinal MRI findings**

SLEC	Likely cause of leak	Patient position	Technique
------	----------------------	------------------	-----------

Present	Discogenic microspur Lateral or dorsal dural tear	Depends on distribution of SLEC	CTM, DSM, UFCTM
Absent	CSF-venous fistula	Lateral decubitus	CTM, DSM

CSF, cerebrospinal fluid; CTM, CT myelography; DSM, digital subtraction myelography; SLEC, spinal longitudinal epidural collection; UFDCTM, ultrafast CT myelography

The presence of a SLEC implies rapid or high-flow leakage of CSF and demonstration of the leak site requires techniques with high spatial and temporal resolution to capture the leakage of contrast from the spinal subarachnoid space into the epidural collection before the collection becomes completely opacified. This is best done with DSM or UFDCTM, where dynamic image acquisition occurs during and immediately after contrast injection (29, 38). The patient is positioned so that the suspected leak site is dependent, to promote gravitational flow of contrast through the dural defect.

When there is no SLEC, a CVF or leaking meningeal diverticulum are the most likely causes, both of which are best detected using DSM or CTM in the lateral decubitus position examining both sides (39-41).

Where diagnosis is uncertain, CSF pressure may be measured at the time of needle insertion, although a normal CSF pressure does not exclude SIH (25, 31).

Renal excretion of contrast, within 1 hour of injection, is an indirect finding of a spinal CSF leak that occurs in 12-14% cases, more frequently in the presence of a CVF than a dural tear and when present should prompt further scrutiny of an apparently negative CTM to look for subtle signs of a CVF (42, 43).

MR myelography after the intrathecal injection of gadolinium-based contrast agent (GBCA) has limited sensitivity but can localise CVFs and distal nerve root sleeve tears in some instances (44). It has low diagnostic yield and the off-licence use of GBCA make it a third line investigation that should only be employed if DSM and CTM are negative. If intrathecal gadolinium MR myelography is undertaken, the injected dose should not exceed 0.5 mmol, to avoid the risk of neurotoxicity or adverse reactions.

Radionuclide cisternography (RNC) has been superseded by DSM and CTM, which have far superior spatial and temporal resolution needed to accurately localise CSF leaks. In some



centres RNC retains a role as a problem-solving tool in patients with otherwise normal imaging when the diagnosis of a CSF leak is in question, but its use is generally not recommended (45).

#### *Uncertainty*

No studies directly compare the diagnostic accuracy of DSM and CTM against each other and it is unknown if one modality is better than the other for identifying each of the different types of spinal CSF leak.

### **Q9. What is the role of intracranial pressure monitoring in the diagnosis of SIH?**

<b>Guideline statements</b>	<b>Consensus level</b>	<b>GRADE</b>
It is unclear whether intraparenchymal intracranial pressure (ICP) monitoring has a role in SIH and it is not recommended as part of the standard clinical pathway.	100%	2D

ICP monitoring is an invasive investigation with a small but definite risk of complications. The published evidence about the value of intraparenchymal ICP monitoring in patients with SIH patients is limited to case reports (46, 47), and therefore it is difficult to recommend this intervention.

Most of the published evidence on ICP monitoring addresses high intracranial pressure conditions, hence there is possible benefit in patients where all other investigations are negative, and the possibility of high-pressure syndrome is raised. Discovering paradoxically raised ICP might alter management in patients where there is suspicion of the presence of rebound high pressure versus persistent low intracranial pressure.

Data for normal ICP is limited, and the definition of low ICP is subjective, therefore ICP monitoring should therefore only be performed in specialist centres with appropriate clinical experience to interpret the results.

#### *Uncertainty:*

Normal ICP physiology is not fully understood, particularly changes with posture, and there is no well-established cut-off for low ICP on intraparenchymal ICP monitoring (48).

**Q10. What are the conservative and pharmacological management strategies that should be considered and for how long?**

<b>Guideline statements</b>	<b>Consensus level</b>	<b>GRADE</b>
Conservative management should be discussed with all patients with suspected SIH and implemented for up to two weeks from symptom onset, while offering non-targeted EBP as soon as possible, if symptoms do not resolve with conservative management alone.	92.3%	1C
Conservative measures recommended should include		
• bed rest	100%	1C
• hydration (2.0-2.5 litres daily)	94.4%	1C
Other strategies which may be recommended are:		
• avoidance of Valsalva manoeuvres	89.5%	2C
• use of abdominal binders	79.0%	2C
Measures to reduce the risk of deconditioning and risk of deep vein thrombosis should be advocated during the period of bed rest.	100%	EO
Though evidence for use of medication is sparse these treatments could be considered but should not delay investigations or definitive treatment.	100%	2C
These pharmacological options may include:		
• oral caffeine	100%	2C
• intravenous caffeine	73.8%	2C

It is a common practice to implement conservative management upon suspicion or diagnosis of SIH, not least because this relieves the patient's symptoms. A recent meta-analysis, of 17 open label studies and case series encompassing 748 patients, estimated that only 28% of patients had resolution of symptoms with conservative management alone (1).

There are limited data available on the speed of improvement, but clinical experience and expert opinion usually suggests that if a response to conservative management is to occur it is likely to do so in the first few weeks after symptom onset. Expert opinion usually suggests a short trial of conservative management for no more than a few days to few weeks, due to the high level of disability from SIH (7). In acutely unwell patients it may be more appropriate to proceed directly to performing EBP.

Both oral and intravenous caffeine appear to be effective in improving symptoms of post-dural puncture headache (PDPH) in small randomised controlled studies (49). There is no direct evidence for the use of caffeine in SIH, but it is sometimes recommended to patients on the basis of its efficacy in PDPH. Intravenous caffeine is not available in many hospitals, and the low level of evidence in SIH does not mandate its widespread provision. Use of intravenous caffeine should only be considered in specialist centres with experience and governance arrangements for its use.

#### *Uncertainty*

There are no clinical trials specifically assessing the efficacy of conservative management in SIH or comparison to early treatment with EBP. There are no trials of oral or intravenous caffeine in SIH.

### **Q11. When should non-targeted epidural blood patches (EBP) be performed in the management of SIH?**

<b>Guideline statements</b>	<b>Consensus level</b>	<b>GRADE</b>
A non-targeted EBP should be offered in all patients with a clinical and/or imaging diagnosis of SIH, after no more than two weeks of conservative management.	100%	1B
If there is no response or a transient response to the first EBP, a second EBP could be considered before proceeding to myelography.	88.5%	1B
The recommended time interval between EBPs (or following symptom recurrence in those with a transient response) should be 2-4 weeks.	77.8%	2C

Although its mechanism of action is debated, non-targeted EBP is usually considered the preferred first-line treatment of SIH. This is based on more than 30 case series, with a recent meta-analysis estimating that 64% of patients successfully responded to the first EBP (1).

It is common practice to trial a second EBP in patients with no response or a transient response to their first EBP, and several observational studies have published a response rate to second EBP, which ranges from 20-78% (37, 50-52).

The interval of 2-4 weeks between EBPs was agreed by consensus, balancing the potential benefits of early repeat EBP (reducing CSF flow across a dural breach to promote closure) against the theoretically increased risk of cord or cauda equina compression if any of the first blood patch remained, as well as allowing time to assess response to the first procedure.

As specified in Question 7, if a patient is already under the care of a specialist centre where myelography is easily available, rarely a patient will proceed to having myelography and targeted treatment without first having a non-targeted EBP.

*Uncertainty:*

The absence of sham-controlled randomised controlled trials means that a placebo effect explaining the positive effect of EBPs in SIH cannot be excluded. A recent study has shown that many patients with symptomatic improvement after non-targeted EBP did not have radiological resolution of the leak (53). The efficacy of a third EBP cannot be reliably estimated based on the limited published studies to date, therefore it is uncertain whether a trial of a third EBP outweighs the benefits of proceeding to locating the site of leak using myelography. There is currently no evidence for the optimal interval between EBPs, this may be revised as further evidence emerges.

**Q12. How should non-targeted EBPs be performed?**

<b>Guideline statements</b>	<b>Consensus level</b>	<b>GRADE</b>
Non-targeted EBPs should be performed by an experienced practitioner; under local anaesthetic; with the option of using conscious sedation; and with the option of using fluoroscopic or CT-guidance to access the epidural compartment.	100%	EO
The practitioner should consider adjunctive pre- and/or peri-	100%	EO

procedural analgesia.		
As much blood as possible should be administered up to 40ml, ideally at a minimum total volume of 20ml.	83.3%	1C
The administration of autologous blood should cease when the patient experiences back pain/pressure, headaches or radicular symptoms that they can no longer tolerate.	100%	1C
Chlorhexidine skin-preparation above 0.5% concentration should not be used.	100%	EO

Wherever possible the procedure should be performed under local anaesthesia. It is helpful if patients are awake and can indicate if they are experiencing symptoms of neural compression. Conscious sedation can be used if the patient does not tolerate the procedure without this or if the patient has a preference. If it is used, patient monitoring is required as recommended by Association of Anaesthetists' guidelines (54). General anaesthesia is rarely required, for instance in a patient with severe needle phobia, and would usually be discouraged because of the inability to monitor for signs of neural compression.

A full discussion of the rationale for epidural blood patching including potential risks and complications must be held and the patient's informed consent must be documented. The referring team should be involved in this discussion. Common adverse effects of EBP include headache, back pain, radicular irritation, and post-treatment rebound headache. Rare adverse events include infection, accidental dural puncture causing a further CSF leak, subdural haematoma, cauda equina syndrome, spinal cord compression, neuropathic radicular symptoms, and arachnoiditis.

Opinion varies on the need for radiographic guidance. Some consider that radiographic guidance enhances the chance of success in locating the epidural space and others try to avoid further exposure to radiation. CT or fluoroscopic guidance may also be used to ascertain spread of blood using a small volume of contrast mixed with the blood. Practicalities can influence local decision-making in organisations where access to equipment is limited.

The obstetric anaesthetic literature suggests that less than 15ml blood is insufficient to treat PDPH but volumes greater than 20ml may cause more side effects (55). As the site of the dural leak is unknown in SIH, the aim is to inject sufficient volume of blood to spread throughout the entire epidural space. We therefore recommend administration of the

maximum volume up to 40ml that can be tolerated by the patient before paraesthesia or pressure-mediated headache, or neck ache occurs. Studies suggest that the volume of blood injected is the most significant procedural determinant of EBP success in SIH, with 20ml or 22.5ml being the statistically significant cut off for a higher efficacy, the total volume either given at a single (lumbar) level, or divided between two levels (lumbar and thoracic) (23, 36). It is known that blood injected in the lumbar region spreads in the cephalad direction and can therefore successfully treat spinal CSF leaks even if they are in the cervical region (56).

For skin disinfection 2% chlorhexidine should not be used, as any increased efficacy in decontamination is offset by a small risk of neurotoxicity or arachnoiditis in case of accidental dural puncture (57).

Outside a specialist neurosurgical centre, an obstetric anaesthetist is likely to have the skills to perform a non-targeted epidural blood patch. However, it is important to establish a service agreement and business case for this extra work such that the anaesthetic service has the capacity to provide this occasional service in a timely manner, there is agreement as to where the procedure is done and under whom the patient is admitted.

*Uncertainty:*

It is unclear whether there is a correlation between additional volumes of instilled blood beyond 22.5ml and successful outcomes, or whether the combination of blood and fibrin is superior or non-inferior to blood alone.

**Q13. What aftercare is recommended following epidural blood or fibrin sealant patching?**

<b>Guideline statements</b>	<b>Consensus level</b>	<b>GRADE</b>
Following targeted or non-targeted EBP or fibrin sealant patch, patients should be monitored in a recovery area and undergo basic physiological observations (heart rate, blood pressure, and pulse oximetry) as well as spinal observations.	94.1%	EO
A period of 2-24 hours bedrest and observation is recommended as an inpatient.	76.5%	EO
Following non-targeted blood patches patients should be either	100%	2C

in the supine or Trendelenburg position.		
Following targeted patches patients should be in the supine position with head elevated as comfortable.	100%	EO
Thromboprophylaxis should be considered during immobilisation following EBP, according to local institution VTE policy.	95.8%	EO
The patient should have a clinical review prior to discharge.	100%	EO
Patients should not drive themselves home.	100%	EO
Patients should be advised to seek urgent medical attention should they develop any of the following: new onset severe back or leg pain, lower limb motor weakness or sensory disturbance, urinary or faecal incontinence, urinary retention, perineal sensory disturbance, nausea and vomiting, or fever.	83.3%	EO
Advice regarding the possible symptoms of post-treatment rebound headache should be provided, including a change in the nature and site of headache.	100%	EO
Patients should be advised to lie flat as much as possible for 1-3 days post-procedure.	100%	EO
Patients should be advised to minimise the following for 4-6 weeks: bending, straining, stretching, twisting, closed-mouth coughing, sneezing, heavy lifting, strenuous exercise, and constipation.	76.5%	EO
If not admitted overnight, patients should be contacted the following day to exclude the presence of concerning features.	83.3%	EO

There is little evidence for optimal post-patching aftercare in SIH. Some authors advocate the Trendelenburg position to encourage cranial spread of blood following a lumbar EBPs, whereas others consider the recumbent position appropriate (52, 58). We formulated this guidance utilising previous guidance for EBP for PDPH (59), alongside case reports and case series for EBP for SIH, before discussion and agreement from the special interest group. The

identification and management of post-treatment rebound headache is covered in Question 19.

*Uncertainty:*

To date, there are no comparative studies and there is insufficient evidence to recommend one strategy over another.

**Q14. When and how should targeted patches be performed?**

<b>Guideline statements</b>	<b>Consensus level</b>	<b>GRADE</b>
Targeted patches should be performed in patients who remain symptomatic following appropriate conservative management and/or non-targeted EBPs, in whom a causative lesion has been identified on DSM or CTM which is safely accessible via an image guided transcutaneous approach.	100%	1B
The risks and benefits of image guided patching should be discussed with the patient. Discussion may include risks/benefits of surgical management where appropriate.	100%	EO
Targeted patching should be performed by a consultant radiologist with appropriate training and experience in image-guided spinal interventional techniques, in a neurosciences centre with local guidelines for the use of percutaneous fibrin sealant patching (off label use/new procedure). This will usually be the neuroradiologist who has performed the myelography that demonstrated the spinal CSF leak / CVF.	100%	EO
Exact technique will vary according to specific requirements of the leak type/site.	100%	1C

Targeted patching once a leak site has been identified using myelography allows smaller volume to be applied directly to the leak site, reducing the flow through the leak or fistula while reducing the risk of a neural compressive effect from a larger volume. Autologous blood is used in non-targeted EBP, and fibrin sealant is used in open spinal procedures for the management of iatrogenic dural injury and CSF leak. Targeted patching with autologous



blood, fibrin sealant, or a combination of both, is supported by several open label observational studies (60-62).

*Uncertainty:*

The absence of sham-controlled randomised controlled trials means that (although unlikely) a placebo effect explaining the positive effect of targeted patches in SIH cannot be excluded.

**Q15. When and how should surgical management of a CSF leak be considered?**

<b>Guideline statements</b>	<b>Consensus level</b>	<b>GRADE</b>
Surgical management of SIH should be considered in patients who remain symptomatic following appropriate conservative management and/or non-targeted EBPs, in whom a causative lesion has been identified on DSM or CTM.	87.5%	1C
The decision to offer surgery should consider the response to previous treatments, severity of symptoms, site and type of the leak or CVF, feasibility and risk of surgery, and patient preference.	100%	EO
The decision to undertake surgery (versus targeted patching) should be made after discussion involving the neurosurgeon, neurologist, neuroradiologist and patient.	100%	EO
Surgery should be performed by a neurosurgeon with expertise in managing spinal CSF leaks.	100%	EO
Exact technique will vary according to specific requirements of the leak type/site.	100%	1C
If a CVF is shown on myelography, then endovascular treatment may also be considered as a first line treatment (along with targeted patching and surgery).	95.2%	2C

Surgery is an effective treatment for refractory SIH once the leak has been localised. In a published case series of 69 patients, complete resolution of symptoms was experienced by 52% after surgical treatment (22).

The decision to proceed with surgery should be made on a case-by-case basis. The risk associated with non-targeted EBPs and targeted sealant patches is relatively low and accepted management would be to start with procedures of low risk, prior to proceeding to surgery.

Surgery for SIH is low volume surgery, and therefore should be performed by surgeons with experience in this condition, and with suitable technical ability to access the spine from all directions to allow the most effective and least risky surgical approach for CSF leak repair (including anterior or lateral approaches to the spine) (63, 64). Careful intraoperative localisation of the spinal level is critical and this can be aided by radiological marking pre-operatively using CT. As a significant proportion of leaks will be ventral or from a nerve root sleeve, spinal stability must also be considered on an individual basis and this may require spinal instrumentation.

For CVFs, an emerging less invasive treatment is endovascular embolisation of the paraspinal vein draining the CVF (65).

*Uncertainty:*

The heterogeneity of the surgical population limits standardised guidelines on timing or technique for surgical repair.

There are no studies comparing outcomes of targeted patching, surgery and/or transvenous embolisation.

**Q16. How should patients with imaging signs of SIH, but who are asymptomatic, be managed?**

<b>Guideline statements</b>	<b>Consensus level</b>	<b>GRADE</b>
Asymptomatic patients with radiological evidence of SIH should be referred to a specialist neuroscience centre and discussed in a MDT.	100%	EO
There is emerging evidence of potential significant long-term sequelae (particularly superficial siderosis) from persistent ventral spinal CSF leaks. This information should be discussed with asymptomatic patients.	100%	2C
Clinicians should discuss with patients and offer to investigate	100%	2C

and treat asymptomatic spinal CSF leak with SLEC, in light of the potential long-term risks, particularly of superficial siderosis.		
Patients who opt for a conservative approach should be offered a clinical review and repeat neuroimaging (MRI brain including SWI or GRE sequence and MRI spine) every 1-2 years.	100%	2C

The evidence for management of asymptomatic patients is limited to case reports and a small case series (66). Therefore discussion amongst a MDT is recommended. Risks of persistent untreated ventral CSF leak are recognised. In a recent study of 55 patients, six patients developed superficial siderosis, and two developed bibrachial amyotrophy, with the rate of these serious complications increasing over time, all occurring after at least four years and the rate reaching 57.9% (95% CI 30.2%-87.6%) after 16 years (67). Superficial siderosis also appears to occur rarely with CVF (68).

*Uncertainty:*

There are no prospective studies following untreated asymptomatic patients with SIH.

**Q17. How should complications of SIH be identified and managed?**

**Subdural haematoma/hygroma**

<b>Guideline statements</b>	<b>Consensus level</b>	<b>GRADE</b>
MRI brain with contrast and whole spine should be performed to investigate the possibility of spinal CSF leak in patients with subdural haematoma/hygromas where there is a high index of suspicion such as supportive history of orthostatic headache, or absence of trauma/coagulopathy/alcohol misuse.	100%	1B
Small or asymptomatic haematomas should be managed conservatively whilst treating the CSF leak.	100%	1B
Symptomatic haematomas with significant mass effect may need burr hole drainage in conjunction with treating the leak.	100%	1B

It can be challenging to differentiate subdural haematoma and hygroma secondary to SIH from conventional subdural haematomas, especially on CT scans which are the most common

initial form of imaging. Several studies have identified factors more commonly associated with subdural haematoma/hygroma secondary to SIH, including history of orthostatic headache, younger age, male gender, absence of trauma/coagulopathy/alcohol misuse, and bilateral collections (1, 16, 69). In cases where there is a high index of suspicion, MRI brain with contrast and whole spine is the most reliable imaging modality.

Numerous retrospective studies agree that small or asymptomatic hematomas can be safely managed conservatively, whilst treating the spinal CSF leak. However neurological deterioration or large subdural hematomas with significant mass effect or uncal herniation may warrant early burr hole drainage in conjunction with treatment of the leak. In these patients, burr hole drainage alone did not lead to improvement or led to deterioration, whereas simultaneous EBP or microsurgical repair of the leak led to sustained improvements (16, 69-71). Drainage of the subdural haematoma without treating the spinal CSF leak will likely lead to recurrence of the subdural haematoma.

*Uncertainty:*

There are few large prospective studies regarding management of the subdural hematoma secondary to SIH.

### Cerebral venous thrombosis

Guideline statements	Consensus level	GRADE
CT or MR venography should be considered in any sudden change in headache pattern or neurological examination in the context of SIH.	100%	2C
EBP should be prioritised as initial treatment of SIH with cerebral venous thrombosis (CVT). Addition of anticoagulation may be considered balancing the risks of bleeding complications on an individual basis.	88.9%	2C

The reported frequency of CVT among patients with SIH is about 2%, which is significantly higher than the 0.0005% rate in the general population (17, 72). The proposed mechanisms for this association include venous stasis caused by venous engorgement, traction on venous structures causing venous distortion resulting in turbulent venous flow, and increased venous

viscosity due to reduced CSF absorption. Although a rare complication of SIH, CVT can lead to significant neurological deterioration or life-threatening conditions including seizures and intracranial haemorrhage.

In the largest literature review available about half of patients who were found to have developed CVT as a complication of SIH reported sudden change in headache pattern or a new neurological sign (72). It therefore seems rational to consider repeat CT or MR venography should these symptoms or signs develop in the context of SIH.

Anticoagulation is the usual treatment of CVT. However, EBP cannot be performed when a patient is anticoagulated. Thus, in patients with SIH, who develop CVT, EBP should ideally be performed prior to anticoagulation, although this may not be possible in all clinical circumstances. Commencing anticoagulation alone with underlying SIH may cause intracranial haemorrhage due to brain sag and does not address the underlying venous factors causing the CVT. There are case reports detailing successful treatment of CVT with anticoagulation alone, but not all comment on the resolution of SIH symptoms. Several of these case reports detail significant intracerebral haemorrhage complications presumably as the underlying SIH pathology has not been addressed. There are several case series where an EBP was performed initially and then anticoagulation commenced. This combination appears to be well tolerated although there are case reports detailing seizures, transient diplopia, and subarachnoid haemorrhage as complications. There are also several cases where EBP alone has been used and the CVT managed conservatively although long term follow-up of the CVT was not detailed (72, 73).

The choice and duration of anticoagulant will depend on individual medical history and circumstances, and haematology advice in complex cases. Given the higher risk profile of anticoagulation in the context of SIH however close monitoring is prudent to avoid over coagulation.

*Uncertainty:*

The combination of SIH and CVT is rare so there are no randomised controlled trials or large case series comparing management strategies. The optimal length of anticoagulant treatment is also not established.

**Superficial siderosis**

Guideline statements	Consensus	GRADE
----------------------	-----------	-------

	level	
Patients with SIH undergoing MR imaging should have MRI brain and spine with blood sensitive sequences which can detect superficial siderosis. A higher index of suspicion is needed in SIH patients who develop ataxia, hearing loss, or myelopathic features.	100%	1B
CSF ferritin levels and xanthochromia may be measured.	91.7%	2C
SIH patients with siderosis should be managed in a specialist centre of expertise for this disorder.	75%	EO
Symptomatic patients with superficial siderosis should be offered non-targeted EBP, or targeted treatment of the CSF leak site if detected on imaging.	100%	1B
Deferiprone may be considered in symptomatic patients where the underlying CSF leak is unable to be found or treated.	100%	2C

There is increasing evidence in recognition of delayed infratentorial superficial siderosis as a complication of SIH. In a study of 55 patients with persistent ventral CSF leak, six patients developed siderosis during the follow up period, all after four years of the onset of SIH. However two thirds were asymptomatic from the siderosis (67). In a recent study of 1589 SIH patients, superficial siderosis was detected in 57 patients (3.6%). The majority of these had ventral CSF leaks, but some had dural ectasia or a CSF venous fistula (68). In a small study of 24 patients with SIH, CSF samples were positive for bilirubin in 2/19 (10.5%), and CSF ferritin was elevated in 7/23 (30.4%) despite imaging signs of siderosis only being present on imaging in four patients (16.7%). Symptom duration was longer in patients with siderosis than those without (74).

It is important to discuss fully with the patient, the potential prognosis in patients with SIH and superficial siderosis, and to agree a treatment or monitoring plan.

The consensus was that based on the paucity of experience in managing superficial siderosis, SIH patients with siderosis should be managed in centres that have the expertise to do so.

There are numerous case series demonstrating the biochemical resolution of siderosis after repair of dural defect or CSF leak repair (75-77).

Treatment response to deferiprone is variable. A recent systematic review reported stability or improvement in 6 studies while 5 showed a mixed response (78). Adverse responses included agranulocytosis and neutropenia (78, 79). Therefore, deferiprone should be considered in symptomatic siderosis patients when a CSF leak has not been found or cannot be treated.

*Uncertainty:*

Further research is needed to establish the role of early treatment versus clinical surveillance in asymptomatic siderosis patients.

**Q18. What is the best approach for headache management in SIH?**

<b>Guideline statements</b>	<b>Consensus level</b>	<b>GRADE</b>
Treatment of headache in SIH should focus primarily on management of the CSF leak, in tandem with best symptomatic management.	100%	1B
Appropriate pain relief should be given as part of best symptom management.	100%	EO
Paracetamol and/or non-steroidal anti-inflammatory drugs (NSAIDs) can be considered.	73.3%	EO
Opioid medication may be required to provide adequate pain relief, but should be avoided in the routine long-term management of headache in SIH.	85.7%	EO
In patients not responding to initial management of SIH, it is important to look for comorbid primary headache and treat as per phenotype, and important to consider and warn patients about the risk of medication overuse headache.	100%	EO
For management of associated primary headache, drugs that potentially lower CSF pressure such as topiramate and indomethacin, and migraine preventives such as candesartan and beta-blockers should be used with caution, as they may exacerbate the postural symptoms of SIH.	78.6%	EO

Given the low chance of successful outcome with conservative treatment alone the primary consideration in headache management in SIH should be prompt investigation for and treatment of an underlying CSF leak. Evidence suggests that patients have better outcomes when definitive treatment is undertaken early in the clinical course (22). Conservative management should therefore not delay definitive treatment.

SIH is a highly disabling condition, and analgesia should be offered as part of headache management. Whilst opioid medication may be required, patients may get adequate pain relief with simple analgesia and opioids should be reserved for patients not responding to simple analgesia.

Clinical experience suggests that many patients with confirmed SIH have other headache disorders, migraine being common, which can pre-date, run concurrently with, or develop after SIH. Migraine prophylaxis is often considered. Whilst often well tolerated, beta blockers and candesartan have the potential to cause postural hypotension and should be used with caution; topiramate may reduce CSF pressure through carbonic anhydrase activity; and indomethacin, used as an analgesic or management of cough headache, may also cause reduction of intracranial pressure (80, 81).

*Uncertainty:*

There are no trials of symptomatic treatment for headache secondary to SIH.

**Q19. How should post-treatment rebound headache be identified and managed?**

<b>Guideline statements</b>	<b>Consensus level</b>	<b>GRADE</b>
Before an EBP, fibrin sealant patch, or surgical repair of spinal CSF leak, patients should be informed about the entity of post-treatment rebound headache.	82.4%	EO
When rebound headache after treatment of SIH occurs, patients need to be evaluated for secondary intracranial hypertension.	100%	EO
If very severe or worsening continues after 1-2 weeks further clinical review may be indicated.	100%	EO
The development of rebound headache after treatment for SIH may indicate post procedural intracranial hypertension which is	100%	EO



self-limiting in most individuals and can often be managed without medical treatment.		
There is anecdotal use of acetazolamide, topiramate and diuretics for rebound intracranial hypertension but these agents are not well tolerated and recommended treatment duration is not well defined in for SIH treatment related rebound headache.	100%	2C

A headache which worsens or changes in phenotype to lose its orthostatic quality has been reported to affect as many as 27% of patients following intervention for SIH(82), some of whom have features of intracranial hypertension such as raised CSF opening pressure on lumbar puncture or papilloedema (83, 84). The term “rebound headache” rather than “rebound intracranial hypertension” has been used in this guideline as objective clinical evidence of intracranial hypertension are not always present.

The average duration of rebound headache is not well reported but clinical consensus and limited case reports suggests that if symptoms and signs suggestive of intracranial hypertension progressively worsen beyond 14 days then clinical reassessment should be considered.

It is recognised that some clinicians may choose to utilise acetazolamide, topiramate, or diuretics for rebound headache, with the rationale originating from their use in idiopathic intracranial hypertension (IIH). It is noted that this practice varies widely and is not evidence-based, as data from IIH treatment trials has identified that acetazolamide does not improve headache symptoms and is poorly tolerated (85, 86).

*Uncertainty:*

Clinical trials are required to compare the use of acetazolamide, topiramate, or diuretics to a ‘watch and wait’ approach.

**Q20. How should neurological symptoms other than headache in patients with SIH be identified and managed?**

<b>Guideline statements</b>	<b>Consensus level</b>	<b>GRADE</b>
Treatment of non-headache symptoms in SIH should focus primarily on management of the CSF leak, in tandem with best	100%	EO

symptomatic management e.g., anti-emetics for nausea and vomiting and encouragement of adequate hydration.		
Symptomatic management and advice on ways of coping with symptoms should be discussed with patients, whilst attempting treatment for CSF leak, but the evidence base for their use is lacking.	100%	EO

It is commonly observed in clinical practice that neurological symptoms other than headache often resolve with effective treatment of a spinal CSF leak, unless they are due to secondary superficial siderosis. Persistence of symptoms requires careful clinical and radiological evaluation to confirm there is no ongoing CSF leak.

*Uncertainty:*

There are no clinical trials or large observational studies that have examined the resolution of non-headache symptoms in SIH.

**Q21. Is there a role for "orthostatic rehabilitation" in the long-term management of orthostatic intolerance in patients with SIH?**

Guideline statements	Consensus level	GRADE
Orthostatic rehabilitation should be considered for patients who have been bedbound, in particular those who have developed symptoms of orthostatic intolerance and patients with pre-existing PoTS and/or hypermobility syndromes.	100%	EO
The rehabilitation programme should address both deconditioning affecting skeletal muscle, and deconditioning affecting autonomic postural responses.	100%	EO

Prolonged periods of bedrest (either as part of conservative advice or prompted by patient symptom self-management) can lead to deconditioning and persistence of orthostatic intolerance causing disability even when intracranial hypotension resolves. Deconditioning leads to orthostatic tachycardia, exercise intolerance, reduced left ventricular mass, reduced stroke volume and reduced blood volume (87). A small study found that patients with SIH

often meet diagnostic criteria for PoTS (15). The recommendations have been extrapolated from those used in PoTS.

Exercise and orthostatic rehabilitation are gold standard treatments in patients with of PoTS. This is based on several observational prospective studies documenting improvement of physical fitness markers, symptoms of orthostatic intolerance, and quality of life (88-90). The rationale is that symptoms of orthostatic intolerance in SIH may respond to similar approach as used in patients with PoTS.

*Uncertainty:*

There is currently no evidence for efficacy of a cardiovascular rehabilitation programme in SIH patients.

**Q22. How should patients be followed up?**

<b>Guideline statements</b>	<b>Consensus level</b>	<b>GRADE</b>
All patients (all types of blood patch, surgery, any person who has had therapeutic intervention) should be followed up clinically and should be given contact details for their responsible clinical team.	100%	EO
We recommend follow up at the following intervals:		EO
<ul style="list-style-type: none"> <li>• Early review for complications (following any intervention): 24-48 hours.</li> </ul>	100%	
<ul style="list-style-type: none"> <li>• Intermediate follow up after EBP: 10-14 days.</li> </ul>	100%	
<ul style="list-style-type: none"> <li>• Intermediate follow up after surgery: 3-6 weeks.</li> </ul>	89.5%	
<ul style="list-style-type: none"> <li>• Late follow up (after any intervention): 3-6 months.</li> </ul>	100%	
We recommend assessing for the following during follow up:		EO
<ul style="list-style-type: none"> <li>• Peak headache severity on 0-10 scale.</li> </ul>	100%	
<ul style="list-style-type: none"> <li>• Time to severe headache onset after becoming upright.</li> </ul>	100%	
<ul style="list-style-type: none"> <li>• Severity of other symptoms e.g., audiovestibular/cognitive.</li> </ul>	94.4%	
<ul style="list-style-type: none"> <li>• Time able to spend upright before needing to lie down.</li> </ul>	94.4%	

<ul style="list-style-type: none"> <li>• Cumulative hours able to spend upright per day.</li> <li>• Headache disability and quality of life outcome scores may be used; however, they are not validated for SIH.</li> </ul>	94.4%	
In cases where there is no clinical improvement, or initial improvement with subsequent relapse following any intervention, it is recommended the patient is referred back to the MDT/specialist for discussion. Further imaging or intervention may be required.	100%	EO
In cases where there is a sustained long-term improvement, no further specialist/MDT involvement may be necessary. Further follow-up imaging to act as a baseline for any further imaging/treatment is at the discretion of the specialist who performed the procedure.	100%	EO
Repeat invasive imaging techniques should not be performed for the purpose of determining a baseline in patients who are asymptomatic or significantly improved.	100%	EO

The rationale for follow-up is based on the timings of immediate complications (24-48 hours), the time frame at which further EBP would be attempted, and assessment of long-term improvement in cases where no immediate repeat treatment was indicated (3-6 months).

There is no single accepted best way of assessing clinical improvement, those listed are suggested by clinicians with experience in assessing patients with SIH.

In all circumstances, patients who relapse or show no improvement following treatment, should be referred back to the specialist or MDT. Those who show continued improvement need not be referred back unless there is evidence of recurrence/persistence of epidural collection on any follow-up imaging.

*Uncertainty:*

These recommendations do not have an evidence base, but are based on practicality and current practice amongst clinicians who regularly manage patients with SIH.

## References

1. D'Antona L, Jaime Merchan MA, Vassiliou A, Watkins LD, Davagnanam I, Toma AK, et al. Clinical Presentation, Investigation Findings, and Treatment Outcomes of Spontaneous Intracranial Hypotension Syndrome: A Systematic Review and Meta-analysis. *JAMA Neurol.* 2021;78(3):329-37.
2. Leep Hunderfund AN, Mokri B. Second-half-of-the-day headache as a manifestation of spontaneous CSF leak. *J Neurol.* 2012;259(2):306-10.
3. Schievink WI, Wijdicks EF, Meyer FB, Sonntag VK. Spontaneous intracranial hypotension mimicking aneurysmal subarachnoid hemorrhage. *Neurosurgery.* 2001;48(3):513-6; discussion 6-7.
4. Mokri B. Spontaneous Intracranial Hypotension. *Continuum (Minneapolis, Minn).* 2015;21(4 Headache):1086-108.
5. Schievink WI. Misdiagnosis of spontaneous intracranial hypotension. *Arch Neurol.* 2003;60(12):1713-8.
6. Capizzano AA, Lai L, Kim J, Rizzo M, Gray L, Smoot MK, et al. Atypical Presentations of Intracranial Hypotension: Comparison with Classic Spontaneous Intracranial Hypotension. *AJNR Am J Neuroradiol.* 2016;37(7):1256-61.
7. Schievink WI. Spontaneous Intracranial Hypotension. *N Engl J Med.* 2021;385(23):2173-8.
8. Chung SJ, Kim JS, Lee MC. Syndrome of cerebral spinal fluid hypovolemia: clinical and imaging features and outcome. *Neurology.* 2000;55(9):1321-7.
9. Mea E, Chiapparini L, Savoiaro M, Franzini A, Grimaldi D, Bussone G, et al. Application of IHS criteria to headache attributed to spontaneous intracranial hypotension in a large population. *Cephalalgia.* 2009;29(4):418-22.
10. Headache Classification Committee of the International Headache Society. The International Classification of Headache Disorders, 3rd edition. *Cephalalgia.* 2018;38(1):1-211.
11. Headache Classification Subcommittee of the International Headache Society. The International Classification of Headache Disorders: 2nd edition. *Cephalalgia.* 2004;24 Suppl 1:9-160.
12. Mathias CJ, Low DA, Iodice V, Bannister R. Investigation of autonomic disorders. *Autonomic Failure A Textbook of Clinical Disorders of the Autonomic Nervous System.* 5th ed. Oxford: Oxford University Press; 2013.
13. D'Amico D, Usai S, Chiapparini L, Erbetta A, Gioppo A, Messina G, et al. Headache in spontaneous intracranial hypotension: an overview with indications for differential diagnosis in the clinical practice. *Neurol Sci.* 2020;41(Suppl 2):423-7.
14. Bond KM, Benson JC, Cutsforth-Gregory JK, Kim DK, Diehn FE, Carr CM. Spontaneous Intracranial Hypotension: Atypical Radiologic Appearances, Imaging Mimickers, and Clinical Look-Alikes. *AJNR Am J Neuroradiol.* 2020;41(8):1339-47.
15. Graf N, Fernandes Santos A, Ulrich CT, Fung C, Raabe A, Beck J, et al. Clinical symptoms and results of autonomic function testing overlap in spontaneous intracranial hypotension and postural tachycardia syndrome: A retrospective study. *Cephalalgia Reports.* 2018.

16. Chen YC, Wang YF, Li JY, Chen SP, Lirng JF, Hseu SS, et al. Treatment and prognosis of subdural hematoma in patients with spontaneous intracranial hypotension. *Cephalalgia*. 2016;36(3):225-31.
17. Schievink WI, Maya MM. Cerebral venous thrombosis in spontaneous intracranial hypotension. *Headache*. 2008;48(10):1511-9.
18. Reinstein E, Pariani M, Bannykh S, Rimoin DL, Schievink WI. Connective tissue spectrum abnormalities associated with spontaneous cerebrospinal fluid leaks: a prospective study. *Eur J Hum Genet*. 2013;21(4):386-90.
19. Beck J, Ulrich CT, Fung C, Fichtner J, Seidel K, Fiechter M, et al. Diskogenic microspurs as a major cause of intractable spontaneous intracranial hypotension. *Neurology*. 2016;87(12):1220-6.
20. Liu FC, Fuh JL, Wang YF, Wang SJ. Connective tissue disorders in patients with spontaneous intracranial hypotension. *Cephalalgia*. 2011;31(6):691-5.
21. Schievink WI, Goseland A, Cunneen S. Bariatric surgery as a possible risk factor for spontaneous intracranial hypotension. *Neurology*. 2014;83(20):1819-22.
22. Häni L, Fung C, Jesse CM, Ulrich CT, Piechowiak EI, Gralla J, et al. Outcome after surgical treatment of cerebrospinal fluid leaks in spontaneous intracranial hypotension—a matter of time. *J Neurol*. 2022;269(3):1439-46.
23. Wu JW, Hseu SS, Fuh JL, Lirng JF, Wang YF, Chen WT, et al. Factors predicting response to the first epidural blood patch in spontaneous intracranial hypotension. *Brain*. 2017;140(2):344-52.
24. Tyagi A. Management of spontaneous intracranial hypotension. *Pract Neurol*. 2016;16(2):87-8.
25. Kranz PG, Tanpitukpongse TP, Choudhury KR, Amrhein TJ, Gray L. Imaging Signs in Spontaneous Intracranial Hypotension: Prevalence and Relationship to CSF Pressure. *AJNR Am J Neuroradiol*. 2016;37(7):1374-8.
26. Dobrocky T, Grunder L, Breiding PS, Branca M, Limacher A, Mosimann PJ, et al. Assessing Spinal Cerebrospinal Fluid Leaks in Spontaneous Intracranial Hypotension With a Scoring System Based on Brain Magnetic Resonance Imaging Findings. *JAMA Neurol*. 2019;76(5):580-7.
27. Kranz PG, Amrhein TJ, Choudhury KR, Tanpitukpongse TP, Gray L. Time-Dependent Changes in Dural Enhancement Associated With Spontaneous Intracranial Hypotension. *AJR Am J Roentgenol*. 2016;207(6):1283-7.
28. Chen ST, Wu JW, Wang YF, Lirng JF, Hseu SS, Wang SJ. The time sequence of brain MRI findings in spontaneous intracranial hypotension. *Cephalalgia*. 2022;42(1):12-9.
29. Farb RI, Nicholson PJ, Peng PW, Massicotte EM, Lay C, Krings T, et al. Spontaneous Intracranial Hypotension: A Systematic Imaging Approach for CSF Leak Localization and Management Based on MRI and Digital Subtraction Myelography. *AJNR Am J Neuroradiol*. 2019;40(4):745-53.
30. Yaffe D, Gordon CR. Noncontrast Brain Computed Tomography Findings of Spontaneous Intracranial Hypotension in the Emergency Department Setting. *J Emerg Med*. 2016;50(4):588-93.
31. Mokri B, Hunter SF, Atkinson JL, Piegras DG. Orthostatic headaches caused by CSF leak but with normal CSF pressures. *Neurology*. 1998;51(3):786-90.

32. Schievink WI, Maya M, Prasad RS, Wadhwa VS, Cruz RB, Moser FG, et al. Spontaneous spinal cerebrospinal fluid-venous fistulas in patients with orthostatic headaches and normal conventional brain and spine imaging. *Headache*. 2021;61(2):387-91.
33. Kim DK, Carr CM, Benson JC, Diehn FE, Lehman VT, Liebo GB, et al. Diagnostic Yield of Lateral Decubitus Digital Subtraction Myelogram Stratified by Brain MRI Findings. *Neurology*. 2021;96(9):e1312-e8.
34. Perthen JE, Dorman PJ, Morland D, Redfern N, Butteriss DJ. Treatment of spontaneous intracranial hypotension: experiences in a UK regional neurosciences Centre. *Clin Med (Lond)*. 2021;21(3):e247-e51.
35. Lee HJ, Lee YH, Park JH, Hong J. Comparison of Efficacy of an Epidural Blood Patch in Patients with Spinal Leakage of Cerebrospinal Fluid. *Pain Physician*. 2021;24(8):571-6.
36. Pagani-Estevez GL, Cutsforth-Gregory JK, Morris JM, Mokri B, Piepgras DG, Mauck WD, et al. Procedural predictors of epidural blood patch efficacy in spontaneous intracranial hypotension. *Reg Anesth Pain Med*. 2019.
37. Martin R, Louy C, Babu V, Jiang Y, Far A, Schievink W. A two-level large-volume epidural blood patch protocol for spontaneous intracranial hypotension: retrospective analysis of risk and benefit. *Reg Anesth Pain Med*. 2019.
38. Thielen KR, Sillery JC, Morris JM, Hoxworth JM, Diehn FE, Wald JT, et al. Ultrafast dynamic computed tomography myelography for the precise identification of high-flow cerebrospinal fluid leaks caused by spiculated spinal osteophytes. *J Neurosurg Spine*. 2015;22(3):324-31.
39. Schievink WI, Maya MM, Moser FG, Prasad RS, Cruz RB, Nuno M, et al. Lateral decubitus digital subtraction myelography to identify spinal CSF-venous fistulas in spontaneous intracranial hypotension. *J Neurosurg Spine*. 2019:1-4.
40. Kranz PG, Gray L, Amrhein TJ. Decubitus CT Myelography for Detecting Subtle CSF Leaks in Spontaneous Intracranial Hypotension. *AJNR Am J Neuroradiol*. 2019;40(4):754-6.
41. Mamlouk MD, Ochi RP, Jun P, Shen PY. Decubitus CT Myelography for CSF-Venous Fistulas: A Procedural Approach. *AJNR Am J Neuroradiol*. 2021;42(1):32-6.
42. Behbahani S, Raseman J, Orłowski H, Sharma A, Eldaya R. Renal Excretion of Contrast on CT Myelography: A Specific Marker of CSF Leak. *AJNR Am J Neuroradiol*. 2020;41(2):351-6.
43. Kinsman KA, Verdoorn JT, Luetmer PH, Clark MS, Diehn FE. Renal Contrast on CT Myelography: Diagnostic Value in Patients with Spontaneous Intracranial Hypotension. *AJNR Am J Neuroradiol*. 2019;40(2):376-81.
44. Madhavan AA, Carr CM, Benson JC, Brinjikji W, Diehn FE, Kim DK, et al. Diagnostic Yield of Intrathecal Gadolinium MR Myelography for CSF Leak Localization. *Clin Neuroradiol*. 2021.
45. Monteith TS, Kralik SF, Dillon WP, Hawkins RA, Goadsby PJ. The utility of radioisotope cisternography in low CSF/volume syndromes compared to myelography. *Cephalalgia*. 2016;36(13):1291-5.

46. Takai K, Taniguchi M. Intracranial Hypotension with Coma: Microsurgical Repair of a Spinal Ventral Dural Tear and Drainage of Subdural Hematoma with Intracranial Pressure Monitoring. *World Neurosurg.* 2018;118:269-73.
47. Fichtner J, Fung C, Z'Graggen W, Raabe A, Beck J. Lack of increase in intracranial pressure after epidural blood patch in spinal cerebrospinal fluid leak. *Neurocrit Care.* 2012;16(3):444-9.
48. Norager NH, Olsen MH, Pedersen SH, Riedel CS, Czosnyka M, Juhler M. Reference values for intracranial pressure and lumbar cerebrospinal fluid pressure: a systematic review. *Fluids Barriers CNS.* 2021;18(1):19.
49. Basurto Ona X, Uriona Tuma SM, Martinez Garcia L, Sola I, Bonfill Cosp X. Drug therapy for preventing post-dural puncture headache. *Cochrane Database Syst Rev.* 2013(2):CD001792.
50. Franzini A, Messina G, Chiapparini L, Bussone G. Treatment of spontaneous intracranial hypotension: evolution of the therapeutic and diagnostic modalities. *Neurol Sci.* 2013;34 Suppl 1:S151-5.
51. Sencakova D, Mokri B, McClelland RL. The efficacy of epidural blood patch in spontaneous CSF leaks. *Neurology.* 2001;57(10):1921-3.
52. Levi V, Di Lorenzo NE, Franzini A, Tramacere I, Erbetta A, Chiapparini L, et al. Lumbar epidural blood patch: effectiveness on orthostatic headache and MRI predictive factors in 101 consecutive patients affected by spontaneous intracranial hypotension. *J Neurosurg.* 2019;132(3):809-17.
53. Piechowiak EI, Aeschmann B, Hani L, Kaesmacher J, Mordasini P, Jesse CM, et al. Epidural Blood Patching in Spontaneous Intracranial Hypotension-Do we Really Seal the Leak? *Clin Neuroradiol.* 2022.
54. Association of Anaesthetists. Recommendations for standards of monitoring during anaesthesia and recovery 2021. 2021.
55. Russell R, Laxton C, Lucas DN, Niewiarowski J, Scrutton M, Stocks G. Treatment of obstetric post-dural puncture headache. Part 2: epidural blood patch. *Int J Obstet Anesth.* 2019;38:104-18.
56. Ferrante E, Arpino I, Citterio A. Is it a rational choice to treat with lumbar epidural blood patch headache caused by spontaneous cervical CSF leak? *Cephalalgia.* 2006;26(10):1245-6.
57. Checketts MR. Wash & go--but with what? Skin antiseptic solutions for central neuraxial block. *Anaesthesia.* 2012;67(8):819-22.
58. Ferrante E, Arpino I, Citterio A, Wetzl R, Savino A. Epidural blood patch in Trendelenburg position pre-medicated with acetazolamide to treat spontaneous intracranial hypotension. *Eur J Neurol.* 2010;17(5):715-9.
59. Obstetric Anaesthetists' Association. Treatment of obstetric post-dural puncture headache. 2018 December 2018.
60. Amrhein TJ, Befera NT, Gray L, Kranz PG. CT Fluoroscopy-Guided Blood Patching of Ventral CSF Leaks by Direct Needle Placement in the Ventral Epidural Space Using a Transforaminal Approach. *AJNR Am J Neuroradiol.* 2016;37(10):1951-6.
61. Cho KI, Moon HS, Jeon HJ, Park K, Kong DS. Spontaneous intracranial hypotension: efficacy of radiologic targeting vs blind blood patch. *Neurology.* 2011;76(13):1139-44.



62. Schievink WI, Maya MM, Moser FM. Treatment of spontaneous intracranial hypotension with percutaneous placement of a fibrin sealant. Report of four cases. *J Neurosurg*. 2004;100(6):1098-100.
63. Royal College of Surgeons. Reconfiguration of surgical services. 2018 September 2018.
64. Society of British Neurological Surgeons. Recommendations for low volume surgery. 2018.
65. Brinjikji W, Garza I, Whealy M, Kisson N, Atkinson JLD, Savastano L, et al. Clinical and imaging outcomes of cerebrospinal fluid-venous fistula embolization. *J Neurointerv Surg*. 2022.
66. Schievink WI, Mamelak AN, Maya MM. Spontaneous intracranial hypotension as an incidental finding on MRI. *Neurology*. 2012;79(12):1298-9.
67. Schievink WI, Maya M, Moser F, Nuno M. Long-term Risks of Persistent Ventral Spinal CSF Leaks in SIH: Superficial Siderosis and Bibrachial Amyotrophy. *Neurology*. 2021;97(19):e1964-e70.
68. Schievink WI, Maya MM, Harris J, Galvan J, Tache RB, Nuno M. Infratentorial Superficial Siderosis and Spontaneous Intracranial Hypotension. *Ann Neurol*. 2022.
69. Kim JH, Roh H, Yoon WK, Kwon TH, Chong K, Hwang SY, et al. Clinical Features of Patients With Spontaneous Intracranial Hypotension Complicated With Bilateral Subdural Fluid Collections. *Headache*. 2019;59(5):775-86.
70. Takai K, Niimura M, Hongo H, Umekawa M, Teranishi A, Kayahara T, et al. Disturbed Consciousness and Coma: Diagnosis and Management of Intracranial Hypotension Caused by a Spinal Cerebrospinal Fluid Leak. *World Neurosurg*. 2019;121:e700-e11.
71. Schievink WI, Maya MM, Moser FG, Tourje J. Spectrum of subdural fluid collections in spontaneous intracranial hypotension. *J Neurosurg*. 2005;103(4):608-13.
72. Ferrante E, Trimboli M, Petrecca G, Allegrini F. Cerebral venous thrombosis in spontaneous intracranial hypotension: A report of 8 cases and review of the literature. *J Neurol Sci*. 2021;425:117467.
73. Zhang D, Wang J, Zhang Q, He F, Hu X. Cerebral Venous Thrombosis in Spontaneous Intracranial Hypotension: A Report on 4 Cases and a Review of the Literature. *Headache*. 2018;58(8):1244-55.
74. Hani L, Fung C, Jesse CM, Schild C, Piechowiak EI, Dobrocky T, et al. Cerebrospinal fluid biomarkers of superficial siderosis in patients with spontaneous intracranial hypotension. *Eur J Neurol*. 2022.
75. Wilson D, Chatterjee F, Farmer SF, Rudge P, McCarron MO, Cowley P, et al. Infratentorial superficial siderosis: Classification, diagnostic criteria, and rational investigation pathway. *Ann Neurol*. 2017;81(3):333-43.
76. Stabile A, Di Lazzaro V, Colosimo C, Piazza F, Ferrarese C, DiFrancesco JC. Idiopathic infratentorial superficial siderosis of the central nervous system: case report and review of literature. *Neurol Neurochir Pol*. 2018;52(1):102-6.
77. Webb AJ, Flossmann E, Armstrong RJ. Superficial siderosis following spontaneous intracranial hypotension. *Pract Neurol*. 2015;15(5):382-4.

78. Flores Martin A, Shanmugarajah P, Hoggard N, Hadjivassiliou M. Treatment Response of Deferiprone in Infratentorial Superficial Siderosis: a Systematic Review. *Cerebellum*. 2021;20(3):454-61.
79. Sammarraiee Y, Banerjee G, Farmer S, Hylton B, Cowley P, Eleftheriou P, et al. Risks associated with oral deferiprone in the treatment of infratentorial superficial siderosis. *J Neurol*. 2020;267(1):239-43.
80. Sader N, Zeiler FA, Gillman LM, West M, Kazina CJ. Indomethacin for control of ICP. *Neurocrit Care*. 2015;22(3):437-49.
81. Scotton WJ, Botfield HF, Westgate CS, Mitchell JL, Yiangou A, Uldall MS, et al. Topiramate is more effective than acetazolamide at lowering intracranial pressure. *Cephalalgia*. 2019;39(2):209-18.
82. Schievink WI, Maya MM, Jean-Pierre S, Moser FG, Nuno M, Pressman BD. Rebound high-pressure headache after treatment of spontaneous intracranial hypotension: MRV study. *Neurol Clin Pract*. 2019;9(2):93-100.
83. Mokri B. Intracranial hypertension after treatment of spontaneous cerebrospinal fluid leaks. *Mayo Clin Proc*. 2002;77(11):1241-6.
84. Kranz PG, Amrhein TJ, Gray L. Rebound intracranial hypertension: a complication of epidural blood patching for intracranial hypotension. *AJNR Am J Neuroradiol*. 2014;35(6):1237-40.
85. Friedman DI, Quiros PA, Subramanian PS, Mejico LJ, Gao S, McDermott M, et al. Headache in Idiopathic Intracranial Hypertension: Findings From the Idiopathic Intracranial Hypertension Treatment Trial. *Headache*. 2017;57(8):1195-205.
86. Ball AK, Howman A, Wheatley K, Burdon MA, Matthews T, Jacks AS, et al. A randomised controlled trial of treatment for idiopathic intracranial hypertension. *J Neurol*. 2011;258(5):874-81.
87. Levine BD, Zuckerman JH, Pawelczyk JA. Cardiac atrophy after bed-rest deconditioning: a nonneural mechanism for orthostatic intolerance. *Circulation*. 1997;96(2):517-25.
88. Fu Q, Vangundy TB, Shibata S, Auchus RJ, Williams GH, Levine BD. Exercise training versus propranolol in the treatment of the postural orthostatic tachycardia syndrome. *Hypertension*. 2011;58(2):167-75.
89. George SA, Bivens TB, Howden EJ, Saleem Y, Galbreath MM, Hendrickson D, et al. The international POTS registry: Evaluating the efficacy of an exercise training intervention in a community setting. *Heart Rhythm*. 2016;13(4):943-50.
90. Shibata S, Fu Q, Bivens TB, Hastings JL, Wang W, Levine BD. Short-term exercise training improves the cardiovascular response to exercise in the postural orthostatic tachycardia syndrome. *J Physiol*. 2012;590(15):3495-505.

## Supplementary material 2. Quality standards

### Clinical assessment and management:

1. Any patient with new onset headache with orthostatic association should be assessed for SIH.
2. While assessing patients for SIH, ensure appropriate conservative management including analgesia and anti-emetics are in place. Education about the role of bed rest should also include advice to prevent deconditioning.
3. All patients with probable or definite SIH should be referred urgently to neurology to be seen within 4 weeks. Patient unable to self-care should be referred as an emergency.
4. Patients with suspected SIH who do not respond to at least one epidural blood patch (EBP), or where facilities to provide EBPs do not exist, should be referred to a centre experienced in the management of SIH, ideally with specialist MDT input. (Special note - rapidly deteriorating patients should be referred immediately/urgently).

### Investigations:

1. MRI of the brain with contrast and MRI of the whole spine should be performed as first line investigations and reviewed by a consultant neuroradiologist.
2. Lumbar puncture should not be performed routinely as a first line investigation.
3. Patients with abnormal brain or spine MRI (including the presence of meningeal diverticula) who undergo myelography for leak localisation should first have had at least one large volume non-targeted epidural blood patches.
4. Patients with a spinal longitudinal epidural collection (SLEC) who have myelography should undergo dynamic myelography - either CTM or DSM with position dependent on where the source of leak is most likely to be as determined by location of SLEC.
5. Patients with no SLEC should undergo lateral decubitus CTM or lateral decubitus DSM, examining both sides for completeness.

### Procedures:

1. All patients with SIH should be offered non-targeted EBP as soon as possible following diagnosis. Time to EBP should not exceed 4 weeks from diagnosis.

2. All patients should be contacted 12-48hrs following EBP to confirm the absence of concerning features and should be given a point of contact for their clinical team in case of development of concerning features.
3. All patients should have efficacy of EBP assessed within 10-14 days and subsequent EBPs within 1 month and details entered into an outcomes database.
4. Time from decision to operate, to date of surgery within 6 weeks.
5. Outcome assessment should be performed at 6 weeks and 3 months and patients in the UK should be included in an outcomes register.

### Supplementary material 3. Audit tool

#### Clinical assessment and pathway:

1. At the time of initial assessment, was the patient asked about the postural component of the headache?

Yes  No

2. What was the time interval from the initial suspicion of spontaneous intracranial hypotension (SIH) to assessment by a neurologist?

<24 hours  <48 hours  <4 weeks  <3 months  >3 months

3. Was the patient educated or directed to educational resources regarding:

Bed rest? Yes  No

Hydration? Yes  No

Analgesia? Yes  No

Methods to avoid deconditioning and deep vein thrombosis? Yes  No

4. At what point was the patient referred for multidisciplinary discussion in a specialist neuroscience centre?

Immediately after SIH was suspected  After 1 epidural blood patch (EBP)

After 2 EBPs  After >2 EBPs  N/A (not referred)

#### Investigations:

1. What imaging was performed at the first assessment?

MRI head with contrast  MRI head without contrast

MRI whole spine  Other (please specify)  \_\_\_\_\_

2. Was the imaging reviewed by a consultant neuroradiologist?

Yes  No

3. Was lumbar puncture performed?

Yes, to measure opening pressure  Yes, for other reasons  No

4. For patients with abnormal brain or spine MRI undergoing myelography, how many blood patches had been performed beforehand?

None  1  2  > 2 (specify)  \_\_\_\_\_

5. For patients with a spinal longitudinal epidural collection (SLEC) undergoing myelography, was “dynamic” myelography performed?

Yes  No

6. For patients without a SLEC undergoing myelography, was lateral decubitus myelography performed?

Yes, examining both sides  Yes, one side only  No

**Procedures:**

1. Once diagnosis of SIH was made, how soon was the first non-targeted EBP performed?

<48 hours  <2 weeks  <4 weeks  <3 months  >3 months

2. After EBP was the patient:

Given a point of contact for their clinical team? Yes  No

Contacted at 12-48 hours to enquire about concerning features? Yes  No

How soon was efficacy of EBP assessed?

<10 days  10-14 days  2-4 weeks  4-8 weeks  >8 weeks

3. Once a decision for to operate has been made, how soon was the date of surgery?

<2 weeks  <6 weeks  <3 months  >3 months

4. Was outcome assessed at the following intervals and included in an outcomes database?

6 weeks Yes  No

3 months Yes  No