

Visual and Tomographic Outcomes of a 300° Arc-length ICRS Implantation in Moderate to Advanced Central Keratoconus

José F Alfonso MD, PhD, Leonardo Torquetti MD, PhD, Luis Fernandez-Vega-Cueto MD, PhD, Bruce Allan MD, FRCOphth, Aranzazu Poo-López, BSc, Belén Alfonso Bartolozzi MD, José de la Cruz, MD, MSc, Tiago Monteiro, MD, David Madrid-Costa, PhD

From Instituto Universitario Fernández-Vega, Fundación de Investigación Oftalmológica, Universidad de Oviedo, Oviedo, Spain (JFA, LF-V-C, AP-L, BA-B); Centro de Excelência em Oftalmologia, Pará de Minas, Brazil (LT); the Department of Corneal and External Eye Diseases, Moorfields Eye Hospital, London, United Kingdom (BA); University of Illinois Eye and Ear, Chicago, Illinois (JD); the Ophthalmology Department, Hospital de Braga, Braga, Portugal (TM); Life and Health Sciences Research Institute, Escola de Medicina, Universidade do Minho, Braga, Portugal (TM); and Faculty of Optics and Optometry, Universidad Complutense de Madrid, Madrid, Spain (DM-C).

Dr. Allan receives partial salary support for research from the Department of Health's NIHR Biomedical Research Centre for Ophthalmology at Moorfields Eye Hospital and UCL Institute of Ophthalmology. The remaining authors have no financial or proprietary interest in the materials presented herein. The views

expressed in the publication are those of the authors and not necessarily those of the Department of Health.

Correspondence: José F. Alfonso, MD, PhD, Instituto Universitario Fernández-Vega, Avda. Dres. Fernández-Vega 114, 33012 Oviedo, Spain. Email: j.alfonso@fernandez-vega.com

Purpose: To assess the outcomes of implanting a new 300° arc-length intrastromal corneal ring segment (ICRS) in moderate to advanced central hyperprolate keratoconus.

Methods: Forty-two eyes with moderate to advanced central hyperprolate keratoconus were evaluated before and after implanting an inferior 300° ICRS (AJL Ophthalmic). The clinical measurements taken included manifest refraction, uncorrected (UDVA) and corrected (CDVA) distance visual acuity (logMAR scale), and corneal tomographic analysis (Sirius; Costruzioni Strumenti Oftalmici). Changes in the anterior and posterior corneal surfaces and the root mean square (RMS) for coma-like aberrations for a pupil size of 4.5 mm were evaluated. All examinations were performed before surgery and 6 months after surgery.

Results: The mean UDVA improved from 1.12 ± 0.48 logMAR preoperatively to 0.73 ± 0.37 logMAR postoperatively ($P < .0001$). The mean CDVA changed from 0.33 ± 0.20 to 0.20 ± 0.11 logMAR ($P < .0001$). Postoperatively, the CDVA improved by two or more lines in 45.2% of the eyes and increased by one line in 19.04%, and none of the patients lost lines of CDVA. All of the anterior and posterior corneal tomographic parameters analyzed were significantly improved after surgery, except posterior flat keratometry, which remained unchanged. In 80.95% of the eyes, the postoperative mean keratometry was 50.00 diopters or less. The 6-month RMS for coma-like aberrations also declined significantly from 1.57 ± 0.68 to 1.06 ± 0.42 μm after surgery ($P < .0001$).

Conclusions: These results suggest that implanting a 300° arc-length ICRS is a safe and effective procedure for treating patients with moderate to advanced central hyperprolate keratoconus and clear cornea.

Keratoconus is a corneal disease that may result in severe visual impairment and is a leading indication for corneal transplantation. (1,2) The visual impact of this disease depends on the disease stage. Parker et al (3) proposed a practical definition of advanced keratoconus based on contact lens intolerance and poor spectacle-corrected vision. Most corneal transplantations for keratoconus are performed for patients who satisfy these two criteria, but these patient-centered measures also correlated with steeper average keratometry. (4,5)

Although corneal transplantation in keratoconus (penetrating keratoplasty and deep lamellar anterior keratoplasty) can provide satisfactory outcomes, sight-threatening complications include rejection, secondary glaucoma, and graft failure. (6-8) Furthermore, many patients with advanced keratoconus will require transplantation early in life and may require more than one graft over their lifetime, with an increased risk of failure in successive transplants. (3) With this in mind, it would be of great benefit if, in patients with advanced keratoconus (those with unacceptable visual acuity and contact lens intolerance), visual restoration could be achieved through surgical options that avoid or at least delay corneal transplantation. Corneal cross-linking has been demonstrated to be safe and effective in arresting disease progression in early keratoconus, (9,10) but it is ineffective in restoring vision or contact lens tolerance in advanced keratoconus. (3)

Short-arc intrastromal corneal ring segment (ICRS) implantation effectively flattens and regularizes corneal shape in eyes with mild to moderate keratoconus, improving visual quality, (10-14) but short-arc ICRS implantation is less effective in more advanced disease. (15,16) The reintroduction of the long-arc ICRS models is yielding encouraging visual and refractive outcomes in more advanced keratoconus. (17-23) Nevertheless, some complications, mainly associated with the proximity of the ICRS tip to the surgical incision, have been reported. (17-20) To overcome these complications, variations in long arc-lengths have been proposed for moderate to advanced keratoconus. (21-23) It has been hypothesized that the ideal indication for this type of ICRS should be specifically for moderate to advanced central hyperprolate keratoconus. (23)

In this study, we explored the clinical outcomes of a novel 300° arc-length ICRS implanted using the femtosecond laser in eyes with moderate to advanced central hyperprolate keratoconus. Furthermore, because both anterior and posterior corneal surfaces are affected in keratoconus, (24) we analyzed the surgically induced changes in a variety of anterior and posterior corneal shape indices.

Patients and Methods

This study analyzed the visual and corneal shape outcomes of 300° arc-length ICRS implantation in a consecutive case series of eyes with central hyperprolate

moderate to advanced keratoconus. Surgery was performed at the Fernández-Vega Ophthalmological Institute (Oviedo, Spain). The tenets of the Declaration of Helsinki were followed, and full ethical approval from the Institute was obtained. After receiving a full explanation of the nature and possible consequences of the study and the surgery, all patients granted their informed consent.

Inclusion criteria were the presence of keratoconus, poor or unsatisfactory corrected distance visual acuity (CDVA) with spectacle correction, contact lens intolerance, mean keratometry of 50.00 diopters (D) or greater, and corneal thickness of at least 400 μm at the zone involved in the implantation. In addition, only eyes meeting the following conditions to be considered as central hyperprolate were included: (1) the highest point of the posterior and anterior elevation map had to be centrally located at a distance of 1.2 mm or less from the center of the cornea (Sirius Tomographer; Costruzioni Strumenti Oftalmici); (2) the thinnest point on the corneal pachymetry map had to be centrally located at a distance of 1.2 mm or less from the center of the cornea (Sirius Tomographer); and (3) corneal asphericity had to be ≤ 1.0 or less for an 8-mm corneal diameter (Sirius Tomographer).

Exclusion criteria were patients who had previous ocular surgery, central corneal scarring or previous hydrops, active ocular disease (other than keratoconus), a history of ocular disorders with a potential impact on the variables under study,

and patients with an autoimmune disease or a systemic connective tissue disease.

Surgery was scheduled immediately after diagnosis. A single, inferior, 300° arc-length Ferrara-type AFR5 ICRS (AJL Ophthalmic) was implanted in all eyes (Figure 1). Segment thickness was 200 µm in all cases. This new long-arc ICRS has the same triangular cross-section as the short-arc Ferrara-type ICRS and is also made of polymethylmethacrylate. Their apical diameter is 5 mm (flat basis width = 600 µm). The same surgeon (JFA) performed all procedures using a femtosecond laser and employing our standard procedure previously described. (25-29) The laser software was programmed for an inner diameter of 4.6 mm and an outer diameter from 5.4 mm. An incision was performed at the 12-o'clock position, and the ICRS was implanted and positioned at 270° (Figure 1). Preoperative medication included 0.5% proparacaine, 0.3% ciprofloxacin, and 0.2% oxybuprocaine CIH. Postoperative treatment consisted of a combination of antibiotics (tobramycin 3 mg/mL) and steroid eye drops (dexamethasone 1 mg/mL), administered three times daily for 2 weeks, tapering the dose over the following 2 weeks.

Figure 1: Single 300° arc length Ferrara-type AFR5 intrastromal corneal ring segment (ICRS) (AJL Ophthalmic) implanted in one case. An incision was

performed at the 12-o'clock position and the ICRS was implanted with its mid-point positioned at 270°.

A complete ophthalmological examination was conducted in all patients preoperatively and postoperatively. The clinical measurements taken primarily included manifest refraction, uncorrected distance visual acuity (UDVA) and CDVA (logMAR), and corneal tomographic analysis (Sirius Tomographer). The following tomographic data were analyzed: flat, steep, and mean (Kmean) keratometry values, keratometry cylinder, corneal asphericity (for an 8-mm corneal diameter), posterior flat keratometry, posterior steep keratometry, posterior corneal astigmatism, highest point of the ectasia on the anterior and posterior corneal surface, symmetry index front, and symmetry index back. Furthermore, the root mean square (RMS) for coma-like aberrations was evaluated for a pupil size of 4.5 mm. All examinations were performed before surgery and 6 months after ICRS implantation by an ophthalmic technician, who was unaware of the objective of the study.

Data analysis was performed with SPSS for Windows software (version 15.0; SPSS, Inc). Normality was checked using the Kolmogorov-Smirnov test, and outcomes were compared using t tests. A P value of less than .05 was considered statistically significant. Data are shown as the mean \pm standard deviation.

Results

This study comprised 42 eyes of 36 patients (20 men and 16 women) with a mean age of 32.9 ± 13.9 years (range: 14 to 62 years). ICRS were successfully implanted in all 42 eyes studied in this series, with no intraoperative or postoperative complications.

The mean UDVA improved from 1.12 ± 0.48 logMAR preoperatively to 0.73 ± 0.37 logMAR postoperatively ($P < .0001$). The mean CDVA (logMAR) changed from 0.33 ± 0.20 to 0.20 ± 0.11 logMAR ($P < .0001$). The efficacy index (mean postoperative UDVA/mean preoperative CDVA) was 0.49. Postoperatively, the CDVA improved by two or more lines in 45.2% of the eyes, increased by one line in 19.1%, and remained unchanged in 35.7% of the eyes, and none of the patients lost lines of CDVA (Figure 2A). Within eyes with a preoperative CDVA worse than 0.3 logMAR (14 eyes), 85.8% gained two or more lines of CDVA postoperatively (Figure 2B). On the other hand, 50% of eyes that had a preoperative CDVA of 0.3 logMAR or better (28 eyes) gained one or more lines of CDVA after the surgery (Figure 2C). The 6-month safety index (ratio of postoperative to preoperative CDVA) was 1.26. The safety index was 1.79 for the eyes with a preoperative CDVA worse than 0.3 logMAR and 1.13 for the eyes with a preoperative CDVA of 0.3 logMAR or better.

Figure 2: Variation in corrected distance visual acuity (CDVA) 6 months after intrastromal corneal ring segment (ICRS) implantation (safety) for (A) the whole

sample, (B) eyes with a preoperative CDVA worse than 0.3 logMAR, and (C) eyes with a preoperative CDVA of 0.3 logMAR or better. [Please download the PDF to view the image]

The spherical equivalent decreased from a preoperative value of 4.24 ± 3.33 D to a 6-month postoperative value of 2.78 ± 2.61 D ($P < .0001$). Table 1 summarizes the corneal tomographic parameters evaluated in this study. All anterior and posterior corneal tomographic parameters analyzed improved significantly after surgery, except posterior flat keratometry, which remained unchanged postoperatively. A total of 80.9% of the eyes had a postoperative mean keratometric value of 50.00 D or less and 57.1% had 48.00 D or less (Figure 3). Figure A (available in the online version of this article) shows the tangential topographic maps before and after ICRS implantation of cases analyzed. Preoperatively, all tomographic parameters were significantly worse in eyes with a preoperative CDVA worse than 0.3 logMAR if compared with eyes with a preoperative CDVA of 0.3 logMAR or better (Table A, available in the online version of this article). However, there were no statistically significant differences between both groups when surgically induced changes in all parameters were compared (Table A).

Discussion

The main indications for corneal transplantation in patients with keratoconus are contact lens intolerance or issues related to vision (poor, unsatisfactory, or worsening visual acuity). (4) Furthermore, steeper keratometry (average keratometry of more than 53.00 D to 55.00 D) has been associated with an increased risk of requiring a corneal transplantation. Specifically, central keratoconus represents a challenge for ophthalmologists due to the increased corneal central steepening and excess corneal prolateness. For these cases, ICRS implantation could represent the last chance to avoid a corneal transplantation. A previous study found that implanting a 210° arc-length ICRS is a safe, effective, and stable procedure for treating patients with mild central keratoconus, (29) showing no intraoperative or postoperative complications. However, the induced corneal flattening (approximately 2.00 D) might not be enough for those cases with an average keratometric value of greater than 50.00 D (or more advanced cases). The 355° arc-length ICRS provides marked corneal flattening and a significant improvement in UDVA and CDVA. (17,18) However, a high rate of postoperative complications (ring extrusion, (17,18) corneal melting, (18) and neovascularization (18) were reported. The proximity between the ICRS tip and the incision is the main explanation for these complications.

Considering the safe results of the 210° ICRS and the large 355° ICRS-induced corneal flattening, new arc-lengths midway between both are being proposed (ie, shorter than 355° and longer than 210°). (21-23) Sadoughi et al (21) reported the visual outcomes of a 340° ICRS in patients with moderate to advanced keratoconus. They found that all analyzed topographic parameters improved significantly after the surgery (Kmean value decreased approximately 4.00 D). However, although no significant postoperative ICRS-related complications were reported, 22.2% of the eyes lost lines of CDVA. The authors found that all eyes that experienced a worsening in CDVA had a preoperative Kmean value of greater than 53.00 D (the average Kmean value in these eyes was 55.20 D). Consequently, the authors suggested that implantation of this ICRS is not recommended in severe cases. It should be noted that both paracentral and central keratoconus were included in this study. Considering the long-arc ICRS-induced corneal changes, it has been suggested that this type of ICRS should be devoted to central advanced keratoconus. (23) Hence, it would be interesting to analyze the results of this type of ICRS in a specific sample of central keratoconus.

Two studies reported their clinical outcomes using a new 320° arc-length ICRS. (22,23) Both studies found similar results to those previously reported with a 355° arc-length ICRS, with significant improvement in UDVA and CDVA (approximately 92.4% of the eyes gained one or more lines of CDVA after

surgery (23) and a significant induced corneal flattening (the Kmean value reduced approximately 4.00 D (22) to 5.00 D (23) postoperatively). Torquetti et al (23) reported a few complications associated with the manual technique for ICRS implantation, but no ICRS-related complications. The authors suggested that the ideal patients to be implanted with these long arc-length ICRS are those with central moderate to advanced hyperprolate keratoconus and CDVA worse than 20/40.

The current study evaluated the clinical results of a new 300° long-arc-length ICRS using a femtosecond laser in a specific sample of moderate to advanced central hyperprolate keratoconus. Our results are in line with those previously reported with the 320° ICRS. Mean UDVA and CDVA significantly improved postoperatively. No eyes lost lines of CDVA after the surgery, and 64.3% improved postoperatively. This improvement was especially significant for those eyes that had a preoperative CDVA worse than 0.3 logMAR (20/40 Snellen scale), with 85.8% of these eyes gaining two or more lines after surgery (Figure 2B).

Regarding the evaluated corneal tomographic parameters, there was a significant improvement in all of them. There was significant induced corneal flattening, a decrease of corneal prolateness, and all indicators related to corneal asymmetry significantly improved postoperatively (Table 1). It is interesting to note that 97.6% of the eyes had a postoperative mean

keratometry of 53.00 D or less, 80.9% had 50.00 D or less, and 57.1% had 48.00 D or less (Figure 3). Considering that having a steeper Kmean value of 53.00 D or less to 55.00 D or less has been described as a risk factor to require corneal transplantation, our results could indicate that this surgery ameliorates this risk factor in a significant percentage of the cases. In addition, the postoperative corneal flattening and the significant decrease in the anterior corneal prolateness and asymmetry could enhance contact lens tolerance. (30,31) At the same time, a secondary refractive procedure with a phakic intraocular lens implantation could also be planned to correct any residual refractive error. (32) All together, the corneal and refractive improvements obtained after the 300° arc-length ICRS implantation could also circumvent another risk factor for corneal keratoplasty, contact lens intolerance. Furthermore, the significant CDVA improvement is another factor reinforcing the idea that this surgery could prevent corneal transplantation in a substantial number of eyes with hyperprolate central moderate to advanced keratoconus. Finally, it is essential to note that the 300° ICRS also regularized the corneal asymmetry, as shown by the improvement obtained in the topography symmetry indicators (symmetry index front and back) and by the significant decrease in the RMS corneal-like aberrations. It is known that corneal irregularities and coma-like aberrations negatively affect the visual quality of patients with keratoconus. Therefore, beyond improving the CDVA in high contrast, this approach would also provide a

significant visual quality improvement for moderate to advanced central keratoconus.

Analyzing Table A, it could be observed that, preoperatively, all tomographic parameters were significantly worse in the eyes with a preoperative CDVA worse than 0.3 logMAR compared with those eyes with a preoperative CDVA of 0.3 logMAR or better. However, there were no statistically significant differences between both groups in the surgically induced changes for any of the parameters analyzed. Considering these results and those published for the 210° ICRS and 320° ICRS, perhaps a good approach for hyperprolate central keratoconus could be to implant a 210° ICRS for mild keratoconus and a 300° ICRS for moderate to advanced cases. In more advanced cases that have a clear cornea, a 300° ICRS thicker than the one used in this study (more than 200 µm) or a 320° ICRS could be an excellent option to obtain a more significant corneal remodelling effect. Based on our surgical experience, a 300° ICRS has the potential advantage over the 320° of being easier to implant. Furthermore, it is interesting to note that new versions of long-arc ICRS (240° to 270°) are currently under study to treat central keratoconus. The new versions of ICRS, along with those already available (210°, 300°, and 320°), represent an outstanding chance to optimize the treatment of central keratoconus, from mild to advanced stages.

The posterior corneal surface is also affected by keratoconus. (24) Although its optical contribution is less important than the anterior surface, the changes and irregularities induced by keratoconus in the posterior corneal surface could contribute to worsening optical quality of the cornea, especially in advanced keratoconus. (33) Our study found that the 300° arc-length ICRS also improved the posterior corneal surface parameters. A flattening of the steep keratometry, a significant reduction of the highest point of the ectasia on the posterior corneal surface, and a significant improvement in the symmetry index back was observed after surgery. These outcomes show that the posterior corneal surface became more regularized and flattened postoperatively.

No intraoperative or postoperative complications were found. The use of the femtosecond laser technique to create the corneal tunnel made the ICRS implantation safer and provided a significant reduction of complications (eg, extrusion ring), mostly due to the precise depth of the implantation. (33-36) Furthermore, no ICRS-related complications were reported, reinforcing the idea that leaving a gap between the tips of the ICRS and the surgical incision makes the procedure safer. (21-23)

The newer types of ICRS with long arc-length are providing encouraging outcomes in advanced central keratoconus, suggesting that they could provide a visual restoration that avoids or at least delays corneal transplantation in this

type of keratoconus when the cornea remains clear. (17,18,22,23) However, more long-term follow-up studies are required to assess the proportion of eyes in which the corneal transplantation is prevented and the percentage in which this procedure just delays the transplant. Nevertheless, if corneal transplantation were required, deep lamellar anterior keratoplasty could be safely performed after ICRS implantation and even with the ICRS in place. (37,38)

The outcomes of the current study suggest that the implantation of a single, inferior, 300° arc-length Ferrara-type ICRS improves corneal tomographic parameters in both anterior and posterior surfaces, with a consequent corneal regularization and a significant improvement of visual acuity results in moderate to advanced central hyperprolate keratoconus.

Author Contributions

Study concept and design (JFA, LT, LF-V-C, BA, AP-L, BA-B, JD, DM-C, TM); data collection (JFA, LF-V-C, AP-L, BA-B); analysis and interpretation of data (JFA, LT, LF-V-C, BA, AP-L, BA-B, JD, TM, DM-C); writing the manuscript (DM-C); critical revision of the manuscript (JFA, LT, LF-V-C, BA, AP-L, BA-B, JD, TM, DM-C); supervision (JFA)

References

- (1.) Ali Javadi M, Kanavi MR, Safi S. A 27-year report from the Central Eye Bank of Iran. *J Ophthalmic Vis Res.* 2020;15(2):149-159. doi:10.18502/jovr.v15i2.6731
- (2.) Zare M, Javadi MA, Einollahi B. Indications for corneal transplantation at a tertiary referral center in Tehran. *J Ophthalmic Vis Res.* 2010;5(2):82-86.
- (3.) Parker JS, van Dijk K, Melles GR. Treatment options for advanced keratoconus: a review. *Surv Ophthalmol.* 2015;60(5):459-480.
doi:10.1016/j.survophthal.2015.02.004
- (4.) Reeves SW, Stinnett S, Adelman RA, Afshari NA. Risk factors for progression to penetrating keratoplasty in patients with keratoconus. *Am J Ophthalmol.* 2005;140(4):607-611. doi:10.1016/j.ajo.2005.05.029
- (5.) Sray WA, Cohen EJ, Rapuano CJ, Laibson PR. Factors associated with the need for penetrating keratoplasty in keratoconus. *Cornea.* 2002;21(8):784-786.
doi:10.1097/00003226-200211000-00011
- (6.) Liu H, Chen Y, Wang P. Efficacy and safety of deep anterior lamellar keratoplasty vs. penetrating keratoplasty for keratoconus: a meta-analysis. *PLoS One.* 2015;10(1):e0113332. doi:10.1371/journal.pone.0113332

(7.) MaharanaPK,AgarwalK,JhanjiV,VajpayeeRB.Deep anterior lamellar keratoplasty for keratoconus: a review.Eye Contact Lens.2014;40(6):382?389. doi:10.1097/ICL.0000000000000076

(8.) RahmanI,CarleyF,HillarbyC,BrahmaA,TulloAB.Penetrating keratoplasty: indications, outcomes, and complications.Eye (Lond).2009;23(6):1288?1294. doi:10.1038/eye.2008.305

(9.) BeckmanKA,GuptaPK,FaridMASCRCornea Clinical Committee.Corneal crosslinking: current protocols and clinical approach.J Cataract Refract Surg.2019;45(11):1670?1679. doi:10.1016/j.jcrs.2019.06.027

(10.) HershPS,StultingRD,MullerDUnited States Crosslinking Study Group.United States Multicenter Clinical Trial of Corneal Collagen Crosslinking for Keratoconus Treatment.Ophthalmology.2017;124(9):1259?1270. doi:10.1016/j.ophtha.2017.03.052

(11.) IzquierdoLJr,MannisMJ,Mejías SmithJA,HenriquezMA.Effectiveness of intrastromal corneal ring Implantation in the treatment of adult patients with keratoconus: a systematic review.J Refract Surg.2019;35(3):191?200. doi:10.3928/1081597X-20190109-02

(12.) Giacomini NT, Mello GR, Medeiros CS. Intracorneal ring segments implantation for corneal ectasia. *J Refract Surg.* 2016;32(12):829-839. doi:10.3928/1081597X-20160822-01

(13.) Fernández-Vega-Cueto L, Romano V, Zaldivar R. Surgical options for the refractive correction of keratoconus: myth or reality. *J Ophthalmol.* 2017;2017:7589816. doi:10.1155/2017/7589816

(14.) Ziaei M, Barsam A, Shamie N. ASCRS Cornea Clinical Committee. Reshaping procedures for the surgical management of corneal ectasia. *J Cataract Refract Surg.* 2015;41(4):842-872. doi:10.1016/j.jcrs.2015.03.010

(15.) Torquetti L, Ferrara G, Almeida F. Intrastromal corneal ring segments implantation in patients with keratoconus: 10-year follow-up. *J Refract Surg.* 2014;30(1):22-26. doi:10.3928/1081597X-20131217-02

(16.) Alfonso JF, Lisa C, Fernández-Vega L, Madrid-Costa D, Montés-Micó R. Intrastromal corneal ring segment implantation in 219 keratoconic eyes at different stages. *Graefes Arch Clin Exp Ophthalmol.* 2011;249(11):1705-1712. doi:10.1007/s00417-011-1759-9

(17.) Abd Elaziz MS, El Saebay Sarhan AR, Ibrahim AM, Elshafy Haggag HA. Anterior segment changes after femtosecond laser-assisted implantation of a 355-degree intrastromal corneal ring segment in advanced

keratoconus.Cornea.2018;37(11):1438?1443.

doi:10.1097/ICO.0000000000001702

(18.) AbdellahMM,AmmanHG.Femtosecond laser implantation of a 355-degree intrastromal corneal ring segment in keratoconus: a three-year follow-up.J

Ophthalmol.2019;2019:6783181. doi:10.1155/2019/6783181

(19.) JadidiK,MosaviSA,NejatF,NaderiM,JananiL,SerahatiS.Intrastromal corneal ring segment implantation (keraring 355°) in patients with central keratoconus:

6-month follow-up.J Ophthalmol.2015;2015:916385. doi:10.1155/2015/916385

(20.) Vega-EstradaA,ChorroE,SewelamA,AlioJL.Clinical outcomes of a new asymmetric intracorneal ring segment for the treatment of

keratoconus.Cornea.2019;38(10):1228?1232.

doi:10.1097/ICO.0000000000002062

(21.) SadoughiMM,EinollahiB,VeisiAR,.Femtosecond laser implantation of a 340-degree intrastromal corneal ring segment in keratoconus: short-term outcomes.J

Cataract Refract Surg.2017;43(10):1251?1256. doi:10.1016/j.jcrs.2017.07.026

(22.) RochaGADN,Ferrara de Almeida CunhaP,Torquetti CostaL,Barbosa de SousaL.Outcomes of a 320-degree intrastromal corneal ring segment

implantation for keratoconus: results of a 6-month follow-up.Eur J

Ophthalmol.2020;30(1):139?146. doi:10.1177/1120672118818018

(23.) TorquettiL,CunhaP,LuzA,.Clinical outcomes after implantation of 320°-arc length intrastromal corneal ring segments in keratoconus.Cornea.2018;37(10):1299?1305. doi:10.1097/ICO.0000000000001709

(24.) TomidokoroA,OshikaT,AmanoS,HigakiS,MaedaN,MiyataK.Changes in anterior and posterior corneal curvatures in keratoconus.Ophthalmology.2000;107(7):1328?1332. doi:10.1016/S0161-6420(00)00159-7

(25.) Fernández-Vega CuetoL,LisaC,Poo-LópezA,Madrid-CostaD,Merayo-LlovesJ,AlfonsoJF.Intrastromal corneal ring segment implantation in 409 paracentral keratoconic eyes.Cornea.2016;35(11):1421?1426. doi:10.1097/ICO.0000000000000978

(26.) AlfonsoJF,Fernández-Vega CuetoL,BaamondeB,Merayo-LlovesJ,Madrid-CostaD,Montés-MicóR.Inferior intrastromal corneal ring segments in paracentral keratoconus with no coincident topographic and coma axis.J Refract Surg.2013;29(4):266?272. doi:10.3928/1081597X-20130318-06

(27.) AlfonsoJF,Fernández-Vega-CuetoL,LisaC,MonteiroT,Madrid-CostaD.Long-term follow-up of intrastromal corneal ring segment implantation in pediatric keratoconus.Cornea.2019;38(7):840?846. doi:10.1097/ICO.0000000000001945

- (28.) Fernández-Vega Cueto L, Lisa C, Madrid-Costa D, Merayo-Llotes J, Alfonso JF. Long-term follow-up of intrastromal corneal ring segments in paracentral keratoconus with coincident corneal keratometric, comatic, and refractive axes: stability of the procedure. *J Ophthalmol*. 2017;2017:4058026.
- (29.) Lisa C, Fernández-Vega Cueto L, Poo-López A, Madrid-Costa D, Alfonso JF. Long-term follow-up of intrastromal corneal ring segments (210-degree arc length) in central keratoconus with high corneal asphericity. *Cornea*. 2017;36(11):1325-1330. doi:10.1097/ICO.0000000000001339
- (30.) Khan MI, Injarie A, Muhtaseb M. Intrastromal corneal ring segments for advanced keratoconus and cases with high keratometric asymmetry. *J Cataract Refract Surg*. 2012;38(1):129-136. doi:10.1016/j.jcrs.2011.07.031
- (31.) Moreira LB, Bardal RA, Crisigiovanni LR. Contact lenses fitting after intracorneal ring segments implantation in keratoconus. *Arq Bras Oftalmol*. 2013;76(4):215-217. doi:10.1590/S0004-27492013000400004
- (32.) Alfonso JF, Lisa C, Fernández-Vega L, Madrid-Costa D, Poo-López A, Montés-Micó R. Intrastromal corneal ring segments and posterior chamber phakic intraocular lens implantation for keratoconus correction. *J Cataract Refract Surg*. 2011;37(4):706-713. doi:10.1016/j.jcrs.2010.10.060

(33.) PiñeroDP, AlióJL, El KadyB,. Refractive and aberrometric outcomes of intracorneal ring segments for keratoconus: mechanical versus femtosecond-assisted procedures. *Ophthalmology*. 2009;116(9):1675-1687.

doi:10.1016/j.ophtha.2009.05.016

(34.) MonteiroT, AlfonsoJF, FranqueiraN,. Comparison of clinical outcomes between manual and femtosecond laser techniques for intrastromal corneal ring segment implantation. *Eur J*

Ophthalmol. 2019;1120672119872367. 10.1177/1120672119872367

(35.) MonteiroT, AlfonsoJF, FreitasR,. Comparison of complication rates between manual and femtosecond laser-assisted techniques for intrastromal corneal ring segments implantation in keratoconus. *Curr Eye Res*. 2019;44(12):1291-1298.

doi:10.1080/02713683.2019.1635165

(36.) MonteiroT, AlfonsoJF, FranqueiraN, Faria-CorreiaF, AmbrósioR Jr, Madrid-CostaD. Predictability of tunnel depth for intrastromal corneal ring segments implantation between manual and femtosecond laser techniques. *J Refract*

Surg. 2018;34(3):188-194. doi:10.3928/1081597X-20180108-01

(37.) FontanaL, ParenteG, SincichA, TassinariG. Deep anterior lamellar keratoplasty after Intacs implantation in patients with keratoconus. *Cornea*. 2009;28(1):32-35.

doi:10.1097/ICO.0b013e318183a40c

(38.) RaveraV,BovoneC,ScorciaV,D'AngeloS,BusinM.Deep anterior lamellar keratoplasty in eyes with intrastromal corneal ring segments.Cornea.2019;38(5):642?644. doi:10.1097/ICO.0000000000001906

Table 1

Parameter	Preoperative	Postoperative	P
K1 (D)	49.74 ± 2.33	45.83 ± 2.77	<.001
K2 (D)	54.54 ± 2.51	49.52 ± 2.87	<.001
Kmean (D)	52.14 ± 2.03	47.67 ± 2.71	<.001
Kcyl (D)	4.79 ± 1.67	3.69 ± 1.90	<.001
Corneal asphericity	?1.62 ± 0.42	?0.80 ± 0.49	<.001
K1b (D)	?7.74 ± 0.88	?7.80 ± 0.82	.27
K2b (D)	?9.06 ± 1.12	?8.64 ± 0.85	.002
PCA (D)	?1.32 ± 1.14	?0.84 ± 0.52	.008
KVf (μm)	49.78 ± 18.19	42.78 ± 19.56	.002
KVb (μm)	110.48 ± 36.44	101.90 ± 31.57	.02
Slf (D)	7.89 ± 6.04	6.54 ± 6.09	.009
Slb (D)	2.04 ± 1.37	1.59 ± 1.12	<.001

Figure Legends

Figure 1: Single 300° arc length Ferrara-type AFR5 intrastromal corneal ring segment (ICRS) (AJL Ophthalmic) implanted in one case. An incision was performed at the 12-o'clock position and the ICRS was implanted with its midpoint positioned at 270°.

Figure 2: Variation in corrected distance visual acuity (CDVA) 6 months after intrastromal corneal ring segment (ICRS) implantation (safety) for (A) the whole sample, (B) eyes with a preoperative CDVA worse than 0.3 logMAR, and (C) eyes with a preoperative CDVA of 0.3 logMAR or better.

Figure 3: Distribution of mean keratometric (Kmean) values preoperatively and 6 months postoperatively. ICRS = intrastromal corneal ring segments; D = diopters

Fig 1

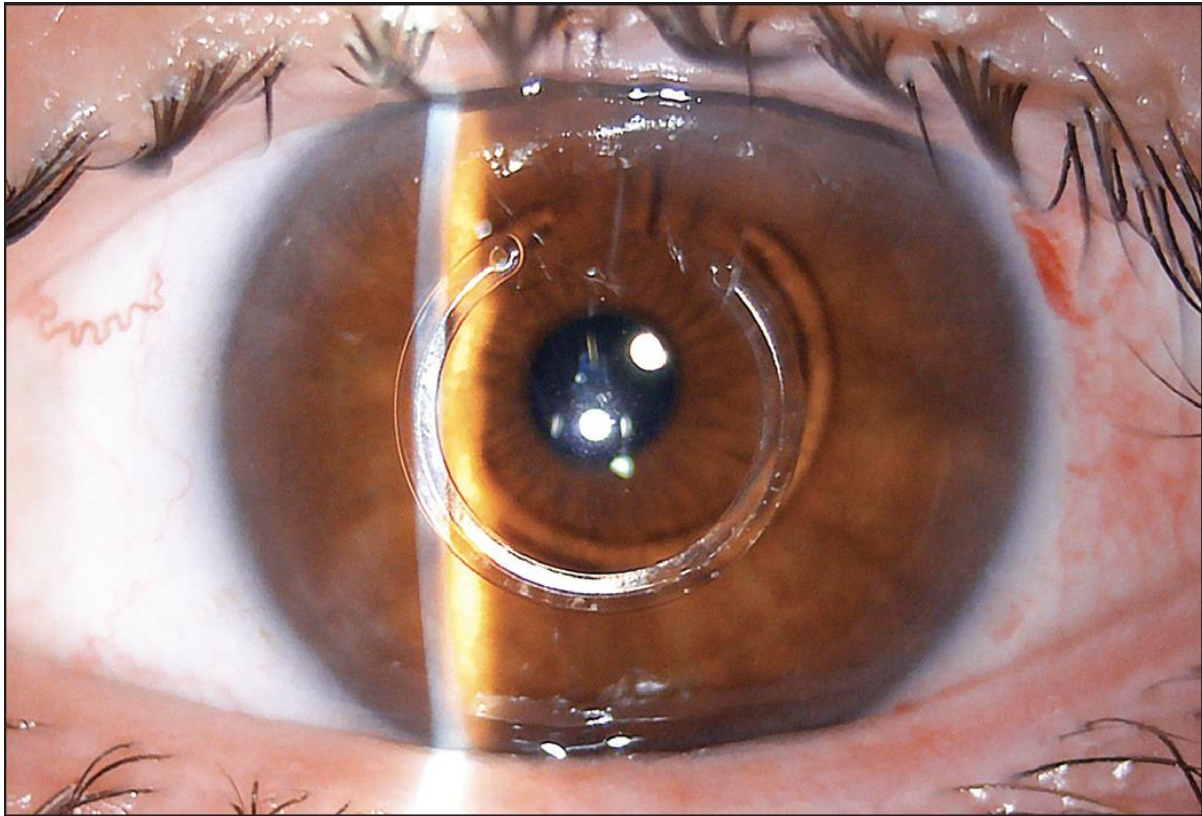


Fig 2

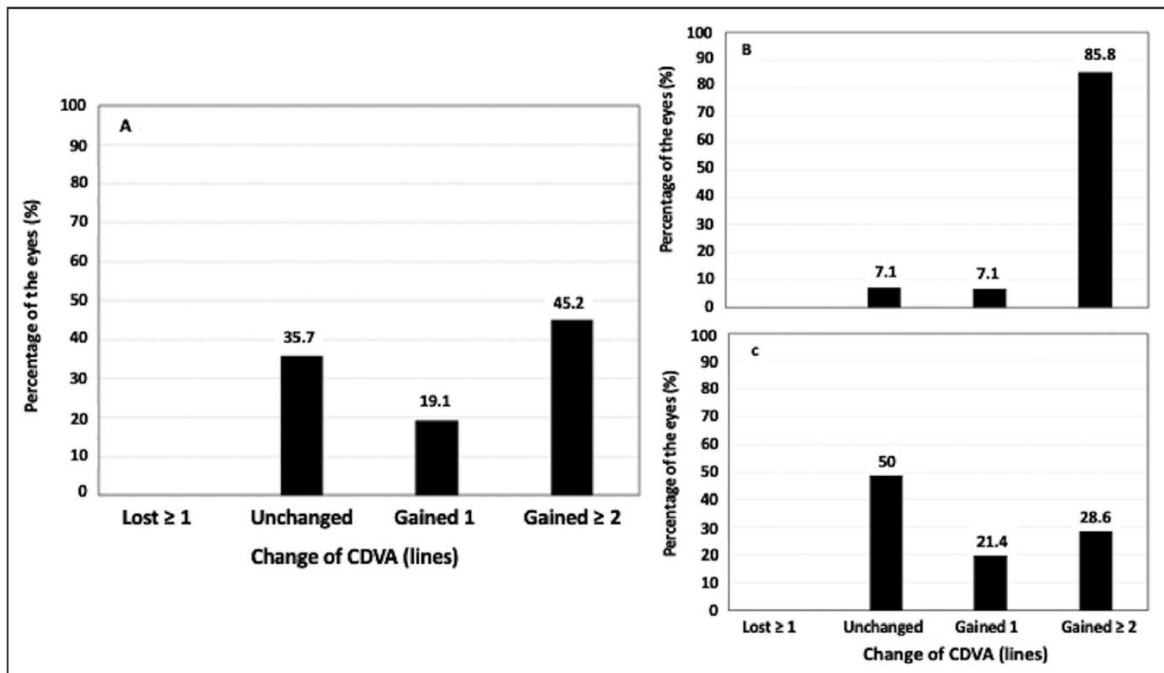


Fig 3

