

## Medusa-like retinoblastoma vasculature

S. Lemaitre, R. Anguita, M.S. Sagoo & M.A. Reddy

A 17-month-old female presented with right leukocoria. On right eye examination intraocular pressure was 24 mmHg, with iris neovascularisation; fundus showed a diffuse white intraocular mass (figure 1) with calcification on ultrasonography. On fluorescein angiography the tumour vasculature had an unusual vasculature giving a 'medusa-like' appearance (figure 2), with no retinal telangiectasia and leakage which ruled out Coats disease. Diagnosis was non-familial unilateral retinoblastoma (AJCC 8<sup>th</sup> Ed cT3c) and the eye was enucleated. Histology confirmed this diagnosis. Genetic studies found a normal karyotype and *RB1* mutations (exon 8 2bp deletion and *RB1* deletion) were present in the tumour but not in the blood.

Fig 1 Right fundus showing a diffuse white retinal mass.

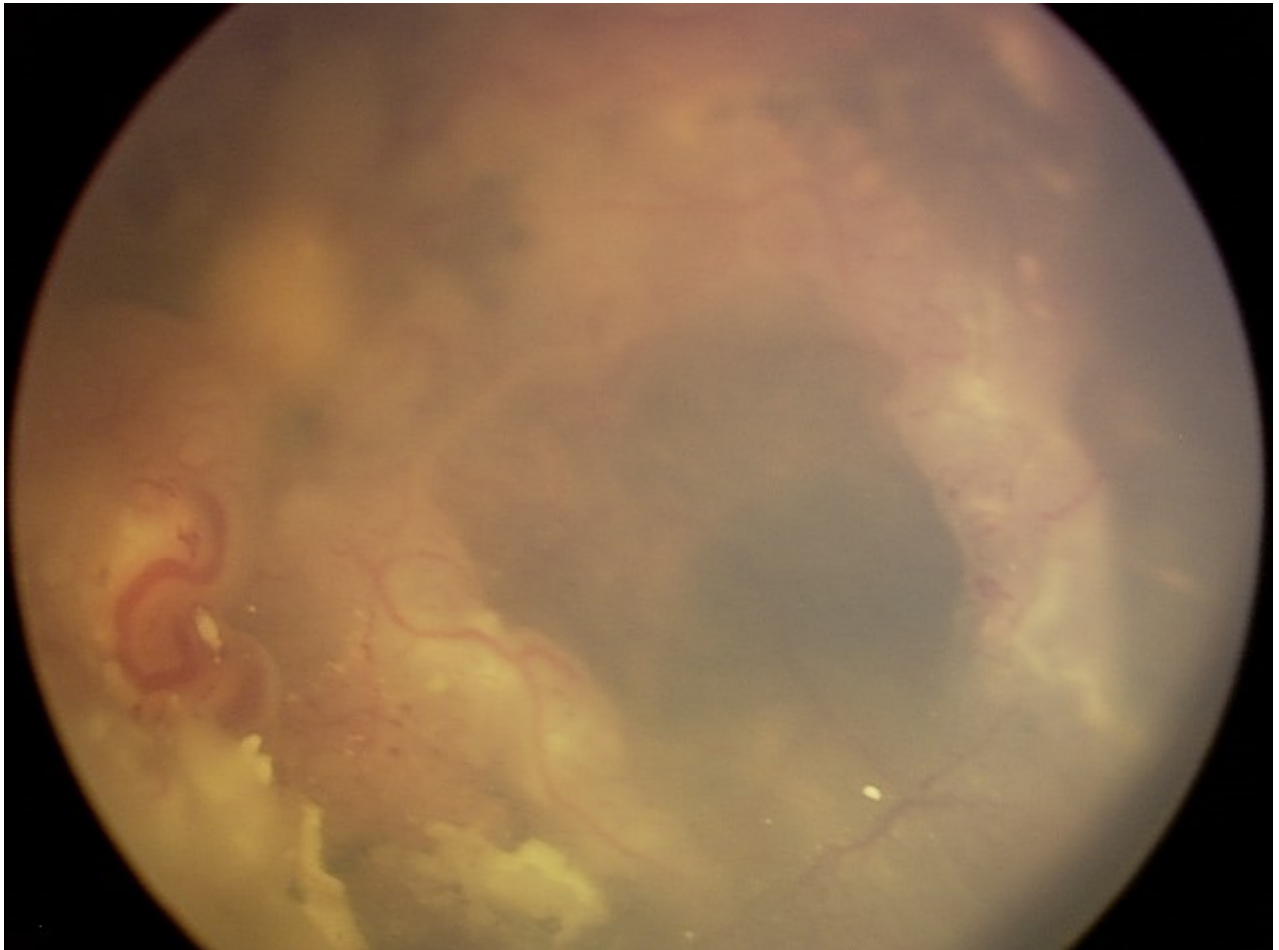


Fig 2 "Medusa" tumour vasculature on the fluorescein angiogram.

