



Open Access

INVITED OPINION

Prostate Cancer

Funneling of the bladder neck - radiological appearance after radical retropubic prostatectomy and clinical relevance

Simon Bugeja, Anastasia Frost, Stella Ivaz, Felix Campos, Daniela E Andrich, Anthony R Mundy

Asian Journal of Andrology (2020) 22, 152–153; doi: 10.4103/aja.aja_73_19; published online: 9 July 2019

Several authors have commented on the anatomical changes following radical prostatectomy (RP) for prostate cancer and their characteristic radiological appearances.^{1,2} Most of these relate to periurethral fibrosis and its clinical significance in patients with postprostatectomy sphincter weakness incontinence.^{3,4} On magnetic resonance imaging (MRI), this postsurgical fibrosis appears as a focus of low-signal intensity in the periurethral tissues at and around the level of the vesicourethral anastomosis (VUA) which is appreciable on both T1- and T2-weighted images.

Another finding on MRI and fluoroscopy has become apparent to us in patients post-RP. We describe this radiological appearance as “funneling of the bladder neck,” and to the best of our knowledge, this has not been previously reported in the literature. In this contribution, we characterize this radiological observation and explain its clinical relevance in the interpretation of radiological imaging in patients following RP, particularly those with a bladder neck contracture (BNC). We outline the role these postsurgical anatomical changes impact the surgical management of these said contractures.

RADIOLOGICAL APPEARANCE

Prior to RP, the bladder base (and prostate) appears flat and well-supported by a well-developed levator sling (**Figure 1a**) on MRI. Following prostatectomy, the bladder base no longer appears flat, but has a typical “funnel-shaped” appearance as demonstrated

in **Figure 1b**. We postulate that the most likely explanation for the occurrence of funneling is that two relatively fixed structures are drawn together to perform an anastomosis. The bladder is fixed to the pelvic sidewall by its lateral pedicles. Consequently, during prostatectomy, the bladder base must be drawn downward (to occupy the space vacated by the prostate) toward the membranous urethra, which is also fixed, at the perineal membrane, when fashioning the anastomosis. The bladder base therefore comes to lie within the levator sling giving rise, we suggest, to the characteristic funneled appearance.

We have looked at 106 post-RP MRIs to determine the incidence of this funneled radiological appearance and found that on T2-weighted images in the coronal plane, this was present in 81 (76.4%) cases.⁵ In the same study, we also looked at retrograde and antegrade urethrograms of patients with proven BNC undergoing surgical correction, providing the opportunity to correlate the radiological findings with direct visualization of the anatomy during surgical exploration. “Funneling,” as demonstrated in **Figure 1c**, was appreciated in 16 of these 19 (84.2%) patients. As this example shows, it was often impossible to make a diagnosis of BNC on imaging alone, and endoscopy was usually necessary to confirm the diagnosis. Only occasionally was it possible to determine the anatomical details of the bladder outlet by imaging alone (**Figure 1d**), albeit with endoscopic confirmation.

CLINICAL RELEVANCE

The appearance described is a radiological one. Nevertheless, this observation does have important clinical implications, particularly in the assessment of BNC following prostatectomy.

In the majority of cases, BNCs originate following a problem in the region of the vesicourethral anastomosis in the early postoperative period, such as a significant urinary leak or pelvic hematoma or a combination of the two.^{6,7} Healing by secondary intention results in fibrosis giving rise to the contracture. In the presence of funneling of the bladder neck, postoperative urinomas/hematomas would not be limited solely to the anastomotic site, but would tend to extend more cranially to surround part or all of the funneled segments. Therefore, the resulting periurethral scarring and fibrosis would progressively involve a longer segment than that would be expected if funneling did not occur.

In the above-mentioned study,⁵ there were three of the 19 cases with BNC, in which funneling of the bladder neck was not apparent on fluoroscopy. Nonetheless, all three of these urethrograms showed extensive contractures (**Figure 1e**) which were confirmed during surgical revision. In these cases, the entire funnel appears to have become obliterated by the fibrotic process. Consequently, failure to demonstrate radiological funneling is actually an extreme variant of the observation rather than its apparent absence.

Most postprostatectomy BNCs are initially managed endoscopically by dilatation, bladder neck incision, or resection.⁸ The extensive nature of some of these contractures resulting from the proximal extension of the fibrosis retrogradely up the funneled bladder neck may explain the high recurrence rate following these minimally invasive approaches such as incision or resection. Surgical revision of the VUA (with excision of all the scar tissues) is the only curative treatment for these patients. Such surgery is often a technically challenging

University College London Hospitals, NHS Foundation Trust, Reconstructive Urology Unit, London NW1 2PG, UK.

Correspondence: Dr. S Bugeja (simbugi@gmail.com)

Received: 10 January 2019; Accepted: 21 May 2019

procedure. Even in the absence of changes due to radiotherapy, the dissection needs to be taken deep into the perineum (**Figure 2**) to excise the extensively scarred and fibrotic funneled segment that constitutes the BNC until a relatively healthy neobladder neck/bladder base can be defined. Wedge pubectomy is almost always necessary to provide access and exposure, since following prostatectomy, the VUA lies anteriorly in the perineum, almost disappearing under the pubic symphysis.

Contrast studies are the most common imaging modality used in the preoperative evaluation in patients with BNCs. This funneled appearance of the bladder neck makes the identification of individual anatomical landmarks difficult. It also makes it difficult to localize the exact site of a contracture (true anastomotic, anastomotic with involvement of a funneled bladder neck, sphincteric,

proximal bulbar, or a combination of these) as demonstrated in **Figure 1c** and **1d**. It is particularly difficult to distinguish between the normal sphincter-active urethra which is seen to open up on a descending study, as opposed to a sphincter stricture below a funneled bladder neck which is rigid and therefore does not distend. Both antegrade and retrograde urethrography are therefore essential in evaluating this region. Even so, endoscopic assessment is almost always necessary to determine the site and extent of a contracture.

It is very difficult to look at the relationship between the radiological appearance and the presence of postprostatectomy incontinence in patients with BNC, because sphincter function is almost always compromised by the presence of the BNC (all patients are either incontinent or have obliterative contractures and are

therefore unable to void urethrally) and even more so by the subsequent surgery.

A typical “funnel-shaped” appearance of the bladder neck is a common radiological observation after RP and distinguishing individual anatomical structures relating to the bladder base, VUA, and membranous and proximal bulbar urethra on MRI and urethrography is difficult on routine postoperative imaging. Funneling of the bladder neck may make localizing the exact position of a BNC problematic when planning reconstructive surgery in these patients.

The funneled area is often part of the BNC to a degree that is impossible to determine except at open surgical revision. This might explain the extensive nature of some of these contractures and why they are so often refractory to endoscopic management. It might also explain why surgery to revise the VUA in patients with postprostatectomy contractures is often a technically challenging undertaking.

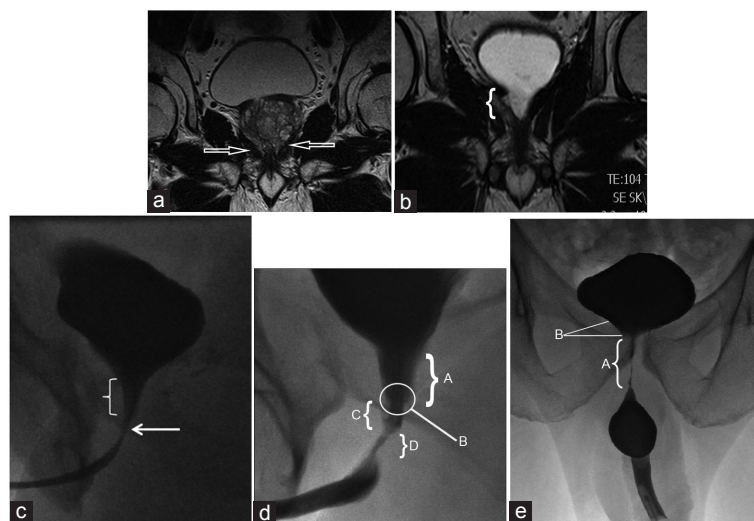


Figure 1: (a) Preoperative MRI – flat and well-supported appearance of the bladder base. Well-developed levator sling (arrows). (b) Postprostatectomy MRI – typical tapered, funneled appearance of the bladder neck. (c) Typical fluoroscopic appearance of a funneled bladder neck after RP with the vesicourethral anastomosis just below it (arrow). (d) Descending urethrogram showing a funneled bladder neck (A) which is contracted and rigid down to the anastomosis (B) and across into the membranous urethra (C) and the proximal part of the urethral sphincter (D). (e) Funneling of the bladder neck not so prominent because the entire funnel is obliterated by the fibrosis giving rise to an extensive contracture (A). Close examination actually shows the proximal end of the funnel terminating abruptly at the proximal end of the contracture (B). RP: radical prostatectomy; MRI: magnetic resonance imaging.

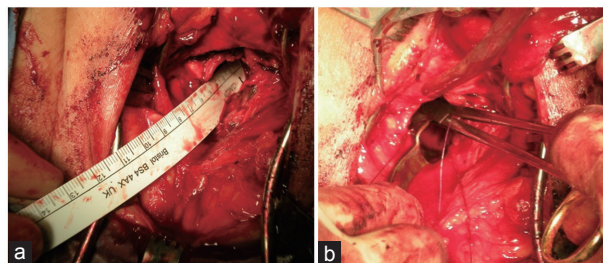


Figure 2: Redo vesicourethral anastomosis. (a) The neobladder neck lies deep in the perineum (12 cm from skin level in this case) after excising the extensive “funneled” bladder neck contracture. (b) Consequently fashioning the anastomosis at that depth is technically very difficult.

REFERENCES

- Allen SD, Thompson A, Aslam Sohaib S. The normal post-surgical anatomy of the male pelvis following radical prostatectomy as assessed by magnetic resonance imaging. *Eur Radiol* 2008; 18: 1281–91.
- Summers RM, Korobkin M, Quint LE, Ellis JH, Grossman HB, et al. Pelvic CT findings after radical prostatectomy. *J Comput Assist Tomogr* 1993; 17: 767–71.
- Kordan Y, Alkibay T, Sozen S, Bozkurt Y, Acar C, et al. Is there an impact of postoperative urethral and periurethral anatomical features in post-radical retropubic prostatectomy incontinence? *Urol Int* 2007; 78: 208–13.
- Tuygun C, Imamoglu A, Keyik B, Alisir I, Yorubulut M. Significance of fibrosis around and/or at external urinary sphincter on pelvic magnetic resonance imaging in patients with postprostatectomy incontinence. *Urology* 2006; 68: 1308–12.
- Bugeja S, Chaudhury I, Andrich DE. Funneling of the bladder neck after radical retropubic prostatectomy – radiological appearance and clinical relevance. *J Urol* 2013; 189: e155.
- Huang G, Lepor H. Factors predisposing to the development of anastomotic strictures in a single-surgeon series of radical retropubic prostatectomies. *BJU Int* 2006; 97: 255–8.
- Webb DR, Sethi K, Gee K. An analysis of the causes of bladder neck contracture after open and robot-assisted laparoscopic radical prostatectomy. *BJU Int* 2009; 103: 957–63.
- Anger JT, Raj GV, Delvecchio FC, Webster GD. Anastomotic contracture and incontinence after radical prostatectomy: a graded approach to management. *J Urol* 2005; 173: 1143–6.

This is an open access journal, and articles are distributed under the terms of the Creative Commons Attribution-NonCommercial-ShareAlike 4.0 License, which allows others to remix, tweak, and build upon the work non-commercially, as long as appropriate credit is given and the new creations are licensed under the identical terms.

©The Author(s)(2019)

