



OPEN LETTER

REVISED Checklists to guide the supportive and critical care of tuberculous meningitis [version 2; peer review: 2 approved]Joseph Donovan ^{1,2}, Ursula K. Rohlwink ³, Elizabeth W. Tucker ⁴⁻⁶,
Nguyen Thi Thu Hiep¹, Guy E. Thwaites ^{1,2}, Anthony A. Figaji ³,
Tuberculous Meningitis International Research Consortium¹Oxford University Clinical Research Unit, Centre for Tropical Medicine, Ho Chi Minh City, Vietnam²Centre for Tropical Medicine and Global Health, Nuffield Department of Medicine, University of Oxford, Oxford, UK³Neuroscience Institute and Division of Neurosurgery, University of Cape Town, Cape Town, 7700, South Africa⁴Department of Anesthesiology and Critical Care Medicine, Johns Hopkins University School of Medicine, Baltimore, MD, 21287, USA⁵Division of Pediatric Critical Care, Johns Hopkins All Children's Hospital, St. Petersburg, FL, USA⁶Center for Tuberculosis Research, Johns Hopkins University School of Medicine, Baltimore, MD, 21287, USA**V2** First published: 31 Oct 2019, 4:163
<https://doi.org/10.12688/wellcomeopenres.15512.1>Latest published: 07 Feb 2020, 4:163
<https://doi.org/10.12688/wellcomeopenres.15512.2>**Abstract**

The assessment and management of tuberculous meningitis (TBM) is often complex, yet no standardised approach exists, and evidence for the clinical care of patients, including those with critical illness, is limited. The roles of proformas and checklists are increasing in medicine; proformas provide a framework for a thorough approach to patient care, whereas checklists offer a priority-based approach that may be applied to deteriorating patients in time-critical situations. We aimed to develop a comprehensive assessment proforma and an accompanying 'priorities' checklist for patients with TBM, with the overriding goal being to improve patient outcomes. The proforma outlines what should be asked, checked, or tested at initial evaluation and daily inpatient review to assist supportive clinical care for patients, with an adapted list for patients in critical care. It is accompanied by a supporting document describing why these points are relevant to TBM. Our priorities checklist offers a useful and easy reminder of important issues to review during a time-critical period of acute patient deterioration. The benefit of these documents to patient outcomes would require investigation; however, we hope they will promote standardisation of patient assessment and care, particularly of critically unwell individuals, in whom morbidity and mortality remains unacceptably high.

Keywords

Tuberculous meningitis, critical care, checklist, proforma

Open Peer Review**Reviewer Status**

Invited Reviewers

1

2

version 2(revision)
07 Feb 2020**version 1**

31 Oct 2019

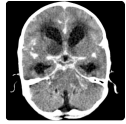


report



report

1. **Abdu Kisekka Musubire** , Makerere
University, Kampala, Uganda2. **Rakesh K. Gupta**, Fortis Memorial Research
Institute, Gurgaon, IndiaAny reports and responses or comments on the
article can be found at the end of the article.



This article is included in the [Tuberculous Meningitis International Research Consortium](#) collection.

Corresponding author: Joseph Donovan (jdonovan@oucru.org)

Author roles: **Donovan J:** Conceptualization, Writing – Original Draft Preparation, Writing – Review & Editing; **Rohlwink UK:** Conceptualization, Writing – Original Draft Preparation, Writing – Review & Editing; **Tucker EW:** Conceptualization, Writing – Original Draft Preparation, Writing – Review & Editing; **Hiep NTT:** Conceptualization, Writing – Original Draft Preparation, Writing – Review & Editing; **Thwaites GE:** Conceptualization, Writing – Original Draft Preparation, Writing – Review & Editing; **Figaji AA:** Conceptualization, Writing – Original Draft Preparation, Writing – Review & Editing;

Competing interests: No competing interests were disclosed.

Grant information: This work was supported by the Wellcome Trust through an Investigator Award to Professor Guy Thwaites [110179]. This work was supported by the Wellcome Trust through funding to the Tuberculous Meningitis International Research Consortium. *The funders had no role in study design, data collection and analysis, decision to publish, or preparation of the manuscript.*

Copyright: © 2020 Donovan J *et al.* This is an open access article distributed under the terms of the [Creative Commons Attribution License](#), which permits unrestricted use, distribution, and reproduction in any medium, provided the original work is properly cited.

How to cite this article: Donovan J, Rohlwink UK, Tucker EW *et al.* **Checklists to guide the supportive and critical care of tuberculous meningitis [version 2; peer review: 2 approved]** Wellcome Open Research 2020, 4:163 <https://doi.org/10.12688/wellcomeopenres.15512.2>

First published: 31 Oct 2019, 4:163 <https://doi.org/10.12688/wellcomeopenres.15512.1>

REVISED Amendments from Version 1

Under respiratory monitoring we have added here that pneumothorax is rare in PJP (with a reference).

In [Table 4](#) we have added 'preferably with contrast' in reference to brain imaging.

In [Table 4](#) we have specifically mentioned IRIS and cerebral sinus thrombosis. In the supporting document we have added the sentence 'Cerebral venous thrombosis is an unusual cause of acute neurological deterioration in TBM, but has been described' with references.

Regarding risks of prolonged hospital admission, we have added 'Deep vein thrombosis is a risk of prolonged critical care admission'

Any further responses from the reviewers can be found at the end of the article

Disclaimer

The views expressed in this article are those of the authors. Publication in Wellcome Open Research does not imply endorsement by Wellcome.

Abbreviations

AFB, acid-fast bacilli; ALT, alanine transaminase; ART, anti-retroviral therapy; AST, aspartate aminotransferase; BCG, Bacillus Calmette Guerin; CO₂, carbon dioxide; CBF, cerebral blood flow; CPP, cerebral perfusion pressure; CRP, C-reactive protein; CSF, cerebrospinal fluid; CSW, cerebral salt wasting; CT, computed tomography; CVP, central venous pressure; ESR, erythrocyte sedimentation rate; ETCO₂, end-tidal carbon dioxide; ETV, endoscopic third ventriculostomy; EVD, external ventricular drainage; GCS, Glasgow coma scale; HIV, human immunodeficiency virus; ICP, intracranial pressure; ICU, intensive care unit; INR, international normalised ratio; IVC, inferior vena cava; MAP, mean arterial pressure; MRI, magnetic resonance imaging; NIRS, near-infrared spectroscopy; ONSD, optic nerve sheath diameter; PbtO₂, brain tissue oxygen tension monitoring; SIADH, syndrome of inappropriate diuretic hormone secretion; TB, tuberculosis; TBI, traumatic brain injury; TBM, tuberculous meningitis; TCD, transcranial Doppler; VP, ventriculoperitoneal

Introduction

Tuberculous meningitis (TBM) is the most severe form of tuberculosis (TB) and causes critical illness from direct neurological injury or complications from the infection, treatment, or prolonged hospitalisation.

Due to serious complications, the management of TBM is complex, and includes supportive medical and neurosurgical measures. Currently there are no guidelines or standardised approach for the assessment and management of TBM. This is due to limited literature to develop an evidence-based approach, and because each TBM patient is unique. However, common themes exist, and a comprehensive proforma to guide patient assessment could be the first step towards standardised management.

Checklists can be powerful tools to focus attention¹ and their use in the medical field is growing²⁻⁴. We aimed to develop a comprehensive proforma for the assessment and management of TBM as well as a priorities checklist for the decompensating patient. The document cannot account for every scenario, but is designed to identify priorities; i.e. potentially reversible factors that contribute to morbidity and mortality. Local modifications to increase uptake and tailor use to suit local needs are encouraged.

Accompanying our proforma and checklist is the rationale for why these assessments may be important. Importantly, this article is not a guideline and does not make recommendations for care. It is not intended to replace a comprehensive ward round, nor to increase the clinical workload. Instead, it should provide a framework to highlight vital components during different stages of TBM care, with many complications overlapping throughout illness. We acknowledge that investigations and procedures will not be available at all centres.

Comprehensive proforma

The comprehensive proforma is split into initial evaluation ([Table 1](#)), daily inpatient review ([Table 2](#)), and critical care in the intensive care unit (ICU) ([Table 3](#)). However, as elements can occur at any time, the rationale is grouped by themes within sections titled "General supportive and critical care" and "Neurocritical care".

General supportive and critical care**History of present illness**

Obtaining a thorough history of the patient's signs and symptoms is paramount ([Table 1](#) and [Box 1](#)).

Box 1. Key predictors of poor outcome in tuberculous meningitis

Increased Medical Research Council TBM disease severity⁵⁻⁸
 Reduced consciousness^{6,9}
 Hydrocephalus and raised ICP^{8,10,11}
 Cerebral infarction^{6,12}
 Seizures^{12,13}
 HIV co-infection^{9,14}
 Multidrug resistant, or isoniazid mono-resistant, disease¹⁵
 Lower body weight⁵
 Younger and older age^{5,16}

General clinical examination and monitoring

General assessment and non-invasive monitoring of vital signs may be the only tools available to guide patient management in many centres. These provide valuable information in all care settings, and are mentioned in [Table 1–Table 4](#).

Respiratory monitoring. A change in neurological status may cause hypoxia due to airway compromise, and pulse oximetry may raise the alarm. Chest X-rays can help diagnose pulmonary TB,

Table 1. Initial evaluation.

Category	Specific question or assessment	✓
History		
	Age	
	Presenting complaints and duration (i.e., headache, irritability, vomiting, fever, neck stiffness, seizures, altered consciousness, lethargy, developmental regression, weight loss, night sweats, cough)	
	Other respiratory symptoms	
	Previous treatment for tuberculosis	
	BCG immunisation	
	History of recent TB contact	
	Other previous illnesses or comorbidities	
	If HIV positive: - Date of diagnosis, treatment history, treatment adherence, recent CD4 and HIV viral load values	
General clinical examination		
	Weight and nutritional status	
	Vital signs (i.e., oxygen saturation, heart rate, blood pressure, temperature)	
	Hydration status (i.e., fluid input and output, clinical signs of dehydration)	
	Evidence of tuberculosis elsewhere (e.g., lung, lymph nodes)	
	BCG scar	
Neurological examination		
	Level of consciousness (i.e., GCS, modified for infants)	
	Pupillary exam (shape, size and reaction to light)	
	Assess for papilloedema by fundoscopy	
	Focal neurological deficits (i.e., cranial nerve palsies, hemiplegia, paraplegia, tetraplegia, urinary retention)	
	Head circumference and fontanelle in children	
CSF examination (lumbar or ventricular)		
	Opening pressure (immediately with needle insertion at lumbar puncture)	
	General appearance (i.e. colour, turbidity)	
Laboratory tests (CSF)		
	Lumbar or ventricular?	
	AFB smear	
	NAAT (e.g., GeneXpert)	
	Mycobacterial culture and drug susceptibility testing	
	White cell count (i.e., total and cell differential)	
	Protein	
	Glucose (paired with blood glucose)	
	Lactate	
Laboratory tests (blood)		
	Full blood count (i.e., haemoglobin, white blood cell count, platelets)	
	Non-specific inflammatory markers (i.e., ESR, CRP)	
	Electrolyte and renal function panel (i.e., sodium, potassium, glucose, creatinine, urea)	
	Liver function panel (i.e., ALT, AST, bilirubin)	
	Coagulation panel (i.e., INR, PTT)	
	HIV test (if positive, CD4 count and HIV viral load)	
	Serum osmolality (if hyponatraemia)	
Laboratory tests (urine)		
	Urine sodium (if hyponatraemia)	
	Urine osmolality (if hyponatraemia)	

Category	Specific question or assessment	✓
Imaging		
	Chest X-ray	
	Brain and/or spine (i.e. CT or MRI)	
Intracranial pressure measurement		
	Intermittent measurements (i.e., lumbar puncture)	
	Continuous measurements (i.e., invasive monitoring with/ without drain)	
	Assessment for communicating hydrocephalus with air encephalogram or column test	
	Non-invasive estimates of ICP	

AFB, acid-fast bacilli; ALT, alanine transaminase; AST, aspartate aminotransferase; BCG, Bacillus Calmette Guerin; CRP, C-reactive protein; CSF, cerebrospinal fluid; CT, computed tomography; ESR, erythrocyte sedimentation rate; GCS, Glasgow coma scale; HIV, human immunodeficiency virus; INR, international normalised ratio; MRI, magnetic resonance imaging; NAAT, nucleic acid amplification test; PTT, prothrombin time; TB, tuberculosis.

'✓' can be selected when a proforma question has been answered, or a proforma point has been reviewed or tested.

Table 2. Daily inpatient review.

Category	Specific question or assessment	✓
General clinical examination		
	Weight and nutritional status (i.e., use of oral feeds, intravenous fluids, etc.)	
	Monitor for vomiting/inability to take drugs orally	
	Monitor for gastrointestinal bleeding	
	Vital signs (i.e., oxygen saturation, heart rate, blood pressure, temperature)	
	Hydration status (i.e., fluid input and output, clinical signs of dehydration, CVP, IVC ultrasound)	
Medication evaluation		
	Have any doses of anti-TB chemotherapy been missed?	
	Monitor for side effects from anti-TB chemotherapy	
	Check drug susceptibility testing results. Are changes to anti-TB chemotherapy required?	
	Monitor recent liver function and renal function panels for medication toxicity	
	Repeat liver function and renal function panels if toxicity concerns remain	
	Check corticosteroid dose	
	Schedule corticosteroid taper (i.e., when to reduce the dose)	
Neurological examination		
	Level of consciousness (i.e., GCS, modified for infants)	
	Assess for papilloedema by fundoscopy	
	Focal neurological deficits (i.e., cranial nerve palsies, hemiplegia, paraplegia, tetraplegia, urinary retention)	
	Has there been a change in examination since last review? If so, what is the suspected cause?	
	Does the patient need repeat neuroimaging?	
Laboratory tests (blood)		
	Repeat complete full blood count and inflammatory markers (i.e., if concern for other infection)	
	Repeat electrolyte and renal function panel (i.e., sodium, potassium, glucose, creatinine, urea) if change in hydration status	
	Repeat liver function panel (i.e., ALT, AST, bilirubin) if change in medications	
	Repeat serum osmolality if change in hydration status or new/worsening hyponatraemia	
Laboratory tests (urine)		
	Urine sodium if change in hydration status	
	Urine osmolality if change in hydration status	

ALT, alanine transaminase; AST, aspartate aminotransferase; CSF, cerebrospinal fluid; CVP, central venous pressure; GCS, Glasgow coma scale; IVC, inferior vena cava; TB, tuberculosis.

'✓' can be selected when a proforma question has been answered, or a proforma point has been reviewed or tested.

Table 3. Critical care.

Category	Specific question or assessment	✓
General clinical examination		
	Weight and nutritional status (i.e., use of oral feeds, intravenous fluids, etc.)	
	Monitor for vomiting/inability to take drugs orally	
	Monitor for gastrointestinal bleeding	
	Vital signs (i.e., oxygen saturation, heart rate, blood pressure, temperature)	
	Hydration status (i.e., fluid input and output, clinical signs of dehydration)	
	Monitor skin for pressure damage	
Medication evaluation		
	Have any doses of anti-TB chemotherapy been missed?	
	Monitor for side effects from anti-TB chemotherapy	
	Check drug susceptibility testing results. Are changes to anti-TB chemotherapy required?	
	Monitor recent liver function and renal function panels for medication toxicity	
	Repeat liver function and renal function panels if toxicity concerns remain	
	Check corticosteroid dose	
	Schedule corticosteroid taper (i.e., when to reduce the dose)	
Vascular access		
	Is central venous access still needed?	
	Is central venous access functioning properly?	
	Are there signs/symptoms of central line-associated blood stream infection?	
	Is invasive blood pressure monitoring (arterial line) still needed?	
Urinary catheter		
	Is the urinary catheter still needed?	
	Are there signs/symptoms of catheter-associated urinary tract infection?	
Respiratory examination		
	Monitor respiratory examination	
	Monitor ventilation with end tidal CO ₂ monitoring (if available)	
	Monitor ventilation and oxygenation with arterial blood gas sampling (if available)	
	Monitor and adjust mechanical ventilation settings/modes	
	Are there signs/symptoms of ventilator-associated pneumonia?	
	Repeat chest X-ray if ventilator-associated pneumonia suspected	
	Can removal of endotracheal tube be considered?	
Neurological examination		
	Follow up neurosurgical consultation (if applicable)	
	Level of consciousness (i.e., GCS, modified for infants) – is sedation required?	
	Has there been a change in examination since last review?	
	Assess for papilloedema by fundoscopy	
	Focal neurological deficits (i.e., cranial nerve palsies, hemiplegia, paraplegia, tetraplegia, urinary retention)	
	Is repeat neuroimaging needed?	

Category	Specific question or assessment	✓
Intracranial pressure optimisation		
	Optimise head-of-bed elevation	
	Ensure appropriate sedation/analgesia	
	Check for fevers (if applicable, treat)	
	Check for appropriate blood pressure to determine cerebral perfusion pressure (if ICP is known)	
	Is continuous monitoring required (i.e., continuous parenchymal ICP or EVD)?	
	Consider non-invasive measures for evaluating ICP and brain perfusion	
Post-operative neurosurgical management		
	Monitor for changes in neurological exam	
	Monitor surgical wound for infection	
	Is repeat neuroimaging required (to check VP shunt or EVD placement)?	
	Plan for suture removal	
	If an EVD is <i>in situ</i> , check the level and check the drainage	
Laboratory tests (blood)		
	Repeat complete full blood count and inflammatory markers (i.e., if concern for other infection)	
	Repeat electrolyte and renal function panel (i.e., sodium, potassium, glucose, creatinine, urea) if change in hydration status	
	Repeat liver function panel (i.e., ALT, AST, bilirubin) if change in medications	
	Repeat serum osmolality if change in hydration status or new/worsening hyponatraemia	
Laboratory tests (urine)		
	Urine sodium if change in hydration status	
	Urine osmolality if change in hydration status	

ALT, Alanine transaminase; AST, aspartate aminotransferase; CBF, cerebral blood flow; EVD, external ventricular drain; GCS, Glasgow coma scale; ICP, intracranial pressure; TB, tuberculosis; VP, ventriculoperitoneal.

'✓' can be selected when a proforma question has been answered, or a proforma point has been reviewed or tested.

Table 4. Priorities checklist for the acutely deteriorating patient with TBM.

	Reviewed
Reduced consciousness	
- Has the patient developed hydrocephalus, infarcts, cerebral venous thrombosis, or possible mass effect from tuberculomas, TB abscesses or IRIS? (consider repeat brain imaging [preferably with contrast], ICP monitoring)	
- Is the EVD or VP shunt working? (if applicable check EVD drainage, consider repeat imaging for VP shunt)	
- Is urgent neurosurgery required?	
- Have seizures been excluded?	
- Does serum glucose need correcting?	
- Does serum sodium need correcting?	
- Is there hypotension?	
Systemically unwell	
- Is supplemental oxygen required?	
- Are serum liver function tests elevated?	
- Do large urine outputs suggest hypovolaemia?	
- Is there gastrointestinal bleeding?	
- Are there signs of new infection?	

EVD, external ventricular drain; ICP, intracranial pressure; IRIS: immune reconstitution inflammatory syndrome; TBM, tuberculous meningitis; VP, ventriculoperitoneal.

Check box for each checklist question when that question has been reviewed.

and in HIV co-infected patients with *Pneumocystis jirovecii*, pneumothorax, although this is rare¹⁷.

Heart rate monitoring. Bradycardia may be caused by raised intracranial pressure (ICP) or brainstem ischaemia, and the development of tachycardia or bradycardia could indicate new infection or hypovolemia.

Blood pressure monitoring. Blood pressure monitoring may detect septic shock or cerebral salt wasting (CSW)-associated hypotension. It may also help calculate cerebral perfusion pressure (CPP).

Temperature monitoring. Fever is associated with worse outcomes in neurocritical care and an increased one-year mortality in HIV-uninfected individuals with TBM⁹. Pyrexia may indicate superimposed bacterial infection.

Medication evaluation and management

Important characteristics to monitor for anti-TB chemotherapy are described below and in [Table 2](#).

Anti-tuberculosis chemotherapy. The optimum delivery of essential anti-TB chemotherapy is a priority, but optimal doses and administration routes are unknown¹⁸. Prompt treatment and avoidance of therapy interruptions are essential to reduce mortality, and in unconscious patients, crushed medication administered via nasogastric tube, or intravenous therapy, may be considered^{18,19}.

Anti-TB chemotherapy can change during the long duration of treatment. Regimen modifications may be necessitated by drug resistance, changes in weight, interactions with cytochrome P450-inhibiting anti-retroviral therapy (ART), and drug side effects, many of which cause and exacerbate critical illness¹⁸. Rifampicin, isoniazid, pyrazinamide and fluoroquinolones can cause liver injury; therefore, regular monitoring of alanine transaminase (ALT), aspartate aminotransferase (AST), and bilirubin is important. Optimal management of drug-induced liver injury in TBM is unknown and is currently being studied^{20,21}.

Nutrition and the gastrointestinal tract

TB causes a chronic catabolic illness and patients commonly present with weight loss or failure to thrive in children. Additionally, TBM patients are at risk of the negative consequences of the catabolic stress of critical illness²². Controlling glycaemia may be complicated by corticosteroids, which increase serum glucose. Nutrition in TBM often requires nasogastric tube placement when consciousness is reduced. Maintaining adequate nutrition is important to provide substrate for healing. Early feeding and avoidance of hypoglycaemia may improve outcomes after acute brain injury²³, but has not been studied in TBM.

Multidrug regimens, corticosteroids and anti-platelet drugs can lead to gastrointestinal intolerance and bleeding²⁴. Gastrointestinal bleeding may cause hypovolaemia and exacerbate reduced cerebral perfusion. Nausea and vomiting, common side effects of anti-TB chemotherapy, may further contribute to

hypovolaemia. Aspiration of vomited gastric contents is a risk when consciousness is impaired. See [Table 1](#) and [Table 2](#).

Kidney function, fluid balance, and electrolytes

Kidney function. Acute dehydration may place patients at risk for hypovolemia and prerenal acute kidney injury. Chronic use of anti-TB chemotherapy may be nephrotoxic^{25,26}. Obtaining baseline kidney function tests, including creatinine and urea, may identify those at risk of acute or chronic kidney injury. Changes in urine output or fluid balance may precede laboratory abnormalities. See [Table 1](#) and [Table 2](#).

Hyponatraemia and fluid balance. Fluid balance is an important distinguishing parameter between the causes of hyponatremia (sodium <135mmol/L). Central venous pressure (CVP) reflects the intravascular volume and helps determine hydration status. CVP can be measured continuously or intermittently from a central venous catheter most often placed in the internal jugular vein or femoral vein if they are available. CSW is often characterised by high volume urine output, hypovolemia with low CVP, clinical signs of dehydration (dry mucous membranes, delayed capillary refill time, tachycardia, and hypotension) and haemoconcentrated laboratory parameters (elevated haematocrit, haemoglobin or urea)²⁷. Conversely, the syndrome of inappropriate anti-diuretic hormone (SIADH) lacks a high volume urine output, and patients are usually euvolaemic with a normal CVP, and no clinical signs of dehydration²⁷. Fluid balance charts may help identify these fluid shifts. Despite these distinguishing features, CSW and SIADH can be difficult to diagnose and other laboratory tests, such as serum and urinary osmolality and urinary sodium, may help further identify the aetiology, which is critical due to their divergent management approaches.

Hypokalaemia. Hypokalaemia may be a result of drugs or of poor nutrition, whereas hyperkalaemia may be due to hypoadrenalism either directly from TB or from withdrawal of corticosteroids. Monitoring low serum potassium and replacement requires an environment capable of close monitoring. The use of hypertonic saline, fludrocortisone and acetazolamide, individually or in combination, may rapidly shift electrolytes.

Risks of prolonged critical care admission

Pressure ulcers are common in immobile individuals requiring prolonged care. Nosocomial infections occur due to changes in patients' immune system and placement of foreign objects, such as a central venous line, arterial line, urinary catheter or endotracheal tube. Deep vein thrombosis is a risk of prolonged critical care admission. Urinary tract infections may occur secondary to urinary catheters. Further, impaired consciousness may require prolonged intubation and mechanical ventilation²⁸, which may be associated with a higher risk for gastrointestinal haemorrhage, septicemia and pressure ulcers²⁹. Prolonged recovery and slow ventilator wean may involve tracheostomy placement.

Neurocritical care

In addition to general and critical care management, specific neurocritical care may assist in TBM management.

Neurological examination

Level of consciousness. The Glasgow coma scale (GCS) assesses level of consciousness. It can be confounded by intubation, sedatives, and pre-existing neurological conditions^{18,30}. For paediatrics, modified GCS versions have been developed, but are used variably³⁰. Decreased GCS (<15) could be due to irreversible neurological injury and also reversible factors including electrolyte disturbances, raised ICP, seizures, and medication. Consequently, the GCS one week post-admission may be a stronger prognostic marker³¹. A deteriorating GCS may signal worsening hydrocephalus, poorly controlled ICP, and progressive ischaemia.

Focal neurological deficits. Palsies commonly involve cranial nerves II, III and VI and can denote nerve arachnoiditis, ischaemia, a mass lesion, or hydrocephalus³². Motor weakness and abnormalities may be due to ischaemia, infarction or brain shift.

Cranial examination. An enlarging head may signify subacute or chronic development of hydrocephalus in young children if their sutures are not fused.

General monitoring in neurocritical care

Blood pressure and cerebral perfusion. Maintaining normotension is important for adequate CPP, defined as mean arterial pressure (MAP) minus ICP, which reflects the pressure gradient that drives cerebral blood flow (CBF)³³. Current treatment guidelines in traumatic brain injury (TBI) recommend maintaining age-appropriate CPP and MAP^{33–36}. Hydration status and overall fluid balance, often compromised by CSW or poor oral intake, can affect MAP and subsequently CPP. TBM-specific goals for CPP and MAP are not established.

Ventilation and oxygenation. Oxygen administration may increase cerebral oxygenation and possibly reverse brain hypoxia³⁷. Oxygen and carbon dioxide (CO₂) levels also affect CBF and ICP. Decreased arterial oxygen and increased CO₂ both dilate cerebral vessels, which may increase cerebral blood volume and ICP³⁸. Conversely, aggressive hyperventilation may constrict cerebral vessels and cause ischaemia from decreased CBF³⁸. Therefore, tight control of end tidal carbon dioxide (ETCO₂) is crucial to control raised ICP but avoid ischaemia and is an important parameter in TBI management guidelines, although the target level for TBM is unknown^{34,39}. Both oxygenation and ventilation can be monitored noninvasively with pulse oximetry and ETCO₂ or invasively with arterial blood gases.

Temperature. Hyperthermia may increase cerebral metabolic rate and CBF, which can further increase ICP in a swollen brain⁴⁰. Induced hypothermia is experimentally neuroprotective but is associated with poorer outcomes in TBI^{34,35,39}. The target temperature in TBM is not established.

Head-of-bed elevation. Elevating the head end of a bed lowers ICP through improved venous drainage and extracranial shift of cerebrospinal fluid (CSF). However, the MAP may also

fall. In non-TBM pathology, studies suggest a beneficial or non-detrimental role of head-of-bed elevation to 30°^{41–43}.

Neuroimaging

Infarcts may not be visible on admission computed tomography (CT) scans^{44,45}, but diffusion-weighted magnetic resonance imaging (MRI) is sensitive to acute/evolving infarcts^{46,47}. Follow-up imaging is important to detect new infarcts^{44,45,48} and, although there are little data on the temporal profile of infarct development, patients appear to be at greatest risk during the acute phase (first month).

Hydrocephalus is the commonest cause of increased ICP in TBM^{45,49}. The communicating nature of hydrocephalus has implications for the safety of lumbar punctures and the method of treatment. However, communication cannot be determined from standard imaging⁵⁰ and lumbar exudate can confound determination of the level of CSF obstruction. ICP cannot be estimated from ventricular size alone on imaging⁴⁸. Hydrocephalus may persist or develop *de novo* over the first six months after treatment initiation; therefore, repeat neuroimaging may be warranted^{10,51}.

Tuberculomas and TB abscesses occasionally complicate the management of TBM if they cause local mass effect⁵² and precipitate CSF obstruction, focal deficits or seizures^{45,48,53,54}. During treatment, paradoxical enlargement of established tuberculomas or development of new tuberculomas may necessitate follow-up imaging^{45,53,55–57}.

Repeat neuroimaging can be used to monitor disease progression, evaluate deteriorating patients, and confirm the placement of a ventriculoperitoneal (VP) shunt or an external ventricular drain (EVD). The ideal timing of follow up imaging is unclear in stable patients.

Raised intracranial pressure

Raised ICP is a key factor precipitating adverse outcomes. Firstly, it reduces CPP and exacerbates existing cerebral ischaemia due to vasculitis. Secondly, generalised or compartmentalised increased ICP causes brain shift and consequent neural injury. ICP monitoring is useful; non-invasive monitoring techniques may be used when gold-standard invasive monitoring is unavailable. New monitoring techniques have potential for improving patient care, yet these are not widely available. Important points for the monitoring and optimisation of ICP are shown in [Table 3](#) and [Table 4](#).

Non-invasive intracranial pressure measurement and monitoring

Fundoscopy

Optic disc swelling can indicate raised ICP. However, fundoscopy is challenging to perform and highly operator dependent, and the development of papilloedema can be delayed.

Optic nerve sheath diameter ultrasound

Changes in optic nerve sheath diameter (ONSD) due to raised ICP occur rapidly and can be measured using ultrasound⁵⁸.

ONS ultrasound is quick, easy, and reproducible, and correlates with ICP^{59,60}, although evidence for its use in TBM is limited⁶¹⁻⁶³.

Compromised cerebral perfusion

Various neuromonitors have been used in non-TBM pathologies, to detect ischaemic brain injury⁶⁴⁻⁶⁶. These measure various facets of brain perfusion and each have strengths and limitations.

Transcranial Doppler ultrasound

Transcranial Doppler (TCD) can be used to measure flow velocity in basal vessels and detect vasculopathy; however, it may not detect mild-moderate ICP changes, is limited to flow in the major cerebral vessels, and is technically challenging^{18,67}.

Non-invasive cerebral oxygenation monitoring: near-infrared spectroscopy. Near-infrared spectroscopy (NIRS) is a non-invasive monitor that uses optical technology to continuously assess brain oxygenation^{68,69}. NIRS is limited by superficial penetration of cortex, distortion by the skull, CSF and oedema^{68,70,71} and poor long term monitoring.

Invasive cerebral oxygenation monitoring: partial pressure of brain tissue oxygen tension. The partial pressure of brain tissue oxygen tension (PbtO₂) monitor is a thin parenchymal catheter that offers continuous monitoring of brain oxygenation^{66,72}. Normal values have not been established; however, the risk of poor outcome increases with PbtO₂ <20mmHg⁷³, especially <10mmHg^{64,72,74,75}.

Invasive intracranial pressure measurement and monitoring. CSF opening pressure may be measured from the ventricles with an EVD or via lumbar puncture (when safe)⁷⁶. CSF drainage allows simultaneous ICP monitoring and treatment. Continuous monitoring is possible with a parenchymal probe.

Post-operative neurosurgery management. This includes wound review, suture removal, and clinical monitoring for signs of treatment failure. Repeat imaging can check treatment success. EVDs must be carefully managed to avoid life-threatening complications (infection and overdrainage-related intracranial haemorrhage). VP shunts are permanent and therefore complication rates must be viewed over the full lifetime of the patient.

Management of acutely decompensating patients

Causes for acute neurological decompensation include raised ICP, metabolic disturbances (i.e., hyponatremia, hypoglycaemia), stroke (ischaemic or haemorrhagic) and seizures. [Table 4](#) outlines a priorities-based checklist approach to the acutely decompensating patient. The rationale for this checklist is described below, unless already discussed.

Seizures

Clinical and subclinical seizures can increase ICP due to the increased cerebral metabolic demand and resultant increased

CBF. Hydrocephalus, infarcts, tuberculomas, and electrolyte imbalance can all precipitate seizures. Anti-convulsants that induce cytochrome P450 enzymes, or are susceptible to enzyme induction by rifampicin, may complicate management.

Hyperosmolar treatment

Intravenous administration of a hyperosmolar solution creates an osmotic gradient, removing water from the brain and decreasing ICP⁷⁷. Hypertonic saline may lower ICP faster, further, and for longer than mannitol¹⁸; however, no trials have directly compared these agents in TBM.

Raised intracranial pressure surgical management

Hydrocephalus

VP shunting has long been standard practice for hydrocephalus but may be associated with complications^{78,79}. EVD may be used for temporary drainage of CSF, and to assess the benefit of a VP shunt in patients with an altered sensorium. With endoscopic third ventriculostomy (ETV), CSF is drained internally by connecting the ventricles with the subarachnoid space via a stoma in the floor of the third ventricle. ETV is particularly challenging in TBM and experience is required^{80,81}.

Mass lesions

Surgical excision for tuberculomas is uncommon but may be indicated depending on their size, location, expansion, and clinical consequences. Surgery is more commonly needed for TB abscesses (drainage and/or excision).

Cerebral venous thrombosis

Cerebral venous thrombosis is an unusual cause of acute neurological deterioration in TBM, but has been described^{82,83}.

Data availability

No data are associated with this article.

Acknowledgements

Tuberculous Meningitis International Research Consortium

Rob E. Aarnoutse; Suzanne T. B. Anderson; Nathan C. Bahr; Nguyen D. Bang; David R. Boulware; Tom Boyles; Lindsey H. M. te Brake; Satish Chandra; Felicia C. Chow; Fiona V. Cresswell; Reinout van Crevel; Angharad G. Davis; Sofiati Dian; Joseph Donovan; Kelly E. Dooley; Anthony Figaji; A. Rizal Ganiem; Ravindra Kumar Garg; Diana M. Gibb; Raph L. Hamers; Nguyen T. T. Hiep; Darma Imran; Akhmad Imron; Sanjay K. Jain; Sunil K. Jain; Byramee Jeejeebhoy; Jayantee Kalita; Rashmi Kumar; Vinod Kumar; Arjan van Laarhoven; Rachel P.-J. Lai; Abi Manesh; Suzaan Marais; Vidya Mave; Graeme Meintjes; David B. Meya; Usha K. Misra; Manish Modi; Alvaro A. Ordonez; Nguyen H. Phu; Sunil Pradhan; Kameshwar Prasad; Alize M. Proust; Lalita Ramakrishnan; Ursula Rohlwick; Rovina Ruslami; Johannes F. Schoeman; James A. Seddon; Kusum Sharma; Omar Siddiqi; Regan S. Solomons; Nguyen T. T. Thuong; Guy E. Thwaites; Ronald van Toorn; Elizabeth W. Tucker; Sean A. Wasserman; Robert J. Wilkinson.

References

- Kramer HS, Drews FA: **Checking the lists: A systematic review of electronic checklist use in health care.** *J Biomed Inform.* 2017; **71S**: S6–12.
[PubMed Abstract](#) | [Publisher Full Text](#)
- Semrau KEA, Hirschhorn LR, Marx Delaney M, *et al.*: **Outcomes of a Coaching-Based WHO Safe Childbirth Checklist Program in India.** *N Engl J Med.* 2017; **377**(24): 2313–24.
[PubMed Abstract](#) | [Publisher Full Text](#) | [Free Full Text](#)
- Haynes AB, Weiser TG, Berry WR, *et al.*: **A surgical safety checklist to reduce morbidity and mortality in a global population.** *N Engl J Med.* 2009; **360**(5): 491–9.
[PubMed Abstract](#) | [Publisher Full Text](#)
- Pronovost P, Needham D, Berenholtz S, *et al.*: **An intervention to decrease catheter-related bloodstream infections in the ICU.** *N Engl J Med.* 2006; **355**(26): 2725–32.
[PubMed Abstract](#) | [Publisher Full Text](#)
- Thao LTP, Heemskerck AD, Geskus RB, *et al.*: **Prognostic Models for 9-Month Mortality in Tuberculous Meningitis.** *Clin Infect Dis.* 2018; **66**(4): 523–32.
[PubMed Abstract](#) | [Publisher Full Text](#) | [Free Full Text](#)
- Kalita J, Misra UK: **Outcome of tuberculous meningitis at 6 and 12 months: a multiple regression analysis.** *Int J Tuberc Lung Dis.* 1999; **3**(3): 261–5.
[PubMed Abstract](#)
- Chiang SS, Khan FA, Milstein MB, *et al.*: **Treatment outcomes of childhood tuberculous meningitis: a systematic review and meta-analysis.** *Lancet Infect Dis.* 2014; **14**(10): 947–57.
[PubMed Abstract](#) | [Publisher Full Text](#)
- Modi M, Sharma K, Prabhakar S, *et al.*: **Clinical and radiological predictors of outcome in tubercular meningitis: A prospective study of 209 patients.** *Clin Neurol Neurosurg.* 2017; **161**: 29–34.
[PubMed Abstract](#) | [Publisher Full Text](#)
- van Laarhoven A, Dian S, Ruesen C, *et al.*: **Clinical Parameters, Routine Inflammatory Markers, and LTA4H Genotype as Predictors of Mortality Among 608 Patients With Tuberculous Meningitis in Indonesia.** *J Infect Dis.* 2017; **215**(7): 1029–39.
[PubMed Abstract](#) | [Publisher Full Text](#)
- Raut T, Garg RK, Jain A, *et al.*: **Hydrocephalus in tuberculous meningitis: Incidence, its predictive factors and impact on the prognosis.** *J Infect.* 2013; **66**(4): 330–7.
[PubMed Abstract](#) | [Publisher Full Text](#)
- Cag Y, Ozturk-Engin D, Gencer S, *et al.*: **Hydrocephalus and vasculitis delay therapeutic responses in tuberculous meningitis: Results of Haydarpaşa-III study.** *Neurol India.* 2016; **64**(5): 896–905.
[PubMed Abstract](#) | [Publisher Full Text](#)
- Brancusi F, Farrar J, Heemskerck D: **Tuberculous meningitis in adults: a review of a decade of developments focusing on prognostic factors for outcome.** *Future Microbiol.* 2012; **7**(9): 1101–16.
[PubMed Abstract](#) | [Publisher Full Text](#)
- Misra UK, Kumar M, Kalita J: **Seizures in tuberculous meningitis.** *Epilepsy Res.* 2018; **148**: 90–5.
[PubMed Abstract](#) | [Publisher Full Text](#)
- Thwaites GE, Duc Bang N, Huy Dung N, *et al.*: **The influence of HIV infection on clinical presentation, response to treatment, and outcome in adults with Tuberculous meningitis.** *J Infect Dis.* 2005; **192**(12): 2134–41.
[PubMed Abstract](#) | [Publisher Full Text](#)
- Heemskerck AD, Nguyen MTH, Dang HTM, *et al.*: **Clinical Outcomes of Patients With Drug-Resistant Tuberculous Meningitis Treated With an Intensified Antituberculosis Regimen.** *Clin Infect Dis.* 2017; **65**(1): 20–8.
[PubMed Abstract](#) | [Publisher Full Text](#) | [Free Full Text](#)
- Yaramiş A, Gurkan F, Elevli M, *et al.*: **Central nervous system tuberculosis in children: a review of 214 cases.** *Pediatrics.* 1998; **102**(5): E49.
[PubMed Abstract](#) | [Publisher Full Text](#)
- Christe A, Walti L, Charimo J, *et al.*: **Imaging patterns of Pneumocystis jirovecii pneumonia in HIV-positive and renal transplant patients - a multicentre study.** *Swiss Med Wkly.* 2019; **149**: w20130.
[PubMed Abstract](#) | [Publisher Full Text](#)
- Donovan J, Figaji A, Imran D, *et al.*: **The neurocritical care of tuberculous meningitis.** *Lancet Neurol.* 2019; **18**(8): 771–83.
[PubMed Abstract](#) | [Publisher Full Text](#)
- Wilkinson RJ, Rohlwick U, Misra UK, *et al.*: **Tuberculous meningitis.** *Nat Rev Neurol.* 2017; **13**(10): 581–98.
[PubMed Abstract](#) | [Publisher Full Text](#)
- Donovan J, Phu NH, Mai NTH, *et al.*: **Adjunctive dexamethasone for the treatment of HIV-infected adults with tuberculous meningitis (ACT HIV): Study protocol for a randomised controlled trial [version 2; peer review: 1 approved, 2 approved with reservations].** *Wellcome Open Res.* 2018; **3**: 31.
[PubMed Abstract](#) | [Publisher Full Text](#) | [Free Full Text](#)
- Donovan J, Phu NH, Thao LTP, *et al.*: **Adjunctive dexamethasone for the treatment of HIV-uninfected adults with tuberculous meningitis stratified by Leukotriene A4 hydrolase genotype (LAST ACT): Study protocol for a randomised double blind placebo controlled non-inferiority trial [version 1; peer review: 2 approved].** *Wellcome Open Res.* 2018; **3**: 32.
[PubMed Abstract](#) | [Publisher Full Text](#) | [Free Full Text](#)
- McClave SA, Taylor BE, Martindale RG, *et al.*: **Guidelines for the Provision and Assessment of Nutrition Support Therapy in the Adult Critically Ill Patient: Society of Critical Care Medicine (SCCM) and American Society for Parenteral and Enteral Nutrition (A.S.P.E.N.).** *JPEN J Parenter Enteral Nutr.* 2016; **40**(2): 159–211.
[PubMed Abstract](#) | [Publisher Full Text](#)
- Vavilala MS, Kernic MA, Wang J, *et al.*: **Acute care clinical indicators associated with discharge outcomes in children with severe traumatic brain injury.** *Crit Care Med.* 2014; **42**(10): 2258–66.
[PubMed Abstract](#) | [Publisher Full Text](#) | [Free Full Text](#)
- Narum S, Westergren T, Klemp M: **Corticosteroids and risk of gastrointestinal bleeding: a systematic review and meta-analysis.** *BMJ Open.* 2014; **4**(5): e004587.
[PubMed Abstract](#) | [Publisher Full Text](#) | [Free Full Text](#)
- Kwon SH, Kim JH, Yang JO, *et al.*: **Ethambutol-induced acute renal failure.** *Nephrol Dial Transplant.* 2004; **19**(5): 1335–6.
[PubMed Abstract](#) | [Publisher Full Text](#)
- Sakashita K, Murata K, Takahashi Y, *et al.*: **A Case Series of Acute Kidney Injury During Anti-tuberculosis Treatment.** *Intern Med.* 2019; **58**(4): 521–7.
[PubMed Abstract](#) | [Publisher Full Text](#) | [Free Full Text](#)
- Misra UK, Kalita J, Bhoi SK, *et al.*: **A study of hyponatremia in tuberculous meningitis.** *J Neurol Sci.* 2016; **367**: 152–7.
[PubMed Abstract](#) | [Publisher Full Text](#)
- Verdon R, Chevret S, Laissy JP, *et al.*: **Tuberculous meningitis in adults: review of 48 cases.** *Clin Infect Dis.* 1996; **22**(6): 982–8.
[PubMed Abstract](#) | [Publisher Full Text](#)
- Misra UK, Kalita J, Betai S, *et al.*: **Outcome of tuberculous meningitis patients requiring mechanical ventilation.** *J Crit Care.* 2015; **30**(6): 1365–9.
[PubMed Abstract](#) | [Publisher Full Text](#)
- Teasdale G, Maas A, Lecky F, *et al.*: **The Glasgow Coma Scale at 40 years: standing the test of time.** *Lancet Neurol.* 2014; **13**(8): 844–54.
[PubMed Abstract](#) | [Publisher Full Text](#)
- van Toorn R, Springer P, Laubscher JA, *et al.*: **Value of different staging systems for predicting neurological outcome in childhood tuberculous meningitis.** *Int J Tuberc Lung Dis.* 2012; **16**(5): 628–32.
[PubMed Abstract](#) | [Publisher Full Text](#)
- van Laarhoven A, Dian S, Aguirre-Gamboa R, *et al.*: **Cerebral tryptophan metabolism and outcome of tuberculous meningitis: an observational cohort study.** *Lancet Infect Dis.* 2018; **18**(5): 526–35.
[PubMed Abstract](#) | [Publisher Full Text](#)
- Kochanek PM, Carney N, Adelson PD, *et al.*: **Guidelines for the acute medical management of severe traumatic brain injury in infants, children, and adolescents—second edition.** *Pediatr Crit Care Med.* 2012; **13** Suppl 1: S1–82.
[PubMed Abstract](#) | [Publisher Full Text](#)
- Kochanek PM, Tasker RC, Carney N, *et al.*: **Guidelines for the Management of Pediatric Severe Traumatic Brain Injury, Third Edition: Update of the Brain Trauma Foundation Guidelines, Executive Summary.** *Neurosurgery.* 2019; **84**(6): 1169–78.
[PubMed Abstract](#) | [Publisher Full Text](#)
- McHugh GS, Engel DC, Butcher I, *et al.*: **Prognostic value of secondary insults in traumatic brain injury: results from the IMPACT study.** *J Neurotrauma.* 2007; **24**(2): 287–93.
[PubMed Abstract](#) | [Publisher Full Text](#)
- Spaite DW, Hu C, Bobrow BJ, *et al.*: **The Effect of Combined Out-of-Hospital Hypotension and Hypoxia on Mortality in Major Traumatic Brain Injury.** *Ann Emerg Med.* 2017; **69**(1): 62–72.
[PubMed Abstract](#) | [Publisher Full Text](#) | [Free Full Text](#)
- Figaji AA, Sandler SI, Fieggan AG, *et al.*: **Continuous monitoring and intervention for cerebral ischemia in tuberculous meningitis.** *Pediatr Crit Care Med.* 2008; **9**(4): e25–30.
[PubMed Abstract](#) | [Publisher Full Text](#)
- Gibbs F, Gibbs EL, Lennox WG: **Changes in human cerebral blood flow consequent on alterations in blood gases.** *Am J Physiol Content.* 1935; **111**(3): 557–63.
[Publisher Full Text](#)
- Carney N, Totten AM, O'Reilly C, *et al.*: **Guidelines for the Management of Severe Traumatic Brain Injury, Fourth Edition.** *Neurosurgery.* 2017; **80**(1): 6–15.
[PubMed Abstract](#) | [Publisher Full Text](#)
- Schwarz S, Hafner K, Aschoff A, *et al.*: **Incidence and prognostic significance of fever following intracerebral hemorrhage.** *Neurology.* 2000; **54**(2): 354–361.
[PubMed Abstract](#) | [Publisher Full Text](#)
- Feldman Z, Kanter MJ, Robertson CS, *et al.*: **Effect of head elevation on intracranial pressure, cerebral perfusion pressure, and cerebral blood flow in head-injured patients.** *J Neurosurg.* 1992; **76**(2): 207–11.
[PubMed Abstract](#) | [Publisher Full Text](#)
- Dunward QJ, Amacher AL, Del Maestro RF, *et al.*: **Cerebral and cardiovascular**

- responses to changes in head elevation in patients with intracranial hypertension. *J Neurosurg.* 1983; 59(6): 938–44.
[PubMed Abstract](#) | [Publisher Full Text](#)
43. Mahfoud F, Beck J, Raabe A: Intracranial pressure pulse amplitude during changes in head elevation: a new parameter for determining optimum cerebral perfusion pressure? *Acta Neurochir (Wien).* 2010; 152(3): 443–50.
[PubMed Abstract](#) | [Publisher Full Text](#)
44. Rohlwink UK, Kilborn T, Wieselthaler N, et al.: Imaging Features of the Brain, Cerebral Vessels and Spine in Pediatric Tuberculous Meningitis With Associated Hydrocephalus. *Pediatr Infect Dis J.* 2016; 35(10): e301–10.
[PubMed Abstract](#) | [Publisher Full Text](#) | [Free Full Text](#)
45. Thwaites GE, Macmullen-Price J, Tran TH, et al.: Serial MRI to determine the effect of dexamethasone on the cerebral pathology of tuberculous meningitis: an observational study. *Lancet Neurol.* 2007; 6(3): 230–6.
[PubMed Abstract](#) | [Publisher Full Text](#) | [Free Full Text](#)
46. Misra UK, Kalita J, Maurya PK: Stroke in tuberculous meningitis. *J Neurol Sci.* 2011; 303(1–2): 22–30.
[PubMed Abstract](#) | [Publisher Full Text](#)
47. Andronikou S, Wieselthaler N, Smith B, et al.: Value of early follow-up CT in paediatric tuberculous meningitis. *Pediatr Radiol.* 2005; 35(11): 1092–9.
[PubMed Abstract](#) | [Publisher Full Text](#)
48. Schoeman JF, Van Zyl LE, Laubscher JA, et al.: Serial CT scanning in childhood tuberculous meningitis: prognostic features in 198 cases. *J Child Neurol.* 1995; 10(4): 320–9.
[PubMed Abstract](#) | [Publisher Full Text](#)
49. Rohlwink UK, Donald K, Gavine B, et al.: Clinical characteristics and neurodevelopmental outcomes of children with tuberculous meningitis and hydrocephalus. *Dev Med Child Neurol.* 2016; 58(5): 461–8.
[PubMed Abstract](#) | [Publisher Full Text](#) | [Free Full Text](#)
50. Figaji AA, Fieggen AG, Peter JC: Air encephalography for hydrocephalus in the era of neuroendoscopy. *Child's Nerv Syst.* 2005; 21(7): 559–65.
[PubMed Abstract](#) | [Publisher Full Text](#)
51. Chan KH, Cheung RT, Fong CY, et al.: Clinical relevance of hydrocephalus as a presenting feature of tuberculous meningitis. *QJM.* 2003; 96(6): 643–8.
[PubMed Abstract](#) | [Publisher Full Text](#)
52. Rajshekhkar V: Surgery for brain tuberculosis: a review. *Acta Neurochir (Wien).* 2015; 157(10): 1665–78.
[PubMed Abstract](#) | [Publisher Full Text](#)
53. Ravenscroft A, Schoeman JF, Donald PR: Tuberculous granulomas in childhood tuberculous meningitis: radiological features and course. *J Trop Pediatr.* 2001; 47(1): 5–12.
[PubMed Abstract](#) | [Publisher Full Text](#)
54. Patwari AK, Aneja S, Ravi RN, et al.: Convulsions in tuberculous meningitis. *J Trop Pediatr.* 1996; 42(2): 91–7.
[PubMed Abstract](#) | [Publisher Full Text](#)
55. Farinha NJ, Razali KA, Holzel H, et al.: Tuberculosis of the central nervous system in children: a 20-year survey. *J Infect.* 2000; 41(1): 61–8.
[PubMed Abstract](#) | [Publisher Full Text](#)
56. Anuradha HK, Garg RK, Sinha MK, et al.: Intracranial tuberculomas in patients with tuberculous meningitis: predictors and prognostic significance. *Int J Tuberc Lung Dis.* 2011; 15(2): 234–9.
[PubMed Abstract](#)
57. Shah I, Borse S: Paradoxical tuberculomas after completion of antituberculous treatment. *Trop Med Health.* 2012; 40(1): 15–7.
[PubMed Abstract](#) | [Free Full Text](#)
58. Rajajee V, Vanaman M, Fletcher JJ, et al.: Optic nerve ultrasound for the detection of raised intracranial pressure. *Neurocrit Care.* 2011; 15(3): 506–15.
[PubMed Abstract](#) | [Publisher Full Text](#)
59. Dubourg J, Javouhey E, Geeraerts T, et al.: Ultrasonography of optic nerve sheath diameter for detection of raised intracranial pressure: a systematic review and meta-analysis. *Intensive Care Med.* 2011; 37(7): 1059–68.
[PubMed Abstract](#) | [Publisher Full Text](#)
60. Robba C, Santori G, Czosnyka M, et al.: Optic nerve sheath diameter measured sonographically as non-invasive estimator of intracranial pressure: a systematic review and meta-analysis. *Intensive Care Med.* 2018; 44(8): 1284–94.
[PubMed Abstract](#) | [Publisher Full Text](#)
61. Godara SC, Srivastava VK, Godara S, et al.: Role of optic nerve sheath diameter measured by ultrasonography in the detection of increased intracranial tension in patients with tuberculous meningitis. *Int J Recent Trends Sci Technol.* 2015; 16(3): 548–50.
[Reference Source](#)
62. Bhatt S, Sangani S, Roberts J, et al.: The Optic Nerve Sheath Diameter in Cerebral Infections. *Ann Emerg Med.* 2014; 64(4 Supplement): S92.
[Publisher Full Text](#)
63. Sangani S, Parikh S: Can sonographic measurement of optic nerve sheath diameter be used to detect raised intracranial pressure in patients with tuberculous meningitis? A prospective observational study. *Indian J Radiol Imaging.* 2015; 25(2): 173–6.
[PubMed Abstract](#) | [Publisher Full Text](#) | [Free Full Text](#)
64. Figaji AA, Zwane E, Thompson C, et al.: Brain tissue oxygen tension monitoring in pediatric severe traumatic brain injury. Part 2: Relationship with clinical, physiological, and treatment factors. *Childs Nerv Syst.* 2009; 25(10): 1325–43.
[PubMed Abstract](#) | [Publisher Full Text](#)
65. Stiefel MF, Spiotta A, Gracias VH, et al.: Reduced mortality rate in patients with severe traumatic brain injury treated with brain tissue oxygen monitoring. *J Neurosurg.* 2005; 103(5): 805–11.
[PubMed Abstract](#) | [Publisher Full Text](#)
66. Lang EW: Systematic and Comprehensive Literature Review of Publications on Direct Cerebral Oxygenation Monitoring. *Open Crit Care Med J.* 2013; 6: 1–24.
[Publisher Full Text](#)
67. Mayer SA, Chong JY: Critical Care Management of Increased Intracranial Pressure. *J Intensive Care Med.* 2002; 17(2): 55–67.
[Publisher Full Text](#)
68. Smith M, Elwell C: Near-infrared spectroscopy: shedding light on the injured brain. *Anesth Analg.* 2009; 108(4): 1055–7.
[PubMed Abstract](#) | [Publisher Full Text](#)
69. Kurth CD, McCann JC, Wu J, et al.: Cerebral oxygen saturation-time threshold for hypoxic-ischemic injury in piglets. *Anesth Analg.* 2009; 108(4): 1268–77.
[PubMed Abstract](#) | [Publisher Full Text](#)
70. Diedler J, Czosnyka M: Merits and pitfalls of multimodality brain monitoring. *Neurocrit Care.* 2010; 12(3): 313–6.
[PubMed Abstract](#) | [Publisher Full Text](#)
71. Knirsch W, Stutz K, Kretschmar O, et al.: Regional cerebral oxygenation by NIRS does not correlate with central or jugular venous oxygen saturation during interventional catheterisation in children. *Acta Anaesthesiol Scand.* 2008; 52(10): 1370–4.
[PubMed Abstract](#) | [Publisher Full Text](#)
72. Lang EW, Mulvey JM, Mudaliar Y, et al.: Direct cerebral oxygenation monitoring—a systematic review of recent publications. *Neurosurg Rev.* 2007; 30(2): 99–106; discussion 106–7.
[PubMed Abstract](#) | [Publisher Full Text](#)
73. Valadka AB, Gopinath SP, Contant CF, et al.: Relationship of brain tissue PO2 to outcome after severe head injury. *Crit Care Med.* 1998; 26(9): 1576–81.
[PubMed Abstract](#) | [Publisher Full Text](#)
74. Wartenberg KE, Schmidt JM, Mayer SA: Multimodality monitoring in neurocritical care. *Crit Care Clin.* 2007; 23(3): 507–38.
[PubMed Abstract](#) | [Publisher Full Text](#)
75. Bratton SL, Chestnut RM, Ghajar J, et al.: X. Brain Oxygen Monitoring and Thresholds. *J Neurotrauma.* 2007; 24(Supplement 1): S-65–S-70.
[Publisher Full Text](#)
76. Schoeman J, Donald P, van Zyl L, et al.: Tuberculous hydrocephalus: comparison of different treatments with regard to ICP, ventricular size and clinical outcome. *Dev Med Child Neurol.* 1991; 33(5): 396–405.
[PubMed Abstract](#) | [Publisher Full Text](#)
77. Ropper AH: Management of raised intracranial pressure and hyperosmolar therapy. *Pract Neurol.* 2014; 14(3): 152–8.
[PubMed Abstract](#) | [Publisher Full Text](#)
78. Rizvi I, Garg RK, Malhotra HS, et al.: Ventriculo-peritoneal shunt surgery for tuberculous meningitis: A systematic review. *J Neurol Sci.* 2017; 375: 255–63.
[PubMed Abstract](#) | [Publisher Full Text](#)
79. Lamprecht D, Schoeman J, Donald P, et al.: Ventriculoperitoneal shunting in childhood tuberculous meningitis. *Br J Neurosurg.* 2001; 15(2): 119–25.
[PubMed Abstract](#) | [Publisher Full Text](#)
80. Figaji AA, Fieggen AG, Peter JC: Endoscopic third ventriculostomy in tuberculous meningitis. *Childs Nerv Syst.* 2003; 19(4): 217–25.
[PubMed Abstract](#)
81. Figaji AA, Fieggen AG, Peter JC: Endoscopy for tuberculous hydrocephalus. *Childs Nerv Syst.* 2007; 23(1): 79–84.
[PubMed Abstract](#) | [Publisher Full Text](#)
82. Verma R, Lalla R, Patil TB, et al.: A rare presentation of cerebral venous sinus thrombosis associated with tubercular meningitis. *BMJ Case Rep.* 2013; 2013: pii: bcr2013009892.
[PubMed Abstract](#) | [Publisher Full Text](#) | [Free Full Text](#)
83. Dhawan SR, Chatterjee D, Radotra BD, et al.: A Child with Tuberculous Meningitis Complicated by Cortical Venous and Cerebral Sino-Venous Thrombosis. *Indian J Pediatr.* 2019; 86(4): 371–8.
[PubMed Abstract](#) | [Publisher Full Text](#)

Open Peer Review

Current Peer Review Status:  

Version 1

Reviewer Report 15 January 2020

<https://doi.org/10.21956/wellcomeopenres.16979.r37331>

© 2020 Gupta R. This is an open access peer review report distributed under the terms of the [Creative Commons Attribution License](#), which permits unrestricted use, distribution, and reproduction in any medium, provided the original work is properly cited.



Rakesh K. Gupta

Department of Radiology and Imaging, Fortis Memorial Research Institute, Gurgaon, Haryana, India

The authors have attempted to streamline the management of TBM and its complications in a step wise fashion and is a welcome step. However, there is nothing new in what they have mentioned and is practised in the countries where the disease is endemic. I am fine with summary for management except for a small comment on table I and is as under:

Table 1:

- Assessment for communicating hydrocephalus with air encephalogram or column test is obsolete and is only of historical relevance and should be deleted.

Is the rationale for the Open Letter provided in sufficient detail?

Yes

Does the article adequately reference differing views and opinions?

Yes

Are all factual statements correct, and are statements and arguments made adequately supported by citations?

Partly

Is the Open Letter written in accessible language?

Yes

Where applicable, are recommendations and next steps explained clearly for others to follow?

Yes

Competing Interests: No competing interests were disclosed.

Reviewer Expertise: Imaging

I confirm that I have read this submission and believe that I have an appropriate level of expertise to confirm that it is of an acceptable scientific standard.

Author Response 22 Jan 2020

Joseph Donovan, Oxford University Clinical Research Unit, Centre for Tropical Medicine, Ho Chi Minh City, Vietnam

Dear Dr Rakesh K. Gupta,,

Thank you for reviewing our open letter "Checklists to guide the supportive and critical care of tuberculous meningitis".

Please find below our point by point responses.

1. The authors have attempted to streamline the management of TBM and its complications in a step wise fashion and is a welcome step. However, there is nothing new in what they have mentioned and is practiced in the countries where the disease is endemic. I am fine with summary for management except for a small comment on table I and is as under: Table 1: Assessment for communicating hydrocephalus with air encephalogram or column test is obsolete and is only of historical relevance and should be deleted.

Thank you for your comment. However, we disagree that this does not offer anything new; our proforma is the first comprehensive patient assessment tool for tuberculous meningitis. No other checklist exists to allow a priority-based approach to a deteriorating patient in this disease. Whilst the information included in the checklist and proforma may be accepted knowledge, or available elsewhere, our presentation of this information in proforma and checklist formats aim to support clinical assessment, and highlight vital components, during clinical care.

2. Table 1: Assessment for communicating hydrocephalus with air encephalogram or column test is obsolete and is only of historical relevance and should be deleted.

We note, but disagree with, the reviewer's comment on air encephalography and column tests. These are used as standard approaches in at least two big centres that publish on TB meningitis, based on published data, so this is hardly historical nor obsolete.

There is no current technology, apart from invasive methods, that have been shown to safely and reliably distinguish between communicating and non-communicating hydrocephalus. This is based on published studies. We know that some centres do not try to distinguish and therefore have higher rates of surgical procedures - VP shunting and endoscopy. However, with medical management, most patients can avoid those surgical procedures - this was published by Johan Schoeman many years ago and the results are as relevant today as they were then. But this of course depends on being able to do lumbar punctures safely, which may be risky for the 15-20% of patients that may have non-communicating hydrocephalus. To our knowledge, there has been no paper showing the safety and reliability of any imaging to confirm the communicating nature of hydrocephalus in TBM.

So the reviewer's comment is not evidence-based and we are comfortable that our manuscript reflects published data.

Competing Interests: No competing interests were disclosed.

Reviewer Report 03 December 2019

<https://doi.org/10.21956/wellcomeopenres.16979.r36903>

© 2019 Musubire A. This is an open access peer review report distributed under the terms of the [Creative Commons Attribution License](#), which permits unrestricted use, distribution, and reproduction in any medium, provided the original work is properly cited.



Abdu Kisekka Musubire 

Infectious Disease Institute, College of Health Sciences, Makerere University, Kampala, Uganda

The authors attempt to answer a very relevant question with scarce data. The article is timely and very important. I have the following concerns:

Box 1 page 3: Define the extremes of ages for the readers

Under respiratory monitoring: page 3
Pneumothorax is rare in PJP

Swiss Med Wkly. 2019 Oct 3;149:w20130. Imaging patterns of *Pneumocystis jirovecii* pneumonia in HIV-positive and renal transplant patients - a multicentre study. Christe A1, Walti L2, Charimo J1, Rauch A2, Furrer H2, Meyer A3, Huynh-Do U3, Heverhagen JT4, Mueller NJ5, Cavassini M6, Mombelli M6, van Delden C7, Frauenfelder T8, Montet X9, Beigelman-Aubry C10, Arampatzis S11, Ebner L3¹.

Indian J Crit Care Med. 2015 Jan;19(1):34-7. Paroxysmal sympathetic hyperactivity in neurological critical care. Verma R1, Giri P1, Rizvi I1².

Still on page 3, the roles for Heart rate monitoring are presented in a limited way
Tachycardia is common and directly associated with TBM.

West Indian Med J. 2015 Dec;64(5):543-547. Epub 2016 Apr 29. Paroxysmal Sympathetic Hyperactivity in a Child with Tuberculous Meningitis A Case Study and Review of Related Literature. Xu Y1, Wan L2, Ning J2, Guo W2, Ren L2³.

Int J Infect Dis. 2010 Jul;14(7):e586-91. Tuberculous meningitis in HIV-infected patients in Brazil: clinical and laboratory characteristics and factors associated with mortality.

Croda MG1, Vidal JE, Hernández AV, Dal Molin T, Gualberto FA, de Oliveira AC⁴.

Author information

Still under temperature monitoring. The reader is interested in clues as to how to differentiate the temperature of TBM from super imposed infection?

Table 1 page 4: Relevance of the previous BCG scar?

I propose that the tests be separated in to those with high utility like gene expert, low CSF glucose from those with low utility like AAFB, culture. Imaging must always be contrasted unless contraindicated

Table 2: The part on monitoring for GIT bleeding, what is the practical way of doing this? Not so much information about its relevance in TBM patients.

If possible the authors should expound on how to suspect superimposed infections

Table 4 page 7. In a rapidly deteriorating patient with TBM, paradoxical reactions like IRIS needs to be mentioned especially in HIV positive patients. And cerebral venous thrombosis(BMJ Case Rep. 2013 Aug 5;2013. pii: bcr2013009892⁵. Indian J Pediatr. 2019 Apr;86(4):371-378. Epub 2019 Jan 9⁶.

Risks of prolonged hospital admission should include DVT.

Page 9 Last paragraph under neuroimaging needs a reference.

References

1. Christie A, Walti L, Charimo J, Rauch A, et al.: Imaging patterns of *Pneumocystis jirovecii* pneumonia in HIV-positive and renal transplant patients – a multicentre study. *Swiss Medical Weekly*. 2019. [Publisher Full Text](#)
2. Rizvi I, Verma R, Giri P: Paroxysmal sympathetic hyperactivity in neurological critical care. *Indian Journal of Critical Care Medicine*. 2015; **19** (1): 34-37 [Publisher Full Text](#)
3. Xu Y, Wan L, Ning J, Guo W, et al.: Paroxysmal Sympathetic Hyperactivity in a Child with Tuberculous Meningitis: A Case Study and Review of Related Literature. *West Indian Medical Journal* . 2016. [Publisher Full Text](#)
4. Croda M, Vidal J, Hernández A, Dal Molin T, et al.: Tuberculous meningitis in HIV-infected patients in Brazil: clinical and laboratory characteristics and factors associated with mortality. *International Journal of Infectious Diseases*. 2010; **14** (7): e586-e591 [Publisher Full Text](#)
5. Verma R, Lalla R, Patil T, Tiwari N: A rare presentation of cerebral venous sinus thrombosis associated with tubercular meningitis. *Case Reports*. 2013; **2013** (aug05 1). [Publisher Full Text](#)
6. Dhawan S, Chatterjee D, Radotra B, Vaidya P, et al.: A Child with Tuberculous Meningitis Complicated by Cortical Venous and Cerebral Sino-Venous Thrombosis. *The Indian Journal of Pediatrics*. 2019; **86** (4): 371-378 [Publisher Full Text](#)

Is the rationale for the Open Letter provided in sufficient detail?

Yes

Does the article adequately reference differing views and opinions?

Yes

Are all factual statements correct, and are statements and arguments made adequately supported by citations?

Partly

Is the Open Letter written in accessible language?

Yes

Where applicable, are recommendations and next steps explained clearly for others to follow?

Partly

Competing Interests: No competing interests were disclosed.

Reviewer Expertise: Internal Medicine

I confirm that I have read this submission and believe that I have an appropriate level of expertise to confirm that it is of an acceptable scientific standard.

Author Response 22 Jan 2020

Joseph Donovan, Oxford University Clinical Research Unit, Centre for Tropical Medicine, Ho Chi Minh City, Vietnam

Dear Dr Abdu Kisekka Musubire,
Thank you for reviewing our open letter "Checklists to guide the supportive and critical care of tuberculous meningitis".
Please find below our point by point responses.

1. Box 1 page 3: Define the extremes of ages for the readers

'Older age' is based upon a Cox regression model for 9-month survival in HIV uninfected adults with TBM.¹ An increase in age (per +10 years) gave a hazard ratio of 1.24 (95% CI 1.15-1.34, p <0.001). In this HIV uninfected group, median age was 40 years (IQR 27-56 years). Regarding 'younger age', in a study of 214 children with TBM (mean age at presentation 4.1 years), 49 patients (23%) died.² 63% of deaths were in age 5 or younger; however this age group is represented more frequently. Defining 'extremes of age' in adults is challenging; these are based on age ranges of individual studies. In paediatrics it is broadly accepted that most cases occur in children < 5yrs, and therefore more deaths are likely in that age range.

2. Under respiratory monitoring: page 3, Pneumothorax is rare in PJP

We have added here that this is rare and referenced this³

3. Still on page 3, the roles for Heart rate monitoring are presented in a limited way
Tachycardia is common and directly associated with TBM.

Tachycardia is common with many medical conditions. In our article we have tried to focus on critical care of TBM. Whilst it clearly can occur, we do not feel paroxysmal sympathetic hyperactivity is sufficiently associated with TBM to include here. In the first cited study,⁴ there was only one case of TBM associated with paroxysmal sympathetic hyperactivity. The second cited study⁵ notes it is rare in TBM. We

note the reference describing tachycardia being associated with mortality in a HIV infected cohort.⁶

4. Still under temperature monitoring. The reader is interested in clues as to how to differentiate the temperature of TBM from super imposed infection?

This is a valid point, and we are not suggesting there are clues to differentiate these. We wish to note that fever in TBM may not only be due to TBM disease. Resolution of TBM-associated fever, followed by the development of new fever, may indicate new infection.

5. Table 1 page 4: Relevance of the previous BCG scar?

BCG vaccine protects against meningeal and miliary TB in infants ⁷

6. I propose that the tests be separated in to those with high utility like gene expert, low CSF glucose from those with low utility like AAFB, culture.

We feel the value of these tests will vary by site, and have therefore kept these listed together.

7. Imaging must always be contrasted unless contraindicated

This is a good point. However the addition of contrast may not always be possible. We have added 'preferably with contrast' to table 4

8. Table 2: The part on monitoring for GIT bleeding, what is the practical way of doing this? Not so much information about its relevance in TBM patients.

Recommending how to practically monitor for GI bleeding goes beyond the scope of this article. This adverse event is relevant given frequent dexamethasone use in TBM, and the increasing evidence base for aspirin ⁸

9. If possible the authors should expound on how to suspect superimposed infections

Although this is an important component to TBM care, we feel expanding on this is beyond the scope of this article

10. Table 4 page 7. In a rapidly deteriorating patient with TBM, paradoxical reactions like IRIS needs to be mentioned especially in HIV positive patients. And cerebral venous thrombosis(BMJ Case Rep. 2013 Aug 5;2013. pii: bcr2013009892⁵. Indian J Pediatr. 2019 Apr;86(4):371-378. Epub 2019 Jan 9⁶.

We have now specifically mentioned IRIS and cerebral sinus thrombosis in table 4. In the supporting document we have added the sentence 'Cerebral venous thrombosis is an unusual cause of acute neurological deterioration in TBM, but has been described' with references.

11. Risks of prolonged hospital admission should include DVT.

We have added 'Deep vein thrombosis is a risk of prolonged critical care admission'

12. Page 9 Last paragraph under neuroimaging needs a reference.

We have discussed the repeat imaging with references in the preceding paragraphs, and repeat imaging after placing hardware in the brain is standard neurosurgical practice

- 1 Thao LTP, Heemskerk AD, Geskus RB, *et al.* Prognostic Models for 9-Month Mortality in Tuberculous Meningitis. *Clin Infect Dis* 2018; **66**: 523–32.
- 2 Yaramış A, Gurkan F, Eevli M, *et al.* Central nervous system tuberculosis in children: a review of 214 cases. *Pediatrics* 1998; **102**: E49.
- 3 Christe A, Walti L, Charimo J, *et al.* Imaging patterns of *Pneumocystis jirovecii* pneumonia in HIV-positive and renal transplant patients - a multicentre study. *Swiss Med Wkly* 2019; **149**: w20130.
- 4 Verma R, Giri P, Rizvi I. Paroxysmal sympathetic hyperactivity in neurological critical care. *Indian J Crit Care Med* 2015; **19**: 34–7.
- 5 Xu Y, Wan L, Ning J, Guo W, Ren L. Paroxysmal Sympathetic Hyperactivity in a Child with Tuberculous Meningitis A Case Study and Review of Related Literature. *West Indian Med J* 2015; **64**: 543–7.
- 6 Croda MG, Vidal JE, Hernández A V, Dal Molin T, Gualberto FA, de Oliveira ACP. Tuberculous meningitis in HIV-infected patients in Brazil: clinical and laboratory characteristics and factors associated with mortality. *Int J Infect Dis* 2010; **14**: e586-91.
- 7 Mangtani P, Abubakar I, Ariti C, *et al.* Protection by BCG vaccine against tuberculosis: A systematic review of randomized controlled trials. *Clin Infect Dis* 2014; **58**: 470–80.
- 8 Mai NT, Dobbs N, Phu NH, *et al.* A randomised double blind placebo controlled phase 2 trial of adjunctive aspirin for tuberculous meningitis in HIV-uninfected adults. *Elife* 2018; **7**. DOI:10.7554/eLife.33478.

Competing Interests: No competing interests were disclosed.