

Case report

## Adrenoleukodystrophy in the Differential Diagnosis of Boys Presenting with Primary Adrenal Insufficiency without Adrenal Antibodies

Short Title: Adrenal insufficiency as a red flag for CALD

Michael R Ryalls MBB BCh\*, FRCPCH, MRCP(UK)<sup>1</sup>, Hoong-Wei Gan BMedSci, BMBS, MSc, MRCPCH<sup>2,3</sup>, James E Davison, MBChB, PhD, FRCPCH<sup>4</sup>

<sup>1</sup>Paediatric Department, Royal Surrey County Hospital NHS Foundation Trust, Guildford, UK

<sup>2</sup>Paediatric Endocrinology & Diabetes, Great Ormond Street Hospital for Children NHS Foundation Trust, London, UK

<sup>3</sup>University College of London Institute of Child Health, London, UK

<sup>4</sup>Metabolic Medicine, Great Ormond Street Hospital for Children NHS Foundation Trust, London UK

### What is Already Known

- The cerebral form (CALD) of adrenoleukodystrophy (ALD) is characterized by progressive inflammatory demyelination resulting in loss of neurological function and early death.
- Approximately 70-80% of boys have impaired adrenal function at the time of ALD diagnosis.
- 

### What This Study Adds

- Despite appropriate screening, some ALD cases may still be missed when relying on very-long chain fatty acid (VLCFA) levels alone, since some mutations may result in initial normal levels of VLCFA.
- The need for early CALD diagnosis in order to initiate timely treatment mandates awareness of the potential need for repetitive VLCFA screening of boys with unexplained antibody negative primary adrenal insufficiency.

### Abstract

Background: Adrenoleukodystrophy (ALD) is an X-linked, metabolic disorder caused by deficiency of peroxisomal ALD protein resulting in accumulation of very-long chain fatty acids (VLCFA) primarily in the adrenal cortex and central nervous system. Approximately 35-40% of boys with ALD develop cerebral ALD (CALD), which causes rapidly progressive cerebral demyelination, loss of neurologic function, and death. Approximately **70-80%** of boys with ALD **have impaired adrenal function** prior to the onset of neurologic symptoms. Case Report: We present a boy who had recurrent episodes of hypoglycaemia from age 2 years and was diagnosed with adrenal insufficiency without adrenal antibodies at age 5.5 years. Results: Following initial normal VLCFA levels, subsequent VLCFA analysis demonstrated elevated C26 fatty acids consistent with peroxisomal dysfunction and suggestive of ALD, which was confirmed via molecular genetic analysis of the *ABCD1* gene. Brain imaging evidence of cerebral involvement emerged at age 7, and the child underwent successful allogeneic hematopoietic stem cell transplantation. At last assessment (11.5 years old), he was performing as expected for age. Conclusion: This case highlights the importance of pursuing a diagnosis when clinical suspicion remains, and the significance of VLCFA analysis for patients with adrenal insufficiency without adrenal antibodies in prompting an ALD diagnosis. Subsequent brain imaging surveillance can detect early, pre-symptomatic cerebral disease allowing for timely treatment and successful arrest of cerebral disease progression.

**Keywords:** adrenal insufficiency; adrenoleukodystrophy; very-long chain fatty acids; x-linked

### Corresponding Author/reprint requests\*

Michael R Ryalls, Paediatric Department, Royal Surrey County Hospital NHS Foundation Trust, Egerton Road Guildford, Surrey, GU2 7XX, UK

Tel: 01483 571122

Asst: 01483 464182

E-mail: mryalls@nhs.net

06.01.2020

26.04.2020

0000-0002-1974-2667

### Introduction

Adrenoleukodystrophy (ALD) is a rare X-linked metabolic disorder caused by mutations in the *ABCD1* gene that result in deficiency of peroxisomal membrane ALD protein and accumulation of very-long chain fatty acids (VLCFA) in tissues and plasma [1, 2]. The most severe phenotype is the cerebral form (CALD), which develops in 35-40% of at-risk male children typically between the ages of 3 and 12 years [1]. CALD rapidly progresses with inflammatory cerebral demyelination, loss of neurological function, and early death.

ALD was added to the recommended uniform screening panel (RUSP) in the United States in 2016, but newborn screening (NBS) remains limited both within the US and worldwide [3]. Therefore, early identification of ALD remains challenging due to nonspecific initial symptoms that overlap with other medical and developmental issues. Mutations in the *ABCD1* gene are associated with genetic forms of primary adrenal insufficiency (PAI) [4-6], therefore PAI in boys in the absence of adrenal antibodies can be an early red flag for a potential ALD diagnosis. Unexplained PAI may be the only clinical sign prior to the onset of neurologic symptoms in boys ultimately diagnosed with CALD [7, 8].

Early detection of CALD is critical since allogeneic hematopoietic stem cell transplantation (HSCT) has the potential to stabilize cerebral disease progression, but is only effective if performed in the early stages of cerebral disease [9, 10]. While not possible to determine which children with ALD will develop CALD based on genotype, plasma VLCFA levels, or family history [11, 12], monitoring at-risk boys for MRI abnormalities can successfully detect changes indicative of CALD prior to the onset of neurological symptoms [13, 14]. HSCT is only indicated once imaging detects white matter changes indicative of progression to CALD, and current management guidelines recommend repeating MRIs in presymptomatic boys with ALD every 6 months between the ages of 3 and 12 years [15]. Given this need for early ALD diagnosis and monitoring for CALD, ALD should be included in the differential diagnosis of boys presenting with PAI without adrenal antibodies. The following case presentation highlights the clinical course in a boy who was diagnosed with ALD through presentation with PAI, and who upon progression to CALD, received a timely and successful allogeneic stem cell transplant.

#### Case Report and Results

A white male infant was born at term to non-consanguineous parents. There were no antenatal or perinatal concerns and early childhood was reported to be normal with normal growth parameters. No hyperpigmentation was ever noted. At 2 years of age he was admitted to a paediatric resuscitation bay via the local GP walk in service following a 24 hour vomiting illness with subsequent collapse, convulsion and fever with acidosis (pH 7.279, base deficit 9.2 mmol/l), cardiac compensation (pulse 161/minute with mean peripheral BP 84 mm Hg) requiring 20 ml/kg saline bolus, and hypoglycaemia (glucose 1.1 mmol/L; 19.82 mg/dL) which responded rapidly to 5 ml/kg 10% dextrose. He also had elevated urine ketones (+++ on urine dipstick test), and his plasma cortisol measured after normalisation of glucose, was 320 nmol/L. Bedside sodium was 131 mmol/L and potassium 3.2 mmol/L. He recovered promptly with rehydration and dextrose infusions with intravenous antibiotics and was discharged after a full infection screen including lumbar puncture was negative, tolerating oral food and fluids, 48 hours later with a presumptive diagnosis of hypoglycaemia following prolonged vomiting with a febrile convulsion.

At 2.5 years, he had an episode of multiple febrile convulsions, and again presented with hypoglycaemia (glucose 1.2 mmol/L; 21.62 mg/dL; sodium 137 mmol/L; potassium 3.8 mmol/L) and elevated urine ketones (+++ on urine dipstick test). Plasma insulin (46 pmol/L) and C-Peptide (350-315 pmol/L) were found to be inappropriately elevated at the time of hypoglycaemia. Plasma cortisol was 470 nmol/L. The hypoglycaemic episodes were initially ascribed to idiopathic ketotic hypoglycaemia. In view of the multiple episodes of hypoglycaemia and hyperinsulinaemia on this most recent admission, investigations included a 24-hour glucose profile and controlled 17-hour fast, both of which did not demonstrate any hypoglycaemia but normal suppression of insulin and mobilisation of ketone bodies at the end of the fast. Random plasma cortisol concentrations were 281 and 226 nmol/l at 1200 and 1800 hours respectively.

A subsequent hypoglycaemic event (glucose 1.4 mmol/L; sodium 139 mmol/L; potassium 3.9 mmol/L) with vomiting at age 5.2 years was associated with a plasma cortisol of 553 nmol/L. The supervising clinician changed at this time, and because of recurrent unexplained hypoglycaemia, a standard synacthen (tetracosactide) test was performed and showed adrenal insufficiency (Table 1 cortisol and ACTH test 1). A repeat synacthen test was performed at age 5.5 years in view of the relatively high cortisol at the time of the last hypoglycaemia event and confirmed these findings (Table 1, cortisol and ACTH test 2). Adrenal antibodies were negative, and the boy was commenced on standard hydrocortisone replacement at 10.0 mg/m<sup>2</sup>/day in divided doses.

In view of the adrenal failure and negative adrenal antibodies, an analysis of VLCFA levels was ordered (using UKAS accredited laboratories), although due to family reasons there was a delay of several months in performance of these tests. VLCFA testing typically assesses abnormalities in three parameters: the level of hexacosanoic acid (C26:0), and the ratio of hexacosanoic acid to tetracosanoic acid (C26:0/C24:0) and to docosanoic acid (C26:0/C22:0) [2]. Initial VLCFA tests at age 6.5 years showed normal C26/C22 and C24/C22 levels (Table 1, VLCFA Laboratory A test 1). Continued clinical suspicion and negative adrenal antibodies prompted repeat VLCFA tests using a different laboratory at 7 and 7.5 years of age (Table 1, Laboratory B, test 2 and 3) that showed elevated C26 fatty acids with moderately raised C26/C22 ratio, mildly raised C24/C22 ratio, and normal phytanic and pristanic acid levels (pristanic and phytanic acids are branched chain fatty acids that undergo oxidation in peroxisomes, and are typically elevated in peroxisome biogenesis disorders in the Zellweger spectrum, but not in ALD). These findings were consistent with a disturbance in peroxisomal function suggestive of ALD rather than a peroxisomal biogenesis disorder. Subsequent molecular genetic analysis of the *ABCD1* gene identified a previously reported pathogenic hemizygous mutation (c.1849C>T, [p.Arg617Cys]), which on family testing was confirmed to be maternally inherited. The child was commenced on Lorenzo's oil (oleic acid and erucic acid 4:1, such that 20% of energy requirements in diet came from Lorenzo's oil) available for use in UK with provision for monitoring on a non-research basis and a low fat diet at 7.5 years of age following the second confirmatory VLCFA assessment.

At 7.5 years of age, baseline MRI brain scan identified features possibly consistent with cerebral ALD (Figure 1), with signal abnormality in the splenium of the corpus callosum and subtle changes in the deep parietal white matter, but no convincing gadolinium enhancement (an indicator of active inflammation and hallmark of cerebral disease). The MRI Loes score, a 34-point scale used to measure the extent of demyelinating brain lesions [16], was assessed as 2 with bilateral splenium of corpus callosum and bilateral parietal white matter central change. A repeat MRI after 3 months showed some progression of the lesion in the splenium with patchy signal change in the parietal lobes and mild prominence of cerebellar folia and sulci (Loes score assessed as 3 with now additional mild symmetrical cerebellar atrophy. Although splenium lesion had progressed in size, this did not alter the Loes scoring of the already bilateral splenium lesion). Neurological examination at this stage was normal. The child had a history of temper tantrums but no other significant behavioural or psychological problems. In view of the MRI findings suggestive of progressing cerebral ALD, allogeneic HSCT was indicated.

At age 8 years, he underwent 10/10 HLA-matched unrelated allogeneic HSCT with pretransplant conditioning consisting of a combination of busulfan (1.9 mg/kg to a target cumulative AUC of 80 mg/l/hr), fludarabine (40 mg/m<sup>2</sup> x 4 doses) and alemtuzumab (0.2 mg/kg x 5 doses). The total white cell dose was 3.68x10<sup>8</sup>/kg with a CD34 count of 7.03x 10<sup>6</sup>/kg and CD3 count 0.36x10<sup>8</sup>/kg. There were no significant peri-transplant complications. Transplant outcome was excellent with 100% engraftment in myeloid lineage and stable mixed chimerism in T-cells (82% donor). Brain MRI imaging following transplant

showed initial progression of the lesion in the splenium at one year post-transplant, but subsequent stabilisation with no further progression through 3 years post-treatment (Figure 1) (Loes score remained 3).

At last assessment at 11.5 years of age, the boy was attending mainstream secondary school where he was performing very well academically. He was on the 25<sup>th</sup> percentile for weight and 50<sup>th</sup> for height, and was being assessed for delayed puberty as possible late sequelae of either the transplant conditioning or primary testicular dysfunction due to ALD. He continued to receive hydrocortisone replacement but has not required mineralocorticoid replacement. Neurological examination revealed moderately brisk reflexes in the lower limbs but normal tone and power, and no gait disturbance.

### Discussion

Recognition of PAI without adrenal antibodies in this boy with recurrent hypoglycaemic episodes prompted repeated analysis of VLCFAs and identification of the underlying ALD diagnosis before the onset of neurological symptoms. MRI surveillance detected early pre-symptomatic cerebral disease and permitted timely allogeneic HSCT, which was successful in arresting the progression of the cerebral disease. Glucocorticoid replacement requirements, stress-dosing guidelines, and monitoring for mineralocorticoid deficiency for patients with ALD are generally the same as those in other forms of PAI [17], and the patient continues on hydrocortisone replacement therapy without the need for mineralocorticoid supplementation currently. Mineralocorticoid deficiency is **not typically seen less common** in ALD [7, 18], in part due to accumulation of VLCFA preferentially in the zona fasciculata and zona reticularis, with a relative sparing of the zona glomerulosa.

Since there is no ability to predict which boys diagnosed with ALD will develop CALD, vigilant MRI monitoring must be implemented in order to detect brain changes indicative of progression to CALD and ensure early HSCT [15]. Allogeneic HSCT has been shown to have a beneficial effect on clinical indices of disease and long-term survival, but outcomes are more favourable if transplant is performed in the early stages of cerebral disease [10, 19, 20].

PAI can result from genetic or acquired diseases that affect adrenal function. Adrenal insufficiency in ALD may arise as a result of abnormal VLCFA accumulation that alters the viscosity of adrenocortical cell membranes, and prevents the stimulatory effects of adrenocorticotropin (ACTH) on adrenocortical cells by inhibiting ACTH receptor binding [21]. Impaired activity of ACTH leads to primary atrophy of the adrenal cortex with resulting cortisol deficiency. ALD is estimated to account for up to 5% of unexplained PAI cases [5, 6]. Among boys with ALD, approximately 70-80% have impaired adrenal function at the time of diagnosis [7, 8, 18].

In retrospective analyses of boys with ALD, PAI was the presenting and only sign in 25%-37% of patients [8, 18]. There were delays of between 1 and 10 years between diagnosis of PAI and diagnosis of ALD for approximately half of the boys in the study. Delays in ALD diagnosis were associated with higher Loes scores at the time of evaluation for HSCT, progression of disease after HSCT, and decreased survival [8]. These data emphasize that all boys with unexplained PAI should be screened for ALD.

Published diagnostic guidelines for PAI include recommended VLCFA testing for males with PAI who are negative for 21-hydroxylase (21-OH) antibodies, and concurrent testing for adrenal antibodies and VLCFA through accredited laboratories in preadolescent boys [22]. However, despite these guidelines and older cases or case series highlighting the need to screen children and adult males with unexplained PAI for ALD [23-25], a recent study highlights the continued need for education that PAI in the absence of adrenal antibodies should be a red flag for a potential ALD diagnosis. Age related ranges for VLCFA need to be used. Furthermore, other confounding factors such as diets rich in rapeseed or mustard seed oils, which can potentially be associated with false negative results, need to be considered when performing VLCFA tests. Results from a pilot educational program intended to encourage reflex VLCFA testing in cases of PAI with negative 21-OH antibodies suggest that gaps in reflex testing remain [26].

Although NBS programs will assist in early identification and surveillance of boys with ALD, [27] the potential for delayed diagnosis persists where NBS is not available and where absence of family history precludes family screening. This case demonstrates that some ALD cases may still be missed when relying on VLCFA levels alone, since some mutations may not only result in initial normal levels of VLCFA but varying levels of adrenal insufficiency requiring clinical vigilance and suspicion for a potential underlying VLCFA abnormality. The need for early diagnosis in order to initiate current and future treatments mandates pursuit of a clear diagnosis and awareness of the need to screen boys with unexplained PAI for ALD.

### Acknowledgments

The authors thank the patient and his family, as well as Dr. Robert Chiesa of the Bone Marrow Transplant Unit at the Great Ormond Street Hospital for Children and NHS Foundation Trust, London, UK, for his contribution to the care of the patient. The authors also thank Iva Ivanovska Holder, PhD, bluebird bio, Inc., for providing editorial assistance.

### Statement of Ethics

Committee review was not required for a case study. The patient's family provided informed consent.

### Disclosure Statement

The authors have no conflicts of interest to declare.

### Funding Sources

Patrice Ferriola, PhD provided assistance with manuscript writing and was funded by bluebird bio, Inc., Cambridge, MA, USA.

### Author Contributions

MR and JED provided the case history clinical evidence, and H-WG provided details of post-transplant endocrine care. All authors edited all manuscript drafts.

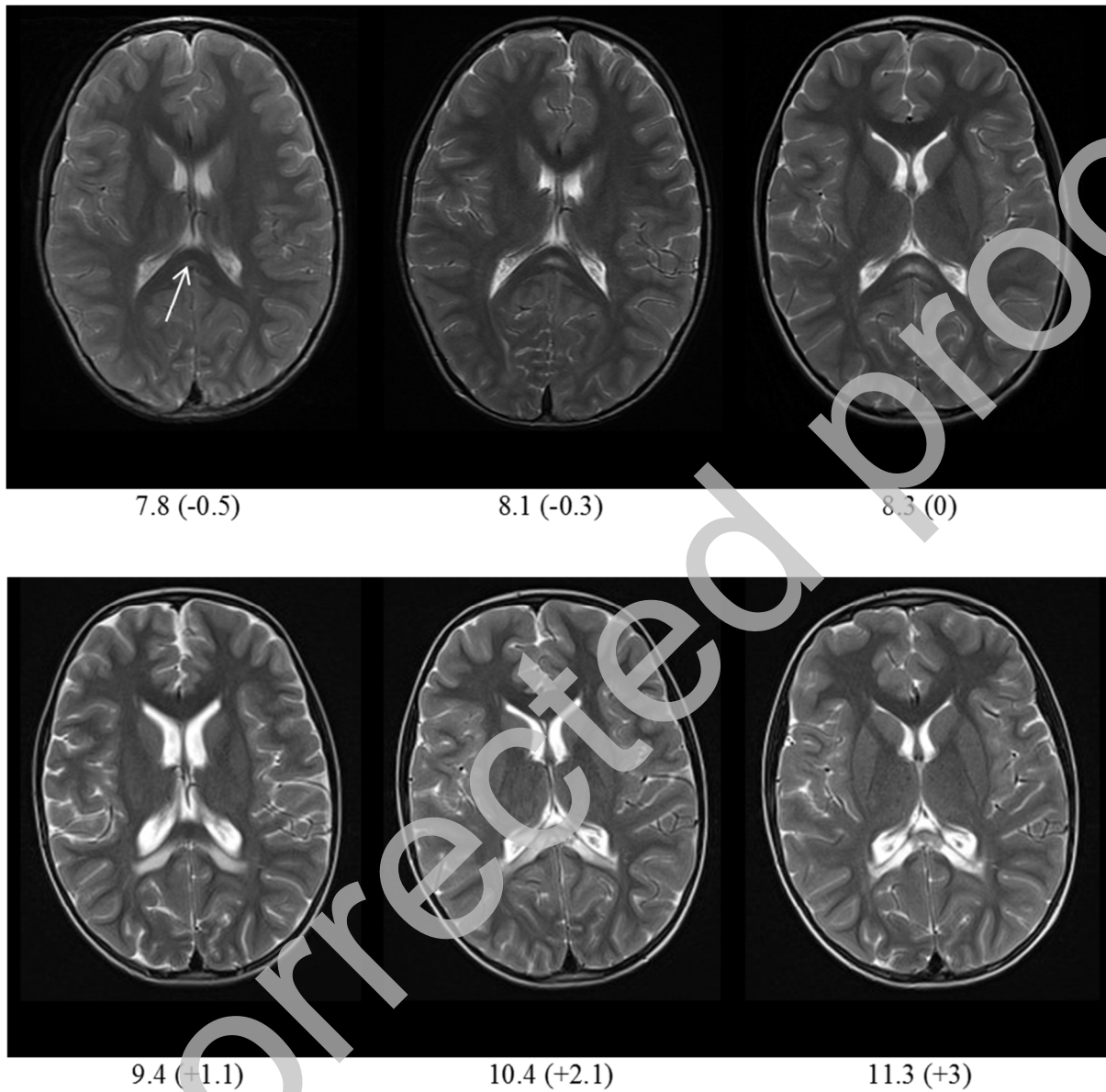
### References

1. Moser HW, Mahmood A, Raymond GV. X-linked adrenoleukodystrophy. *Nat Clin Pract Neurol* 2007;3:140-51.
2. Raymond GV, Moser AB, Fatemi A. X-Linked Adrenoleukodystrophy. In: Adam MP, Ardinger HH, Pagon RA, Wallace SE, Bean LJH, Stephens K, et al., editors. *GeneReviews*(R). Seattle (WA): University of Washington, Seattle

University of Washington, Seattle. GeneReviews is a registered trademark of the University of Washington, Seattle. All rights reserved.; 1999 (last updated 2018).

3. Martinez-Morillo E, Prieto Garcia B, Alvarez Menendez FV. Challenges for Worldwide Harmonization of Newborn Screening Programs. *Clin Chem* 2016;62:689-98.
4. Brett EM, Auchus RJ. Genetic forms of adrenal insufficiency. *Endocr Pract* 2015;21:395-9.
5. Perry R, Kecha O, Paquette J, et al. Primary adrenal insufficiency in children: twenty years experience at the Sainte-Justine Hospital, Montreal. *J Clin Endocrinol Metab* 2005;90:3243-50.
6. Guran T, Buonocore F, Saka N, et al. Rare Causes of Primary Adrenal Insufficiency: Genetic and Clinical Characterization of a Large Nationwide Cohort. *J Clin Endocrinol Metab* 2016;101:284-92.
7. Dubey P, Raymond GV, Moser AB, et al. Adrenal insufficiency in asymptomatic adrenoleukodystrophy patients identified by very long-chain fatty acid screening. *J Pediatr* 2005;146:528-32.
8. Polgreen LE, Chahla S, Miller W, et al. Early diagnosis of cerebral X-linked adrenoleukodystrophy in boys with Addison's disease improves survival and neurological outcomes. *Eur J Pediatr* 2011;170:1049-54.
9. Mahmood A, Raymond GV, Dubey P, et al. Survival analysis of haematopoietic cell transplantation for childhood cerebral X-linked adrenoleukodystrophy: a comparison study. *Lancet Neurol* 2007;6:687-92.
10. Miller WP, Rothman SM, Nascene D, et al. Outcomes after allogeneic hematopoietic cell transplantation for childhood cerebral adrenoleukodystrophy: the largest single-institution cohort report. *Blood* 2011;118:1971-8.
11. Wiesinger C, Eichler FS, Berger J. The genetic landscape of X-linked adrenoleukodystrophy: inheritance, mutations, modifier genes, and diagnosis. *Appl Clin Genet* 2015;8:109-21.
12. Moser AB, Kreiter N, Bezman L, et al. Plasma very long chain fatty acids in 3,000 peroxisome disease patients and 29,000 controls. *Ann Neurol* 1999;45:100-10.
13. Tran C, Patel J, Stacy H, et al. Long-term outcome of patients with X-linked adrenoleukodystrophy: A retrospective cohort study. *Eur J Paediatr Neurol* 2017;21:600-9.
14. Moser HW, Loes DJ, Melhem ER, et al. X-Linked adrenoleukodystrophy: overview and prognosis as a function of age and brain magnetic resonance imaging abnormality. A study involving 372 patients. *Neuropediatrics* 2000;31:227-39.
15. Engelen M, Kemp S, de Visser M, et al. X-linked adrenoleukodystrophy (X-ALD): clinical presentation and guidelines for diagnosis, follow-up and management. *Orphanet J Rare Dis* 2012;7:51.
16. Loes DJ, Hite S, Moser H, et al. Adrenoleukodystrophy: a scoring method for brain MR observations. *AJNR Am J Neuroradiol* 1994;15:1761-6.
17. Burtman E, Regelman MO. Endocrine Dysfunction in X-Linked Adrenoleukodystrophy. *Endocrinol Metab Clin North Am* 2016;45:295-309.
18. Huffnagel IC, Laheji FK, Aziz-Bose R, et al. The Natural History of Adrenal Insufficiency in X-Linked Adrenoleukodystrophy: An International Collaboration. *J Clin Endocrinol Metab* 2019;104:118-26.
19. Peters C, Charnas LR, Tan Y, et al. Cerebral X-linked adrenoleukodystrophy: the international hematopoietic cell transplantation experience from 1982 to 1999. *Blood* 2004;104:881-8.
20. Raymond GV, Aubourg P, Paker A, et al. Survival and Functional Outcomes in Boys with Cerebral Adrenoleukodystrophy with and without Hematopoietic Stem Cell Transplantation. *Biol Blood Marrow Transplant* 2019;25:538-48.
21. Whitcomb RW, Linehan WM, Knazek RA. Effects of long-chain, saturated fatty acids on membrane microviscosity and adrenocorticotropin responsiveness of human adrenocortical cells in vitro. *J Clin Invest* 1988;81:185-8.
22. Bornstein SR, Alolio B, Arit W, et al. Diagnosis and Treatment of Primary Adrenal Insufficiency: An Endocrine Society Clinical Practice Guideline. *J Clin Endocrinol Metab* 2016;101:364-89.
23. Nascimento M, Rodrigues N, Espada F, et al. Adrenoleukodystrophy: a forgotten diagnosis in children with primary Addison's disease. *BMJ Case Rep* 2012;2012.
24. Ronghe MD, Barton J, Jardine PE, et al. The importance of testing for adrenoleukodystrophy in males with idiopathic Addison's disease. *Arch Dis Child* 2002;86:185-9.
25. Laureti S, Casucci G, Santeusano F, et al. X-linked adrenoleukodystrophy is a frequent cause of idiopathic Addison's disease in young adult male patients. *J Clin Endocrinol Metab* 1996;81:470-4.
26. Ryalls M, Gan H-W, Biedenkapp J, et al. Identification of X-linked adrenoleukodystrophy in boys presenting with adrenal insufficiency in the absence of adrenal antibodies. *Horm Res Paediatrics* 2018;82 (supp 1).
27. Vogel BH, Bradley SE, Adams DJ, et al. Newborn screening for X-linked adrenoleukodystrophy in New York State: diagnostic protocol, surveillance protocol and treatment guidelines. *Mol Genet Metab* 2015;114:599-603.

**Figure 1:** Brain magnetic resonance imaging, T2-weighted axial images. Top row: pre-transplant, bottom row post-transplant. Interval of scan in years (years before [-] or after [+] transplant). Arrow indicates increased signal lesion in splenium of corpus callosum that progressively enlarged pre-transplant, further progressed at 1.1 year post-transplant, but subsequent stabilisation



**TABLE 1** Results of Tests Evaluating Cortisol, ACTH, and VLCFA levels

Test			
<b>Standard Short Synacthen</b>			
	<b>Time (mins)</b>	<b>Test 1</b>	<b>Test 2</b>
Cortisol nmol/l	0	178	226
(Normal: rise above 550	30	<b>163</b>	<b>201</b>
nmol/l with an increment of	60	<b>157</b>	<b>200</b>
>200 nmol/l)			
ACTH ng/l (normal <50)		<b>1106</b>	<b>522</b>
<b>VLCFA Analyses</b>			
	<b>Laboratory A</b>	<b>Laboratory B</b>	

	Test 1	Reference	Test 2	Test 3	Reference
C22 (μmol/L)	NA	NA	43.3	47.6	33.2 - 96.3
C24 (μmol/L)	NA	NA	63.0	68.3	25.2 - 71.4
C26 (μmol/L)	NA	NA	<b>3.32</b>	<b>3.72</b>	0.23 - 1.79
C24/C22 ratio	0.95	<1.4	<b>1.45</b>	<b>1.43</b>	0 - 1.01
C26/C22 ratio	0.52	<0.7	<b>0.077</b>	<b>0.078</b>	0 - 0.026
Phytanate (μmol/L)	NA	NA	2.89	6.11	0 - 15.00
Pristanate (μmol/L)	NA	NA	0.24	0.55	0 - 2.00

NA not available

Bold numbers indicate parameters outside of normal references range