

**CASE REPORT**

# A novel homozygous variant extending the peripheral myelin protein 22 by 9 amino acids causes early-onset Charcot-Marie-Tooth disease with predominant severe sensory ataxia

Alberto A. Zambon<sup>1</sup> | Matthew Pitt<sup>2</sup> | Matilde Laurà<sup>3</sup> | James M. Polke<sup>3</sup> | Mary M. Reilly<sup>3</sup> | Francesco Muntoni<sup>1,4</sup>

<sup>1</sup>Dubowitz Neuromuscular Centre, UCL Great Ormond Street Institute of Child Health & Great Ormond Street Hospital, London, UK

<sup>2</sup>Department of Clinical Neurophysiology, Great Ormond Street Hospital for Children NHS Foundation Trust, London, UK

<sup>3</sup>MRC Centre for Neuromuscular Diseases, National Hospital for Neurology and Neurosurgery and UCL Queen Square Institute of Neurology, London, UK

<sup>4</sup>NIHR Great Ormond Street Hospital Biomedical Research Centre, Great Ormond Street Institute of Child Health, University College London & Great Ormond Street Hospital Trust, London, UK

**Correspondence**

Francesco Muntoni, 30 Guilford Street, London WC1N 1EH, UK.  
Email: f.muntoni@ucl.ac.uk

**Abstract**

Peripheral myelin protein 22 (PMP22) related neuropathies account for over 50% of inherited peripheral neuropathies. A gene copy variation results in CMT1A (duplication) and hereditary neuropathy with liability to pressure palsies (HNPP; single deletion). Point mutations comprise both phenotypes. The underlying pathological mechanisms are incompletely understood and biallelic mutations of *PMP22* are very rare. We describe a 9-year-old girl who presented before the age of 1 year with severe locomotor delay. She now requires support for standing and walking in view of her severe sensory ataxia. Strikingly, her muscle power and bulk are close to normal in all segments. Nerve conduction studies showed sensory-motor velocities below 5 m/s. Genetic analysis revealed a homozygous sequence change in the *PMP22* gene causing the loss of termination codon (c.483A > G; p.[\*161Trpext\*10]), extending the protein by 9 amino acids. Both heterozygous parents have neurophysiological abnormalities consistent with HNPP, consistent with this being a loss-of-function mutation. *PMP22*-deficient human models are rare but important to decipher the physiological function of the *PMP22* protein in vivo. The predominance of large fiber sensory involvement in this and other rare similar cases suggests a pivotal role played by *PMP22* in the embryogenesis of dorsal root ganglia in humans.

**KEYWORDS**

ataxia, CMT, Dejerine Sottas, early-onset neuropathy, loss-of-function, *PMP22*

**1 | BACKGROUND AND AIMS**

Peripheral myelin protein 22 (*PMP22*) related neuropathies account for over 50% of inherited peripheral neuropathies, termed Charcot-Marie-Tooth disease.<sup>1</sup> *PMP22* is a tetraspan membrane glycoprotein of the internodal myelin, the exact function of which is unknown. Variations in the *PMP22* gene copy number results in distinct clinical, neurophysiologic<sup>2</sup> and histopathological phenotypes. Most commonly,

a heterozygous 1.5 Mb duplication of chromosome 17p11.2-p12, encompassing the *PMP22* gene, causes the autosomal dominant demyelinating form (CMT1A), with onset of symptoms in the first two decades of life. A heterozygous deletion of the same region is associated with hereditary neuropathy with liability to pressure palsy (HNPP).<sup>3</sup> Lastly, *PMP22* point mutations have been described as causing both CMT1A and HNPP, in addition to a more severe demyelinating neuropathy with a congenital onset (Dejerine-Sottas disease

This is an open access article under the terms of the Creative Commons Attribution-NonCommercial License, which permits use, distribution and reproduction in any medium, provided the original work is properly cited and is not used for commercial purposes.

© 2020 The Authors. *Journal of the Peripheral Nervous System* published by Wiley Periodicals LLC on behalf of Peripheral Nerve Society.

spectrum, DSS).<sup>4</sup> Bi-allelic mutations are exceptionally rare and have been associated with early onset and prominent ataxia.<sup>5-9</sup> Here we describe a patient with a novel homozygous sequence change in the PMP22 gene presenting in the first year of life with gross motor delay due to severe sensory ataxia. Remarkably, muscle power and bulk as well as cranial nerves are clinically spared.

## 1.1 | Case Report

The proband is a 9-year-old girl born as a second child to consanguineous Afghani parents following an uneventful pregnancy with reported reduced fetal movements but no polyhydramnios. She did not require any ventilator support and was discharged home on day 3. Family history was negative for neuromuscular disorders or neurodevelopmental delay.

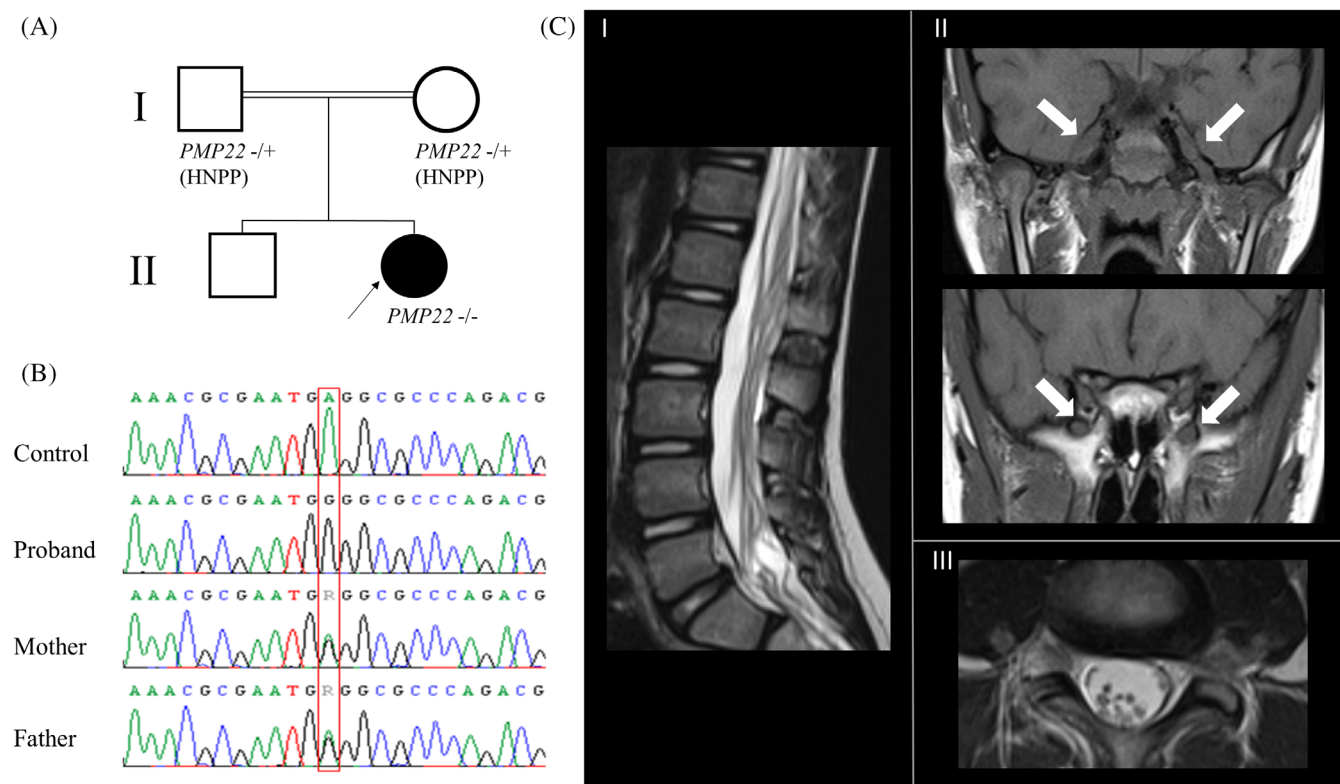
Parents started having concerns with her development and floppiness at around one year of age. Rolling was attained at the age of 12 months, sitting at one-and-a-half years, crawling at two, pulling to stand and walking (with hand support) at the age of three. She never acquired independent ambulation, but she can walk, if hand-held, for limited distances.

From the second year of age she developed mildly unusual posturing of hands and feet. Initial general and metabolic investigations

(CK, lactate, thyroid function, carnitine profile, plasma amino acids, VLCFA, purines, organic acids), karyotype, and brain magnetic resonance imaging (MRI) were normal. At the age of three and half years, neurological examination only revealed mildly reduced muscle bulk in lower limbs, proximally, attributed to her lack of exercise. Power was at least 4/5 (MRC) in all muscle groups. Feet were pronated but with no pes cavus and range of movements of all joints was normal. She was able to pull to stand but needed single hand support to stand and double-support to walk. Gait was severely ataxic. Upper limbs displayed a mild intention tremor and pseudo athetotic movements. Sensory examination was limited by age, but pain and temperature sensation were unremarkable. Reflexes were generally reduced with normal withdrawal of the plantar reflex. There was a mild speech delay, which later improved, and no overt intellectual impairment.

There have never been concerns regarding feeding, breathing, recurrent infections, sleeping or sphincter control.

She was re-assessed at the age of 7 years after being lost to follow-up. Repeat brain and spine MRI were initially reported normal. Subsequent review identified an enlargement of the second and third branches of the fifth cranial nerve (V2, V3) and mild enlargement of the cauda equina (anterior roots) (Figure 1C). No contrast-enhanced study was available. CSF analysis showed a remarkable increase of proteins (3.52 g/L; normal values 0.15-0.45).



**FIGURE 1** A, Pedigree of the reported family. B, Sanger sequencing of PMP22 depicting homozygosity for the c.483A > G p.(<sup>\*</sup>161Trpext<sup>\*</sup>10) mutation in the proband, and heterozygous parents. C, MRI scans performed at the age of seven years. (I, III) Sagittal and axial T2-weighted spinal MRI showing mild enlargement of spinal roots. (II) Coronal T1-weighted brain scan showing prominent enlargement of the V3 and V2 branches of the trigeminal nerve (indicated by arrows in the top and bottom figure, respectively). HNPP, hereditary neuropathy with liability to pressure palsy; MRI, magnetic resonance imaging

At the last clinical evaluation aged 9 years, the main features included gross truncal ataxia with necessity to hold onto a support for walking and the ability to perform only few steps unaided, with severe imbalance. Romberg's maneuver was strongly positive. Deep tendon reflexes were absent in the lower limbs, reduced in upper limbs. Muscle power was normal in all segments (including feet dorsiflexors and evertors) apart from hip flexors and extensors, in which there was a very slight weakness (MRC 4/5). Strikingly, muscle bulk was mildly reduced only in the thenar eminence bilaterally. Her feet continued to display mild varus posture with no contractures or cavus deformity. Hand function was characterized by mild intention tremor and no overt dysmetria. Light touch sensation was normal, proprioception was present but diminished.

## 1.2 | Nerve conduction studies

A nerve conduction study performed at the age of 7 years showed a severe demyelinating motor-sensory neuropathy with markedly reduced conduction velocities. Sensory responses were not elicitable. Motor responses of tibialis anterior and first dorsal interosseous were obtained through needle electrodes only (CVs 2 and 3 m/s, respectively). Concomitantly, there were only minor signs of secondary axonal degeneration on EMG.

Both parents were subsequently tested. Findings of absent or reduced sensory responses at the wrist, with prolonged distal motor latencies and motor conduction slowing at compression points gave strong neurophysiological support for a diagnosis of HNPP in both. Both parents retrospectively recalled recurrent episodes of compression-induced limb numbness.

## 1.3 | Molecular diagnosis

Following neurophysiological findings, a next-generation sequencing (NGS) panel targeting 14 genes associated with CMT1 was requested (Illumina Nextera Rapid Capture custom panel run on an Illumina NextSeq). Genetic analysis revealed a homozygous sequence change in the PMP22 gene causing loss of the termination codon (c.483A>G; p.[\*161Trpext\*10]). Both parents were heterozygous carriers of the same mutation, confirmed by Sanger sequencing (Figure 1B). This variant is predicted to extend the protein by an addition of 9 amino acids. Multiplex ligation-dependent probe amplification (MLPA, MRC Holland) analysis confirmed the presence of both copies of PMP22.

## 2 | INTERPRETATION

Despite accounting for up to 5% of all peripheral myelin protein and causing pathology in approximately 1:5000 people, the role of PMP22 in humans is still incompletely understood. To expand the current knowledge about different phenotypes, here we report a patient whose symptoms started during the first year of life and who

presented with severe sensory ataxia in absence of significant muscle weakness. Nerve conduction studies showed a severe sensory-motor involvement with motor conduction velocities below 5 m/s and non-evocable sensory action potentials, similar to what observed in DSS hypomyelination. However, the mild neurogenic EMG changes suggested sparing of the axons, hence preserved muscle power at least at last clinical assessment.

Markedly elevated CSF proteins and enlargement of cranial nerves and spinal roots, as demonstrated by MRI, are also features previously attributed to congenital hypomyelination syndrome. Genetic analysis revealed a homozygous PMP22 mutation causing the loss of termination codon. The HNPP phenotype found in both heterozygous parents points to this being a loss of function mutation. The mechanism is unknown but there are several possibilities including affecting the transcriptional processing of the mRNA, the translation of the protein, the processing/delivery of the protein within the cell or directly affecting protein function.

Increased apoptosis is evident in PMP22-deficient Schwann cells *in vitro*. However, in murine models this is only observed in aged Schwann cells and tends to be milder in PMP22 deficient cells when compared to cells harboring over-expression or toxic gain of function variants.<sup>10</sup> Interestingly, Pmp22  $-/-$  mice display severely shortened internodes and have extreme difficulties in forming myelin.<sup>11,12</sup> Contrariwise, compact myelin is appropriately formed in PMP22 $+/-$  nerves. In humans, compound heterozygosity for the chromosome 17p11.2-p12 1.5 Mb deletion with missense point mutations has been associated with a CMT1A-like phenotype.<sup>13,14</sup> The presence of the heterozygous missense variant in one individual was not linked to clinical/neurophysiological signs of peripheral neuropathy or HNPP, suggesting residual functional activity.<sup>13</sup>

Interestingly, the 1.5 Mb deletion has never been reported in homozygosity, most likely due to the fact that the depletion of COX10, which lies in that region, is not compatible with life.

We have summarized in Table 1 the features of patients with early onset severe CMT associated with biallelic, putative loss-of-function, PMP22 variants.<sup>5-9</sup>

Loss of proprioception and ataxia were constantly present as the predominant symptoms in all but one case, where this was not mentioned. Interestingly, while our patient did not show other significant features, scoliosis and pes cavus were reported in two families and cranial nerve involvement in one. The most comprehensive discussion regarding clinical and pre-clinical findings has been performed by Saporta and colleagues.<sup>8</sup> They suggested that PMP22 deficiency might affect both motor and sensory nerve fibers, with Schwann cell being more damaged in ventral roots and axons being involved proximally more than distally. Such finding is reflected in the presence of severely reduced conduction velocities of both motor and sensory nerves in all reported cases. Nevertheless, the question why early onset sensory ataxia prevails as a symptom in these rare patients as opposed to weakness remains open. As previously advocated, the early onset of symptoms and the presence of conduction velocities not entirely mirroring the severity of symptoms, suggest that neuronal damage might be more selective during early development.

**TABLE 1** Clinical reports of early-onset CMT cases associated with bi-allelic, putative loss-of-function, PMP22 variants

Article	Patient (sex, age)	Mutation	Nerve conduction studies	Age of onset	Symptoms at onset	Independent walking acquired Y/N (age)	Sensory Ataxia	Muscle wasting	Muscle weakness	Deep tendon reflexes	Other features
Present Case	F, 8 y	c.483A>G; p. (*161Trpext*10) (Homozygous)	Motor CVs <5 m/s SAPs absent	< 1 y	Motor delay Hypotonia	N	+++	-	-	Absent in LL Diminished in UL	Mild pseudothetosis Both Parents with NCSs consistent with HNPP Mild scoliosis CSF proteins 3.52 g/L
D'Arrigo et al <sup>a</sup>	F, 3 y	1.5-Mb deletion + exon 5 deletion	CVs <5 m/s	< 1 y	Motor delay Hypotonia	N	NR <sup>a</sup>	-	+	Absent	Feet overpronation. Mild dysphagia for liquids. Father with HNPP. Mother clinically asymptomatic but harboring exon 5 del.
Saporta et al 2011	M, 7y 10mo	1.1 MB 17p deletion (Homozygous)	CVs ≤10 m/s	< 1 y	Motor delay Hypotonia	Y (3y)	+++	-	-	Absent	Bilateral facial weakness, Mild pseudothetosis. Skin biopsy + Both parents with HNPP
Abe et al 2010	F, 3y 6mo	1.5-Mb deletion + exon 5 deletion	CVs <5 m/s	< 1 y	Motor delay Hypotonia	N	++?	NR	NR	Absent in LL Diminished in UL	Hyperextended knees Mother with clinical signs of HNPP Father with normal NCSs CSF proteins 0.74 g/L
Al-Thlyli et al 2008	M, 7y	1.5-Mb deletion + exon 2-3 deletion	CVs < 5 m/s	< 1 y	Motor delay Hypotonia	N	++	NR	NR	NR	Scoliosis, pes cavus, metatarsus adductus GERD Sural nerve biopsy + CSF proteins 1.17 g/L
Parman et al 1999	F, 10y F, 5y M, 1y 6mo	c.518C>T; p.(Arg157Trp) (Homozygous)	CVs ≤10 m/s (all)	<1 y (all)	Motor delay (all)	Y (4y) Y (20mo) N	++ ++ ++	+ (distally) + (distally)	+ (distally) -	Absent Absent Absent in LL/ diminished in UL	Hand tremor Pes cavus, scoliosis Sural nerve biopsy + CSF proteins 0.74 g/L

Abbreviations: CSF, cerebrospinal fluid; CV, Conduction velocities; GERD, gastroesophageal reflux disease; HNPP, hereditary neuropathy with liability to pressure palsy; NCSs, nerve conduction studies; SAP, sensory action potential. NR, not reported. LL, lower limbs; UL, upper limbs; mo, month; y, year.

<sup>a</sup>Patient able to walk with support.

Throughout embryogenesis, the expression of PMP22 varies greatly among tissues. On the contrary, PMP22 transcription in adulthood is predominantly observed in Schwann Cells, with lower levels detected in the central nervous system.<sup>10</sup> In rodents, Parmantier and colleagues showed that dorsal root ganglia display abundant levels of PMP22 during the embryonic stage, with a dramatic decline after birth.<sup>15</sup>

Our case provides further evidence that a threshold level of PMP22 might be required for the normal development of dorsal root ganglia in humans and might be essential for myelin formation in all nerve types. The lack of facial weakness in the present case fuels the conundrum regarding the importance of PMP22 expression in motor nuclei of cranial nerves and spinal motor neurons.<sup>8</sup> Interestingly the DRG and Scarpa's ganglion undergo similar development during embryogenesis, suggesting that a detailed vestibular function should ideally also be assessed to rule out the additional vestibular involvement in these patients; unfortunately, we were not able to investigate the vestibular function in our patient. Considering the clinical variability of previously reported cases, it is possible that the answer lies in the way different neuron cell types adapt to dysmyelination.

In conclusion, we believe that human models are vital to get insights on the role of PMP22 during the entire span of development in vivo. Biallelic loss-of-function mutations in PMP22 lead to a congenital hypomyelinating/demyelinating neuropathy which manifests predominantly as sensory ataxia, suggesting a pivotal role played by PMP22 during dorsal root ganglia embryogenesis. Very slow conduction velocities and sensory ataxia should therefore prompt clinicians to look for such variants in children. An extensive neurophysiological assessment of family members is essential to establish the functional effect of unusual mutations. Lastly, considering potential drawbacks of early PMP22 modulation, future therapies aimed at reducing PMP22 levels should only be considered post-natally.

#### ACKNOWLEDGEMENTS

We would like to thank Dr Felice D'Arco for the critical revision of MRI scans.

#### CONFLICT OF INTEREST

The authors declare no potential conflict of interest.

#### ORCID

Alberto A. Zambon  <https://orcid.org/0000-0002-6539-5360>

#### REFERENCES

- Pareyson D, Marchesi C. Diagnosis, natural history, and management of Charcot-Marie-Tooth disease. *Lancet Neurol*. 2009;8(7):654-667.
- Yiu EM, Burns J, Ryan MM, Ouvrier RA. Neurophysiologic abnormalities in children with Charcot-Marie-Tooth disease type 1A. *J Peripher Nerv Syst*. 2008;13(3):236-241.
- van Paassen BW, van der Kooij AJ, van Spaendonck-Zwarts KY, Verhamme C, Baas F, de Visser M. PMP22 related neuropathies: Charcot-Marie-Tooth disease type 1A and Hereditary Neuropathy with liability to Pressure Palsies. *Orphanet J Rare Dis*. 2014;9:38.
- Fabrizi GM, Simonati A, Taioli F, et al. PMP22 related congenital hypomyelination neuropathy. *J Neurol Neurosurg Psychiatr*. 2001;70(1):123-126.
- Parman Y, Plante-Bordeneuve V, Guiochon-Mantel A, Eraksoy M, Said G. Recessive inheritance of a new point mutation of the PMP22 gene in Dejerine-Sottas disease. *Ann Neurol*. 1999;45(4):518-522.
- Al-Thihli K, Rudkin T, Carson N, Poulin C, Melancon S, Der Kaloustian VM. Compound heterozygous deletions of PMP22 causing severe Charcot-Marie-Tooth disease of the Dejerine-Sottas disease phenotype. *Am J Med Genet Part A*. 2008;146a(18):2412-2416.
- Abe A, Nakamura K, Kato M, et al. Compound heterozygous PMP22 deletion mutations causing severe Charcot-Marie-Tooth disease type 1. *J Hum Genet*. 2010;55(11):771-773.
- Saporta MA, Katona I, Zhang X, et al. Neuropathy in a human without the PMP22 gene. *Arch Neurol*. 2011;68(6):814-821.
- D'Arrigo S, Tessarollo V, Taroni F, et al. A case of severe early-onset neuropathy caused by a compound heterozygous deletion of the PMP22 gene: clinical and neurographic aspects. *Neuropediatrics*. 2019;51:173-177.
- Li J, Parker B, Martyn C, Natarajan C, Guo J. The PMP22 gene and its related diseases. *Mol Neurobiol*. 2013;47(2):673-698.
- Adlkofer K, Martini R, Aguzzi A, Zielasek J, Toyka KV, Suter U. Hypermyelination and demyelinating peripheral neuropathy in Pmp22-deficient mice. *Nat Genet*. 1995;11(3):274-280.
- Amici SA, Dunn WA Jr, Notterpek L. Developmental abnormalities in the nerves of peripheral myelin protein 22-deficient mice. *J Neurosci Res*. 2007;85(2):238-249.
- Roa BB, Garcia CA, Pentao L, et al. Evidence for a recessive PMP22 point mutation in Charcot-Marie-Tooth disease type 1A. *Nat Genet*. 1993;5(2):189-194.
- Numakura C, Lin C, Oka N, Akiguchi I, Hayasaka K. Hemizygous mutation of the peripheral myelin protein 22 gene associated with Charcot-Marie-Tooth disease type 1. *Ann Neurol*. 2000;47(1):101-103.
- Parmantier E, Braun C, Thomas JL, Peyron F, Martinez S, Zalc B. PMP-22 expression in the central nervous system of the embryonic mouse defines potential transverse segments and longitudinal columns. *J Comp Neurol*. 1997;378(2):159-172.

**How to cite this article:** Zambon AA, Pitt M, Laurà M, Polke JM, Reilly MM, Muntoni F. A novel homozygous variant extending the peripheral myelin protein 22 by 9 amino acids causes early-onset Charcot-Marie-Tooth disease with predominant severe sensory ataxia. *J Peripher Nerv Syst*. 2020; 25:303-307. <https://doi.org/10.1111/jns.12386>