

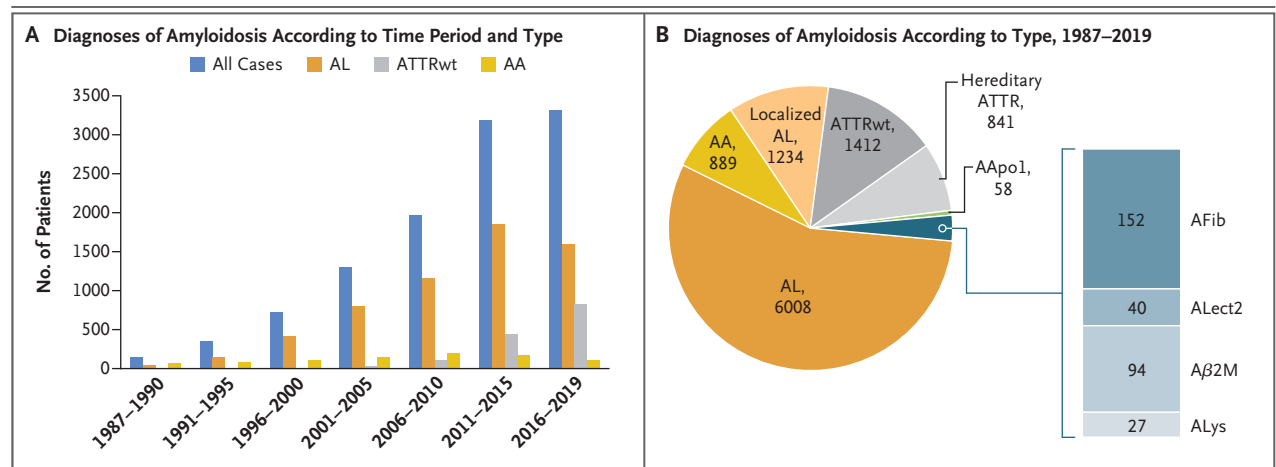
## Epidemiologic and Survival Trends in Amyloidosis, 1987–2019

**TO THE EDITOR:** Amyloidosis is a group of rare disorders caused by deposition of misfolded proteins as insoluble fibrils, which leads to progressive multiorgan failure and death.<sup>1</sup> The past 30 years have seen remarkable advances in diagnostic imaging, more accurate identification of fibrils, and (in recent years) the first approved treatments.<sup>2,3</sup>

We report here data on 11,006 patients who received a diagnosis of amyloidosis during the period from 1987 through October 2019. All data were obtained from the United Kingdom National Amyloidosis Centre database. The number of cases increased by 670% from the period 1987–1999 to the period 2010–2019 (Fig. 1A). Systemic light-chain (AL) amyloidosis remained the most common type and accounted for 55% of all cases (Fig. 1B). With the advances in therapies that target plasma cells, overall survival among patients with AL amyloidosis in-

creased from a median of 18 months among patients who received a diagnosis before 2005 to more than 5 years in the past decade (see the Supplementary Appendix, available with the full text of this letter at NEJM.org). However, early mortality remained high and essentially unchanged.

The most remarkable changes we observed were the decline in cases of systemic amyloid A (AA) amyloidosis (a complication of persistent inflammation), from 13% of all amyloidosis cases diagnosed before 2010 to 3% in the period 2016–2019, and the increase in cases of late-onset acquired wild-type transthyretin-associated (ATTRwt) amyloidosis. The incidence of ATTRwt amyloidosis increased from less than 3% of all cases in the period 1987–2009 to 14% in the period 2010–2015 and to 25% in the past 4 years. This increasing incidence reflects a growing awareness of amyloidosis and particularly re-



**Figure 1. Diagnoses of Amyloidosis over Three Decades and Amyloidosis Types.**

Panel A shows data for 11,006 cases of amyloidosis diagnosed from 1987 to 2019. Panel B shows data for the 10,755 cases for which fibril type could be determined accurately. AA denotes amyloid A, AApo1 amyloid apolipoprotein A-I, Aβ2M amyloid beta<sub>2</sub>-microglobulin, AFib amyloid fibrinogen, ALect2 amyloid leukocyte chemotactic factor 2, AL light chain, ALys amyloid lysozyme, ATTR transthyretin-associated, and ATTRwt wild-type ATTR.

flects recognition of the role of diagnostic cardiac imaging, such as cardiac magnetic resonance imaging and bone scintigraphy performed with the use of agents such as technetium-99 pyrophosphate.<sup>3</sup>

These findings provide evidence of both substantially greater recognition of amyloidosis and a change in the distribution of types over the past three decades. The near disappearance of AA amyloidosis highlights the success of biologic treatments in controlling a variety of chronic inflammatory disorders. The recognition of transthyretin-associated (ATTR) amyloidosis as a specifically treatable cause of heart failure with preserved ejection fraction, along with improved diagnostic techniques, has resulted in a substantial increase in the diagnosis of ATTR cardiac amyloidosis. In 2019, the Food and Drug Administration (FDA) approved the TTR stabilizer tafamidis for the treatment of amyloid cardiomyopathy,<sup>2</sup> and there is an expectation that patisiran and inotersen — new therapies that have been shown to reduce hepatic production of TTR and were recently approved by the FDA and the European Medicines Agency for the treatment of hereditary ATTR amyloidosis — may be beneficial in ATTRwt amyloidosis as

well.<sup>4,5</sup> New targeted treatments for these previously inexorable cardiac and neurologic diseases can potentially transform the standard of care, but correct identification of amyloid type remains absolutely fundamental.

Sriram Ravichandran, M.D.  
Helen J. Lachmann, M.D.  
Ashutosh D. Wechalekar, M.D.  
National Amyloidosis Centre  
London, United Kingdom  
a.wechalekar@ucl.ac.uk

Disclosure forms provided by the authors are available with the full text of this letter at NEJM.org.

1. Merlini G, Dispenzieri A, Santhorawala V, et al. Systemic immunoglobulin light chain amyloidosis. *Nat Rev Dis Primers* 2018;4:38.
2. Maurer MS, Schwartz JH, Gundapaneni B, et al. Tafamidis treatment for patients with transthyretin amyloid cardiomyopathy. *N Engl J Med* 2018;379:1007-16.
3. Dorbala S, Ando Y, Bokhari S, et al. ASNC/AHA/ASE/EANM/HFSA/ISA/SCMR/SNMMI expert consensus recommendations for multimodality imaging in cardiac amyloidosis: Part 1 of 2 — evidence base and standardized methods of imaging. *J Nucl Cardiol* 2019;26:2065-123.
4. Adams D, Gonzalez-Duarte A, O'Riordan WD, et al. Patisiran, an RNAi therapeutic, for hereditary transthyretin amyloidosis. *N Engl J Med* 2018;379:11-21.
5. Benson MD, Waddington-Cruz M, Berk JL, et al. Inotersen treatment for patients with hereditary transthyretin amyloidosis. *N Engl J Med* 2018;379:22-31.

DOI: 10.1056/NEJMc1917321

