



European Guideline on Achalasia – UEG and ESNM recommendations

RAB Oude Nijhuis¹, G Zaninotto², S Roman³, GE Boeckxstaens⁴, P Fockens¹,
MW Langendam⁵, AA Plumb⁶, AJPM Smout¹, EM Targarona⁷,
AS Trukhmanov⁸ , BLAM Weusten⁹ and AJ Bredenoord¹ 

United European Gastroenterology Journal
2020, Vol. 8(1) 13–34

© Author(s) 2020



Article reuse guidelines:

sagepub.com/journals-permissions

DOI: 10.1177/2050640620903213

journals.sagepub.com/home/ueg

Abstract

Introduction: Achalasia is a primary motor disorder of the oesophagus characterised by absence of peristalsis and insufficient lower oesophageal sphincter relaxation. With new advances and developments in achalasia management, there is an increasing demand for comprehensive evidence-based guidelines to assist clinicians in achalasia patient care.

Methods: Guidelines were established by a working group of representatives from United European Gastroenterology, European Society of Neurogastroenterology and Motility, European Society of Gastrointestinal and Abdominal Radiology, and the European Association of Endoscopic Surgery in accordance with the Appraisal of Guidelines for Research and Evaluation (AGREE) II instrument. A systematic review of the literature was performed and the certainty of the evidence was assessed using the Grading of Recommendations Assessment, Development, and Evaluation (GRADE) methodology. Recommendations were voted upon using a nominal group technique.

Results: These guidelines focus on the definition of achalasia, treatment aims, diagnostic tests, medical, endoscopic and surgical therapy, management of treatment failure, follow-up and oesophageal cancer risk.

Conclusion: These multidisciplinary guidelines provide a comprehensive evidence-based framework with recommendations on the diagnosis, treatment and follow-up of adult achalasia patients.

Keywords

Dysphagia, oesophagus, manometry, myotomy, motility

Received: 25 October 2019; accepted: 25 December 2019

Abbreviations

AGREE, Appraisal of Guidelines for Research and Evaluation; BMI, body mass index; BTX, botulinum toxin; EA, oesophageal adenocarcinoma; EAES, European Association of Endoscopic Surgery; ESGAR, European Society of Gastrointestinal and Abdominal Radiology; ESNM, European Society of Neurogastroenterology and Motility; GORD, gastro-oesophageal reflux disease; GRADE, Grading of Recommendations Assessment, Development, and Evaluation; HRM, high-resolution manometry; IP, impedance planimetry; IRP, integrated relaxation pressure; LOS, lower oesophageal sphincter; LHM, laparoscopic heller myotomy; OGJ, oesophago-gastric junction PD, pneumatic dilation; PICO, patient, intervention, control, outcome; POEM, peroral endoscopic myotomy; PPI, proton pump inhibitor; RCT, randomised controlled trial; SSC, squamous cell carcinoma; TBE, timed barium oesophagram; UEG, United European Gastroenterology.

¹Department of Gastroenterology and Hepatology, Amsterdam Gastroenterology & Metabolism, Amsterdam University Medical Centers, University of Amsterdam, Meibergdreef 9, Amsterdam, the Netherlands

²Department of Surgery and Cancer, Imperial College, London, UK

³Digestive Physiology, Hôpital Edouard Herriot, Lyon, France

⁴Department of Chronic Diseases, Metabolism and Ageing, Translational Research Center for Gastrointestinal Disorders, KU Leuven, Leuven, Belgium

⁵Department of Clinical Epidemiology, Biostatistics and Bioinformatics, Amsterdam UMC, University of Amsterdam, Amsterdam Public Health Research Institute, Amsterdam, The Netherlands

⁶Centre for Medical Imaging, University College London, London, UK

⁷Department of General and Digestive Surgery, Hospital De La Santa Creu I Sant Pau, Autonomous University of Barcelona, Barcelona, Spain

⁸I.M. Sechenov First Moscow State Medical University, Ministry of Health of the Russian Federation (Sechenov University), Moscow, Russia

⁹Department of Gastroenterology and Hepatology, St Antonius Hospital, Nieuwegein, the Netherlands; Department of Gastroenterology and Hepatology, University Medical Center Utrecht, Utrecht University, Utrecht, the Netherlands

Corresponding author:

Albert J. Bredenoord, Department of Gastroenterology & Hepatology, Academic Medical Center, Amsterdam, PO Box 22660, 1100 DD Amsterdam, the Netherlands.

Email: a.j.bredenoord@amsterdamumc.nl

Introduction

Achalasia is a primary motility disorder in which insufficient relaxation of the lower oesophageal sphincter (LOS) and absent peristalsis result in stasis of ingested foods and subsequently, lead to oesophageal symptoms of dysphagia, regurgitation, chest pain or weight loss.¹ Achalasia occurs as an effect of destruction of enteric neurons controlling the LOS and oesophageal body musculature by an unknown cause, most likely inflammatory. Idiopathic achalasia is a rare disease and affects individuals of both sexes and all ages. The annual incidence is estimated between 1.07–2.2 cases per 100,000 individuals with prevalence rates estimated between 10–15.7 per 100,000 individuals.^{2–4}

A diagnosis of achalasia should be considered when patients present with dysphagia in combination with other oesophageal symptoms and when upper endoscopy ruled out other disorders. Barium esophagogram may reveal a classic “bird’s beak” sign, oesophageal dilation, or a corkscrew appearance. Oesophageal manometry is the golden standard for the diagnosis of achalasia; incomplete relaxation of the LOS, reflected by an increased integrative relaxation pressure, in absence of normal peristalsis, are the diagnostic hallmarks. The use of high-resolution manometry (HRM) has led to the subclassification of achalasia into three clinically relevant groups based on oesophageal contractility patterns, as seen in Table 1.

The clinical care of patients with achalasia has changed significantly in the past decade under influence of new developments such as high-resolution manometry, per-oral endoscopic myotomy and studies providing new insights regarding achalasia subtypes, cancer risk and follow-up. Given the substantial growth of knowledge in the past years, there is need for a comprehensive, evidence-based European guideline covering all aspects of the disease. This multidisciplinary guideline aims to provide an evidence-based framework with recommendations on the diagnosis, treatment and follow-up of adult achalasia patients. Chagas disease and achalasia secondary to other disorders, as can be seen after fundoplication, bariatric surgery, sarcoid infiltration, opiate usage or malignancy, is not covered by this guideline. This guideline is intended for clinicians involved in their management, including gastroenterologists, endoscopists, radiologists, gastrointestinal surgeons, dietitians and primary care practitioners.

Methodology

The achalasia guideline working group

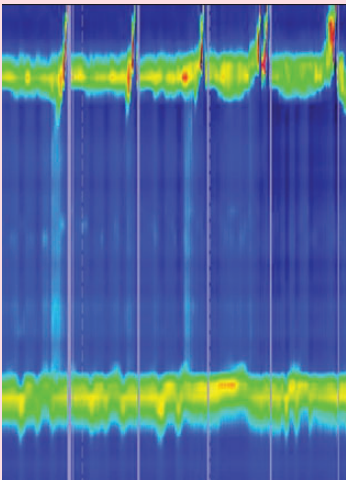
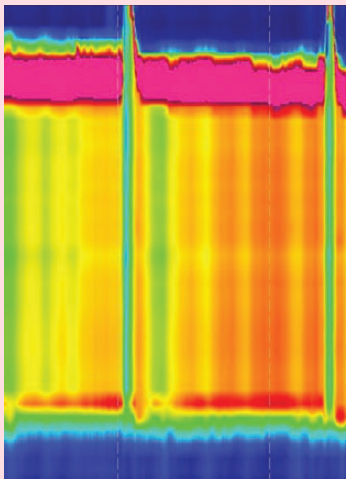
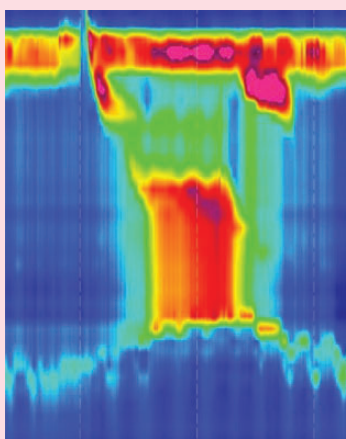
Ten researchers and clinicians with recognised expertise in the field of clinical achalasia management were gathered (AB, GB, PF, AP, SR, AS, AT, ET, BW, GZ) on

behalf of United European Gastroenterology (UEG), European Society of Neurogastroenterology and Motility (ESNM), the European Society of Gastrointestinal and Abdominal Radiology (ESGAR), and The European Association of Endoscopic Surgery (EAES) to form a guideline expert working group. All concerned societies were contacted and asked to support the guideline by appointing one or two representatives for the guideline committee. First, the guideline development team (RON, AB, and ML) drafted the guideline protocol and the preliminary list of clinical topics to be covered by the guidelines. This list was circulated to a panel of achalasia patients. Based upon patients’ interests, the final list of research questions was formatted into the PICO (patient, intervention, control, outcome) framework, and presented to all members of the guideline working group at an initial meeting which occurred on 23rd of October at UEG week 2018. All working group members were assigned to one of the subgroups (diagnosis, treatment or follow-up) and were responsible for the elaboration of one or multiple research questions. Results of the search strategies and GRADE assessments were first discussed in conference calls by each group and checked again for completeness, after which these documents were updated and subsequently sent to the entire group in advance of a face-to-face consensus meeting.

From assessment of evidence to recommendation

An electronic literature search was performed on the 18th of October 2018 using MEDLINE, EMBASE (accessed via Ovid), The Cochrane Database of Systematic Reviews (The Cochrane Library), and the Cochrane Central Register of Controlled Trials (CENTRAL) without restrictions of language or publication year. The search strategy and the process of study selection categorised per research question can be found in appendix A. Risk of bias was assessed using the appropriate study-design specific tools (appendix B). The certainty of evidence was assessed using the GRADE methodology (www.gradeworkinggroup.org) and for each outcome graded into four levels: high, moderate, low, or very low quality (Table 2). Based on the certainty of evidence and the balance between desirable and undesirable outcomes, patient values and preferences, applicability, feasibility, equity and costs/resources, recommendations were categorised into four final categories (strong or conditional recommendations in favour of or against an intervention), as proposed by GRADE (Table 3). In case of insufficient or limited evidence, research questions were answered by and classified as ‘expert opinion’. The results of data extraction, the risk of bias and quality of the evidence assessments are presented in appendix C and appendix D.

Table 1. Manometric subtypes of achalasia.

Type I	Classic achalasia	<ul style="list-style-type: none"> • Median IRP > Cutoff* • 100% failed peristalsis 	
Type II	Achalasia with oesophageal compression	<ul style="list-style-type: none"> • Median IRP > Cutoff* • 100% failed peristalsis • $\geq 20\%$ pan-oesophageal pressurization 	
Type III	Spastic achalasia	<ul style="list-style-type: none"> • Median IRP > Cutoff* • No normal peristalsis • $\geq 20\%$ premature contractions with DCI > 450 	

DCI, Distal Contractile Integral; IRP, Integrated Relaxation Pressure. *note: the cutoff for IRP is catheter-dependent, varying between 15 and 28 mmHg.

Consensus process

In order to establish consensus-based recommendations, a second physical meeting was organised in Amsterdam, the Netherlands on the 11th of April 2019. GRADE assessments and recommendations were presented and discussed. Voting was conducted according to the nominal group technique and based upon a six-point Likert scale (1: strongly disagree; 2: mostly disagree; 3: somewhat disagree; 4: somewhat agree; 5: mostly agree; 6: strongly agree). A recommendation was approved if > 75% of the members agreed (reflected by a Likert score of 4–6).

Recommendations

Clinical questions formed the basis of the systematic literature reviews (appendix A in supplementary

material). The working group formulated 30 recommendations based on these reviews (Table 4).

1. Achalasia diagnosis

1.1 What is the current definition of achalasia?

Recommendation 1.1

Achalasia is a disorder characterised by insufficient LOS relaxation and absent peristalsis. It is usually primary (idiopathic) but can be secondary to other conditions that affect oesophageal function. In idiopathic achalasia the enteric neurons controlling the LOS and oesophageal body musculature are affected by an unknown cause, most likely inflammatory.

Expert opinion recommendation

Consensus: 100% agree [Vote: A++, 100%; A+, 0%; A, 0%; D 0%; D+, 0%; D++, 0%]

1.2 What is the value of HRM and conventional manometry in achalasia diagnosis?

The diagnosis of achalasia not only requires impaired OGJ relaxation, but also absent or abnormal peristalsis. Therefore, oesophageal manometry is considered as being the gold standard for the diagnosis of achalasia, as it evaluates both pressures of the lower oesophageal sphincter (LOS) and contractility of the oesophageal body. Worldwide, high-resolution manometry (HRM), usually defined as manometry carried out with a catheter with at least 21 pressure sensors spaced at 1-cm intervals,⁵ is rapidly replacing conventional manometry. The generally perceived advantages of HRM over conventional manometry are that positioning of the catheter is less critical and that interpretation of the recorded pressures, displayed in the form of topographical colour-coded plots, is more intuitive.

Table 2. Grading of Recommendations Assessment, Development, and Evaluation Definitions of Quality, and Certainty of the Evidence (GRADE).

Certainty of evidence	Definition
High	We are very confident that the true effect lies close to the estimate of the effect.
Moderate	We are moderately confident in the effect estimate. The true effect is likely to be close to the estimate of effect, but there is a possibility that it is substantially different.
Low	Our confidence in the estimate is limited. The true effect may be substantially different from the estimate of effect.
Very low	We have very little confidence in the effect estimate. The true effect is likely to be substantially different from the estimate of effect.

Table 3. Grading of Recommendations Assessment, Development, and Evaluation Definitions on Strength of Recommendation and Guide to Interpretation.

Strength of recommendation	Wording in the guideline	For the patient		For the clinician	
Strong	“We recommend...”	Most individuals in this situation would want the recommended course and only a small proportion would not.		Most individuals should receive the recommended course of action. Formal decision aids are not likely to be needed to help individuals make decisions consistent with their values and preferences.	
Conditional	“We suggest...”	The majority of individuals in this situation would want the suggested course, but many would not.		Different choices would be appropriate for different patients. Decision aids may be useful in helping individuals in making decisions consistent with their values and preferences. Clinicians should expect to spend more time with patients when working towards a decision.	

Table 4. Summary of recommendations of the United European Gastroenterology Clinical Guidelines Committee for the diagnosis, management and follow-up of Achalasia.

Recommendations	Strength	Certainty of evidence	Voting
Diagnosis			
1.1	Expert opinion	-	100%
1.2	Strong	Moderate	100%
1.3	Conditional	Moderate	100%
1.4	Expert opinion	-	100%
1.5	Expert opinion	-	100%
	Expert opinion	-	77.8%
1.6	Conditional	Low	100%
1.7	Expert opinion	-	100%
Treatment			
2.1	Expert opinion	-	100%
	Expert opinion	-	100%
2.2	Expert opinion	-	100%

(continued)

Table 4. Continued.

Recommendations	Strength	Certainty of evidence	Voting
2.3 Botulinum toxin therapy can be considered an effective and safe therapy for short-term symptom relief in oesophageal achalasia.	Conditional	Moderate	88.9%
2.4 Graded pneumatic dilatation is an effective and relatively safe treatment for oesophageal achalasia.	Strong	High	100%
2.5 POEM is an effective and relatively safe treatment for Achalasia.	Strong	High	100%
2.6 Laparoscopic Heller myotomy combined with an anti-reflux procedure is an effective and relatively safe therapy for achalasia.	Strong	High	100%
2.7 We suggest taking age and manometric subtype into account when selecting a therapeutic strategy.	Conditional	Moderate	100%
2.8 I. Treatment decisions in achalasia should be made based on patient-specific characteristics, patient preference, possible side effects and/or complications and a center's expertise. Overall, graded repetitive PD, LHM and POEM have comparable efficacy.	Strong	Moderate	100%
II. Botulinum toxin should be reserved for patients that are unfit for more invasive treatments, or in whom a more definite treatment needs to be deferred.	Conditional	Moderate	100%
2.9 We suggest treating recurrent or persistent dysphagia after laparoscopic Heller myotomy with PD, POEM or redo surgery.	Conditional	Very low	100%
2.10 We suggest treating recurrent or persistent dysphagia after POEM with either re-POEM, laparoscopic Heller myotomy or pneumatic dilation.	Conditional	Very low	100%
2.11 Oesophagectomy should be considered the last resort to treat achalasia, after all other treatments have been considered.	Expert opinion	-	100%
2.12 We suggest against oesophageal stents and intrasphincteric injection of sclerosing agents in the treatment of achalasia.	Expert opinion	-	100%
Follow-up			
3.1 I. Patients with recurrent or persistent dysphagia after initial treatment should undergo repeat evaluation with timed barium esophagram with or without oesophageal manometry.	Expert opinion	-	100%
II. Repeat endoscopy should be considered in patients with recurrent dysphagia.	Expert opinion	-	100%
3.2 I. In patients with persistent or recurrent chest pain, inappropriate emptying due to ineffective initial treatment or recurrent disease should be excluded by TBE with or without oesophageal manometry. For type III achalasia, we suggest a repeat HRM to exclude or confirm persistent spastic contractions.	Expert opinion	-	100%
II. If there is no evidence of impaired oesophageal emptying, empirical treatment with PPI, endoscopy and/or 24 hr pH-(impedance)metry can be considered.	Expert opinion	-	100%
3.3 I. We suggest follow-up endoscopy to screen for GERD in patients treated with myotomy without anti-reflux procedure.	Expert opinion	-	100%
II. In case of reflux symptoms in absence of reflux esophagitis, TBE, empiric PPI therapy, and/or 24-h oesophageal pH-(impedance)monitoring can be considered.	Expert opinion	-	100%
III. Proton pump inhibitors are the first line treatment of GORD after achalasia treatment. We recommend lifelong PPI therapy in patients with oesophagitis > grade A (LA classification).	Expert opinion	-	100%
3.4 We suggest against performing systematic screening for dysplasia and carcinoma. However, the threshold of upper GI endoscopy should be low in patients with recurrent symptoms and longstanding achalasia.	Conditional	Low	100%

In 4 of the 5 included studies, the diagnosis of achalasia was made more often with HRM than with conventional manometry.^{6–9} However, one may argue that a higher rate of achalasia diagnosis with HRM does not prove that HRM is better than conventional manometry; HRM might also lead to more false-positive findings. The only prospective randomised trial that compared HRM and conventional manometry⁹ had the additional advantage of defining the clinical outcome after 6 months as the gold standard, and found a superior sensitivity of HRM for the diagnosis of achalasia to that of conventional manometry (93 vs 78%). The specificities of both tests were equal (100%).⁹

In two studies the diagnostic values of imaging techniques were compared with manometry.^{10,11} The results of these two studies lend some support to the notion that manometry rather than imaging is the gold standard for the diagnosis of achalasia.

Recommendation 1.2

We recommend using high-resolution manometry (with topographical pressure presentation) to diagnose achalasia in adult patients with suspected achalasia.

Strong recommendation, moderate certainty of evidence

Consensus: 100% agree [Vote: A++, 66.7%; A+, 33.3%; A, 0%; D 0%; D+, 0%; D++, 0%]

1.3 What is the value of (timed) barium swallow studies in achalasia diagnosis?

The barium esophagram is generally seen as a valuable and complementary, but relatively insensitive, diagnostic test. One study evaluated the diagnostic value of barium esophagography in comparison with HRM and found a high sensitivity, but poor specificity for detecting dysmotility. The authors conclude that barium swallow studies accurately rule out achalasia-related dysmotility but are not very helpful in diagnosing other causes of dysmotility.¹² Two studies comparing barium esophagography with conventional manometry found sensitivities for achalasia diagnosis between 58 – 75%.^{11,13} However, as the positive predictive accuracy was 96%, the authors concluded that the barium esophagram is a useful tool in achalasia diagnosis.¹¹ Similar sensitivity and specificity rates were obtained in another study comparing barium swallow studies with HRM; the diagnostic sensitivity, specificity and accuracy of the barium esophagram were 78.3%, 88.0%, and 83.0%, respectively.¹⁴ Consequently, it may be concluded that diagnosing achalasia by using barium esophagram alone has a limited yield. The technique of timed barium esophagram (TBE) is similar to the usual barium swallow study but uses set time intervals (1, 2 and 5 minutes) after ingestion of a fixed barium

suspension, to measure height and width of the barium column in order to assess oesophageal emptying more objectively (Figure 1).¹⁵ Because of this advantage, TBE is generally preferred over a standard barium esophagram. One study compared TBE with HRM, and found a sensitivity of 85% and specificity of 86%.¹⁵

Recommendation 1.3

We suggest using a barium esophagram to diagnose achalasia if manometry is unavailable, although it is less sensitive than oesophageal manometry. The working group suggests using timed barium esophagram, if available, over standard barium esophagram.

conditional recommendation, moderate certainty of evidence

Consensus: 100% agree [Vote: A++, 88.9%; A+, 11.1%; A, 0%; D 0%; D+, 0%; D++, 0%]

1.4 What is the value of impedance planimetry in the diagnosis of achalasia?

Oesophageal impedance planimetry is a technique in which the cross-sectional area of the oesophagus is simultaneously measured at multiple levels using a saline-filled cylindrical bag containing an array of impedance electrodes.⁶ The commercially-available device for endoluminal impedance planimetry is known as Endoflip[®].

Studies using impedance planimetry have consistently demonstrated that the distensibility of the oesophago-gastric junction (OGJ) is reduced in untreated achalasia compared to healthy controls.^{16–19} A systematic review identified 6 studies with data on oesophago-gastric junction (OGJ) distensibility in untreated achalasia patients (n = 154) and 5 studies with data in healthy subjects (n = 98) and found that at 40-mL distension there was a clear difference between the two groups (point estimates < 1.6 mm²/mmHg and > 2.7 mm²/mmHg in patients and controls respectively).²⁰

However, in order to distinguish achalasia from OGJ outflow obstruction, information about the motility of the tubular oesophagus is required, which is not provided by impedance planimetry measurement. Recent studies indicate that dynamic impedance planimetry can also provide information on peristalsis.^{21,22} However, this technique assesses distension-, rather than swallow-induced contractions, and requires sedation. Furthermore, high-quality diagnostic studies comparing impedance planimetry with the gold standard HRM are not available yet. In line with this, one recommendation from a recent AGA clinical practice update on functional lumen imaging is that clinicians should not make a diagnosis of achalasia based on impedance planimetry alone.²³

There is data to suggest that impedance planimetry may be used as an additional tool to diagnose achalasia

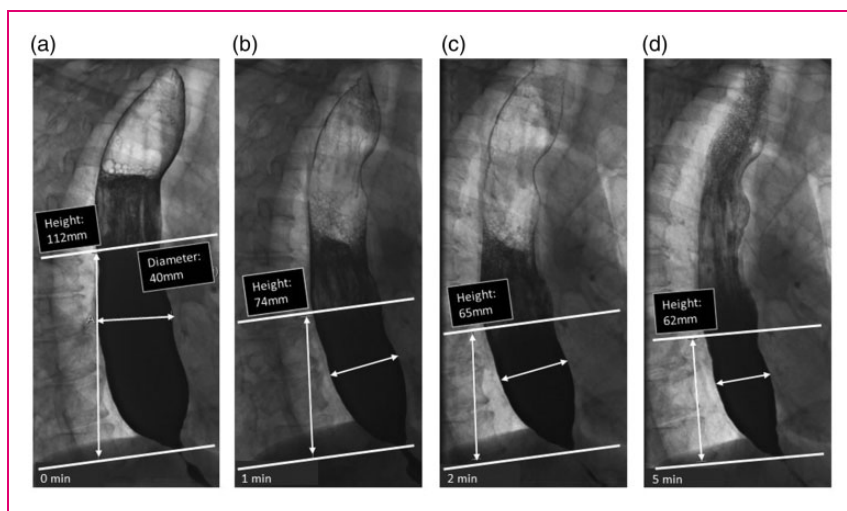


Figure 1. Interpretation of timed barium esophagram. Radiographs taken 0, 1, 2 and 5 minutes in left posterior oblique position after ingestion of 100 to 200 mL low-density barium suspension in an achalasia patient. Measurement of height and width of barium column, measured from the OGJ to the barium-foam interface. Barium height of >5 cm at 1 min and >2 cm at 5 min are suggestive of achalasia.

in patients who do not meet the manometric criteria (Chicago 3.0) for achalasia. In 13 patients with symptoms and signs of achalasia, but with manometrically normal integrated relaxation pressure (IRP), OGJ distensibility was below the lower limit of normal. Treatment of these patients as if the diagnosis were achalasia resulted in a decrease of symptoms.²⁴ This observation suggests that impedance planimetry may be a useful complimentary diagnostic tool for the diagnosis of achalasia, in a subset of patients with a low IRP.

Recommendation 1.4

We suggest against making the diagnosis of achalasia solely based on impaired OGJ distensibility as measured with impedance planimetry.

Expert opinion recommendation

Consensus: 100% agree [Vote: A++, 100%; A+, 0%; A, 0%; D 0%; D+, 0%; D++, 0%]

1.5 What is the value of endoscopy in achalasia diagnosis?

Thorough endoscopic evaluation of the gastro-oesophageal junction and gastric cardia is recommended in all patients with symptoms suggestive of achalasia to exclude other diseases, especially to rule out malignancies. However, the value of endoscopy in achalasia diagnosis is relatively low. Depending on the stage of disease, endoscopic evaluation can suggest a diagnosis of achalasia in 30-50% of patients. Achalasia diagnosis can easily be missed, as endoscopic abnormalities are uncommon in early-stage achalasia.²⁵⁻²⁷ In more

advanced stages, a diagnosis of achalasia is supported by endoscopic findings such as an oesophageal dilatation with axis deviation and tortuosity and retained saliva and food in the oesophagus.²⁸⁻³⁰

Recommendation 1.5

a. We suggest against making the diagnosis of achalasia solely based on endoscopy.

Expert opinion recommendation

Consensus: 100% agree [Vote: A++, 100%; A+, 0%; A, 0%; D 0%; D+, 0%; D++, 0%]

b. We suggest performing endoscopy in all patients with symptoms suggestive of achalasia to exclude other diseases.

Expert opinion recommendation

Consensus: 77.8% agree [Vote: A++, 77.8%; A+, 0%; A, 0%; D 0%; D+, 22.2%; D++, 0%]

1.6 In which patients should additional diagnostic tests be performed in order to exclude pseudo-achalasia?

Malignant pseudo-achalasia is the condition in which a patient is initially diagnosed with achalasia, and sometimes even treated for achalasia, but later found to have an underlying malignancy as the primary cause. This can occur in a submucosally growing adenocarcinoma of the cardia, locally advanced pancreatic cancer, submucosal metastases or anti-Hu-producing carcinomas (typically small cell lung carcinomas).³¹ Certainly not all patients diagnosed with achalasia should undergo additional testing in the form of a CT scan or endoscopic ultrasound to rule out malignancy, however,

valuable time is missed if malignancy is not detected in an early stage. Only two studies have addressed the issue of how to identify patients with malignant pseudo-achalasia.^{32,33} Both case-control studies identified the same differences between patients with primary achalasia and patients with malignant pseudo-achalasia: relatively short duration of symptoms, considerable weight loss and older age. The study by Ponds et al also identified difficulty introducing the endoscope in the stomach as mentioned by the endoscopist as a risk factor. A model was produced in which presence of less than 2 risk factors did not result in increased risk for malignancy, while risk increased from presence of 2 risk factors or more. The authors recommend additional testing in these patients.

Recommendation 1.6

We suggest additional testing using CT or endoscopic ultrasound only in those achalasia patients suspected of malignant pseudo-achalasia. Multiple recognised risk factors for malignant pseudo-achalasia e.g. age > 55 yrs, duration of symptoms < 12 months, weight loss > 10 kg, severe difficulty passing LES with scope may prompt further imaging.

Conditional recommendation, low certainty of evidence

Consensus: 100% agree [Vote: A++, 66.7%; A22.2%; A, 11.1%; D 0%; D+, 0%; D++, 0%]

1.7 What information should the newly diagnosed patient receive?

We recommend to provide the patient with information on the disease and the treatment stated in Table 1.7.1.

Table 1.7.1. Information the newly diagnosed achalasia patient should receive.

Information on the disease

- normal function of oesophagus
- rare condition that affects the neurons, leads to LOS dysrelaxation and absent peristalsis, exact cause not known
- no increased chance of disease in siblings
- what might happen if left untreated
- no progression to other organs
- small increased risk of cancer

Information on treatment options

- explanation of all treatment options, choice of treatment is based upon shared-decision making.
- treatment is not curative, but does improve symptoms
- risk of complications
- risk of reflux
- efficacy of treatments

Expert opinion recommendation

Consensus: 100% agree [Vote: A++, 100%; A+, 0%; A, 0%; D 0%; D+, 0%; D++, 0%]

2. Achalasia treatment

2.1 What should we aim for when treating achalasia patients?

Treatment can be considered for the purpose of reducing symptoms and consequently, improvement of quality of life. As the evidence for the use of standardized questionnaires in the clinical setting is limited, a thorough clinical assessment of oesophageal symptoms before and after therapy should be used to evaluate treatment success. Secondly, treatment might prevent progression to end-stage disease and occurrence of late complications, such as aspiration and carcinogenesis. However, data on the natural history of disease to support this is scarce. There are series showing that if patients remain untreated, oesophageal distension progresses over a period of many years.^{34,35} There is some indirect evidence that treatment can prevent progression of the disease; in a study evaluating patients treated with pneumatic dilation (PD), the persistence of oesophageal stasis on timed barium esophagography was associated with progressive oesophageal dilatation of 0.5 cm in a 2-year period, whereas successful PD (no stasis on TBE) was not.³⁶ Additionally, several surgical studies showed that treatment directed to LOS pressure is less effective in patients with late-stage disease and decompensated oesophagus.^{37–39} In summary, there is some indirect evidence that adequate treatment might reduce the risk of progressive oesophageal dilation in patients with achalasia, potentially preventing a state of gross oesophageal dilation, which in turn is associated with poor outcome. In addition to amelioration of symptoms, improvement of objectively measured oesophageal emptying should therefore be regarded as an important additional treatment aim.

Recommendation 2.1

a. We suggest that in the treatment of achalasia symptom relief should be regarded as the primary treatment aim.

Expert opinion recommendation

Consensus: 100% agree [Vote: A++, 100%; A+, 0%; A, 0%; D 0%; D+, 0%; D++, 0%]

b. We suggest that improvement of objectively measured oesophageal emptying on barium esophagram should be regarded as an important additional treatment aim.

Expert opinion recommendation

Consensus: 100% agree [Vote: A++, 66.7%; A22.2%; A, 11.1%; D 0%; D+, 0%; D++, 0%]

2.2 What is the role of oral pharmacological therapy in achalasia?

There is no convincing evidence that treatment with smooth muscle relaxants (calcium blockers, phosphodiesterase inhibitors or nitrates) provides symptomatic

relief in adults with achalasia. The table presented in appendix C summarises the available literature. None of the studies is of sufficiently high quality, has sufficient sample size and measured adequate endpoints to answer this question.^{40–46} Treatment with smooth muscle relaxants can cause side-effects, and is therefore not recommended. It should certainly not delay an effective endoscopic or surgical treatment. Whether chest pain that is presumed to be due to spastic contractions can be relieved with medical therapy will be discussed in question 3.2.

Recommendation 2.2

We suggest against the use of calcium blockers, phosphodiesterase inhibitors or nitrates for the treatment of achalasia.

Expert opinion recommendation

Consensus: 100% agree [Vote: A++, 66.7%; A+, 33.3%; A, 0%; D 0%; D+, 0%; D++, 0%]

2.3 What is the comparative therapeutic efficacy and safety of endoscopic botulinum toxin injection in the treatment of achalasia?

Endoscopic injection of botulinum toxin (BTX) in the LOS has been compared with laparoscopic Heller myotomy (LHM) or endoscopic pneumatic dilation (PD) in several RCTs.^{47–49} The results of these studies all point in the same direction; BTX injections result in a reduction in LOS pressure, stasis and symptoms in the short term, but generally the disease symptoms and signs recur with time. PD and BTX treatment are equally effective at the short term, while PD is the more effective endoscopic treatment in the long term (greater than six months). Heller and BTX treatment are equally effective at the short term; Heller is the more effective treatment in the long term (greater than six months).

Recommendation 2.3

Botulinum toxin therapy can be considered an effective and safe therapy for short-term symptom relief in oesophageal achalasia.

Conditional recommendation, moderate certainty of evidence

Consensus: 88.9% agree [Vote: A++, 88.9%; A+, 0%; A, 0%; D, 11.1%; D+, 0%; D++, 0%]

2.4 What is the comparative therapeutic efficacy and safety of endoscopic dilation?

Pneumatic dilation (PD) has been compared to endoscopic botulinum toxin injections in the LOS, POEM and Heller myotomy. A factor of importance when comparing the different studies is the PD regimen followed, which varies widely. Broadly speaking,

treatment regimens with multiple dilations performed in case of recurrent symptoms, increase the efficacy. A single series of PDs is less efficacious than LHM or POEM, while there is no difference in safety between the two treatment groups.^{50–53} In studies in which repeated dilation was allowed upon symptom recurrence, the efficacy of PD generally approached that of LHM at a similar safety profile.^{54–58} Given the risk of perforation, it is always advised to start with a 30-mm balloon in an untreated achalasia patient. A second dilation with 35 mm will prolong the time to recurrence.^{54,59}

Recommendation 2.4

Graded pneumatic dilatation is an effective and relatively safe treatment for oesophageal achalasia.

Strong recommendation, high certainty of evidence

Consensus: 100% agree [Vote: A++, 100%; A+, 0%; A, 0%; D 0%; D+, 0%; D++, 0%]

2.5 What is the comparative therapeutic efficacy and safety of per-oral endoscopic myotomy?

POEM appears to be a safe treatment option with a low rate of serious adverse events.^{50,60} Although no long-term (beyond 2 years) follow-up data are available yet, POEM appears to be equally effective to LHM. In a recently published multicentre RCT, treatment success rate, defined as a reduction in Eckardt score <3 and the absence of severe complications or need for re-treatment, after 2 years of follow-up was significantly higher in patients treated with POEM compared to patients treated with PD.⁵⁰ In this study, patients assigned to the PD arm were treated with a single 30-mm dilation, and received a second dilation with a 35-mm balloon if still symptomatic (which was the case in 50 of 66 (76%) patients). GORD occurs more frequently after POEM than after LMH or PD, but high grades of oesophagitis are uncommon.^{61,62} However, one should note that it is very challenging to objectify GORD in achalasia patients, as gastro-oesophageal acid reflux is hard to differentiate from fermentation due to stasis. Nevertheless, in patients with a high risk of post-procedure GORD who are unwilling to use proton pump inhibitor (PPI) therapy, LHM or PD might be preferred over POEM.

Recommendation 2.5

Per-oral endoscopic myotomy is an effective and relatively safe treatment for oesophageal achalasia.

Strong recommendation, high certainty of evidence

Consensus: 100% agree [Vote: A++, 100%; A+, 0%; A, 0%; D 0%; D+, 0%; D++, 0%]

2.6 What is the comparative therapeutic efficacy and safety of surgical myotomy?

During a surgical cardiomyotomy, the spastic LOS is disrupted by cleaving the muscle layers of both the LOS and cardia, allowing passage of foods. Nowadays, the procedure is typically performed laparoscopically and combined with a partial anti-reflux procedure (fundoplication). A complete 360-degree wrap should be avoided in achalasia patients to prevent worsening, rather than relieving, the dysphagia.⁶³ Six RCTs compared the efficacy of LHM versus PD (two of them reporting long-term results) and multiple meta-analyses were performed.^{51–58,64,65} These studies report a similar outcome for LHM and PD when multiple sessions of graded dilations were allowed (sequential dilations). However, LHM performed better than two sessions of PD. The meta-analysis (where PD outcome was assessed independently of the number of PD sessions) was in favour of LHM. LHM was more effective than PD in type III achalasia in a sub-group analysis of the European Achalasia Trial. One RCT compared LHM to botulinum toxin injection and showed a better outcome for LHM after 6 months of follow-up, after an initial similar response.⁴⁹ There is only one RCT, comparing LHM and POEM, showing a similar symptomatic outcome for the two treatments after a follow-up of up to 2 years.⁶⁰ A meta-analysis focusing on risk of iatrogenic reflux after POEM versus LHM suggested the increased risk of GORD after POEM.⁶¹

Recommendation 2.6

Laparoscopic Heller myotomy combined with an anti-reflux procedure is an effective and relatively safe therapy for achalasia.

Strong recommendation, high certainty of evidence

Consensus: 100% agree [Vote: A++, 100%; A+, 0%; A, 0%; D, 0%; D+, 0%; D++, 0%]

2.7 What are predictors of treatment outcome? How to choose initial treatment?

In order to guide therapeutic decisions, it is useful to distinguish patient types that are likely to respond favourably to a certain therapy. Patient-specific factors such as age, sex, and manometric type are commonly believed to be predictive of treatment outcome, with the unfavourable effect of young age undoubtedly being the most frequently described example.^{66–69} A recently published review systematically assessed 75 studies that investigated potential patient-specific predictors.⁷⁰ A total of 34 predictors were identified, but of all pre-therapeutic factors, only age and manometric subtype were identified as important predictors with a strong level of cumulative evidence. A meta-analysis confirmed that older patients (>45 years) responded better to PD

treatment than younger individuals. Manometric subtype 3 was associated with poor treatment outcome in general. Interestingly, of the 49 included studies that evaluated sex as potential predictor, 90% did not find an association between sex and treatment outcome, indicating that sex most likely is not of predictive value in clinical decision making. The predictive value of some of the studied factors, such as chest pain and symptom severity remains unclear, as the total body of evidence was inconclusive or insufficient to draw firm conclusions. It is suggested that age and manometric subtype should be taken into account when selecting a therapeutic strategy, in conjunction with information on efficacy and safety of the individual procedures, patient preference, and local expertise.

Recommendation 2.7

We suggest taking age and manometric subtype into account when selecting a therapeutic strategy.

Conditional recommendation, moderate certainty of evidence

Consensus: 100% agree [Vote: A++, 100%; A+, 0%; A, 0%; D, 0%; D+, 0%; D++, 0%]

2.8 Overall recommendations on treatment (comparative effectiveness and safety)

Based on the systematic reviews and GRADE assessments of research question 2.3 – 2.7 combined, the working group proposes the following overall recommendations with regard to achalasia therapy:

Recommendation 2.8

a. Treatment decisions in achalasia should be made based on patient-specific characteristics, the patient's preference, possible side effects and/or complications and a center's expertise. Overall, graded repetitive PD, LHM and POEM have comparable efficacy.

Strong recommendation, moderate certainty of evidence

Consensus: 100% agree [Vote: A++, 55.6%; A+, 44.4%; A, 0%; D, 0%; D+, 0%; D++, 0%]

b. Botulinum toxin therapy should be reserved for patients who are too unfit for more invasive treatments, or in whom a more definite treatment needs to be deferred.

Conditional recommendation, moderate certainty of evidence

Consensus: 100% agree [Vote: A++, 100%; A+, 0%; A, 0%; D, 0%; D+, 0%; D++, 0%]

2.9 How to treat post-Heller recurrence?

Minimally invasive surgical therapy in achalasia is effective in the majority of patients, however symptom relapse occurs in 10-20% of patients at the long term.⁵⁵ No adequate prospective controlled trials have been

conducted on management of failed Heller myotomy due to low patient numbers. Current options for treatment of Heller recurrence include endoscopic dilation, POEM, or redo surgery. When no gross anatomic abnormalities are present, PD or POEM can be considered. Both procedures show equally modest efficacy rates, but PD is often regarded a less-invasive first step.^{71–79} In the event of recurrence due to a too tight or twisted fundoplication, or a more complex anatomy with oesophageal distortion, fibrosis or a post-myotomy diverticulum, redo surgery may be considered. However, this is associated with a substantial risk of post-operative complications.^{74,80–82}

Recommendation 2.9

We suggest treating recurrent or persistent dysphagia after laparoscopic Heller myotomy with PD, POEM or redo surgery.

Conditional recommendation, very low certainty of evidence

Consensus: 100% agree [Vote: A++, 22.2%; A+, 77.8%; A, 0%; D 0%; D+, 0%; D++, 0%]

2.10 How to treat post-POEM recurrence

Although POEM has good-to-excellent efficacy rates, treatment failure with recurrent or persistent symptoms does occur.^{50,62,83} In a recently published randomised controlled trial comparing endoscopic myotomy with PD, the authors reported clinical failure in 8% of patients treated with POEM after two years of follow-up.⁵⁰ Data on the best therapeutic approach after POEM failure is limited. Two case series reported success rates of 80–100% after three months of follow-up in patients treated with re-POEM after initial failure.^{84,85} Another study evaluating retreatment after POEM failure in 43 patients, showed that retreatment with either LHM or re-POEM gives modest efficacy rates of 45% and 63%, respectively, whereas PD showed a poor efficacy of only 20%.⁸⁶ These results may indicate superiority of both POEM and LHM compared to PD in the management of POEM failure. However, it must be noted, that the data to support this is weak and based on case series only. Moreover, PD is feasible and available in many centres, and is considered to be less invasive than re-myotomy and can therefore not completely be omitted in the management of this patient group.

Recommendation 2.10

We suggest treating recurrent or persistent dysphagia after POEM with either re-POEM, laparoscopic Heller myotomy or pneumatic dilation.

Conditional recommendation, very low certainty of evidence

Consensus: 100% agree [Vote: A++, 77.8%; A+, 22.2%; A, 0%; D 0%; D+, 0%; D++, 0%]

2.11 What are indications for oesophagectomy?

Oesophagectomy for achalasia is associated with a high risk of complications and mortality.^{87,88} A systematic review of 8 studies and 1307 patients that underwent oesophagectomy, reported a complication rate of 19%–50% and a mortality rate 0–3.8%.⁸⁷ In a large series of over 500 patients, oesophagectomy was initially performed in less than 1% of the entire population, but ultimately 17% of patients required oesophageal resection. Particularly those who failed surgical treatment or those with end-stage achalasia, which is often associated with massive oesophageal dilatation and tortuosity.⁸² In a report on 53 patients with end-stage achalasia that underwent oesophageal resection, the indications were tortuous mega-oesophagus (64%) or oesophageal stricture formation due to reflux (7%).⁸⁹ Other indications for oesophageal resection are presence of high-grade dysplasia or cancer. Although the in-hospital mortality after oesophagectomy is lower in patients with achalasia than in patients with cancer (2.8% vs. 7.7%, respectively), it is still a substantial risk, especially as the indication for resection is not as strong as for malignant disease. Moreover, the overall post-operative complication rate is similar in both patient groups.⁹⁰ Hence, oesophagectomy should be considered the last resort in end-stage achalasia, where disabling symptoms reoccur despite aggressive treatment.^{91,92} On the other hand, as the risk and complexity of oesophageal resection increases with the deterioration of a patient's condition and nutritional status, end-stage achalasia should be carefully followed-up to promptly identify when oesophagectomy is necessary.

Recommendation 2.11

Oesophagectomy should be considered the last resort to treat achalasia, after all other treatments have been considered.

Expert opinion recommendation

Consensus: 100% agree [Vote: A++, 77.8%; A+, 22.2%; A, 0%; D 0%; D+, 0%; D++, 0%]

2.12 What is the role of alternative therapies in the treatment of achalasia?

Several studies have investigated the use of alternative therapies such as oesophageal stents^{93–101} and intrasphincteric injection with ethanalamine oleate in achalasia treatment.^{102–105} Overall, there is no high-quality evidence to support that either of these therapies are effective for symptom relief in achalasia patients. Moreover, as occurrence of complications such as bleeding, stent migration, or strictures are fairly common, use of these therapies is not recommended.

Recommendation 2.12

We suggest against oesophageal stents and intrasphincteric injection of sclerosing agents in the treatment of achalasia.

Expert opinion recommendation

Consensus: 100% agree [Vote: A++, 100%; A+, 0%; A, 0%; D 0%; D+, 0%; D++, 0%]

3. Achalasia follow-up**3.1 How to diagnose and manage recurrent or persistent dysphagia after treatment?**

Despite treatment, a proportion of patients will experience ongoing or recurrent symptoms that significantly impair quality of life.^{86,106} In some cases, treatment does not lead to meaningful improvement in the first place (persistent symptoms). In others, a period of initial improvement is followed by subsequent recurrence. In general terms, the former suggests that initial treatment was incomplete, whereas the latter can be due to a variety of causes. There is no universal definition of what constitutes persistence or recurrence of symptoms. In most trials an Eckardt score above 3 or a less than 50% improvement in symptoms is regarded as treatment failure.^{47,50,54,107–109} However, this fails to distinguish between dysphagia, and alternative troublesome symptoms such as regurgitation or chest pain. Although dysphagia is the most common ongoing symptom after achalasia treatment,⁸⁶ the aetiology may be different to that in the treatment-naïve setting (Table 3.1.1).

Given the wide variety of potential causes of recurrent dysphagia, it is critical to undertake a comprehensive evaluation using objective testing in order to determine the pathophysiology underpinning the recurrent symptoms, and thus select appropriate treatment. Conversely, in selected cases of persistent dysphagia,

Table 3.1.1. Potential causes for persistent and recurrent dysphagia after initial treatment.

Common

- Persistent OGJ non-relaxation (e.g. incomplete myotomy)
- Post-treatment oesophageal fibrosis/scarring
- Excessively tight fundoplication post-myotomy
- Gastro-oesophageal reflux (with or without oesophagitis)
- Aperistalsis and oesophageal stasis
- Functional dysphagia

Uncommon

- Development of malignant stricture
- Wrap migration after fundoplication and myotomy
- Benign stricture (e.g. from reflux)
- Extrinsic compression from hiatal hernia (para-oesophageal) or post-treatment collection

where the diagnosis of achalasia is beyond doubt, it may be appropriate to proceed immediately to further treatment without repeat testing (for example, POEM after failure to improve with PD).

Since the commonest causes of recurrent dysphagia are incomplete myotomy, post-treatment scarring, and oesophageal stasis due to aperistalsis and functional dysphagia, objective testing should be targeted at these conditions. Timed barium esophagram helps determine if there is persistent delay to oesophageal emptying, but reports regarding its usefulness as a predictor of long-term treatment success are conflicting.^{36,55,108} High-resolution manometry provides additional information on LOS pressure. Impedance planimetry might be a useful complementary tool to assess OGJ distensibility and determine treatment efficacy.^{16,110} In patients with a suspicion of severe oesophagitis, possible candida oesophagitis or anatomic abnormalities endoscopy should be considered.

Recommendation 3.1

- a. Patients with recurrent or persistent dysphagia after initial treatment should undergo repeat evaluation with timed barium esophagram with or without oesophageal manometry.

Expert opinion recommendation

Consensus: 100% agree [Vote: A++, 100%; A+, 0%; A, 0%; D 0%; D+, 0%; D++, 0%]

- b. Repeat endoscopy should be considered in patients with recurrent dysphagia.

Expert opinion recommendation

Consensus: 100% agree [Vote: A++, 66.7%; A+, 33.3%; A, 0%; D 0%; D+, 0%; D++, 0%]

3.2 How to diagnose and manage recurrent or persistent chest pain after treatment?

Although chest pain is one of the main presenting symptoms of achalasia, its response to treatment is less well studied and remarkably underreported, most likely as dysphagia is considered the leading and most relevant symptom. Nevertheless, up to 64% of patients report chest pain, often occurring in the middle of the night (in 47% of patients with chest pain) and lasting from a few minutes to almost 24 hours.¹¹¹ In contrast to dysphagia, chest pain is more challenging to treat and represents a risk factor for unsatisfactory treatment results for both pneumatic dilation (PD) and laparoscopic Heller myotomy (LHM).^{37,54,112} In approximately 19% of patients, chest pain is completely relieved following LHM, but in the remainder chest pain persists, with an intensity that is less (73%), similar (21%) or even more severe (4%) than before surgery.¹¹³ Comparable results have been reported for PD.¹¹¹ Of note, chest pain persists in these patients even though dysphagia was

successfully treated. In general, achalasia-associated chest pain seems to decrease with time, but complete disappearance is rather exceptional.¹¹¹

The exact cause underlying (non-cardiac) chest pain remains unknown, and can be attributed to acid reflux, oesophageal motor abnormalities or visceral hypersensitivity. However, as chest pain is also considered to result from oesophageal distension as a result of incomplete emptying, treatment failure should first be excluded in patients with persistent or recurrent chest pain by performing oesophageal manometry and timed barium esophagram (TBE).

If manometry (IRP above cut-off; catheter-dependency, varying between 15 and 28 mmHg)¹¹⁴ or TBE are abnormal (barium column height of >5cm after 5 minutes),¹¹⁵ treatment should aim to normalize oesophageal emptying. HRM also serves to exclude spastic contractions as cause of the pain. If there is no evidence indicating insufficient treatment, one can consider investigation for gastro-oesophageal reflux (GER) as trigger of chest pain using 24-hour pH (impedance) monitoring and treat accordingly.¹¹⁶ Data demonstrating the effect of PPI on chest pain in achalasia are however lacking, and anecdotally the response to PPI is poor if there is chest pain without heartburn.

The management of achalasia patients with chest pain with no evidence of GER and normal oesophageal emptying/IRP remains a major challenge, mainly as there are no or only a limited number of randomised clinical trials available. Hence, clinical decision making is mostly based on studies performed in patients with non-cardiac chest pain due to oesophageal dysmotility. Potential options for medical treatment are smooth muscle relaxants (nifedipine, nitrates, diltiazem), botulinum toxin injection or neuromodulators (imipramine, venlafaxine, sertraline)¹¹⁶; however, the success rates are rather limited and/or the effect is short lasting (in case of botulinum toxin). Of interest, evidence is accumulating that POEM might be effective in relieving chest pain, both in patients with achalasia and other primary oesophageal motility disorders. Several case series evaluating patients with hypercontractile oesophageal motility disorders and chest pain that were treated with POEM showed promising results.^{117–120} However, as none of the studies were sham-controlled, patient numbers were small and lengths of follow-up relatively short, future controlled data with longer follow-up is needed to investigate the exact role of POEM for patients with chest pain after initial achalasia treatment.

Recommendation 3.2

a. In patients with persistent or recurrent chest pain, inappropriate emptying due to ineffective initial treatment or recurrent disease should be excluded by TBE with or without oesophageal
(continued)

Continued.

manometry. For type III achalasia, we suggest a repeat HRM to exclude or confirm persistent spastic contractions.

Expert opinion recommendation

Consensus: 100% agree [Vote: A++, 88.9%; A+, 11.1%; A, 0%; D 0%; D+, 0%; D++, 0%]

b. If there is no evidence of impaired oesophageal emptying, empirical treatment with PPI, endoscopy and/or 24-hour pH (impedance) monitoring can be considered.

Expert opinion recommendation

Consensus: 100% agree [Vote: A++, 100%; A+, 0%; A, 0%; D 0%; D+, 0%; D++, 0%]

3.3 How to manage reflux disease after treatment?

As the aim of achalasia treatment is to alleviate the OGJ obstruction, an expected side effect of treatment is the occurrence of gastro-oesophageal reflux disease (GORD), usually defined in achalasia as the presence of reflux oesophagitis or pathological acid exposure. Indeed GORD is frequently observed after treatment (10 to 31% of cases after pneumatic dilation^{51–53,55,58,121} 5 to 35% after Heller's myotomy^{52,53,55,121–123} and up to 60% of patients after POEM)^{50,60,61,124–126} GORD complications including peptic stricture, Barrett's mucosa, and oesophageal adenocarcinoma have been reported after achalasia treatment.^{124,126–130} Comparative studies demonstrated that the rate of GORD was similar after PD and LHM with fundoplication.¹²¹ One study showed that LHM without lateral and posterior dissection might also achieve sufficient reflux control.¹³¹ However, in other studies, prevalence of GORD was significantly higher after POEM or laparoscopic Heller myotomy without fundoplication than after pneumatic dilation or laparoscopic Heller myotomy with fundoplication.^{50,60,62,132} Therefore, systematic screening for GORD after achalasia treatment should be recommended if the risk for GORD is high. Moreover, due to the different GORD rates, the choice of achalasia treatment should take into account the risk of iatrogenic reflux disease. In line with this, empiric PPI therapy might be considered in patients that underwent myotomy without an anti-reflux procedure.

GORD symptoms such as heartburn and regurgitation are not reliable to diagnose GORD in achalasia patients, especially as regurgitation is also a hallmark of achalasia and poor oesophageal emptying. Upper endoscopy can reveal oesophagitis and Barrett's mucosa as proof of GORD. Another way to diagnose GORD is 24-h oesophageal pH monitoring. The interpretation of this examination requires a careful review of pH tracings to eliminate periods of

oesophageal fermentation.⁵³ The correlation between oesophageal symptoms and objective diagnosis of GORD (including oesophagitis and oesophageal acid exposure) is poor.^{62,123,133–135} Upper GI endoscopy, TBE and 24-h pH monitoring might be complementary.

So far, no study has clearly evaluated the management of GORD after achalasia treatment. Post-treatment GORD is usually treated successfully with PPI. The percentage of patients on PPI after achalasia treatment is up to 60%.^{60,61,136–138} Few other GORD treatments have been proposed for refractory cases and presented only as case reports (re-do fundoplication, Roux-en-Y gastric bypass, esophagectomy, transoral incisionless fundoplication).^{89,139,140}

Recommendation 3.3

a. We suggest follow-up endoscopy to screen for GORD in patients treated with myotomy without anti-reflux procedure.

Expert opinion recommendation

Consensus: 100% agree [Vote: A++, 44.4%; A+, 44.4%; A, 11.1%; D 0%; D+, 0%; D++, 0%]

b. In case of reflux symptoms in absence of reflux oesophagitis, TBE, empiric PPI therapy, and/or 24-h oesophageal pH-(impedance)monitoring can be considered.

Expert opinion recommendation

Consensus: 100% agree [Vote: A++, 77.8%; A+, 22.2%; A, 0%; D 0%; D+, 0%; D++, 0%]

c. Proton pump inhibitors are the first line treatment of GORD after achalasia treatment. We recommend lifelong PPI therapy in patients with oesophagitis > grade A (LA classification).

Expert opinion recommendation

Consensus: 100% agree [Vote: A++, 33.3%; A+, 55.6%; A, 11.1%; D 0%; D+, 0%; D++, 0%]

3.4 Is surveillance endoscopy for dysplasia needed?

What is the incidence of oesophageal cancer in achalasia patients?

Achalasia is a risk factor for oesophageal cancer. Poor oesophageal clearance increases bacterial growth, chemical irritation and mucosal inflammation that can facilitate dysplastic changes of oesophageal epithelial cells and result in squamous cell carcinoma (SCC).¹⁴¹ Furthermore, acid exposure secondary to reduction of oesophago-gastric junction pressure as a consequence of achalasia treatment may lead to Barrett's mucosa and oesophageal adenocarcinoma (EA).¹⁴²

The exact level of risk for oesophageal cancer (SCC and EA) is controversial. Differences in study design

(retrospective or prospective, length of Follow-up, number of patients, countries) might explain some of the observed differences. While the absolute risk of oesophageal cancer is quite low in achalasia, the relative risk of cancer is higher in achalasia patients than in the general population (risk ratio to develop EA and SCC in achalasia patients is 6.63 and 72.65 respectively).^{143,144} Most of the cases of carcinoma are observed more than 10 years after symptom onset.^{144,145} The type of treatment does not influence the risk of cancer^{130,146} but to date there are no long-term data following POEM. Cancer risk might be higher in males and in patients with Chagas disease.^{130,146,147}

Screening practices differ among geographic regions (routine endoscopy versus no endoscopy, screening intervals).^{92,148} Chromoendoscopy with lugol was proposed to improve the detection rate of dysplastic lesion but the yield was low and hampered by stratification risk.¹⁴⁵

Finally the cost efficacy of the screening has not been demonstrated; the low absolute risk of cancer and the difficulty to identify pre-neoplastic lesions might explain the absence of advantage to screen achalasia patients for oesophageal cancer.

Recommendation 3.4

We suggest against performing systematic screening for dysplasia and carcinoma. However, the threshold of upper GI endoscopy should be low in patients with recurrent symptoms and longstanding achalasia.

Conditional recommendation, low certainty of evidence

Consensus: 100% agree [Vote: A++, 66.7%; A+, 33.3%; A, 0%; D 0%; D+, 0%; D++, 0%]

Conclusions and future perspectives

The ESNM/UEG guidelines on the management of achalasia are the result of an evidence-based approach and international and multidisciplinary efforts. These guidelines provide recommendations for key aspects of the diagnosis and management of achalasia, combined with comments based on the best-available literature and the opinions of leading European achalasia experts. The main objective of these guidelines is to reduce variation in practice and improve patient outcomes across Europe. Consequently, thorough and extensive dissemination of these guidelines is needed to assure high compliance in clinical practice. Promotion of the guideline as well as education play a key role in this regard. Future well-designed clinical trials should address the gaps of knowledge and unmet needs that have arisen during the development of this guideline.

Author contributions

RON and AB were responsible for drafting the guidelines protocol, coordinating the development of the guidelines and the initial list of research questions to be covered by the guidelines. RON and ML conducted the literature search and systematic selection of articles. Working group expert members (AB, GB, PF, AP, SR, AS, AT, ET, BW, GZ) systematically appraised the literature and assessed the evidence according to GRADE and drafted the statements. RON and ML provided methodological support. All expert members voted on the recommendations. RON and AB drafted the manuscript, which was reviewed, revised and approved by all authors.

Declaration of conflicting interests

No disclosures or conflicts of interest: GB, ML, RON, AT, ET, AS, BW, GZ. Research support: Bayer (AB), Crospon (SR), Diversatek (SR), Laborie (AB), Medtronic (SR) Nutricia (AB), Norgine (AB). Advisory, honoraria or consultation: Calypso (AB), Celgene (AB), Cook (PF), Diversatek (AB), EsoCap (AB), Ethicon (PF), Falk (AB), Fujifilm (PF), Laborie (AB), Medtronic (PF, SR), Olympus (PF), Regeneron (AB). Speaker's bureau: Actavis (AP), Falk (AB), Janssen-Cilag (AP), Laborie (AB), Mayoly Spindler (SR), Medtronic (AB), Takeda (AP).

Funding

These guidelines have been developed and funded within the United European Gastroenterology.

ORCID iD

AS Trukhmanov  <https://orcid.org/0000-0003-3362-2968>

Supplemental Material

Supplemental material for this article is available online.

References

1. Jeon HH, Kim JH, Youn YH, et al. Clinical Characteristics of Patients with Untreated Achalasia. *Journal of neurogastroenterology and motility* 2017; 23: 378–384. 2017/03/30. DOI: 10.5056/jnm16177.
2. van Hoeij FB, Ponds FA, Smout AJ, et al. Incidence and costs of achalasia in The Netherlands. *Neurogastroenterology and motility: the official journal of the European Gastrointestinal Motility Society* 2018; 302017/08/25. DOI: 10.1111/nmo.13195.
3. Samo S, Carlson DA, Gregory DL, et al. Incidence and Prevalence of Achalasia in Central Chicago, 2004–2014, Since the Widespread Use of High-Resolution Manometry. *Clinical gastroenterology and hepatology: the official clinical practice journal of the American Gastroenterological Association* 2017; 15: 366–373. 2016/09/02. DOI: 10.1016/j.cgh.2016.08.030.
4. Sadowski DC, Ackah F, Jiang B, et al. Achalasia: incidence, prevalence and survival. A population-based study. *Neurogastroenterology and motility: the official journal of the European Gastrointestinal Motility Society* 2010; 22: e256–261. 2010/05/15. DOI: 10.1111/j.1365-2982.2010.01511.x.
5. Fox MR and Bredenoord AJ. Oesophageal high-resolution manometry: moving from research into clinical practice. *Gut* 2008; 57: 405–423. 2007/09/27. DOI: 10.1136/gut.2007.127993.
6. Carlson DA, Ravi K, Kahrilas PJ, et al. Diagnosis of Esophageal Motility Disorders: Esophageal Pressure Topography vs. Conventional Line Tracing. *The American journal of gastroenterology* 2015; 110: 967–977; quiz 978. 2015/06/03. DOI: 10.1038/ajg.2015.159.
7. Soudagar AS, Sayuk GS and Gyawali CP. Learners favour high resolution oesophageal manometry with better diagnostic accuracy over conventional line tracings. *Gut* 2012; 61: 798–803. 2011/10/15. DOI: 10.1136/gutjnl-2011-301145.
8. Clouse RE, Staiano A, Alrakawi A, et al. Application of topographical methods to clinical esophageal manometry. *The American journal of gastroenterology* 2000; 95: 2720–2730. 2000/10/29. DOI: 10.1111/j.1572-0241.2000.03178.x.
9. Roman S, Huot L, Zerbib F, et al. High-Resolution Manometry Improves the Diagnosis of Esophageal Motility Disorders in Patients With Dysphagia: A Randomized Multicenter Study. *The American journal of gastroenterology* 2016; 111: 372–380. 2016/02/03. DOI: 10.1038/ajg.2016.1.
10. O'Rourke AK, Lazar A, Murphy B, et al. Utility of Esophagram versus High-Resolution Manometry in the Detection of Esophageal Dysmotility. *Otolaryngology–head and neck surgery: official journal of American Academy of Otolaryngology-Head and Neck Surgery* 2016; 154: 888–891. 2016/02/26. DOI: 10.1177/0194599816629379.
11. Parkman HP, Maurer AH, Caroline DF, et al. Optimal evaluation of patients with nonobstructive esophageal dysphagia: Manometry, scintigraphy, or videoesophagography? *Digestive diseases and sciences* 1996; 41: 1355–1368. 1996/07/01.
12. Aronova. Esophageal Dysmotility and the Utility of Barium Swallow: An Opaque Diagnosis. *Ann Surgery and Perioperative Care*, 2017.
13. El-Takli I, O'Brien P and Paterson WG. Clinical diagnosis of achalasia: how reliable is the barium x-ray? *Canadian journal of gastroenterology = Journal canadien de gastroenterologie* 2006; 20: 335–337. 2006/05/13.
14. Yamasaki T, Tomita T, Mori S, et al. Esophagography in Patients With Esophageal Achalasia Diagnosed With High-resolution Esophageal Manometry. *Journal of neurogastroenterology and motility* 2018; 24: 403–409. 2018/07/04. DOI: 10.5056/jnm17147.
15. Blonski W, Kumar A, Feldman J, et al. Timed Barium Swallow: Diagnostic Role and Predictive Value in Untreated Achalasia, Esophagogastric Junction Outflow Obstruction, and Non-Achalasia Dysphagia. *The American journal of gastroenterology* 2018; 113: 196–203. 2017/12/20. DOI: 10.1038/ajg.2017.370.
16. Rohof WO, Hirsch DP, Kessing BF, et al. Efficacy of treatment for patients with achalasia depends on the distensibility of the esophagogastric junction. *Gastroenterology* 2012; 143: 328–335. 2012/05/09. DOI: 10.1053/j.gastro.2012.04.048.

17. Rieder E, Swanstrom LL, Perretta S, et al. Intraoperative assessment of esophagogastric junction distensibility during per oral endoscopic myotomy (POEM) for esophageal motility disorders. *Surgical endoscopy* 2013; 27: 400–405. 2012/09/08. DOI: 10.1007/s00464-012-2484-0.
18. Pandolfino JE, de Ruigh A, Nicodeme F, et al. Distensibility of the esophagogastric junction assessed with the functional lumen imaging probe (FLIP) in achalasia patients. *Neurogastroenterology and motility: the official journal of the European Gastrointestinal Motility Society* 2013; 25: 496–501. 2013/02/19. DOI: 10.1111/nmo.12097.
19. Smeets FG, Masclee AA, Keszthelyi D, et al. Esophagogastric junction distensibility in the management of achalasia patients: relation to treatment outcome. *Neurogastroenterology and motility: the official journal of the European Gastrointestinal Motility Society* 2015; 27: 1495–1503. 2015/08/13. DOI: 10.1111/nmo.12651.
20. Chen JW and Rubenstein JH. Esophagogastric junction distensibility assessed using the functional lumen imaging probe. *World journal of gastroenterology* 2017; 23: 1289–1297. 2017/03/10. DOI: 10.3748/wjg.v23.i7.1289.
21. Carlson DA, Kou W, Lin Z, et al. Normal Values of Esophageal Distensibility and Distension-Induced Contractility Measured by Functional Luminal Imaging Probe Panometry. *Clinical gastroenterology and hepatology: the official clinical practice journal of the American Gastroenterological Association* 2019; 17: 674–681.e671. 2018/08/07. DOI: 10.1016/j.cgh.2018.07.042.
22. Carlson DA, Lin Z, Kahrilas PJ, et al. The Functional Lumen Imaging Probe Detects Esophageal Contractility Not Observed With Manometry in Patients With Achalasia. *Gastroenterology* 2015; 149: 1742–1751. 2015/08/19. DOI: 10.1053/j.gastro.2015.08.005.
23. Hirano I, Pandolfino JE and Boeckxstaens GE. Functional Lumen Imaging Probe for the Management of Esophageal Disorders: Expert Review From the Clinical Practice Updates Committee of the AGA Institute. *Clinical gastroenterology and hepatology: the official clinical practice journal of the American Gastroenterological Association* 2017; 15: 325–334. 2017/02/19. DOI: 10.1016/j.cgh.2016.10.022.
24. Ponds FA, Bredenoord AJ, Kessing BF, et al. Esophagogastric junction distensibility identifies achalasia subgroup with manometrically normal esophagogastric junction relaxation. *Neurogastroenterology and motility: the official journal of the European Gastrointestinal Motility Society* 2017; 29 2016/07/28. DOI: 10.1111/nmo.12908.
25. Howard PJ, Maher L, Pryde A, et al. Five year prospective study of the incidence, clinical features, and diagnosis of achalasia in Edinburgh. *Gut* 1992; 33: 1011–1015. 1992/08/01. DOI: 10.1136/gut.33.8.1011.
26. Reynolds JC and Parkman HP. Achalasia. *Gastroenterology clinics of North America* 1989; 18: 223–255. 1989/06/01.
27. Fisichella PM, Raz D, Palazzo F, et al. Clinical, radiological, and manometric profile in 145 patients with untreated achalasia. *World journal of surgery* 2008; 32: 1974–1979. 2008/06/26. DOI: 10.1007/s00268-008-9656-z.
28. Boeckxstaens GE. Achalasia. *Best practice & research Clinical gastroenterology* 2007; 21: 595–608. 2007/07/24. DOI: 10.1016/j.bpg.2007.03.004.
29. Boeckxstaens GE, Zaninotto G and Richter JE. Achalasia. *Lancet (London, England)* 2014; 383: 83–93. 2013/07/23. DOI: 10.1016/s0140-6736(13)60651-0.
30. Triadafilopoulos G, Boeckxstaens GE, Gullo R, et al. The Kagoshima consensus on esophageal achalasia. *Diseases of the esophagus: official journal of the International Society for Diseases of the Esophagus* 2012; 25: 337–348. 2011/05/21. DOI: 10.1111/j.1442-2050.2011.01207.x.
31. Barret M, Rouquette A, Massault PP, et al. Pseudoachalasia. *Clinics and research in hepatology and gastroenterology* 2018; 42: 99–100. 2017/08/07. DOI: 10.1016/j.clinre.2017.05.006.
32. Ponds FA, van Raath MI, Mohamed SMM, et al. Diagnostic features of malignancy-associated pseudoachalasia. *Alimentary pharmacology & therapeutics* 2017; 45: 1449–1458. 2017/04/07. DOI: 10.1111/apt.14057.
33. Rozman RW Jr and Achkar E. Features distinguishing secondary achalasia from primary achalasia. *The American journal of gastroenterology* 1990; 85: 1327–1330. 1990/10/01.
34. Ellis FG. The natural history of achalasia of the cardia. *Proceedings of the Royal Society of Medicine* 1960; 53: 663–666. 1960/08/01.
35. Csendes P, Csendes A, Cortes C, et al. Evolutive radiological changes of the esophagus in patients with achalasia who did not receive treatment. *Surgery today* 2007; 37: 183–186. 2007/03/08. DOI: 10.1007/s00595-006-3365-8.
36. van Hoeij FB, Smout A and Bredenoord AJ. Esophageal stasis in achalasia patients without symptoms after treatment does not predict symptom recurrence. *Neurogastroenterology and motility: the official journal of the European Gastrointestinal Motility Society* 2017; 29 2017/03/21. DOI: 10.1111/nmo.13059.
37. Costantini M, Salvador R, Capovilla G, et al. A Thousand and One Laparoscopic Heller Myotomies for Esophageal Achalasia: a 25-Year Experience at a Single Tertiary Center. *Journal of gastrointestinal surgery: official journal of the Society for Surgery of the Alimentary Tract* 2019; 23: 23–35. 2018/09/22. DOI: 10.1007/s11605-018-3956-x.
38. Schuchert MJ, Luketich JD, Landreneau RJ, et al. Minimally-invasive esophagomyotomy in 200 consecutive patients: factors influencing postoperative outcomes. *The Annals of thoracic surgery* 2008; 85: 1729–1734. 2008/04/30. DOI: 10.1016/j.athoracsur.2007.11.017.
39. Pechlivanides G, Chrysos E, Athanasakis E, et al. Laparoscopic Heller cardiomyotomy and Dor fundoplication for esophageal achalasia: possible factors predicting outcome. *Archives of surgery (Chicago, Ill: 1960)* 2001; 136: 1240–1243. 2001/12/26. DOI: 10.1001/archsurg.136.11.1240.
40. Bortolotti M and Labo G. Clinical and manometric effects of nifedipine in patients with esophageal achalasia. *Gastroenterology* 1981; 80: 39–44. 1981/01/01.

41. Gelfond M, Rozen P and Gilat T. Isosorbide dinitrate and nifedipine treatment of achalasia: a clinical, manometric and radionuclide evaluation. *Gastroenterology* 1982; 83: 963–969. 1982/11/01.
42. Nasrallah SM, Tommaso CL, Singleton RT, et al. Primary esophageal motor disorders: clinical response to nifedipine. *Southern medical journal* 1985; 78: 312–315. 1985/03/01.
43. Marzio L, Grossi L, DeLaurentiis MF, et al. Effect of cimetropium bromide on esophageal motility and transit in patients affected by primary achalasia. *Digestive diseases and sciences* 1994; 39: 1389–1394. 1994/07/01.
44. Wong RK, Maydonovitch C, Garcia JE, et al. The effect of terbutaline sulfate, nitroglycerin, and aminophylline on lower esophageal sphincter pressure and radionuclide esophageal emptying in patients with achalasia. *Journal of clinical gastroenterology* 1987; 9: 386–389. 1987/08/01.
45. Eherer AJ, Schwetz I, Hammer HF, et al. Effect of sildenafil on oesophageal motor function in healthy subjects and patients with oesophageal motor disorders. *Gut* 2002; 50: 758–764. 2002/05/16.
46. Bortolotti M, Mari C, Lopilato C, et al. Effects of sildenafil on esophageal motility of patients with idiopathic achalasia. *Gastroenterology* 2000; 118: 253–257. 2000/01/29.
47. Leyden JE, Moss AC and MacMathuna P. Endoscopic pneumatic dilation versus botulinum toxin injection in the management of primary achalasia. *The Cochrane database of systematic reviews* 2014; Cd005046. 2014/12/09. DOI: 10.1002/14651858.CD005046.pub3.
48. Pasricha PJ, Ravich WJ, Hendrix TR, et al. Intraspincteric botulinum toxin for the treatment of achalasia. *The New England journal of medicine* 1995; 332: 774–778. 1995/03/23. DOI: 10.1056/nejm199503233321203.
49. Zaninotto G, Annese V, Costantini M, et al. Randomized controlled trial of botulinum toxin versus laparoscopic heller myotomy for esophageal achalasia. *Annals of surgery* 2004; 239: 364–370. 2004/04/13.
50. Ponds FA, Fockens P, Lei A, et al. Effect of Peroral Endoscopic Myotomy vs Pneumatic Dilation on Symptom Severity and Treatment Outcomes Among Treatment-Naive Patients With Achalasia: A Randomized Clinical Trial. *Jama* 2019; 322: 134–144. 2019/07/10. DOI: 10.1001/jama.2019.8859.
51. Chrystoja CC, Darling GE, Diamant NE, et al. Achalasia-Specific Quality of Life After Pneumatic Dilation or Laparoscopic Heller Myotomy With Partial Fundoplication: A Multicenter, Randomized Clinical Trial. *The American journal of gastroenterology* 2016; 111: 1536–1545. 2016/11/04. DOI: 10.1038/ajg.2016.402.
52. Borges AA, Lemme EM, Abrahao LJ Jr, et al. Pneumatic dilation versus laparoscopic Heller myotomy for the treatment of achalasia: variables related to a good response. *Diseases of the esophagus: official journal of the International Society for Diseases of the Esophagus* 2014; 27: 18–23. 2013/04/05. DOI: 10.1111/dote.12064.
53. Novais PA and Lemme EM. 24-h pH monitoring patterns and clinical response after achalasia treatment with pneumatic dilation or laparoscopic Heller myotomy. *Alimentary pharmacology & therapeutics* 2010; 32: 1257–1265. 2010/10/20. DOI: 10.1111/j.1365-2036.2010.04461.x.
54. Boeckxstaens GE, Annese V, des Varannes SB, et al. Pneumatic dilation versus laparoscopic Heller’s myotomy for idiopathic achalasia. *The New England journal of medicine* 2011; 364: 1807–1816. 2011/05/13. DOI: 10.1056/NEJMoa1010502.
55. Moonen A, Annese V, Belmans A, et al. Long-term results of the European achalasia trial: a multicentre randomised controlled trial comparing pneumatic dilation versus laparoscopic Heller myotomy. *Gut* 2016; 65: 732–739. 2015/11/29. DOI: 10.1136/gutjnl-2015-310602.
56. Kostic S, Kjellin A, Ruth M, et al. Pneumatic dilatation or laparoscopic cardiomyotomy in the management of newly diagnosed idiopathic achalasia. Results of a randomized controlled trial. *World journal of surgery* 2007; 31: 470–478. 2007/02/20. DOI: 10.1007/s00268-006-0600-9.
57. Persson J, Johnsson E, Kostic S, et al. Treatment of achalasia with laparoscopic myotomy or pneumatic dilatation: long-term results of a prospective, randomized study. *World journal of surgery* 2015; 39: 713–720. 2014/11/21. DOI: 10.1007/s00268-014-2869-4.
58. Hamdy E, El Nakeeb A, El Hanfy E, et al. Comparative Study Between Laparoscopic Heller Myotomy Versus Pneumatic Dilatation for Treatment of Early Achalasia: A Prospective Randomized Study. *Journal of laparoendoscopic & advanced surgical techniques Part A* 2015; 25: 460–464. 2015/05/08. DOI: 10.1089/lap.2014.0682.
59. van Hoeij FB, Prins LI, Smout A, et al. Efficacy and safety of pneumatic dilation in achalasia: A systematic review and meta-analysis. *Neurogastroenterology and motility: the official journal of the European Gastrointestinal Motility Society* 2019; 31: e13548. 2019/01/31. DOI: 10.1111/nmo.13548.
60. Werner YB, Hakanson B, Martinek J, et al. Endoscopic or Surgical Myotomy in Patients with Idiopathic Achalasia. *The New England journal of medicine* 2019; 381: 2219–2229. 2019/12/05. DOI: 10.1056/NEJMoa1905380.
61. Repici A, Fuccio L, Maselli R, et al. GERD after per-oral endoscopic myotomy as compared with Heller’s myotomy with fundoplication: a systematic review with meta-analysis. *Gastrointestinal endoscopy* 2018; 87: 934–943.e918. 2017/11/06. DOI: 10.1016/j.gie.2017.10.022.
62. Schlottmann F, Luckett DJ, Fine J, et al. Laparoscopic Heller Myotomy Versus Peroral Endoscopic Myotomy (POEM) for Achalasia: A Systematic Review and Meta-analysis. *Annals of surgery* 2017. Journal Article 2017/05/27. DOI: 10.1097/sla.0000000000002311.
63. Rebecchi F, Allaix ME, Schlottmann F, et al. Laparoscopic Heller Myotomy and Fundoplication: What Is the Evidence? *The American surgeon* 2018; 84: 481–488. 2018/05/02.
64. Schoenberg MB, Marx S, Kersten JF, et al. Laparoscopic Heller myotomy versus endoscopic balloon dilatation for the treatment of achalasia: a network meta-analysis. *Annals of surgery* 2013; 258: 943–952. Comparative Study Journal Article Meta-Analysis 2013/11/14. DOI: 10.1097/sla.0000000000000212.

65. Yaghoobi M, Mayrand S, Martel M, et al. Laparoscopic Heller's myotomy versus pneumatic dilation in the treatment of idiopathic achalasia: a meta-analysis of randomized, controlled trials. *Gastrointestinal endoscopy* 2013; 78: 468–475. 2013/05/21. DOI: 10.1016/j.gie.2013.03.1335.
66. Eckardt VF, Aignherr C and Bernhard G. Predictors of outcome in patients with achalasia treated by pneumatic dilation. *Gastroenterology* 1992; 103: 1732–1738. 1992/12/01. DOI: 10.1016/0016-5085(92)91428-7.
67. Andolfi CFP. Meta-analysis of clinical outcome after treatment for achalasia based on manometric subtypes. *British Journal of Surgery* 2019 February 2019. DOI: 10.1002/bjs.11049.
68. Farhoomand K, Connor JT, Richter JE, et al. Predictors of outcome of pneumatic dilation in achalasia. *Clinical gastroenterology and hepatology: the official clinical practice journal of the American Gastroenterological Association* 2004; 2: 389–394. 2004/05/01.
69. Alderliesten J, Conchillo JM, Leeuwenburgh I, et al. Predictors for outcome of failure of balloon dilatation in patients with achalasia. *Gut* 2011; 60: 10–16. 2010/11/12. DOI: 10.1136/gut.2010.211409.
70. Oude Nijhuis RAB, Prins LI, Mostafavi N, et al. Factors Associated With Achalasia Treatment Outcomes: Systematic Review and Meta-analysis. *Clinical gastroenterology and hepatology: the official clinical practice journal of the American Gastroenterological Association* 2019 2019/10/18. DOI: 10.1016/j.cgh.2019.10.008.
71. Kumbhari V, Behary J, Szczesniak M, et al. Efficacy and safety of pneumatic dilatation for achalasia in the treatment of post-myotomy symptom relapse. *The American journal of gastroenterology* 2013; 108: 1076–1081. 2013/03/06. DOI: 10.1038/ajg.2013.32.
72. Saleh CM, Ponds FA, Schijven MP, et al. Efficacy of pneumodilation in achalasia after failed Heller myotomy. *Neurogastroenterology and motility: the official journal of the European Gastrointestinal Motility Society* 2016; 28: 1741–1746. 2016/10/27. DOI: 10.1111/nmo.12875.
73. Amani M, Fazlollahi N, Shirani S, et al. Assessment of Pneumatic Balloon Dilatation in Patients with Symptomatic Relapse after Failed Heller Myotomy: A Single Center Experience. *Middle East journal of digestive diseases* 2016; 8: 57–62. 2016/03/05. DOI: 10.15171/mejdd.2016.08.
74. Fernandez-Ananin S, Fernandez AF, Balague C, et al. What to do when Heller's myotomy fails? Pneumatic dilatation, laparoscopic remyotomy or peroral endoscopic myotomy: A systematic review. *Journal of minimal access surgery* 2018; 14: 177–184. 2018/01/11. DOI: 10.4103/jmas.JMAS_94_17.
75. Ngamruengphong S, Inoue H, Ujiki MB, et al. Efficacy and Safety of Peroral Endoscopic Myotomy for Treatment of Achalasia After Failed Heller Myotomy. *Clinical gastroenterology and hepatology: the official clinical practice journal of the American Gastroenterological Association* 2017; 15: 1531–1537.e1533. 2017/02/13. DOI: 10.1016/j.cgh.2017.01.031.
76. Zhou PH, Li QL, Yao LQ, et al. Peroral endoscopic myotomy for failed Heller myotomy: a prospective single-center study. *Endoscopy* 2013; 45: 161–166. 2013/02/08. DOI: 10.1055/s-0032-1326203.
77. Onimaru M, Inoue H, Ikeda H, et al. Peroral endoscopic myotomy is a viable option for failed surgical esophago-cardiomyotomy instead of redo surgical Heller myotomy: a single center prospective study. *Journal of the American College of Surgeons* 2013; 217: 598–605. 2013/07/31. DOI: 10.1016/j.jamcollsurg.2013.05.025.
78. Zhang Y, Wang H, Chen X, et al. Per-Oral Endoscopic Myotomy Versus Laparoscopic Heller Myotomy for Achalasia: A Meta-Analysis of Nonrandomized Comparative Studies. *Medicine* 2016; 95: e2736. 2016/02/13. DOI: 10.1097/md.0000000000002736.
79. Tyberg A, Sharaiha RZ, Familiari P, et al. Peroral endoscopic myotomy as salvation technique post-Heller: International experience. *Digestive endoscopy: official journal of the Japan Gastroenterological Endoscopy Society* 2018; 30: 52–56. 2017/07/12. DOI: 10.1111/den.12918.
80. Wood TW, Ross SB, Ryan CE, et al. Reoperative Heller myotomy: more pain, less gain. *The American surgeon* 2015; 81: 637–645. 2015/06/03.
81. Veenstra BR, Goldberg RF, Bowers SP, et al. Revisional surgery after failed esophagogastric myotomy for achalasia: successful esophageal preservation. *Surgical endoscopy* 2016; 30: 1754–1761. 2015/08/16. DOI: 10.1007/s00464-015-4423-3.
82. Loviscek MF, Wright AS, Hinojosa MW, et al. Recurrent dysphagia after Heller myotomy: is esophagectomy always the answer? *Journal of the American College of Surgeons* 2013; 216: 736–743. discussion 743–734. 2013/02/19. DOI: 10.1016/j.jamcollsurg.2012.12.008.
83. Inoue H, Minami H, Kobayashi Y, et al. Peroral endoscopic myotomy (POEM) for esophageal achalasia. *Endoscopy* 2010; 42: 265–271. 2010/04/01. DOI: 10.1055/s-0029-1244080.
84. Li QL, Yao LQ, Xu XY, et al. Repeat peroral endoscopic myotomy: a salvage option for persistent/recurrent symptoms. *Endoscopy* 2016; 48: 134–140. 2015/09/09. DOI: 10.1055/s-0034-1393095.
85. Tyberg A, Seewald S, Sharaiha RZ, et al. A multicenter international registry of redo per-oral endoscopic myotomy (POEM) after failed POEM. *Gastrointestinal endoscopy* 2017; 85: 1208–1211. 2016/10/21. DOI: 10.1016/j.gie.2016.10.015.
86. van Hoeij FB, Ponds FA, Werner Y, et al. Management of recurrent symptoms after per-oral endoscopic myotomy in achalasia. *Gastrointestinal endoscopy* 2018; 87: 95–101. 2017/05/10. DOI: 10.1016/j.gie.2017.04.036.
87. Aiolfi A, Asti E, Bonitta G, et al. Esophagectomy for End-Stage Achalasia: Systematic Review and Meta-analysis. *World journal of surgery* 2018; 42: 1469–1476. 2017/10/13. DOI: 10.1007/s00268-017-4298-7.
88. Miller DL, Allen MS, Trastek VF, et al. Esophageal resection for recurrent achalasia. *The Annals of thoracic surgery* 1995; 60: 922–925; discussion 925–926. 1995/10/01. DOI: 10.1016/0003-4975(95)00522-m.
89. Devaney EJ, Lannettoni MD, Orringer MB, et al. Esophagectomy for achalasia: patient selection and clinical experience. *The Annals of thoracic surgery* 2001;

- 72: 854–858. 2001/09/22. DOI: 10.1016/s0003-4975(01)02890-9.
90. Molena D, Mungo B, Stem M, et al. Outcomes of esophagectomy for esophageal achalasia in the United States. *Journal of gastrointestinal surgery: official journal of the Society for Surgery of the Alimentary Tract* 2014; 18: 310–317. 2013/08/22. DOI: 10.1007/s11605-013-2318-y.
91. Duranceau A, Liberman M, Martin J, et al. End-stage achalasia. *Diseases of the esophagus: official journal of the International Society for Diseases of the Esophagus* 2012; 25: 319–330. 2010/12/21. DOI: 10.1111/j.1442-2050.2010.01157.x.
92. Zaninotto G, Bennett C, Boeckxstaens G, et al. The 2018 ISDE achalasia guidelines. *Diseases of the esophagus: official journal of the International Society for Diseases of the Esophagus* 2018; 31. 2018/09/01. DOI: 10.1093/dote/doy071.
93. Cheng YS, Ma F, Li YD, et al. Temporary self-expanding metallic stents for achalasia: a prospective study with a long-term follow-up. *World journal of gastroenterology* 2010; 16: 5111–5117. 2010/10/27. DOI: 10.3748/wjg.v16.i40.5111.
94. Zeng Y, Dai YM and Wan XJ. Clinical remission following endoscopic placement of retrievable, fully covered metal stents in patients with esophageal achalasia. *Diseases of the esophagus: official journal of the International Society for Diseases of the Esophagus* 2014; 27: 103–108. 2013/06/26. DOI: 10.1111/dote.12083.
95. Zhao H, Wan XJ and Yang CQ. Comparison of endoscopic balloon dilation with metal stent placement in the treatment of achalasia. *Journal of digestive diseases* 2015; 16: 311–318. 2015/03/15. DOI: 10.1111/1751-2980.12241.
96. De Palma GD, Iovino P, Masone S, et al. Self-expanding metal stents for endoscopic treatment of esophageal achalasia unresponsive to conventional treatments. Long-term results in eight patients. *Endoscopy* 2001; 33: 1027–1030. 2001/12/12. DOI: 10.1055/s-2001-18933.
97. Coppola F, Gaia S, Rolle E, et al. Temporary endoscopic metallic stent for idiopathic esophageal achalasia. *Surgical innovation* 2014; 21: 11–14. 2013/06/25. DOI: 10.1177/1553350613492024.
98. Li YD, Cheng YS, Li MH, et al. Temporary self-expanding metallic stents and pneumatic dilation for the treatment of achalasia: a prospective study with a long-term follow-up. *Diseases of the esophagus: official journal of the International Society for Diseases of the Esophagus* 2010; 23: 361–367. 2010/04/01. DOI: 10.1111/j.1442-2050.2010.01048.x.
99. Zhu YQ, Cheng YS, Tang GY, et al. Comparison of temporary stent insertion with pneumatic dilation of the same diameter in the treatment of achalasia patients: a retrospective study. *Journal of gastroenterology and hepatology* 2010; 25: 499–505. 2010/01/16. DOI: 10.1111/j.1440-1746.2009.06107.x.
100. Cheng YS, Li MH, Chen WX, et al. Selection and evaluation of three interventional procedures for achalasia based on long-term follow-up. *World journal of gastroenterology* 2003; 9: 2370–2373. 2003/10/17. DOI: 10.3748/wjg.v9.i10.2370.
101. Cai XB, Dai YM, Wan XJ, et al. Comparison between botulinum injection and removable covered self-expanding metal stents for the treatment of achalasia. *Digestive diseases and sciences* 2013; 58: 1960–1966. 2013/02/12. DOI: 10.1007/s10620-013-2564-6.
102. Mikaeli J, Veisari AK, Fazlollahi N, et al. Ethanolamine oleate versus botulinum toxin in the treatment of idiopathic achalasia. *Annals of gastroenterology* 2015; 28: 229–235. 2015/04/02.
103. Moreto M, Ojembarrena E, Barturen A, et al. Treatment of achalasia by injection of sclerosant substances: a long-term report. *Digestive diseases and sciences* 2013; 58: 788–796. 2012/11/28. DOI: 10.1007/s10620-012-2476-x.
104. Niknam R, Mikaeli J, Fazlollahi N, et al. Ethanolamine oleate as a novel therapy is effective in resistant idiopathic achalasia. *Diseases of the esophagus: official journal of the International Society for Diseases of the Esophagus* 2014; 27: 611–616. 2013/08/10. DOI: 10.1111/dote.12122.
105. Niknam R, Mikaeli J, Mehrabi N, et al. Ethanolamine oleate in resistant idiopathic achalasia: a novel therapy. *European journal of gastroenterology & hepatology* 2011; 23: 1111–1115. 2011/10/06. DOI: 10.1097/MEG.0b013e328349647e.
106. Frankhuisen R, van Herwaarden MA, Heijkoop R, et al. Persisting symptoms and decreased health-related quality-of-life in a cross-sectional study of treated achalasia patients. *Alimentary pharmacology & therapeutics* 2007; 26: 899–904. 2007/09/05. DOI: 10.1111/j.1365-2036.2007.03423.x.
107. Jeon HH, Youn YH, Rhee K, et al. For patients with primary achalasia the clinical success of pneumatic balloon dilatation can be predicted from the residual fraction of radionuclide during esophageal transit scintigraphy. *Digestive diseases and sciences* 2014; 59: 375–382. 2013/10/30. DOI: 10.1007/s10620-013-2906-4.
108. Vaezi MF, Baker ME, Achkar E, et al. Timed barium oesophagram: better predictor of long term success after pneumatic dilation in achalasia than symptom assessment. *Gut* 2002; 50: 765–770. 2002/05/16. DOI: 10.1136/gut.50.6.765.
109. Yamashita H, Ashida K, Fukuchi T, et al. Predictive factors associated with the success of pneumatic dilatation in Japanese patients with primary achalasia: a study using high-resolution manometry. *Digestion* 2013; 87: 23–28. 2013/01/25. DOI: 10.1159/000343902.
110. Wu PI, Szczesniak MM, Craig PI, et al. Novel Intra-Procedural Distensibility Measurement Accurately Predicts Immediate Outcome of Pneumatic Dilatation for Idiopathic Achalasia. *The American journal of gastroenterology* 2018; 113: 205–212. 2017/12/06. DOI: 10.1038/ajg.2017.411.
111. Eckardt VF, Staaf B and Bernhard G. Chest pain in achalasia: patient characteristics and clinical course. *Gastroenterology* 1999; 116: 1300–1304. 1999/05/29.
112. Sasaki A, Obuchi T, Nakajima J, et al. Laparoscopic Heller myotomy with Dor fundoplication for achalasia:

- long-term outcomes and effect on chest pain. *Diseases of the esophagus: official journal of the International Society for Diseases of the Esophagus* 2010; 23: 284–289. 2009/12/17. DOI: 10.1111/j.1442-2050.2009.01032.x.
113. Wuller C, Bessell JR and Watson DI. Chest pain before and after laparoscopic cardiomyotomy for achalasia. *ANZ J Surg* 2011; 81: 590–594. 2012/02/03.
 114. Kahrilas PJ, Bredenoord AJ, Fox M, et al. Expert consensus document: Advances in the management of oesophageal motility disorders in the era of high-resolution manometry: a focus on achalasia syndromes. *Nat Rev Gastroenterol Hepatol* 2017; 14: 677–688. DOI: 10.1038/nrgastro.2017.132.
 115. Rohof WO, Lei A and Boeckxstaens GE. Esophageal Stasis on a Timed Barium Esophagogram Predicts Recurrent Symptoms in Patients With Long-Standing Achalasia. *The American journal of gastroenterology* 2012 2012/09/26. DOI: 10.1038/ajg.2012.318.
 116. George N, Abdallah J, Maradey-Romero C, et al. Review article: the current treatment of non-cardiac chest pain. *Alimentary pharmacology & therapeutics* 2016; 43: 213–239. 2015/11/26. DOI: 10.1111/apt.13458.
 117. Sharata AM, Dunst CM, Pescarus R, et al. Peroral endoscopic myotomy (POEM) for esophageal primary motility disorders: analysis of 100 consecutive patients. *Journal of gastrointestinal surgery: official journal of the Society for Surgery of the Alimentary Tract* 2015; 19: 161–170. discussion 170. 2014/09/04. DOI: 10.1007/s11605-014-2610-5.
 118. Filicori F, Dunst CM, Sharata A, et al. Long-term outcomes following POEM for non-achalasia motility disorders of the esophagus. *Surgical endoscopy* 2018 2018/09/21. DOI: 10.1007/s00464-018-6438-z.
 119. Khan MA, Kumbhari V, Ngamruengphong S, et al. Is POEM the Answer for Management of Spastic Esophageal Disorders? A Systematic Review and Meta-Analysis. *Digestive diseases and sciences* 2017; 62: 35–44. 2016/11/20. DOI: 10.1007/s10620-016-4373-1.
 120. Albers D, Frieling T, Dakkak D, et al. Peroral endoscopic myotomy (POEM) is effective in treatment of noncardiac chest pain caused by hypercontractile esophageal motility disorders: results of the POEM-HYPE-Study. *Z Gastroenterol* 2018; 56: 1337–1342. 2018/10/09. DOI: 10.1055/a-0668-2605.
 121. Bonifacio P, de Moura DTH, Bernardo WM, et al. Pneumatic dilation versus laparoscopic Heller's myotomy in the treatment of achalasia: systematic review and meta-analysis based on randomized controlled trials. *Diseases of the esophagus: official journal of the International Society for Diseases of the Esophagus* 2019; 32. 2018/11/01. DOI: 10.1093/dote/doy105.
 122. Rawlings A, Soper NJ, Oelschlager B, et al. Laparoscopic Dor versus Toupet fundoplication following Heller myotomy for achalasia: results of a multicenter, prospective, randomized-controlled trial. *Surgical endoscopy* 2012; 26: 18–26. 2011/07/27. DOI: 10.1007/s00464-011-1822-y.
 123. Salvador R, Pesenti E, Gobbi L, et al. Postoperative Gastroesophageal Reflux After Laparoscopic Heller-Dor for Achalasia: True Incidence with an Objective Evaluation. *Journal of gastrointestinal surgery: official journal of the Society for Surgery of the Alimentary Tract* 2017; 21: 17–22. 2016/07/02. DOI: 10.1007/s11605-016-3188-x.
 124. Hungness ES, Sternbach JM, Teitelbaum EN, et al. Peroral Endoscopic Myotomy (POEM) After the Learning Curve: Durable Long-term Results With a Low Complication Rate. *Annals of surgery* 2016; 264: 508–517. 2016/08/12. DOI: 10.1097/sla.0000000000001870.
 125. Kumbhari V, Familiari P, Bjerregaard NC, et al. Gastroesophageal reflux after peroral endoscopic myotomy: a multicenter case-control study. *Endoscopy* 2017; 49: 634–642. 2017/05/05. DOI: 10.1055/s-0043-105485.
 126. Werner YB, Costamagna G, Swanstrom LL, et al. Clinical response to peroral endoscopic myotomy in patients with idiopathic achalasia at a minimum follow-up of 2 years. *Gut* 2016; 65: 899–906. 2015/05/03. DOI: 10.1136/gutjnl-2014-308649.
 127. Falkenback D, Johansson J, Oberg S, et al. Heller's esophagomyotomy with or without a 360 degrees floppy Nissen fundoplication for achalasia. Long-term results from a prospective randomized study. *Diseases of the esophagus: official journal of the International Society for Diseases of the Esophagus* 2003; 16: 284–290. 2003/12/04.
 128. Gossage JA, Devitt PG, Watson DI, et al. Surveillance endoscopy at five or more years after cardiomyotomy for achalasia. *Annals of surgery* 2014; 259: 464–468. 2013/06/05. DOI: 10.1097/SLA.0b013e318297ae28.
 129. Teitelbaum EN, Dunst CM, Reavis KM, et al. Clinical outcomes five years after POEM for treatment of primary esophageal motility disorders. *Surgical endoscopy* 2018; 32: 421–427. 2017/07/01. DOI: 10.1007/s00464-017-5699-2.
 130. Tustumi F, Bernardo WM, da Rocha JRM, et al. Esophageal achalasia: a risk factor for carcinoma. A systematic review and meta-analysis. *Diseases of the esophagus: official journal of the International Society for Diseases of the Esophagus* 2017; 30: 1–8. 2017/09/02. DOI: 10.1093/dote/dox072.
 131. Robert M, Poncet G, Mion F, et al. Results of laparoscopic Heller myotomy without anti-reflux procedure in achalasia. Monocentric prospective study of 106 cases. *Surgical endoscopy* 2008; 22: 866–874. 2007/10/19. DOI: 10.1007/s00464-007-9600-6.
 132. Campos GM, Vittinghoff E, Rabl C, et al. Endoscopic and surgical treatments for achalasia: a systematic review and meta-analysis. *Annals of surgery* 2009; 249: 45–57. 2008/12/25. DOI: 10.1097/SLA.0b013e31818e43ab.
 133. Anderson SH, Yadegarfar G, Arastu MH, et al. The relationship between gastro-oesophageal reflux symptoms and achalasia. *European journal of gastroenterology & hepatology* 2006; 18: 369–374. 2006/03/16.
 134. Gholoum S, Feldman LS, Andrew CG, et al. Relationship between subjective and objective outcome measures after Heller myotomy and Dor fundoplication for achalasia. *Surgical endoscopy* 2006; 20: 214–219. 2005/12/08. DOI: 10.1007/s00464-005-0213-7.

135. Shiwaku H, Inoue H, Sasaki T, et al. A prospective analysis of GERD after POEM on anterior myotomy. *Surgical endoscopy* 2016; 30: 2496–2504. 2015/09/30. DOI: 10.1007/s00464-015-4507-0.
136. Vela MF, Richter JE, Khandwala F, et al. The long-term efficacy of pneumatic dilatation and Heller myotomy for the treatment of achalasia. *Clinical gastroenterology and hepatology: the official clinical practice journal of the American Gastroenterological Association* 2006; 4: 580–587. 2006/04/25.
137. Perry KA, Kanji A, Drosdeck JM, et al. Efficacy and durability of robotic Heller myotomy for achalasia: patient symptoms and satisfaction at long-term follow-up. *Surgical endoscopy* 2014; 28: 3162–3167. 2014/06/01. DOI: 10.1007/s00464-014-3576-9.
138. Kumbhari V, Tieu AH, Onimaru M, et al. Peroral endoscopic myotomy (POEM) vs laparoscopic Heller myotomy (LHM) for the treatment of Type III achalasia in 75 patients: a multicenter comparative study. *Endoscopy international open* 2015; 3: E195–201. 2015/07/15. DOI: 10.1055/s-0034-1391668.
139. Pallati PK and Mittal SK. Operative interventions for failed heller myotomy: a single institution experience. *The American surgeon* 2011; 77: 330–336. 2011/03/08.
140. Tyberg A, Choi A, Gaidhane M, et al. Transoral incisional fundoplication for reflux after peroral endoscopic myotomy: a crucial addition to our arsenal. *Endoscopy international open* 2018; 6: E549–E552. 2018/05/15. DOI: 10.1055/a-0584-6802.
141. Chino O, Kijima H, Shimada H, et al. Clinicopathological studies of esophageal carcinoma in achalasia: analyses of carcinogenesis using histological and immunohistochemical procedures. *Anticancer research* 2000; 20: 3717–3722. 2001/03/28.
142. Leeuwenburgh I, Scholten P, Calje TJ, et al. Barrett's esophagus and esophageal adenocarcinoma are common after treatment for achalasia. *Digestive diseases and sciences* 2013; 58: 244–252. 2012/11/28. DOI: 10.1007/s10620-012-2157-9.
143. Sandler RS, Nyren O, Ekblom A, et al. The risk of esophageal cancer in patients with achalasia. A population-based study. *Jama* 1995; 274: 1359–1362. 1995/11/01.
144. Leeuwenburgh I, Scholten P, Alderliesten J, et al. Long-term esophageal cancer risk in patients with primary achalasia: a prospective study. *The American journal of gastroenterology* 2010; 105: 2144–2149. 2010/07/01. DOI: 10.1038/ajg.2010.263.
145. Ponds FA, Moonen A, Smout A, et al. Screening for dysplasia with Lugol chromoendoscopy in longstanding idiopathic achalasia. *The American journal of gastroenterology* 2018; 113: 855–862. 2018/05/12. DOI: 10.1038/s41395-018-0064-1.
146. Zendejdel K, Nyren O, Edberg A, et al. Risk of esophageal adenocarcinoma in achalasia patients, a retrospective cohort study in Sweden. *The American journal of gastroenterology* 2011; 106: 57–61. 2011/01/08. DOI: 10.1038/ajg.2010.449.
147. Zaninotto G, Rizzetto C, Zambon P, et al. Long-term outcome and risk of oesophageal cancer after surgery for achalasia. *The British journal of surgery* 2008; 95: 1488–1494. 2008/11/11. DOI: 10.1002/bjs.6413.
148. Ravi K, Geno DM and Katzka DA. Esophageal cancer screening in achalasia: is there a consensus? *Diseases of the esophagus: official journal of the International Society for Diseases of the Esophagus* 2015; 28: 299–304. 2014/03/08. DOI: 10.1111/dote.12196.