



Contents lists available at ScienceDirect

Pediatric Neurology

journal homepage: www.elsevier.com/locate/pnu

Research Paper

Cerebral Infarcts and Vasculopathy in Tanzanian Children With Sickle Cell Anemia

Mboka Jacob, MD, Mmed ^{a,*}, Dawn E. Saunders, MD ^b, Raphael Z. Sangeda, PhD ^c,
 Magda Ahmed, MD, Mmed ^a, Hilda Tutuba, MD ^d, Frank Kussaga, MD ^a,
 Balowa Musa, MD, Mmed ^a, Bruno Mmbando, PhD ^{d,e}, April E. Slee, MS ^b,
 Jamie M. Kawadler, PhD ^{b,†}, Julie Makani, MD, PhD ^{d,†}, Fenella J. Kirkham, MD Res ^{b,†}

^a Department of Radiology & Imaging, Muhimbili University of Health and Allied Sciences, Dar Es Salaam, Tanzania

^b Developmental Neurosciences Section, UCL Great Ormond Street Institute of Child Health, London, United Kingdom

^c Department of Pharmaceutical Microbiology, Muhimbili University of Health and Allied Sciences, Dar Es Salaam, Tanzania

^d Department of Hematology and Blood Transfusion, Muhimbili Sickle Cell Program, Muhimbili University of Health and Allied Sciences, Dar Es Salaam, Tanzania

^e Department of Hematology and Blood Transfusion, Muhimbili Sickle Cell Program, Muhimbili University of Health and Allied Sciences & National Institute for Medical Research, Tanga Center, Tanga, Tanzania

[†] Muhimbili Sickle Cell Program & Department of Hematology and Blood Transfusion, Muhimbili University of Health and Allied Sciences, Dar Es Salaam, Tanzania

ARTICLE INFO

Article history:

Received 27 August 2019

Accepted 14 December 2019

Available online xxx

Keywords:

Silent cerebral infarction

Vasculopathy

Transcranial Doppler

MRI

MRA

ABSTRACT

Background: Cerebral infarcts and vasculopathy in neurologically asymptomatic children with sickle cell anemia (SCA) have received little attention in African settings. This study aimed to establish the prevalence of silent cerebral infarcts (SCI) and vasculopathy and determine associations with exposure to chronic hemolysis, anemia, and hypoxia.

Methods: We prospectively studied 224 children with SCA with transcranial Doppler (TCD), and magnetic resonance imaging (MRI) and magnetic resonance angiography (MRA). Regressions were undertaken with contemporaneous hemoglobin, reticulocyte count, mean prior hemoglobin, oxygen content, reticulocyte count, and indirect bilirubin.

Results: Prevalence of SCI was 27% (61 of 224); cerebral blood flow velocity was abnormal (>200 cm/s) in three and conditional (>170<200 cm/s) in one. Vasculopathy grades 2 (stenosis) and 3 (occlusion) occurred in 16 (7%) and two (1%), respectively; none had grade 4 (moyamoya). SCI was associated with vasculopathy on MRA (odds ratio 2.68; 95% confidence intervals [95% CI] 1.32 to 5.46; $P = 0.007$) and mean prior indirect bilirubin (odds ratio 1.02, 95% CI 1.00 to 1.03, $P = 0.024$; $n = 83$) but not age, sex, non-normal TCD, or contemporaneous hemoglobin. Vasculopathy was associated with mean prior values for hemoglobin (odds ratio 0.33, 95% CI 0.16 to 0.69, $P = 0.003$; $n = 87$), oxygen content (odds ratio 0.43, 95% CI 0.25 to 0.74, $P = 0.003$), reticulocytes (odds ratio 1.20, 95% CI 1.01-1.42, $P = 0.041$; $n = 77$), and indirect bilirubin (odds ratio 1.02, 95% CI 1.01 to 1.04, $P = 0.009$).

Conclusions: SCI and vasculopathy on MRA are common in neurologically asymptomatic children with SCA living in Africa, even when TCD is normal. Children with vasculopathy on MRA are at increased risk of SCI. Longitudinal exposure to anemia, hypoxia, and hemolysis appear to be risk factors for vasculopathy.

© 2020 The Authors. Published by Elsevier Inc. This is an open access article under the CC BY-NC-ND license (<http://creativecommons.org/licenses/by-nc-nd/4.0/>).

Financial support: Supported by Swedish International Development Cooperation Agency (SIDA)-MUHAS small grant (2016-12-14/AEC/Vol.XII/04).

Disclosures: None.

* Communications should be addressed to: Dr. Jacob; Department of Radiology & Imaging; Muhimbili University of Health and Allied Sciences; UN Road, Upanga, Ilala, Dar es Salaam, Tanzania.

E-mail address: mbokajacob@gmail.com (M. Jacob).

† Joint senior authors.

<https://doi.org/10.1016/j.pediatrneuro.2019.12.008>

0887-8994/© 2020 The Authors. Published by Elsevier Inc. This is an open access article under the CC BY-NC-ND license (<http://creativecommons.org/licenses/by-nc-nd/4.0/>).

Please cite this article as: Jacob M et al., Cerebral Infarcts and Vasculopathy in Tanzanian Children With Sickle Cell Anemia, Pediatric Neurology, <https://doi.org/10.1016/j.pediatrneuro.2019.12.008>

Introduction

Silent cerebral infarct (SCI) is the most common neurological injury in children with sickle cell anemia (SCA),^{1,2} and prevalence in children ranges from 21% to 40%.²⁻⁶ SCI is an independent risk factor for clinical stroke,⁷⁻⁹ and new or more extensive SCI,^{6,7} and is associated with neuropsychological deficits.^{7,10-13}

Despite the fact that more than 90% of the children with SCA are born in sub-Saharan Africa and India,¹⁴ there is limited access to blood transfusion and other resources for primary and secondary stroke prevention and little exploration of predictors of brain injury in these countries. In a Tanzanian study of 200 patients with SCA, 67 had abnormal internal carotid/middle cerebral artery (ICA/MCA) time-averaged mean of the maximum cerebral blood flow velocity (CBFV) on transcranial Doppler (TCD). Among 49 of 67 patients who also had brain magnetic resonance imaging (MRI), 14% had stroke and 29% had SCI.¹⁵ However, little is known on the prevalence of vasculopathy on magnetic resonance angiography (MRA) in asymptomatic patients with SCA anywhere in the world¹⁶ and there are few data on any association with SCI, TCD measures,¹⁷ or previous exposure to hemolysis or hypoxia.^{18,19}

We hypothesized that vasculopathy, detected by MRA and TCD, would be more common in neurologically asymptomatic children with SCA and adolescents with SCI. We also hypothesized that clinical events and laboratory markers of anemia (e.g., hemoglobin), hemolysis (e.g., reticulocyte count, indirect bilirubin), and hypoxic exposure (e.g., low arterial oxygen content)^{16,20} would predict SCI and vasculopathy. We specifically studied (1) prevalence of SCI and vasculopathy; (2) comparison between presence of SCI and age, sex, clinical variables, CBFV on TCD, laboratory variables at the time of and before MRI, and presence of intracranial vasculopathy on MRA; and (3) comparison between presence of vasculopathy on MRA and CBFV on TCD and laboratory variables at the time of and before MRI.

Methods

Standard protocol approvals, registrations, and patient consents

Formal ethics approval was obtained from the Muhimbili University of Health and Allied Sciences Institutional Review Board (MUHAS-IRB Ref.2014-11-03/AEC/Vol.IX/32). Individual written consent was obtained from parents or guardians of minors and participants older than 18 years.

Demographic and clinical variables

A cross-sectional hospital-based study was conducted at Muhimbili National Hospital in Dar es Salaam for a period of 22 months from June 1, 2016, to March 31, 2018. Patients aged five to 19 years with no clinical neurological manifestations by history and examination undertaken by a doctor with neurological training were eligible for this study of TCD and brain MRI. Patients with prior stroke and history of seizures were not included. Simple random sampling technique was used to select a list of patients from Muhimbili Sickle Cell Program Database. Penicillin was prescribed, but chloroquine was not, although use of insecticide-treated nets was emphasized to prevent malaria infections. No child was on hydroxyurea or a chronic blood transfusion regime.

Demographic information was collected, and clinical history, including history of stroke, fever, chest crises, and painful crises, was taken. Full blood counts were obtained at the time of recruitment. For those who had been enrolled in a previous study,²¹ we obtained from that database available daytime oxygen saturation (SpO₂) measured in clinic by pulse oximetry, hemoglobin level,

reticulocyte count, and indirect bilirubin. Where daytime oxygen saturation and hemoglobin were available on the same day, arterial oxygen content (CaO₂) was calculated as:

$$\text{CaO}_2 = 1.34 \times \text{Hemoglobin} \times \text{SpO}_2 + (0.003 \times \text{pO}_2)$$

where pO₂, the partial pressure of oxygen, was assumed to be 100 torr in room air. The number of all measurements, the average of all available historical values, and the time between measurement and participation in this study were recorded.

Transcranial Doppler ultrasonography

Patients underwent TCD using a DWL Ez-Dop with a 2-MHz probe following the STOP (Stroke Prevention in Sickle Cell Disease) protocol,²² by radiologists M.J. or M.A. As part of their radiological training, they had already received training in ultrasound physics, equipment, and scanning techniques and underwent one week of intensive training by F.J.K. involving the scanning of around 100 patients with sickle cell disease (SCD). Transtemporal and suboccipital sonographic windows were used to determine time-averaged maximum CBFV of the MCA, ICA, and basilar artery using inbuilt software. The highest time-averaged maximum CBFV in the ICA/MCA on either left or right side was determined and was classified as low (<50 cm/s), normal (50<149 cm/s),^{23,24} slightly elevated (≥150<170 cm/s), conditional (≥170<200 cm/s), and abnormal (≥200 cm/s)²⁵ CBFV. Patients with low, slightly elevated, conditional, and abnormal CBFV were classified as “non-normal,” and patients who did not have a reliable reading were excluded. Patients with abnormal neuroradiologic findings were referred back to their respective sickle cell clinics for discussion of the results and further management; those with abnormal TCD were offered hydroxyurea, but long-term blood transfusion was not available.

Neuroimaging

MRI was performed on a 1.5-Tesla Philips Achieva scanner. A standardized head protocol was used, including axial and coronal T2-weighted sequences, an axial fluid-attenuated inversion recovery sequence, and a time-of-flight MRA with source and maximum intensity projection.

Two experienced neuroradiologists (M.J. and D.E.S.), unaware of the TCD results, interpreted the images independently. Discordant readings were resolved by consensus. Magnetic resonance images were evaluated for the presence of parenchymal injury, atrophy, and vessel occlusion or stenosis.

SCI were defined using the Silent Infarct Transfusion (SIT) trial definition: a lesion measuring at least 3 mm in greatest linear dimension, visible in at least two planes on T2-weighted images.²⁶ Anatomical locations of SCI within the cerebrum, basal ganglia, thalamus, brainstem, and cerebellum were recorded.

MRA examinations were reviewed for turbulence or signal loss in the terminal ICA and in the A1, M1, M2, P1, and P2 segments of the basal vessels, according to previously published criteria²⁷: four segments of each ICA, and three segments of each anterior cerebral artery (ACA) and MCA were examined. Vasculopathy on MRA was graded according to severity of signal loss: 0, none (normal); 1, minor signal attenuation (turbulence) and normal-appearing vessel on MRI; 2, obvious signal attenuation, but presence of distal flow (stenosis); 3, signal loss and no distal flow (occlusion); 4, occlusion with collaterals (moyamoya) (Fig 1).¹⁸ The worst vasculopathy in any vessel was recorded.

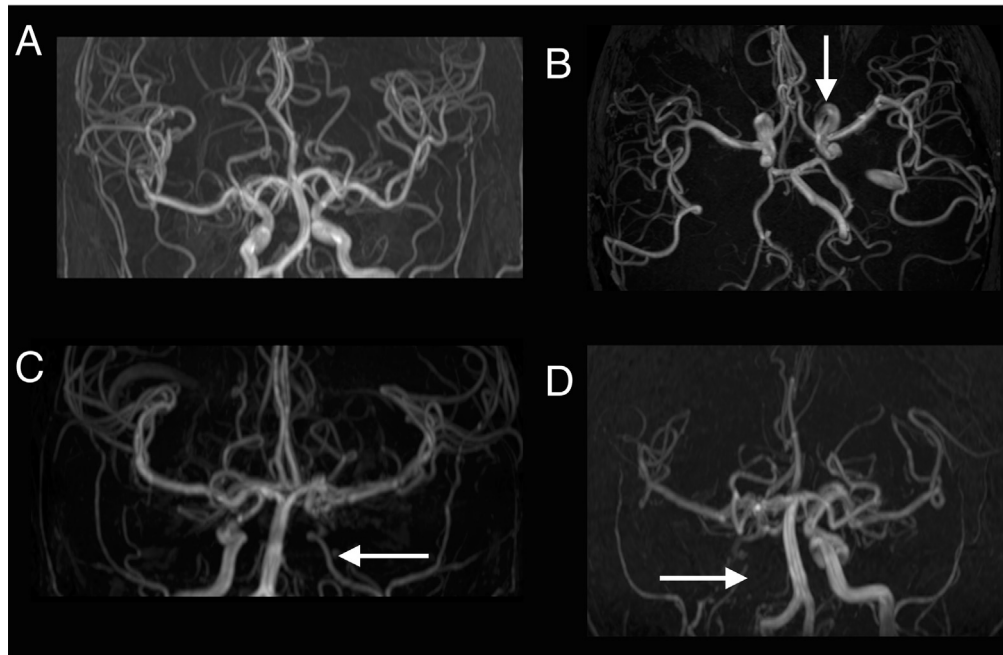


FIGURE 1. Vasculopathy on magnetic resonance angiography was graded according to severity of signal loss: (A) grade 0: normal; (B) grade 1: minor signal attenuation (turbulence) and normal appearing vessel on magnetic resonance imaging; (C) grade 2: obvious signal attenuation, but presence of distal flow (stenosis); (D) grade 3: signal loss and no distal flow (occlusion). Grade 4: occlusion with collaterals (moyamoya) not shown. The arrows show areas with named abnormalities. Reprinted with permission from Dlamini et al.¹⁸

Statistical analysis

Statistical Package for Social Science (SPSS) version 25 was used for data analysis. Normally distributed continuous variables were compared using two-sided Student *t* test. Categorical variables were compared using a χ^2 test or Fisher exact test if cell counts were less than 5. Kappa statistics was used for comparison between observers. Analysis of variance (ANOVA) was used to compare CBFV across grades of vasculopathy. Univariate logistic regressions were used to determine associations between (1) presence of SCI and (2) presence of vasculopathy and age, sex, non-normal TCD, and laboratory measures at the time of MRI and the mean before MRI. Multivariate models were not used because there were fewer patients with laboratory values. $P < 0.05$ was considered statistically significant.

Data availability

Anonymized data will be shared at the request of qualified investigators.

Results

Within a 22-month period, 394 neurologically asymptomatic children and adolescents with SCA (HbSS) were enrolled; 379 had TCD. MRI and MRA were undertaken in 210 of the 379 with TCD and in a further 14 who had not undergone TCD (Fig 2).

Between those who underwent MRI ($n = 224$) and those who did not ($n = 170$), there were no differences in the mean age (MRI: 12.80 years, no MRI: 12.51 years, $t = 0.724$, $P = 0.470$), sex (MRI: 113 male, 111 female, no MRI: 88 male, 82 female, $\chi^2 = 0.067$, $P = 0.795$), or mean contemporaneous hemoglobin (MRI₍₂₀₉₎: 7.54 g/dL, no MRI₍₁₆₈₎: 7.74 g/dL, $t = 1.569$, $P = 0.118$).

Silent cerebral infarction

Demographic and neuroimaging data for those with and without SCI on MRI are shown in Table 1. Prevalence of SCI was 27% (61 of 224) overall and did not differ between male and female participants ($\chi^2 < 0.001$, $P = 1.0$). Prevalence was lower in younger children ($\chi^2 = 2.415$, $P = 0.299$, Table 1). Most of the affected children (93%; 57/61) had multiple SCI. The most prevalent locations were in the deep white matter of the frontal lobes (80%; 49 of 61), parietal lobes (26%; 16 of 61), occipital lobes (8%; five of 61), basal ganglia (7%; four of 61), and cerebellum (5%; three of 61). SCI in the temporal lobe and thalamus was each seen in one patient. There was no relationship between presence of SCI and clinical measures: history of fever (SCI: six of 61, no SCI: six of 163; $\chi^2 = 3.317$, $P = 0.07$), chest crisis (SCI: zero of 61, no SCI: two of 163; Fisher's exact test, $P = 0.5$), or painful crisis (SCI: 38 of 61, no SCI: 103 of 163; $\chi^2 = 0.015$, $P = 0.9$).

Validation of the MRA vasculopathy scale

Kappa was 0.84 for vasculopathy grading on MRA in all 224 patients on all grades (0, 1, 2, or 3), which is excellent inter-rater agreement.

Vasculopathy on MRA

Prevalence of cerebral vasculopathy grades 1, 2, or 3 in at least one artery on MRA was 18% (40 of 224). Twenty-two (10%) of the patients were graded as having turbulence (grade 1), 16 (7%) as having stenosis (grade 2), and two (1%) as having occlusion (grade 3) as the worst grade (Table 1). None of the patients had moyamoya (grade 4). Of those with vasculopathy, the ICA was affected in 63% (25 of 40), the ACA in 43% (17 of 40), and the MCA in 35% (14 of 40). Vasculopathy was not observed in the posterior cerebral artery on MRA. Prevalence of SCI was higher in those with MRA vasculopathy grades 2 and 3 (12 of 18; 67%) than in those with grade 1 (6/22; 27%)

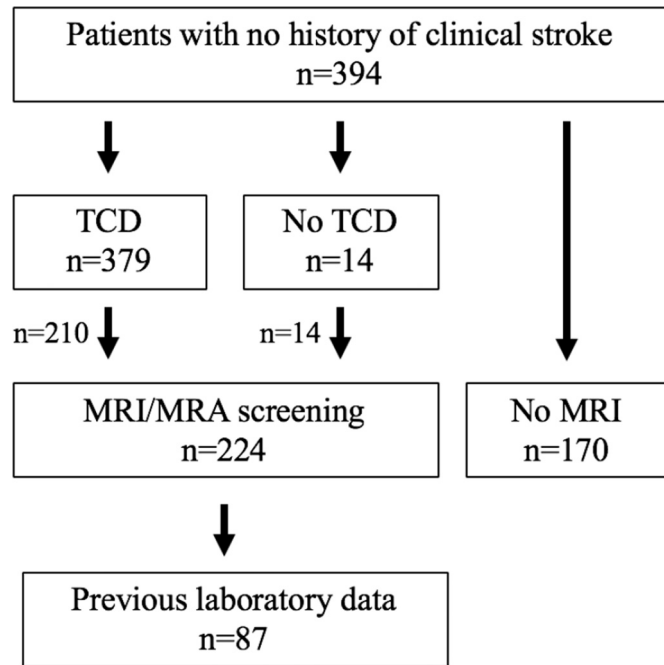


FIGURE 2. Study flow diagram showing total number of recruited patients with no history of stroke and those patients who underwent transcranial Doppler (TCD) measurement and magnetic resonance imaging (MRI)/magnetic resonance angiography (MRA) investigation.

or grade 0 (normal) MRA (43 of 184; 23%; $\chi^2 = 15.51$, $P < 0.001$) (Table 1). The majority (81%; 47 of 58) of patients with normal TCD and SCI had normal MRA, although 19% (11 of 58) had vasculopathy ($\chi^2 = 11.993$, $P = 0.001$).

Cerebral blood flow velocity

A total of 379 children underwent TCD; six had no TCD signal. The majority of those with recordable TCD (97.3%; 363 of 373) had ICA/MCA CBFV in the normal range. Only 10 of 373 (2.7%) had ICA/MCA CBFV outside the normal range: two with maximum CBFV <50 cm/s, four with slightly elevated CBFV 150 to 169 cm/s, one with conditional CBFV 170 to 199 cm/s, and three with abnormal CBFV >200 cm/s.

Of patients who underwent MRI, four of 210 had no TCD signal on either side, none of whom had intracranial vasculopathy on MRA; they were excluded from further analysis. Seven of the remaining 206 had CBFV outside the normal range: two with maximum CBFV <50 cm/s, three with CBFV 150 to 169 cm/s, and two with abnormal CBFV ≥ 200 cm/s. There were no differences in the proportion with SCI between those with normal TCD and those with non-normal TCD (SCI: $n = 56$ with normal TCD, $n = 2$ with non-normal TCD; Fisher exact test $P = 1.0$). Patients with non-normal TCD had a nonsignificantly higher prevalence (42.9%; three of seven) of vasculopathy when compared with those with normal TCD (17.6%; 35 of 199; Fisher exact test $P = 0.12$) (Table 2). Of the 38 children with vasculopathy on MRA, SCI occurred in 66.7% (two of three) of those with non-normal TCD and in 42.9% (15 of 35) of those with normal TCD (Fisher exact test $P = 0.58$).

Laboratory variables

Contemporaneous hemoglobin data were available from full blood counts at the time of MRI/MRA in 209 of 224 patients and laboratory data before MRI/MRA were available for 87 of 224.

Associations between laboratory measures and MRI/MRA

Logistic regressions to predict presence of SCI and vasculopathy are shown in Table 2. Presence of vasculopathy was associated with SCI (odds ratio [OR] 2.68, confidence interval [CI] 1.32 to 5.46, $P = 0.007$). Of the laboratory measures contemporaneous with MRI and before MRI, only mean indirect bilirubin before MRI was associated with presence of SCI (OR 1.02, CI 1.00 to 1.03, $P = 0.024$). Age, male sex, and non-normal TCD were not associated with either SCI or vasculopathy.

Presence of vasculopathy was associated with the following values for prior laboratory data: mean hemoglobin (OR 0.33, CI 0.16 to 0.69, $P = 0.003$), mean oxygen content (OR 0.43, CI 0.25 to 0.74, $P = 0.003$), mean reticulocyte count (OR 1.20, CI 1.01 to 1.42, $P = 0.041$), and mean indirect bilirubin (OR 1.02, CI 1.01 to 1.04, $P = 0.009$) (Table 3).

Discussion

This is the largest neuroimaging study with TCD, MRI, and MRA in neurologically asymptomatic and untreated children and adolescents with SCA residing in Africa. The prevalence of SCI in this study was 27%, in line with previous studies in Europe and the United States. SCI was associated with presence of vasculopathy on MRA and prior mean indirect bilirubin, and not with age, male sex, or contemporaneous hemoglobin, in contrast with previous studies in Europe and the United States.²⁸ However, prior mean hemoglobin, mean oxygen content, mean reticulocyte count, and mean indirect bilirubin were associated with presence of vasculopathy.

MRI

In our study, there was no relationship between SCI and age, sex, or clinical complications in the past year. There was an increase in prevalence with age, from 19% in those aged nine years or younger to 42% in those aged greater than 10 years, of likely clinical importance, although not statistically significant. The distribution of SCI was similar to that of previous studies,^{2,4,6} with the majority of our patients having SCI in the deep white matter of the frontal lobe, followed by the parietal lobe, whereas the other parts of the brain were less affected. Any relationship between previous seizures and SCI⁸ cannot be ascertained from this study, as we did not include these patients.

In contrast to studies that showed lower baseline hemoglobin to be associated with SCI,^{2,19,28-30} contemporaneous and previous mean hemoglobin levels were not related to the presence of SCI in the current study, perhaps because the range of hemoglobin in these Tanzanian patients is lower. Results from the Co-operative Study of Sickle Cell Disease and the Stroke With Transfusions Changing to Hydroxyurea (SWITCH) trial also found no consistent clinical or hematological predictors of MRI abnormality.^{4,8,31}

MRA

Vasculopathy on MRA has various definitions, and there are few data on prevalence in unselected children with SCA with normal neurology by history and examination.¹⁶ The prevalence of MRA-detected stenosis (grade 2 vasculopathy) in this study was 7%, slightly lower than the prevalence of stenosis (10% to 15%) in previous studies of children without prior stroke^{3,32} and much lower than the reported 33% to 55% prevalence of stenosis in children with stroke and abnormal TCD.^{27,33} In a study using the same definitions in children without previous stroke,¹⁸ the overall prevalence of vasculopathy on MRA was 64%, compared with 18% in the current study. Grades 1, 2, and 3 were seen in 13%, 23%, and 28%,

TABLE 1
Demographics of Patients With MRI and MRA (n = 224)

Patient Characteristics	No SCI (n = 163)	SCI (n = 61)	Statistical Test P-Value
Age (mean, S.D.)	12.7 (3.8)	13.0 (3.7)	t = 0.521 (P = 0.603)
Age group (n)			$\chi^2 = 2.415$ (P = 0.299)
5-9 years	42	10	
10-14 years	57	26	
15-20 years	64	25	
Sex n (%)			$\chi^2 = 0.005$ (P = 0.946)
Male	82	31	
Female	81	30	
MRA group (n)			$\chi^2 = 15.511$ (P < 0.001)
Grade 0 (normal)	141	43	
Grade 1 (turbulence)	16	6	
Grade 2 (stenosis) & Grade 3 (occlusion)	6	12	

Abbreviations:

MRA = Magnetic resonance angiography

MRI = Magnetic resonance imaging

SCI = Silent cerebral infarct

respectively, in Dlamini et al.'s study,¹⁸ compared with 10%, 7%, and 1% in the current study; moyamoya (grade 4) was not seen in either.¹⁸

In the current study we also observed a higher (19%) prevalence of vasculopathy in patients with normal TCD and SCI compared with that reported in the SIT trial (1.8%).³⁴ This difference may be due to difference in the intracranial vasculopathy definition used; the SIT trial included patients with stenosis greater than 50%, whereas we included any with signal dropout.¹⁸ Further studies should compare the utility of these vasculopathy definitions.

The terminal ICA, proximal ACA, and MCA were the most affected by vasculopathy detected by MRA, in keeping with previously published data.³⁵ Stenosis has previously been reported to be rare in the posterior circulation³⁶ and was not seen in our data. The exact cause of vasculopathy is unclear, but it is probably mediated by endothelial injury with adhesion of abnormal cellular elements, which eventually results in damage of the muscularis.³⁵

It is very important to prevent or reverse vasculopathy in asymptomatic patients before vascular occlusion, but few studies have examined whether previous exposures to complications are important via the use of longitudinal laboratory data. Reticulocyte percentage is an independent predictor of cerebrovascular disease in children with SCD.^{37,38} Chronic hypoxic exposure^{18,20,39} may be associated with vasculopathy as well as white matter damage. We observed a relationship between vasculopathy on MRA and previously collected mean hemoglobin, mean oxygen content, mean reticulocyte count, and mean indirect bilirubin, consistent with

data in a UK population.¹⁸ The association with indirect bilirubin as well as reticulocytosis suggests that the hemolytic rate is important, although reticulocytosis may also be related to erythropoiesis in response to chronic anemia and hypoxemia.¹⁸

Abnormal CBFV (≥ 200 cm/s) appears to be much less common in this study and other East African cohorts^{15,23} than the 10% reported in studies from the United States, where the majority of people with SCD are of West African origin. Differences in mechanisms of vascular injury in patients with SCD residing in East Africa compared with those residing in Europe or the United States may be due to differences in genetics (e.g., haplotypes), burden of infection, environmental exposures including nutrition, and access to quality health care. The small proportion of patient with CBFV ≥ 200 cm/s could also be related to a more rapid progression of arteriopathy in East African patients.¹⁵

In this study of asymptomatic children with SCD, those with non-normal TCD were not significantly more likely to have intracranial vasculopathy on MRA, whereas in children with stroke, Helton et al.³¹ found higher rates of and more severe intracranial stenosis on MRA if TCD showed low or uninterpretable MCA velocities. Those with non-normal TCD with normal intracranial MRA might have extracranial vasculopathy; future studies should include MRA of the carotid and vertebral arteries in the neck.⁴⁰ Although this was not statistically significantly different from those with normal TCD and vasculopathy, two of the three children with non-normal TCD and vasculopathy on MRA had SCI in the current study, in accordance with previous studies.^{3,18}

TABLE 2
Comparison Between CBFV on TCD and SCI on MRI and Vasculopathy on MRA

TCD	SCI- n = 148	SCI+ n = 58	Fisher's Exact Test	No Vasculopathy n = 168	Vasculopathy Grades 1, 2, or 3 n = 38	Fisher's Exact Test
Normal CBFV	143	56	(P = 1.0)	164	35	(P = 0.12)
Non-normal CBFV	5	2		4	3	

Abbreviations:

CBFV = Cerebral blood flow velocity

MRA = Magnetic resonance angiography

MRI = Magnetic resonance imaging

SCI = Silent cerebral infarct

TCD = Transcranial Doppler

SCI- = No Silent cerebral infarction

SCI+ = Presence of SCI.

Normal CBFV: (50 to 149 cm/s).

Non-normal CBFV: low (<50 cm/s), slightly elevated (≥ 150 <170 cm/s), conditional (≥ 170 <200 cm/s), and abnormal (≥ 200 cm/s).

TABLE 3
Univariate Logistic Regression Results Showing Variables Associated With Presence of SCI and Vasculopathy

Variable	N	Silent Cerebral Infarction		Vasculopathy	
		OR (95% CI)	P	OR (95% CI)	P
Age	224	1.02 (0.94–1.10)	0.660	1.03 (0.94–1.13)	0.544
Sex (male)	224	1.02 (0.57–1.84)	0.946	0.68 (0.34–1.35)	0.269
Non-normal TCD	206	1.02 (0.19–5.42)	0.980	3.52 (0.75–16.41)	0.110
Abnormal MRA	224	2.68 (1.32–5.46)	0.007		
Hemoglobin at time of MRI (g/L)	209	0.95 (0.73–1.24)	0.716	0.87 (0.64–1.19)	0.391
Hemoglobin before MRI (g/L)	87	0.86 (0.53–1.40)	0.542	0.33 (0.16–0.69)	0.003
Reticulocytes before MRI ($\times 10^{-9}/L$)	83	1.05 (0.91–1.20)	0.539	1.20 (1.01–1.42)	0.041
Indirect bilirubin before MRI (mmol/L)	77	1.02 (1.00–1.03)	0.024	1.02 (1.01–1.04)	0.009
Oxygen content before MRI	87	0.90 (0.63–1.29)	0.564	0.43 (0.25–0.74)	0.003

Abbreviations:

CI = Confidence interval

MRA = Magnetic resonance angiography

MRI = Magnetic resonance imaging

OR = Odds ratio

SCI = Silent cerebral infarct

TCD = Transcranial Doppler

 $P < 0.05$ was considered statistically significant and are indicated in bold.**Study limitations**

TCD is operator dependent, and it is possible that the relatively few patients with conditional or abnormal TCD means that short segments of intracranial vascular narrowing with high velocity may have been missed. The alternative strategy for the diagnosis of vasculopathy is the addition of MRA when MRI screening for SCI is undertaken. For MRA a comparison with a gold standard would be ideal. However, it is difficult to justify the use of invasive digital subtraction angiography for stroke risk assessment as there is an intraprocedure risk of stroke and the radiation dose for computed tomographic angiography is too high to justify use for screening in children with SCA. Grades 1, 2, and 3 MRA appears to be associated with differences in quantitative brain tissue MRI compared with grade 0, but follow-up of those with MRA to determine sensitivity and specificity for future stroke risk in comparison with TCD in asymptomatic children with SCD will be important to determine whether it is a cost-effective stroke screening tool. Prevalence of SCI might have been higher if we had used a scanner with higher field strength (3T)⁶ and new pulse sequences, which allow for improved discrimination of lesions in children whose earlier studies were initially read as normal. We did not compare the lateralization of the vasculopathy and the locations of SCI, which should be considered in future studies.

Conclusions

SCI and vasculopathy on MRA are common in neurologically asymptomatic children with SCA living in Africa, even when TCD CBFV is < 200 cm/s. Children and adolescents with all grades of vasculopathy on MRA are at higher risk of brain parenchymal injury. Longitudinal exposure to anemia, hypoxia, and hemolysis appear to be risk factors for vasculopathy.

Acknowledgments

The authors acknowledge the efforts of the Muhimbili National Hospital MRI technologists without whom the study would not have been possible. The work was supported by the Muhimbili Sickle Cell program, Muhimbili National Hospital, Muhimbili University of Health and Allied Sciences, and Great Ormond Street Hospital Biomedical Research Centre (BRC).

References

- DeBaun MR, Kirkham FJ. Central nervous system complications and management in sickle cell disease. *Blood*. 2016;127:829–838.
- DeBaun MR, Armstrong FD, McKinstry RC, Ware RE, Vichinsky E, Kirkham FJ. Silent cerebral infarcts: a review on a prevalent and progressive cause of neurologic injury in sickle cell anemia. *Blood*. 2012;119:4587–4596.
- Arkuszewski M, Krejza J, Chen R, et al. Sickle cell anemia: intracranial stenosis and silent cerebral infarcts in children with low risk of stroke. *Adv Med Sci*. 2014;59:108–113.
- Moser FG, Miller ST, Bello JA, et al. The spectrum of brain MR abnormalities in sickle-cell disease: a report from the Cooperative Study of Sickle Cell Disease. *AJNR Am J Neuroradiol*. 1996;17:965–972.
- Bernaudin F, Verlhac S, Arnaud C, et al. Impact of early transcranial Doppler screening and intensive therapy on cerebral vasculopathy outcome in a newborn sickle cell anemia cohort. *Blood*. 2011;117:1130–1140.
- Pegelow CH, Macklin EA, Moser FG, et al. Longitudinal changes in brain magnetic resonance imaging findings in children with sickle cell disease. *Blood*. 2002;99:3014–3018.
- Miller ST, Macklin EA, Pegelow CH, et al. Silent infarction as a risk factor for overt stroke in children with sickle cell anemia: a report from the Cooperative Study of Sickle Cell Disease. *J Pediatr*. 2001;139:385–390.
- Kinney TR, Sleeper LA, Wang WC, et al. Silent cerebral infarcts in sickle cell anemia: a risk factor analysis. *The Cooperative Study of Sickle Cell Disease. Pediatrics*. 1999;103:640–645.
- Pegelow CH, Wang W, Granger S, et al. Silent infarcts in children with sickle cell anemia and abnormal cerebral artery velocity. *Arch Neurol*. 2001;58:2017–2021.
- Berkelhammer LD, Williamson AL, Sanford SD, et al. Neurocognitive sequelae of pediatric sickle cell disease: a review of the literature. *Child Neuropsychol*. 2007;13:120–131.
- Wang W, Enos L, Gallagher D, et al. Neuropsychologic performance in school-aged children with sickle cell disease: a report from the Cooperative Study of Sickle Cell Disease. *J Pediatr*. 2001;139:391–397.
- van der Land V, Hijmans CT, de Ruyter M, et al. Volume of white matter hyperintensities is an independent predictor of intelligence quotient and processing speed in children with sickle cell disease. *Br J Haematol*. 2015;168:553–556.
- Kawadler JM, Clayden JD, Clark CA, Kirkham FJ. Intelligence quotient in paediatric sickle cell disease: a systematic review and meta-analysis. *Dev Med Child Neurol*. 2016;58:672–679.
- Piel FB, Hay SI, Gupta S, Weatherall DJ, Williams TN. Global burden of sickle cell anaemia in children under five, 2010–2050: modelling based on demographics, excess mortality, and interventions. *PLoS Med*. 2013;10:e1001484.
- Kija EN, Saunders DE, Munubhi E, et al. Transcranial Doppler and magnetic resonance in Tanzanian children with sickle cell disease. *Stroke*. 2019;50:1719–1726.
- Guilliams KP, Fields ME, Dowling MM. Advances in understanding ischemic stroke physiology and the impact of vasculopathy in children with sickle cell disease. *Stroke*. 2019;50:266–273.
- Quinn CT, Variste J, Dowling MM. Haemoglobin oxygen saturation is a determinant of cerebral artery blood flow velocity in children with sickle cell anaemia. *Br J Haematol*. 2009;145:500–505.
- Dlamini N, Saunders DE, Bynevelt M, et al. Nocturnal oxyhemoglobin desaturation and arteriopathy in a pediatric sickle cell disease cohort. *Neurology*. 2017;89:2406–2412.

19. Dowling MM, Quinn CT, Rogers ZR, Buchanan GR. Acute silent cerebral infarction in children with sickle cell anemia. *Pediatr Blood Cancer*. 2010;54:461–464.
20. Stotesbury H, Kirkham FJ, Kölbl M, et al. White matter integrity and processing speed in sickle cell anemia. *Neurology*. 2018;90:e2042–e2050.
21. Makani J, Thlway F, Makubi A, et al. A ten year review of the sickle cell program in Muhimbili National Hospital, Tanzania. *BMC Hematol*. 2018;18:33.
22. Nichols FT, Jones AM, Adams RJ. Stroke prevention in sickle cell disease (STOP) study guidelines for transcranial Doppler testing. *J Neuroimaging*. 2001;11:354–362.
23. Makani J, Kirkham FJ, Komba A, et al. Risk factors for high cerebral blood flow velocity and death in Kenyan children with Sickle Cell Anaemia: role of haemoglobin oxygen saturation and febrile illness. *Br J Haematol*. 2009;145:529–532.
24. Newton CR, Marsh K, Peshu N, Kirkham FJ. Perturbations of cerebral hemodynamics in Kenyans with cerebral malaria. *Pediatr Neurol*. 1966;15:41–49.
25. Adams RJ, McKie VC, Carl EM, et al. Long-term stroke risk in children with sickle cell disease screened with transcranial Doppler. *Ann Neurol*. 1997;42:699–704.
26. Casella JF, King AA, Barton B, et al. Design of the silent cerebral infarct transfusion (SIT) trial. *Pediatr Hematol Oncol*. 2010;27:69–89.
27. Steen RG, Emudianughe T, Hankins GM, et al. Brain imaging findings in pediatric patients with sickle cell disease. *Radiology*. 2003;228:216–225.
28. DeBaun MR, Sarnaik SA, Rodeghier MJ, et al. Associated risk factors for silent cerebral infarcts in sickle cell anemia: low baseline hemoglobin, sex, and relative high systolic blood pressure. *Blood*. 2012;119:3684–3690.
29. Zhang X, Li C, Li Q. Magnetic resonance imaging in pediatric sickle cell anemia. *Exp Ther Med*. 2016;12:555–558.
30. Bernaudin F, Verlhac S, Arnaud C, et al. Chronic and acute anemia and extracranial internal carotid stenosis are risk factors for silent cerebral infarcts in sickle cell anemia. *Blood*. 2015;125:1653–1661.
31. Helton KJ, Adams RJ, Kesler KL, et al. Magnetic resonance imaging/angiography and transcranial Doppler velocities in sickle cell anemia: results from the SWITCH trial. *Blood*. 2014;124:891–898.
32. Thangarajh M, Yang G, Fuchs D, et al. Magnetic resonance angiography-defined intracranial vasculopathy is associated with silent cerebral infarcts and glucose-6-phosphate dehydrogenase mutation in children with sickle cell anemia. *Br J Haematol*. 2012;159:352–359.
33. Cancio MI, Helton KJ, Schreiber JE, Smeltzer MP, Kang G, Wang WC. Silent cerebral infarcts in very young children with sickle cell anaemia are associated with a higher risk of stroke. *Br J Haematol*. 2015;171:120–129.
34. Choudhury NA, DeBaun MR, Ponisio MR, et al. Intracranial vasculopathy and infarct recurrence in children with sickle cell anaemia, silent cerebral infarcts and normal transcranial Doppler velocities. *Br J Haematol*. 2018;183:324–326.
35. Thust SC, Burke C, Siddiqui A. Neuroimaging findings in sickle cell disease. *Br J Radiol*. 2014;87:20130699.
36. Adegoke SA, Figueiredo MS, Vicari P, et al. Posterior circulation evaluation in patients with sickle cell anemia. *J Stroke Cerebrovasc Dis*. 2016;25:717–721.
37. Silva CM, Giovani P, Viana MB. High reticulocyte count is an independent risk factor for cerebrovascular disease in children with sickle cell anemia. *Pediatr Blood Cancer*. 2011;56:116–121.
38. Kaushal M, Byrnes C, Khademian Z, et al. Examination of reticulocytosis among chronically transfused children with sickle cell anemia. *PLoS One*. 2016;11:e0153244.
39. Kawadler JM, Kirkham FJ, Clayden JD, et al. White matter damage relates to oxygen saturation in children with sickle cell anemia without silent cerebral infarcts. *Stroke*. 2015;46:1793–1799.
40. Telfer PT, Evanson J, Butler P, et al. Cervical carotid artery disease in sickle cell anemia: clinical and radiological features. *Blood*. 2011;118:6192–6199.