



# Expert consensus recommendations to improve diagnosis of ATTR amyloidosis with polyneuropathy

David Adams<sup>1</sup> · Yukio Ando<sup>2</sup> · João Melo Beirão<sup>3</sup> · Teresa Coelho<sup>4</sup> · Morie A. Gertz<sup>5</sup> · Julian D. Gillmore<sup>6</sup> · Philip N. Hawkins<sup>6</sup> · Isabelle Lousada<sup>7</sup> · Ole B. Suhr<sup>8</sup> · Giampaolo Merlini<sup>9,10</sup>

Received: 10 December 2019 / Revised: 20 December 2019 / Accepted: 23 December 2019  
© The Author(s) 2020

## Abstract

Amyloid transthyretin (ATTR) amyloidosis with polyneuropathy (PN) is a progressive, debilitating, systemic disease wherein transthyretin protein misfolds to form amyloid, which is deposited in the endoneurium. ATTR amyloidosis with PN is the most serious hereditary polyneuropathy of adult onset. It arises from a hereditary mutation in the *TTR* gene and may involve the heart as well as other organs. It is critical to identify and diagnose the disease earlier because treatments are available to help slow the progression of neuropathy. Early diagnosis is complicated, however, because presentation may vary and family history is not always known. Symptoms may be mistakenly attributed to other diseases such as chronic inflammatory demyelinating polyradiculoneuropathy (CIDP), idiopathic axonal polyneuropathy, lumbar spinal stenosis, and, more rarely, diabetic neuropathy and AL amyloidosis. In endemic countries (e.g., Portugal, Japan, Sweden, Brazil), ATTR amyloidosis with PN should be suspected in any patient who has length-dependent small-fiber PN with autonomic dysfunction and a family history of ATTR amyloidosis, unexplained weight loss, heart rhythm disorders, vitreous opacities, or renal abnormalities. In nonendemic countries, the disease may present as idiopathic rapidly progressive sensory motor axonal neuropathy or atypical CIDP with any of the above symptoms or with bilateral carpal tunnel syndrome, gait disorders, or cardiac hypertrophy. Diagnosis should include DNA testing, biopsy, and amyloid typing. Patients should be followed up every 6–12 months, depending on the severity of the disease and response to therapy. This review outlines detailed recommendations to improve the diagnosis of ATTR amyloidosis with PN.

**Keywords** ATTR amyloidosis · ATTRv · Diagnosis · hATTR · Peripheral neuropathy · Transthyretin amyloidosis

## Introduction

Hereditary amyloid transthyretin (ATTRv; v for “variant”) amyloidosis with polyneuropathy (PN) is a rare multisystemic disease with predominant involvement of the peripheral nervous system and amyloid deposits in the

endoneurium [1]. It was first described in endemic areas in Portugal and later in Japan and Sweden and is now considered a worldwide disease [2]. ATTRv amyloidosis has an autosomal-dominant mode of transmission because of a point mutation of the *TTR* gene [3]. Certain *TTR* mutations are associated predominantly with endoneurial amyloid

✉ David Adams  
david.adams@aphp.fr

<sup>1</sup> Department of Neurology, French National Reference Centre for Familial Amyloidotic Polyneuropathy, CHU Bicêtre, Université Paris-Saclay APHP, INSERM U1195, 94276 Le Kremlin-Bicêtre, France

<sup>2</sup> Department of Neurology, Graduate School of Medical Sciences, Kumamoto, Japan

<sup>3</sup> Ophthalmology Service, Hospital de Santo António, Porto, Portugal

<sup>4</sup> Centro Hospitalar Do Porto, Porto, Portugal

<sup>5</sup> Mayo Clinic, Rochester, MN, USA

<sup>6</sup> National Amyloidosis Centre, University College London, London, UK

<sup>7</sup> Amyloidosis Research Consortium, Boston, MA, USA

<sup>8</sup> Department of Public Health and Clinical Medicine, Umeå University, Umeå, Sweden

<sup>9</sup> Amyloidosis Center Foundation, IRCCS Policlinico San Matteo, San Matteo, Italy

<sup>10</sup> Department of Molecular Medicine, University of Pavia, Pavia, Italy

deposition that results in polyneuropathy (most commonly *Val30Met*); others are associated with predominant cardiomyopathy or a mixed phenotype [4–6] (Fig. 1).

ATTRv amyloidosis is the most serious hereditary polyneuropathy of adult onset and a progressive, devastating, and life-threatening disease. Diagnostic delay varies in non-endemic regions from 3 to 4 years. Average survival from disease onset varies from 6 to 12 years, and cardiac involvement is often the cause of death [7, 8].

The disease is caused by abnormal transthyretin (TTR) protein that misfolds and aggregates to form amyloid fibrils that deposit in organs and tissue. It has long been considered an endemic disease with a high prevalence (~ 1/1000 persons). Early diagnosis is typically facilitated by positive family history, stereotypical neurologic manifestations such as length-dependent polyneuropathy and autonomic dysfunction [9], and presence of the unique TTR variant *Val30Met*. Gradually, it has been reported in many countries outside endemic areas with a sporadic presentation and is now well accepted as a globally prevalent disease. The estimated prevalence of ATTRv amyloidosis with PN worldwide is 10,000 (1/1,000,000 persons) [2].

## Purpose and methodology

The diagnosis of this rare disease is a challenge for the neurologist and is most often delayed by 3–4 years, which impacts patients' functional and vital prognosis. Diagnostic delays occur for multiple reasons, but oftentimes misleading

diagnoses are made because of sporadic, late-onset, highly varied clinical presentation patterns of various TTR variants [10]. In this review, we describe the main phenotypes of neuropathies of this disease and present simple tools to quickly confirm the diagnosis and to perform the minimal investigations needed to clarify the systemic extension of the disease.

Consensus recommendations for the suspicion and diagnosis of all forms of ATTR amyloidosis were developed through a series of development and review cycles by an international working group consisting of key amyloidosis specialists in collaboration with companies conducting research in ATTR amyloidosis (GSK, Ionis, Pfizer, Alnylam) and the Amyloidosis Research Consortium. These consensus recommendations were developed based on the published literature and the medical expertise of the international working group through in-person meetings along with refinement of the draft by telephone or email. The literature was surveyed using PubMed Central, and references were selected by the expert working group according to the relevance of the data. Recently, specific consensus recommendations were provided for cardiology ATTR amyloidosis [11]. This review describes the specific consensus recommendations for best practices in ATTR with predominant PN. It is intended to provide clinicians with an overview of important aspects of ATTR diagnosis that may facilitate rapid and accurate identification of the disease.

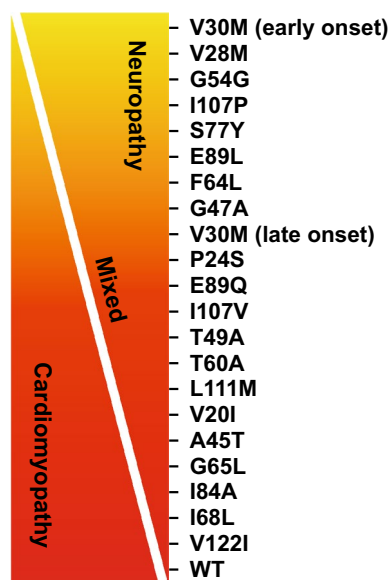
## Clinical presentation and suspicion index

### Clinical manifestations and phenotypes

#### Historical phenotypes in endemic areas

In endemic areas (such as Portugal, Japan, Sweden, Brazil), the main phenotype represents the hallmark of ATTRv with PN—a length-dependent small-fiber PN with dysautonomia—with manifestations mimicking those of diabetic neuropathy [12]. In these areas, the disease may not be as difficult to diagnose because it is aided by positive family history, high penetrance, and typical clinical presentation and by genetic counseling for, detection in, and follow-up of carriers of the mutant *TTR* gene [13]. Penetrance, however, is highly variable. For instance, in Portugal, the median age at onset is around 30 years [7], and 80% of mutation carriers are reported to exhibit the disease by age 50, whereas this number is only 11% in Sweden [14, 15].

Initial symptoms of ATTRv with PN vary but can include sensory symptoms such as pain, paresthesia, and numbness in the feet; autonomic dysfunction such as digestive disorders and erectile dysfunction; and general items such as fatigue, weight loss, and plantar ulcers [7, 16]. Sensory loss



**Fig. 1** Genotype–phenotype correlations in ATTR amyloidosis. *ATTR* amyloid transthyretin, *WT* wild type. Reprinted with permission from Castano et al. [6]

progresses with advancing disease and eventually extends to the lower limbs and to the hands and arms. More advanced disease may also involve loss of reflexes, reduced motor skills, and muscle weakness [4, 17].

### Two clinical neuropathic phenotypes in late versus early onset in Val30Met variant

ATTRv amyloidosis is classified on the basis of age at onset, and symptoms before the age of 50 distinguish early from late onset [18]. Clinical presentation and disease course differ considerably between patients with early-onset and those with late-onset ATTRv with PN associated with the *Val30Met* mutation [7, 8, 18–21] (Table 1). Early-onset disease follows the classical course. In patients with early onset, penetrance is high (0.8) [14] and the disease is nearly always associated with a positive family history, initial symptoms of somatic or autonomic peripheral neuropathy, less severe disease course, and longer survival [19]. Late-onset disease tends to occur sporadically and typically presents with peripheral (not autonomic) neuropathy. In families with late-onset disease, there is a male predominance and low penetrance. At 50 years, sensorimotor symptoms begin in the lower extremities with disturbance of both superficial and deep sensation (mixed sensory loss) and relatively mild autonomic symptoms [19, 22]. In the Swedish population, amyloid fibril composition determines the phenotype; ATTR consisting of full-length TTR is associated with early onset and neuropathy, whereas a mixture of TTR fragments is

associated with late onset, neuropathy, and cardiomyopathy [23].

### Other clinical phenotypes in nonendemic countries

In nonendemic regions, four ATTRv amyloidosis phenotypes are reported [13, 24]. Small-fiber PN is not predominant and may occur in about 33% of patients. Also reported are length-dependent, all-fiber PN with diffuse areflexia and mixed sensory loss for pain, temperature, and proprioception [19] mimicking demyelinating polyneuropathy [25, 26]; multifocal neuropathy with onset in the upper limbs [8, 27]; ataxic neuropathy [24]; and exceptional motor neuropathy [26, 28, 29].

### Misdiagnosis

For people in nonendemic areas, diagnosis is likely to be missed. In these areas, 52–77% of cases occur with no family history of the disease [13, 24, 28], and presentation is variable. It has been reported that ATTRv with PN is suspected in only 26–38% of initial evaluations in these areas [24, 28]. Multiple misdiagnoses before the correct diagnosis of amyloid neuropathy have been reported in 20–40% of cases [25, 27].

Misdiagnoses depend on the initial clinical presentation of neuropathy (symptoms and signs). Common misdiagnoses (Table 2) [13, 25–27, 29–32] of patients before the correct diagnosis of ATTRv with PN include chronic inflammatory

**Table 1** Characteristics of *Val30Met* early- and late-onset ATTR amyloidosis at the time of diagnosis and clinical course

	Early-onset <i>Val30Met</i> [7, 19]	Late-onset <i>Val30Met</i> [8, 19, 20]
Age at onset, years	< 50	≥ 50
Country	Portugal, Japan <sup>a</sup> , Brazil, Sweden <sup>b</sup>	Sweden <sup>b</sup> , France, UK, Italy, Japan, USA
Positive family history, %	94	48
Peripheral neuropathy, %	57	81
Autonomic neuropathy, %	48	10
Weight loss, %	5	0
Disease course		
Mean delay in need for aid in walking, years	> 5.6	3
Mean delay for wheelchair bound, years	10	6
Cardiac events	Progressive conduction disorders	Restrictive cardiomyopathy Cardiac insufficiency Progressive conduction disorders
Median survival, years	11	7.3
Cause of death	Cachexia Infection	Cardiac insufficiency Sudden death Cachexia or secondary infection

Reprinted with permission from Adams [18]

ATTR amyloid transthyretin

<sup>a</sup>Endemic areas, Nagano and Arai Kumamoto, Japan

<sup>b</sup>Patients with early- and late-onset disease are found in the endemic area in Sweden; all are believed to have a common Swedish founder [21]

**Table 2** Main misdiagnosis and red flags

Misdiagnosis	Incidence, %	Misleading features	Red flags	References
CIDP	13–15	SM 4 limbs Diffuse areflexia Albuminocytologic dissociation Demyelination on biopsy Demyelinating NCS	Pain Sensory loss (wrists) Autonomic dysfunction Upper limb weakness NCS	[26] [25] [30] [31]
Chronic axonal idiopathic PN	24–33	Axonal neuropathy in the elderly, seemingly idiopathic	Severity, disability, rapid Difficulties in walking	[13] [30] [27]
CTS	11	Paresthesia in the hands	No relief after surgery	[27]
Lumbar spinal stenosis	7.3	Progressive difficulty walking in the elderly Spinal stenosis on lumbar CT or MRI	Abnormal NCS Worsening in spite of surgery	[25]
Motor neuron disease Motor neuropathy, ALS	< 1	Upper limb and tongue amyotrophy Dysarthria Hand weakness	Abnormal sensory SNAP (NCS) No symptoms of upper motor neuron involvement	[32] [29]
Miscellaneous				
Alcoholic PNP		Small-fiber length-dependent PN	Alcoholism	[25]
Diabetic PNP		Small-fiber length-dependent PN Autonomic dysfunction	Rapid severity/duration of diabetes Difficulties in walking	[30]
Paraneoplastic neuropathy		Non-length-dependent sensory loss + ataxia Weight loss	No anti-onconeurological antibody Negative findings on whole-body PET	[27]

ALS amyotrophic lateral sclerosis, CIDP chronic inflammatory demyelinating polyneuropathy, CT computed tomography, CTS carpal tunnel syndrome, MRI magnetic resonance imaging, NCS nerve conduction study, PET positron emission tomography, PN polyneuropathy, PNP peripheral neuropathy, SM sensorimotor, SNAP sensory nerve action potential

demyelinating polyradiculoneuropathy (CIDP), idiopathic axonal polyneuropathy, lumbar spinal stenosis, and, more rarely, diabetic neuropathy and AL amyloidosis. Increased awareness of this serious disease and its symptoms—as well as better knowledge of simple diagnostic tools, especially among neurologists—is essential to enable early diagnosis and optimal treatment of ATTRv with PN.

The disease course for late onset is more aggressive and has a shorter survival time than for early onset [18]. Initial symptoms of late-onset disease may also include sensory problems in upper limbs (33%) and walking disorders (11%) [24], and autonomic neuropathy may occur later in the disease in approximately 47–78% of these patients [24, 28, 30].

Amyloid can also be deposited in the heart, eyes, and leptomeninges, resulting in associated organ dysfunction and clinical symptoms. Cardiac involvement is usually asymptomatic at diagnosis but has been detected in up to 72% of patients when using cardiac imaging [30]. Cardiac hypertrophy (septal thickness > 12 mm) is found at presentation in 33 of 60 (55%) patients with late-onset *Val30Met*, predominantly in males [20].

Physicians should be aware of the leptomeningeal forms of ATTRv amyloidosis, which are associated with cerebral hemorrhage [33–36] and CNS dysfunction, typically with symptoms related to CNS impairment such as dementia, ataxia, spasticity, seizures, and stroke-like

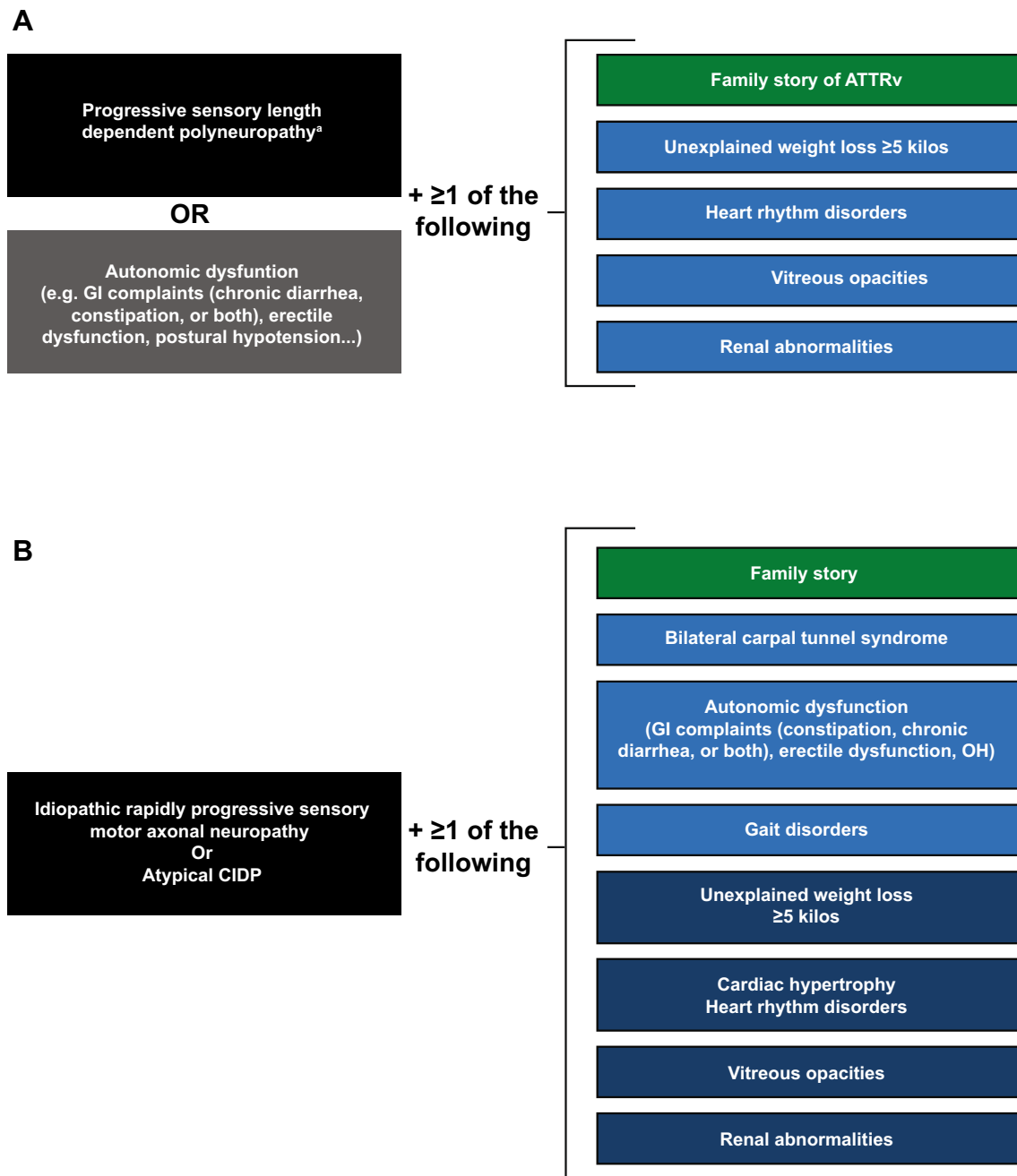
episodes [37–40]. The abnormal TTR protein deposited in the leptomeninges may be produced in the choroid plexus, making liver transplantation less effective in these patients [37].

### Suspicion index

Suspicion of ATTRv amyloidosis should be high for patients with progressive and disabling polyneuropathy, particularly in elderly patients. The disease should also be considered in patients with neuropathy plus at least one red flag symptom suggestive of multisystemic involvement (Fig. 2) [41].

For patients with a known family history of ATTRv amyloidosis, any onset of length-dependent axonal polyneuropathy predominantly affecting temperature and pain sensation, autonomic dysfunction, or cardiac arrhythmia signals a need to assess organ involvement.

For patients without a family history of amyloidosis, diagnosis of ATTRv amyloidosis should be considered if they have progressive idiopathic, axonal polyneuropathy, or atypical CIDP. Particular attention should be given to those who have autonomic dysfunction, early gait disorders, gastrointestinal disturbances and weight loss, carpal tunnel syndrome or previous surgery for bilateral carpal tunnel, concurrent cardiac abnormalities, or unexplained weight loss.



**Fig. 2** Suspicion index for diagnosis of ATTRv amyloidosis with PN. **a** In endemic areas. **b** In nonendemic areas. ATTRv hereditary transthyretin amyloid amyloidosis, CIDP chronic inflammatory demyelinating

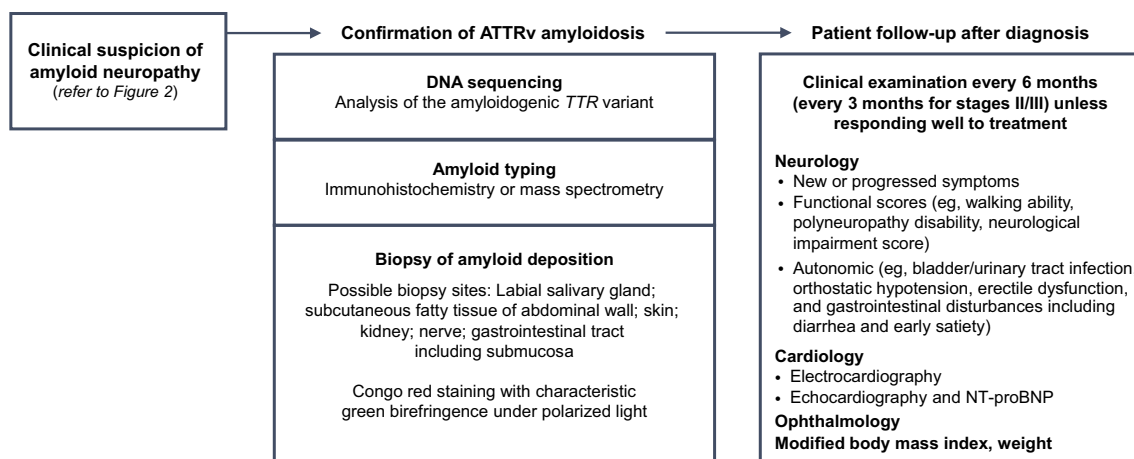
polyneuropathy, GI gastrointestinal, OH orthostatic hypotension. <sup>a</sup>No diabetes, no alcohol abuse, vitamin B<sub>12</sub> deficiency. Adapted with permission from Conceicao et al. [41]

## Diagnosis

Physicians should be aware of the clinical presentation and diagnostic approaches for patients with ATTRv amyloidosis with PN [10, 18, 25, 42–45] (Figs. 2, 3, Table 3). Clinical manifestations are diverse and nonspecific and may include neuropathic pain, loss of balance, carpal tunnel syndrome, and unexpected weight loss.

## Diagnostic tools

There are only two main categories of diagnostic tools in ATTR-PN: *TTR* gene sequencing looking for *TTR* gene amyloidogenic variants and tools for detection of amyloid deposits including classical biopsy and, more recently, bone scintigraphy with diphosphono-1,2-propanodicarboxylic acid (DPD), hydroxymethylene diphosphonate (HMDP),



**Fig. 3** Diagnostic approach and patient follow-up. *ATTRv* hereditary transthyretin amyloid, *NT-proBNP* N-terminal fragment of the probrain natriuretic peptide, *TTR* transthyretin

**Table 3** Diagnostic tools for ATTR-PN

	<i>TTR</i> gene analysis	Amyloid detection	
		Biopsy <sup>a</sup>	DPD, PYP, HMDP scintigraphy
Advantages	Looking for 1 of the 130 amyloidogenic variants [10] Possible to rule out <i>ATTRv</i> if gene analysis is negative for a variant Fastest method to confirm <i>ATTRv</i> in case of neuropathy	Formal proof of amyloidosis in carriers of <i>TTR</i> variants and sporadic amyloid neuropathy	Noninvasive demonstration of cardiac amyloid with bone scintigraphy [43, 44]
Rules	<i>TTR</i> gene sequencing of the 4 exons	Congo red staining Examination under polarized microscopy Many sections often needed to detect a single deposit	
Limits	13 nonamyloidogenic variants, including Gly6Ser and Thr119Met [10] Possible delay of genetic results	Sensitivity for amyloid detection 60–80% [25] Dependent on experience and expertise of pathologist May be invasive and risky (cardiac) Time-consuming Several biopsy sites sometimes needed to find a deposit <sup>a</sup>	Radiolabeling if no light chain Sensitivity < 100% LV wall thickness > 12 mm in combination with abnormal heart/whole-body retention Heart/whole-body > 7.5 associated with the highest event rate [45]
Remarks	Some correlation between mutation and predominant organ involvement (e.g., heart, brain, eye)	False negative Amyloid light chain must be excluded	Complementarity of <i>TTR</i> gene analysis May avoid cardiac biopsy

*ATTR-PN* amyloid transthyretin polyneuropathy, *DPD* diphosphono-1,2-propanodicarboxylic acid, *HMDP* hydroxymethylene diphosphonate, *LV* left ventricular, *PYP* pyrophosphate

<sup>a</sup>At least one tissue biopsy should be performed to identify amyloid deposits and, if negative, another biopsy, preferentially mini-invasive (skin, labial salivary gland, abdominal fat), should be performed

or pyrophosphate (PYP) (Table 3). Staining a tissue biopsy (salivary gland, abdominal fat, or nerve tissue), typing for amyloid, and screening for *TTR* mutations by *TTR* gene sequencing are important measures for identifying amyloid neuropathy in sporadic cases presenting with rapidly idiopathic progressive axonal polyneuropathy of undetermined origin or atypical CIDP [13].

## ***TTR* gene sequencing**

The *TTR* gene, located in chromosome 18, is small (4 exons). More than 130 mutations can occur, most of which are pathogenic and amyloidogenic and are associated with varied phenotypes including predominant neuropathy,



cardiomyopathy, and, more rarely, ocular and cerebro-meningeal. A registry has been established to record the significance of mutations and phenotypes in ATTRv amyloidosis [10]. A few nonamyloidogenic variants have also been identified, including the polymorphism Gly6Ser; the discovery of such a variant has no significant value in a patient with idiopathic sporadic peripheral neuropathy. A TTR variant alone cannot confirm a diagnosis of ATTRv amyloidosis because of incomplete penetrance in carriers. Nevertheless, DNA sequencing of the *TTR* gene can be a useful approach in patients with idiopathic neuropathy to support or exclude a diagnosis of ATTRv amyloidosis and for predictive genetic counseling testing in healthy but potentially at-risk persons with a family history of ATTRv amyloidosis.

## Amyloid confirmation

### Biopsy

Staining of biopsy samples with Congo red and visualization of apple-green birefringence of Congo red-stained preparations under polarized light are crucial to confirm the diagnosis of disease and are indicative of the presence of amyloid fibrils. Finding amyloid deposits can be challenging, however, and negative biopsy results should not exclude a diagnosis [46, 47]. Mini-invasive biopsy include labial salivary gland biopsy, skin biopsy, and abdominal

fat biopsy, which are preferred to invasive biopsies such as nerve biopsy and cardiac biopsy. The sensitivity of a biopsy can be impeded by inadequacies of the tissue samples; much depends on the site of the biopsy and on whether the biopsy includes nerve tissue (Table 4). In France and Portugal [48], biopsy of the salivary gland is preferred over abdominal fat aspiration, which is used in the USA, the UK, and other European countries except Sweden, where fat pad biopsy is used. The diagnostic sensitivity of a 3-mm-diameter skin punch biopsy at the distal leg 10 cm proximal to the lateral malleolus and proximal thigh is 70% [49, 50]. The minimal number of tissues to be examined for amyloid detection, including by mini-invasive biopsy, is two.

### Bone scintigraphy

Myocardial radiotracer uptake in bone scintigraphy with  $^{99m}\text{Tc}$ -labeled 3,3-DPD,  $^{99m}\text{Tc}$ -labeled PYP, or  $^{99m}\text{Tc}$ -labeled HMDP could be useful in patients with peripheral neuropathy, amyloidogenic *TTR* mutation, and hypertrophic cardiopathy who have negative biopsy findings, and it may obviate the need for endomyocardial biopsy [44].

**Table 4** Histologic and mass spectrometry methods for diagnosis of ATTR amyloidosis

Investigation	Sensitivity	Specificity	Aim
Biopsy site			
Sural nerve	79–80% TTR	High	Detecting amyloid deposits [24, 28, 30]
Labial salivary gland <sup>a</sup>	91% <i>Val30Met</i> early onset	High	Detecting amyloid deposits [77]
Abdominal fat pad <sup>b</sup>	14–83%	High	Detecting amyloid deposits [78]
Heart	~ 100%	~ 100%	Detecting amyloid deposits
Renal	92–100%	High	Detecting amyloid deposits [79–82]
Skin biopsy	70%	100%	Detecting amyloid deposits [49, 50]
Pathology test [83]			
Congo red staining	Medium–high	High	Detecting amyloid deposits
Polarized microscopy examination	High	High	Green birefringence
IHC with anti-TTR antibodies	High	Medium–high	–
Immuno-EM with anti-TTR antibodies	High	High	Detecting and typing amyloid fibrils
Mass spectrometry tests [84]			
LMD/MS	~ 100%	High	Determining specific type of amyloid deposits

Adapted with permission from Adams et al. [85]

ATTR amyloid transthyretin, EM electron microscopy, IHC immunohistochemistry, LMD/MS laser microdissection mass spectrometry-based proteomic analysis, TTR transthyretin

<sup>a</sup>Portugal and France

<sup>b</sup>USA, UK, the Netherlands, Germany, Sweden

## Assessment of the extent of the disease

### Grading and staging other manifestations

Because ATTRv amyloidosis is a systemic disease, physicians should be aware of manifestations other than those of the peripheral nervous system, such as cardiac, ocular, and renal manifestations. A multidisciplinary approach is required to assess whether, through effects of autonomic dysfunction or amyloid deposition, other organs and systems are likely to be affected [18, 41].

### Autonomic dysfunction

Autonomic dysfunction occurs in approximately 73% of patients with ATTR amyloidosis with PN and affects the gut, bladder sphincter, genital nerves, and cardiovascular system. Common symptoms include impotence (73% of male patients), gastrointestinal (GI) disturbance (53%), urinary incontinence (50%), and orthostatic dysregulation (46%) [51]. The most common symptoms seen in the GI system include weight loss (approximately 30% of patients), early satiety, and alternating constipation and diarrhea [52]. The incidence of GI disturbances increases as the disease progresses [53], and the onset of diarrhea earlier in the course of the disease is associated with shorter survival [54, 55].

### Other organ involvement

Amyloid can also be deposited in the heart, eyes, kidneys, and, rarely, the leptomeninges, resulting in associated organ dysfunction and clinical symptoms. Cardiac involvement is usually asymptomatic at diagnosis but has been detected in up to 72% of patients through cardiac imaging [30] or cardiac multimodal imaging [56]. Cardiac involvement is associated with progressive myocardial infiltration, denervation, and conduction and rhythm disturbances. Systematic assessment and management of cardiac involvement is critical because cardiac manifestations worsen with disease progression and are more likely to cause death [18]. Ophthalmic manifestations have been reported in 20% (glaucoma and/or vitreous opacities) to 70% (dry eye) of patients with ATTR amyloidosis with PN [57–60].

### Evaluation of the spread of the disease

Assessment of the spread of the disease is crucial for the detection of accompanying organ damage and requires a multidisciplinary approach by a neurologist (polyneuropathy, autonomic neuropathy), a cardiologist, an ophthalmologist, and a nephrologist or general health practitioner

(Table 5) [61–71]. This is essential because the involvement of most organs, other than the nervous system, is latent but may have potentially major consequences—heart blocks, restrictive cardiomyopathy, glaucoma, renal insufficiency—for patients. Required evaluations for neuropathy include neuropathy impairment score (NIS), search for orthostatic hypotension, sudoscan, heart rate variability tests, Compound Autonomic Dysfunction Test for autonomic dysfunction, and Rasch-built Overall Disability Scale (RODS). Required evaluations for cardiac involvement include New York Heart Association (NYHA) score, electrocardiography (ECG), multimodal cardiac imaging [echocardiography (ECHO), magnetic resonance imaging (MRI), DPD, metaiodobenzylguanidine], complete ophthalmologic examination, and modified body mass index (mBMI). Biomarkers are also required for heart [N-terminal fragment of the probrain natriuretic peptide (NT-proBNP) and cardiac troponins] and renal [estimated glomerular filtration rate (eGFR), proteinuria] dysfunction (Table 5).

### Grading of the disease

Grading of the disease in each organ system involved is important for the follow-up of these patients. Grading allows detection of eventual disease progression and of organ complications that will require specific management (Tables 3, 5). The frequency of examinations should be determined by the severity and the systemic nature of the disease in each patient.

### Follow-up

Patients with confirmed diagnoses should be routinely followed up to monitor for disease progression [18] (Fig. 3). Assessments should evaluate somatic neuropathy with locomotion (polyneuropathy disability score), severity of sensory motor neuropathy (NIS), autonomic dysfunction, manifestations with cardiac insufficiency (NYHA), biomarkers (ECG, ECHO, NT-proBNP), mBMI, renal dysfunction with eGFR, and proteinuria (Table 5). Assessments should be scheduled every 6–12 months, and that schedule should be maintained, depending on investigations.

The quantification of dysfunction caused by ATTRv amyloidosis depends on an array of clinical tests, including those that measure nerve conduction, autonomic neuropathy, manual grip strength, and lower limb function (Tables 5, 6) [7, 8, 18, 51, 72]. However, many of these tests have been used only in relatively small studies; further refinement and validation of these tests in larger patient cohorts are needed.



**Table 5** Evaluation of disease progression at initial screening and follow-up

	Evaluation	Purpose	References
Neurologic manifestations			
A. Sensory motor neuropathy	Questionnaire		[61]
	Paresthesia, neurogenic pain	Small fiber loss	
	Gait disability	Large fiber loss	
	NIS (0–244)		
	Weakness in LL and UL	Large fiber loss	
	Sensory loss in toes and fingers	Small and large fiber loss	
	Tendon reflex loss in the four limbs	Large fiber loss	
	Examination		
Pain and thermal sensory loss in the extremities in LL and UL (extension)	Small fiber loss		
Disability	Modified Norris test	Sensorimotor neuropathy	[62]
	FAP-RODS	Overall disability	[63]
	RODS	Overall disability	[86]
Locomotion	PND score	Autonomy to walk	
B. Autonomic neuropathy	CADT* (24-0)	Overall dysfunction	[62]
	COMPASS 31		[64]
	Sudoscan	Denervated sweat glands of the soles and palms	
	Orthostatic hypotension		[87]
	MIBG scintigraphy	Sympathetic cardiac denervation	
	Heart rate variability tests	Sympathetic and parasympathetic	
Non-neurologic manifestations			
C. Cardiac	ECG, Holter-ECG	Looking for conduction block or arrhythmia	
	Cardiac staging		
	ECHO (strain)	Cardiac involvement	
	Cardiac MRI	Cardiac involvement	
	DPD, PYP, and HMDP scintigraphy	Cardiac amyloidosis	
	NT-proBNP	Cardiomyocyte stress	
	Cardiac troponin	Cardiomyocyte death	
	NYHA class	Extent of heart failure	
	NYHA class	Stage the extent of cardiac damage	[65]
	D. Ocular	Slit-lamp examination	Vitreous opacities
Intraocular pressure		Ocular hypertension	
Schirmer test		Dry eye (sicca syndrome)	
Visual acuity			
E. Kidney	Proteinuria	Renal dysfunction	
	eGFR	Renal insufficiency	
F. General condition	Weight	Nutritional status	
	mBMI	Nutritional status	
Quality of life	Norfolk QOL-DN	Disease-specific changes in QOL	[66]
	SF-36 QOL	Non-disease-specific changes in QOL	[67]
Overall scale for ATTR disease	Kumamoto neurologic scale	Sensory disturbances, motor weakness, autonomic dysfunction, and visceral organ impairment	[68, 69]
Sensory motor deficit in the limbs and autonomic dysfunction	NIS + 7, mNIS + 7	Composite score for clinical trial only	[70]
			[71]

*CADT* Compound Autonomic Dysfunction Test, *COMPASS* Composite Autonomic Symptom Score, *DN* diabetic neuropathy, *DPD* diphosphono-1,2-propanodicarboxylic acid, *ECG* electrocardiography, *ECHO* echocardiography, *eGFR* estimated glomerular filtration rate, *FAP-RODS* Familial Amyloid Polyneuropathy-Specific Rasch-built Overall Disability Scale, *HMDP* hydroxymethylene diphosphonate, *LL* lower limb, *mBMI* modified body mass index, *MIBG* metaiodobenzylguanidine, *MRI* magnetic resonance imaging, *mNIS* modified Neuropathy Impairment Score, *NIS* Neuropathy Impairment Score, *NT-proBNP* N-terminal fragment of the probrain natriuretic peptide, *NYHA* New York Heart Association, *PND* polyneuropathy disability, *PYP* pyrophosphate, *QOL* quality of life, *SF-36* 36-Item Short Form Survey, *UL* upper limb

**Table 6** Staging of ATTRv amyloidosis with PN, scales, and tools at baseline

Locomotion stage description [7]	Duration of stage, years		PND score [88]
	Early-onset Val30Met [7]	Late-onset Val30Met Other variants [8, 72]	
Stage 1 Disease limited to the lower limbs Walking without help Slight weakness of the extensors of the big toes	5.6 ± 2.8	2–4	PND I Sensory disturbances in extremities Preserved walking capacity PND II Difficulty walking but no need for a walking stick
Stage 2 Progression of motor signs in lower limbs with steppage and distal amyotrophies; muscles of the hands becoming wasted and weak Patient obviously disabled but can still move around with help	4.8 ± 3.6	2–3	PND IIIa 1 stick or 1 crutch required for walking PND IIIb 2 sticks or 2 crutches required for walking
Stage 3 Patient confined to a wheelchair or a bed, with generalized weakness and areflexia	2.3 ± 3.1	1–2	PND IV Patient confined to a wheelchair or a bed

Reprinted with permission from Adams [18]

ATTRv hereditary transthyretin amyloidosis, PND polyneuropathy disability

### Consequences of diagnosis with ATTRv with PN

For patients with diagnoses of ATTRv with PN, early disease-modifying therapy may be beneficial [73, 74] and underscores the need for diagnosis as soon as possible. Genetic counseling is recommended for family members of patients, and therapeutic patient education is recommended for siblings and children [75, 76].

### Conclusions

Identification of ATTRv amyloidosis with PN can be challenging, particularly in nonendemic regions, and a high level of suspicion is required to diagnose patients as early as possible. Patients can present with heterogeneous symptoms and variable levels of disease severity, which often leads to a misdiagnosis of diabetic neuropathy or CIDP. Early and accurate diagnosis may also be confounded by a lack of family history and the presence of various phenotypes common to multiple disease conditions such as GI disorders. Older patient age at disease onset can also contribute to misdiagnosis because symptoms of ATTR amyloidosis may be confused with declines in systemic neurologic function that typically occur with normal aging.

In sporadic and potentially misdiagnosed cases, important tools for identifying amyloid neuropathy include *TTR* gene sequencing for amyloidogenic mutations, tissue biopsy (salivary gland, skin, abdominal fat, or nerve tissue) with staining, and amyloid typing. Because ATTRv with PN is

a systemic disease, a holistic assessment approach should be used that includes consultation across multiple specialties (e.g., neurologists, cardiologists, ophthalmologists and eventually gastroenterologists, and nephrologists). Early and accurate diagnosis of ATTR amyloidosis allows early treatment and will potentially modify disease progression in patients.

**Acknowledgements** Funding for these recommendations was provided by the Amyloidosis Research Consortium. Medical editorial assistance with nonintellectual content and manuscript preparation was provided by ApotheCom (San Francisco, CA, USA). This review was sponsored by the Amyloidosis Research Consortium.

**Author contributions** Dr Adams wrote the first draft of the manuscript. All authors revised the manuscript for intellectual content and gave approval for it to be submitted for publication.

### Compliance with ethical standards

**Conflicts of interest** This review was sponsored by the Amyloidosis Research Consortium. Dr Adams reports grants from Alnylam and Pfizer and personal fees from Prothena, GSK, Alnylam, and Pfizer. Dr Ando has nothing to disclose. Dr Beirão has nothing to disclose. Dr Coelho was paid per protocol for clinical trials from FoldRx, Pfizer, Ionis, and Alnylam and received grants from FoldRx and Pfizer; received support from Pfizer, Ionis, Biogen, and Alnylam to attend scientific meetings; and has presented on behalf of Pfizer, Alnylam, GSK, Prothena, and Ionis/Akcea and received honoraria. Dr Gertz has received personal fees from Ionis/Akcea, Alnylam, Prothena, Celgene, Janssen, Annexon, Appellis, Amgen, Medscape, Physicians Education Resource, and Research to Practice; grants and personal fees from Spectrum; personal fees for Data Safety Monitoring board from AbbVie; speaker fees from Teva, Johnson and Johnson, Medscape, and

DAVA Oncology; royalties from Springer Publishing; and grant funding from the Amyloidosis Foundation, the International Waldenström Foundation, and the National Cancer Institute (SPORE MM SPORE 5P50 CA186781-04). In addition, he has served on advisory boards for Pharmacocyclics and for Proclara (outside the submitted work). Dr Gillmore has participated in advisory boards for Alnylam Pharmaceuticals Inc and GSK Inc. Dr Hawkins has nothing to disclose. Ms Lousada has received honoraria from Akcea. Dr Suhr has received honoraria and travel and consultancy fees from Ionis/Akcea, Alnylam, Prothena, and Intellia. Dr Merlini has received honoraria from Janssen and Prothena; travel support from Prothena and Celgene; and consulting fees from Millennium, Pfizer, Janssen, Prothena, and Ionis.

**Ethical standards** Not applicable for this type of study.

**Informed consent** Not applicable for this type of study.

**Open Access** This article is licensed under a Creative Commons Attribution 4.0 International License, which permits use, sharing, adaptation, distribution and reproduction in any medium or format, as long as you give appropriate credit to the original author(s) and the source, provide a link to the Creative Commons licence, and indicate if changes were made. The images or other third party material in this article are included in the article's Creative Commons licence, unless indicated otherwise in a credit line to the material. If material is not included in the article's Creative Commons licence and your intended use is not permitted by statutory regulation or exceeds the permitted use, you will need to obtain permission directly from the copyright holder. To view a copy of this licence, visit <http://creativecommons.org/licenses/by/4.0/>.

## References

- Adams D, Koike H, Slama M, Coelho T (2019) Hereditary transthyretin amyloidosis: a model of medical progress for a fatal disease. *Nat Rev Neurol* 15(7):387–404
- Schmidt HH, Waddington-Cruz M, Botteman MF, Carter JA, Chopra AS, Hopps M, Stewart M, Fallet S, Amass L (2018) Estimating the global prevalence of transthyretin familial amyloid polyneuropathy. *Muscle Nerve* 57:829–837
- Saraiva MJ, Birken S, Costa PP, Goodman DS (1984) Amyloid fibril protein in familial amyloidotic polyneuropathy, Portuguese type. Definition of molecular abnormality in transthyretin (prealbumin). *J Clin Invest* 74:104–119
- Hawkins PN, Ando Y, Dispenzeri A, Gonzalez-Duarte A, Adams D, Suhr OB (2015) Evolving landscape in the management of transthyretin amyloidosis. *Ann Med* 47:625–638
- Rapezzi C, Quarta CC, Obici L, Perfetto F, Longhi S, Salvi F, Biagini E, Lorenzini M, Grigioni F, Leone O, Cappelli F, Palladini G, Rimessi P, Ferlini A, Arpesella G, Pinna AD, Merlini G, Perlini S (2013) Disease profile and differential diagnosis of hereditary transthyretin-related amyloidosis with exclusively cardiac phenotype: an Italian perspective. *Eur Heart J* 34:520–528
- Castano A, Drachman BM, Judge D, Maurer MS (2015) Natural history and therapy of TTR-cardiac amyloidosis: emerging disease-modifying therapies from organ transplantation to stabilizer and silencer drugs. *Heart Fail Rev* 20:163–178
- Coutinho P, Martins da Silva A, Lopas LJ (1980) Forty years of experience with type 1 amyloid neuropathy. Review of 483 cases. In: *Amyloid and amyloidosis*. Excerpta Medica, Amsterdam, pp 88–98
- Koike H, Tanaka F, Hashimoto R, Tomita M, Kawagashira Y, Iijima M, Fujitake J, Kawanami T, Kato T, Yamamoto M, Sobue G (2012) Natural history of transthyretin Val30Met familial amyloid polyneuropathy: analysis of late-onset cases from non-endemic areas. *J Neurol Neurosurg Psychiatry* 83:152–158
- Andrade C (1952) A peculiar form of peripheral neuropathy; familiar atypical generalized amyloidosis with special involvement of the peripheral nerves. *Brain* 75:408–427
- Rowczenio DM, Noor I, Gillmore JD, Lachmann HJ, Whelan C, Hawkins PN, Obici L, Westermarck P, Grateau G, Wechalekar AD (2014) Online registry for mutations in hereditary amyloidosis including nomenclature recommendations. *Hum Mutat* 35:E2403–2412
- Maurer MS, Bokhari S, Damy T, Dorbala S, Drachman BM, Fontana M, Grogan M, Kristen AV, Lousada I, Nativi-Nicolau J, Cristina Quarta C, Rapezzi C, Ruberg FL, Witteles R, Merlini G (2019) Expert consensus recommendations for the suspicion and diagnosis of transthyretin cardiac amyloidosis. *Circ Heart Fail* 12:e006075
- Adams D, Cauquil C, Labeyrie C, Beaudonnet G, Algalarrondo V, Theaudin M (2016) TTR kinetic stabilizers and TTR gene silencing: a new era in therapy for familial amyloidotic polyneuropathies. *Expert Opin Pharmacother* 17:791–802
- Adams D, Lozeron P, Lacroix C (2012) Amyloid neuropathies. *Curr Opin Neurol* 25:564–572
- Plante-Bordeneuve V, Carayol J, Ferreira A, Adams D, Clerget-Darpoux F, Misrahi M, Said G, Bonaiti-Pellie C (2003) Genetic study of transthyretin amyloid neuropathies: carrier risks among French and Portuguese families. *J Med Genet* 40:e120
- Hellman U, Alarcon F, Lundgren HE, Suhr OB, Bonaiti-Pellie C, Plante-Bordeneuve V (2008) Heterogeneity of penetrance in familial amyloid polyneuropathy, ATTR Val30Met, in the Swedish population. *Amyloid* 15:181–186
- Adams D, Beaudonnet G, Adam C, Lacroix C, Theaudin M, Cauquil C, Labeyrie C (2016) Familial amyloid polyneuropathy: when does it stop to be asymptomatic and need a treatment? *Rev Neurol (Paris)* 172:645–652
- Coelho T, Vinik A, Vinik EJ, Tripp T, Packman J, Grogan DR (2017) Clinical measures in transthyretin familial amyloid polyneuropathy. *Muscle Nerve* 55:323–332
- Adams D (2013) Recent advances in the treatment of familial amyloid polyneuropathy. *Ther Adv Neurol Disord* 6:129–139
- Koike H, Misu K, Ikeda S, Ando Y, Nakazato M, Ando E, Yamamoto M, Hattori N, Sobue G (2002) Type I (transthyretin Met30) familial amyloid polyneuropathy in Japan: early- vs late-onset form. *Arch Neurol* 59:1771–1776
- Hornsten R, Pennlert J, Wiklund U, Lindqvist P, Jensen SM, Suhr OB (2010) Heart complications in familial transthyretin amyloidosis: impact of age and gender. *Amyloid* 17:63–68
- Olsson M, Norgren N, Obayashi K, Plante-Bordeneuve V, Suhr OB, Cederquist K, Jonasson J (2010) A possible role for miRNA silencing in disease phenotype variation in Swedish transthyretin V30M carriers. *BMC Med Genet* 11:130
- Yamashita T, Ueda M, Misumi Y, Masuda T, Nomura T, Tasaki M, Takamatsu K, Sasada K, Obayashi K, Matsui H, Ando Y (2018) Genetic and clinical characteristics of hereditary transthyretin amyloidosis in endemic and non-endemic areas: experience from a single-referral center in Japan. *J Neurol* 265:134–140
- Ihse E, Ybo A, Suhr OB, Lindqvist P, Backman C (2008) Amyloid fibril composition is related to the phenotype of hereditary transthyretin V30M amyloidosis. *J Pathol* 216:253–261
- Adams D, Lozeron P, Theaudin M, Mincheva Z, Cauquil C, Adam C, Signate A, Vial C, Maisonobe T, Delmont E, Franques J, Vallat JM, Sole G, Pereon Y, Lacour A, Echaniz-Laguna A, Misrahi M, Lacroix C (2012) Regional difference and similarity of familial amyloidosis with polyneuropathy in France. *Amyloid* 19(Suppl 1):61–64

25. Cortese A, Vegezzi E, Lozza A, Alfonsi E, Montini A, Moglia A, Merlini G, Obici L (2017) Diagnostic challenges in hereditary transthyretin amyloidosis with polyneuropathy: avoiding misdiagnosis of a treatable hereditary neuropathy. *J Neurol Neurosurg Psychiatry* 88:457–458
26. Lozeron P, Mariani LL, Dodet P, Beaudonnet G, Theaudin M, Adam C, Arnulf B, Adams D (2018) Transthyretin amyloid polyneuropathies mimicking a demyelinating polyneuropathy. *Neurology* 91:e143–e152
27. Theaudin M, Lozeron P, Algalarrondo V, Lacroix C, Cauquil C, Labeyrie C, Slama MS, Adam C, Guiochon-Mantel A, Adams D, French FAPNSG (2019) Upper limb onset of hereditary transthyretin amyloidosis is common in non-endemic areas. *Eur J Neurol* 26:497–e436
28. Cappellari M, Cavallaro T, Ferrarini M, Cabrini I, Taioli F, Ferrari S, Merlini G, Obici L, Briani C, Fabrizi GM (2011) Variable presentations of TTR-related familial amyloid polyneuropathy in seventeen patients. *J Peripher Nerv Syst* 16:119–129
29. Goyal NA, Mozaffar T (2015) Tongue atrophy and fasciculations in transthyretin familial amyloid neuropathy: An ALS mimicker. *Neurol Genet* 1:e18
30. Koike H, Hashimoto R, Tomita M, Kawagashira Y, Iijima M, Tanaka F, Sobue G (2011) Diagnosis of sporadic transthyretin Val30Met familial amyloid polyneuropathy: a practical analysis. *Amyloid* 18:53–62
31. Mathis S, Magy L, Diallo L, Boukhris S, Vallat JM (2012) Amyloid neuropathy mimicking chronic inflammatory demyelinating polyneuropathy. *Muscle Nerve* 45:26–31
32. Lozeron P, Lacroix C, Theaudin M, Richer A, Gugenheim M, Adams D, Misrahi M (2013) An amyotrophic lateral sclerosis-like syndrome revealing an amyloid polyneuropathy associated with a novel transthyretin mutation. *Amyloid* 20:188–192
33. Arpa Gutierrez J, Morales C, Lara M, Munoz C, Garcia-Rojo M, Caminero A, Gutierrez M (1993) Type I familial amyloid polyneuropathy and pontine haemorrhage. *Acta Neuropathol* 86:542–545
34. Bersano A, Del Bo R, Ballabio E, Cinnante C, Lanfranconi S, Comi GP, Baron P, Bresolin N, Candelise L (2009) Transthyretin Asn90 variant: amyloidogenic or non-amyloidogenic role. *J Neurol Sci* 284:113–115
35. Sakashita N, Ando Y, Jinnouchi K, Yoshimatsu M, Terazaki H, Obayashi K, Takeya M (2001) Familial amyloidotic polyneuropathy (ATTR Val30Met) with widespread cerebral amyloid angiopathy and lethal cerebral hemorrhage. *Pathol Int* 51:476–480
36. Salvi F, Pastorelli F, Plasmati R, Morelli C, Rapezzi C, Bianchi A, Mascalchi M (2015) Brain microbleeds 12 years after orthotopic liver transplantation in Val30Met amyloidosis. *J Stroke Cerebrovasc Dis* 24:e149–151
37. Benson MD (1996) Leptomeningeal amyloid and variant transthyretins. *Am J Pathol* 148:351–354
38. Vidal R, Garzuly F, Budka H, Lalowski M, Linke RP, Brittig F, Frangione B, Wisniewski T (1996) Meningocerebrovascular amyloidosis associated with a novel transthyretin mis-sense mutation at codon 18 (TTRD 18G). *Am J Pathol* 148:361–366
39. Yamashita T, Ando Y, Okamoto S, Misumi Y, Hirahara T, Ueda M, Obayashi K, Nakamura M, Jono H, Shono M, Asonuma K, Inomata Y, Uchino M (2012) Long-term survival after liver transplantation in patients with familial amyloid polyneuropathy. *Neurology* 78:637–643
40. Ikeda SI (2013) Cerebral amyloid angiopathy with familial transthyretin-derived oculoleptomeningeal amyloidosis. *Brain Nerve* 65:831–842
41. Conceicao I, Gonzalez-Duarte A, Obici L, Schmidt HH, Simoneau D, Ong ML, Amass L (2016) "Red-flag" symptom clusters in transthyretin familial amyloid polyneuropathy. *J Peripher Nerv Syst* 21:5–9
42. Carvalho A, Rocha A, Lobato L (2015) Liver transplantation in transthyretin amyloidosis: issues and challenges. *Liver Transpl* 21:282–292
43. Fine NM, Arruda-Olson AM, Dispenzieri A, Zeldenrust SR, Gertz MA, Kyle RA, Swiecicki PL, Scott CG, Grogan M (2014) Yield of noncardiac biopsy for the diagnosis of transthyretin cardiac amyloidosis. *Am J Cardiol* 113:1723–1727
44. Gillmore JD, Maurer MS, Falk RH, Merlini G, Damy T, Dispenzieri A, Wechalekar AD, Berk JL, Quarta CC, Grogan M, Lachmann HJ, Bokhari S, Castano A, Dorbala S, Johnson GB, Glaudemans AW, Rezk T, Fontana M, Palladini G, Milani P, Guidalotti PL, Flatman K, Lane T, Vonberg FW, Whelan CJ, Moon JC, Ruberg FL, Miller EJ, Hutt DF, Hazenberg BP, Rapezzi C, Hawkins PN (2016) Nonbiopsy diagnosis of cardiac transthyretin amyloidosis. *Circulation* 133:2404–2412
45. Rapezzi C, Quarta CC, Guidalotti PL, Pettinato C, Fanti S, Leone O, Ferlini A, Longhi S, Lorenzini M, Reggiani LB, Gagliardi C, Gallo P, Villani C, Salvi F (2011) Role of (99m)Tc-DPD scintigraphy in diagnosis and prognosis of hereditary transthyretin-related cardiac amyloidosis. *JACC Cardiovasc Imag* 4:659–670
46. Luigetti M, Conte A, Del Grande A, Bisogni G, Madia F, Lo Monaco M, Laurenti L, Obici L, Merlini G, Sabatelli M (2013) TTR-related amyloid neuropathy: clinical, electrophysiological and pathological findings in 15 unrelated patients. *Neurol Sci* 34:1057–1063
47. Plante-Bordeneuve V, Ferreira A, Lalu T, Zarus C, Lacroix C, Adams D, Said G (2007) Diagnostic pitfalls in sporadic transthyretin familial amyloid polyneuropathy (TTR-FAP). *Neurology* 69:693–698
48. Do Amaral B, Coelho T, Sousa A, Guimaraes A (2009) Usefulness of labial salivary gland biopsy in familial amyloid polyneuropathy Portuguese type. *Amyloid* 16:232–238
49. Ebenezer GJ, Liu Y, Judge DP, Cunningham K, Truelove S, Carter ND, Sebastian B, Byrnes K, Polydefkis M (2017) Cutaneous nerve biomarkers in transthyretin familial amyloid polyneuropathy. *Ann Neurol* 82:44–56
50. Chao CC, Hsueh HW, Kan HW, Liao CH, Jiang HH, Chiang H, Lin WM, Yeh TY, Lin YH, Cheng YY, Hsieh ST (2019) Skin nerve pathology: biomarkers of premanifest and manifest amyloid neuropathy. *Ann Neurol* 85:560–573
51. Dohrn MF, Rocken C, De Bleecker JL, Martin JJ, Vorgerd M, Van den Bergh PY, Ferbert A, Hinderhofer K, Schroder JM, Weis J, Schulz JB, Claeys KG (2013) Diagnostic hallmarks and pitfalls in late-onset progressive transthyretin-related amyloid-neuropathy. *J Neurol* 260:3093–3108
52. Wixner J, Mundayat R, Karayal ON, Anan I, Karling P, Suhr OB (2014) THAOS: gastrointestinal manifestations of transthyretin amyloidosis - common complications of a rare disease. *Orphanet J Rare Dis* 9:61
53. Steen L, Ek B (1983) Familial amyloidosis with polyneuropathy. A long-term follow-up of 21 patients with special reference to gastrointestinal symptoms. *Acta Med Scand* 214:387–397
54. Suhr O, Danielsson A, Holmgren G, Steen L (1994) Malnutrition and gastrointestinal dysfunction as prognostic factors for survival in familial amyloidotic polyneuropathy. *J Intern Med* 235:479–485
55. Andersson R (1976) Familial amyloidosis with polyneuropathy. A clinical study based on patients living in northern Sweden. *Acta Med Scand Suppl* 590:1–64
56. Bechiri MY, Eliahou L, Rouzet F, Fouret PJ, Antonini T, Samuel D, Adam R, Adams D, Slama MS, Algalarrondo V (2016) Multimodality imaging of cardiac transthyretin amyloidosis 16 years after a domino liver transplantation. *Am J Transplant* 16:2208–2212
57. Ando E, Ando Y, Okamura R, Uchino M, Ando M, Negi A (1997) Ocular manifestations of familial amyloidotic polyneuropathy type I: long-term follow up. *Br J Ophthalmol* 81:295–298

58. Liu T, Zhang B, Jin X, Wang W, Lee J, Li J, Yuan H, Cheng X (2014) Ophthalmic manifestations in a Chinese family with familial amyloid polyneuropathy due to a TTR Gly83Arg mutation. *Eye* 28:26–33
59. Beirao JM, Malheiro J, Lemos C, Beirao I, Costa P, Torres P (2015) Ophthalmological manifestations in hereditary transthyretin (ATTR V30M) carriers: a review of 513 cases. *Amyloid* 22:117–122
60. Martins AC, Rosa AM, Costa E, Tavares C, Quadrado MJ, Murta JN (2015) Ocular manifestations and therapeutic options in patients with familial amyloid polyneuropathy: a systematic review. *BioMed Res Int* 2015:282405
61. Dyck PJ, Davies JL, Litchy WJ, O'Brien PC (1997) Longitudinal assessment of diabetic polyneuropathy using a composite score in the Rochester Diabetic Neuropathy Study cohort. *Neurology* 49:229–239
62. Denier C, Ducot B, Husson H, Lozeron P, Adams D, Meyer L, Said G, Planté-Bordeneuve V (2007) A brief compound test for assessment of autonomic and sensory-motor dysfunction in familial amyloid polyneuropathy. *J Neurol* 254:1684–1688
63. Pruppers MHJ, Merkies ISJ, Faber CG, Da Silva AM, Costa V, Coelho T (2015) The Val30Met familial amyloid polyneuropathy specific Rasch-built overall disability scale (FAP-RODS©). *J Peripher Nerv Syst* 20:319–327
64. Sletten DM, Suarez GA, Low PA, Mandrekar J, Singer W (2012) COMPASS 31: a refined and abbreviated Composite Autonomic Symptom Score. *Mayo Clin Proc* 87:1196–1201
65. Gillmore JD, Damy T, Fontana M, Hutchinson M, Lachmann HJ, Martinez-Naharro A, Quarta CC, Rezk T, Whelan CJ, Gonzalez-Lopez E, Lane T, Gilbertson JA, Rowczenio D, Petrie A, Hawkins PN (2018) A new staging system for cardiac transthyretin amyloidosis. *Eur Heart J* 39:2799–2806
66. Vinik EJ, Vinik AI, Paulson JF, Merkies IS, Packman J, Grogan DR, Coelho T (2014) Norfolk QOL-DN: validation of a patient reported outcome measure in transthyretin familial amyloid polyneuropathy. *J Peripher Nerv Syst* 19:104–114
67. Ware JE Jr, Sherbourne CD (1992) The MOS 36-item short-form health survey (SF-36). I. Conceptual framework and item selection. *Med Care* 30:473–483
68. Vita GL, Stancanelli C, Gentile L, Barcellona C, Russo M, Bella GD, Vita G, Mazzeo A (2018) 6MWT performance correlates with peripheral neuropathy but not with cardiac involvement in patients with hereditary transthyretin amyloidosis (hATTR). *Neuromuscul Disord* 29(3):213–220
69. Tashima K, Ando Y, Terazaki H, Yoshimatsu S-i, Suhr OB, Obayashi K, Yamashita T, Ando E, Uchino M, Ando M (1999) Outcome of liver transplantation for transthyretin amyloidosis: follow-up of Japanese familial amyloidotic polyneuropathy patients. *J Neurol Sci* 171:19–23
70. Dyck PJ, Kincaid JC, Dyck PJB, Chaudhry V, Goyal NA, Alves C, Salhi H, Wiesman JF, Labeyrie C, Robinson-Papp J, Cardoso M, Laura M, Ruzhansky K, Cortese A, Brannagan TH 3rd, Khoury J, Khella S, Waddington-Cruz M, Ferreira J, Wang AK, Pinto MV, Ayache SS, Benson MD, Berk JL, Coelho T, Polydefkis M, Gorevic P, Adams DH, Plante-Bordeneuve V, Whelan C, Merlini G, Heitner S, Drachman BM, Conceicao I, Klein CJ, Gertz MA, Ackermann EJ, Hughes SG, Mauermann ML, Bergemann R, Lodermeier KA, Davies JL, Carter RE, Litchy WJ (2017) Assessing mNIS+7Ionis and international neurologists' proficiency in a familial amyloidotic polyneuropathy trial. *Muscle Nerve* 56:901–911
71. Adams D, Cauquil C, Labeyrie C (2017) Familial amyloid polyneuropathy. *Curr Opin Neurol* 30:481–489
72. Mariani LL, Lozeron P, Theaudin M, Mincheva Z, Signate A, Ducot B, Algalarrondo V, Denier C, Adam C, Nicolas G, Samuel D, Slama MS, Lacroix C, Misrahi M, Adams D (2015) Genotype-phenotype correlation and course of transthyretin familial amyloid polyneuropathies in France. *Ann Neurol* 78:901–916
73. Adams D, Gonzalez-Duarte A, O'Riordan WD, Yang CC, Ueda M, Kristen AV, Tournev I, Schmidt HH, Coelho T, Berk JL, Lin KP, Vita G, Attarian S, Plante-Bordeneuve V, Mezei MM, Campistol JM, Buades J, Brannagan TH 3rd, Kim BJ, Oh J, Parman Y, Sekijima Y, Hawkins PN, Solomon SD, Polydefkis M, Dyck PJ, Gandhi PJ, Goyal S, Chen J, Strahs AL, Nochur SV, Sweetser MT, Garg PP, Vaishnav AK, Gollob JA, Suhr OB (2018) Patisiran, an RNAi therapeutic, for hereditary transthyretin amyloidosis. *N Engl J Med* 379:11–21
74. Benson MD, Waddington-Cruz M, Berk JL, Polydefkis M, Dyck PJ, Wang AK, Plante-Bordeneuve V, Barroso FA, Merlini G, Obici L, Scheinberg M, Brannagan TH 3rd, Litchy WJ, Whelan C, Drachman BM, Adams D, Heitner SB, Conceicao I, Schmidt HH, Vita G, Campistol JM, Gamez J, Gorevic PD, Gane E, Shah AM, Solomon SD, Monia BP, Hughes SG, Kwok TJ, McEvoy BW, Jung SW, Baker BF, Ackermann EJ, Gertz MA, Coelho T (2018) Inotersen treatment for patients with hereditary transthyretin amyloidosis. *N Engl J Med* 379:22–31
75. Obici L, Kuks JB, Buades J, Adams D, Suhr OB, Coelho T, Kyriakides T, European Network for T-F (2016) Recommendations for presymptomatic genetic testing and management of individuals at risk for hereditary transthyretin amyloidosis. *Curr Opin Neurol* 29(Suppl 1):S27–S35
76. Theaudin M, Cauquil C, Antonini T, Algalarrondo V, Labeyrie C, Aycaguer S, Clement M, Kubezyk M, Nonnez G, Morier A, Bourges C, Darras A, Mouzat L, Adams D (2014) Familial amyloid polyneuropathy: elaboration of a therapeutic patient education programme, "EdAmyl". *Amyloid* 21:225–230
77. Dardiotis E, Koutsou P, Papanicolaou EZ, Vonta I, Kladi A, Vassilopoulos D, Hadjigeorgiou G, Christodoulou K, Kyriakides T (2009) Epidemiological, clinical and genetic study of familial amyloidotic polyneuropathy in Cyprus. *Amyloid* 16:32–37
78. van Gameren II, Hazenberg BP, Bijzet J, van Rijswijk MH (2006) Diagnostic accuracy of subcutaneous abdominal fat tissue aspiration for detecting systemic amyloidosis and its utility in clinical practice. *Arthritis Rheum* 54:2015–2021
79. Lobato L, Beirao I, Guimaraes SM, Droz D, Guimaraes S, Grunfeld JP, Noel LH (1998) Familial amyloid polyneuropathy type I (Portuguese): distribution and characterization of renal amyloid deposits. *Am J Kidney Dis* 31:940–946
80. Lobato L, Beirao I, Silva M, Bravo F, Silvestre F, Guimaraes S, Sousa A, Noel LH, Sequeiros J (2003) Familial ATTR amyloidosis: microalbuminuria as a predictor of symptomatic disease and clinical nephropathy. *Nephrol Dial Transplant* 18:532–538
81. Oguchi K, Takei Y, Ikeda S (2006) Value of renal biopsy in the prognosis of liver transplantation in familial amyloid polyneuropathy ATTR Val30Met patients. *Amyloid* 13:99–107
82. Snanoudj R, Durrbach A, Gauthier E, Adams D, Samuel D, Ferlicot S, Bedossa P, Prigent A, Bismuth H, Charpentier B (2004) Changes in renal function in patients with familial amyloid polyneuropathy treated with orthotopic liver transplantation. *Nephrol Dial Transplant* 19:1779–1785
83. Ando Y, Coelho T, Berk JL, Cruz MW, Ericzon BG, Ikeda S, Lewis WD, Obici L, Plante-Bordeneuve V, Rapezzi C, Said G, Salvi F (2013) Guideline of transthyretin-related hereditary amyloidosis for clinicians. *Orphanet J Rare Dis* 8:31
84. Klein CJ, Vrana JA, Theis JD, Dyck PJ, Dyck PJ, Spinner RJ, Mauermann ML, Bergen HR 3rd, Zeldenrust SR, Dogan A (2011) Mass spectrometric-based proteomic analysis of amyloid neuropathy type in nerve tissue. *Arch Neurol* 68:195–199
85. Adams D, Suhr OB, Hund E, Obici L, Tournev I, Campistol JM, Slama MS, Hazenberg BP, Coelho T, European Network for T-F (2016) First European consensus for diagnosis, management, and

- treatment of transthyretin familial amyloid polyneuropathy. *Curr Opin Neurol* 29(Suppl 1):S14–S26
86. van Nes SI, Vanhoutte EK, van Doorn PA, Hermans M, Bakkers M, Kuitwaard K, Faber CG, Merkies IS (2011) Rasch-built Overall Disability Scale (R-ODS) for immune-mediated peripheral neuropathies. *Neurology* 76:337–345
87. Piekarski E, Chequer R, Algalarrondo V, Eliahou L, Mahida B, Vigne J, Adams D, Slama MS, Le Guludec D, Rouzet F (2018) Cardiac denervation evidenced by MIBG occurs earlier than amyloid deposits detection by diphosphonate scintigraphy in TTR mutation carriers. *Eur J Nucl Med Mol Imaging* 45:1108–1118
88. Yamamoto S, Wilczek HE, Nowak G, Larsson M, Oksanen A, Iwata T, Gjertsen H, Soderdahl G, Wikstrom L, Ando Y, Suhr OB, Ericzon BG (2007) Liver transplantation for familial amyloidotic polyneuropathy (FAP): a single-center experience over 16 years. *Am J Transplant* 7:2597–2604