

Annual renal ultrasound may prevent acute presentation with acetazolamide-associated urolithiasis

Karen J. Suetterlin, MRCP, Vinojini Vivekanandam, FRACP, Natalie James, BSc (Hons), Richa Sud, PhD, Sarah Holmes, MSc, Doreen Fialho, MRCP, Michael G. Hanna, FRCP, and Emma L. Matthews, MRCP

Neurology: Clinical Practice October 2019 vol. 00 no. 00 1-3 doi:10.1212/CPJ.0000000000000761

Correspondence

Dr. Matthews
emma.matthews@ucl.ac.uk

Acetazolamide is used as first-line treatment for many neurologic channelopathies and as add-on therapy for other conditions such as epilepsy, idiopathic intracranial hypertension, and migraine. There is no randomized controlled trial evidence of its efficacy in genetically confirmed muscle channelopathies.^{1,2}

Most adverse events associated with acetazolamide therapy are considered benign or tolerable, but fatal agranulocytosis, aplastic anemia, and an increased incidence of renal calculi have been reported.^{3,4} Despite this, routine ultrasound monitoring for the development of renal calculi is often not performed.

We reviewed records of all patients prescribed acetazolamide by our national channelopathy service between 2011 and 2018 as part of a service evaluation approved by our hospital audit committee. Patients with a genetically confirmed channelopathy who had been prescribed acetazolamide and had at least 1 posttreatment clinic appointment were included (minimum follow-up period of 6 months). Acetazolamide efficacy was determined by patient report of reduced frequency, duration, or severity of symptoms. Adverse effects were clinician, investigation, or patient-reported events that occurred while taking acetazolamide and not clearly attributable to an alternative cause.

Fifty-eight patients with genetically confirmed channelopathy were included. All but one of these took the immediate release formulation. The self-reported efficacy rate for acetazolamide varied with genetic diagnosis (figure, A).

Paresthesia was the most frequent side effect (24%) but was generally well tolerated unless it affected the face. Paresthesia occurred at doses as low as 125 mg. No blood dyscrasias occurred. Seven patients (12%) developed renal calculi while taking acetazolamide. There was no correlation between dose or duration of acetazolamide therapy and urolithiasis ($p = 0.6$ and $p = 0.8$, respectively, Student t test with Welch correction).

Six of the 7 renal calculi were detected on routine ultrasound monitoring. Four of these 6 eventually required elective lithotripsy, 1 required monitoring without intervention, and for 1, it was not known. The seventh patient required emergency lithotripsy when she presented to the emergency department in extremis with acute ureteric obstruction. This patient had not had the recommended yearly renal ultrasounds.

PRACTICAL IMPLICATIONS

Annual renal ultrasound may prevent acute presentation with ureteric obstruction from acetazolamide-induced renal calculi.

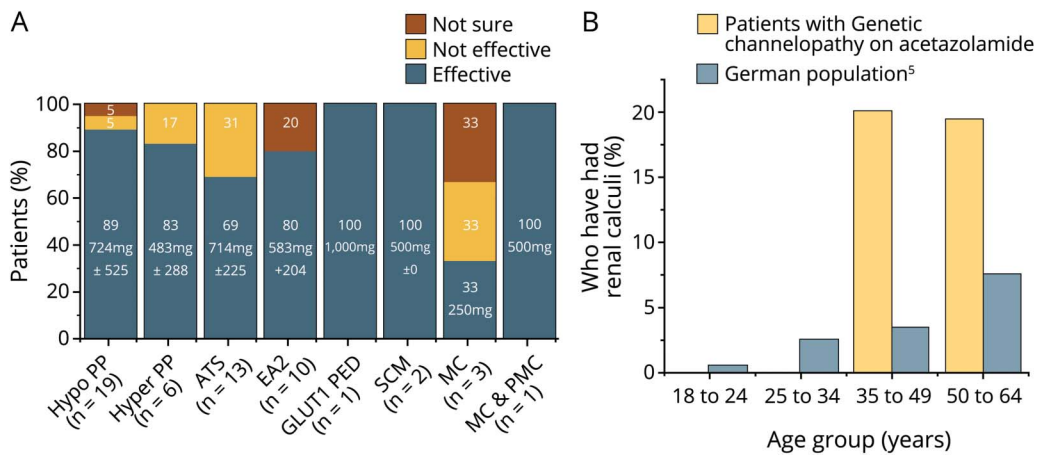
MRC Centre for Neuromuscular Diseases (KJS, VV, NJ, SH, DF, MGH, ELM), Queen Square Institute of Neurology, UCL and National Hospital for Neurology and Neurosurgery; and Neurogenetics Unit (RS), National Hospital for Neurology and Neurosurgery, Queen Square, London, UK.

Funding information and disclosures are provided at the end of the article. Full disclosure form information provided by the authors is available with the full text of this article at Neurology.org/cp.

The Article Processing Charge was funded by Wellcome Trust.

This is an open access article distributed under the terms of the Creative Commons Attribution License 4.0 (CC BY), which permits unrestricted use, distribution, and reproduction in any medium, provided the original work is properly cited.

Figure Safety and efficacy of acetazolamide in genetic channelopathies



(A) Patient-reported acetazolamide efficacy by genetic diagnosis. Mean effective dose of acetazolamide and number of patients with efficacy data are also given for each genetic diagnosis. (B) Prevalence of renal stones in patients with genetic channelopathy taking acetazolamide compared with published data looking at the population prevalence of renal stones in a comparable European country (Germany in 2001). In the German study, a representative sample of the German population (7,500 people) was questioned on the incidence of renal stones during their life time. As in our cohort of patients with channelopathy, some of the renal stones reported in this group had been asymptomatic and identified as a result of medical imaging. The incidence of renal stones found in our patients with genetic channelopathy on acetazolamide is given in brackets for each age group. ATS = Andersen-Tawil syndrome, EA2 = episodic ataxia type 2, GLUT1 PED = paroxysmal exertion-induced dyskinesia, SCM = sodium channel myotonia, MC = myotonia congenita, PMC = paramyotonia congenita; Hyper PP = hyperkalaemic periodic paralysis; Hypo PP = hypokalaemic periodic paralysis.

Seventy percent of patients with acetazolamide-associated renal calculi chose to continue acetazolamide under urology supervision, as it was the only effective treatment for their channelopathy. This was despite 60% of them developing further calculi and requiring repeat lithotripsy.

Discussion

The prevalence of renal calculi was increased between 4- and 7-fold in patients with channelopathy older than 35 years treated with acetazolamide compared with the general population (figure, B).⁵ This was irrespective of the dose or duration of treatment.

As the vast majority (90%) of monitoring ultrasounds were performed locally and results communicated to us, we cannot be certain that every patient had the recommended annual ultrasound. Nevertheless, patients who did had their renal stones diagnosed before ureteric obstruction could occur allowing for elective lithotripsy when needed. In contrast, 1 patient who did not have the recommended monitoring presented acutely with complications requiring emergency intervention.

Note was also made of 1 patient receiving acetazolamide but not included in the selection criteria (genetically unconfirmed). This patient also presented with urolithiasis causing ureteric obstruction and acute renal failure after failing to receive monitoring scans. The severity of their presentation was increased by previously unidentified renal agenesis. Renal agenesis in the general population is common, 1 in 1,000.⁶ This suggests that a baseline scan before

commencing acetazolamide is warranted, as acetazolamide's complications may be further exacerbated in those with congenital abnormalities.

This study demonstrates that acetazolamide can be effective for Andersen-Tawil syndrome. The patient-reported efficacy rate for episodic ataxia type 2 (80%) and hyperkalaemic periodic paralysis (83%) is in keeping with that published previously.^{1,2} The efficacy rate for hyperkalaemic periodic paralysis (89%) was higher than previous reports.^{1,7} This is potentially because all patients had arginine to histidine genetic mutations predicted to be the most acetazolamide responsive.⁷

Although this is a retrospective study and comes with the associated limitations, in the absence of randomized controlled trial data, our clinical experience of efficacy, monitoring, and safety data provide a useful resource to help counsel patients before treatment of genetic channelopathies. In addition, our monitoring and safety findings have important implications for any neurologist prescribing acetazolamide, e.g., for epilepsy, migraine, or idiopathic intracranial hypertension, as treatment-associated renal stones are not specific to channelopathies.^{3,4}

In summary, our study suggests that regular ultrasound monitoring may reduce acute presentation with ureteric obstruction from acetazolamide-induced urolithiasis. A prospective study with a control group is required to confirm this. However, in the absence of such a study, we suggest that a baseline scan be performed before commencing acetazolamide therapy and annual ultrasound monitoring continues for the duration of treatment.

Acknowledgment

The authors thank Dr Sheetal Sumaria (pharmacist at the National Hospital for Neurology and Neurosurgery, London, UK) for her help in generating the list of patients who had been prescribed acetazolamide by the NHNN pharmacy.

Study funding

Part of this work was undertaken at University College London Hospitals/University College London, which received a proportion of funding from the Department of Health's National Institute for Health Research Biomedical Research Centre's funding scheme. This work was supported by Medical Research Council Centre grant 512225 and the UCLH Biomedical Research Centre. University College London's National Muscle Channelopathy Service is supported by National Health Service England specialist commissioning (cnmd.ac.uk). K.J. Suetterlin is funded by an MRC Clinical Research Training Fellowship. E.L. Matthews is supported by a Wellcome Trust Clinical Research Career Development Fellowship. M.G. Hanna is supported by a Medical Research Council Centre grant (S12225), the UCLH Biomedical Research Centre, the National Centre for Research Resources, and the National Highly Specialised Service (HSS) Department of Health UK. D. Fialho is supported by the HSS Department of Health UK.

Disclosure

The authors report no disclosures relevant to the manuscript. Full disclosure form information provided by the authors is available with the full text of this article at Neurology.org/cp.

Publication history

Received by *Neurology: Clinical Practice* June 24, 2019. Accepted in final form October 7, 2019.

Appendix Authors

Name	Location	Role	Contribution
Karen J. Suetterlin, MRCP	Queen Square Institute of Neurology, UCL and National Hospital for Neurology and Neurosurgery, London, UK	Author	Drafting/revising the manuscript, data acquisition, study concept or design, analysis or interpretation of data, statistical analysis, and study supervision
Vinojini Vivekanandam, FRACP	Queen Square Institute of Neurology, UCL and National Hospital for Neurology and Neurosurgery, London, UK	Author	Drafting/revising the manuscript and data acquisition
Natalie James, BSc (Hons)	Queen Square Institute of Neurology, UCL and National Hospital for Neurology and Neurosurgery, London, UK	Author	Data acquisition

Appendix (continued)

Name	Location	Role	Contribution
Richa Sud, PhD	National Hospital for Neurology and Neurosurgery, Queen Square, London, UK	Author	Drafting/revising the manuscript and acquisition of data
Sarah Holmes, MSc	Queen Square Institute of Neurology, UCL and National Hospital for Neurology and Neurosurgery, London, UK	Author	Drafting/revising the manuscript and data acquisition
Doreen Fialho, MRCP	Queen Square Institute of Neurology, UCL and National Hospital for Neurology and Neurosurgery, London, UK	Author	Drafting/revising the manuscript, study concept or design, and analysis or interpretation of data
Michael G. Hanna, FRCP	Queen Square Institute of Neurology, UCL and National Hospital for Neurology and Neurosurgery, London, UK	Author	Study concept or design, analysis or interpretation of data, acquisition of data, and study supervision
Emma L. Matthews, MRCP	Queen Square Institute of Neurology, UCL and National Hospital for Neurology and Neurosurgery, London, UK	Author	Drafting/revising the manuscript, data acquisition, study concept or design, analysis or interpretation of data, and study supervision, and accepts responsibility for conduct of research and will give final approval

References

1. Sansone V, Meola G, Links TP, Panzeri M, Rose MR. Treatment for periodic paralysis. *Cochrane Database Syst Rev* 2008;CD005045.
2. Strupp M, Zwergal A, Brandt T. Episodic ataxia type 2. *Neurotherapeutics* 2007;4:267–273.
3. Resor SR, Resor LD. Chronic acetazolamide monotherapy in the treatment of juvenile myoclonic epilepsy. *Neurology* 1990;40:1677–1681.
4. Effect of acetazolamide on visual function in patients with idiopathic intracranial hypertension and mild visual loss. *JAMA* 2014;311:1641–1651.
5. Hesse A, Brändle E, Wilbert D, Köhrmann KU, Alken P. Study on the prevalence and incidence of urolithiasis in Germany comparing the years 1979 vs. 2000. *Eur Urol* 2003;44:709–713.
6. Shapiro E, Goldfarb DA, Ritchey ML. The congenital and acquired solitary kidney. *Rev Urol* 2003;5:2–8.
7. Matthews E, Portaro S, Ke Q, et al. Acetazolamide efficacy in hypokalemic periodic paralysis and the predictive role of genotype. *Neurology* 2011;77:1960–1964.

Neurology® Clinical Practice

Annual renal ultrasound may prevent acute presentation with acetazolamide-associated urolithiasis

Karen J. Suetterlin, Vinojini Vivekanandam, Natalie James, et al.
Neurol Clin Pract published online October 29, 2019
DOI 10.1212/CPJ.0000000000000761

This information is current as of October 29, 2019

Updated Information & Services	including high resolution figures, can be found at: http://cp.neurology.org/content/early/2019/10/29/CPJ.0000000000000761.full.html
Subspecialty Collections	This article, along with others on similar topics, appears in the following collection(s): All Clinical Neurology http://cp.neurology.org/cgi/collection/all_clinical_neurology Antiepileptic drugs http://cp.neurology.org/cgi/collection/antiepileptic_drugs Idiopathic intracranial hypertension http://cp.neurology.org/cgi/collection/idiopathic_intracranial_hypertension Ion channel gene defects http://cp.neurology.org/cgi/collection/ion_channel_gene_defects Muscle disease http://cp.neurology.org/cgi/collection/muscle_disease
Permissions & Licensing	Information about reproducing this article in parts (figures, tables) or in its entirety can be found online at: http://cp.neurology.org/misc/about.xhtml#permissions
Reprints	Information about ordering reprints can be found online: http://cp.neurology.org/misc/addir.xhtml#reprintsus

Neurol Clin Pract is an official journal of the American Academy of Neurology. Published continuously since 2011, it is now a bimonthly with 6 issues per year. Copyright © 2019 The Author(s). Published by Wolters Kluwer Health, Inc. on behalf of the American Academy of Neurology. All rights reserved. Print ISSN: 2163-0402. Online ISSN: 2163-0933.

