

Optical Coherence Tomography Findings After Childhood Lensectomy

Moritz C. Daniel,^{1,2} Adam M. Dubis,¹ Becky MacPhee,¹ Patricia Ibanez,¹ Gillian Adams,³ John Brookes,⁴ Maria Papadopoulos,⁴ Peng T. Khaw,^{1,4} Maria Theodorou,^{1,3} and Annegret H. Dahlmann-Noor^{1,3}

¹National Institute of Health Research Moorfields Biomedical Research Centre, London, United Kingdom

²Eye Center, Medical Center, Faculty of Medicine, University of Freiburg, Freiburg, Germany

³Paediatric Service, Moorfields Eye Hospital, London, United Kingdom

⁴Glaucoma Service, Moorfields Eye Hospital, London, United Kingdom

Correspondence: Annegret H. Dahlmann-Noor, National Institute of Health Research Moorfields Biomedical Research Centre, 162 City Road, London EC1V 2PD, United Kingdom; annegret.dahlmann-noor@nhs.net.

Submitted: February 20, 2019

Accepted: August 8, 2019

Citation: Daniel MC, Dubis AM, MacPhee B, et al. Optical coherence tomography findings after childhood lensectomy. *Invest Ophthalmol Vis Sci.* 2019;60:4388–4396. <https://doi.org/10.1167/iovs.19-26806>

PURPOSE. To explore the impact of childhood lensectomy on posterior segment development.

METHODS. Cross-sectional observational study at children's eye clinics at a tertiary referral center in London, UK. We included 45 children age 4 to 16 years with healthy eyes and 38 who had undergone lensectomy. We acquired posterior segment optical coherence tomography scans of both eyes. We used parametric and nonparametric tests in SPSS24 for the comparison of parameters between groups and within individuals; a *P* value less than 0.05 was considered significant. The main outcome measures were foveal pit depth and subfoveal choroidal thickness (CT). Secondary outcomes were inner and outer ring CT and photoreceptor layer parameters, macular and peripapillary retinal nerve fiber layer thickness.

RESULTS. Foveal pit depth and subfoveal CT are significantly reduced in eyes that have undergone lensectomy compared with nonoperated eyes. Inner ring CT and outer ring CT are reduced. Foveal inner retinal layer thickness is increased. Mean inner retinal and outer nuclear layer thickness are not affected.

CONCLUSIONS. Childhood lensectomy is associated with a reduction in developmental foveal pit deepening and lack of developmental thickening of the posterior choroid. Mechanical and optical disruption of foveal and subfoveal choroidal development may affect structural foveal development after childhood lensectomy.

Keywords: child, adolescent, congenital, hereditary and neonatal diseases and abnormalities, cataract

Cataract is now the leading cause of treatable blindness in children in some developing countries,^{1,2} and one of the three main leading causes worldwide.³ Early lensectomy can rescue visual development, but despite early intervention, visual outcomes are often poor: children who have undergone cataract surgery before 7 weeks of age often achieve a visual acuity approximately 0.50 logMAR only, and those who had cataract surgery after this age, 1.10 logMAR.⁴ Outcomes are worse in children with unilateral cataract, with a median acuity of 1.0 logMAR in unilateral versus 0.48 logMAR in bilateral cases.⁵

Several factors contribute to poor visual outcome. Lack of visual stimulation in the first weeks of life may cause an irreparable defect in the development of afferent and efferent pathways, reflected in poor acuity (amblyopia), poor fixation stability, and nystagmus.^{6,7} Post-lensectomy glaucoma and corneal thickening are additional significant factors.⁸

In children, removal of the crystalline lens may have a mechanical effect on ciliary muscle and choroidal dynamics and disrupt the feedback loops between retina/fovea, visual cortex, ciliary muscle and choroid required for normal visual development.

Little is known about the development of fovea and posterior choroid after lensectomy for childhood cataract.

One study reported normal macular structure, with central optical coherence tomography (OCT)-subfield thickening.⁹ The aim of this study was to test the hypothesis that lensectomy in children disrupts normal posterior segment development and is associated with an arrest in foveal and subfoveal choroidal development.

METHODS

This cross-sectional study was approved by the National Research Ethics Committee London - Stanmore (16/LO/0327). The study adhered to the tenets of the Declaration of Helsinki.

Participants

We included children aged 4 to 16 years with healthy eyes (visual acuity normal for age, normal IOP) and children who had undergone lensectomy, excluding those with other developmental eye defects, such as persistent fetal vasculature and optic nerve and/or retinal coloboma, and those unable to cooperate with the study procedures. We screened the notes of all children attending our pediatric clinics in advance to identify those who met the inclusion criteria. A research fellow (MCD)



approached families, provided age-appropriate written information material, and addressed any questions before obtaining written consent and assent. Between May 16, 2016, and April 27, 2017, we enrolled 45 children with healthy eyes and 40 who had undergone lensectomy.

We recorded age at study participation, sex, and ethnic background. We defined glaucoma as “diagnosis of glaucoma by the managing ophthalmologist and requiring sustained treatment with drops, laser, surgery, or a combination of these.” From the medical notes, we recorded age at lensectomy, surgical details of cataract surgery, presence/absence of glaucoma at last follow-up, presence of any wider developmental eye defect, refractive error and best-corrected visual acuity (BCVA) in both eyes. There were two bilateral and one unilateral case of “hand movements,” and two bilateral and one unilateral case of “perception of light” acuity; consistent with previous work, we converted these to 2.4 and 2.7 logMAR, respectively.¹⁰

Main Outcome Measures

The two principal outcome measures for this study were foveal pit depth and subfoveal choroidal thickness (CT). Secondary outcomes included other quantitative and qualitative parameters of retinal and choroidal morphology as described below.

Posterior Segment OCT (PS-OCT)

Before posterior segment image acquisition we instilled topical tropicamide 1% drops to dilate the pupil, unless the pupils had been dilated during the clinical appointment or dilation of the pupil was clinically contraindicated. Two pediatric imaging specialists (BM, PI) acquired images of both eyes of all children using the Heidelberg Spectralis OCT, software version 6.7.12.0 (Heidelberg Spectralis OCT; Heidelberg Engineering GmbH, Heidelberg, Germany). We took three images per eye: two images of the posterior pole (macular volume scan and enhanced depth imaging [EDI] scan, respectively) and one image of the optic nerve head including the peripapillary retina. We used standard settings for the macular volume scan (25 horizontal line scans, 20 × 20 degrees, Automatic Real-Time [ART] 9, 240 μm line distance). The settings for the EDI scan were as follows: 25 horizontal line scans, 20 × 20 degrees, 240 μm line distance, ART 25. The diameter of the peripapillary retinal nerve fiber layer (RNFL) scan was set at 12 degrees (circle scan, ART 100).

Retinal/Choroidal Layer Segmentation and Thickness Measurements

The retina was segmented automatically using Heidelberg Eye Explorer (Software Version 6.7.12.0). We exported the EDI scans (or the macular volume scan if the external border of the choroid was clearly visible and an EDI scan was not available) as AVI-files. We then performed an automated segmentation of the choroid using the Iowa Reference Algorithms, software version 4.0 beta (Retinal Image Analysis Lab, Iowa Institute for Biomedical Imaging, Iowa City, IA, USA). If necessary, two investigators (AD and MCD) corrected the segmentation manually. All thickness calculations were based on the standard Early Treatment Diabetic Retinopathy Study (ETDRS) grid (nine subfields) and the peripapillary seven-subfield grid (for peripapillary RNFL thickness, diameter 3.4 mm), respectively (Supplementary Fig. S1). We recorded the mean thicknesses of the following layers/retinal segments: retina, inner retinal layers, outer nuclear layer, macular RNFL, peripapillary RNFL and choroid. We summa-

rized the values for the ETDRS grid inner ring as the mean of subfields two, three, four, and five, and the outer ring as the mean of subfields six, seven, eight, and nine. Similarly, we summarized the superior sectors of the peripapillary grid as the mean of subfields one and six, and the inferior sectors as the mean of subfields three and four.

Additional Measurements of the Foveal Region and Qualitative Parameters

MCD measured the foveal pit depth by calculating the difference between the retinal layer thickness at the foveal center and the mean retinal thickness of the adjoining subfields. Using the caliper tool in Heidelberg Eye Explorer, we measured the distance from the center of the foveal pit to the inner border of the ellipsoid zone (EZ) as well as the distance from the outer border of the ellipsoid zone to Bruch's membrane (both measured in triplicate). Furthermore, we quantitatively and qualitatively described the foveal region using the following parameters: persistence of inner retinal layers at the foveal center, number of retinal layers at/below the foveal pit, presence of cystoid macular edema (within the foveal region and/or beyond).

Statistics

MCD entered data onto a spreadsheet in Excel (Microsoft, Redmond, WA, USA) and calculated the means of the triplicate measurements. Using SPSS24 (IBM, Armonk, NY, USA) we inspected the data distribution using Q-Q plots. Where data were normally distributed, we calculated cohort means and SDs; where data were not normally distributed, we calculated medians and interquartile range (IQR). We used the two-tailed independent samples *t*-test to compare means of measurements in healthy versus post-lensectomy eyes, and the two-tailed paired samples *t*-test for interocular, intra-individual analysis; statistical significance was set at the 5% level. Similarly, we used the Mann-Whitney *U* test to test differences between medians of nonparametric data. Presented here is the analysis of data from the right eye of healthy volunteers and bilateral lensectomy cases, and the operated eye of unilateral cases. Analysis of left eyes/unilateral cases is available as online supplement (Supplementary Tables S1-S3).

RESULTS

We enrolled 45 children with healthy eyes and 38 post-lensectomy (Supplementary Fig. S2). Table 1 summarizes demographic and clinical characteristics. There was no statistically significant difference between groups with regard to age ($P = 0.9$) and spherical equivalent in the study eye ($P = 0.35$). BCVA was significantly lower in eyes that had undergone lensectomy than in unoperated eyes. Post-lensectomy glaucoma affected 24 (42%) of 57 operated eyes (Table 1); of these, 14 had undergone glaucoma surgery.

Foveal Pit Depth and Subfoveal CT

Foveal pit depth and subfoveal CT are significantly reduced in eyes that have undergone lensectomy (Table 2). Figure 1 shows two typical cases of interocular differences in foveal appearance after unilateral lensectomy.

There is a significant association of foveal pit depth with age at lensectomy (Spearman's rho correlation coefficient SRCC 0.448, $P = 0.028$), but not with BCVA or spherical equivalent (SE) ($P = 0.108$ and $P = 0.955$, respectively). There was no

TABLE 1. Demographic and Clinical Participant Details

Characteristic	Healthy Volunteers		Unilateral Lensectomy		Bilateral Lensectomy	
	Right Eye	Left Eye	Operated Eye	Fellow Eye	Right Eye	Left Eye
<i>n</i>						
Sex, <i>n</i> female (%)	45	45	19	19	19	19
Mean age at participation, <i>y</i> (SD)	26 (6.4)	26 (6.4)	12 (6.3)	12 (6.3)	8 (4.2)	8 (4.2)
Ethnic background (<i>n</i> , %)	11.1 (3)	11.1 (3)	10.8 (3)	10.8 (3)	11.6 (3.7)	11.6 (3.7)
White	12 (26.7)	12 (26.7)	2 (10.5)	2 (10.5)	3 (16)	3 (16)
Asian/Asian British	10 (22.2)	10 (22.2)	1 (5.3)	1 (5.3)	1 (5)	1 (5)
Black/black British	6 (13.3)	6 (13.3)	2 (10.5)	2 (10.5)	3 (16)	3 (16)
Mixed	0	0	0	0	0	0
Other	3 (6.7)	3 (6.7)	2 (10.5)	2 (10.5)	3 (16)	3 (16)
Unknown	14 (31.1)	14 (31.1)	2 (10.5)	2 (10.5)	1 (5)	1 (5)
Median age at lensectomy, mo (IQR)			4 (1.3 to 52.1)	n/a	8 (1.5 to 36.7)	7.5 (1.25 to 33.2)
Median BCVA (IQR)	n/a	n/a	0.94 (0.72 to 1.55)	n/a	0.3 (0.20 to 0.4)	0.3 (0.16 to 1)
Median SE in Diopter (IQR)	0 (0 to 0.04)	0 (0 to 0.04)	0.25 (-0.75 to 1.69)	0 (-0.08 to 0.05)	3 (-1.28 to 1.1.65)	3.56 (-0.56 to 12.28)
Post-lensectomy glaucoma (<i>n</i> , %)	0.25 (-0.09 to 0.81)	0.19 (0 to 0.75)	7 (39)	n/a	8 (42)	9 (47)
Primary IOL implant (<i>n</i> , %)	n/a	n/a	14 (74)	n/a	8 (42)	6 (32)

n/a, not applicable.

significant association of subfoveal CT with any of these parameters.

Macular CT

Following lensectomy, CT is reduced in most subfields, including the summary fields of inner and outer ring and the mean of all subfields (Table 3).

Other Foveal Parameters

Mean distance from the center of the foveal pit to the inner border of the EZ and mean distance from the outer border of the EZ to Bruch's membrane are not different in eyes that have undergone lensectomy from those in unoperated eyes (Table 2). In two eyes, we observed a persistence of inner retinal layers at the foveal center. The foveal inner retinal layer thickness is higher in eyes that have undergone lensectomy (Table 4). Cystoid macular edema (within the foveal region and/or beyond) was seen in one eye only.

Other Retinal Parameters

Including only eyes without a diagnosis of glaucoma, there was no statistically significant difference in peripapillary RNFL thickness between post-lensectomy eyes and eyes of healthy volunteers. Mean inner ring and all subfield macular RNFL was reduced in eyes post-lensectomy in the analysis of right eye of bilateral and all unilateral cases, but not in the analysis of left eye of bilateral and all unilateral cases (Table 4; Supplementary Table S3a-d).

There was no difference in central retinal and photoreceptor layer thickness between healthy and post-lensectomy eyes (Table 4 and Supplementary Table S3a-d), with the exception of the foveal zone. There was no correlation between outer retinal layer thickness or central macular thickness and BCVA ($P = 0.086$ and 0.461 , respectively).

Interocular Differences

Children who have undergone unilateral lensectomy have reduced foveal pit depth in the operated eye only; in bilateral cases and healthy volunteers, there is no significant interocular difference in foveal parameters (Table 5).

Results were similar for left eyes of healthy volunteers and bilateral lensectomy cases plus the operated eye of unilateral cases and are available as supplementary material.

DISCUSSION

The principal finding of this study is that childhood lensectomy is associated with reduced foveal pit depth and subfoveal CT. Associated defects are a generalized reduction in macular CT and macular and peripapillary RNFL thickness.

This study has some limitations, inherent to a cross-sectional observational study design. We attempted to minimize selection bias by consecutively approaching all families with eligible children; bias from self-selection appears small, as the demographic characteristics of our study population reflect our general patient population. Missing data occurred when children were tired of participating in multiple imaging assessments, or families felt they did not have sufficient time to complete assessments. Foveal imaging was sometimes limited by fixation instability. The high prevalence of glaucoma in the post-lensectomy eyes (45%) may have affected RNFL thickness measurements, but we did not detect a statistically significant difference between eyes with and without glaucoma. We omitted measurements of the axial length (AL) to

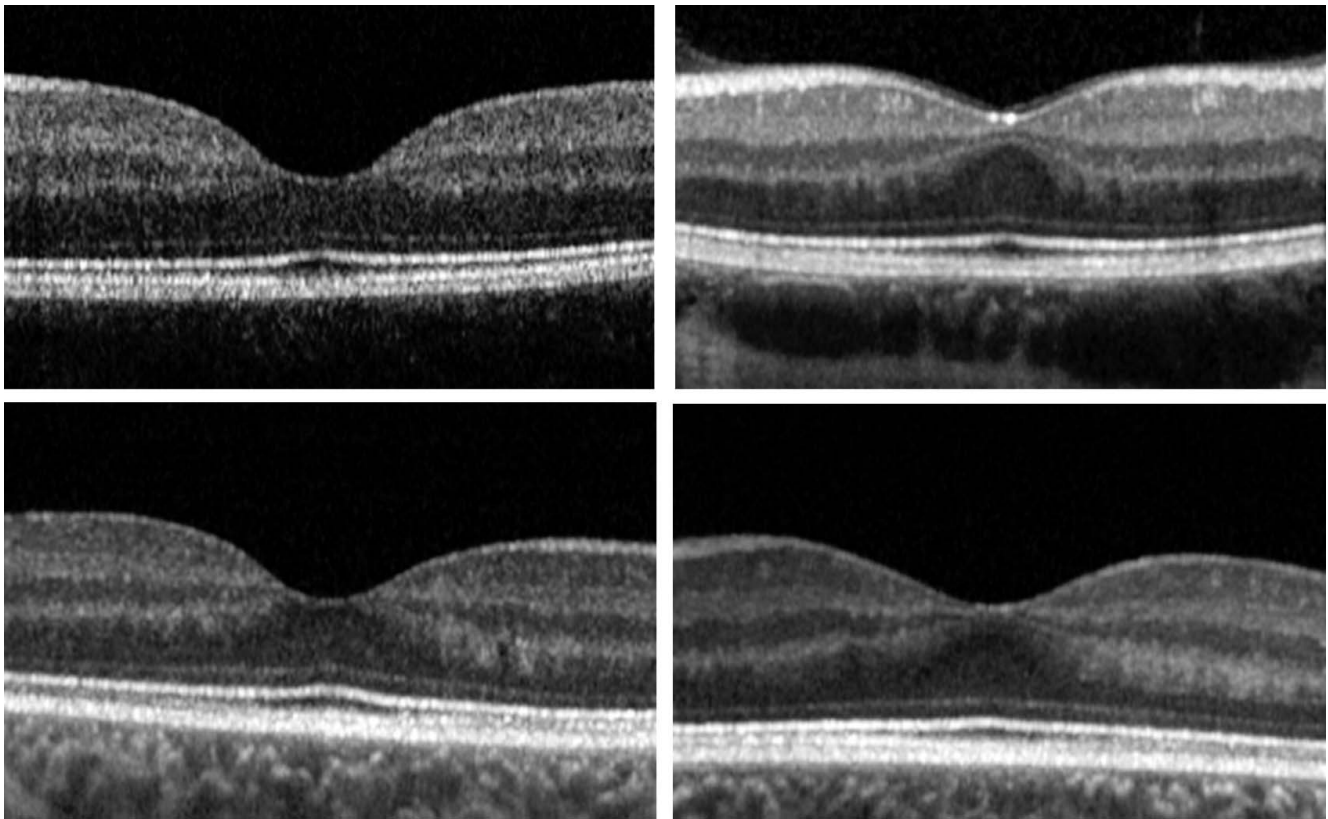


FIGURE 1. Posterior segment OCT of two typical cases of unilateral lensectomy. Left: unoperated eye. Right: operated eye. Note the reduction in foveal depth following lensectomy.

TABLE 2. Foveal Pit Depth and Subfoveal CT Are Significantly Reduced in the Right Eye of Children Who Have Undergone Lensectomy

OCT Parameter	Healthy Eyes			Eyes After Lensectomy			Sig. (2-tailed)	95% Confidence Interval of the Difference	
	<i>n</i>	Mean	SD	<i>n</i>	Mean	SD		Lower	Upper
Foveal pit depth, μm	44	72.6	14.3	27	58.9	24.4	<0.01	-22.8	-4.5
Subfoveal CT, μm	42	353.7	88.4	26	287.9	95.0	0.01	-111.1	-20.5
Mean distance fovea to EZ	44	140.8	15.4	26	152.0	31.9	0.05	-0.2	22.4
Mean distance EZ to Bruch's membrane	44	69.6	8.8	25	66.8	9.8	0.22	-7.4	1.7

Values in bold indicate $P < 0.05$. sig., significance.

TABLE 3. Following Lensectomy, CT Is Reduced in Most Subfields, Indicating a Lack of Physiological Thickness Increase During Childhood Years

CT	Healthy Eyes			Eyes After Lensectomy			Sig. (2-tailed)	95% Confidence Interval of the Difference	
	<i>n</i>	Mean	SD	<i>n</i>	Mean	SD		Lower	Upper
2 - inner ring, superior	43	337.7	83.0	26	258.7	94.2	0.00	-122.2	-35.6
3 - inner ring, temporal	43	320.8	88.0	26	280.9	93.3	0.08	-84.6	4.7
4 - inner ring, inferior	43	363.6	86.6	26	296.0	94.9	0.00	-112.1	-23.0
5 - inner ring, nasal	43	353.6	80.7	26	280.6	94.4	0.00	-115.6	-30.3
6 - outer ring, superior	43	314.8	75.3	26	219.3	90.7	0.00	-135.9	-55.2
7 - outer ring, temporal	43	254.0	85.4	26	250.4	90.9	0.87	-47.0	39.8
8 - outer ring, inferior	43	347.9	75.9	26	285.3	91.5	0.00	-103.4	-22.0
9 - outer ring, nasal	43	335.2	71.3	26	258.3	84.6	0.00	-114.9	-38.9
Mean inner ring	43	343.9	81.7	26	279.1	90.5	0.00	-107.0	-22.6
Mean outer ring	43	313.0	71.6	26	253.3	80.1	0.00	-96.8	-22.5
Mean all 9 subfields	43	331.4	77.2	26	268.6	85.5	0.00	-102.7	-23.0

Values in bold indicate $P < 0.05$. sig., significance.

TABLE 4. Excluding Eyes With Glaucoma From the Analysis, Peripapillary RNFL Thickness (Top), Central Retinal and Photoreceptor Layer Thickness (Bottom) Are Not Affected by Lensectomy

	Healthy Eyes			Eyes After Lensectomy			Sig. (2-tailed)	95% Confidence Interval of the Difference		Eyes After Lensectomy Without Glaucoma			Sig. (2-tailed)	95% Confidence Interval of the Difference	
	n	Mean	SD	n	Mean	SD		Lower	Upper	n	Mean	SD		Lower	Upper
RNFL thickness															
Macular RNFL															
Mean inner ring	44	34.9	4.9	27	24.2	5.1	0.00	1.1	4.4	23	24.1	5.4	0.02	-2.9	-0.3
Mean outer ring	44	21.4	1.8	27	39.6	9.9	0.01	1.1	8.1	23	39.2	10.6	0.05	-5.8	0.0
Mean all 9 subfields	44	26.4	2.7	27	29.7	6.8	0.01	1.1	5.6	23	29.6	7.1	0.03	-3.8	-0.2
Peripapillary RNFL															
Mean superior RNFL	43	125.5	16.4	26	113.2	23.5	0.01	-21.9	-2.7	20	115.4	24.2	0.18	-3.3	17.3
Mean inferior RNFL	43	128.3	17.3	25	112.3	18.6	0.00	-25.0	-7.1	19	115.1	12.2	0.18	-3.1	15.7
Retinal thickness															
Central retinal thickness															
Mean inner ring	44	339.6	13.0	27	336.5	23.2	0.48	-11.6	5.5	23	331.2	34.3	0.44	-5.1	11.4
Mean outer ring	44	299.2	15.9	27	292.3	24.0	0.15	-16.3	2.6	23	290.2	26.7	0.22	-3.5	14.9
Mean all 9 subfields	44	313.6	13.3	27	310.6	21.2	0.47	-11.1	5.2	23	306.9	27.9	0.44	-4.8	10.7
Inner retinal layers															
Foveal															
Mean inner ring	44	177.2	16.7	27	192.5	23.2	0.00	5.8	24.7	23	189.5	27.8	0.03	-19.6	-0.8
Mean outer ring	44	258.2	11.9	27	257.4	20.6	0.83	-8.5	6.9	23	252.9	31.0	0.76	-6.1	8.3
Mean all 9 subfields	44	220.4	14.9	27	215.3	21.4	0.25	-13.7	3.6	23	213.7	24.2	0.35	-4.4	12.2
Outer nuclear layer															
Mean inner ring	43	68.9	7.8	27	68.8	11.6	0.97	-4.7	4.5	23	66.6	13.3	0.71	-3.8	5.6
Mean outer ring	43	59.7	6.7	27	56.4	8.9	0.09	-7.0	0.5	23	55.0	9.1	0.05	-0.1	7.5
Mean all 9 subfields	43	66.8	7.0	27	65.3	10.1	0.47	-5.6	2.6	23	63.4	11.6	0.38	-2.3	5.9

sig., significance.

TABLE 5. Following Unilateral Lensectomy, Foveal Pit Depth Is Reduced in the Operated Eye Only; in Bilateral Cases and Healthy Volunteers, There Is No Significant Difference in Foveal Parameters

	Operated Eye			Nonoperated Eye			Paired Differences		95% Confidence Interval of the Difference		Sig. (2-tailed)
	n	Mean	SD	n	Mean	SD	Mean	SD	Lower	Upper	
Unilateral lensectomy											
Foveal pit depth, μm	15	58.6	27.8	20	77.3	16.0	-18.1	25.0	-31.9	-4.2	0.01
Subfoveal CT, μm	16	278.9	113.5	19	324.8	68.8	-37.2	106.8	-96.4	22.0	0.20
Mean distance fovea to EZ, μm	13	154.9	32.6	20	136.5	14.5	19.2	27.8	2.4	36.0	0.03
Mean distance EZ to Bruch's membrane, μm	13	64.9	6.9	20	67.4	4.8	-3.0	5.5	-6.3	0.3	0.07
	Right Eye			Left Eye			Paired Differences		95% Confidence Interval of the Difference		Sig. (2-tailed)
	n	Mean	SD	n	Mean	SD	Mean	SD	Lower	Upper	
Healthy volunteers											
Foveal pit depth, μm	44	72.6	14.3	44	73.1	13.9	-0.5	4.4	-1.8	0.9	0.47
Subfoveal CT, μm	42	353.7	88.4	43	336.4	76.9	19.3	43.1	5.7	33.0	0.01
Mean distance fovea to EZ, μm	44	140.8	15.4	44	137.7	16.0	3.2	12.3	-0.6	6.9	0.10
Mean distance EZ to Bruch's membrane, μm	44	69.6	8.8	44	69.7	6.1	-0.1	8.2	-2.6	2.4	0.93
Bilateral lensectomy											
Foveal pit depth, μm	13	56.4	22.4	12	53.8	20.5	3.9	10.8	-3.3	11.2	0.25
Subfoveal CT, μm	11	290.1	67.2	11	286.3	79.1	-11.5	44.5	-43.3	20.4	0.44
Mean distance fovea to EZ, μm	13	149.1	32.2	12	153.2	30.3	-3.8	8.0	-9.2	1.6	0.15
Mean distance EZ to Bruch's membrane, μm	12	68.8	12.2	12	69.5	5.1	0.9	9.9	-5.7	7.5	0.77

Values in bold indicate $P < 0.05$. sig., significance.

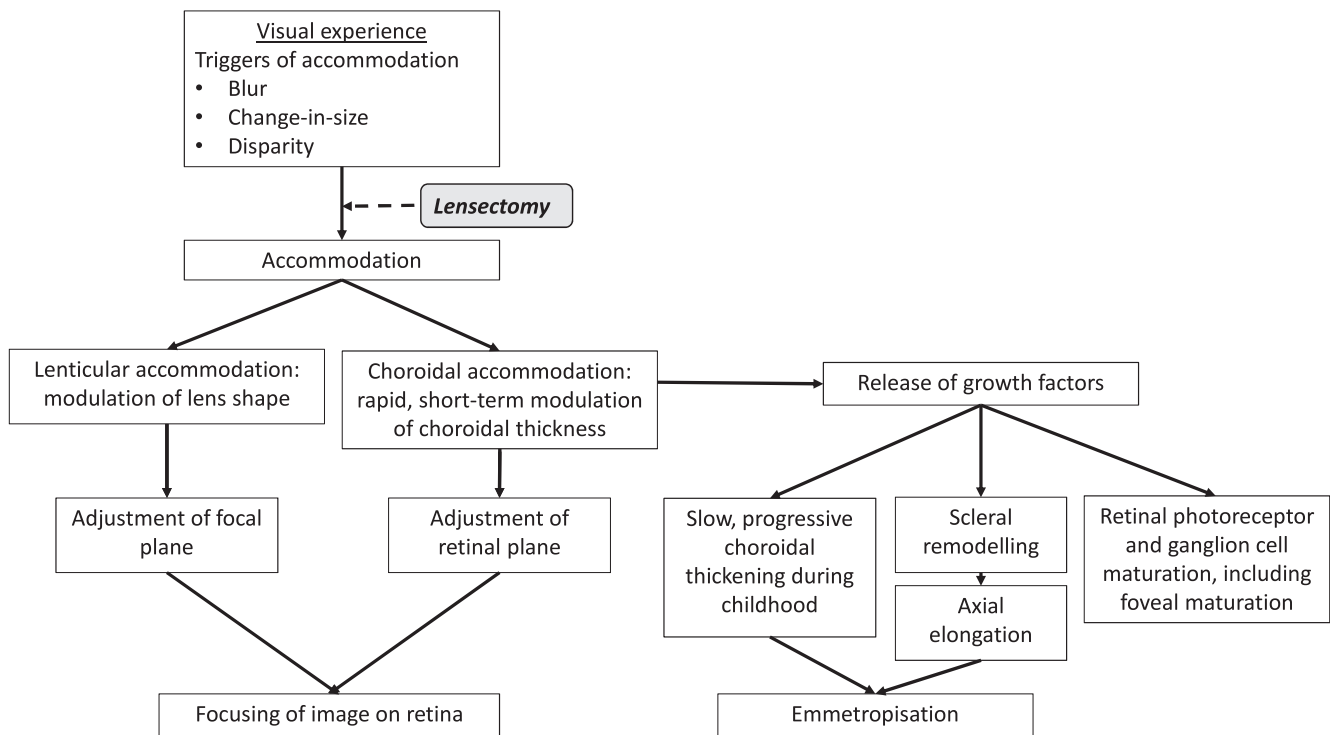


FIGURE 2. Diagram summarizing the role of visual experience and lenticular and choroidal accommodation in the postnatal development of the eye, and the potentially disruptive effect of childhood lensectomy.

reduce the burden of research to children, as this would have required an additional test. Some authors suggest formulas including AL to correct RNFL thickness measurements for optical magnification arising from refractive errors,¹¹ but these formulas are not universally accepted and may not take into account all refractive components of the eye. Coexisting wider developmental eye defects could have affected foveal development, but to our knowledge this series did not include children with microphthalmia or persistent fetal vasculature. Last, association is not causation, and although our findings may reflect structural changes induced by biomechanical changes in the ciliary muscle-choroid-retina complex, a longitudinal study would be required to confirm causality. Future work should also include dynamic choroidal imaging with and without accommodative effort,^{12,13} to directly visualize choroidal accommodation. It is possible that the foveal underdevelopment we observe correlates with the presence of cataract rather than lensectomy. Prenatal foveal development is thought to be promoted principally by orthogonal forces exerted onto the foveal avascular zone by IOP, and to a lesser degree by tangential retinal stretch during ocular growth.¹⁴ It is possible that the same developmental defect that caused childhood cataract also caused foveal underdevelopment. Our group of children with unilateral lensectomy included only two children with unoperated cataract in the fellow eye. In both cases, subfoveal CT was reduced in the operated eye, compared with the unoperated eye, and foveal pit depth was reduced on the operated side in one case. Both children had good visual acuity in the unoperated eye, and poor acuity in the operated eye (0.7 and 0.94 logMAR), indicating that the lens opacity in the unoperated eye was not visually significant. It is not possible to explore the possibility of patterning defects causing cataract and foveal underdevelopment based on this very low number of cases.

An alternative possibility is that in eyes that have undergone removal of the crystalline lens in early childhood, the fovea and subfoveal choroid remain in an immature state. During physiological postnatal development, the fovea undergoes remodeling, changing shape from a narrow and deep pit toward a wider and more shallow depression.¹⁴ During this phase, tangential retinal stretch during ocular growth is considered to be the leading force driving foveal development.¹⁴ How lensectomy might affect this postnatal development is speculative, but we propose the following mechanism, in which visual experience, accommodation, and choroid play a central role (Fig. 2).

Three cues trigger accommodation to maintain the image on the fovea in sharp focus: blur, change-in-size (“proximity”), and binocular disparity.¹⁵ In the first 14 weeks of life, change-in-size is the leading stimulus to induce accommodation. During this early phase, blur cues may be less available, due to retinal, cortical, and optical immaturity¹⁵; disparity detection is immature, as stereopsis only emerges at the age of 12 to 16 weeks.^{16,17} Between 12 and 28 weeks of age, blur, change-in-size, and disparity all induce accommodation, and by the age of 5 to 9 years, stimulus responsiveness is similar to that observed in adults, with disparity now mature¹⁷ and inducing the greatest changes in accommodative state.¹⁵

This visual experience guides postnatal development of the eye, which includes axial elongation and emmetropization (reviewed in Refs. 18–20). The choroid plays a central part in this process: modulation of CT adjusts the retinal plane to the focal plane of the eye (“choroidal accommodation”),^{18,21} and release of growth factors by the choroid regulates extracellular matrix remodeling in the sclera, inducing scleral growth.^{18,19} In addition, the subfoveal choroid itself undergoes maturational changes, increasing in thickness over the first years of life, then thinning during adulthood.²² After childhood lensectomy, axial elongation is highly variable; implantation of a primary IOL implant may facilitate a more physiological development than

aphakia.²³ However, variability in postoperative development complicates the calculation of IOL power, and eyes are often intentionally left hypermetropic, anticipating axial elongation in the first years of life; residual hypermetropia is corrected with contact lenses or glasses (reviewed in Ref. 24).

Foveal maturation is also guided by visual experience, but proceeds at a slower pace. Although eye growth (axial elongation) is greatest in the first 24 months of life,^{25,26} with rapid changes in optics and focusing ability, retinal and photoreceptor maturation and ganglion cell layer development continue throughout childhood.²⁷⁻³² Disruption of developmental processes can affect foveal development and subfoveal CT.

Genetic conditions such as albinism and aniridia can arrest foveal pit formation during fetal development and maturation after birth.^{33,34} Sporadic developmental defects such as fovea plana similarly affect foveal pit morphology, often without impact on visual acuity.^{35,36} Premature birth has also been associated with reduced foveal depth and increased inner and outer retinal layer thickness persisting into childhood,³⁷ as well as an increase in the distance from fovea to EZ, with normal height from EZ to Bruch's membrane at the foveal center.³⁸ Our observations on foveal development after childhood lensectomy are similar to these reports, with reduced foveal pit depth, reduced subfoveal CT, increased fovea-EZ distance (although not statistically significant) and normal EZ-Bruch's membrane height. The lack of correlation between foveal parameters and BCVA in our study may be due to the presence of amblyopia and, to a lesser degree, variability in cooperation during acuity testing. In albinism, a similar lack of correlation between foveal pit depth and BCVA has been reported.³⁹ In our study population, we did not observe a correlation between outer retinal layer thickness or central macular thickness and BCVA, as previously reported in normal visual development.³⁰ Without direct visualization of the photoreceptors it is also difficult to know how many cells are present,⁴⁰ but there is also a large range of foveal shapes with normal acuity.⁴¹

Ultimately, foveal development is a carefully choreographed series of events leading to the development of a pit, increased cone density, and high-resolution visual acuity.¹⁴

It could be argued that the foveal changes we observe may have been caused by postoperative CME. In infants who have undergone lensectomy and anterior vitrectomy, the reported incidence of CME varies widely, from 0 to 37%.⁴²⁻⁴⁴ We observed CME in only one eye, but a longitudinal study including the early postoperative period would be required to explore the potential impact of CME on foveal development.

Despite the hypermetropic mean SE of post-lensectomy eyes in our study, our OCT findings are markedly different from previous reports of increased subfoveal CT in eyes with hypermetropia/short AL⁴⁵ and in hypermetropic anisometric amblyopia, where the more hypermetropic eye displays greater subfoveal CT than the fellow eye.^{46,47}

Contrary to our finding of reduced macular and peripapillary RNFL thickness, several studies have reported that these do not differ significantly between amblyopic and fellow or healthy control eyes.⁴⁸⁻⁵⁰ In our study, RNFL thickness was reduced, even in eyes without coexisting glaucoma.

Last, visual experience guides the maintenance and connections of cortical neurons. Cellular architecture of the visual cortex and neural sensitivity reach relative maturity early (reviewed in Ref. 31). Disruption of visual experience leads to cortical remodeling, such as in amblyopia.⁵¹ Preference for the unoperated eye is common in unilateral cataract management, and unsuccessful amblyopia treatment often results in profound reduction in vision despite technically successful surgery.

Lensectomy disrupts both the biomechanical accommodative processes and the optical focus of the eye. Following lensectomy, reduced posterior/choroidal accommodation may reduce production and release of scleral growth factors and subsequently reduce axial elongation. Physiological subfoveal choroidal thickening and foveal pit development may be reduced secondary to both mechanical factors and the reduced exposure to a well-focused foveal image. Despite IOL implantation or correction of aphakia with contact lenses and bifocal glasses, the fovea will receive less focused images compared with an eye with an intact crystalline lens. This in turn may interfere with the normal feedback between visual cortex and fovea. This is exacerbated after unilateral lensectomy, where we observed significant foveal differences between the two eyes, which were not noted in healthy volunteers nor in children who had undergone bilateral lensectomies. The asymmetry in the processes governing foveal and cortical neuronal network development are significant risk factors for amblyopia,⁵¹ and can only be overcome by intense visual stimulation of the operated eye/occlusion or blurring of the fellow eye.

IOL implants, contact lenses, and glasses may need to move toward multifocal optical correction to optimize the delivery of a focused image to the fovea. Pharmacological agents may in the future stimulate posterior accommodation and contribute to foveal and choroidal development.

In summary, our study shows reduced foveal pit depth and subfoveal CT post-lensectomy in childhood, which we suggest may be due to increased blur and reduced biomechanical input to the choroid, leading to an arrest in foveal development. Further work is required to study detailed mechanisms and to test the impact of current and future treatments.

Acknowledgments

The authors thank Marie Restori for advice and support on acquiring anterior segment OCT images, and Eme Chan and Konstantina Prapa for their help with approaching families about taking part in this study. Our particular thanks go to the children who took part in this study and their families, who selflessly gave their time to help other children in the future.

Supported by the Wates Foundation (award number NWF 00026), Fight for Sight (Small Grant award number 1706/07), and Moorfields Eye Charity. The research was supported by the National Institute of Health Research Moorfields Biomedical Research Centre. The views expressed are those of the authors and not necessarily those of the NHS, the NIHR, or the Department of Health.

Disclosure: **M.C. Daniel**, None; **A.M. Dubis**, None; **B. MacPhee**, None; **P. Ibanez**, None; **G. Adams**, None; **J. Brookes**, None; **M. Papadopoulos**, None; **P.T. Khaw**, None; **M. Theodorou**, None; **A.H. Dahlmann-Noor**, None

References

1. Waddell KM. Childhood blindness and low vision in Uganda. *Eye*. 1998;12(Pt 2):184-192.
2. Sheeladevi S, Lawrenson JG, Fielder AR, Suttle CM. Global prevalence of childhood cataract: a systematic review. *Eye*. 2016;30:1160-1169.
3. Solebo AL, Teoh L, Rahi J. Epidemiology of blindness in children. *Arch Dis Child*. 2017;102:853-857.
4. Hartmann EE, Lynn MJ, Lambert SR; Infant Aphakia Treatment Study Group. Baseline characteristics of the infant aphakia treatment study population: predicting recognition acuity at 4.5 years of age. *Invest Ophthalmol Vis Sci*. 2015;56:388-395.
5. Chak M, Wade A, Rahi JS; British Congenital Cataract Interest Group. Long-term visual acuity and its predictors after surgery

- for congenital cataract: findings of the British congenital cataract study. *Invest Ophthalmol Vis Sci.* 2006;47:4262-4269.
6. Birch EE, Wang J, Feliuss J, Stager DR Jr, Hertle RW. Fixation control and eye alignment in children treated for dense congenital or developmental cataracts. *J AAPOS.* 2012;16:156-160.
 7. Abadi RV, Forster JE, Lloyd IC. Ocular motor outcomes after bilateral and unilateral infantile cataracts. *Vision Res.* 2006;46:940-952.
 8. Morrison DG, Lynn MJ, Freedman SF, Orge FH, Lambert SR; Infant Aphakia Treatment Study Group. Corneal changes in children after unilateral cataract surgery in the Infant Aphakia Treatment Study. *Ophthalmology.* 2015;122:2186-2192.
 9. Wang J, Smith HA, Donaldson DL, et al. Macular structural characteristics in children with congenital and developmental cataracts. *J AAPOS.* 2014;18:417-422.
 10. Day AC, Donachie PH, Sparrow JM, Johnston RL; Royal College of Ophthalmologists' National Ophthalmology Database. The Royal College of Ophthalmologists' National Ophthalmology Database study of cataract surgery: report 1, visual outcomes and complications. *Eye.* 2015;29:552-560.
 11. Kang SH, Hong SW, Im SK, Lee SH, Ahn MD. Effect of myopia on the thickness of the retinal nerve fiber layer measured by Cirrus HD optical coherence tomography. *Invest Ophthalmol Vis Sci.* 2010;51:4075-4083.
 12. Daniel MC, Dubis AM, Quartilho A, et al. Dynamic changes in Schlemm canal and iridocorneal angle morphology during accommodation in children with healthy eyes: a cross-sectional cohort study. *Invest Ophthalmol Vis Sci.* 2018;59:3497-3502.
 13. Daniel MC, Dubis AM, Theodorou M, et al. Childhood lensectomy is associated with static and dynamic reduction in Schlemm canal size: a biomechanical hypothesis of post-lensectomy glaucoma. *Ophthalmology.* 2019;126:233-241.
 14. Provis JM, Dubis AM, Maddess T, Carroll J. Adaptation of the central retina for high acuity vision: cones, the fovea and the avascular zone. *Prog Retin Eye Res.* 2013;35:63-81.
 15. Horwood AM, Riddell PM. Developmental changes in the balance of disparity, blur, and looming/proximity cues to drive ocular alignment and focus. *Perception.* 2013;42:693-715.
 16. Birch EE, Shimojo S, Held R. Preferential-looking assessment of fusion and stereopsis in infants aged 1-6 months. *Invest Ophthalmol Vis Sci.* 1985;26:366-370.
 17. Norcia AM, Gerhard HE, Meredith WJ. Development of relative disparity sensitivity in human visual cortex. *J Neurosci.* 2017;37:5608-5619.
 18. Nickla DL, Wallman J. The multifunctional choroid. *Prog Retin Eye Res.* 2010;29:144-168.
 19. Summers JA. The choroid as a sclera growth regulator. *Exp Eye Res.* 2013;114:120-127.
 20. Mutti DO, Mitchell GL, Jones LA, et al. Accommodation, acuity, and their relationship to emmetropization in infants. *Optom Vis Sci.* 2009;86:666-676.
 21. Zhu X. Temporal integration of visual signals in lens compensation (a review). *Exp Eye Res.* 2013;114:69-76.
 22. Mapelli C, Dell'Arti L, Barteselli G, et al. Choroidal volume variations during childhood. *Invest Ophthalmol Vis Sci.* 2013;54:6841-6845.
 23. Lambert SR, Lynn MJ, DuBois LG, et al. Axial elongation following cataract surgery during the first year of life in the infant Aphakia Treatment Study. *Invest Ophthalmol Vis Sci.* 2012;53:7539-7545.
 24. Nischal KK. State of the art in pediatric cataract surgery. *Dev Ophthalmol.* 2016;57:15-28.
 25. Larsen JS. The sagittal growth of the eye. IV. Ultrasonic measurement of the axial length of the eye from birth to puberty. *Acta Ophthalmol (Copenh).* 1971;49:873-886.
 26. Fledelius HC, Christensen AC. Reappraisal of the human ocular growth curve in fetal life, infancy, and early childhood. *Br J Ophthalmol.* 1996;80:918-921.
 27. Hendrickson AE, Yuodelis C. The morphological development of the human fovea. *Ophthalmology.* 1984;91:603-612.
 28. Vajzovic L, Hendrickson AE, O'Connell RV, et al. Maturation of the human fovea: correlation of spectral-domain optical coherence tomography findings with histology. *Am J Ophthalmol.* 2012;154:779-789.
 29. Dubis AM, Costakos DM, Subramaniam CD, et al. Evaluation of normal human foveal development using optical coherence tomography and histologic examination. *Arch Ophthalmol.* 2012;130:1291-1300.
 30. Lee H, Purohit R, Patel A, et al. In vivo foveal development using optical coherence tomography. *Invest Ophthalmol Vis Sci.* 2015;56:4537-4545.
 31. Kiorpes L. The puzzle of visual development: behavior and neural limits. *J Neurosci.* 2016;36:11384-11393.
 32. Yuodelis C, Hendrickson A. A qualitative and quantitative analysis of the human fovea during development. *Vision Res.* 1986;26:847-855.
 33. McAllister JT, Dubis AM, Tait DM, et al. Arrested development: high-resolution imaging of foveal morphology in albinism. *Vision Res.* 2010;50:810-817.
 34. Calvao-Pires P, Santos-Silva R, Falcao-Reis F, Rocha-Sousa A. Congenital aniridia: clinic, genetics, therapeutics, and prognosis. *Int Sch Res Notices.* 2014;2014:305350.
 35. Noval S, Freedman SF, Asrani S, El-Dairi MA. Incidence of fovea plana in normal children. *J AAPOS.* 2014;18:471-475.
 36. Villegas VM, Schwartz SG, Hamet TD, McKeown CA, Capo H, Flynn HW Jr. Variable clinical profile of fovea plana in normal children. *Ophthalmic Surg Lasers Imaging Retina.* 2018;49:251-257.
 37. Rosen R, Sjostrand J, Nilsson M, Hellgren K. A methodological approach for evaluation of foveal immaturity after extremely preterm birth. *Ophthalmic Physiol Opt.* 2015;35:433-441.
 38. Vajzovic L, Rothman AL, Tran-Viet D, Cabrera MT, Freedman SF, Toth CA. Delay in retinal photoreceptor development in very preterm compared to term infants. *Invest Ophthalmol Vis Sci.* 2015;56:908-913.
 39. Mohammad S, Gottlob I, Kumar A, et al. The functional significance of foveal abnormalities in albinism measured using spectral-domain optical coherence tomography. *Ophthalmology.* 2011;118:1645-1652.
 40. Wilk MA, Wilk BM, Langlo CS, Cooper RF, Carroll J. Evaluating outer segment length as a surrogate measure of peak foveal cone density. *Vision Res.* 2017;130:57-66.
 41. Dubis AM, Hansen BR, Cooper RF, Beringer J, Dubra A, Carroll J. Relationship between the foveal avascular zone and foveal pit morphology. *Invest Ophthalmol Vis Sci.* 2012;53:1628-1636.
 42. Gilbard SM, Peyman GA, Goldberg MF. Evaluation for cystoid maculopathy after pars plicata lensectomy-vitreotomy for congenital cataracts. *Ophthalmology.* 1983;90:1201-1206.
 43. Hoyt CS, Nickel B. Aphakic cystoid macular edema: occurrence in infants and children after transpupillary lensectomy and anterior vitrectomy. *Arch Ophthalmol.* 1982;100:746-749.
 44. Kirwan C, O'Keeffe M. Cystoid macular oedema in paediatric aphakia and pseudophakia. *Br J Ophthalmol.* 2006;90:37-39.
 45. Zhang JM, Wu JF, Chen JH, et al. Macular choroidal thickness in children: The Shandong Children Eye Study. *Invest Ophthalmol Vis Sci.* 2015;56:7646-7652.

46. Nishi T, Ueda T, Hasegawa T, Miyata K, Ogata N. Choroidal thickness in children with hyperopic anisometropic amblyopia. *Br J Ophthalmol*. 2014;98:228-232.
47. Mori T, Sugano Y, Maruko I, Sekiryu T. Subfoveal choroidal thickness and axial length in preschool children with hyperopic anisometropic amblyopia. *Curr Eye Res*. 2014;1-8.
48. Al-Haddad CE, Mollayess GM, Cherfan CG, Jaafar DE, Bashshur ZF. Retinal nerve fibre layer and macular thickness in amblyopia as measured by spectral-domain optical coherence tomography. *Br J Ophthalmol*. 2011;95:1696-1699.
49. Kantarci FA, Tatar MG, Uslu H, et al. Choroidal and peripapillary retinal nerve fiber layer thickness in adults with anisometropic amblyopia. *Eur J Ophthalmol*. 2015;25:437-442.
50. Araki S, Miki A, Goto K, et al. Macular retinal and choroidal thickness in unilateral amblyopia using swept-source optical coherence tomography. *BMC Ophthalmol*. 2017;17:167.
51. Tailor VK, Schwarzkopf DS, Dahlmann-Noor AH. Neuroplasticity and amblyopia: vision at the balance point. *Curr Opin Neurol*. 2017;30:74-83.