

Ido Didi Fabian and Mandeep S. Sagoo

Intraocular tumours may be classified according to a wide range of variables, including their malignant potential, incidence, age of presentation, anatomical location within the eye, tissue from which the tumour arises, relation to systemic disease, and primary site of origin (i.e. a primary ocular tumour *versus* secondary deposit from a distant cancer).

Patients with intraocular tumours may present with acute vision-related symptoms, such as reduced visual acuity, visual field defects, flashing lights or floaters; however they can be asymptomatic, depending on the size and location of the tumour. A significant number of asymptomatic patients harbouring an intraocular tumour are diagnosed on routine eye examinations or as part of screening surveys for other diseases such as diabetic retinopathy.

The main benign and malignant intraocular tumours that will be discussed in this chapter

are retinoblastoma, choroidal naevus, choroidal melanoma, choroidal osteoma, choroidal haemangioma, retinal capillary haemangioma, vasoproliferative tumour, sclerochoroidal calcification and intraocular lymphoma.

Retinoblastoma

Retinoblastoma is the most common intraocular malignancy of childhood, with a constant incidence worldwide of 1 in 15,000 to 1 in 20,000 live births [1]. In the majority of cases the tumour is initiated by a mutation in the *RBI* gene and mutations in both *RBI* alleles are a prerequisite for developing the cancer [2]. In heritable retinoblastoma, which in most cases affects both eyes, mutation in one *RBI* allele is constitutional, whereas a somatic mutation in the second allele initiates tumour growth in the sensory retinal cells. In non-heritable *RBI*-related retinoblastoma, both mutations are somatic, giving rise to unilateral, unifocal disease in the vast majority of cases. Retinoblastoma patients with the heritable form are also prone to developing additional non-ocular tumours [3] and are at risk of developing trilateral retinoblastoma [4].

Median age of diagnosis of unilateral retinoblastoma is 24 months and of bilateral retinoblastoma is 10 months [5]. A white pupillary reflex, also termed leucocoria (Fig. 8.1), is the most common presenting clinical sign, both in devel-

I. D. Fabian
Goldschleger Eye Institute, Sheba Medical Center,
Tel-Aviv University, Tel-Aviv, Israel

International Centre for Eye Health, London School
of Hygiene and Tropical Medicine, London, UK
e-mail: didi@didifabian.com

M. S. Sagoo (✉)
Ocular Oncology Service, Moorfields Eye Hospital
and Retinoblastoma Service, Royal London Hospital,
UCL Institute of Ophthalmology, London, UK
e-mail: mandeep.sagoo@nhs.net

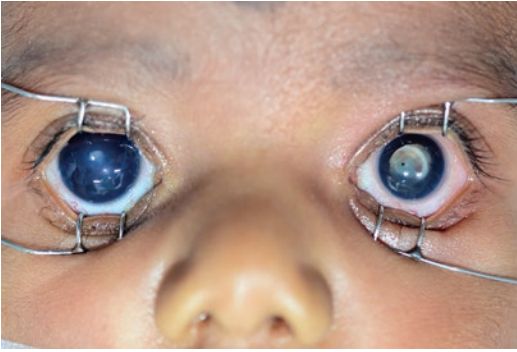

Fig. 8.1 Leucocoria, or white pupillary reflex

oping and developed countries [6–8]. Additional signs are strabismus, and less frequently, red eye, inflammation and additional non-specific signs [8]. Untreated, retinoblastoma will spread outside the globe, via the central nervous system, and haematogenously, inevitably leading to death. In developing countries, in which there is a lack of educational strategies and infrastructure is poor, retinoblastoma patients' survival rate is estimated to be 40% or less [1, 9]. In developed countries, while these were the rates in the early twentieth century, nowadays 5-year survival is estimated to be >95% [10].

Treatment strategies for retinoblastoma have evolved significantly throughout the years. Traditionally, retinoblastoma was treated by enucleation of the eye, a treatment modality still in use today in cases of advanced intraocular disease.

In the mid-twentieth century, external beam radiotherapy (EBRT) was developed and was found to be an effective conservative treatment modality for retinoblastoma. It soon replaced enucleation as the mainstay of treatment for most retinoblastoma cases [11, 12]. Unfortunately, after nearly half a century of extensive use of EBRT for retinoblastoma, it was recognized that radiation significantly increases the risk of developing a secondary cancer in survivors of hereditary retinoblastoma [13, 14]. As a result, radiotherapy was widely abandoned, replaced by chemotherapy as the primary treatment for intraocular retinoblastoma, and to date, is reserved only as a last resort, when all other

modalities have failed. Radiotherapy also forms a part of the protocol for treatment of Orbital RB. The use of systemic chemotherapy as a primary treatment modality for intraocular disease was initiated in the 1990s using potent chemotherapeutic agents, namely vincristine, etoposide and carboplatin (VEC). It was first given in combination with EBRT, resulting in 70% eyes salvaged [15], and following with additional focal therapy, used as an alternative to EBRT, and resulted with high eye salvage rate [16–18]. Soon after it was first introduced, the VEC regimen became the standard protocol for retinoblastoma in most centers.

In order to better predict outcomes of retinoblastoma patients treated with chemotherapy, the International Intraocular Retinoblastoma Classification (IIRC) was introduced in early 2000's [19]. Eyes manifesting the tumour were classified into five groups from A to E (Fig. 8.2) according to size, presence and extent of tumour seeds (vitreous or sub-retinal), and development of secondary complications (e.g. neovascular glaucoma).

In an attempt to avoid potential systemic complications of systemically delivered chemotherapy, new methods of delivery arose, namely, intra-arterial and intravitreal chemotherapy. The former method of delivery developed in Japan [20] and refined in the USA [21] is used in some centres as the primary modality for retinoblastoma, and the latter developed in Sweden [22, 23] and extensively used in Japan and Switzerland is used as adjuvant or salvage therapy [24, 25].

Choroidal Naevus

The commonest fundus tumour in adults is a benign choroidal naevus (Fig. 8.3), arising from melanocytes of the choroidal stroma, often discovered as an incidental finding and is rarely symptomatic. It is a flat or minimally elevated pigmented lesion, but infrequently can be a pale colour (amelanotic). Overlying changes such as drusen or retinal pigment epithelial changes imply chronicity. Approximately 5% of the white population has a choroidal naevus and the risk of

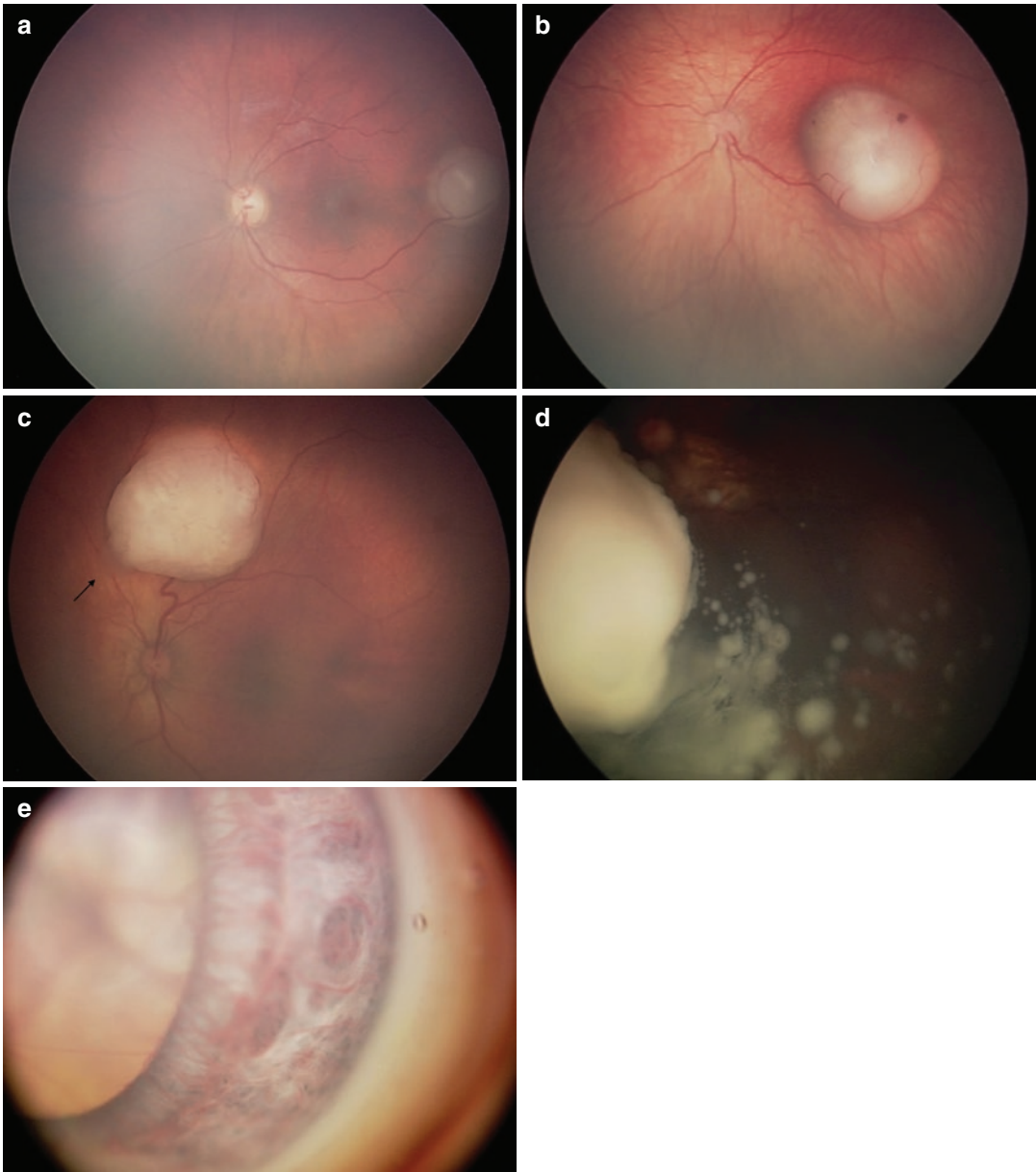


Fig. 8.2 Retinoblastoma tumour grouping according to the International Intraocular Retinoblastoma Classification. Group A: Tumour confined to the retina, >3 mm away from the macula (a); Group B: tumour confined to the retina,

at the macular region (b); Group C: local seeding (arrow) (c); Group D: diffuse vitreous seeding (d); and Group E: iris neovascularization of the iris and a large tumour seen behind the crystalline lens (e)

malignant transformation is low (approximately 1:8000) [26].

A choroidal naevus does not usually warrant treatment, however leakage of fluid into the subretinal space, presence of visual symptoms, secretion of orange-pigmented lipofuscin and/

or growth, raise the suspicion for malignant transformation into choroidal malignant melanoma and need for intervention. Occasionally a naevus will cause symptoms without malignant transformation, such as the onset of choroidal neovascularization [27].

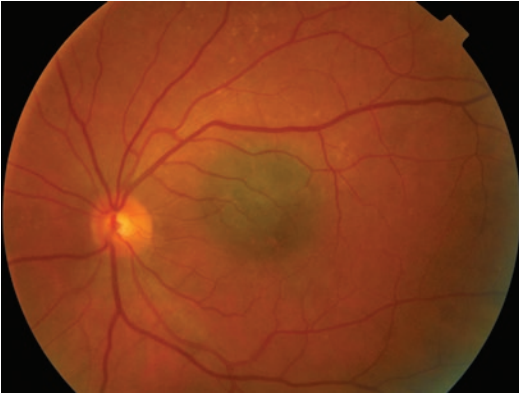


Fig. 8.3 A left eye choroidal naevus

Patients diagnosed from photographic diabetic retinopathy screening with a choroidal naevus should be referred to an ophthalmologist, retinal specialist or even an ocular oncologist depending on the level of suspicion for a complete evaluation. In future this may be changed into a virtual assessment process [28], but for now, the gold standard remains clinical examination, photographic and ultrasonographic documentation.

Uveal Melanoma

Uveal melanoma is the most common primary intraocular malignancy in adults, occurring in approximately 6 individuals per million population annually [29]. Of these, 5% originate from the iris, 10% from the ciliary body, and the majority, 85%, are choroidal (Fig. 8.4). Uveal melanoma mainly affects light-skinned individuals, though it can occur less frequently in dark-skinned. There is a slight male preponderance. It is considered to be a sporadic event, although associated with dysplastic naevus syndrome and ocular melanocytosis.

An undiagnosed or untreated choroidal melanoma will eventually not only threaten vision, but also the integrity of the globe and even risk life. Early detection of a choroidal melanoma is of paramount importance, as tumour size directly correlates with chances of metastatic spread [30].

Common symptoms related to choroidal melanoma include blurred vision, floaters and photopsia. However, patients can be asymptomatic,

and the lesion picked up on a routine eye check. Compared to choroidal naevus a choroidal melanoma is an active cancer that grows in size (albeit slowly) and leaks subretinal fluid, and therefore more commonly causes visual symptoms.

Examination reveals a dome-shaped or ‘collar stud’ mass, located in the choroid, usually pigmented, but can occasionally be partly or entirely non-pigmented (amelanotic). Retinal detachment and lipofuscin orange pigment deposition are common features. Less frequently, they can cause severe glaucoma, cataract, and even extra-ocular extension into the orbit. Such tumours generally carry a worse prognosis.

Historically, uveal melanoma was treated by primary enucleation. However with advances in radiation delivery, most centers now use radiotherapy by proton beam or plaque brachytherapy if tumour size allows, with high local tumour control rates and more than 90% eyes salvaged [31]. In spite of treatment, vision is often compromised or lost due to radiation damage to the retina and optic nerve. Additional modalities, used less frequently, include surgical resection, by means of transscleral local resection or endoresection. Deciding on which treatment modality should be employed depends on multiple factors, including tumour size, visual acuity of the affected eye and contralateral eye, age and general health of the patient, and the presence of metastases.

Uveal melanoma metastasizes via haematogenous spread primarily to the liver, and is believed to occur early in the course of the disease, despite successful treatment of the eye [32]. In a retrospective analysis by Shields et al. of more than 8000 patients, 33% and 25% of ciliary body and choroidal melanoma patients, respectively, were diagnosed with metastatic spread at 10 years [30]. Iris melanoma had a more favourable prognosis. Size of the primary tumour at time of detection was important in determining the chances for secondary spread: at 10 years, metastasis were diagnosed in 12% of small melanoma (elevation ≤ 3.0 mm), 26% of medium melanoma (elevation 3.1–8.0 mm) and 49% of large melanoma (elevation > 8.0 mm). Metastatic spread at the time of presentation with the intraocular tumour is unusual, but sys-

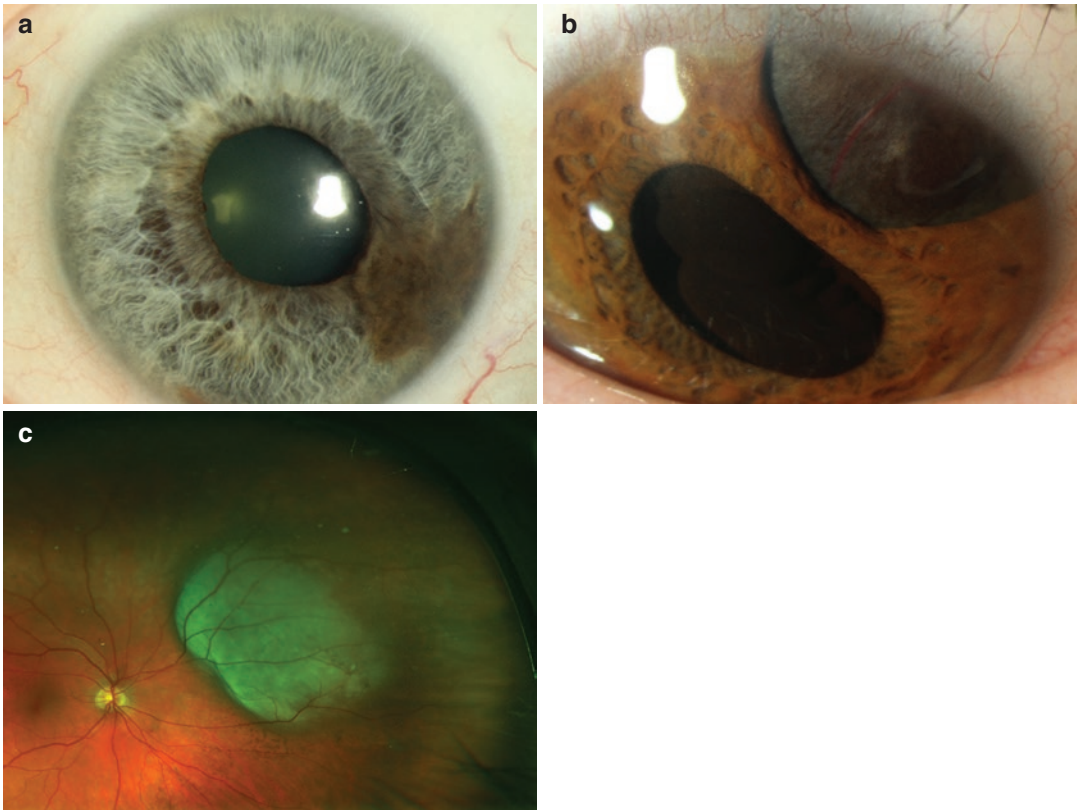


Fig. 8.4 Uveal melanoma in the iris (a), ciliary body with iris root erosion (b) and choroid (c)

temic screening is advised for detection of liver involvement, even years after treatment of the primary intraocular tumour. Despite the improvements in treatment of the primary tumour, a corresponding decrease in metastatic death has not been documented and stands overall at a 5 year survival of 20–30% and a 10 year survival estimate of 50% [33, 34]. To date, metastatic uveal melanoma is a major challenge for physicians to treat although many new targeted immune modulatory treatments are now available such as PD1 inhibitors and MEK inhibitors in addition to targeted hepatic chemotherapy.

Ocular Metastasis

Secondary deposits from distant malignancies occur in the eye; particularly in the choroid due to its vascular nature [35]. The commonest primary cancers to metastasize to the eye

are lung cancer in males and breast cancer in females. In approximately 2/3 of cases the primary site of the cancer is already known, but in the other 1/3 will prompt examination and imaging of the rest of the body. If no primary cancer is found, then biopsy of the eye tumour may be required. Choroidal metastases present as yellow creamy subretinal deposits that grow rapidly (Fig. 8.5). They tend to leak fluid in large amounts, as compared to primary ocular malignancies.

Treatment involves controlling the primary tumour site, but also local treatment to the eye with EBRT, visudyne photodynamic therapy (PDT) or plaque radiotherapy to try to preserve as much vision as possible. Patients with poor systemic status usually warrant observation only and systemically treatment-naïve patients that were newly diagnosed might benefit from systemic therapy (e.g. chemotherapy) to have a positive effect on the ocular deposits.

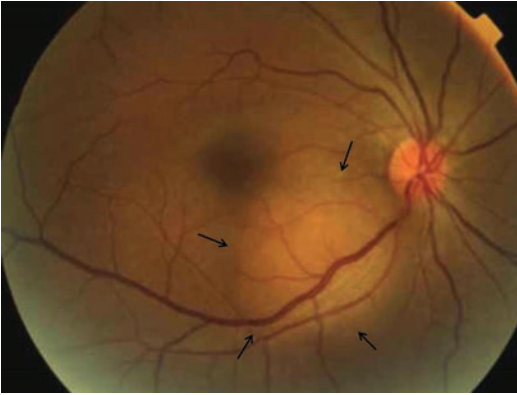


Fig. 8.5 A right eye pale choroidal metastasis (arrows)

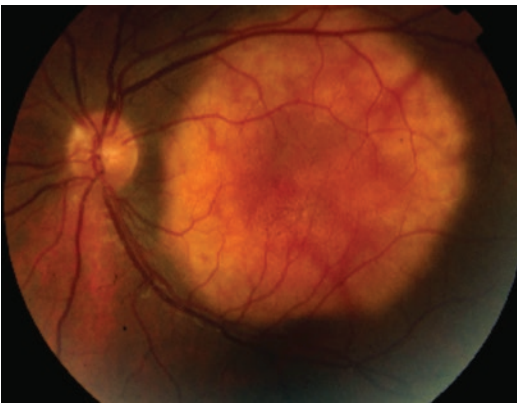


Fig. 8.6 A left eye choroidal osteoma in the macular region

Choroidal Osteoma

Choroidal osteoma (Fig. 8.6) is a benign intra-ocular tumour composed of mature bone that typically replaces the full thickness of the choroid, and hence is a choristoma (abnormal tissue growth not indigenous to that anatomical location). The tumour classically manifests as an orange-yellow plaque deep to the retina in the juxtapapillary or macular region. It typically occurs as a unilateral condition found in healthy young females in the second or third decades of life. Patients with a choroidal osteoma may be asymptomatic. When symptoms are present they include mild to severe visual blurring, metamorphopsia, and visual field defects corresponding to the location of the tumour. Clinical complications

of a choroidal osteoma include enlargement of its basal diameter, leakage of subretinal fluid and development of subretinal neovascularization with or without haemorrhage [36]. Management options include observation, when no complications occur, or the use of intravitreal anti-VEGF or laser for treatment of neovascular membrane and subretinal fluid.

Choroidal Haemangioma

Choroidal haemangiomas are benign, vascular hamartomas, classified as circumscribed or diffuse. The circumscribed form (Fig. 8.7) occurs sporadically, while the diffuse one is related to Sturge-Weber syndrome, a rare non-hereditary neuro-oculo-cutaneous syndrome presenting at childhood [37].

Circumscribed choroidal haemangiomas commonly occur between the second and fourth decades of life, are usually asymptomatic, but may be associated with visual symptoms, including decreased vision, metamorphopsia, floaters and photopsia. On clinical examination, circumscribed choroidal haemangiomas appear as orange-coloured masses with indistinct borders. Ultrasonography usually demonstrates a dome shaped choroidal lesion with high internal echogenicity. Leakage of fluid into the subretinal space overlying the choroidal lesion is a common manifestation, and depending on location, might result with visual loss. Management options for circumscribed choroidal haemangiomas include monitoring asymptomatic cases, use of oral beta blockers, laser photocoagulation, and visudyne PDT and for resistant or large tumours – EBRT or brachytherapy. Resolution of SRF is achieved in most cases; however visual prognosis depends mainly on tumour location (i.e. involvement of macula).

Retinal Capillary Haemangioma

Retinal capillary haemangioma (RCH) is a benign retinal vascular tumour (Fig. 8.8). RCH may occur sporadically or in association with von Hippel Lindau (VHL) disease, a genetic disorder,

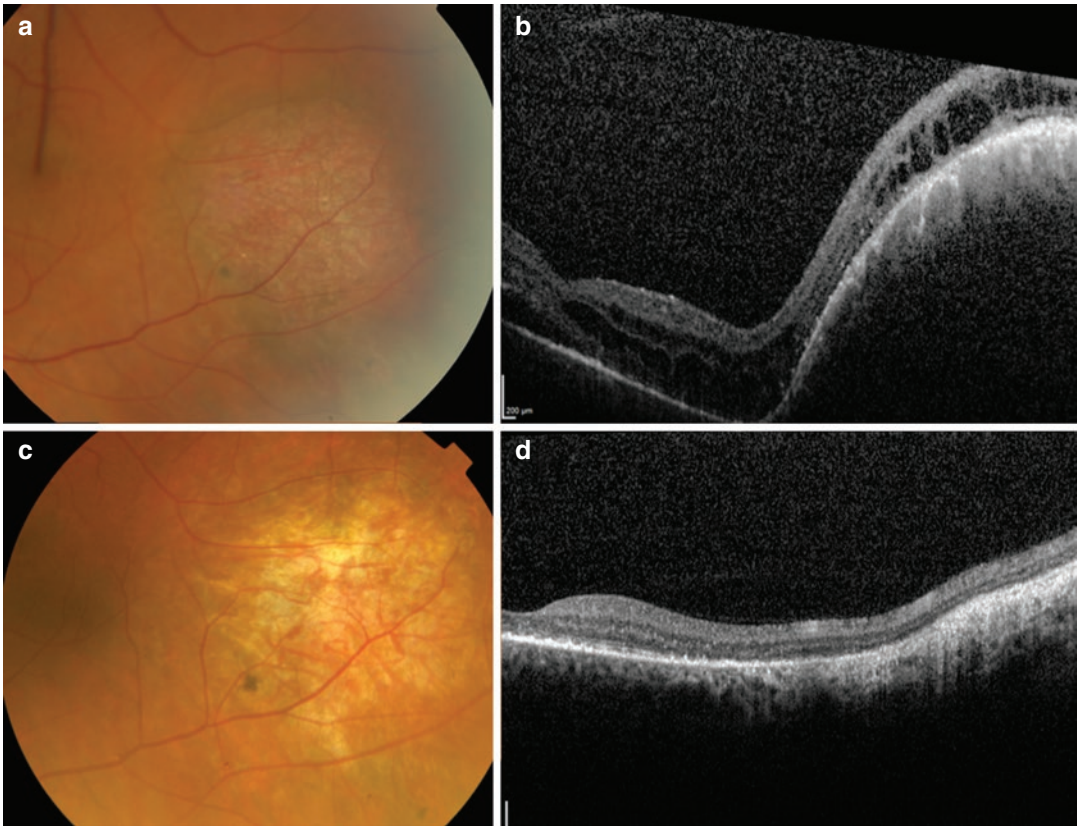


Fig. 8.7 A left eye choroidal haemangioma (a), with overlying sub- and intra-retinal fluid, as shown on OCT (b). After treatment with photodynamic therapy, the lesion formed into a scar (c) and fluid resolved (d)

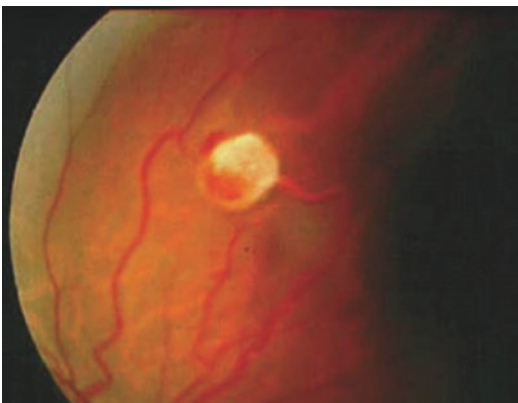


Fig. 8.8 A right eye retinal capillary haemangioma with feeding and draining vessels

which may involve the adrenal glands, kidneys, cardiovascular system, spine and central nervous system [38].

The mean age of diagnosis of RCH in VHL patients is 25 years old. Common symptoms include vision deterioration and photopsia, but some patients may be asymptomatic and diagnosed incidentally in a routine eye examination or as part of screening test for families with VHL. On clinical examination and more evident on fluorescein angiography, a prominent feeding vessel and a draining vein are commonly seen entering and exiting the tumour. Most RCH are located in the temporal periphery and cause intra- and subretinal leakage. Treatment options include observation for small tumours, laser photocoagulation of the tumour and/or feeding artery, cryotherapy, visudyne PDT and plaque radiotherapy. In advanced cases, complicated with retinal detachment, vitreoretinal surgery is a valid option. Regular screening of the body is also recommended.

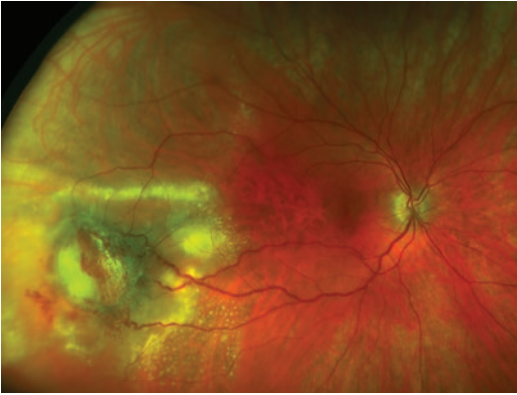


Fig. 8.9 A right eye vasoproliferative tumour with surrounding exudation

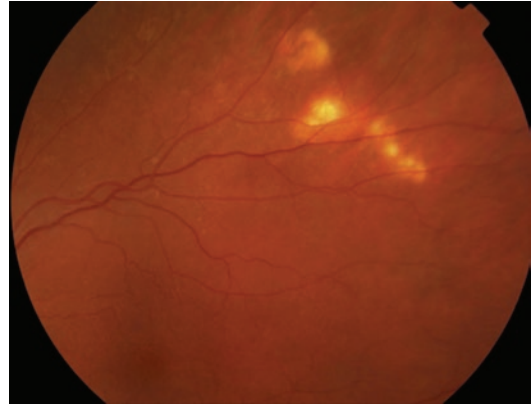


Fig. 8.10 Typical appearance of a left eye sclerochoroidal calcifications located along the superotemporal arcade

Vasoproliferative Tumour

Similar to RCH, a vasoproliferative tumour (VPT) is a benign vascular retinal lesion, present at the third–fourth decades of life. VPTs appear as isolated lesions (Fig. 8.9), but may develop secondary to a pre-existing ocular disorder, in which case multiple lesions are commonly found [39]. VPTs are usually present in the peripheral retina and show significant leakage of fluid. They can be distinguished from RCHs by the absence of large dilated feeder and drainage vessels that commonly occur with RCHs. Macular pucker is a common feature, causing visual deterioration. Treatment options used for RCH are also used for VPT, and decisions as to the best management step depend on tumour size, location, related clinical complications (e.g. exudation, epiretinal membrane) and association to other ocular disorders.

Sclerochoroidal Calcification

Sclerochoroidal calcification is a rare benign condition that classically manifests as multiple discrete yellow lesions, often discovered as an incidental finding in asymptomatic older white individuals (Fig. 8.10). This condition may be idiopathic, secondary to hypercalcemia, or syndrome-associated [40]. The clinical appearance is typical and recognizable by indirect ophthalmoscopy as an elevated mass with overlying

retinal pigment epithelial atrophy. Diagnostic evaluation using ultrasonography can confirm the presence of intrinsic calcification. The lesions are commonly bilateral and located in the superotemporal quadrant along the arcades, and are frequently multiple, features that help differentiating them from choroidal osteoma.

Patients diagnosed with sclerochoroidal calcifications require no ocular intervention unless vision loss occurs from the development of a choroidal neovascular membrane. They should undergo systemic workup to screen for abnormalities in calcium and phosphate metabolism.

Primary Intraocular Lymphoma

Primary intraocular vitreoretinal lymphoma, or PIOL (Fig. 8.11), is an intraocular malignancy that is a subset of primary central system lymphoma (PCNSL). Approximately one-third of PIOL patients will have concurrent PCNSL at presentation, and up to 90% will develop PCNSL within 1–2 years [41]. PIOL is bilateral in up to 85% of cases, although initially it may seem unilateral. Posterior segment findings of PIOL include the presence of vitreous cells in the majority of cases. Another sign is the development of creamy lesions with orange–yellow infiltrates that are deep to the retina. Imaging studies, including fluorescein angiography, OCT and ultrasonography, and tissue (vitreous/retina/choroid) biopsy are usually required for

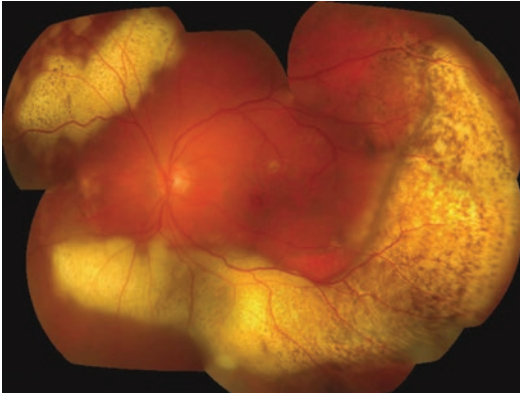


Fig. 8.11 Primary intraocular lymphoma in the left eye showing diffuse subretinal creamy deposits

diagnosis. Treatment of PIOL includes systemic chemotherapy and eyes and brain radiotherapy. Intravitreal chemotherapy with methotrexate and/or rituximab is used to control the ocular disease. Mortality rate in PIOL patients may be as high as 80% at 3 years.

Conclusion

There are many different types of intraocular tumours. Pattern recognition with suitable ancillary testing can assist in the diagnosis and subsequent management of the majority of tumour types.

References

- Kivelä T. The epidemiological challenge of the most frequent eye cancer: retinoblastoma, an issue of birth and death. *Br J Ophthalmol.* 2009;93(9):1129–31. <https://doi.org/10.1136/bjo.2008.150292>.
- Knudson a G. Mutation and cancer: statistical study of retinoblastoma. *Proc Natl Acad Sci U S A.* 1971;68(4):820–3. <https://doi.org/10.1073/pnas.68.4.820>.
- Eng C, Li FP, Abramson DH, et al. Mortality from second tumors among long-term survivors of retinoblastoma. *J Natl Cancer Inst.* 1993;85(14):1121–8. <https://doi.org/10.1093/jnci/85.14.1121>.
- de Jong MC, Kors WA, de Graaf P, Castelijns JA, Moll AC, Kivelä T. The incidence of trilateral retinoblastoma: a systematic review and meta-analysis. *Am J Ophthalmol.* 2015; <https://doi.org/10.1016/j.ajo.2015.09.009>.
- MacCarthy A, Birch JM, Draper GJ, et al. Retinoblastoma in Great Britain 1963–2002. *Br J Ophthalmol.* 2009;93(1):33–7. <https://doi.org/10.1136/bjo.2008.139618>.
- Bowman RJC, Mafwiri M, Luthert P, Luande J, Wood M. Outcome of retinoblastoma in East Africa. *Pediatr Blood Cancer.* 2008;50(1):160–2. <https://doi.org/10.1002/pbc.21080>.
- Menon BS, Alagaratnam J, Juraida E, Mohamed M, Ibrahim H, Naing NN. Late presentation of retinoblastoma in Malaysia. *Pediatr Blood Cancer.* 2009;52(2):215–7. <https://doi.org/10.1002/pbc.21791>.
- Abramson DH, Frank CM, Susman M, Whalen MP, Dunkel IJ, Boyd NW. Presenting signs of retinoblastoma. *J Pediatr.* 1998;132(3 Pt 1):505–8. [https://doi.org/10.1016/S0022-3476\(98\)70028-9](https://doi.org/10.1016/S0022-3476(98)70028-9).
- Dimaras H, Kimani K, Dimba E a O, et al. Retinoblastoma. *Lancet.* 2012;379(9824):1436–40. [https://doi.org/10.1016/S0140-6736\(11\)61137-9](https://doi.org/10.1016/S0140-6736(11)61137-9).
- Shields CL, Meadows AT, Leahey AM, Shields JA. Continuing challenges in the management of retinoblastoma with chemotherapy. *Retina.* 2004;24(6):849–62. <http://www.ncbi.nlm.nih.gov/pubmed/15579981>. Accessed 13 Oct 2015.
- Stallard HB. Irradiation of retinoblastoma (glioma retinae). *Lancet (London, England).* 1952;1(6717):1046–9. <http://www.ncbi.nlm.nih.gov/pubmed/14928558>. Accessed 15 Oct 2015.
- Reese AB, Merriam GR, Martin HE. Treatment of bilateral retinoblastoma by irradiation and surgery; report on 15-year results. *Am J Ophthalmol.* 1949;32(2):175–90. <http://www.ncbi.nlm.nih.gov/pubmed/18111333>. Accessed 15 Oct 2015.
- Fletcher O, Easton D, Anderson K, Gilham C, Jay M, Peto J. Lifetime risks of common cancers among retinoblastoma survivors. *J Natl Cancer Inst.* 2004;96(5):357–63. <http://www.ncbi.nlm.nih.gov/pubmed/14996857>. Accessed 16 Oct 2015.
- Kleinerman RA, Tucker MA, Tarone RE, et al. Risk of new cancers after radiotherapy in long-term survivors of retinoblastoma: an extended follow-up. *J Clin Oncol.* 2005;23(10):2272–9. <https://doi.org/10.1200/JCO.2005.05.054>.
- Kingston JE, Hungerford JL, Madreperla SA, Plowman PN. Results of combined chemotherapy and radiotherapy for advanced intraocular retinoblastoma. *Arch Ophthalmol (Chicago, Ill 1960).* 1996;114(11):1339–43. <http://www.ncbi.nlm.nih.gov/pubmed/8906024>. Accessed 20 Oct 2015.
- Gallie BL, Budning A, DeBoer G, et al. Chemotherapy with focal therapy can cure intraocular retinoblastoma without radiotherapy. *Arch Ophthalmol (Chicago, Ill 1960).* 1996;114(11):1321–8. <http://www.ncbi.nlm.nih.gov/pubmed/8906022>. Accessed 20 Oct 2015.
- Murphree AL, Villablanca JG, Deegan WF, et al. Chemotherapy plus local treatment in the management of intraocular retinoblastoma. *Arch Ophthalmol (Chicago, Ill 1960).* 1996;114(11):1348–56. <http://www.ncbi.nlm.nih.gov/pubmed/8906025>. Accessed 20 Oct 2015.

18. Shields CL, De Potter P, Himelstein BP, Shields JA, Meadows AT, Maris JM. Chemoreduction in the initial management of intraocular retinoblastoma. *Arch Ophthalmol* (Chicago, Ill 1960). 1996;114(11):1330–8. <http://www.ncbi.nlm.nih.gov/pubmed/8906023>. Accessed 20 Oct 2015.
19. Linn Murphree A. Intraocular retinoblastoma: the case for a new group classification. *Ophthalmol Clin N Am*. 2005;18(1):41–53, viii. <https://doi.org/10.1016/j.ohc.2004.11.003>.
20. Yamane T, Kaneko A, Mohri M. The technique of ophthalmic arterial infusion therapy for patients with intraocular retinoblastoma. *Int J Clin Oncol*. 2004;9(2):69–73. <https://doi.org/10.1007/s10147-004-0392-6>.
21. Abramson DH, Dunkel IJ, Brodie SE, Kim JW, Gobin YP. A phase I/II study of direct intraarterial (ophthalmic artery) chemotherapy with melphalan for intraocular retinoblastoma initial results. *Ophthalmology*. 2008;115(8):1398–404, 1404.e1. <https://doi.org/10.1016/j.ophtha.2007.12.014>.
22. LA E, ROSENGREN BH. Present therapeutic resources in retinoblastoma. *Acta Ophthalmol*. 1961;39:569–76. <http://www.ncbi.nlm.nih.gov/pubmed/13890561>. Accessed 8 Nov 2015.
23. Seregard S, Kock E, af Trampe E. Intravitreal chemotherapy for recurrent retinoblastoma in an only eye. *Br J Ophthalmol*. 1995;79(2):194–5. <http://www.pubmedcentral.nih.gov/articlerender.fcgi?artid=505058&tool=pmcentrez&rendertype=abstract>. Accessed 8 Nov 2015.
24. Kaneko A, Suzuki S. Eye-preservation treatment of retinoblastoma with vitreous seeding. *Jpn J Clin Oncol*. 2003;33(12):601–7. <http://www.ncbi.nlm.nih.gov/pubmed/14769836>. Accessed 8 Nov 2015.
25. Munier FL, Gaillard M-C, Balmer A, et al. Intravitreal chemotherapy for vitreous disease in retinoblastoma revisited: from prohibition to conditional indications. *Br J Ophthalmol*. 2012;96(8):1078–83. <https://doi.org/10.1136/bjophthalmol-2011-301450>.
26. Shields CL, Furuta M, Berman EL, et al. Choroidal nevus transformation into melanoma: analysis of 2514 consecutive cases. *Arch Ophthalmol* (Chicago, Ill 1960). 2009;127(8):981–7. <https://doi.org/10.1001/archophthalmol.2009.151>.
27. Papastefanou VP, Nogueira V, Hay G, et al. Choroidal naevi complicated by choroidal neovascular membrane and outer retinal tubulation. *Br J Ophthalmol*. 2013;97(8):1014–9. <https://doi.org/10.1136/bjophthalmol-2013-303234>.
28. Balaskas K, Gray J, Blows P, et al. Management of choroidal naevomelanocytic lesions: feasibility and safety of a virtual clinic model. *Br J Ophthalmol*. 2015; <https://doi.org/10.1136/bjophthalmol-2015-307168>.
29. Egan KM, Seddon JM, Glynn RJ, Gragoudas ES, Albert DM. Epidemiologic aspects of uveal melanoma. *Surv Ophthalmol*. 1988;32(4):239–51. <http://www.ncbi.nlm.nih.gov/pubmed/3279559>. Accessed 30 Mar 2015.
30. Shields CL, Furuta M, Thangappan A, et al. Metastasis of uveal melanoma millimeter-by-millimeter in 8033 consecutive eyes. *Arch Ophthalmol*. 2009;127(8):989–98. <https://doi.org/10.1001/archophthalmol.2009.208>.
31. Wilson MW, Hungerford JL. Comparison of episcleral plaque and proton beam radiation therapy for the treatment of choroidal melanoma. *Ophthalmology*. 1999;106(8):1579–87. [https://doi.org/10.1016/S0161-6420\(99\)90456-6](https://doi.org/10.1016/S0161-6420(99)90456-6).
32. Eskelin S, Pyrhönen S, Summanen P, Hakka-Kemppinen M, Kivelä T. Tumor doubling times in metastatic malignant melanoma of the uvea: tumor progression before and after treatment. *Ophthalmology*. 2000;107(8):1443–9. [https://doi.org/10.1016/S0161-6420\(00\)00182-2](https://doi.org/10.1016/S0161-6420(00)00182-2).
33. Burr JM, Mitry E, Rachtel B, Coleman MP. Survival from uveal melanoma in England and Wales 1986 to 2001. *Ophthalmic Epidemiol*. 14(1):3–8. <https://doi.org/10.1080/09286580600977281>.
34. Singh AD, Turell ME, Topham AK. Uveal melanoma: trends in incidence, treatment, and survival. *Ophthalmology*. 2011;118(9):1881–5. <https://doi.org/10.1016/j.ophtha.2011.01.040>.
35. Arepalli S, Kaliki S, Shields CL. Choroidal metastases: origin, features, and therapy. *Indian J Ophthalmol*. 2015;63(2):122–7. <https://doi.org/10.4103/0301-4738.154380>.
36. Aylward GW, Chang TS, Pautler SE, Gass JD. A long-term follow-up of choroidal osteoma. *Arch Ophthalmol* (Chicago, Ill 1960). 1998;116(10):1337–41. <http://www.ncbi.nlm.nih.gov/pubmed/9790633>. Accessed 1 Dec 2015.
37. Tsipursky MS, Golchet PR, Jampol LM. Photodynamic therapy of choroidal hemangioma in sturge-weber syndrome, with a review of treatments for diffuse and circumscribed choroidal hemangiomas. *Surv Ophthalmol*. 2011;56(1):68–85. <https://doi.org/10.1016/j.survophthal.2010.08.002>.
38. Haddad NMN, Cavallerano JD, Silva PS. Von hippel-lindau disease: a genetic and clinical review. *Semin Ophthalmol*. 2013;28(5–6):377–86. <https://doi.org/10.3109/08820538.2013.825281>.
39. Shields CL, Shields JA, Barrett J, De Potter P. Vasoproliferative tumors of the ocular fundus. Classification and clinical manifestations in 103 patients. *Arch Ophthalmol* (Chicago, Ill 1960). 1995;113(5):615–23. <http://www.ncbi.nlm.nih.gov/pubmed/7748132>. Accessed 1 Dec 2015.
40. Shields CL, Hasanreisoglu M, Saktanasate J, Shields PW, Seibel I, Shields JA. Sclerochoroidal calcification: clinical features, outcomes, and relationship with hypercalcemia and parathyroid adenoma in 179 eyes. *Retina*. 2015;35(3):547–54. <https://doi.org/10.1097/IAE.0000000000000450>.
41. Sagoo MS, Mehta H, Swampillai AJ, et al. Primary intraocular lymphoma. *Surv Ophthalmol*. 2014;59:503–16. <https://doi.org/10.1016/j.survophthal.2013.12.001>.

Open Access This chapter is licensed under the terms of the Creative Commons Attribution 4.0 International License (<http://creativecommons.org/licenses/by/4.0/>), which permits use, sharing, adaptation, distribution and reproduction in any medium or format, as long as you give appropriate credit to the original author(s) and the source, provide a link to the Creative Commons license and indicate if changes were made.

The images or other third party material in this chapter are included in the chapter's Creative Commons license, unless indicated otherwise in a credit line to the material. If material is not included in the chapter's Creative Commons license and your intended use is not permitted by statutory regulation or exceeds the permitted use, you will need to obtain permission directly from the copyright holder.

