

Retinal Imaging

Is retinal vasculature a biomarker in amyloid proven Alzheimer's disease?

Jurre den Haan^{a,*}, Jacoba A. van de Kreeke^b, Bart N. van Berckel^c, Frederik Barkhof^{c,d},
Charlotte E. Teunissen^e, Philip Scheltens^a, Frank D. Verbraak^b, Femke H. Bouwman^a

^aAlzheimer Center Amsterdam, Department of Neurology, Amsterdam Neuroscience, Vrije Universiteit Amsterdam, Amsterdam UMC, Amsterdam, The Netherlands

^bDepartment of Ophthalmology, Vrije Universiteit Amsterdam, Amsterdam UMC, Amsterdam, The Netherlands

^cDepartment of Radiology and Nuclear Medicine, Amsterdam Neuroscience, Vrije Universiteit Amsterdam, Amsterdam UMC, Amsterdam, The Netherlands

^dUCL institutes of Neurology and Healthcare Engineering, London, UK

^eNeurochemistry Lab and Biobank, Department of Clinical Chemistry, Amsterdam Neuroscience, Vrije Universiteit Amsterdam, Amsterdam UMC, Amsterdam, The Netherlands

Abstract

Introduction: The retina is a potential source of noninvasive vascular biomarkers for Alzheimer's disease (AD). We assessed retinal microvasculature in well-characterized AD cases, taking ophthalmological confounders into account.

Methods: We included 48 amyloid-positive AD patients and 38 amyloid-negative cognitively normal control subjects. All participants underwent ophthalmological screening to exclude interfering ocular disease. Using a multimodal approach, we measured retinal vascular parameters, choroidal thickness, macular vascular density, and foveal avascular zone size.

Results: We found no disease effects on retinal vascular measures (all β 's $< |0.15|$, all $P > .2$), adjusted for confounders. Venular tortuosity was inversely associated with Fazekas score in control subjects ($\beta -0.56$, $P < .01$), while vessel density in the outer ring of the macula was inversely associated with Fazekas score in AD cases ($\beta -0.64$, $P < .01$).

Discussion: In conclusion, retinal vasculature did not discriminate patients with AD from control subjects, despite evident changes on clinical, neuroimaging, and cerebrospinal fluid biomarkers, challenging the use of retinal vasculature measurements as AD biomarker.

© 2019 The Authors. Published by Elsevier Inc. on behalf of the Alzheimer's Association. This is an open access article under the CC BY-NC-ND license (<http://creativecommons.org/licenses/by-nc-nd/4.0/>).

Keywords:

Retinal vasculature; Alzheimer's disease; Biomarker; Choroidal thickness; OCTA; Fundus photographs

1. Background

Alzheimer's disease (AD) pathophysiology is characterized by amyloid beta (A β) accumulation, tau hyperphosphorylation, and neurodegeneration, ultimately leading to cognitive decline [1]. In addition, vascular changes are involved in AD pathophysiology. Vascular changes, either intrinsic or as copathology, interact with AD pathology,

neurodegeneration, and cognitive impairment [2,3] and are described with the term vascular cognitive impairment (VCI) [4,5]. Vascular pathology is prevalent and described at autopsy in up to 75% of dementia cases [4,6]. Vascular changes include white matter hyperintensities (WMHs) as a result of chronic (subcortical) ischemia of small vessels, large vessel infarcts, lacunar infarcts (e.g. thalamus), arteriosclerosis and atherosclerosis, and cerebral amyloid angiopathy (CAA) [7,8]. CAA is an intravascular pathology in which A β is deposited in the vessel wall and is associated with microhemorrhages and microinfarcts [9]. Its prevalence is

*Corresponding author. Tel: +31204440685; Fax: +31204448529.
E-mail address: j.denhaan1@vumc.nl

between 20% and 40% in nondemented elderly and 50-60% in demented elderly in autopsy studies [9,10]. A strong correlation between AD and CAA exists, as in postmortem AD brains, in 85-95% of the cases CAA is found [9]. Moreover, recent studies also showed that decreased cerebral blood flow and blood-brain barrier alterations might be involved in AD pathophysiology, possibly playing a role in A β clearance [2,3]. Currently used biomarkers for vascular changes are limited to magnetic resonance imaging (MRI) [8]. To better understand and measure vascular changes in AD, new biomarkers for vascular changes might increase pathophysiological insight and could complement the currently used ATN system for amyloid(A), tau(T), and neurodegeneration(N) [11].

The retina is a possible source of vascular biomarkers as retinal vasculature can be imaged noninvasively at the micrometer level using different imaging modalities, including fundus photography, measurements of choroidal thickness (using enhanced depth imaging optical coherence tomography (EDI-OCT) and OCT angiography (OCTA)). Vascular changes in the retina have been described in AD, including changes in vascular parameters from fundus photography analysis, using Singapore I Vessel analysis (SIVA) software, such as increased venous diameter, decreased arterial diameter, and decreased fractional dimension [12]. In contrast, a recent report showed an absence of group differences between AD patients and control participants, while showing decreased total and arteriolar fractal dimensions in VCI cases [13]. In addition, choroidal thinning in AD is reported in several studies using EDI-OCT [14–17]. Recent reports on retinal vasculature with OCTA reported increased foveal avascular zone (FAZ) size and decreased vessel density and flow in AD [18,19] and preclinical AD [20].

As ophthalmological comorbidity could potentially influence retinal vascular measurements and is often asymptomatic, a thorough ophthalmological screening is warranted. Second, assessing retinal biomarkers in patients with a confirmed AD diagnosis by established biomarkers such as cortical atrophy, amyloid and tau in cerebrospinal fluid (CSF) or amyloid positron emission tomography (PET) supports the clinical diagnosis on one hand and allows comparison of the new biomarkers to the gold standard on the other hand.

The aim of this study was to identify retinal vascular biomarkers as possible noninvasive biomarkers in AD. Following previous publications, we hypothesize to find increased central retinal artery equivalent (CRAE), decreased central retinal vein equivalent (CRVE), decreased fractal dimension, thinner choroidal thickness, smaller vessel density, and larger FAZ in AD compared to control cases. We, therefore, measured retinal vascular parameters using fundus photography, EDI-OCT, and OCTA in well-characterized amyloid-positive AD cases, while taking ophthalmological confounders into account. In addition, we

assessed relationships between retinal vascular parameters and WMHs on MRI.

2. Methods

2.1. Subjects

We assessed 50 AD patients and 38 control subjects from the Amsterdam Dementia Cohort (ADC) that were enrolled into our retinal imaging cohort as described earlier (all Mini-Mental State Examination (MMSE) ≥ 17 , capable of giving informed consent) [21]. In brief, all patients and control subjects underwent a standardized screening protocol including (medical) history, neuropsychological examination, blood draw for apolipoprotein E $\epsilon 4/\epsilon 4$ (APOE $\epsilon 4/\epsilon 4$) genotype, blood pressure measurements, neuroimaging, and lumbar puncture [22]. All patients met National Institute on Aging and Alzheimer's Association criteria of AD and had evidence of amyloid pathology based on CSF analysis or amyloid PET [11]. Controls were subjects with cognitive complaints that showed no evidence of objective cognitive impairment, neurodegeneration, or amyloid pathology based on amyloid PET or CSF analysis.

2.2. MRI scanning

MRI scans were reviewed by an experienced and blinded rater (FB) before the multidisciplinary meeting of the ADC, where a clinical diagnosis was made by consensus. Visual rating scores for atrophy on MRI were determined based on T1-weighted images and included medial temporal lobe atrophy, global cortical atrophy, and parietal cortical atrophy [23–25]. Vascular assessment included Fazekas score for white matter hyperintensities (fluid attenuation inversion recovery sequence), assessment of lacunar infarcts (fluid attenuation inversion recovery, T2-weighted sequences), and microbleeds (T2*-sequence) [26].

2.3. Cerebrospinal fluid analysis

CSF was analyzed using Innostest ELISA and measured amyloid-beta₁₋₄₂(A β ₁₋₄₂), tau₁₈₁, and phosphorylated Tau (pTau). A tau₁₈₁/A β ₁₋₄₂ ratio $\geq .52$ was considered an AD profile [27].

2.4. Amyloid PET analysis

A subset of cases was enrolled in research programs that included amyloid PET scanning with the following tracers: ¹⁸F-Florbetaben (NeuraCeq) (n = 24), ¹⁸F-Florbetapir (Amyvid) (n = 9), and Pittsburgh compound (¹¹C-PIB) (n = 3). Parametric standardized uptake value images of amyloid PET scans were assessed by an experienced rater (BvB) and visually interpreted as amyloid positive or amyloid negative following guidelines for individual tracers.

2.5. Ophthalmological assessment

Subjects were included within a year after the ADC diagnostic screening program and underwent the following eye examinations to exclude possible confounding ophthalmological pathology: best-corrected visual acuity, intraocular pressure using noncontact tonometry (if intraocular pressure >20 mmHg, we used contact applanation tonometry), slit-lamp examination of the anterior and posterior segment, Heidelberg retinal tomography optic nerve head (ONH) analysis, and frequency doubling technology for visual fields. Tropicamide (0.5%) was administered for pupil dilation to facilitate optimal ophthalmological examination. We followed the fourth European Glaucoma Guideline criteria: glaucoma was diagnosed when two of the three following measurements were abnormal: ocular pressure (>21 mmHg), structural glaucomatous changes (examined with Heidelberg retinal tomography using the Moorfields regression analysis), and functional changes (examined with frequency doubling technology) [28]. All examinations were interpreted by an experienced ophthalmologist (FDV). Exclusion criteria were ophthalmological conditions interfering with imaging or retinal vasculature, such as severe cataract, age-related macular degeneration, and glaucoma or systemic conditions such as diabetes mellitus.

2.6. Retinal vascular imaging

Retinal vasculature was measured by personnel blinded for diagnosis, using three imaging modalities: (1) fundus photography, (2) enhanced depth imaging OCT (EDI-OCT) and (3) OCT angiography (OCTA) (Fig. 1). Digital fundus images of 50° field of view of the macula and ONH were obtained using a Topcon TRC 50DX type IA (Topcon Medical Systems, Inc., Oakland, CA, USA). Macular photographs were assessed for incident pathology by an experienced ophthalmologist (FDV), whereas ONH photographs were used for SIVA analyses (version 3.0; National University of Singapore, Singapore) [29–31] by two trained raters (JdH, JAVdK). Values from both eyes of every participant were averaged; if only one suitable image was present, only this eye was included (n = 3). We assessed vascular parameters that were earlier found to have high intraobserver intraclass correlation (>0.80) [32], namely CRAE, CRVE, arteriole-to-venule ratio, fractal dimension of the arteriolar network (FDa), fractal dimension of the venular network, curvature tortuosity of the arterioles (cTORTa), and curvature tortuosity of the venules. We averaged vascular parameters of two raters. Intraobserver intraclass correlation coefficients of the present study are shown in Supplementary Table 1.

EDI-OCT scans were acquired with a Heidelberg Spectralis spectral domain-OCT, using the following protocol: central retina (macula) fast horizontal scanning; central 20° × 20° area; 25 B-scans (averaging 9 frames per b-scan); 512 a-scans per b-scan. Manual measurements

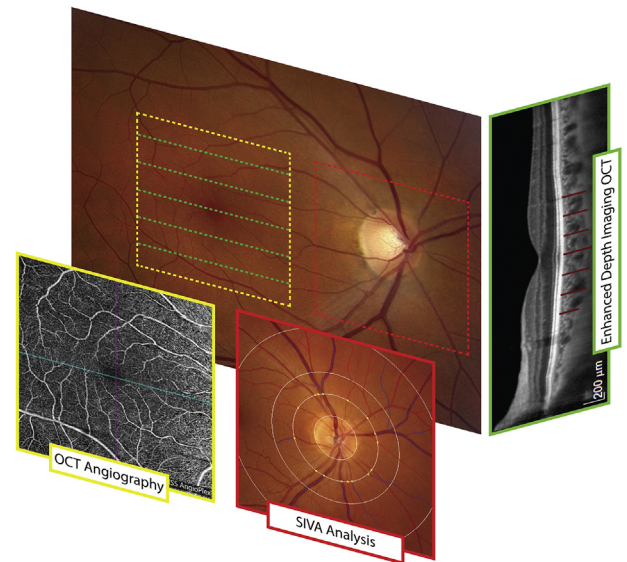


Fig. 1. Overview of retinal modalities to assess microvasculature. Retinal vasculature was assessed using three imaging modalities: retinal vascular parameter analysis using SIVA applied on fundus photographs (red), choroidal thickness measurements using enhanced depth imaging optical coherence tomography (EDI-OCT) (green), and vessel density and foveal avascular zone (FAZ) measured with OCT angiography (OCTA) (yellow). Abbreviations: OCT, optical coherence tomography; SIVA, Singapore I Vessel analysis.

of choroidal thickness were performed in five evenly distributed b-scans per macular volume scan (Supplementary Fig. 1) [14,16,17]. Five measurements per b-scan were performed: foveal, 1 mm nasal and temporal from the fovea and 2 mm nasal and temporal from the fovea. The anterior boundary of the choroid layer was defined as the hyperreflective band corresponding to the retinal pigment epithelium—Bruch's membrane complex. To define the posterior boundary, each measurement point was categorized based on the presence or absence of the choroidal-scleral interface as a hyperreflective band, the suprachoroidal space as a hyporeflecting band, and/or a smooth line marking the posterior boundary on the OCT image. The posterior boundary was then defined as the outer limit of the choroidal-scleral interface, the inner limit of the suprachoroidal space, or the smooth line. If no clear boundary was identifiable over the length of the scan, the image was defined as ungradable. The averages of the measurements (n = 25) from both eyes were used for analysis of mean choroidal thickness.

OCTA was acquired using a Zeiss Model 5000 spectral domain-OCT with Angioplex and consisted of 6 × 6 mm scans of the macula, 350 b-scans each. Vascular density measured in the inner ring (Ø 1-3 mm around fovea) and outer ring (Ø 3-6 mm around fovea) of the Early Treatment in Diabetes Retinopathy Study grid. FAZ surface area was measured. Scans were visually assessed for quality. All scans had quality factors ≥7/10 and could be considered "good" quality.

2.7. Statistical analysis

2.7.1. Power calculation

Based on a previous meta-analysis [12], comparing 374 AD cases compared to 707 control subjects, a decrease of 7.52 μm in CRAE can be expected. Assuming a true effect of 7.52 μm and a standard deviation of $\approx 15 \mu\text{m}$, 28 subjects in each group are needed to reject the null hypothesis of no difference between the disease and control group with a power of 0.80. In addition, from the same meta-analysis a decrease of 10.74 μm in CRVE can be expected. Assuming a true effect of 10.74 μm and a standard deviation of $\approx 15 \mu\text{m}$, 15 subjects in each group are needed to reject the null hypothesis of no difference between the disease and control group with a power of 0.80. From a previous report [16], a decrease of $\approx 60 \mu\text{m}$ in choroidal thickness can be expected. Assuming a true effect of 60 μm and a standard deviation of $\approx 50 \mu\text{m}$, 6 subjects in each group are needed to reject the null hypothesis of no difference between the disease and control group with a power of 0.80. We included >35 participants per disease group.

2.7.2. Data analysis

Data were visually tested for a normal distribution using histograms and Q-Q plots. Measures that were normally distributed were tested with an independent t-test, nonnormally distributed measures with a Mann-Whitney U test, and binary variables with a chi-squared test. Linear regression models were used to assess if changes in retinal vasculature (dependent) were attributable to diagnosis (independent) or age, sex, spherical equivalent, quality factor, and/or hypertension (covariates). All betas reported are standardized betas. Stratified analysis for APOE $\epsilon 4/\epsilon 4$ genotype carriers versus noncarriers was performed for retinal vascular parameters. Intraobserver intraclass correlation (absolute agreement) was calculated to test intrarater variability for SIVA. Data analysis was performed with IBM SPSS Statistics (version 22.0).

3. Results

Table 1 shows cohort characteristics. We included 50 AD patients and 38 control subjects from our retinal imaging [21] cohort with retinal vasculature imaging available. One AD case was excluded because of glaucoma. In addition, we excluded one AD case that was later found to have a progranulin mutation, a mutation known to directly affect retinal integrity [33]. As a result, fundus photographs were available in 48 AD patients and 38 control participants. EDI-OCT and OCTA became available in the course of the study and were obtained in 41 AD patients and 31 control participants for EDI-OCT and 26 AD patients and 31 control participants for OCTA. AD cases were slightly older (65.4 y

Table 1
Cohort characteristics

	Alzheimer's disease	Controls	P value
Number	48	38	
Sex (m/f)	25/23	24/14	.24*
Age	65.4 (± 8.1)	60.6 (± 5.0)	<.01 [†]
MMSE	23 (± 3)	29 (± 1)	<.01 [†]
Body mass index (kg/m^2)	24.4 (± 3.1)	26.2 (± 4.1)	.32 [†]
APOE $\epsilon 4/\epsilon 4$ genotype [§]			
E4 homozygous, n (%)	11 (23.4)	1 (2.9)	<.01 *
E4 heterozygous, n (%)	22 (46.8)	9 (26.5)	.05*
E4 negative, n (%)	14 (29.8)	24 (70.6)	<.01 *
Blood pressure measures			
Systolic blood pressure (mmHg)	148.9 (± 17.5)	139.0 (± 18.4)	.02 [†]
Diastolic blood pressure (mmHg)	84.2 (± 10.1)	82.8 (± 9.1)	.55 [†]
Pulse pressure (mmHg)	64.7 (± 12.6)	56.2 (± 12.5)	<.01 [†]
Mean arterial pressure (mmHg)	84.4 (± 64.1)	59.3 (± 83.5)	.01 [†]
MRI [#]			
Global cortical atrophy (GCA)	1 (0-2)	0 (0-1)	<.01 [†]
Medial temporal lobe atrophy (MTA)	1.5 (0-2.5)	0 (0-2)	<.01 [†]
Parietal cortical atrophy (PCA)	1 (0-3)	0 (0-1)	<.01 [†]
Fazekas score	1 (0-3)	1 (0-2)	.08 [‡]
Microbleeds (n)	0.1 (± 0.4)	2.7 (± 14.6)	.35 [‡]
Lacunar infarcts (n)	0 (± 0)	0.2 (± 0.6)	.02 [‡]
CSF [¶]			
A β_{1-42} (ng/L)	555.1 (± 106.2)	1162.3 (± 200.0)	<.01 [‡]
Tau ₋₁₈₁ (ng/L)	711.5 (± 304.5)	242.2 (± 85.7)	<.01 [‡]
pTau (ng/L)	89.0 (± 28.3)	43.0 (± 11.8)	<.01 [‡]
Tau ₋₁₈₁ /A β_{1-42} ratio	1.3 (± 0.5)	0.2 (± 0.1)	<.01 [‡]
A β PET ^{**}			
Positive/negative	17/0	0/19	<.01 [†]
Ophthalmological			
Intraocular pressure (mmHg)	16.3 (± 2.3)	16.0 (± 2.1)	.39 [‡]
Visual acuity (LogMAR)	0.0 (± 0.1)	-0.1 (0.1)	<.01 [‡]

Significant associations ($P < .05$) are displayed in bold.

Abbreviations: APOE, apolipoprotein E; A β , amyloid beta; CSF, cerebrospinal fluid; MMSE, Mini-Mental State Examination; MRI, magnetic resonance imaging; PET, positron emission tomography.

*Chi-square test.

[†]Independent samples t-test.

[‡]Mann-Whitney U test.

[§]APOE $\epsilon 4/\epsilon 4$ genotype was available in 47 AD cases and 34 control subjects.

[#]MRI was available in 47 AD cases and 35 control subjects.

[¶]CSF was available in 46 AD cases and 29 control subjects.

**Amyloid PET was available in 17 AD cases and 19 control subjects.

vs. 60.6 y, $P < .01$) and had MMSE and MRI atrophy scores indicative of an AD diagnosis. There was no difference between groups for WMH and lacunes indicating similar cerebrovascular loading. By design, all AD cases were amyloid positive and all control participants were amyloid negative based on CSF ($n = 50$), amyloid PET ($n = 11$),

or both ($n = 25$). As expected, APOE $\epsilon 4/\epsilon 4$ carriers were more prevalent in AD cases (70.2% vs. 29.4% in control subjects) [34]. Systolic blood pressure, pulse pressure, and mean arterial pressure were higher in control subjects (independent t-test, $P = .02$, $P < .01$, and $P = .01$, respectively).

3.1. Retinal vasculature parameters

3.1.1. Singapore I Vessel analysis (SIVA)

Seven retinal vascular parameters, previously shown to have good reproducibility [32], showed no group differences between AD patients and control participants (Fig. 2A). Linear regression models assessing relationships between retinal vascular parameters and diagnosis, adjusted for age, and spherical equivalent (SE), showed no disease effect (Table 2). CRVE and FDA were found to be associated with age ($\beta -0.25$, $P = .03$ and $\beta -0.28$, $P = .02$, respectively) (Table 2). Adjusting analysis for systolic blood pressure, pulse pressure, or mean arterial pressure did not alter disease effects.

3.1.2. Choroidal thickness analysis

Choroidal thickness in the macula showed no group differences between AD patients (246.4 μm , ± 82.0) and control participants (251.3 μm , ± 68.6) (independent t-test, $P = .588$) (Fig. 2B). Linear regression models assessing relationships between choroidal thickness and diagnosis, adjusted for age, and SE showed no disease effect ($\beta 0.14$, $P = .24$) but was associated with age ($\beta -0.34$, $P = .01$) and SE ($\beta 0.43$, $P = .01$) (Table 2). Adjusting analysis for different measures of blood pressure did not alter AD disease effects.

3.1.3. OCTA analysis

Vessel density in the inner and outer ring of the macula and the size of the FAZ showed no group differences between AD patients and control participants (Fig. 2C). Linear regression models assessing relationships between OCTA measures and diagnosis, adjusted for age, SE, and quality factor, showed no disease effect for vessel density in the inner ring ($\beta 0.02$, $P = .85$) or outer ring ($\beta -0.10$, $P = .36$), or FAZ ($\beta -0.14$, $P = .33$). Vessel density was, however, strongly associated with quality factor (inner ring [$\beta 0.77$, $P < .001$], outer ring [$\beta 0.65$, $P < .001$]), unlike FAZ ($\beta -0.04$, $P = .81$) (Table 2). Adjusting analysis for different measures of blood pressure did not alter AD disease effects.

3.2. Relationships between retinal vascular parameters and white matter hyperintensities

To assess relationships between retinal vasculature and intracerebral vascular changes, we correlated retinal vascular parameters with WMH scores on MRI (Fazekas

score), adjusting for age and sex. Vessel density in the outer ring was found to be inversely associated with Fazekas score in AD participants ($\beta -0.64$, $P < .01$), while curvature tortuosity of veins was inversely associated with Fazekas score in control subjects ($\beta -0.56$, $P < .01$). No associations were found between other retinal vascular parameters and WMH scores (Table 3).

3.3. Relationships between retinal vascular parameters and MMSE, CSF $A\beta_{1-42}$, and APOE $\epsilon 4/\epsilon 4$ genotype

Both adjusted and unadjusted for age and sex, no relationships between retinal vascular parameters and MMSE or CSF $A\beta_{1-42}$ were observed. Comparing APOE $\epsilon 4/\epsilon 4$ carriers ($n = 44$) versus noncarriers ($n = 37$), irrespective of diagnosis, no differences in retinal vascular measures were found (independent samples t-test, all $P > .16$).

3.4. Stratified analyses for early- versus late-onset Alzheimer's disease

Stratifying analyses of retinal vascular parameters, choroidal thickness, and OCTA measures for early- versus late-onset AD showed no group differences between the two disease group and controls, or between disease groups.

4. Discussion

In this cross-sectional study using three imaging modalities, we found that there were no group differences in retinal vasculature between well-phenotyped, amyloid confirmed, AD and control cases after correction for age and sex. Stratifying cases for early- versus late-onset AD yielded similar results. Vessel density in the outer ring of the macula was found to be associated with WMH scores on MRI in AD participants, while curvature tortuosity of veins was associated with WMH scores in control subjects.

Our findings of unaltered retinal vascular caliber parameters on fundus photography in AD confirm a recent study that included biomarker confirmed AD cases ($n = 29$) based on amyloid PET imaging [13]. In that same study, decreased FDA was observed in subcortical VCI patients [13]. In contrast, other studies found differences in various retinal vascular parameters in different directions, that include decreased CRVE [35,36], CRAE [36], fractal dimension of the venular network [35-37], FDA [35], cTORTa [37] and increased cTORTa [35], and curvature tortuosity of the venules [35] in AD patients compared to control participants. As these cohorts were larger ($n > 100$ per patient group), it might indicate that the effect size of retinal vascular parameters is small and possibly remained undetected in our study. Alternatively, as previous studies used clinical diagnosis, cohorts could have consisted of dementia cases with a primarily vascular etiology or of cases with relevant vascular copathology. In those cases, retinal (micro)vasculature changes may

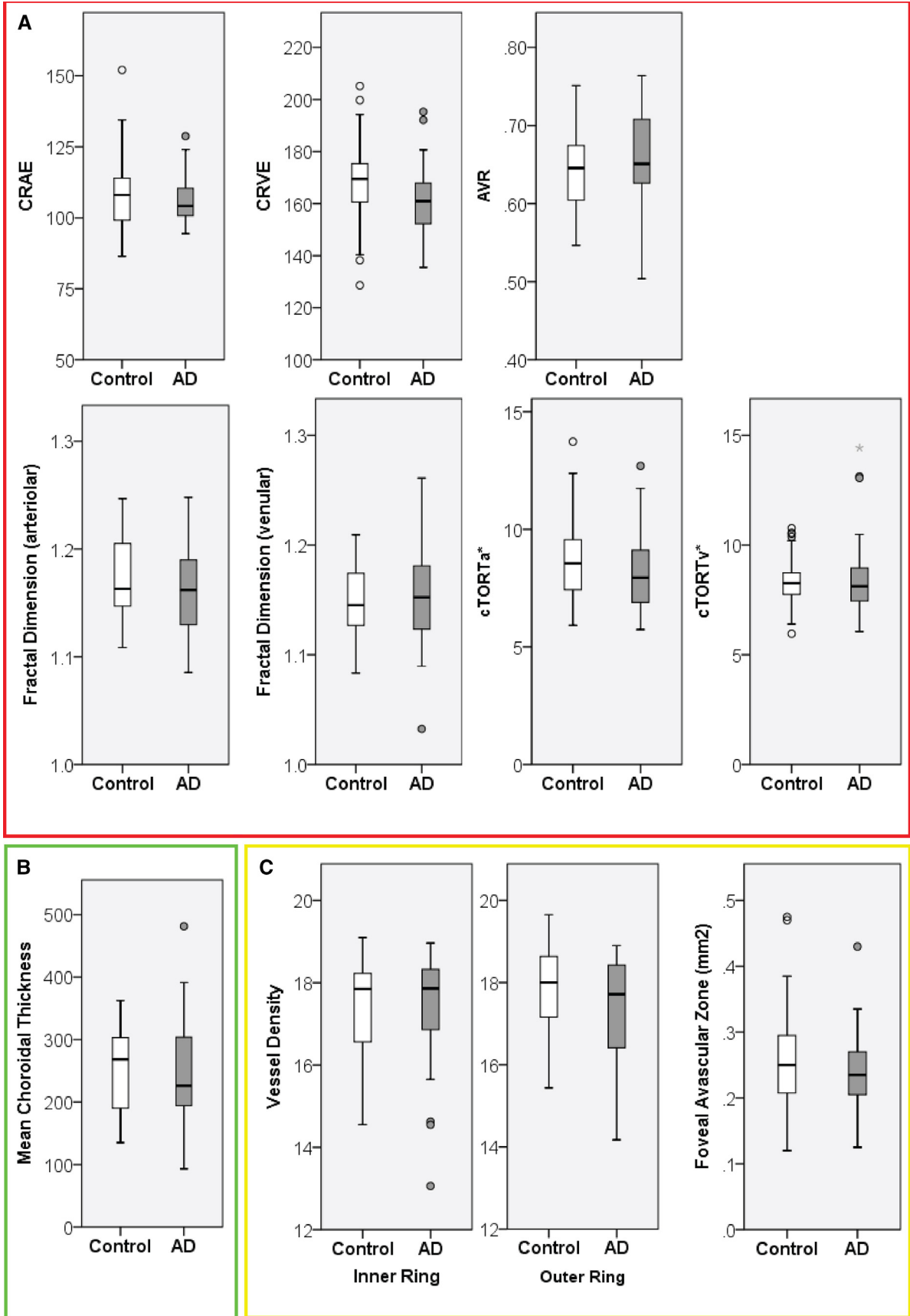


Table 2
Associations of vascular parameters with diagnosis, age, spherical equivalent, and quality factor

Retinal vasculature parameter	Mean (SD)		Age		SE		AD		Quality factor	
	AD	Controls	β	<i>P</i> value	β	<i>P</i> value	β	<i>P</i> value	β	<i>P</i> value
SIVA										
CRAE	106.1 (\pm 7.5)	107.9 (\pm 12.1)	-0.12	.32	0.16	.17	-0.08	.49	n.a.	n.a.
CRVE	161.6 (\pm 12.2)	168.1 (\pm 15.6)	-0.25	.03	0.19	.08	-0.13	.27	n.a.	n.a.
AVR	0.66 (\pm 0.05)	0.64 (\pm 0.06)	0.13	.27	-0.03	.78	0.05	.68	n.a.	n.a.
FDa	1.16 (\pm 0.04)	1.17 (\pm 0.04)	-0.28	.02	0.15	.17	-0.05	.68	n.a.	n.a.
FDv	1.15 (\pm 0.04)	1.15 (\pm 0.04)	-0.15	.21	-0.02	.83	0.14	.23	n.a.	n.a.
cTORTa*	8.1 (\pm 1.5)	8.7 (\pm 1.9)	-0.05	.69	0.04	.74	-0.15	.22	n.a.	n.a.
cTORTv*	8.5 (\pm 1.7)	8.4 (\pm 1.2)	-0.05	.66	0.09	.41	0.06	.61	n.a.	n.a.
EDI-OCT										
Choroidal thickness (μ m)	246.4 (\pm 82.0)	251.3 (\pm 68.6)	-0.34	<.01	0.43	<.01	0.14	.24	n.a.	n.a.
OCTA										
Vessel density inner ring	17.3 (\pm 1.5)	17.4 (\pm 1.2)	0.07	.49	0.08	.37	0.02	.85	0.77	<.01
Vessel density outer ring	17.4 (\pm 1.3)	17.8 (\pm 1.1)	-0.07	.50	0.16	.11	-0.10	.36	0.65	<.01
Foveal avascular zone (mm ²)	0.24 (\pm 0.06)	0.26 (\pm 0.08)	0.04	.81	0.07	.60	-0.14	.33	-0.04	.81

Associations between vascular parameters, age, spherical equivalent, AD diagnosis, and quality factor from linear regression models. Means and standard deviations and uncorrected *P* values are given. Significant associations (*P* < .05) are displayed in bold.

Abbreviations: AD, Alzheimer's disease; AVR, arteriole-to-venule ratio; β , standardized beta; CRAE, central retinal artery equivalent; CRVE, central retinal vein equivalent; cTORTa, curvature tortuosity of the arterioles; cTORTv, curvature tortuosity of the venules; EDI-OCT, enhanced depth imaging optical coherence tomography; FDa, fractal dimension of the arteriolar network; FDv, fractal dimension of the venular network; n.a., not applicable; OCTA, optical coherence tomography angiography; SD, standard deviation; SE, spherical equivalent; SIVA, Singapore I Vessel analysis.

*Values $\times 10^{-5}$.

represent vascular (co)pathology rather than AD-related changes. In the current cohort of amyloid-proven AD participants, clinical, neuroimaging, and fluid biomarkers showed clear disease effects, while an intrinsic AD effect on retinal vasculature was not detected. This queries the clinical use of retinal vascular caliber measurements as AD biomarker.

Using EDI-OCT, we did not observe choroidal thinning as previously described by a number of studies [14–17], despite comparable group size and methodology. Not all studies adjusted their analyses for confounders such as age and spherical equivalent, which could have influenced reported findings, as these confounders showed significant effects on choroidal thickness in the present study contributing to choroidal thinning. Both uncorrected and corrected for age, we found no group differences in choroidal thickness. In addition, as our study did not directly take measurement time point into account, we were not able to control for known diurnal variation of choroidal thickness, that could have possibly influenced our findings, as variation in the order of 15–33 μ m are observed over 24 hours [38–40]. However, distribution of measurement time over the day was comparable between groups in our study, with a mean around midday in both groups.

In this study, describing OCTA measurements in amyloid-positive AD cases for the first time, we found no differences in vessel density and FAZ, while a strong effect of quality factor (QF) on vessel density measurements was observed [$\beta > 0.65$, *P* < .001] in scans with acceptable QFs (between 7 and 10). In contrast, previous studies described a decrease in vessel density and an increase in FAZ surface area in (preclinical) AD cases [18–20]. However, as ophthalmological confounders, age, SE, and QF were not always taken into account, findings of those studies may represent an overestimation of true disease effects.

Given the thorough characterization of our participants, we were able to correlate retinal vascular measurements with WMH on MRI, $A\beta_{1-42}$, Tau_{-181} , and pTau in CSF and MMSE. Venular tortuosity was inversely correlated with WMH scores on MRI in control subjects, while in contrast an earlier study reported a positive correlation between WMH and venular tortuosity in control subjects [32]. Confirming an earlier report, we found an inverse association between macular vessel density and WMH scores in AD, possibly reflecting microvasculature changes in chronic cerebral microinfarction. Similarly, in a recent report, a relation between WMH volume and fractal dimension was observed [13]. These findings need confirmation in larger cohorts, including volumetric

Fig. 2. Vascular parameters measured with fundus photography, EDI-OCT and OCTA. (A) Vascular parameters calculated using Singapore I Vessel Analysis (SIVA) software included central retinal artery equivalent (CRAE), central retinal vein equivalent (CRVE), arteriole–venule ratio (AVR), fractal dimension of the arteriolar network (FDa), fractal dimension of the venular network (FDv), curvature tortuosity of the arterioles (cTORTa, values $\times 10^{-5}$), and curvature tortuosity of the venules (cTORTv, values $\times 10^{-5}$), compared between Alzheimer's disease participants (AD) and controls (HC). (B) Mean choroidal thickness measured in the macula (μ m) in AD. (C) Vascular parameters from optical coherence tomography angiography (OCTA). Vessel density in the inner and outer ring of the Early Treatment in Diabetes Retinopathy Study grid and surface area (mm²) of the foveal avascular zone, compared between AD and control participants. Abbreviation: AD, Alzheimer's disease.

Table 3
Association between vascular parameters and WMHs in the total cohort and stratified for diagnosis, adjusted for age and sex

Retinal vasculature parameter	White matter hyperintensities (Fazekas score)					
	Total		AD		Controls	
	β	<i>P</i> value	β	<i>P</i> value	β	<i>P</i> value
SIVA						
CRAE	0.03	.83	-0.05	.79	0.01	.98
CRVE	-0.06	.560	-0.09	.57	-0.06	.74
AVR	0.07	.57	0.01	.97	0.09	.61
FDa	-0.11	.40	-0.12	.48	-0.14	.47
FDv	-0.01	.94	0.02	.92	-0.21	.29
cTORTa*	0.06	.65	0.27	.12	-0.29	.14
cTORTv*	-0.11	.40	0.10	.57	-0.56	<.01
EDI-OCT						
Choroidal thickness (μm)	-0.07	.58	-0.06	.72	0.02	.92
OCTA						
Vessel density inner ring	-0.29	.09	-0.48	.05	-0.01	.98
Vessel density outer ring	-0.32	<.05	-0.64	<.01	0.18	.40
Foveal avascular zone (mm^2)	-0.18	.29	-0.11	.61	-0.08	.69

Associations between vascular parameters and WMHs (Fazekas score) were assessed using linear regression, adjusted for age and sex. Standardized betas and uncorrected *P* values are given. Significant associations are indicated in bold.

Abbreviations: AD, Alzheimer's disease; AVR, arteriole-to-venule ratio; β , standardized beta; CRAE, central retinal artery equivalent; CRVE, central retinal vein equivalent; cTORTa, curvature tortuosity of the arterioles; cTORTv, curvature tortuosity of the venules; EDI-OCT, enhanced depth imaging optical coherence tomography; FDa, fractal dimension of the arteriolar network; FDv, fractal dimension of the venular network; OCTA, optical coherence tomography angiography; SIVA, Singapore I Vessel analysis.

*Values $\times 10^{-5}$.

measures of WMHs. We found no associations between retinal vascular parameters and CSF biomarkers or MMSE.

A limitation of our study is its relatively small sample size and incomplete collection of all vascular markers, hampering sensitivity for small diseases effects on retinal vasculature. However, despite its relevance for understanding involvement of retinal vasculature in AD pathophysiology, the added value of these small effects for clinical use as a biomarker remain doubtful. As our cohort consisted of cases with relatively little vascular comorbidity, studies in VCI and mixed pathology are warranted to assess the use of retinal vascular parameters to detect vascular (co)-pathology in these populations.

5. Conclusion

Using a multimodal retinal imaging approach in well-characterized amyloid status-confirmed AD and control cases, we found no evidence that retinal vasculature can be used as a noninvasive biomarker for AD.

Acknowledgments

The authors would like to thank all patients, control subjects, and their families for their contributions to our study and Heidelberg and Zeiss for providing their systems for the eye imaging. This study was designed and conducted according to the Declaration of Helsinki, and the study protocol was approved by the Ethical Committee of the Amsterdam UMC, location VUmc. All participants gave their written informed consent for participation in this study in the presence of their caregiver. Research of the Alzheimer Center Amsterdam is part of the neurodegeneration research program of Amsterdam Neuroscience. The Alzheimer Center Amsterdam is supported by Stichting Alzheimer Nederland and Stichting VUmc fonds. The clinical database structure was developed with funding from Stichting Dioraphte. FB is supported by the NIHR biomedical research center at UCL. This research did not receive any specific grant from funding agencies in the public, commercial, or not-for-profit sectors.

Supplementary Data

Supplementary data related to this article can be found at <https://doi.org/10.1016/j.dadm.2019.03.006>.

RESEARCH IN CONTEXT

1. Systematic Review: The authors searched PubMed for all publications assessing retinal microvasculature in Alzheimer's disease (AD). Well-phenotyped cohorts including amyloid status, white matter hyperintensities on magnetic resonance imaging and ophthalmological screening have not previously been examined.
2. Interpretation: In this study, representing the largest cohort with amyloid proven AD cases, we show that retinal vasculature does not discriminate AD from control participants, despite evident changes on clinical, neuroimaging, and cerebrospinal fluid measures, querying the use of retinal vasculature measurements as AD biomarker.
3. Future directions: Future studies in cases with vascular cognitive impairment and mixed pathology are needed to assess the role of retinal vasculature as noninvasive biomarker for vascular (co)-pathology.

References

- [1] Scheltens P, Blennow K, Breteler MMB, de Strooper B, Frisoni GB, Salloway S, et al. Alzheimer's disease. *Lancet* 2016.

- [2] Iturria-Medina Y, Sotero RC, Toussaint PJ, Mateos-Perez JM, Evans AC. Early role of vascular dysregulation on late-onset Alzheimer's disease based on multifactorial data-driven analysis. *Nat Commun* 2016;7:11934.
- [3] Sweeney MD, Kisler K, Montagne A, Toga AW, Zlokovic BV. The role of brain vasculature in neurodegenerative disorders. *Nat Neurosci* 2018;21:1318–31.
- [4] van der Flier WM, Skoog I, Schneider JA, Pantoni L, Mok V, Chen CLH, et al. Vascular cognitive impairment. *Nat Rev Dis Primers* 2018;4:18003.
- [5] Gottesman RF, Schneider AL, Zhou Y, Coresh J, Green E, Gupta N, et al. Association Between Midlife Vascular Risk Factors and Estimated Brain Amyloid Deposition. *JAMA* 2017;317:1443–50.
- [6] Pathological correlates of late-onset dementia in a multicentre, community-based population in England and Wales. NeuroPathology Group of the Medical Research Council Cognitive Function and Ageing Study (MRC CFAS). *Lancet* 2001;357:169–75.
- [7] Prins ND, Scheltens P. White matter hyperintensities, cognitive impairment and dementia: an update. *Nat Rev Neurol* 2015;11:157–65.
- [8] Wardlaw JM, Smith EE, Biessels GJ, Cordonnier C, Fazekas F, Frayne R, et al. Neuroimaging standards for research into small vessel disease and its contribution to ageing and neurodegeneration. *Lancet Neurol* 2013;12:822–38.
- [9] Charidimou A, Boulouis G, Gurol ME, Ayata C, Bacskai BJ, Frosch MP, et al. Emerging concepts in sporadic cerebral amyloid angiopathy. *Brain* 2017;140:1829–50.
- [10] Keage HA, Carare RO, Friedland RP, Ince PG, Love S, Nicoll JA, et al. Population studies of sporadic cerebral amyloid angiopathy and dementia: a systematic review. *BMC Neurol* 2009;9:3.
- [11] Jack CR Jr, Bennett DA, Blennow K, Carrillo MC, Dunn B, Haeberlein SB, et al. NIA-AA Research Framework: Toward a biological definition of Alzheimer's disease. *Alzheimers Dement* 2018;14:535–62.
- [12] McGroary S, Cameron JR, Pellegrini E, Warren C, Doubal FN, Deary IJ, et al. The application of retinal fundus camera imaging in dementia: A systematic review. *Alzheimers Dement (Amst)* 2017; 6:91–107.
- [13] Jung NY, Han JC, Ong YT, Cheung CY, Chen CP, Wong TY, et al. Retinal microvasculature changes in amyloid-negative subcortical vascular cognitive impairment compared to amyloid-positive Alzheimer's disease. *J Neurol Sci* 2018;396:94–101.
- [14] Gharbiya M, Trebbastoni A, Parisi F, Manganiello S, Cruciani F, D'Antonio F, et al. Choroidal thinning as a new finding in Alzheimer's disease: evidence from enhanced depth imaging spectral domain optical coherence tomography. *J Alzheimers Dis* 2014;40:907–17.
- [15] Bayhan HA, Aslan Bayhan S, Celikbilek A, Tanik N, Gurdal C. Evaluation of the chorioretinal thickness changes in Alzheimer's disease using spectral-domain optical coherence tomography. *Clin Exp Ophthalmol* 2015;43:145–51.
- [16] Cunha JP, Proenca R, Dias-Santos A, Melancia D, Almeida R, Aguas H, et al. Choroidal thinning: Alzheimer's disease and aging. *Alzheimers Dement (Amst)* 2017;8:11–7.
- [17] Bulut M, Yaman A, Erol MK, Kurtuluş F, Toslak D, Doğan B, et al. Choroidal Thickness in Patients with Mild Cognitive Impairment and Alzheimer's Type Dementia. *J Ophthalmol* 2016;2016:7291257.
- [18] Bulut M, Kurtuluş F, Gozkaya O, Erol MK, Cengiz A, Akidan M, et al. Evaluation of optical coherence tomography angiographic findings in Alzheimer's type dementia. *Br J Ophthalmol* 2017.
- [19] Jiang H, Wei Y, Shi Y, Wright CB, Sun X, Gregori G, et al. Altered Macular Microvasculature in Mild Cognitive Impairment and Alzheimer Disease. *J Neuroophthalmol* 2018;38:292–8.
- [20] O'Bryhim BE, Apte RS, Kung N, Coble D, Van Stavern GP. Association of Preclinical Alzheimer Disease With Optical Coherence Tomographic Angiography Findings. *JAMA Ophthalmol* 2018;136:1242–8.
- [21] den Haan J, Janssen SF, van de Kreeke JA, Scheltens P, Verbraak FD, Bouwman FH. Retinal thickness correlates with parietal cortical atrophy in early-onset Alzheimer's disease and controls. *Alzheimers Dement (Amst)* 2018;10:49–55.
- [22] van der Flier WM, Scheltens P. Amsterdam Dementia Cohort: performing research to optimize care. *J Alzheimers Dis* 2018;62:1091–111.
- [23] Frisoni GB, Scheltens P, Galluzzi S, Nobili FM, Fox NC, Robert PH, et al. Neuroimaging tools to rate regional atrophy, subcortical cerebrovascular disease, and regional cerebral blood flow and metabolism: consensus paper of the EADC. *J Neurol Neurosurg Psychiatry* 2003;74:1371–81.
- [24] Koedam EL, Lehmann M, van der Flier WM, Scheltens P, Pijnenburg YA, Fox N, et al. Visual assessment of posterior atrophy development of a MRI rating scale. *Eur Radiol* 2011;21:2618–25.
- [25] Scheltens P, Leys D, Barkhof F, Huglo D, Weinstein HC, Vermersch P, et al. Atrophy of medial temporal lobes on MRI in "probable" Alzheimer's disease and normal ageing: diagnostic value and neuropsychological correlates. *J Neurol Neurosurg Psychiatry* 1992; 55:967–72.
- [26] Fazekas F, Chawluk JB, Alavi A, Hurtig HI, Zimmerman RA. MR signal abnormalities at 1.5 T in Alzheimer's dementia and normal aging. *AJR Am J Roentgenol* 1987;149:351–6.
- [27] Duits FH, Teunissen CE, Bouwman FH, Visser PJ, Mattsson N, Zetterberg H, et al. The cerebrospinal fluid "Alzheimer profile": easily said, but what does it mean? *Alzheimers Dement* 2014;10:713–723.e2.
- [28] European Glaucoma Society Terminology and Guidelines for Glaucoma, 4th Edition - Chapter 2: Classification and terminology Supported by the EGS Foundation: Part 1: Foreword; Introduction; Glossary; Chapter 2 Classification and Terminology. *Br J Ophthalmol* 2017;101:73–127.
- [29] Cheung CY, Hsu W, Lee ML, Wang JJ, Mitchell P, Lau QP, et al. A new method to measure peripheral retinal vascular caliber over an extended area. *Microcirculation* 2010;17:495–503.
- [30] Cheung CY, Tay WT, Mitchell P, Wang JJ, Hsu W, Lee ML, et al. Quantitative and qualitative retinal microvascular characteristics and blood pressure. *J Hypertens* 2011;29:1380–91.
- [31] Cheung CY, Zheng Y, Hsu W, Lee ML, Lau QP, Mitchell P, et al. Retinal vascular tortuosity, blood pressure, and cardiovascular risk factors. *Ophthalmology* 2011;118:812–8.
- [32] van de Kreeke JA, Nguyen HT, Konijnenberg E, Tomassen J, den Braber A, Ten Kate M, et al. Retinal and Cerebral Microvasculopathy: Relationships and Their Genetic Contributions. *Invest Ophthalmol Vis Sci* 2018;59:5025–31.
- [33] Kuse Y, Tsuruma K, Mizoguchi T, Shimazawa M, Hara H. Progranulin deficiency causes the retinal ganglion cell loss during development. *Sci Rep* 2017;7:1679.
- [34] Liu CC, Liu CC, Kanekiyo T, Xu H, Bu G. Apolipoprotein E and Alzheimer disease: risk, mechanisms and therapy. *Nat Rev Neuro* 2013;9:106–18.
- [35] Cheung CY, Ong YT, Ikram MK, Ong SY, Li X, Hilal S, et al. Microvascular network alterations in the retina of patients with Alzheimer's disease. *Alzheimers Dement* 2014;10:135–42.
- [36] Frost S, Kanagasigam Y, Sohrahi H, Vignarajan J, Bourgeat P, Salvado O, et al. Retinal vascular biomarkers for early detection and monitoring of Alzheimer's disease. *Translational psychiatry* 2013; 3:e233.
- [37] Williams MA, McGowan AJ, Cardwell CR, Cheung CY, Craig D, Passmore P, et al. Retinal microvascular network attenuation in Alzheimer's disease. *Alzheimers Dement (Amst)* 2015;1:229–35.
- [38] Usui S, Ikuno Y, Akiba M, Maruko I, Sekiryu T, Nishida K, et al. Circadian changes in subfoveal choroidal thickness and the relationship with circulatory factors in healthy subjects. *Invest Ophthalmol Vis Sci* 2012;53:2300–7.
- [39] Tan CS, Ouyang Y, Ruiz H, Satta SR. Diurnal variation of choroidal thickness in normal, healthy subjects measured by spectral domain optical coherence tomography. *Invest Ophthalmol Vis Sci* 2012; 53:261–6.
- [40] Lee SW, Yu SY, Seo KH, Kim ES, Kwak HW. Diurnal variation in choroidal thickness in relation to sex, axial length, and baseline choroidal thickness in healthy Korean subjects. *Retina* 2014; 34:385–93.