

# The Epidemiology of Stargardt Disease in the United Kingdom

Kurt Spiteri Cornish, FRCOphth,<sup>1</sup> Jason Ho, FRCOphth,<sup>2,3</sup> Susan Downes, FRCOphth,<sup>4</sup> Neil W. Scott, PhD,<sup>5</sup> James Bainbridge, PhD,<sup>2,3</sup> Noemi Lois, MD, PhD<sup>6</sup>

**Purpose:** To establish the incidence of Stargardt disease (STGD) in the United Kingdom and define baseline characteristics of newly diagnosed patients.

**Design:** Prospective epidemiologic study undertaken under the auspices of the British Ophthalmological Surveillance Unit (BOSU).

**Participants:** New incident cases of STGD in the United Kingdom reported by ophthalmologists to BOSU during a 12-month period, from June 1, 2012, to June 1, 2013.

**Methods:** Once a new case of STGD was reported, an incident questionnaire was sent to the reporting ophthalmologist, followed by a follow-up questionnaire (when required) 6 months later.

**Main Outcome Measures:** Patient demographics, baseline characteristics including visual acuity, and findings on slit-lamp biomicroscopy, as well as diagnostic technologies undertaken at baseline and their findings, including electrophysiology, fundus autofluorescence, fluorescein angiography, and genetic testing.

**Results:** A total of 81 new cases of STGD were reported during the 12-month period of the study; baseline data were obtained on 70 (86%) of these. These results suggest an annual incidence in the United Kingdom of between 0.110 and 0.128 per 100 000 individuals. The median age of patients at presentation was 27 years, the majority were British (77%), and most (90%) were symptomatic, with a median visual acuity of 0.52 logMAR (Snellen equivalent 20/66).

**Conclusions:** Even considering possible limitations related to incomplete ascertainment, this is the first prospective epidemiology study that provides indication of the incidence of STGD in the United Kingdom. The incidence of STGD estimated herein appears to be lower than that repeatedly quoted in the literature. Fundus autofluorescence and electrophysiology testing are most commonly used for the evaluation of patients with STGD. *Ophthalmology Retina* 2017;1:508-513 © 2017 by the American Academy of Ophthalmology. This is an open access article under the CC BY-NC-ND license (<http://creativecommons.org/licenses/by-nc-nd/4.0/>).

Stargardt disease (STGD) and fundus flavimaculatus (FFM) are synonymous terms used to refer to the same recessively inherited macular dystrophy that affects photoreceptor (PR) and retinal pigment epithelium (RPE).<sup>1,2</sup> The condition was first recognized in 1909 by Stargardt, who described 7 patients with a recessively inherited macular dystrophy characterized by macular atrophy surrounded by deep yellow-white retinal lesions.<sup>1</sup> Other features of the disease include initial loss of vision without clinical signs on funduscopy.<sup>1</sup> The term FFM was later coined by Franceschetti, who described a disease characterized by the presence of “fishlike” (pisciform) deep yellow-white retinal lesions, now referred to as “flecks.”<sup>2</sup> Since the original description, there have been numerous studies evaluating different aspects of this inherited retinal disorder.

The incidence of STGD was estimated to be between 1 in 8000 and 1 in 10 000 in the United States.<sup>3</sup> The 1 in 10 000 incidence has been repeatedly quoted in the literature.<sup>3–5</sup> This estimate, however, does not derive from an epidemiology study but rather from Blacharski’s observation that STGD is more common than retinoblastoma (the incidence of which Blacharski estimated to be 1 in 15 000) but less common than retinitis pigmentosa (which Blacharski

estimated to occur in 1 in 5000 individuals). As new therapies for STGD are currently being investigated, including embryonic stem cell–derived retinal pigment epithelial cell transplantation<sup>6</sup> and *ABCA4* gene replacement therapy using the StarGen,<sup>7</sup> elucidating the incidence and baseline characteristics of patients presenting with this macular dystrophy would be invaluable to plan future therapeutic strategies. This was thus the purpose of the study presented herein. In order to accomplish this purpose, we undertook a prospective population-based epidemiologic study to determine the incidence of STGD in the United Kingdom and gain knowledge on the baseline characteristics of patients presenting with this retinal disorder.

## Methods

The study was conducted in accordance with the tenets of the Declaration of Helsinki. Ethical approval was sought and obtained from the North of Scotland National Research Ethics Service and the NHS Grampian Research and Development Committees before the initiation of the study.

Patients with newly diagnosed STGD (new incident cases) were identified prospectively through active surveillance by the British

Ophthalmological Surveillance Unit (BOSU) during a 12-month period from July 2012 to June 2013, both inclusive. This surveillance scheme involves all ophthalmologists in the United Kingdom (consultants and associate specialists). Before the study was initiated, the BOSU informed ophthalmologists about the new ocular conditions under investigation (STGD), including the case definition. For the purpose of the study, STGD was defined as a recessively inherited retinal dystrophy presenting at any age with a number of characteristics, which include macular changes (mottling, bull's-eye appearance, and/or atrophy) and/or retinal flecks (active or resorbed) with relative peripapillary sparing. An active fleck is defined as an accumulation of yellow material at the level of the RPE, which appears as an area of hypofluorescence on fundus fluorescein angiography (FFA) and as an area of increased signal on autofluorescence (AF) imaging. A resorbed fleck is defined as a small focus of depigmentation or atrophy in the RPE, appearing as an area of hyperfluorescence on FFA and reduced AF signal.

Genetic confirmation (i.e., presence of disease-causing variations in both alleles of the *ABCA4*) was not required for the diagnosis of the cases reported. The diagnosis was made by findings on clinical examination (as per the above description) and ancillary studies including pattern and full-field electroretinography (PERG and FFERG, respectively), fluorescein angiography, and fundus AF. A flat or very reduced PERG (with or without FFERG abnormalities), dark choroid on FFA, and multiple foci or reduced or increased signal on fundus AF imaging with relative peripapillary sparing would be suggestive of the diagnosis. Consultation with national experts on inherited retinal diseases took place before the initiation of the study to set the case definition used.

At the end of each month, a report card was sent out by BOSU to ophthalmologists in the United Kingdom (UK); ophthalmologists then returned the card to BOSU specifying whether a new case had been seen during that month (or whether this had not been the case). After case notification, a study card with the case definition and incident questionnaire was sent to the reporting ophthalmologists by the research group. If the reporting ophthalmologist indicated that further investigations were planned for the patient, a further follow-up questionnaire was sent 6 months after receipt of the incident questionnaire. For this study, units that had not reported cases but that were covering a population sufficiently large to have been expected to have evaluated a case of STGD were independently contacted to confirm the absence of incident STGD cases during the 12-month study period.

Before the initiation of the study, retinal specialists from all over the UK, who were thought to form largely the group that would be most likely reporting new incident cases, were approached and informed about the upcoming study and asked to provide feedback on the study card (case definition) and questionnaires developed for the study. Their input was incorporated in the final materials for the study.

The incident questionnaire collected data on age of onset, gender, ethnicity, family history, and symptoms at presentation. Baseline examination findings including best-corrected visual acuity and fundus features and results of ancillary studies including electrophysiology, AF, FFA, and genetic testing, if available, were also sought. Ophthalmologists were specifically questioned in the incident questionnaire as to whether further testing was planned in the reported case and, if so, follow-up questionnaires were sent at 6 months to collect the results of these tests. To avoid possible reporting duplications related to the fact that patients could be diagnosed in one center and referred to a tertiary center specializing in the diagnosis and evaluation of patients with inherited retinal disorders, nonidentifiable details (date of birth and first part of

postcode) were collected from each patient in the incident questionnaire. In the event that a patient was referred to a different hospital, the 2 separate questionnaires would have the same patient details and would be counted as 1 single patient, if this was confirmed to be the case. Reporting ophthalmologists were encouraged to contact KSC or NL in case of doubt about the possible diagnosis of STGD; in some instances, anonymized images and other investigations were, thus, provided to and analyzed by 2 of the authors (KSC and NL) to confirm or exclude the diagnosis of STGD.

## Results

### New Incident Cases Reported

From July 2012 to June 2013 (both months inclusive), a total of 86 cards were returned to BOSU reporting new incident cases. Of these, 5 cases were excluded: 2 because although they were initially thought to be STGD, they were later diagnosed as cone dystrophy and pattern dystrophy by the reporting ophthalmologist; and 3 because they had been diagnosed outside the specified study period. Thus, there were 81 incident cases; baseline data were obtained through the incident questionnaire in 70 of 81 new incident cases (86%), and follow-up data were obtained in 6 of 7 (85.7%) of the 6-month questionnaires sent. During the study period, there were a total of 1251 reporting ophthalmologists for all BOSU studies and the overall card return rate was 74.5%.

### Incidence of Stargardt Disease in the United Kingdom

In 2012, the UK Office for National Statistics projected the population to be 63 700 000. Considering all 81 cases reported to BOSU, the estimated incidence of STGD in the UK would be 0.127 per 100 000 per year (95% confidence interval, 0.099–0.155). If only the 70 cases of STGD for which data were available to the researchers (questionnaires returned) and the diagnosis of STGD confirmed were to be included, then the estimated annual incidence of STGD in the UK would be 0.110 per 100 000 (95% confidence interval, 0.084–0.136) of the general population per year. Therefore these results would suggest an annual incidence of STGD-FFM in the UK of between 0.110 and 0.127 per 100 000 individuals per year.

### Patient Demographics

The majority of reported cases of STGD affected young adults, with a median age of 27 years (mean 27.4 years; range 5–64 years). The majority were white British (77%), with a higher proportion of female subjects affected (61.4%). A summary of the baseline characteristics of incident cases is presented in [Tables 1 to 3](#).

### Symptoms

The vast majority of cases were symptomatic (90.0%), with reduced vision being the most common symptom (80.0%), followed by nyctalopia (12.9%) and photophobia (11.4%).

### Visual Acuity

Visual acuity at presentation was recorded in either Snellen or logarithm of the minimum angle of resolution (logMAR). For the purpose of this study, Snellen visual acuity values were converted into logMAR acuities using standard conversion tables. Visual

Table 1. Clinical Characteristics of 70 Incident Cases of Stargardt Disease at Presentation

Mean age (SD)	27.4 (17.3)
Female, n (%)	43 (61.4)
Ethnicity, n (%)	
White	57 (81.4)
Black	3 (4.3)
Asian Indian	7 (10.0)
Asian	3 (4.3)
Symptoms, n (%)	
Reduced visual acuity	56 (80.0)
Nyctalopia	9 (12.9)
Photophobia	8 (11.4)
Asymptomatic	7 (10.0)
Other	8 (11.4)

SD = standard deviation.

acuity at presentation varied between -0.08 and 2.0 (Snellen equivalent of 20/16 and 20/2000, respectively) with a median visual acuity of 0.52 (20/66). Twenty-one patients (30%) had a visual acuity of 0.30 (20/40) or better in the best-seeing eye; 31 patients (44.3%) had a visual acuity of 0.80 (20/126) or worse.

### Clinical Features on Slit-Lamp Biomicroscopy

The diagnosis of STGD was based on the specific case definition that was published by BOSU for the duration of the study. One of the key features of the disease was the presence of active or resorbed flecks. In our study, 50 patients (71%) had active retinal flecks in the macula and/or midperipheral retina of 1 or both eyes. In 7 of these 50 patients, flecks were only detected on AF imaging; the rest were evident on slit-lamp biomicroscopy. In the remaining 20 patients in whom flecks were not present, the diagnosis of STGD was supported by a family history of STGD (n = 7) (details in Table 4), confirmed *ABCA4* mutations on genetic analysis (n = 3), or the presence of a severely reduced (flat) PERG (n = 11).

In the majority of patients (n = 38, 54.3%), active macular flecks were present, as identified clinically (n = 36), on AF

Table 2. Visual Acuity and Fundus Features\* in 70 Incident Cases of Stargardt Disease

Feature	N (%)
Visual acuity, Snellen (logMAR)	
6/12 (0.30) or better	41
6/18 (0.48) to 6/60 (1.0)	81
6/60 (1.0) or worse	16
Macular findings	
None	3 (4.3)
Pigment mottling	20 (28.6)
Bull's-eye appearance	17 (24.3)
Atrophy	26 (37.1)
Flecks	36 (51.4)
Midperipheral/peripheral retinal findings	
None	52 (74.3)
Flecks	7 (10.0)
Atrophy	3 (4.3)
Other	3 (4.3)

logMAR = logarithm of the minimum angle of resolution.

\*Findings based on slit-lamp biomicroscopy alone.

Table 3. Retinal Imaging Results

	N (%)
Fundus autofluorescence*	
Macula	
Normal	0 (0)
Reduced signal (atrophy)	17 (53.1)
Foci of increased signal	18 (56.3)
Foci of reduced signal	7 (21.9)
Midperipheral/peripheral retina	
Normal	24 (75.0)
Reduced signal (atrophy)	3 (9.4)
Foci of increased signal	4 (12.5)
Foci of reduced signal	0 (0)
Fundus fluorescein angiogram†	
Normal	1 (7.1)
Dark choroid	12 (85.7)
Window defect (atrophy)	5 (35.7)

\*Fundus autofluorescence features were reported in 32 of 70 patients.

†Fundus fluorescein angiography features were reported in 14 of 70 patients.

imaging (n = 2), or both. The second most common clinical finding at the macula was atrophy, which was detected in over one-third (n = 26, 37.1%) of patients. Macular pigment mottling and bull's-eye maculopathy were present in approximately one-quarter of cases (28.6% and 24.3%, respectively). There were no fundus abnormalities in the midperipheral and peripheral retina in 52 cases (74.3%). The most common sign in the retinal midperiphery was active flecks, present in 12 (17.1%) patients.

### Findings on Fundus Autofluorescence Imaging

AF was the imaging technology most frequently used to aid in the diagnosis of STGD (Table 3). AF imaging was obtained in 32 patients (45.7%); an abnormal AF signal was found in all cases. In the majority of patients (n = 25, 78.2%), foci of increased or reduced AF signal (representing active and resolved flecks, respectively) were detected on AF imaging. A homogeneous background of fundus AF was observed in the midperipheral retina in three-quarters of patients (n = 24, 75.0%). Macular atrophy (central area of reduced AF signal) was present in 17 (53.1%). In 7 of the 32 who underwent AF (21.9%), flecks not visible on clinical examination were identified on AF; in 2 (6.2%), AF identified macular atrophy that was not detected clinically.

Table 4. Family History of Patients with No Retinal Flecks on Examination and on Fundus Autofluorescence Imaging

Patient Number	Positive Family History of STGD
1	2 sisters
2	Father
3	Father
4	1 brother
5	1 sister, 1 maternal uncle
6	1 paternal grandmother
7	1 brother

STGD = Stargardt disease.

## Findings on Fundus Fluorescein Angiography

FFA was infrequently used in the evaluation of patients with STGD (n = 14, 20.0%) and revealed a dark choroid in most cases (n = 12, 85.7%).

## Findings on Electrophysiology

Electrophysiology testing was undertaken in 50 patients (71.4%), including FFERG and PERG. In 45 of these 50 patients (90%), reduced macular function with normal FFERG (group 1 STGD) was found in most cases (n = 51, 73.3%),<sup>8</sup> followed by reduced macular and peripheral cone function (group 2, n = 11, 15.6%)<sup>8</sup> and reduced macular and peripheral rod and cone function (group 3, n = 8, 11.1%).<sup>8</sup> In 5 patients (10%) electrophysiology testing was reported to be within normal limits. In these 5 patients, the diagnosis of STGD was based on the presence of flecks clinically (n = 3), dark choroid on FFA (n = 2), and *ABCA4* mutations (n = 1, 2 disease-causing alleles identified).

## Genetic Testing

Ten patients underwent genetic testing; in 9, *ABCA4* mutations were identified in 1 (n = 4) or 2 (n = 5) alleles. Details of the allelic mutations found were given in 5 patients; these included c.4134C>T and c.5882G>A, p.Ala1038VAL and p.His1406.Tyr, p.C1490Y@c4469G>A and p.L1850P:c.5549T>C, p.R2106H:c.6317G>A, and p.F883L:c.2617T>C and p.L1580S:c.439T>C.

## Discussion

This study represents what we believe to be the first nationwide prospective study aimed at determining the incidence and presenting characteristics of patients with STGD. Herein, the incidence of STGD was found to be 0.127 per 100 000 population per year, which is much lower than the rough estimate of 1 in 10 000 hitherto repeatedly quoted in the literature. There is a possibility that the incidence of STGD may be even higher than that reported herein, because of incomplete ascertainment, which is a known limitation of surveillance studies. Nonetheless, it would be unlikely that the incidence would deviate markedly from that estimated herein. It was not possible to know whether reported cases for which baseline data were not collected (n = 11, 13.6%) (i.e., those cases reported but from which questionnaires were not returned) were indeed cases of STGD. Nonetheless, every effort was made to retrieve all cases seen during the period of the study, not only through active, prospective surveillance by the BOSU but also through contacting the largest reference centers in the UK for inherited retinal diseases. Furthermore, patients initially reported who required additional testing to confirm the diagnosis of STGD were captured in the study by data collected through the 6-month questionnaire.

STGD is often considered a form of juvenile macular dystrophy.<sup>4,9,10</sup> Based on current findings, it seems that most patients present in early adulthood. As reported previously, however, the disease can have an onset at any stage of life, with the oldest patient reported being in the seventh decade of life.<sup>8</sup> Furthermore, it is clear that, although in most patients the disease is confined to the

macula, in a proportion, midperipheral/peripheral anatomic and functional abnormalities are detected and, thus, it would be more appropriate to classify STGD as an “inherited retinal disease” instead of an “inherited macular disease.”

The baseline characteristics identified in incident cases of STGD in this study are overall in agreement with previously published studies. Thus, approximately one-third of patients presented with a vision of 0.30 log-MAR (Snellen equivalent 20/40) or better, consistent with published literature,<sup>8,11–13</sup> and 18.6% (13/70) with a visual acuity of 1.0 (20/200 Snellen equivalent) or worse in the better-seeing eye. Retinal flecks and macular atrophy are the main clinical features of STGD.<sup>1</sup> Herein, 50 patients (71.4%) had retinal flecks; in the vast majority macular and/or midperipheral/peripheral retinal flecks were evident on slit-lamp biomicroscopy (n = 43). However, in some patients (n = 7), flecks were not apparent clinically but were identified on AF imaging. This highlights the importance of this imaging technology to aid the diagnosis of STGD. It is well known, however, as Stargardt pointed out in his original description of the disease, that flecks are not always present at the outset but can develop in time.<sup>1</sup>

The distribution of electrophysiology groups in the current study is very similar to that previously reported,<sup>8</sup> with group 1 (macular dysfunction alone) being the most common and group 3 the least frequent (73% and 11% of patients in the current study with group 1 and group 3 STGD, respectively, compared with 68% and 17% of patients with group 1 and group 3 in our previous study).<sup>8</sup> The pattern of functional loss as determined by FFERG and PERG has implications regarding disease prognosis and hence it is essential for the counseling of patients with STGD.<sup>8,14</sup> Furthermore, the presence of a flat PERG is very characteristic of patients with STGD and can be a very helpful feature, if present, to establish the differential diagnosis between STGD and pattern dystrophy simulating STGD-FFM.<sup>8,15</sup> In the latter, a normal or nearly normal PERG can be identified.<sup>16</sup> The other main feature that allows this differentiation (and differentiating between *ABCA4* and *Peripherin/RDS* [PRPH2] disease) is the presence of a relative peripapillary sparing in STGD,<sup>17</sup> not observed in patients with pattern dystrophy. Interestingly, in a small proportion of patients (n = 5) with STGD presented herein, a normal PERG was reported; 1 of these had confirmed mutations in both alleles of *ABCA4*. Thus, it appears that a normal PERG can be present in a few patients with STGD and, thus, this feature should not rule out the diagnosis of this inherited retinal dystrophy. In patients with severe group 3 disease, the differentiation between STGD and retinitis pigmentosa may be challenging; in both, diffuse retinal abnormalities on slit-lamp biomicroscopy and widespread functional loss (reduced rod and cone function) in electrophysiology testing may be present. Under these circumstances, conventional AF (488 nm excitation) and near-infrared AF (787 nm excitation), as well as the PERG, may be useful disclosing a preserved central island of AF (in conventional or near-infrared AF) and residual



PERG in patients with retinitis pigmentosa and marked reduced AF (in conventional AF and near-infrared AF) and a flat PERG in STGD.<sup>18,19</sup>

The current study suggests that fundus AF imaging and PERG are widely used in the UK to aid in the diagnosis of STGD. It also suggests that fundus AF imaging has superseded the more invasive FFA. During the period of the study, genetic testing was rarely carried out. It is possible that the scarce use of genetic testing related to the fact that, unlike in other monogenic retinal dystrophies, results of *ABCA4* testing are not always easily interpretable. *ABCA4* mutations are not exclusive of patients with STGD but can be identified in other inherited retinal dystrophies, such as bull's-eye maculopathy,<sup>20</sup> cone-rod dystrophy,<sup>21</sup> and retinitis pigmentosa.<sup>22</sup> Furthermore, sequencing of the complete coding sequence in patients with clinical features of STGD often fails to reveal 1 or both *ABCA4* mutations.<sup>5,23–25</sup>

Despite its possible limitations, this study provides a more accurate estimate of the incidence of STGD and a good indication of the presenting characteristics of these patients. The insight gained is valuable to inform the design of therapeutic trials for this condition.

**Acknowledgments.** The authors thank the British Ophthalmological Surveillance Unit (BOSU) for the support received, as well as Mr Barnaby Foot, research coordinator for BOSU, for his help and advice on this project.

The authors thank the following ophthalmologists who assisted with data collection for this study: N. Acharya, S. Anwar, V. Bansal, P.N. Bishop, D. Byles, J.S. Chawla, A. Churchill, M. Clarke, B. Dhillon, M. Ekstein, S. George, J. Gillian, J.T. Gillow, D. Gilmour, R. Gray, P.T.S. Gregory, R. Gupta, S.P. Kelly, I.C. Lloyd, A. Lotery, M. McKibbin, R. MacLaren, G. Menon, A.T. Moore, A. Mulvihill, Y. Osoba, R. Pilling, H. Porooshani, A. Raghu Ram, T. Rimmer, I. Russell-Eggitt, M. Sarhan, R. Savides, S. Shafquat, A. Smith, A. Tekriwal, P. Tesha, P. Watts.

## References

1. Stargardt K. Uber familiare, progressive Degeneration in der Makulagegend des Auges. *Graefes Arch Clin Exp Ophthalmol*. 1909;71:534–550.
2. Franceschetti A, Francois J. Fundus flavimaculatus. *Arch Ophthalmol*. 1965;25:505–530.
3. Blacharski PA. Fundus flavimaculatus. In: Newsome D, ed. *Retinal Dystrophies and Degenerations*. New York, NY: Raven Press; 1988:135–159.
4. Walia S, Fishman GA. Natural history of phenotypic changes in Stargardt macular dystrophy. *Ophthalmic Genet*. 2009;30(2):63–68.
5. Strauss RW, Ho A, Munoz B, et al. The Natural History of the Progression of Atrophy Secondary to Stargardt Disease (ProgStar) Studies: design and baseline characteristics: ProgStar Report No. 1. *Ophthalmology*. 2016;123(4):817–828.
6. Schwartz SD, Regillo CD, Lam BL, et al. Human embryonic stem cell-derived retinal pigment epithelium in patients with age-related macular degeneration and Stargardt's macular dystrophy: follow-up of two open-label phase 1/2 studies. *Lancet*. 2015;385(9967):509–516.
7. Binley K, Widdowson P, Loader J, et al. Transduction of photoreceptors with equine infectious anemia virus lentiviral vectors: safety and biodistribution of StarGen for Stargardt disease. *Invest Ophthalmol Vis Sci*. 2013;54(6):4061–4071.
8. Lois N, Holder GE, Bunce C, Fitzke FW, Bird AC. Phenotypic subtypes of Stargardt macular dystrophy-fundus flavimaculatus. *Arch Ophthalmol*. 2001;119(3):359–369.
9. Ritter M, Zotter S, Schmidt WM, et al. Characterization of Stargardt disease using polarization-sensitive optical coherence tomography and fundus autofluorescence imaging. *Invest Ophthalmol Vis Sci*. 2013;54(9):6416–6425.
10. Fishman GA. Historical evolution in the understanding of Stargardt macular dystrophy. *Ophthalmic Genet*. 2010;31(4):183–189.
11. Rotenstreich Y, Fishman GA, Anderson RJ. Visual acuity loss and clinical observations in a large series of patients with Stargardt disease. *Ophthalmology*. 2003;110(6):1151–1158.
12. Lois N, Holder GE, Fitzke FW, Plant C, Bird AC. Intrafamilial variation of phenotype in Stargardt macular dystrophy-fundus flavimaculatus. *Invest Ophthalmol Vis Sci*. 1999;40(11):2668–2675.
13. Fishman GA, Farber M, Patel BS, Derlacki DJ. Visual acuity loss in patients with Stargardt's macular dystrophy. *Ophthalmology*. 1987;94(7):809–814.
14. Fujinami K, Lois N, Davidson AE, et al. A longitudinal study of Stargardt disease: clinical and electrophysiologic assessment, progression, and genotype correlations. *Am J Ophthalmol*. 2013;155(6):1075–1088.e13.
15. Hadden OB, Gass JDM. Fundus flavimaculatus and Stargardt's disease. *Am J Ophthalmol*. 1976;82:527–539.
16. Downes SM, Fitzke FW, Holder GE, et al. Clinical features of codon 172 RDS macular dystrophy: similar phenotype in 12 families. *Arch Ophthalmol*. 1999;117(10):1373–1383.
17. Lois N, Halfyard AS, Bird AC, Holder GE, Fitzke FW. Fundus autofluorescence in Stargardt macular dystrophy-fundus flavimaculatus. *Am J Ophthalmol*. 2004;138(1):55–63.
18. Robson A, Audo I, Webster A. Fundus autofluorescence in inherited retinal dystrophies: retinitis pigmentosa. In: Lois N, Forrester JV, eds. *Fundus Autofluorescence*. 2nd ed. Philadelphia, PA: Wolters Kluwer; 2016:127–138.
19. Kellner U, Kellner S. Near infrared autofluorescence. In: Lois N, Forrester JV, eds. *Fundus Autofluorescence*. 2nd ed. Philadelphia, PA: Wolters Kluwer; 2016:36–44.
20. Michaelides M, Chen LL, Brantley Jr MA, et al. *ABCA4* mutations and discordant *ABCA4* alleles in patients and siblings with bull's-eye maculopathy. *Br J Ophthalmol*. 2007;91(12):1650–1655.
21. Briggs CE, Rucinski D, Rosenfeld PJ, Hirose T, Berson EL, Dryja TP. Mutations in ABCR (*ABCA4*) in patients with Stargardt macular degeneration or cone-rod degeneration. *Invest Ophthalmol Vis Sci*. 2001;42(10):2229–2236.
22. Mullins RF, Kuehn MH, Radu RA, et al. Autosomal recessive retinitis pigmentosa due to *ABCA4* mutations: clinical, pathologic, and molecular characterization. *Invest Ophthalmol Vis Sci*. 2012;53(4):1883–1894.
23. Fujinami K, Sergouniotis PI, Davidson AE, et al. The clinical effect of homozygous *ABCA4* alleles in 18 patients. *Ophthalmology*. 2013;120(11):2324–2331.
24. Braun TA, Mullins RF, Wagner AH, et al. Non-exonic and synonymous variants in *ABCA4* are an important cause of Stargardt disease. *Hum Mol Genet*. 2013;22(25):5136–5145.
25. Sodi A, Bini A, Passerini I, Forconi S, Menchini U, Torricelli F. Different patterns of fundus autofluorescence related to *ABCA4* gene mutations in Stargardt disease. *Ophthalmic Surg Lasers Imaging*. 2010;41(1):48–53.

## Footnotes and Financial Disclosures

Originally received: February 7, 2017.

Final revision: February 27, 2017.

Accepted: March 3, 2017.

Available online: April 21, 2017. Manuscript no. ORET\_2017\_36.

<sup>1</sup> Sheffield Teaching Hospitals NHS Trust, Sheffield, England, United Kingdom.

<sup>2</sup> Moorfields Eye Hospital, London, England, United Kingdom.

<sup>3</sup> University College London UCL Institute of Ophthalmology, London, England, United Kingdom.

<sup>4</sup> Oxford University Hospitals, Oxford, England, United Kingdom.

<sup>5</sup> Medical Statistics Team, University of Aberdeen, Aberdeen, Scotland, United Kingdom.

<sup>6</sup> Queens University, Belfast, Northern Ireland, United Kingdom.

Financial Disclosure(s):

Supported by the Fighting for Sight Aberdeen (Registered Charity SC033004). The funding organization had no role in the design or conduct of this research.

Conflict of interest: No conflicting relationship exists for any author.

Author Contributions:

Research design: Spiteri Cornish, Lois

Data analysis and/or interpretation: Spiteri Cornish, Ho, Downes, Scott, Lois

Data acquisition and/or research execution: Spiteri Cornish, Ho, Downes, Scott, Bainbridge, Lois

Manuscript preparation: Spiteri Cornish, Lois

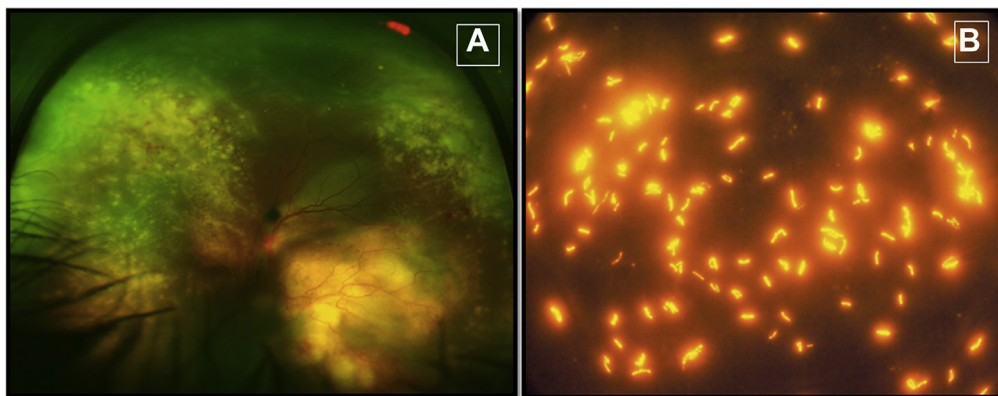
Abbreviations and Acronyms:

**AF** = autofluorescence; **BOSU** = British Ophthalmological Surveillance Unit; **FFA** = fundus fluorescein angiography; **FFERG** = full-field electroretinography; **FFM** = fundus flavimaculatus; **logMAR** = logarithm of the minimum angle of resolution; **PERG** = pattern electroretinography; **PR** = photoreceptor; **RPE** = retinal pigment epithelium; **STGD** = Stargardt disease; **UK** = United Kingdom.

Correspondence:

Noemi Lois, MD, PhD, Wellcome-Wolfson institute for Experimental Medicine, School of Medicine, Dentistry and Biomedical Sciences, Queens University Belfast, 97 Lisburn Road, Belfast BT9 7BL, Northern Ireland, UK. E-mail: [n.lois@qub.ac.uk](mailto:n.lois@qub.ac.uk).

## Pictures & Perspectives



### Auramine-Rhodamine Stain—Detection of *Mycobacteria* in Ocular Fluid

A 38-year-old male patient presented with a large subretinal mass in the left eye. There was massive exudation around the lesion and at the periphery of the fundus (Fig 1A). The right eye was normal. A provisional diagnosis of choroidal granuloma due to tubercular etiology was made. A biopsy sample of the vitreous humor was subjected to various investigations. An auramine-rhodamine stain of vitreous fluid showed acid-fast organisms exhibiting bright orange fluorescence against a dark background, confirming our diagnosis (Fig 1B). (Magnified version available at [www.ophtalmologyretina.org](http://www.ophtalmologyretina.org)).

PRIYA BAJGAI, MS

SURYA PRAKASH SHARMA, MSc

RAMANDEEP SINGH, MS

Advanced Eye Centre, Postgraduate Institute of Medical Education and Research, Chandigarh, India