

Figure 1. Progressive structural and perfusional changes are seen in the macula of glaucomatous

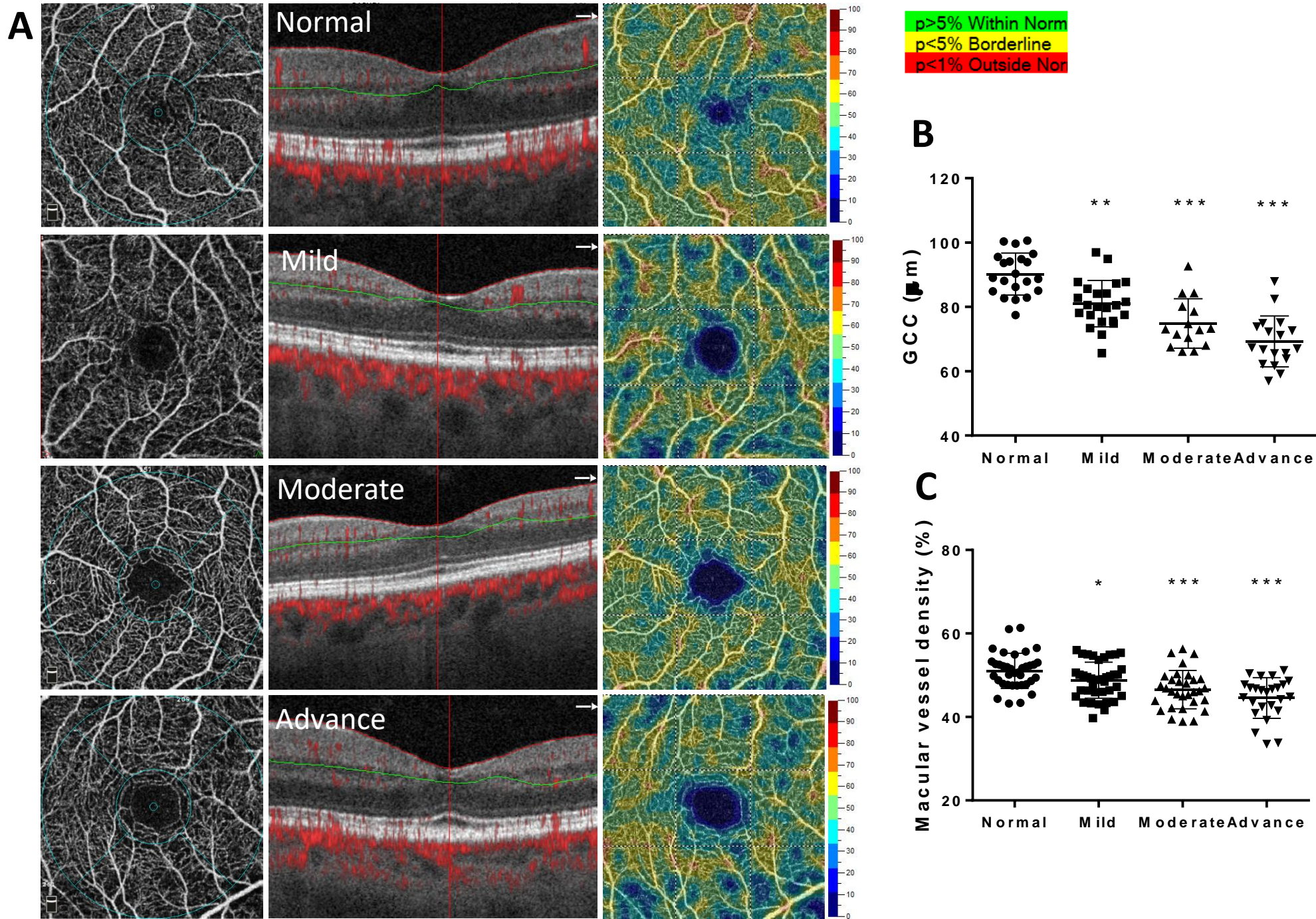


Figure 2. Reduced RNFL thickness is seen at the optic disc in glaucoma

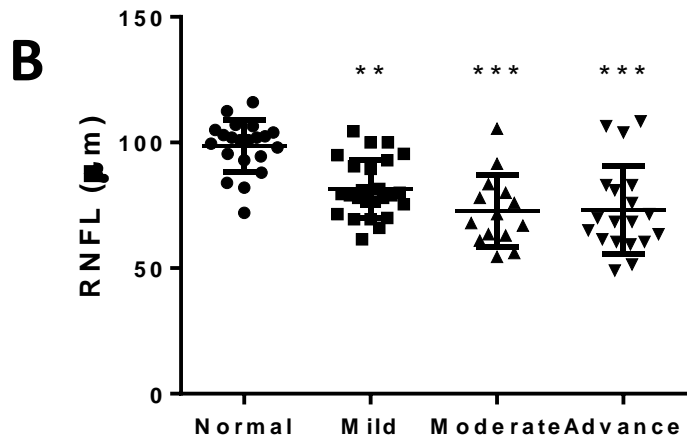
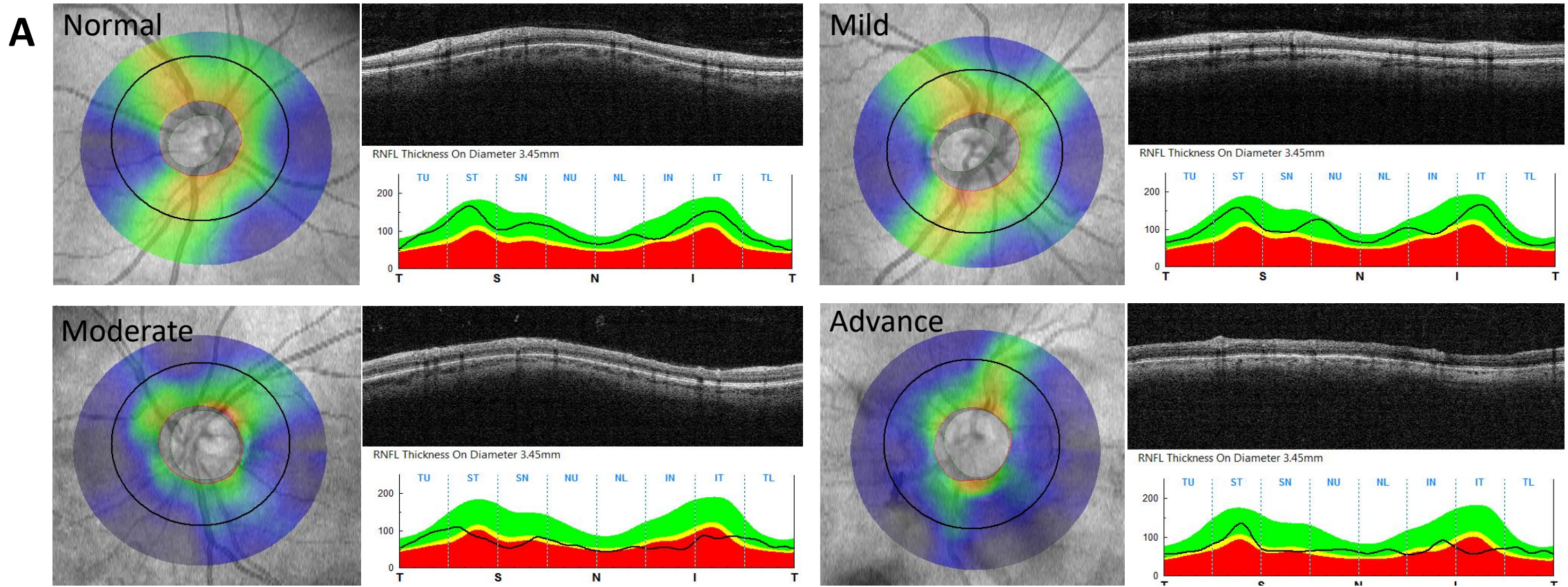
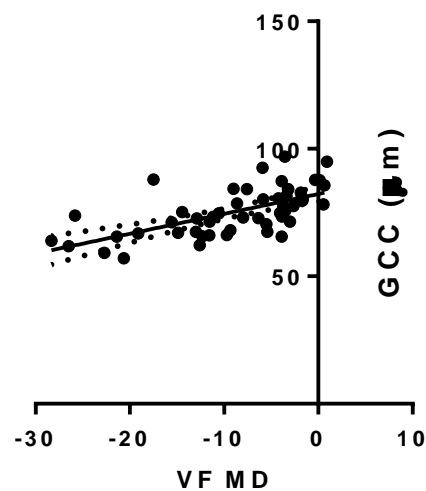
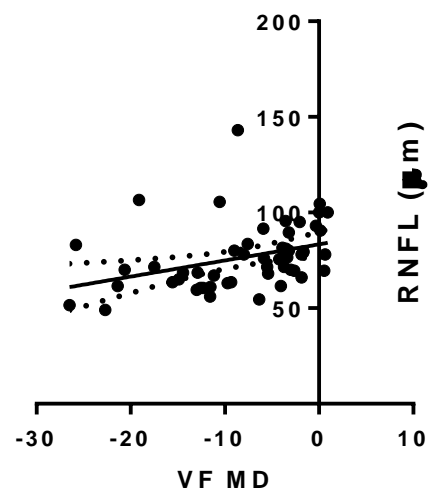


Figure 3. OCTA measurements correlate with visual function in glaucoma

A $p < 0.0001, r = 0.6$



B $p = 0.008, r = 0.36$



C $p = 0.0006, r = 0.3$

