

RESEARCH ARTICLE

The right occipital lobe and poor insight in first-episode psychosis

Diana Tordesillas-Gutierrez^{1,2}*, Rosa Ayesa-Arriola^{2,3}, Manuel Delgado-Alvarado¹, Jennifer L. Robinson^{4,5,6}, Javier Lopez-Morinigo⁷, Jesus Pujol^{2,8}, M. Encarnación Domínguez-Ballesteros⁹, Anthony S. David⁷, Benedicto Crespo-Facorro^{2,3}

1 Neuroimaging Unit, Technological Facilities, Valdecilla Biomedical Research Institute IDIVAL, Santander, Cantabria, Spain, **2** CIBERSAM, Centro Investigación Biomédica en Red de Salud Mental, Santander, Spain, **3** Department of Psychiatry, University Hospital Marqués de Valdecilla, School of Medicine, University of Cantabria-IDIVAL, Santander, Spain, **4** Department of Psychology, Auburn University, Auburn, Alabama, United States of America, **5** Department of Electrical and Computer Engineering, Auburn University, Auburn University Magnetic Resonance Imaging Research Center, Auburn, Alabama, United States of America, **6** Department of Kinesiology, Auburn University, Auburn, Alabama, United States of America, **7** Department of Psychosis Studies, Institute of Psychiatry, Psychology and Neuroscience, King's College London, London, United Kingdom, **8** MRI Research Unit, Hospital del Mar, Barcelona, Spain, **9** UGC Psychiatry, Hospital Virgen Macarena, Sevilla, Spain

* These authors contributed equally to this work.

* diana.tordesillas@idival.org



OPEN ACCESS

Citation: Tordesillas-Gutierrez D, Ayesa-Arriola R, Delgado-Alvarado M, Robinson JL, Lopez-Morinigo J, Pujol J, et al. (2018) The right occipital lobe and poor insight in first-episode psychosis. PLoS ONE 13(6): e0197715. <https://doi.org/10.1371/journal.pone.0197715>

Editor: Kim Q. Do, Universite de Lausanne, SWITZERLAND

Received: January 16, 2018

Accepted: May 2, 2018

Published: June 1, 2018

Copyright: © 2018 Tordesillas-Gutierrez et al. This is an open access article distributed under the terms of the [Creative Commons Attribution License](https://creativecommons.org/licenses/by/4.0/), which permits unrestricted use, distribution, and reproduction in any medium, provided the original author and source are credited.

Data Availability Statement: The Cantabria Ethics Committee placed data sharing restrictions on the image data because the patient images cannot be de-identified. The SPM data has been deposited in a public repository (DOI: [10.5281/zenodo.1211475](https://doi.org/10.5281/zenodo.1211475)). Interested researchers can request the full data set by contacting the The Cantabria Ethics Committee at ceicc@idival.org.

Funding: This work was supported by the Instituto de Salud Carlos III (PI020499, PI050427,

Abstract

Lack of insight is a core feature of non-affective psychosis and has been associated with poorer outcomes. Brain abnormalities underlying lack of insight have been suggested, mostly in the frontal lobe, although previous research showed mixed results. We used a voxel-based morphometry (VBM) analysis in 108 first-episode non-affective psychosis patients to investigate the pattern of brain structural abnormalities related to lack of insight. In addition, 77 healthy volunteers were compared with the patients classified as having poor and good insight. The shortened version of the Scale to Assess Unawareness of Mental Disorder was used to evaluate insight. Patients with poor insight ($n = 68$) compared with patients with good insight ($n = 40$) showed a single significant cluster ($k_c = 5834$; $P_{cFWE} = 0.001$) of reduced grey matter volume (GMV) in the right occipital lobe extending to its lateral and medial surfaces, the cuneus, and the middle temporal gyrus. In addition, GMV at this cluster showed a negative correlation with the score of the SUMD ($r = -0.305$; $p = 0.001$). When comparing patients with poor insight with healthy subjects overall reductions of GMV were found, mainly in frontal and occipital lobes. Hence, poor insight in non-affective psychosis seems to be associated with specific brain abnormalities in the right occipital and temporal cortical regions. Dysfunction in any combination of these areas may contribute to lack of insight in non-affective psychosis. Specifically, the 'right' hemisphere dysfunction underlying impaired insight in our sample is consistent with previously reported similarities between lack of insight in psychosis and anosognosia in neurological disorders.

PI060507, PI14/00639 and PI14/00918) and Fundación Instituto de Investigación Marqués de Valdecilla (NCT0235832, NCT02534363, and APO7/011). No pharmaceutical industry has participated in the study. The funders had no role in study design, data collection and analysis, decision to publish, or preparation of the manuscript.

Competing interests: The authors have declared that no competing interests exist.

Abbreviations: FEP, first episode psychosis; GMV, grey matter volume; SUMD, Scale to Assess Unawareness of Mental Disorder.

1. Introduction

Lack of insight is considered to be a cardinal feature of psychoses [1, 2]. Even at the time of diagnosis, up to 50–80% of first-episode psychosis (FEP) patients show poor insight into having a mental illness, which remains in some cases after psychosis improvement [3–5]. Importantly, lack of insight has been linked with treatment non-adherence [6] and poor long-term outcomes [7].

Little is known about the mechanisms that underlie poor insight in non-affective psychosis. Similarities between lack of insight in schizophrenia and unawareness of neurological deficits, termed anosognosia, has prompted speculation that they might share a common mechanism, which might involve perception and attentional processes. Some authors have linked right hemisphere dysfunction with poor insight [8, 9] in both neurological and psychiatric disorders [1, 10, 11]. It is well established that subjects suffering right perisylvian lesions as a consequence of stroke, for example, are frequently unaware of their left-sided paralysis [12]. Indeed Morgan et al., in one of the first studies using voxel-based morphometry (VBM) in a FEP sample found a cluster of reduced grey matter volume (GMV) in a right hemisphere posterior region which correlated with the inability to relabel psychotic symptoms as abnormal [11].

On the other hand, frontal lobe changes affecting the left or both hemispheres have been found in many neuroimaging studies on insight. Particularly, dorsolateral frontal GMV reduction has been suggested to be critically involved in insight [9, 10]. Furthermore, functional imaging studies showed that the neural network underlying insight involves several regions, encompassing the medial frontal (including cingulate), the parietal, and the temporal cortices [13–18]. Recent VBM studies investigating patients with chronic schizophrenia have confirmed associations between GMV reductions and poor insight in several brain regions [19–21]. In addition, VBM studies in FEP patients have shown volume reductions in the bilateral superior frontal gyri, the right inferior frontal gyrus, the right inferior temporal gyrus, the left cerebellum, the left insula, the bilateral superior temporal gyri, the precentral gyrus, the bilateral posterior cingulate gyrus, and the right cuneus to be associated with poor insight [11, 22]. On the other hand, McFarland et al. [23] found excess of GMV in relation to impaired insight in the caudate, the insula, the putamen, the thalamus, and the cerebellum in first-episode affective and non-affective psychosis patients.

Variability among studies may be due to the small size of the examined samples and/or their clinical heterogeneity. Besides, most of the previous studies just compare patients with healthy controls. Thus, using a large FEP sample, with more statistical power to compare patients with good and poor insight while avoiding the effect of some of the confounders associated with chronic illness, may help to clarify the role of cerebral structures specifically associated with lack of insight.

The aim of the present study was to investigate the pattern of brain structural abnormalities related to lack of insight into mental illness in a large homogeneous sample of first-episode non-affective psychosis patients. We hypothesized that psychosis patients unaware of having a mental illness would show reduced GMV in brain regions associated with self-awareness and, in line with the anosognosia theory, predominantly in the right hemisphere.

2. Methods

2.1. Study setting and financial support

The studied sample was extracted from a large epidemiological program on first-episode psychosis (PAFIP) at University Hospital Marqués de Valdecilla (Santander, Spain). Complete methodological information of this program has been reported elsewhere [24]. Subjects

included in the present investigation were part of an on-going longitudinal intervention with a three-year follow-up (clinical trial NCT02305823). The study was approved by the Cantabria ethics committee in accordance with the international standards for research ethics (Declaration of Helsinki, 1964) and written informed consent was obtained from all the patients. Capacity of consent was determined by the psychiatrist (BC-F) through clinical interview. When minors were included in PAFIP, parents/legal guardians signed a parental permission consent document.

2.2. Subjects

A total of 264 subjects were included in the PAFIP program from February 2001 to December 2007. The inclusion criteria were: (1) age 15–60 years; (2) residence in the catchment area; (3) experiencing a FEP; (4) meeting DSM-IV criteria for schizophrenia, schizophreniform disorder, brief psychotic disorder, or schizoaffective disorder (5) no prior treatment with antipsychotic drugs or, if previously treated, a total life time of adequate antipsychotic treatment of less than 6 weeks. Patients were excluded if they met DSM-IV criteria for (1) drug dependence (except nicotine dependence), (2) mental retardation, or (3) had a history of neurological disease or head injury. Confirmation of diagnoses were done by using the Structured Clinical Interview for DSM-IV (SCID-I) [25], which was administered by an independent psychiatrist 6 months after the initial contact.

Of the 264 patients who entered the program, 153 agreed to participate in the MRI study. Of those who took part in this investigation, 22 did not complete the scan and 3 were excluded because of poor quality data. Twenty subjects of age older than 40 were also excluded, resulting in 108 patients, who were included in the final analysis (see Flow-chart). These patients have been randomly assigned to receive treatment with olanzapine ($n = 24$), risperidone ($n = 22$), ziprasidone ($n = 16$), quetiapine ($n = 16$), aripiprazole ($n = 13$) or haloperidol ($n = 17$) as part of the larger clinical trial. Only two patients had been minimally treated prior to randomization to antipsychotic treatments (one with quetiapine and one with haloperidol). Patients had a baseline structural MRI as soon as they could tolerate the procedure following the initiation of treatment. The mean time between initiation of treatment and MRI was 4.5 weeks (± 3.6 SD).

Healthy volunteers ($n = 77$) were also recruited from the same local area through advertisements. Exclusion criteria were: (1) current or past history of psychiatric, neurological or general medical illnesses, including substance dependence and significant loss of consciousness, which was determined using an abbreviated version of the Comprehensive Assessment of Symptoms and History [26] (2) history of psychosis in first-degree relatives. The selection of healthy controls was performed in order to obtain similar distribution in age, gender, laterality index, drug history and years of education as the patient population.

2.3. Insight assessment

Insight was assessed in the FEP patients at 6 weeks after entering the program with the abbreviated version of the Scale to Assess Unawareness of Mental Disorder (SUMD) [27].

The abbreviated version of SUMD in schizophrenia [28] is a valid and reliable instrument for measuring insight in patients with schizophrenia and may be used by clinicians to accurately assess insight in clinical settings [29]. A short form of a scale is frequently associated with better acceptability in clinical practices. The abbreviated version of the SUMD (9 items): SUMD1: Awareness of a mental disorder, SUMD2: Awareness of the consequences of a mental disorder, SUMD3: Awareness of the effects of drugs, SUMD4: Awareness of a hallucinatory experience, SUMD5: Awareness of delusional ideas, SUMD6: Awareness of disorganised thoughts, SUMD7: Awareness of blunted affect, SUMD8: Awareness of anhedonia, SUMD9:

Awareness of lack of sociability) may appear to be more practical than the long version and could lead to the inclusion of insight assessments as a part of routine clinical practice to offer individualised care. Each item was encoded in the same way with respect to the following modalities: not applicable (response of '0' or missing data), aware (response of '1'), slightly aware/unaware (response of '3'), and seriously unaware (response of '5').

First dimension, and particularly SUMD1 (Awareness of a mental disorder), which correlation is 0.99 with Awareness of disease, was considered the most representative measure of clinical insight, and scores ≤ 1 are considered as good insight[28, 30, 31].

2.4. Clinical assessment

The Brief Psychiatric Rating Scale total[32], the Scale for the Assessment of Negative Symptoms (SANS)[33] and the Scale for the Assessment of Positive Symptoms (SAPS)[34] in their validated Spanish versions were used to assess clinical symptoms at baseline and at the end of weeks 1, 2, 3, 4, and 6 of antipsychotic treatment. The same trained psychiatrist (BC-F) completed the clinical evaluation of patients. Handedness was evaluated by the Edinburgh Inventory [35], right handedness being defined as an Edinburgh laterality index higher than 0.6.

Duration of untreated illness was defined as the time from the first unspecific symptom related to psychosis (for such symptom to be considered, there should be no return to previous stable level of functioning) to the date of initiation of an adequate dose of antipsychotic drug taken regularly. Duration of untreated psychosis was defined as the time from the first continuous (present most of the time) psychotic symptom to initiation of adequate antipsychotic drug treatment. Duration of prodromal period was defined as the period from the first unspecific symptoms related to psychosis (as defined above) to the first continuous (present most of the time) psychotic symptom. These disease-related time intervals were retrospectively evaluated. Age of onset of psychosis was defined as the age of emergence of the first continuous (present most of the time) psychotic symptom.

2.5. MRI data acquisition and image processing

In the first 12 weeks after entering the program patients were offered an MRI scan. High-resolution three-dimensional (3D) T1-weighted images were acquired on a 1.5-T whole-body scanner (SIGNA, GE, Milwaukee, WI, USA) at the University Hospital Marques of Valdecilla, Santander, Spain. Three-dimensional T1-weighted images, using a spoiled gradient-recalled acquisition in the steady state (GRASS) (SPGR) sequence, were acquired in the coronal plane with the following parameters: TE = 5 msec, TR = 24 msec, NEX = 2, rotation angle = 45°, FOV = 26 x 19.5 cm, slice thickness = 1.5 mm and a matrix of 256 x 192.

Voxel Based Morphometry (VBM) [36] was performed using the VBM5 toolbox (<http://dbm.neuro.uni-jena.de/vbm/download/>), an extension of the SPM5 software package (Statistical Parametric Mapping, Wellcome Department of Imaging Neuroscience, London, UK). The VBM pre-processing included the following steps. First, inspection for scanner artifacts and gross abnormalities for each subject, then, images were segmented into grey matter (GM), white matter (WM) and cerebrospinal fluid. In order to improve the quality of segmentation a Hidden Markov Random Field (HMRF) model [37] was applied to the segmented tissue. Afterwards, GM and WM images were imported into the DARTEL toolbox to create a population template from the complete dataset using a high-dimensional diffeomorphic registration algorithm DARTEL [38]. The obtained deformation fields were applied to the GM images to register them to Montreal Neurological Institute (MNI) standard space, followed by modulation in order to assess GMV differences and smoothing with a 5mm FWHM Gaussian kernel (voxel size 1x1x1).

2.6. Statistical analysis

Processed images were analyzed within the framework of the General Linear Model. Several t-test analyses were performed to investigate GMV differences between healthy controls and both insight psychosis patients groups using pairwise contrasts. Age at scan, gender and total intracranial volume were entered as covariates of no interest in the statistical design in order to regress out possible effects of these parameters on between-group volume differences. First, a primary cluster-forming voxel-level threshold of $p < 0.01$ (uncorrected) was applied. Then, a cluster-level inference strategy was employed by evaluating obtained clusters at a cluster-extent threshold of $p < 0.05$ family-wise error (FWE) corrected. All clusters sizes were adjusted for smoothness non-uniformity by means of the VBM5 toolbox[39]. Anatomical regions covered by significant clusters were identified using automated anatomical labeling[40]. Pearson's chi-square for categorical data and Student's t-tests for continuous variables were used to evaluate differences in sociodemographic characteristics between controls and patients. The Statistical Package for Social Science, version 19.0 (SPSS Inc., Chicago, IL, USA), was used for these analysis.

3. Results

3.1. Subjects

First Episode Psychosis (FEP), 40 (37%) individuals presented good insight and 68 (63%) poor insight. The control group included 77 healthy volunteers. Demographic and clinical characteristics of both patient groups and socio-demographically similar healthy control subjects are summarized in Table 1. There were no statistically significant differences in relevant socio-demographic characteristics between groups (all $p > 0.06$, cut off $p > 0.05$).

3.2. VBM analysis

Results regarding differences between healthy subjects and the FEP patients group have been reported elsewhere[41].

3.2.1. Healthy controls versus patients with poor insight. The comparison between healthy controls (HC) ($n = 77$) and patients with poor illness insight ($n = 68$) (HC > poor insight) showed an extensive decrease in GMV in five clusters (Tables 2–6):

Cluster 1: $kc = 42041$; $PcFWE < 0.001$. This large cluster showed bilateral reductions mainly in the occipital and temporal lobes and cerebellum also extended to the parietal lobe and parahippocampalgyrus (Table 2).

Cluster 2: $kc = 30893$; $PcFWE < 0.001$. This cluster showed bilaterally reduction through the frontal lobe (more in right orbitofrontal cortex) and anterior and medial part of the cingulum (Table 3).

Cluster 3: $kc = 16654$; $PcFWE < 0.001$. This cluster is located in the right hemisphere, mainly in the occipital lobe (inferior, middle and superior occipital gyri, Cuneus, lingual gyrus and Calcarine fissure) extending to the middle and inferior temporal gyrus, angular gyrus in the parietal lobe and cerebellum (Table 4).

Cluster 4: $kc = 3825$; $PcFW < 0.001$. 95% of the fourth cluster was located in the right temporal lobe (middle and superior temporal gyri) and extended to the Rolandic operculum and supramarginalgyrus. (Table 5).

Cluster 5: $kc = 3101$; $PcFWE < 0.014$. This cluster showed reductions in the left hemisphere, mainly in the temporal lobe (superior temporal and Heschgyrus), Rolandic operculum, insula and limbic lobe (amygdala and putamen)(Table 6).

3.2.2. Healthy controls versus patients with good insight. Whole brain GMV differences between 40 patients with good insight and 77 HC were identified mainly within cerebellum

Table 1. Socio-demographic and clinical characteristics of the study groups.

	GoodInsight (n = 40)	Poor Insight (n = 68)	HealthyVolunteers (n = 77)	Statistics (dof)
Males, n (%)	28 (70)	46 (67.6)	51 (66.2)	$\chi^2(2) = 0.71; p = 0.92$
Age at MRI, mean (SD), years	27.36 (5.58)	26.49 (5.22)	26.18 (5.76)	F(2) = 0.60; p = 0.55
Handedness, right n (%)	35 (87.5)	56 (86.2)	69(90.8)	$\chi^2(2) = 0.77; p = 0.68$
Height, mean (SD), cm ¹	170.63 (9.40)	169.59 (8.22)	172 (8.35)	F(2) = 1.48; p = 0.23
Age at onset, mean (SD), years	26.77 (5.81)	25.50 (4.96)	-	F(1) = 1.46; p = 0.23
Interval inclusion-mri, mean (SD) weeks	4.13 (3.09)	4.77 (3.62)	-	F(1) = 0.81; p = 0.37
Low parental socioeconomic status, n (%) ²	17 (42.5)	39 (58.2)	32 (43.2)	$\chi^2(2) = 3.92; p = 0.14$
Education, mean (SD), years	10.63 (3.18)	9.56 (2.89)	10.51 (2.59)	F(2) = 2.62; p = 0.08
Alcohol users, n (%) ³	27 (67.5)	45 (66.2)	48 (65.8)	$\chi^2(2) = 0.04; p = 0.98$
Cannabis users, n (%) ⁴	20 (50.0)	41 (60.3)	30 (40.5)	$\chi^2(2) = 5.53; p = 0.06$
Tobaccousers, n (%) ⁴	21 (52.5)	45 (66.2)	44 (59.5)	$\chi^2 = 2.02; p = 0.36$
DUP, mean, (SD), months ⁵	6.06 (8.73)	9.63 (15.00)	-	F(1) = 1.79; p = 0.18
DUI, mean, (SD), months ⁵	15.42 (17.52)	25.33 (31.26)	-	F(1) = 3.39; p = 0.07
DDP, mean, (SD), months ⁵	9.36 (13.88)	15.70 (25.66)	-	F(1) = 2.08; p = 0.15
Symptomatology mean, (SD) (total scores)				
Negativedimension	4.83 (4.98)	4.51 (4.91)	-	F(1) = 0.10; p = 0.75
SANS	7.00 (4.81)	6.01 (5.20)	-	F(1) = 0.96; p = 0.33
SAPS	13.33 (4.15)	13.88 (4.40)	-	F(1) = 0.42; p = 0.52
Positive dimension	7.38 (2.35)	7.40 (2.34)	-	F(1) = 0.002; p = 0.96
Disorganizeddimension	5.95 (3.30)	6.49 (3.46)	-	F(1) = 0.62; p = 0.43

Abbreviations: DUP, duration of untreated psychosis; DUI, duration of untreated illness; DPP, duration of premorbid period; SANS, Scale for the Assessment of Negative Symptoms; SAPS, Scale for the Assessment of Positive Symptoms. Statistics: F test value of ANOVA; χ^2 : value of chi-square test, dof: degrees of freedom.

¹Based in data from 100 first episode of psychosis patients and 68 healthy volunteers.

²Based in data from 100 first episode of psychosis patients and 69 healthy volunteers.

³Based in data from 101 first episode of psychosis patients and 67 healthy volunteers.

⁴Based in data from 101 first episode of psychosis patients and 68 healthy volunteers.

⁵Based in data from 40 patients with good insight and 67 with poor insight.

<https://doi.org/10.1371/journal.pone.0197715.t001>

(tonsil, tuber and culmen), left inferior temporal lobe and fusiform ($k_c = 4039; PcFWE = 0.001$). At $p < 0.05$ cluster-level corrected, one cluster was identified (Table 7 and S1 Fig). No GMV increases were observed when comparing both groups.

3.2.3. Patients with good versus poor insight. The contrast revealed just a single significant cluster ($k_c = 5834; PcFWE = 0.001$) for smaller GMV in patients with poor insight ($n = 68$) compared to patients with good insight ($n = 40$). This was detected in the right occipital lobe, and extended to both its lateral and medial surfaces, and the cuneus. The cluster also extended into the middle temporal gyrus (BA 19 and BA 18) [x,y,z, coordinates 16, -95, 26] as shown in Table 8, Fig 1 and S2 Fig. In addition, we extracted grey matter voxels values at this cluster and using SPSS showed a negative correlation with the groups of insight (Pearson $r = -0.363; p < 0.001$) (Fig 1).

4. Discussion

In the present work the neuroanatomical substrate of poor insight has been studied in a large epidemiological sample of FEP patients. Interestingly, we found a reduction in GMV in the lateral and medial gyrus of the right occipital lobe, the cuneus, and the middle temporal gyrus in patients with poor insight into having a mental illness compared to those with good insight.

Table 2. SPM results; areas where patients with poor illness insight show less grey matter volume than healthy controls (HC > poor IMI).

Anatomical region	Left		Right	
	Extent	T	Extent	T
	K(%clust;%reg)	Max; mean (SD)	K(%clust;%reg)	Max; mean (SD)
<i>Cluster 1: $k_c = 42041$; $P_{cFWE} < 0.001$; $Voxel_{maximum_{x,y,z}}$ [mm]: -50,-76,23; $P_{FWE} = 0.017$</i>				
Calcarine fissure	5521 (13.13; 30.56)	4.59; 2.96 (0.42)	4041 (9.61; 27.14)	5.04; 3.01 (0.51)
Middle occipital gyrus	5411 (12.87; 20.68)	5.18; 2.88 (0.41)		
Lingual gyrus	4370 (10.39; 26.07)	4.86; 2.87 (0.39)	2175 (5.17; 11.82)	3.82; 2.69 (0.28)
Cerebellum Crus I	4300 (10.23; 20.65)	3.86; 2.86 (0.35)		
Cerebellum Crus II	1940 (4.61; 12.80)	3.50; 2.73 (0.25)		
Fusiform gyrus	1614 (3.84; 8.73)	3.55; 2.77 (0.29)	1379 (3.28; 6.85)	3.63; 2.72 (0.27)
Inferior temporal gyrus	1515 (3.60; 5.92)	3.76; 2.75 (0.29)		
Middle temporal gyrus	1498 (3.56; 3.79)	4.56; 2.75 (0.31)		
Cuneus	1126 (2.68; 9.22)	4.33; 2.87 (0.40)	436 (1.04; 3.83)	3.40; 2.77 (0.27)
Superior occipital gyrus	1086 (2.58; 9.94)	3.98; 2.76 (0.27)		
Cerebellum VI	1040 (2.47; 7.67)	3.66; 2.67 (0.24)	45 (0.11; 0.31)	2.77; 2.50 (0.11)
Inferior occipital gyrus	874 (2.08; 11.61)	3.65; 2.66 (0.23)		
Cerebellum VII	863 (2.05; 18.44)	3.42; 2.76 (0.27)		
Cerebellum VIII	716 (1.70; 4.74)	3.48; 2.70 (0.25)		
Angular gyrus	288 (0.69; 3.07)	5.25; 2.93 (0.58)		
Vermis IV-V	205 (0.49; 3.85)	3.75; 2.66 (0.26)		
Cerebellum IV-V	175 (0.42; 1.94)	3.87; 2.85 (0.37)	39 (0.09; 0.57)	3.17; 2.66 (0.24)
ParaHippocampal gyrus	135 (0.32; 1.73)	3.08; 2.63 (0.21)	4 (0.01; 0.04)	2.54; 2.45 (0.08)
Precuneus	9 (0.02; 0.03)	2.77; 2.57 (0.13)	37 (0.09; 0.14)	3.17; 2.58 (0.19)
Inferior parietal gyrus	25 (0.06; 0.13)	3.12; 2.65 (0.24)		
Vermis VI	18 (0.04; 0.61)	3.24; 2.69 (0.29)		

Clusters were characterized by their extent K_c and significance P_{cFWE} , family-wise error corrected for cluster extent and smoothness non-stationary, as well as by the localization x,y,z [mm] and corrected PFW value of the maximum voxel. For anatomical regions within clusters, the number of voxels K , the percentage of the cluster covered %clust, the percentage of the region covered by the cluster %reg.

<https://doi.org/10.1371/journal.pone.0197715.t002>

The present results partially agree with some previous neuroimaging studies of insight in FEP subjects [11, 20, 22, 41, 42]. It has been previously shown that insight correlated with GMV in right frontal superior and inferior gyri, right frontal inferior opercular gyrus, and right inferior temporal gyrus [22]. Symptom relabeling, the ability to identify and attribute the symptoms of psychosis as pathological, has been correlated with GMV decreases in right superior temporal and precentral gyri and right cuneus, and precuneus [11]. Similarly, Cooke et al. [20] found that right superior temporal gyrus GMV had a positive correlation with the ability to recognize experiences as abnormal. In addition, using surface-based analyses, cortical thickness of the inferior occipital gyrus was negatively correlated with mean awareness of illness [42]. Decreases of GMV in other areas such as the cerebellum, the left frontal and temporal cortices and the bilateral posterior cingulate and precuneus have also been related with poor insight [11, 20, 22]. Nonetheless, it seems that there is a predominance of abnormalities in right-sided areas.

Frontal lobe abnormalities have been one of the most consistent findings in the literature regarding insight in psychosis. In fact, structural changes in several areas of the frontal lobe have been linked to poor insight, particularly those affecting the prefrontal cortex [9, 22, 42–45]. And, indeed, frontal lobe mediated cognitive functions have been consistently associated with insight in patients with schizophrenia [8, 46–49]. Prefrontal cortex has been suggested to

Table 3. SPM results; areas where patients with poor illness insight show less grey matter volume than healthy controls. (HC > poor IMI).

Anatomicalregion	Left		Right	
	Extent	T	Extent	T
	K(%clust;%reg)	Max; mean (SD)	K(%clust;%reg)	Max; mean (SD)
<i>Cluster 2: $k_c = 30893$; $P_{cFWE} < 0.001$; $Voxel_{maximum,x,y,z} [mm]: 4,51,26$; $P_{FWE} = 0.042$</i>				
Superior Medial frontal gyrus	8016 (25.95; 33.49)	4.76; 2.80 (0.35)	7784 (25.20; 45.60)	4.83; 2.78 (0.34)
Middle frontal gyrus			2135 (6.91; 5.23)	3.78; 2.79 (0.30)
Supplementary motor area	1899 (6.15; 11.06)	4.86; 2.83 (0.38)	1657 (5.36; 8.74)	4.58; 2.83 (0.42)
Anterior cingulum	436 (1.41; 3.89)	3.71; 2.86 (0.37)	1634 (5.29; 15.56)	3.82; 2.80 (0.34)
Superior frontal gyrus	863 (2.79; 3.00)	4.53; 2.79 (0.35)	1578 (5.11; 4.86)	4.59; 2.79 (0.30)
MiddlesectionCingulum	1303 (4.22; 7.39)	4.43; 2.85 (0.39)	435 (1.41; 2.80)	3.75; 2.83 (0.35)
Middleorbitofrontalgyrus			837 (2.71; 10.31)	3.50; 2.82 (0.29)
Medial orbitofrontalgyrus	750 (2.43; 13.04)	3.48; 2.75 (0.27)	555 (1.80; 8.10)	3.47; 2.78 (0.30)
Inferior orbitofrontalgyrus			539 (1.74; 3.95)	3.31; 2.62 (0.21)
Inferior frontal gyrus, triangular part			168 (0.54; 0.98)	3.51; 2.65 (0.22)

Clusters were characterized by their extent K_c and significance P_{cFWE} , family-wise error corrected for cluster extent and smoothness non-stationary, as well as by the localization x,y,z [mm] and corrected PFW value of the maximum voxel. For anatomical regions within clusters, the number of voxels K , the percentage of the cluster covered %clust, the percentage of the region covered by the cluster %reg.

<https://doi.org/10.1371/journal.pone.0197715.t003>

mediate insight in psychosis through impairment of a meta-representation of the self or deficits in Theory of Mind [50]. In this regard, medial prefrontal cortex has been consistently associated not only with the attribution of mental states to others but also to that of oneself [51]. However, most of the studies addressing insight in non-affective psychosis compared patients in the chronic phase of schizophrenia with healthy volunteers, which might have introduced the effect of the illness as a confounding factor. For example, a recent study found that

Table 4. SPM results; areas where patients with poor illness insight show less grey matter volume than healthy controls(HC > poor IMI).

Anatomicalregion	Left		Right	
	Extent	T	Extent	T
	K(%clust;%reg)	Max; mean (SD)	K(%clust;%reg)	Max; mean (SD)
<i>Cluster 3: $k_c = 16654$; $P_{cFWE} < 0.001$; $Voxel_{maximum,x,y,z} [mm]: 30,-97,14$; $P_{FWE} = 0.624$</i>				
Middle occipital gyrus			6117 (36.73; 36.45)	3.82; 2.80 (0.32)
Middle temporal gyrus			2727 (16.37; 7.73)	3.86; 2.82 (0.33)
Superior occipital gyrus			2237 (13.43; 19.79)	3.71; 2.74 (0.29)
Inferior temporal gyrus			2104 (12.63; 7.39)	3.50; 2.76 (0.30)
Inferior occipital gyrus			1596 (9.58; 20.17)	3.41; 2.74 (0.24)
Cuneus			599 (3.60; 5.26)	3.51; 2.69 (0.25)
Angular gyrus			199 (1.19; 1.42)	3.62; 2.78 (0.25)
Lingual gyrus			139 (0.83; 0.76)	3.32; 2.63 (0.23)
Fusiformgyrus			53 (0.32; 0.26)	3.06; 2.56 (0.19)
CerebelumCrus I			43 (0.26; 0.20)	3.19; 2.50 (0.15)
Calcarinefissure			40 (0.24; 0.27)	3.03; 2.72 (0.22)
Cerebelum VI			10 (0.06; 0.07)	3.28; 2.76 (0.32)

Clusters were characterized by their extent K_c and significance P_{cFWE} , family-wise error corrected for cluster extent and smoothness non-stationary, as well as by the localization x,y,z [mm] and corrected PFW value of the maximum voxel. For anatomical regions within clusters, the number of voxels K , the percentage of the cluster covered %clust, the percentage of the region covered by the cluster %reg.

<https://doi.org/10.1371/journal.pone.0197715.t004>

Table 5. SPM results; areas where patients with poor illness insight show less grey matter volume than healthy controls (HC > poor IMI).

Anatomicalregion	Left		Right	
	Extent	T	Extent	T
	K(%clust;%reg)	Max; mean (SD)	K(%clust;%reg)	Max; mean (SD)
<i>Cluster 4: $k_c = 3825$; $P_{cFWE} = 0.015$; $Voxel_{maximum\ x,y,z} [mm]: 52,-37,4$; $P_{FWE} = 0.981$</i>				
Superior temporal gyrus			2552 (66.71; 10.16)	3.76; 2.80 (0.27)
Middle temporal gyrus			1084 (28.34; 3.07)	3.41; 2.70 (0.26)
Rolandicoperculum			95 (2.48; 0.89)	3.67; 2.79 (0.28)
Supramarginal gyrus			48 (1.25; 0.30)	3.72; 2.93 (0.41)

Clusters were characterized by their extent Kc and significancePcFWE, family-wise error corrected for cluster extent and smoothness non-stationary, as well as by the localization x,y,z [mm] and corrected PFWE value of the maximum voxel. For anatomical regions within clusters, the number of voxels K, the percentage of the cluster covered %clust, the percentage of the region covered by the cluster %reg.

<https://doi.org/10.1371/journal.pone.0197715.t005>

Table 6. SPM results; areas where patients with poor illness insight show less grey matter volume than healthy controls (HC > poor IMI).

Anatomicalregion	Left		Right	
	Extent	T	Extent	T
	K(%clust;%reg)	Max; mean (SD)	K(%clust;%reg)	Max; mean (SD)
<i>Cluster 5: $k_c = 3101$; $P_{cFWE} = 0.041$; $Voxel_{maximum\ x,y,z} [mm]: -43,-6,-8$; $P_{FWE} = 0.999$</i>				
Superior temporal gyrus	1101 (35.50; 5.99)	3.47; 2.72 (0.26)		
Heschlgyrus	747 (24.09; 41.50)	3.50; 2.85 (0.31)		
Insula	553 (17.83; 3.72)	3.41; 2.73 (0.27)		
Rolandicoperculum	295 (9.51; 3.72)	3.28; 2.70 (0.24)		
Amygdala	17 (0.55; 0.97)	2.75; 2.55 (0.11)		

Clusters were characterized by their extent Kc and significancePcFWE, family-wise error corrected for cluster extent and smoothness non-stationary, as well as by the localization x,y,z [mm] and corrected PFWE value of the maximum voxel. For anatomical regions within clusters, the number of voxels K, the percentage of the cluster covered %clust, the percentage of the region covered by the cluster %reg.

<https://doi.org/10.1371/journal.pone.0197715.t006>

Table 7. SPM results of grey matter analysis between patients with good illness insight and healthy controls (HC > good IMI).

Anatomicalregion	Left		Right	
	Extent	T	Extent	T
	K(%clust;%reg)	Max; mean (SD)	K(%clust;%reg)	Max; mean (SD)
<i>Cluster 1: $k_c = 4039$; $P_{cFWE} = 0.001$; $Voxel_{maximum\ x,y,z} [mm]: -51,-54,-34$; $P_{FWE} = 0.059$</i>				
CerebelumCrus I	3061 (75.79; 14.70)	4.99; 3.31 (0.60)		
CerebelumCrus II	458 (11.34; 3.02)	4.06; 3.09 (0.46)		
Cerebelum VI	191 (4.73; 1.41)	3.18; 2.60 (0.18)		
CerebelumVIIb	131 (3.24; 2.80)	3.82; 2.89 (0.38)		
Inferior temporal Gyrus	50 (1.24; 0.20)	3.73; 2.95 (0.40)		
Cerebelum VIII	27 (0.67; 0.18)	2.94; 2.57 (0.15)		

Clusters were characterized by their extent Kc and significancePcFWE, family-wise error corrected for cluster extent and smoothness non-stationary, as well as by the localization x,y,z [mm] and corrected PFWE value of the maximum voxel. For anatomical regions within clusters, the number of voxels K, the percentage of the cluster covered %clust, the percentage of the region covered by the cluster %reg.

<https://doi.org/10.1371/journal.pone.0197715.t007>

Table 8. SPM results; areas where patients with poor illness insight show less grey matter volume than patients with good illness insight. (good IMI > poor IMI).

Anatomical region	Left		Right	
	Extent	T	Extent	T
	K(%clust;%reg)	Max; mean (SD)	K(%clust;%reg)	Max; mean (SD)
<i>Cluster 1: $k_c = 5834$; $P_{cFWE} = 0.001$; Voxel maximum x,y,z [mm]: 16,-95,26; $P_{FWE} = 0.306$</i>				
Middle occipital gyrus			2945 (50.48; 17.55)	3.90; 2.87 (0.37)
Superior occipital gyrus			1661 (28.47; 14.69)	4.52; 3.19 (0.51)
Cuneus			466 (7.99; 4.09)	4.05; 2.79 (0.37)
Middle temporal gyrus			420 (7.20; 1.19)	3.24; 2.61 (0.18)

Clusters were characterized by their extent K_c and significance P_{cFWE} , family-wise error corrected for cluster extent and smoothness non-stationary, as well as by the localization x,y,z [mm] and corrected PFWE value of the maximum voxel. For anatomical regions within clusters, the number of voxels K , the percentage of the cluster covered %clust, the percentage of the region covered by the cluster %reg.

<https://doi.org/10.1371/journal.pone.0197715.t008>

schizophrenia patients with poor insight had widespread reductions in GMV as compared to those with preserved insight [52] but this may have been confounded by long-term exposure to neuroleptic drugs[53]. In addition, many of the previous studies adopted a region of interest approach rather than the less constrained whole brain approach. By contrast, our results suggest that differences in GMV due to different insight status are present at the earliest stage of the disease. Using VBM we have shown reductions in GMV in several areas of the frontal lobe when comparing patients with poor insight with healthy controls, but our findings also showed reductions in the temporal and occipital lobes in patients with poor insight compared to those with good insight. Taken together, it could be interpreted that reductions in frontal grey matter may be linked with the illness per se, while temporal and occipital reductions could be more specifically related to lack of insight into psychological (in addition to physical) change.

The right hemisphere predominance of our findings might be explained by the parallelism between insight and anosognosia for left-sided hemiplegia. Patients showing left hemiplegia, left spatial neglect, and anosognosia in comparison with those with hemiplegia and neglect but not anosognosia have lesions specifically associated with anosognosia distributed in right Brodmann’s premotor areas 6 and 44, right motor area 4, and the right somatosensory cortex, and also, although less frequently, in right prefrontal areas such as area 46 and the insula [54]. Indeed, several studies have associated anosognosia with damage of the right hemisphere motor and sensory cortices, the inferior frontal cortex, the insula, and the superior temporal gyrus[55, 56]. It is interesting to note that impaired self-awareness of motor symptoms in Parkinson’s disease patients has also been recently associated with right hemisphere structures [57]. The involvement of right hemisphere structures in anosognosia is complex and it has been suggested that, in addition to playing a key role in integrating somatosensory representations of the current state with an expected healthy state, the right hemisphere network plays a part in comparing a broader set of representations that include psychological and social skills.

The role of medial temporal gyrus in insight deserves comment. Previous studies have shown reductions in this area in patients with poor insight[52] or have correlated its volume with insight in patients with schizophrenia[20, 22]. This part of the temporal lobe has been classically associated with semantic and memory processing [58], and multimodal sensory integration [59]. Of note, it has been suggested that the medial temporal lobe plays a key role encoding episodic experiences during memory formation. Thus, difficulties in this function might hamper incoming corrective information and thus impair the updating of irrational beliefs [60]. In fact, memory impairment has been associated with poor insight in schizophrenia[61].

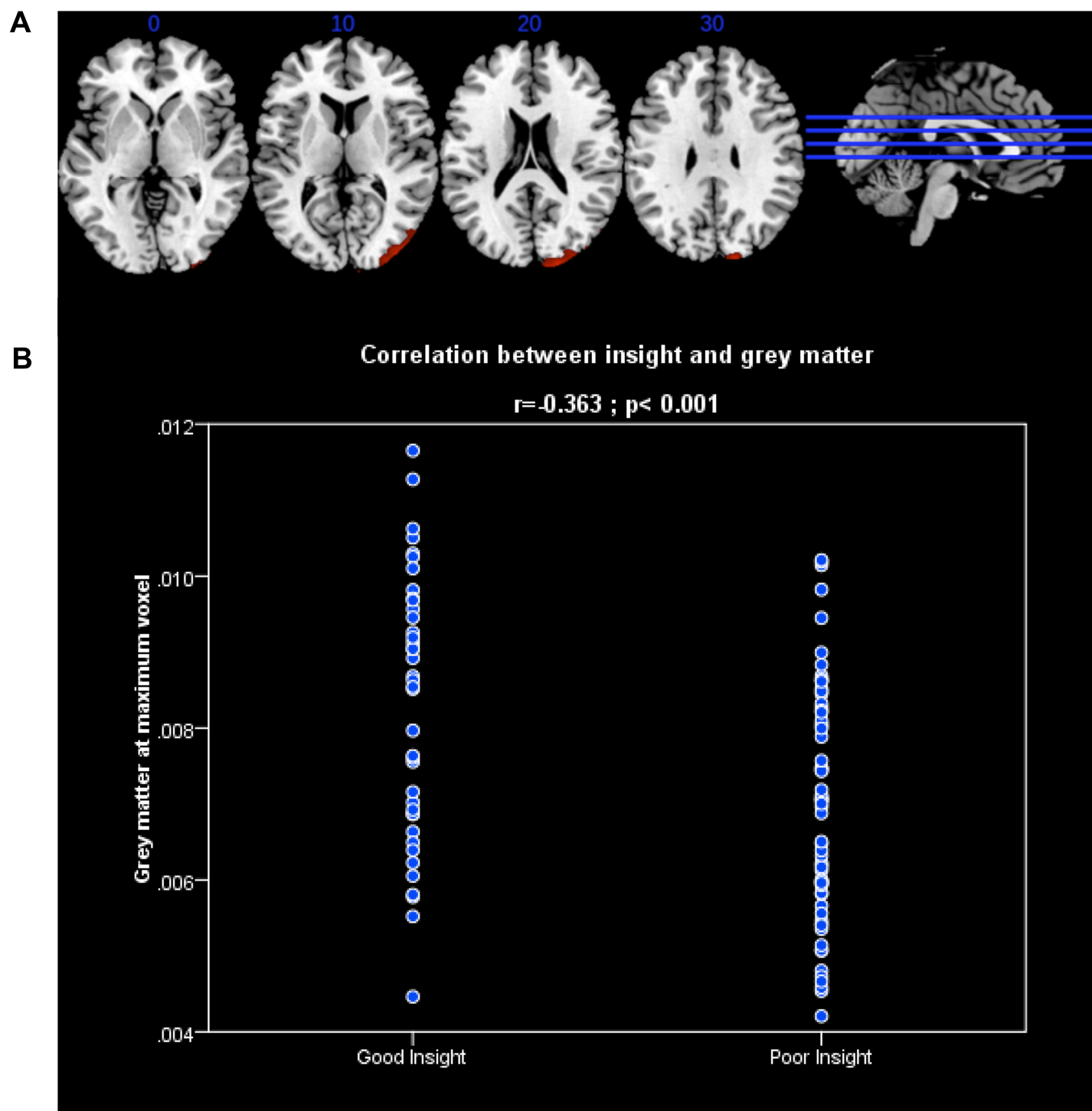


Fig 1. (A) In red are shown the results of the VBM contrast FEP patients with good insight vs. FEP with poor insight, cluster extends through the right middle and superior occipital gyri, cuneus and middle temporal gyrus. All results are in MNI space. (B) Correlation analysis: Grey matter values at maximum voxel of the contrast good insight > poor insight and insight.

<https://doi.org/10.1371/journal.pone.0197715.g001>

Finally, our findings of decreased GMV in the cuneus and medial gyrus of the right occipital lobe, are in keeping with two previous studies. One of them showed reduced GMV at the inferior occipital gyrus in patients with poor insight as compared to those with preserved insight [52], while another found an association between poor insight and volume reduction in a cluster extending posteriorly from the precuneus through the cuneus to the medial occipital gyrus [11]. The role of occipital structures in insight has been scarcely considered. Interestingly, Anton's syndrome, visual anosognosia or denial of loss of vision in the setting of cortical blindness, is derived from bilateral occipital brain damage [62]. Moreover, patients with homonymous hemianopia due to unilateral occipital infarcts, may also be unaware of their visual defect [63]. Thus, occipital cortex might be involved in self-awareness, either in isolation such as in neurological conditions, or in coordination with other right-sided cortical areas in schizophrenia patients. However, further research is warranted to clarify the involvement of this and other herein discussed areas in insight in psychosis.

The main strength of this study lies on the methodology used, particularly in the sample recruitment and design. To the best of our knowledge, this is the largest VBM study carried out with a FEP sample regarding insight. Of most importance, our approach comparing not only patients and healthy controls but also patients with good versus those with poor insight, has allowed us to exclude the overall effect of schizophrenia per se on GMV. However, some limitations should be considered. Although our patients were only treated for a short period of time (mean = 4.53 weeks), the effect of antipsychotic medication on GMV cannot be excluded. In addition, VBM methodology has its own limitations, mainly concerning spatial normalization, smoothing and template [64]. However, a cautious methodological choice of pre-processing parameters and statistical options should lead to more reliable VBM results [65].

In conclusion, lack of insight in non-affective psychosis is associated with specific brain anomalies in right occipital and temporal cortical regions. Consistent with anosognosia in neurological disorders, lack of insight does not seem to be caused by damage to a specific brain area. Rather, insight in psychosis appears to involve a wider brain network, which includes temporal and occipital, and probably the interactions between these areas. Further research is needed to clarify how these brain regions, the circuitries linking them, or a combination of both underlie lack of insight in psychosis.

Supporting information

S1 Fig. In blue GMV reduction in patients with good insight with respect to healthy controls is overlaid over the contrast HC GMV greater than first episode of psychosis patients in red. As it can be seen the cluster falls inside the difference between patients and healthy subjects (overlaid area is shown in purple).

(TIF)

S2 Fig. In blue GMV reduction in patients with poor insight with respect patients with good insight is overlaid on the red contrast that shows GMV reduction in patients with poor insight with respect healthy subjects (overlaid area is shown in purple).

(TIF)

Acknowledgments

The authors wish to thank all PAFIP research team and all patients and family members who participated in the study. We wish to acknowledge IDIVAL Neuroimaging Unit for imaging acquirement.

Author Contributions

Conceptualization: Diana Tordesillas-Gutierrez, Rosa Ayesa-Arriola, Benedicto Crespo-Facorro.

Formal analysis: Diana Tordesillas-Gutierrez, Jennifer L. Robinson.

Funding acquisition: Benedicto Crespo-Facorro.

Investigation: Diana Tordesillas-Gutierrez, Anthony S. David.

Methodology: Diana Tordesillas-Gutierrez, Rosa Ayesa-Arriola, Benedicto Crespo-Facorro.

Software: Diana Tordesillas-Gutierrez.

Supervision: Rosa Ayesa-Arriola, Benedicto Crespo-Facorro.

Visualization: Diana Tordesillas-Gutierrez.

Writing – original draft: Diana Tordesillas-Gutierrez, Rosa Ayesa-Arriola.

Writing – review & editing: Manuel Delgado-Alvarado, Jennifer L. Robinson, Javier Lopez-Morinigo, Jesus Pujol, M. Encarnación Dominguez-Ballesteros, Anthony S. David, Benedicto Crespo-Facorro.

References

1. Amador XF, David AS. Insight and Psychosis: Awareness of Illness in Schizophrenia and Related Disorders: OUP Oxford; 2004.
2. Arango C, Amador X. Lessons learned about poor insight. *Schizophr Bull.* 2011 Jan; 37(1):27–8. <https://doi.org/10.1093/schbul/sbq143> PMID: 21163898
3. Crumlish N, Whitty P, Kamali M, Clarke M, Browne S, McTigue O, et al. Early insight predicts depression and attempted suicide after 4 years in first-episode schizophrenia and schizophreniform disorder. *Acta Psychiatr Scand.* 2005 Dec; 112(6):449–55. <https://doi.org/10.1111/j.1600-0447.2005.00620.x> PMID: 16279874
4. Saeedi H, Addington J, Addington D. The association of insight with psychotic symptoms, depression, and cognition in early psychosis: a 3-year follow-up. *Schizophr Res.* 2007 Jan; 89(1–3):123–8. <https://doi.org/10.1016/j.schres.2006.09.018> PMID: 17097272
5. Ayesa-Arriola R, Morinigo JD, David AS, Perez-Iglesias R, Rodríguez-Sánchez JM, Crespo-Facorro B. Lack of insight 3 years after first-episode psychosis: an unchangeable illness trait determined from first presentation? *Schizophr Res.* 2014 Aug; 157(1–3):271–7. <https://doi.org/10.1016/j.schres.2014.05.011> PMID: 24934905
6. Buckley PF, Wirshing DA, Bhushan P, Pierre JM, Resnick SA, Wirshing WC. Lack of insight in schizophrenia: impact on treatment adherence. *CNS drugs.* 2007; 21(2):129–41. PMID: 17284095
7. Lincoln TM, Lullmann E, Rief W. Correlates and long-term consequences of poor insight in patients with schizophrenia. A systematic review. *Schizophr Bull.* 2007 Nov; 33(6):1324–42. <https://doi.org/10.1093/schbul/sbm002> PMID: 17289653
8. Kumar A, Sharma P, Das S, Nath K, Talukdar U, Bhagabati D. Insight in psychotic disorder: relation with psychopathology and frontal lobe function. *Psychopathology.* 2014; 47(1):32–8. <https://doi.org/10.1159/000348486> PMID: 23711569
9. Shad MU, Muddasani S, Prasad K, Sweeney JA, Keshavan MS. Insight and prefrontal cortex in first-episode Schizophrenia. *Neuroimage.* 2004 Jul; 22(3):1315–20. <https://doi.org/10.1016/j.neuroimage.2004.03.016> PMID: 15219603
10. Larøi F, Fannemel M, Ronneberg U, Flekkoy K, Opjordsmoen S, Dullerud R, et al. Unawareness of illness in chronic schizophrenia and its relationship to structural brain measures and neuropsychological tests. *Psychiatry research.* 2000 Nov 20; 100(1):49–58. PMID: 11090725
11. Morgan KD, Dazzan P, Morgan C, Lappin J, Hutchinson G, Suckling J, et al. Insight, grey matter and cognitive function in first-onset psychosis. *The British journal of psychiatry: the journal of mental science.* 2010 Aug; 197(2):141–8.
12. Cocchini G, Beschin N, Cameron A, Fotopoulou A, Della Sala S. Anosognosia for motor impairment following left brain damage. *Neuropsychology.* 2009 Mar; 23(2):223–30. <https://doi.org/10.1037/a0014266> PMID: 19254095

13. Antonius D, Prudent V, Rebani Y, D'Angelo D, Ardekani BA, Malaspina D, et al. White matter integrity and lack of insight in schizophrenia and schizoaffective disorder. *Schizophr Res.* 2011 May; 128(1–3):76–82. <https://doi.org/10.1016/j.schres.2011.02.020> PMID: 21429714
14. Bedford NJ, Surguladze S, Giampietro V, Brammer MJ, David AS. Self-evaluation in schizophrenia: an fMRI study with implications for the understanding of insight. *BMC Psychiatry.* 2012; 12:106. <https://doi.org/10.1186/1471-244X-12-106> PMID: 22876974
15. Kim JJ, Ku J, Lee H, Choi SH, Kim IY. Distinct neural responses used to gain insight into hallucinatory perception in patients with schizophrenia. *Journal of psychiatric research.* 2012 Oct; 46(10):1318–25. <https://doi.org/10.1016/j.jpsychires.2012.06.012> PMID: 22770670
16. Liemburg EJ, van der Meer L, Swart M, Curcic-Blake B, Bruggeman R, Knegtering H, et al. Reduced connectivity in the self-processing network of schizophrenia patients with poor insight. *PLoS One.* 2012; 7(8):e42707. <https://doi.org/10.1371/journal.pone.0042707> PMID: 22912723
17. Raij TT, Riekkari TJ, Hari R. Association of poor insight in schizophrenia with structure and function of cortical midline structures and frontopolar cortex. *Schizophr Res.* 2012 Aug; 139(1–3):27–32. <https://doi.org/10.1016/j.schres.2012.05.011> PMID: 22664168
18. van der Meer L, de Vos AE, Stiekema AP, Pijnenborg GH, van Tol MJ, Nolen WA, et al. Insight in schizophrenia: involvement of self-reflection networks? *Schizophr Bull.* 2013 Nov; 39(6):1288–95.
19. Bassitt DP, Neto MR, de Castro CC, Busatto GF. Insight and regional brain volumes in schizophrenia. *European archives of psychiatry and clinical neuroscience.* 2007 Feb; 257(1):58–62. <https://doi.org/10.1007/s00406-006-0685-z> PMID: 16960651
20. Cooke MA, Fannon D, Kuipers E, Peters E, Williams SC, Kumari V. Neurological basis of poor insight in psychosis: a voxel-based MRI study. *Schizophr Res.* 2008 Aug; 103(1–3):40–51. <https://doi.org/10.1016/j.schres.2008.04.022> PMID: 18539438
21. Ha TH, Youn T, Ha KS, Rho KS, Lee JM, Kim IY, et al. Gray matter abnormalities in paranoid schizophrenia and their clinical correlations. *Psychiatry research.* 2004 Dec 30; 132(3):251–60. <https://doi.org/10.1016/j.psychres.2004.05.001> PMID: 15664796
22. Berge D, Carmona S, Rovira M, Bulbena A, Salgado P, Vilarroya O. Gray matter volume deficits and correlation with insight and negative symptoms in first-psychotic-episode subjects. *Acta Psychiatr Scand.* 2011 Jun; 123(6):431–9. <https://doi.org/10.1111/j.1600-0447.2010.01635.x> PMID: 21054282
23. McFarland J, Cannon DM, Schmidt H, Ahmed M, Hehir S, Emsell L, et al. Association of grey matter volume deviation with insight impairment in first-episode affective and non-affective psychosis. *European archives of psychiatry and clinical neuroscience.* 2013 Mar; 263(2):133–41. <https://doi.org/10.1007/s00406-012-0333-8> PMID: 22673767
24. Pelayo-Teran JM, Perez-Iglesias R, Ramirez-Bonilla M, Gonzalez-Blanch C, Martinez-Garcia O, Pardo-Garcia G, et al. Epidemiological factors associated with treated incidence of first-episode non-affective psychosis in Cantabria: insights from the Clinical Programme on Early Phases of Psychosis. *Early Interv Psychiatry.* 2008 Aug; 2(3):178–87. <https://doi.org/10.1111/j.1751-7893.2008.00074.x> PMID: 21352151
25. First MB, Spitzer RL, Gibbon M, Williams J. Structured clinical interview for DSM-IV-TR Axis I disorders-Non patient edition. New York: New York State Psychiatric Institute 2001.
26. Andreasen NC, Flaum M, Arndt S. The Comprehensive Assessment of Symptoms and History (CASH). An instrument for assessing diagnosis and psychopathology. *Archives of general psychiatry.* 1992 Aug; 49(8):615–23. PMID: 1637251
27. Amador XF, Flaum M, Andreasen NC, Strauss DH, Yale SA, Clark SC, et al. Awareness of illness in schizophrenia and schizoaffective and mood disorders. *Archives of general psychiatry.* 1994 Oct; 51(10):826–36. PMID: 7944872
28. Ruiz A, Pousa E, Duno R, Crosas J, Cuppa S, Garcia C. [Spanish adaptation of the Scale to Assess Unawareness of Mental Disorder (SUMD)]. *Actas Esp Psiquiatr.* 2008 Mar-Apr; 36(2):111–119. PMID: 18365791
29. Michel P, Baumstarck K, Auquier P, Amador X, Dumas R, Fernandez J, et al. Psychometric properties of the abbreviated version of the Scale to Assess Unawareness in Mental Disorder in schizophrenia. *BMC Psychiatry.* 2013 Sep 22; 13:229. <https://doi.org/10.1186/1471-244X-13-229> PMID: 24053640
30. Ayesa-Arriola R, Rodriguez-Sanchez JM, Morelli C, Pelayo-Teran JM, Perez-Iglesias R, Mata I, et al. Insight dimensions in first-episode psychosis patients: clinical, cognitive, pre-morbid and socio-demographic correlates. *Early Interv Psychiatry.* 2011 May; 5(2):140–9. <https://doi.org/10.1111/j.1751-7893.2010.00249.x> PMID: 21352512
31. Trevisi M, Talamo A, Bandinelli PL, Ducci G, Kotzalidis GD, Santucci C, et al. Insight and awareness as related to psychopathology and cognition. *Psychopathology.* 2012; 45(4):235–43. <https://doi.org/10.1159/000329998> PMID: 22627702
32. Overall JE, Gorman DR. The Brief Psychiatric Rating Scale. *Psychol. Rep.* 10:799–821 1962.

33. Andreasen NC. The Scale for the Assessment of Negative Symptoms (SANS). Iowa City: University of Iowa. 1983.
34. Andreasen NC. The Scale for the Assessment of Positive Symptoms (SAPS). Iowa City: University of Iowa. 1984.
35. Oldfield RC. The assessment and analysis of handedness: the Edinburgh inventory. *Neuropsychologia*. 1971 Mar; 9(1):97–113. PMID: [5146491](https://pubmed.ncbi.nlm.nih.gov/5146491/)
36. Ashburner J, Friston KJ. Voxel-based morphometry—the methods. *Neuroimage*. 2000 Jun; 11(6 Pt 1):805–21. <https://doi.org/10.1006/nimg.2000.0582> PMID: [10860804](https://pubmed.ncbi.nlm.nih.gov/10860804/)
37. Cuadra MB, Cammoun L, Butz T, Cuisenaire O, Thiran JP. Comparison and validation of tissue modelization and statistical classification methods in T1-weighted MR brain images. *IEEE Trans Med Imaging*. 2005 Dec; 24(12):1548–65. <https://doi.org/10.1109/TMI.2005.857652> PMID: [16350916](https://pubmed.ncbi.nlm.nih.gov/16350916/)
38. Ashburner J. A fast diffeomorphic image registration algorithm. *Neuroimage*. 2007 Oct 15; 38(1):95–113. <https://doi.org/10.1016/j.neuroimage.2007.07.007> PMID: [17761438](https://pubmed.ncbi.nlm.nih.gov/17761438/)
39. Hayasaka S, Phan KL, Liberzon I, Worsley KJ, Nichols TE. Nonstationary cluster-size inference with random field and permutation methods. *Neuroimage*. 2004 Jun; 22(2):676–87. <https://doi.org/10.1016/j.neuroimage.2004.01.041> PMID: [15193596](https://pubmed.ncbi.nlm.nih.gov/15193596/)
40. Tzourio-Mazoyer N, Landeau B, Papathanassiou D, Crivello F, Etard O, Delcroix N, et al. Automated anatomical labeling of activations in SPM using a macroscopic anatomical parcellation of the MNI MRI single-subject brain. *Neuroimage*. 2002 Jan; 15(1):273–89. <https://doi.org/10.1006/nimg.2001.0978> PMID: [11771995](https://pubmed.ncbi.nlm.nih.gov/11771995/)
41. Tordesillas-Gutierrez D, Koutsouleris N, Roiz-Santianez R, Meisenzahl E, Ayasa-Arriola R, Marco de Lucas E, et al. Grey matter volume differences in non-affective psychosis and the effects of age of onset on grey matter volumes: A voxelwise study. *Schizophr Res*. 2015 May; 164(1–3):74–82. <https://doi.org/10.1016/j.schres.2015.01.032> PMID: [25687531](https://pubmed.ncbi.nlm.nih.gov/25687531/)
42. Buchy L, Ad-Dab'bagh Y, Malla A, Lepage C, Bodnar M, Joober R, et al. Cortical thickness is associated with poor insight in first-episode psychosis. *Journal of psychiatric research*. 2011 Jun; 45(6):781–7. <https://doi.org/10.1016/j.jpsychires.2010.10.016> PMID: [21092987](https://pubmed.ncbi.nlm.nih.gov/21092987/)
43. Flashman LA, McAllister TW, Johnson SC, Rick JH, Green RL, Saykin AJ. Specific frontal lobe subregions correlated with unawareness of illness in schizophrenia: a preliminary study. *J Neuropsychiatry Clin Neurosci*. 2001 Spring; 13(2):255–7. <https://doi.org/10.1176/jnp.13.2.255> PMID: [11449033](https://pubmed.ncbi.nlm.nih.gov/11449033/)
44. Orfei MD, Piras F, Macci E, Caltagirone C, Spalletta G. The neuroanatomical correlates of cognitive insight in schizophrenia. *Soc Cogn Affect Neurosci*. 2013 Apr; 8(4):418–23. <https://doi.org/10.1093/scan/nss016> PMID: [22287264](https://pubmed.ncbi.nlm.nih.gov/22287264/)
45. Sapara A, Cooke M, Fannon D, Francis A, Buchanan RW, Anilkumar AP, et al. Prefrontal cortex and insight in schizophrenia: a volumetric MRI study. *Schizophr Res*. 2007 Jan; 89(1–3):22–34. <https://doi.org/10.1016/j.schres.2006.09.016> PMID: [17097853](https://pubmed.ncbi.nlm.nih.gov/17097853/)
46. Aleman A, Agrawal N, Morgan KD, David AS. Insight in psychosis and neuropsychological function: meta-analysis. *The British journal of psychiatry: the journal of mental science*. 2006 Sep; 189:204–12.
47. Braff DL, Heaton R, Kuck J, Cullum M, Moranville J, Grant I, et al. The generalized pattern of neuropsychological deficits in outpatients with chronic schizophrenia with heterogeneous Wisconsin Card Sorting Test results. *Archives of general psychiatry*. 1991 Oct; 48(10):891–8. PMID: [1929758](https://pubmed.ncbi.nlm.nih.gov/1929758/)
48. Drake RJ, Lewis SW. Insight and neurocognition in schizophrenia. *Schizophr Res*. 2003 Jul 1; 62(1–2):165–73. PMID: [12765757](https://pubmed.ncbi.nlm.nih.gov/12765757/)
49. Lysaker P, Bell M. Work rehabilitation and improvements in insight in schizophrenia. *J Nerv Ment Dis*. 1995 Feb; 183(2):103–6. PMID: [7844571](https://pubmed.ncbi.nlm.nih.gov/7844571/)
50. Osatuke K, Ciesla J, Kasckow JW, Zisook S, Mohamed S. Insight in schizophrenia: a review of etiological models and supporting research. *Compr Psychiatry*. 2008 Jan-Feb; 49(1):70–7. <https://doi.org/10.1016/j.comppsy.2007.08.001> PMID: [18063044](https://pubmed.ncbi.nlm.nih.gov/18063044/)
51. Mitchell JP, Macrae CN, Banaji MR. Dissociable medial prefrontal contributions to judgments of similar and dissimilar others. *Neuron*. 2006 May 18; 50(4):655–63. <https://doi.org/10.1016/j.neuron.2006.03.040> PMID: [16701214](https://pubmed.ncbi.nlm.nih.gov/16701214/)
52. Sapara A, Ffytche DH, Cooke MA, Williams SC, Kumari V. Voxel-based magnetic resonance imaging investigation of poor and preserved clinical insight in people with schizophrenia. *World J Psychiatry*. 2016 Sep 22; 6(3):311–21. <https://doi.org/10.5498/wjp.v6.i3.311> PMID: [27679770](https://pubmed.ncbi.nlm.nih.gov/27679770/)
53. Yue Y, Kong L, Wang J, Li C, Tan L, Su H, et al. Regional Abnormality of Grey Matter in Schizophrenia: Effect from the Illness or Treatment? *PLoS One*. 2016; 11(1):e0147204. <https://doi.org/10.1371/journal.pone.0147204> PMID: [26789520](https://pubmed.ncbi.nlm.nih.gov/26789520/)

54. Berti A, Bottini G, Gandola M, Pia L, Smania N, Stracciari A, et al. Shared cortical anatomy for motor awareness and motor control. *Science*. 2005 Jul 15; 309(5733):488–91. <https://doi.org/10.1126/science.1110625> PMID: 16020740
55. Besharati S, Forkel SJ, Kopelman M, Solms M, Jenkinson PM, Fotopoulou A. The affective modulation of motor awareness in anosognosia for hemiplegia: behavioural and lesion evidence. *Cortex*. 2014 Dec; 61:127–40. <https://doi.org/10.1016/j.cortex.2014.08.016> PMID: 25481471
56. Moro V, Pernigo S, Tsakiris M, Avesani R, Edelstyn NM, Jenkinson PM, et al. Motor versus body awareness: Voxel-based lesion analysis in anosognosia for hemiplegia and somatoparaphrenia following right hemisphere stroke. *Cortex*. 2016 Oct; 83:62–77. <https://doi.org/10.1016/j.cortex.2016.07.001> PMID: 27494375
57. Maier F, Williamson KL, Tahmasian M, Rochhausen L, Ellereit AL, Prigatano GP, et al. Behavioural and neuroimaging correlates of impaired self-awareness of hypo- and hyperkinesia in Parkinson's disease. *Cortex*. 2016 Sep; 82:35–47. <https://doi.org/10.1016/j.cortex.2016.05.019> PMID: 27341471
58. Chao LL, Haxby JV, Martin A. Attribute-based neural substrates in temporal cortex for perceiving and knowing about objects. *Nat Neurosci*. 1999 Oct; 2(10):913–9. <https://doi.org/10.1038/13217> PMID: 10491613
59. Mesulam MM, Mufson EJ. Insula of the old world monkey. I. Architectonics in the insulo-orbito-temporal component of the paralimbic brain. *J Comp Neurol*. 1982 Nov 20; 212(1):1–22. <https://doi.org/10.1002/cne.902120102> PMID: 7174905
60. Fan J, Zhong M, Gan J, Liu W, Niu C, Liao H, et al. Spontaneous neural activity in the right superior temporal gyrus and left middle temporal gyrus is associated with insight level in obsessive-compulsive disorder. *J Affect Disord*. 2017 Jan 1; 207:203–11. <https://doi.org/10.1016/j.jad.2016.08.027> PMID: 27723545
61. Gilleen J, Greenwood K, David AS. Domains of awareness in schizophrenia. *Schizophr Bull*. 2011 Jan; 37(1):61–72. <https://doi.org/10.1093/schbul/sbq100> PMID: 20851850
62. Aldrich MS, Alessi AG, Beck RW, Gilman S. Cortical blindness: etiology, diagnosis, and prognosis. *Ann Neurol*. 1987 Feb; 21(2):149–58. <https://doi.org/10.1002/ana.410210207> PMID: 3827223
63. Celesia GG, Brigell MG, Vaphiades MS. Hemianopic anosognosia. *Neurology*. 1997 Jul; 49(1):88–97. PMID: 9222175
64. Davatzikos C. Why voxel-based morphometric analysis should be used with great caution when characterizing group differences. *Neuroimage*. 2004 Sep; 23(1):17–20. <https://doi.org/10.1016/j.neuroimage.2004.05.010> PMID: 15325347
65. Kubicki M, Shenton ME, Salisbury DF, Hirayasu Y, Kasai K, Kikinis R, et al. Voxel-based morphometric analysis of gray matter in first episode schizophrenia. *Neuroimage*. 2002 Dec; 17(4):1711–9. PMID: 12498745