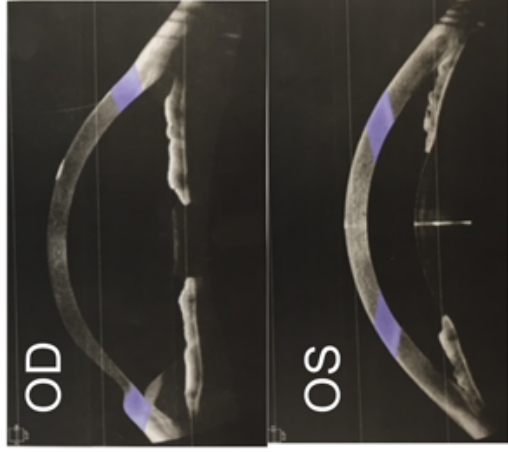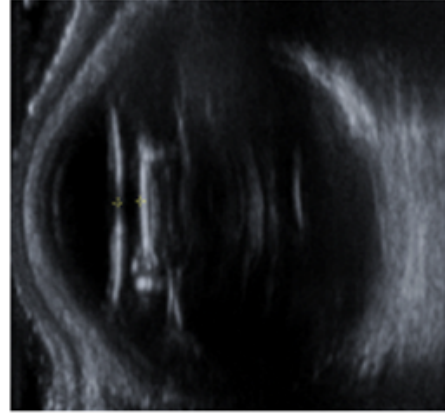


Lens-induced

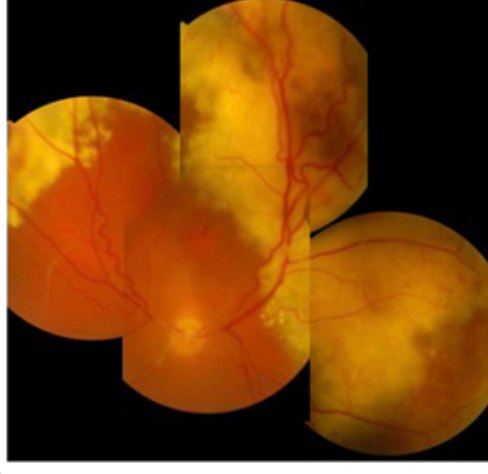
Phacomorphic - lens bulging anteriorly

Possible unstable lens-iris diaphragm - other eye has subluxed IOL

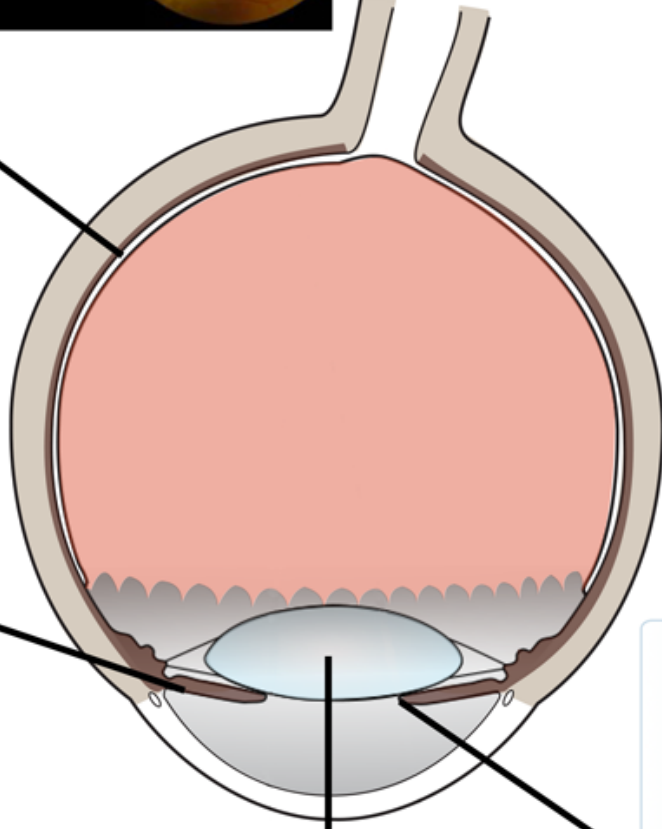


Plateau iris / non-pupil block

Angle remained closed after iridotomy



Retro-lenticular Exudative retinal detachment



Pupil block

Small eye
+5.00 hyperope
Axial length 20.9mm