

## **Risk Factors for Situs Defects and Congenital Heart Disease in Primary Ciliary Dyskinesia**

Sunayna Best BSc MBBS MSc MRCPCH<sup>1,2</sup>, Amelia Shoemark BSc PhD<sup>2</sup>, Bruna Rubbo MBBS MSc<sup>3,4</sup>, Mitali P. Patel BSc MSc<sup>1</sup>, Mahmoud R. Fassad MBBCH MSc<sup>1,5</sup>, Melissa Dixon BSc PhD<sup>2</sup> Andrew V. Rogers BSc PhD<sup>2</sup>, Robert A. Hirst BSc PhD<sup>6</sup>, Andrew Rutman CBiol MRSB<sup>6</sup>, Sarah Olsson BSc<sup>2</sup>, Claire Jackson BSc MSc PhD<sup>3,4</sup>, Patricia Goggin BSc, MMedSci.<sup>3,4</sup>, Simon Thomas BSc PhD<sup>7,8</sup>, Reuben Pengelly MBiol PhD<sup>7</sup>, Thomas Cullup BSc<sup>9</sup>, Eleni Pissaridou BSc MSc<sup>10</sup>, Jane Hayward BSc PhD<sup>1,9</sup>, Alexandros Onoufriadis BSc MSc PhD<sup>11</sup>, Christopher O'Callaghan BMedSci BM BS PhD DM<sup>6,12</sup>, Michael R. Loebinger MA FRCP PhD<sup>13</sup>, Robert Wilson MD FRCP<sup>13</sup>, Eddie Chung MBChB MD FRCPCH<sup>10</sup>, Priti Kenia MBBS, MD Paediatrics, MRCPCH<sup>14</sup>, Victoria L. Doughty BSc PhD<sup>15</sup>, Julene S. Carvalho MD PhD FRCPCH<sup>15,16,17</sup>, Jane S. Lucas BM PhD<sup>3,4</sup>, Hannah M. Mitchison BSc PhD<sup>1\*</sup>, Claire Hogg MBChB, BSc MRCPCH<sup>2\*</sup>

<sup>1</sup>Genetics and Genomic Medicine, University College London, UCL Great Ormond Street Institute of Child Health, London WC1N 1EH, UK

<sup>2</sup> PCD Diagnostic Team, Department of Paediatric Respiratory Medicine, Royal Brompton and Harefield NHS Trust, Sydney Street, London SW3 6NP, UK

<sup>3</sup> Primary Ciliary Dyskinesia Centre, University Hospital Southampton NHS Foundation Trust and Clinical and Experimental Sciences Academic Unit, University of Southampton Faculty of Medicine, Southampton SO17 1BJ, UK

<sup>4</sup> NIHR Southampton Biomedical Research Centre, University of Southampton and University Hospital Southampton NHS Foundation Trust, Southampton SO16 6YD, UK

<sup>5</sup> Human Genetics Department, Medical Research Institute, Alexandria University, Alexandria 21561, Egypt

<sup>6</sup> Centre for PCD Diagnosis and Research, Department of Infection, Immunity and Inflammation, RKCSB, University of Leicester, Leicester LE2 7LX, UK

<sup>7</sup> Human Genetics and Genomic Medicine, Faculty of Medicine, University of Southampton SO17 1BJ, UK

<sup>8</sup> Wessex Regional Genetics Laboratory, Salisbury NHS Foundation Trust, Salisbury District Hospital, Salisbury SP2 8BJ, UK

<sup>9</sup> North East Thames Regional Genetics Service, Great Ormond Street Hospital for Children, London WC1N 3BH, UK

<sup>10</sup> Population, Policy and Practice Programme, University College London Great Ormond Street Institute of Child Health, 30 Guildford Street, London WC1N 1EH, UK

<sup>11</sup> Department of Medical and Molecular Genetics, Division of Genetics and Molecular Medicine, King's College London School of Medicine, Guy's Hospital, London SE1 9RT, UK

<sup>12</sup> Respiratory, Critical Care & Anaesthesia, UCL Great Ormond Street Institute of Child Health, London WC1N 1EH, UK

<sup>13</sup> Host Defence Unit, Royal Brompton and Harefield NHS Trust, Sydney Street, London SW3 6NP, UK

<sup>14</sup> Department of Respiratory Paediatrics, Birmingham Children's Hospital NHS Foundation Trust, Steelhouse Lane, Birmingham B4 6NH, UK

<sup>15</sup> Brompton Centre for Fetal Cardiology, Royal Brompton and Harefield NHS Trust, Sydney Street, London, SW3 6NP, UK

<sup>16</sup> Fetal Medicine Unit, St George's University Hospitals NHS Foundation Trust, Blackshaw Road, Tooting, London SW17 0QT, UK

<sup>17</sup> Molecular & Clinical Sciences Research Institute, St George's, University of London, Cranmer Terrace, London SW17 0RE, UK

\* Shared senior authorship

## Supplementary Methods

### Included Patients and Clinical Data

This is a retrospective cohort study, designed to investigate the prevalence of situs and visceral defects in UK based patients with PCD and determine whether there are any clinical or genetic risk factors for these. Patients eligible had been diagnosed in a specialist UK PCD clinic according to European Respiratory Society (ERS) guidelines including by transmission electron microscopy (TEM), high speed video microscopy, immunofluorescence and nasal nitric oxide measurement<sup>1 2</sup>; a definite diagnosis defined by a characteristic ciliary ultrastructural abnormality detected by TEM or a bi-allelic mutation in a known PCD gene. Genetic testing was conducted using next generation sequencing and PCD was confirmed where bi-allelic mutations in a known PCD gene with predicted or known pathogenicity in both alleles were identified and confirmed by Sanger sequencing. Paediatric and adult patients were identified from three UK PCD clinical centres (London, Birmingham and Southampton) and participants gave written informed consent to take part. Study recruiters attended the monthly PCD outpatient clinics over the course of a decade with eligible patients seen in the clinic on days of recruitment approached to take part. The protocol was approved by the London Bloomsbury Research Ethics Committee (08/H0713/82). Retrospective clinical data were obtained from electronic records and paper notes, including ethnicity, parental consanguinity, TEM reports and imaging reports. Ethnicity was categorised into three groups: South Asian (Indian, Bangladeshi, Pakistani, Sri Lankan), Caucasian and other (other Asian, Black and mixed ethnicity).

### Situs and Organ Defect Classification

Situs classification was performed for all patients in whom the position of at least one thoracic and one abdominal organ was known from chest X-ray and/or other detailed imaging reports. For example, from the chest-X-ray, if the stomach and heart were on the left, the patients were assumed to have SS, and if they were both on the right, they were assumed to have SIT, unless detailed imaging reports were available to provide further clarification. Situs was classified as: (1) situs solitus (SS), defined as normal organ arrangement, (2) situs inversus totalis (SIT), defined as mirror image arrangement of all organs and (3) SA, defined as any abnormal arrangement that was not SS or SIT. The SA group also included cases of apparently isolated dextrocardia or cases with malposition of other organs (e.g. kidney). SS was considered normal situs and SIT and SA were collectively considered abnormal situs.

Organ defect classification was performed on all patients with at least one detailed cardiac (echocardiography, cardiac magnetic resonance imaging (MRI), surgical reports) or abdominal imaging report (abdominal computer tomography (CT), abdominal ultrasound scan (USS), surgical reports). If the patients had undergone surgery, their pre-operative anatomical defect was used for classification. In all cases, available surgical and radiology/echocardiography reports agreed. Only structural congenital abnormalities were included in the classification; acquired abnormalities were not considered. A two-stage classification system was used, as shown in online supplementary **Table S1**. CHD classification was performed first using “CHD present” versus “CHD absent”, modified from previous attempts to classify CHD according to clinical severity<sup>3</sup>. Of note, the “CHD present” category can be further subdivided according to clinical severity into “major” and “simple”. The major CHD category includes those defects classified as “severe” in the International Classification of Disease, ninth revision (ICD-9)<sup>4</sup>, as well as abnormalities

which required significant surgical intervention in the first year of life or long term follow up, excluding patent ductus arteriosus (PDA) and isolated septal defects <sup>3 5</sup>. A similar system is used throughout the UK (<http://www.ucl.ac.uk/nicor>). Patients with CHD also underwent classification according to the modified Botto et al <sup>6</sup> classification of complexity, used in the previous publications of Shapiro et al and Kennedy et al <sup>7-9</sup>.

The organ defect classification was performed second, which included two categories: “laterality defect other than SIT present” and “laterality defect other than SIT absent”. This system was used to label all visceral and vascular abnormalities detected that were not defined as CHD that potentially resulted from ciliary problems during embryogenesis. Isomerism was classified as a laterality defect other than SIT; if patients with isomerism had associated CHD, this was classified separately <sup>10</sup>.

### **Genetic Analysis**

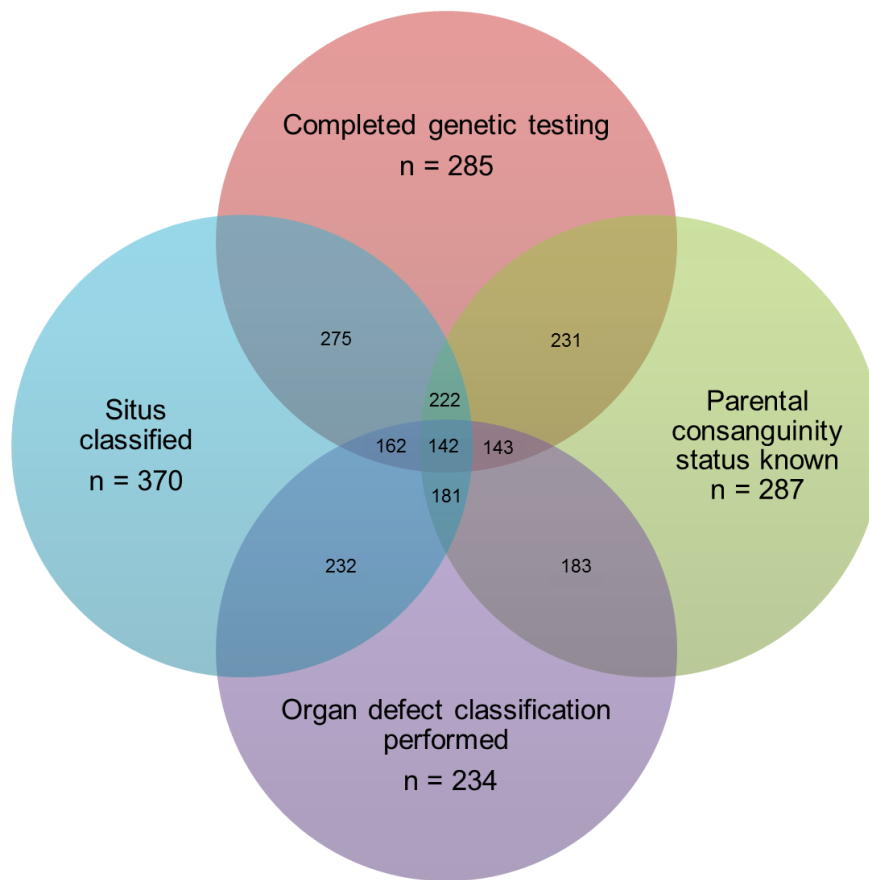
Genetic testing used a variety of gene-mutational analysis performed over a ten-year period: whole exome sequencing was applied in 20% of cases, custom designed ciliopathy gene-panels (TruSeq or Agilent SureSelectXT systems) and a targeted ‘clinical exome’ (Illumina TruSight One) applied in 70% of cases and first line Sanger sequencing of candidate genes applied in 10% of cases <sup>11</sup>. Families were determined to have “solved” genetic testing when bi-allelic mutations in a known PCD gene with predicted or known pathogenicity in both alleles were identified, then confirmed by Sanger sequencing and where possible by familial segregation analysis. The primary genetic literature references used are contained in **Table S2**.

### **Statistical Analysis**

Statistical analysis focussed on associations between clinical and genetic factors and two main outcomes: situs abnormality and CHD and/or laterality defects other than SIT. Analysis was performed using Fisher’s exact test and univariate and multivariable logistic regression modelling. The relative burden of each risk factor was described in odds ratios. The statistical significance level was set to 5%. Data were analysed using Stata Statistical Software (Release 14, College Station, TX: StataCorp LP, 2015).

**Figure S1. Summary of clinical data and genetic test results available for analysis in the 389 confirmed PCD patients in the study**

Shows the number of patients for whom data was available for situs classification and organ defect classification, as well as the number of patients with genetic test results and known parental consanguinity status. Combinations of data from these categories were used for logistic regression modelling. The four categories are not mutually exclusive, several patients fell into multiple categories. Shaded overlapping areas represent where patients had combinations of data available. The central point shows that 142 patients had data within all 4 categories. Not all categories used for the regression analysis are represented, e.g. ethnicity, and subcategories such as functional gene effect are not shown.



**Table S1. Organ defect classification system**

Classification Stage	CHD classification		Laterality defect other than SIT classification	
Categories within classification	CHD absent	CHD present	Laterality defect other than SIT absent	Laterality defect other than SIT present
<b>Included Abnormalities</b>	<ul style="list-style-type: none"> <li>• Normal cardiac anatomy</li> <li>• Abdominal and/or cardiac isomerism without association CHD</li> <li>• Situs inversus without associated CHD</li> </ul>	<p>Usually termed simple CHD</p> <ul style="list-style-type: none"> <li>• ASD</li> <li>• VSD</li> <li>• Isolated valvular stenosis or regurgitation</li> <li>• PDA</li> <li>• Aortopathy</li> </ul> <p>Generally termed major CHD</p> <ul style="list-style-type: none"> <li>• AVSD</li> <li>• TOF</li> <li>• TGA</li> <li>• Truncus arteriosus</li> <li>• Hypoplastic left heart syndrome</li> <li>• Coarctation of the aorta</li> <li>• Tricuspid atresia and other forms of univentricular heart</li> <li>• Pulmonary artery atresia with or without a VSD</li> <li>• Double outlet ventricle</li> <li>• Ebstein's anomaly</li> <li>• Any other CHD requiring significant surgical or catheter intervention in the first year of life, excluding ASD, VSD and PDA</li> </ul>	<ul style="list-style-type: none"> <li>• Normal detailed abdominal imaging report(s) and/or no isomerism detected on cardiac imaging</li> </ul>	<p><b>Incomplete situs inversus:</b></p> <ul style="list-style-type: none"> <li>• Isolated situs inversus thoracalis</li> <li>• Isolated situs inversus abdominalis</li> </ul> <hr/> <p><b>Abdominal visceral abnormalities:</b></p> <ul style="list-style-type: none"> <li>• Intestinal malrotation</li> <li>• Intestinal or biliary atresia</li> <li>• Midline liver</li> <li>• Polysplenia</li> <li>• Asplenia</li> <li>• Structural kidney abnormalities (cystic kidneys, dysplastic kidneys, additional or missing kidneys, malpositioned kidneys)</li> </ul> <hr/> <p><b>Vascular abnormalities:</b></p> <ul style="list-style-type: none"> <li>• Abnormalities of major abdominal vessels (e.g. interrupted IVC, duplicated SVC)</li> </ul> <hr/> <p><b>Abdominal, thoracic or cardiac isomerism:</b></p> <ul style="list-style-type: none"> <li>• Left isomerism</li> <li>• Right isomerism</li> </ul>

CHD = Congenital Heart Disease. ASD = atrial septal defect. VSD = ventricular septal defect. PDA = patent ductus arteriosus. AVSD = atrial-ventricular septal defect. TOF = tetralogy of Fallot. TGA = transposition of the great arteries. IVC = inferior vena cava. SVC = superior vena cava.

**Table S2. Genes known to cause PCD**

PCD gene	Associated ultrastructural defect	Functional gene effect category	Previously associated with situs abnormalities in the literature?	Reference		
<i>CCDC164 (DRC1)</i>	Microtubular disorganisation (MTD)	Involved in the structure and stability of the central pair and nexin links	No (Group B)	12		
<i>CCDC65 (DRC2)</i>	MTD			13		
<i>GAS8</i>	MTD			14		
<i>HYDIN</i>	Normal (subtle central apparatus defect)			15		
<i>STK36</i>	Central apparatus defect			16		
<i>RPGR</i>	Normal or MTD (syndromic form of PCD)	Photoreceptor connecting cilium protein	No (Group B)	17 18		
<i>CCNO</i>	RGMC	Involved in regulation of multiciliated cell differentiation	No (Group B)	19		
<i>MCIDAS</i>	RGMC			20		
<i>DNAJB13</i>	Central apparatus defect	Encode structural radial spoke proteins	No (Group B)	21		
<i>RSPH1</i>	Central apparatus defect			22		
<i>RSPH3</i>	Central apparatus defect and MTD			23		
<i>RSPH4A</i>	Central apparatus defect			24		
<i>RSPH9</i>	Central apparatus defect			24		
<i>CCDC39</i>	IDA and MTD			Encode molecular ruler proteins	Yes (Group A)	25 26
<i>CCDC40</i>	IDA and MTD	25 26				
<i>ARMC4</i>	ODA defect	Involved in structure and stability of the ODA (encode structural ODA components and factors required for ODA attachment and docking)	Yes (Group A)	27		
<i>CCDC114</i>	ODA defect			28		
<i>CCDC151</i>	ODA defect			29		
<i>DNAH11</i>	Normal (subtle ODA defect)			30		
<i>DNAH5</i>	ODA defect			31		
<i>DNAI1</i>	ODA defect			32		
<i>DNAI2</i>	ODA defect			33		
<i>DNAL1</i>	ODA defect			34		
<i>TTC25</i>	ODA defect			35		
<i>TXNDC3 (NME8)</i>	ODA defect			36		
<i>CCDC103</i>	ODA defect			37		
<i>C21orf59</i>	IDA and ODA defect			Encode cytoplasmic dynein-arm-assembly machinery proteins	Yes (Group A)	13
<i>DNAAF1 (LRRC50)</i>	IDA and ODA defect					38
<i>DNAAF2 (KTU)</i>	IDA and ODA defect					39
<i>DNAAF3</i>	IDA and ODA defect					40
<i>DNAAF4 (DYX1C1)</i>	IDA and ODA defect					41
<i>DNAAF5 (HEATR2)</i>	IDA and ODA defect	42				
<i>LRRC6</i>	IDA and ODA defect	43				
<i>PIH1D3</i>	IDA and ODA defect	44				
<i>SPAG1</i>	IDA and ODA defect	45				
<i>ZYMND10</i>	IDA and ODA defect	46 47				

PCD = Primary Ciliary Dyskinesia. MTD = Microtubular Disorganisation. RGMC = Reduced Generation of Multiple Motile Cilia. IDA = Inner Dynein Arm. ODA = Outer Dynein Arm.

**Table S3. Features of Primary Ciliary Dyskinesia patients identified to have congenital heart disease (CHD) and/or a structural laterality defect**

ID	Detailed imaging reports available	Situs classification*	Cardiac apex position	Position of stomach	Position of liver	Position of spleen	Overall laterality defect (includes SIT)	Laterality defect other than SIT**	Presence of CHD	Botto's CHD classification	Further details of CHD, if available	CHD classification (clinical complexity)
SHN60	CXR, echo, surgical reports	SA	Right	Right	Unknown	Unknown	Abnormal situs; isolated situs inversus thoracalis	Present	Yes	Heterotaxy + CHD	AVSD, pulmonary atresia	Major CHD
SHN32	CXR, echo	SS	Left	Left	Unknown	Unknown	No	Absent	Yes	DORV-TGA	DORV, TGA, coarctation of the aorta, PDA, VSD	Major CHD
RBH66	CXR, echo, abdo USS, CT chest, surgical reports	SIT	Right	Right	Left	Right	Abnormal situs	Absent	Yes	d-TGA	TGA, coarctation of the aorta	Major CHD
SHN92	CXR, echo, surgical reports	SIT	Right	Right	Unknown	Unknown	Abnormal situs	Absent	Yes	d-TGA	TGA, VSD	Major CHD
SHN89	CXR, echo, surgical reports	SS	Unknown	Left	Unknown	Unknown	No	Absent	Yes	d-TGA	TGA, pulmonary stenosis, VSD	Major CHD
RBH274	CXR, echo, CT chest, surgical reports	SA	Left	Right	Left	Right	Abnormal situs; Isolated situs inversus abdominalis; Accessory left IVC	Present	Yes	Heterotaxy + CHD	AVSD	Major CHD
RBH149	CXR, echo, abdo USS, surgical reports	SA	Left	Left	Right	Left	Abnormal situs; IVC stenosis	Present	Yes	Heterotaxy + CHD	AVSD, TGA	Major CHD
RBH147	CXR, echo, abdo USS, CT chest, surgical reports	SA	Right	Right	Left	Asplenia	Abnormal situs, right atrial isomerism	Present	Yes	Heterotaxy + CHD	AVSD, Ebstein's anomaly	Major CHD
RBH145	CXR, cardiac MRI, CT chest, surgical reports	SA	Left	Left	Unknown	Unknown	Abnormal situs, left atrial isomerism	Present	Yes	Heterotaxy + CHD	DORV, pulmonary stenosis, VSD, ASD	Major CHD
RBH140	CXR, CT chest, surgical reports	SIT	Right	Right	Unknown	Unknown	Abnormal situs	Absent	Yes	DORV	DORV	Major CHD
BCH23	CXR, echo, surgical reports	SIT	Right	Right	Unknown	Unknown	Abnormal situs	Absent	Yes	Fallot	TOF	Major CHD
RBH119	CXR, echo, abdo USS, CT chest	SA	Left	Right	Right	Left	Abnormal situs, left atrial isomerism plus Intestinal malrotation	Present	Yes	Heterotaxy + CHD	ASD, bilateral SVC, anomalous IVC drainage (operated 3 weeks of life)	Major CHD
SHN53	Echo, abdo USS	SA	Left	Left	Right	Left	Abnormal situs, left atrial isomerism plus left renal duplication	Present	Yes	Heterotaxy + CHD	Large ASD, multiple small VSDs, coarctation of the aorta	Major CHD
RBH215	CXR, echo, surgical reports	SS	Left	Left	Unknown	Unknown	No	Absent	Yes	d-TGA	TGA	Major CHD
RBH32	CXR, echo, abdo USS, surgical reports	SA	Right	Right	Left	Asplenia	Abnormal situs, right atrial isomerism plus Intestinal malrotation	Present	Yes	Heterotaxy + CHD	Complex cyanotic CHD requiring multiple surgeries in first year of life	Major CHD
RBH170	CXR, echo, abdo USS, CT chest, surgical reports	SA	Left	Right	Left	Right	Abnormal situs	Present	Yes	Heterotaxy + CHD	Complex cyanotic CHD, pulmonary atresia	Major CHD
BCH16	CXR, echo, abdo USS	SA	Left	Right	Left	Right	Abnormal situs; Situs inversus abdominalis, cardiac apex to the left, mirror image bronchial branching pattern	Present	Yes	Heterotaxy + CHD	TGA, pulmonary artery atresia, VSD	Major CHD
RBH169	CXR, echo, abdo USS, CT chest, surgical reports	SIT	Right	Right	Left	Right	Abnormal situs	Absent	Yes	Tricuspid atresia	Tricuspid atresia, VSD, PDA	Major CHD
SHN61	CXR, echo	SIT	Right	Right	Unknown	Unknown	Abnormal situs	Absent	Yes	VSD	VSD	Simple CHD
RBH70	CXR, echo, abdo USS	SIT	Right	Right	Left	Right	Abnormal situs	Absent	Yes	ASD 2	ASD	Simple CHD
BCH4	CXR, echo	SS	Left	Left	Unknown	Unknown	No	Absent	Yes	VSD	VSD	Simple CHD

RBH8	CXR, echo, abdo USS	SA	Right	Right	Left	Right	Abnormal situs plus duplex right kidney	Present	Yes	Heterotaxy + CHD	VSD	Simple CHD
RBH63	CXR, echo, abdo USS, CT chest	SS	Left	Left	Right	Left	No	Absent	Yes	VSD	VSD	Simple CHD
RBH55	CXR, echo, abdo USS	SS	Left	Left	Right	Left	No	Absent	Yes	AS	Aortic stenosis and regurgitation	Simple CHD
RBH2	CXR, echo	SIT	Right	Right	Unknown	Unknown	Abnormal situs	Absent	Yes	N/A	PDA	Simple CHD
RBH141	CXR, echo	SIT	Right	Right	Unknown	Unknown	Abnormal situs	Absent	Yes	VSD	VSD	Simple CHD
RBH79	CXR, echo, abdo USS	SIT	Right	Right	Left	Right	Abnormal situs	Absent	Yes	N/A	PDA	Simple CHD
RBH159	CXR, echo	SIT	Right	Right	Unknown	Unknown	Abnormal situs	Absent	Yes	VSD	VSD	Simple CHD
SHN10	CXR, echo	SA	Left	Left	Unknown	Unknown	Abnormal situs, left atrial isomerism	Present	Yes	Heterotaxy + CHD	PDA	Simple CHD
RBH253	CXR, cardiac MRI, CT chest, surgical reports	SA	Left	Left	Unknown	Unknown	Abnormal situs, left atrial isomerism	Present	Yes	Heterotaxy + CHD	Aortic stenosis	Simple CHD
RBH11	CXR, echo	SS	Left	left	Unknown	Unknown	No	Absent	Yes	ASD 2	ASD	Simple CHD
RBH94	CXR, echo, abdo USS	SIT	Right	Right	Left	Right	Abnormal situs	Absent	Yes	N/A	Aortopathy	Simple CHD
RBH101	CXR, echo, abdo USS, CT chest	SIT	Right	Right	Left	Right	Abnormal situs	Absent	Yes	VSD	VSD	Simple CHD
BCH32	CXR, echo	SIT	Right	Right	Unknown	Unknown	Abnormal situs	Absent	Yes	VSD	VSD,	Simple CHD
BCH24	CXR, echo, abdo USS	SA	Right	Right	Left	Right	Abnormal situs plus malrotation of SMA/SMV axis	Present	Yes	Heterotaxy + CHD	ASD	Simple CHD
RBH53	CXR, echo, CT chest	SIT	Right	Right	Left	Right	Abnormal situs	Absent	Yes	VSD	VSD	Simple CHD
BCH18	CXR, echo	SIT	Right	Right	Unknown	Unknown	Abnormal situs	Absent	Yes	VSD (?)	Septal defect - no further detail available	Simple CHD
RBH103	CXR, echo, abdo USS, CT chest	SIT	Right	Right	Left	Right	Abnormal situs	Absent	Yes	N/A	Bicuspid aortic valve	Simple CHD
RBH122	CXR, echo, abdo USS, CT chest	SS	Left	Left	Right	Left	No	Absent	Yes	ASD 2	ASD	Simple CHD
BCH9	CXR, echo	SS	Left	Left	Unknown	Unknown	No	Absent	Yes	VSD (?)	Septal defect - no further detail available	Simple CHD
RBH156	CXR, echo, CT chest	SA	Right	Left	Midline	Poly splenia (left)	Abnormal situs; Isolated situs inv ersus thoracalis; azygos continuation of the IVC	Present	No CHD	Heterotaxy	No CHD	No CHD
RBH13	CXR, echo, abdo USS	SA	Right	Left	Right	Left	Abnormal situs; Isolated situs inv ersus thoracalis; interrupted IVC with azygos continuation to the SVC	Present	No CHD	Heterotaxy	No CHD	No CHD
RBH105	CXR, echo, abdo USS, CT chest	SA	Right	Left	Right	Left	Abnormal situs; Isolated situs inv ersus thoracalis	Present	No CHD	Heterotaxy	No CHD	No CHD
RBH64	CXR, echo, abdo USS	SA	Right	Right	Left	Right	Abnormal situs, left atrial isomerism	Present	No CHD	Heterotaxy	No CHD	No CHD
SHN73	CXR, echo	SA	Right	Right	Unknown	Unknown	Abnormal situs, left atrial isomerism	Present	No CHD	Heterotaxy	No CHD	No CHD
RBH286	CXR, echo, CT chest	SA	Right	Left	Unknown	Unknown	Abnormal situs; Isolated situs inv ersus thoracalis	Present	No CHD	Heterotaxy	No CHD	No CHD
RBH135	CXR, echo, abdo USS, surgical reports	SA	Left	Right	Left	Poly splenia (right)	Abnormal situs plus total jejunal atresia	Present	No CHD	Heterotaxy	No CHD	No CHD
RBH102	CXR, echo, abdo USS	SA	Right	Right	Left	Right	Abnormal situs, left atrial isomerism	Present	No CHD	Heterotaxy	No CHD	No CHD
RBH118	CXR, echo, abdo USS	SA	Left	Right	Left	Right	Abnormal situs, left atrial isomerism	Present	No CHD	Heterotaxy	No CHD	No CHD
RBH27	CXR, echo, abdo USS, CT chest	SA	Left	Right	Left	Poly splenia (right)	Abnormal situs, left atrial isomerism	Present	No CHD	Heterotaxy	No CHD	No CHD
SHN58	CXR, echo	SA	Right	Right	Unknown	Unknown	Abnormal situs, left atrial isomerism	Present	No CHD	Heterotaxy	No CHD	No CHD
RBH153	CXR, echo, abdo	SA	Left	Right	Left	Right	Abnormal situs, left atrial	Present	No CHD	Heterotaxy	No CHD	No CHD



	USS, CT chest						isomerism					
SHN54	CXR, echo, abdo USS	SA	Right	Left	Right	Left	Isolated situs inv ersus thoracalis, left multicystic dysplastic kidney	Present	No CHD	Heterotaxy	No CHD	No CHD
RBH6	CXR, echo, abdo USS, CT chest	SA	Left	Right	Left	Poly splenia (right)	Abnormal situs; Isolated situs inv ersus thoracalis	Present	No CHD	Heterotaxy	No CHD	No CHD
RBH81	CXR, echo, abdo USS	SA	Left	Left	Midline	Poly splenia (left)	Abnormal situs	Present	No CHD	Heterotaxy	No CHD	No CHD
RBH15	CXR, echo, abdo USS	SA	Right	Right	Left	Right	Abnormal situs; Azygous vein to left sided SVC	Present	No CHD	Heterotaxy	No CHD	No CHD
RBH90	CXR, echo, abdo USS, CT chest	SA	Left	Right	Central	Right	Abnormal situs, left atrial isomerism plus ileal atresia	Present	No CHD	Heterotaxy	No CHD	No CHD
RBH198	CXR, abdo USS, CT chest	SA	Right	Right	Central	Poly splenia (one spleen in the LUQ and one in RUQ)	Abnormal situs plus poly splenia	Present	Unknown	Heterotaxy (unknown CHD status)	Unknown	Unknown
BCH28	CXR, echo, CT chest	SA	Right	Left	Unknown	Unknown	Abnormal situs, isolated situs inv ersus thoracalis	Present	No CHD	Heterotaxy	No CHD	No CHD

CXR = Chest X-ray; echo = cardiac echocardiograph; AVSD = Atrial Ventricular Septal Defect; CHD = Congenital Heart Disease; SA = Situs Ambiguous; DORV = Double Outlet Right Ventricle; TGA= Transposition of the Great Arteries; PDA = Patent Ductus Arteriosus; VSD = Ventricular Septal Defect; SS = Situs Solitus; SIT = Situs Inversus Totalis; L/RUQ = left/right upper quadrant; Abdo USS = Abdominal Ultrasound Scan; CT = Computer Tomography; IVC = Inferior Vena Cava; MRI = Magnetic Resonance Imaging; ASD = Atrial Septal Defect; TOF = Tetralogy of Fallot; SVC = Superior Vena Cava; SMA = Superior Mesenteric Artery; SMV = Superior Mesenteric. We note for four CHD cases in this study, that a persistent PDA (RBH2, RBH79, SHN10) or aortopathy (RBH94) could have other aetiologies. \*Echocardiographic diagnosis of situs is based on Huhta et al <sup>10</sup>. \*\*Laterality defect other than SIT indicates SA or other possible laterality defect. Botto's Classification of CHD (Level 2) is also shown <sup>6</sup>.

**Table S4. Results of statistical regression modelling**

Risk factor	Reference category	Comparison category	Relative frequencies	Univariate model			Multivariable model		
				OR	p-value	95% CI	OR	p-value	95% CI
<b>OUTCOME 1: SITUS ABNORMALITY</b>									
Parental consanguinity	Non-consanguineous parents	Consanguineous parents	67/119 vs 64/152	1.77	0.02 (significant)	1.09 – 2.88	3.21	0.02 (significant)	1.16 – 8.88
Ethnicity	Caucasian	South Asian	54/92 vs 88/188	1.61	0.06	0.97 – 2.67	0.66	0.48	0.20 – 2.10
		Other	23/51 vs 88/188	0.93	0.83	0.50 - 1.74	0.52	0.27	0.16 – 1.69
Functional gene effect category	Genes involved in structure and stability of the ODA	Genes encoding cytoplasmic dynein arm assembly proteins	26/36 vs 59/95	1.59	0.28	0.69 - 3.67	1.61	0.36	0.58 - 4.49
		Genes encoding ruler proteins	13/30 vs 59/95	0.47	0.07	0.20 - 1.07	0.53	0.21	0.63 - 2.09
Literature evidence for gene association with abnormal situs	Genes thought to be associated with abnormal situs (Group A)	Genes thought to not be associated with abnormal situs (Group B)	0/38 vs 98/161	n/a	n/a	n/a	n/a	n/a	n/a
<b>OUTCOME 2: CHD AND/OR LATERALITY DEFECTS OTHER THAN SIT</b>									
Parental consanguinity	Non-consanguineous parents	Consanguineous parents	23/83 vs 20/100	1.53	0.22	0.77 - 3.05	3.77	0.11	0.75 - 18.95
Ethnicity	Caucasian	South Asian	16/63 vs 29/119	1.06	0.88	0.52 - 2.14	0.36	0.224	0.07 - 1.87
		Other	10/30 vs 29/119	1.55	0.32	0.65 - 3.69	0.43	0.410	0.60 – 3.16
At least one truncating mutation	No truncating mutations	At least one truncating mutation	23/87 vs 6/33	1.62	0.35	0.59 - 4.42	1.75	0.370	0.52- 5.93
Situs abnormality	Normal situs	Abnormal situs	50/126 vs 9/105	7.98	<0.001 (significant)	3.57 - 17.83	8.79	0.002 (significant)	2.28 - 33.89

OR = odds ratio. CI = confidence interval. ODA = outer dynein arm. SIT = situs inversus totalis. Logistic regression modelling was performed with situs abnormality as the dependent dichotomous variable in outcome 1 and the presence of congenital heart disease (CHD) and/or laterality defects other than SIT as the dependent dichotomous variable in outcome 2. For each outcome, separate univariate logistic regression models for each individual risk factor, and one multivariable model incorporating all the risk factors were fitted to the data. Only patients with bi-allelic mutations in known Primary Ciliary Dyskinesia (PCD) genes were included in the tests involving genetic risk factors (functional gene effect category and having at least one truncating mutation). Within the functional gene effect association tests, only the three categories of genes that are thought to be associated with situs abnormalities from the literature were compared (detailed in Table 1). In the multivariate logistic regression, for outcome 1 (situs abnormality) two events (normal/abnormal) were used and 127 subjects included; for outcome 2 (CHD and/or laterality defects other than SIT) two events (presence of defects: no/yes) were used and 101 subjects included.

## Supplementary references

1. Lucas JS, Barbato A, Collins SA, et al. European Respiratory Society guidelines for the diagnosis of primary ciliary dyskinesia. *Eur Respir J* 2017;49(1) doi: 10.1183/13993003.01090-2016
2. Lucas JS BA, Collins SA, Goutaki M, Behan L, Caudri D, Dell S, Eber E, Escudier E, Hirst RA, Hogg C, Jorissen M, Latzin P, Legendre M, Leigh MW, Midulla F, Nielsen KG, Omran H, Papon JF, Pohunek P, Redfern B, Rigau D, Rindlisbacher BF, Shoemark A, Snijders D, Tonia T, Titieni A, Walker WT, Werner C, Bush A, Kuehni CE. ERS Task Force guideline for the diagnosis of primary ciliary dyskinesia. *European Respiratory Journal* 2016;In Press
3. Bull C. Current and potential impact of fetal diagnosis on prevalence and spectrum of serious congenital heart disease at term in the UK. British Paediatric Cardiac Association. *Lancet (London, England)* 1999;354(9186):1242-7. doi: 10.1016/S0140-6736(99)03101-1 [published Online First: 1999/10/16]
4. Marelli AJ, Mackie AS, Ionescu-Ittu R, et al. Congenital heart disease in the general population: changing prevalence and age distribution. *Circulation* 2007;115(2):163-72. doi: 10.1161/circulationaha.106.627224 [published Online First: 2007/01/11]
5. Carvalho JS, Mavrides E, Shinebourne EA, et al. Improving the effectiveness of routine prenatal screening for major congenital heart defects. *Heart (British Cardiac Society)* 2002;88(4):387-91. [published Online First: 2002/09/17]
6. Botto LD, Lin AE, Riehle-Colarusso T, et al. Seeking causes: Classifying and evaluating congenital heart defects in etiologic studies. *Birth Defects Res A Clin Mol Teratol* 2007;79(10):714-27. doi: 10.1002/bdra.20403 [published Online First: 2007/08/31]
7. Shapiro AJ, Davis SD, Ferkol T, et al. Laterality defects other than situs inversus totalis in primary ciliary dyskinesia: insights into situs ambiguus and heterotaxy. *Chest* 2014;146(5):1176-86. doi: 10.1378/chest.13-1704 [published Online First: 2014/03/01]
8. Harrison MJ, Shapiro AJ, Kennedy MP. Congenital Heart Disease and Primary Ciliary Dyskinesia. *Paediatr Respir Rev* 2016;18:25-32. doi: 10.1016/j.prrv.2015.09.003 [published Online First: 2015/11/08]
9. Kennedy MP, Omran H, Leigh MW, et al. Congenital heart disease and other heterotaxic defects in a large cohort of patients with primary ciliary dyskinesia. *Circulation* 2007;115(22):2814-21. doi: 10.1161/CIRCULATIONAHA.106.649038 [pii] 10.1161/CIRCULATIONAHA.106.649038 [published Online First: 2007/05/23]
10. Huhta JC, Smallhorn JF, Macartney FJ. Two dimensional echocardiographic diagnosis of situs. *British heart journal* 1982;48(2):97-108. [published Online First: 1982/08/01]
11. Shoemark A, Moya E, Hirst RA, et al. High prevalence of CCDC103 p.His154Pro mutation causing primary ciliary dyskinesia disrupts protein oligomerisation and is associated with normal diagnostic investigations. *Thorax* 2017 doi: 10.1136/thoraxjnl-2017-209999
12. Wirschell M, Olbrich H, Werner C, et al. The nexin-dynein regulatory complex subunit DRC1 is essential for motile cilia function in algae and humans. *Nature genetics* 2013;45(3):262-8. doi: 10.1038/ng.2533 [published Online First: 2013/01/29]
13. Austin-Tse C, Halbritter J, Zariwala MA, et al. Zebrafish Ciliopathy Screen Plus Human Mutational Analysis Identifies C21orf59 and CCDC65 Defects as Causing Primary Ciliary Dyskinesia. *American journal of human genetics* 2013;93(4):672-86. doi: 10.1016/j.ajhg.2013.08.015 [published Online First: 2013/10/08]
14. Olbrich H, Cremers C, Loges NT, et al. Loss-of-Function GAS8 Mutations Cause Primary Ciliary Dyskinesia and Disrupt the Nexin-Dynein Regulatory Complex. *American journal of human genetics* 2015;97(4):546-54. doi: 10.1016/j.ajhg.2015.08.012 [published Online First: 2015/09/22]
15. Olbrich H, Schmidts M, Werner C, et al. Recessive HYDIN mutations cause primary ciliary dyskinesia without randomization of left-right body asymmetry. *American journal of human genetics* 2012;91(4):672-84. doi: 10.1016/j.ajhg.2012.08.016 [published Online First: 2012/10/02]
16. Edelbusch C, Cindric S, Dougherty GW, et al. Mutation of serine/threonine protein kinase 36 (STK36) causes primary ciliary dyskinesia with a central pair defect. *Hum Mutat* 2017;38(8):964-69. doi: 10.1002/humu.23261
17. Moore A, Escudier E, Roger G, et al. RPGR is mutated in patients with a complex X linked phenotype combining primary ciliary dyskinesia and retinitis pigmentosa. *Journal of medical genetics* 2006;43(4):326-33. doi: 10.1136/jmg.2005.034868 [published Online First: 2005/08/02]
18. Bukowy-Bieryllo Z, Zietkiewicz E, Loges NT, et al. RPGR mutations might cause reduced orientation of respiratory cilia. *Pediatric pulmonology* 2013;48(4):352-63. doi: 10.1002/ppul.22632 [published Online First: 2012/08/14]

19. Wallmeier J, Al-Mutairi DA, Chen CT, et al. Mutations in CCNO result in congenital mucociliary clearance disorder with reduced generation of multiple motile cilia. *Nature genetics* 2014;46(6):646-51. doi: 10.1038/ng.2961 [published Online First: 2014/04/22]
20. Boon M, Wallmeier J, Ma L, et al. MCIDAS mutations result in a mucociliary clearance disorder with reduced generation of multiple motile cilia. *Nature communications* 2014;5:4418. doi: 10.1038/ncomms5418 [published Online First: 2014/07/23]
21. El Khouri E, Thomas L, Jeanson L, et al. Mutations in DNAJB13, Encoding an HSP40 Family Member, Cause Primary Ciliary Dyskinesia and Male Infertility. *American journal of human genetics* 2016;99(2):489-500. doi: 10.1016/j.ajhg.2016.06.022 [published Online First: 2016/08/04]
22. Kott E, Legendre M, Copin B, et al. Loss-of-function mutations in RSPH1 cause primary ciliary dyskinesia with central-complex and radial-spoke defects. *American journal of human genetics* 2013;93(3):561-70. doi: 10.1016/j.ajhg.2013.07.013 [published Online First: 2013/09/03]
23. Jeanson L, Copin B, Papon JF, et al. RSPH3 Mutations Cause Primary Ciliary Dyskinesia with Central-Complex Defects and a Near Absence of Radial Spokes. *American journal of human genetics* 2015;97(1):153-62. doi: 10.1016/j.ajhg.2015.05.004 [published Online First: 2015/06/16]
24. Castleman VH, Romio L, Chodhari R, et al. Mutations in radial spoke head protein genes RSPH9 and RSPH4A cause primary ciliary dyskinesia with central-microtubular-pair abnormalities. *American journal of human genetics* 2009;84(2):197-209. doi: 10.1016/j.ajhg.2009.01.011 [published Online First: 2009/02/10]
25. Antony D, Becker-Heck A, Zariwala MA, et al. Mutations in CCDC39 and CCDC40 are the major cause of primary ciliary dyskinesia with axonemal disorganization and absent inner dynein arms. *Human mutation* 2013;34(3):462-72. doi: 10.1002/humu.22261 [published Online First: 2012/12/21]
26. Oda T, Yanagisawa H, Kamiya R, et al. A molecular ruler determines the repeat length in eukaryotic cilia and flagella. *Science* 2014;346(6211):857-60. doi: 10.1126/science.1260214
27. Hjeij R, Lindstrand A, Francis R, et al. ARMC4 mutations cause primary ciliary dyskinesia with randomization of left/right body asymmetry. *American journal of human genetics* 2013;93(2):357-67. doi: 10.1016/j.ajhg.2013.06.009 [published Online First: 2013/07/16]
28. Onoufriadis A, Paff T, Antony D, et al. Splice-site mutations in the axonemal outer dynein arm docking complex gene CCDC114 cause primary ciliary dyskinesia. *American journal of human genetics* 2013;92(1):88-98. doi: 10.1016/j.ajhg.2012.11.002 [published Online First: 2012/12/25]
29. Hjeij R, Onoufriadis A, Watson CM, et al. CCDC151 mutations cause primary ciliary dyskinesia by disruption of the outer dynein arm docking complex formation. *American journal of human genetics* 2014;95(3):257-74. doi: 10.1016/j.ajhg.2014.08.005 [published Online First: 2014/09/06]
30. Schwabe GC, Hoffmann K, Loges NT, et al. Primary ciliary dyskinesia associated with normal axoneme ultrastructure is caused by DNAH11 mutations. *Human mutation* 2008;29(2):289-98. doi: 10.1002/humu.20656 [published Online First: 2007/11/21]
31. Omran H, Haffner K, Volkel A, et al. Homozygosity mapping of a gene locus for primary ciliary dyskinesia on chromosome 5p and identification of the heavy dynein chain DNAH5 as a candidate gene. *American journal of respiratory cell and molecular biology* 2000;23(5):696-702. doi: 10.1165/ajrcmb.23.5.4257 [published Online First: 2000/11/04]
32. Pennarun G, Escudier E, Chapelin C, et al. Loss-of-function mutations in a human gene related to *Chlamydomonas reinhardtii* dynein IC78 result in primary ciliary dyskinesia. *American journal of human genetics* 1999;65(6):1508-19. doi: 10.1086/302683 [published Online First: 1999/12/01]
33. Loges NT, Olbrich H, Fenske L, et al. DNAI2 mutations cause primary ciliary dyskinesia with defects in the outer dynein arm. *American journal of human genetics* 2008;83(5):547-58. doi: 10.1016/j.ajhg.2008.10.001 [published Online First: 2008/10/28]
34. Mazor M, Alkrinawi S, Chalifa-Caspi V, et al. Primary ciliary dyskinesia caused by homozygous mutation in DNAL1, encoding dynein light chain 1. *American journal of human genetics* 2011;88(5):599-607. doi: 10.1016/j.ajhg.2011.03.018 [published Online First: 2011/04/19]
35. Wallmeier J, Shiratori H, Dougherty GW, et al. TTC25 Deficiency Results in Defects of the Outer Dynein Arm Docking Machinery and Primary Ciliary Dyskinesia with Left-Right Body Asymmetry Randomization. *American journal of human genetics* 2016;99(2):460-9. doi: 10.1016/j.ajhg.2016.06.014 [published Online First: 2016/08/04]
36. Duriez B, Duquesnoy P, Escudier E, et al. A common variant in combination with a nonsense mutation in a member of the thioredoxin family causes primary ciliary dyskinesia. *Proceedings of the National Academy of Sciences of the United States of America* 2007;104(9):3336-41. doi: 10.1073/pnas.0611405104 [published Online First: 2007/03/16]

37. Panizzi JR, Becker-Heck A, Castleman VH, et al. CCDC103 mutations cause primary ciliary dyskinesia by disrupting assembly of ciliary dynein arms. *Nature genetics* 2012;44(6):714-9. doi: 10.1038/ng.2277 [published Online First: 2012/05/15]
38. Loges NT, Olbrich H, Becker-Heck A, et al. Deletions and point mutations of LRRC50 cause primary ciliary dyskinesia due to dynein arm defects. *American journal of human genetics* 2009;85(6):883-9. doi: 10.1016/j.ajhg.2009.10.018 [published Online First: 2009/12/01]
39. Omran H, Kobayashi D, Olbrich H, et al. Ktu/PF13 is required for cytoplasmic pre-assembly of axonemal dyneins. *Nature* 2008;456(7222):611-6. doi: 10.1038/nature07471 [published Online First: 2008/12/05]
40. Mitchison HM, Schmidts M, Loges NT, et al. Mutations in axonemal dynein assembly factor DNAAF3 cause primary ciliary dyskinesia. *Nature genetics* 2012;44(4):381-9, s1-2. doi: 10.1038/ng.1106 [published Online First: 2012/03/06]
41. Tarkar A, Loges NT, Slagle CE, et al. DYX1C1 is required for axonemal dynein assembly and ciliary motility. *Nature genetics* 2013;45(9):995-1003. doi: 10.1038/ng.2707 [published Online First: 2013/07/23]
42. Horani A, Druley TE, Zariwala MA, et al. Whole-exome capture and sequencing identifies HEATR2 mutation as a cause of primary ciliary dyskinesia. *American journal of human genetics* 2012;91(4):685-93. doi: 10.1016/j.ajhg.2012.08.022 [published Online First: 2012/10/09]
43. Kott E, Duquesnoy P, Copin B, et al. Loss-of-function mutations in LRRC6, a gene essential for proper axonemal assembly of inner and outer dynein arms, cause primary ciliary dyskinesia. *American journal of human genetics* 2012;91(5):958-64. doi: 10.1016/j.ajhg.2012.10.003 [published Online First: 2012/11/06]
44. Olcese C, Patel MP, Shoemark A, et al. X-linked primary ciliary dyskinesia due to mutations in the cytoplasmic axonemal dynein assembly factor PIH1D3. *Nat Commun* 2017;8:14279. doi: 10.1038/ncomms14279
45. Knowles MR, Ostrowski LE, Loges NT, et al. Mutations in SPAG1 cause primary ciliary dyskinesia associated with defective outer and inner dynein arms. *American journal of human genetics* 2013;93(4):711-20. doi: 10.1016/j.ajhg.2013.07.025 [published Online First: 2013/09/24]
46. Zariwala MA, Gee HY, Kurkowiak M, et al. ZMYND10 is mutated in primary ciliary dyskinesia and interacts with LRRC6. *American journal of human genetics* 2013;93(2):336-45. doi: 10.1016/j.ajhg.2013.06.007 [published Online First: 2013/07/31]
47. Moore DJ, Onoufriadis A, Shoemark A, et al. Mutations in ZMYND10, a gene essential for proper axonemal assembly of inner and outer dynein arms in humans and flies, cause primary ciliary dyskinesia. *American journal of human genetics* 2013;93(2):346-56. doi: 10.1016/j.ajhg.2013.07.009 [published Online First: 2013/07/31]