

Accepted Version

## **Parkinsonism in patients with chronic hepatitis C treated with interferon- $\alpha$ 2b: a report of two cases**

Mikio Kajihara,<sup>1</sup> Sara Montagnese,<sup>1,2</sup> Pooja Khanna,<sup>1</sup> Piero Amodio,<sup>2</sup> Anthony HV Schapira,<sup>3</sup>  
Geoffrey M Dusheiko,<sup>1</sup> Marsha Y Morgan<sup>1</sup>

<sup>1</sup> Centre for Hepatology, Department of Medicine, Royal Free Campus, University College London Medical School, University College London, London, UK

<sup>2</sup> Clinical Medicine V, Department of Clinical and Experimental Medicine, University of Padua, Italy

<sup>3</sup> University Department of Clinical Neurosciences, University College London Medical School, University College London, London, UK

Correspondence:

Dr Marsha Y Morgan

Centre for Hepatology

Department of Medicine, Royal Free Campus

University College London Medical School

Rowland Hill Street

London NW3 2PF

United Kingdom

[mymorgan@medsch.ucl.ac.uk](mailto:mymorgan@medsch.ucl.ac.uk)

**Details of two patients with chronic hepatitis C who developed features of Parkinsonism when treated with IFN- $\alpha$ 2b and ribavirin are reported. The symptoms resolved when treatment was discontinued in one patient but not in the other. Physicians should be alert to the possibility that drug-related Parkinsonism may complicate treatment of hepatitis C with antiviral agents; the agent most likely responsible is IFN- $\alpha$ 2b. Prompt withdrawal of treatment is mandatory but does not always guarantee reversal of the Parkinsonian features.**

## INTRODUCTION

Hepatitis C (HCV) infection has reached pandemic proportions and is considered to be ‘one of the most serious and significant public health risks of our generation’ [1]. It is estimated that 170 million individuals are infected world-wide although the reported numbers most likely underestimate the prevalence rates [2]. An estimated 1% of the Scottish [3] and 0.5% of the English population [4] are infected with this virus. However, two-thirds of the 37,500 individuals in Scotland and the 2,000,000 individuals in England likely to be infected with HCV remain undiagnosed [3,4].

Pegylated interferon (IFN)- $\alpha$ , in combination with ribavirin, is the treatment of choice for HCV infection; a sustained viral clearance is achieved in 50-60% of treated individuals [5-7]. Treatment is considered to be cost-effective [8] and its use widely endorsed [8,9]. However, treatment is associated with a number of side-effects, predominantly fatigue, influenza-like symptoms, haematological and neuropsychiatric abnormalities, which result in premature withdrawal of therapy in 10-14% of individuals [10].

The neuropsychiatric side-effects, which have been attributed to the use of IFN- $\alpha$ , include depression, lethargy, irritability, cognitive impairment and, less frequently, mania, peripheral neuropathy, severe depression and suicide [10-12]. Movement disorders have been described but only rarely [13,14]; thus, Parkinsonian features have been reported in a patient with HCV infection treated with intramuscular IFN- $\alpha$  monotherapy [15] and, more recently, in a patient with HCV infection treated with pegylated IFN- $\alpha$ 2a and ribavirin [16]. In both these patients the Parkinsonian features persisted after the withdrawal of the antiviral therapy raising the possibility that the IFN- $\alpha$  may simply have unmasked latent Parkinson’s disease.

Evidence for a more direct drug-related effect is provided in the current report of two patients with HCV infection who developed Parkinsonism during treatment with IFN- $\alpha$ 2b and

ribavirin, in one of whom the symptoms resolved completely following withdrawal of the antiviral therapy.

## **CASE REPORTS**

### **Patient 1**

In September 1997, a 52-year-old man with a history of functional dyspepsia was referred for management of his alcohol misuse and longstanding HCV infection, genotype 1, acquired most likely when he shared a prison cell with an infected inmate. He was clinically well with no features of hepatic decompensation but his liver biopsy showed cirrhosis with mildly active inflammatory change.

In May 2001, when he had been abstinent from alcohol for almost 2 years, he was started on standard IFN- $\alpha$ 2b, 3MU thrice weekly together with oral ribavirin 1g daily. His HCV RNA became undetectable during treatment but the response was not sustained.

In March 2003, a second course of treatment was initiated with pegylated IFN- $\alpha$ 2b 120  $\mu$ g subcutaneously once weekly and oral ribavirin 1g daily. During the first few weeks of treatment he developed flu-like symptoms and nausea for which he took prochlorperazine intermittently, a medication he had used previously, with effect, to control his dyspepsia. By week eight his mood was low and he had developed some difficulty in walking and in hand manoeuvres (Figure 1).

At the end of May 2003, after 9 weeks of treatment, he had obvious extrapyramidal signs including bilateral low frequency resting tremor, inexpressive facies and a small stepped gait. There were no clinical, psychometric or electroencephalographic (EEG) features suggestive of hepatic encephalopathy. Cerebral magnetic resonance imaging showed no intracranial abnormalities; his serum manganese concentration was normal. No haematological or biochemical abnormalities, other than those associated with his liver disease, were found. All treatment was discontinued and, over a period of approximately 3 weeks, the Parkinsonian features resolved completely. He remained HCV RNA positive; he subsequently developed hepatocellular carcinoma and died of liver failure in September 2008.

## **Patient 2**

In July 1995, a 57-year-old man was referred for investigation of raised serum aminotransferases. He complained of lethargy and tiredness but was otherwise well. He had a history of systemic hypertension treated with beta-blockers; he had only ever consumed modest amounts of alcohol. He was found to have HCV infection, genotype 1, although no definite route of infection was identified. He had no features of hepatic decompensation but his liver biopsy showed cirrhosis with mildly active hepatitis, in keeping with chronic HCV infection. In August 1995 he started treatment with standard IFN- $\alpha$ 2b, 3MU subcutaneously thrice-weekly, and oral ribavirin 1g daily.

During the first four months of treatment he became significantly more fatigued and lethargic and shortly thereafter developed poor sleep, impaired concentration, a shuffling gait and an asymmetrical resting tremor (Figure 2). There were no clinical, psychometric or EEG features suggestive of hepatic encephalopathy. Cerebral magnetic resonance imaging was unremarkable; his serum manganese concentration was normal. No haematological or biochemical abnormalities, other than those associated with his liver disease, were found. Anti-viral therapy was stopped in January 1996 but although his depression and poor concentration resolved rapidly, the extrapyramidal symptoms persisted. Approximately 10 months later he was started on anti-Parkinsonian medication with a good initial response but his symptoms then worsened progressively (Figure 2). Over the next 10 years he remained HCV RNA negative with well-compensated cirrhosis. However, his Parkinsonism became incapacitating and he eventually died of its complications in February 2006.

## **DISCUSSION**

Drug-induced Parkinsonism is a common, often underdiagnosed condition, which closely resembles Parkinson's disease in its clinical manifestations [17]. It is caused by disruption of dopaminergic neurotransmission as a result of inhibition of striatal dopamine synthesis or release [18], interference with presynaptic vesicular dopamine storage [19] or postsynaptic dopamine receptor blockade [20]. It is not associated with the nigrostriatal degeneration seen on cerebral single photon emission tomography and positron emission tomography (PET) imaging in Parkinson's disease [17,21].

The features of drug-induced Parkinsonism resolve in 60-70% of individuals within 2 months of drug withdrawal but recovery may take as long as 15 to 18 months [22] or, exceptionally, considerably longer [23,24]. However, it is not always reversible; persistence or even worsening of the Parkinsonian features may occur after drug withdrawal [23-26]. In these instances, the possibility that the drug may have unmasked latent Parkinson's disease has to be considered but would be difficult to prove [17], although the presence of nigrostriatal dysfunction on <sup>18</sup>F-dopa PET would be supportive [26]. Rarely, patients may recover from drug-induced Parkinsonism only to develop Parkinson's disease at a later date [27].

The first patient described in this report developed Parkinsonism during treatment with pegylated IFN- $\alpha$ 2b and ribavirin having previously been treated, albeit unsuccessfully, with standard IFN- $\alpha$ 2b and ribavirin, without significant side-effects. Pegylation of IFN- $\alpha$  results in a ten-fold increase in the serum half-life of the drug [28] and, clearly, more sustained drug exposure may have been an important aetiological factor. He was also taking prochlorperazine, which has dopamine receptor inhibitory properties and is associated with extrapyramidal side-effects [17]. However, he had used prochlorperazine during treatment with standard IFN and intermittently for prolonged periods both before and after this episode,

without complications. Clearly, an interaction between IFN- $\alpha$  and prochlorperazine resulting in enhanced dopaminergic antagonism cannot be ruled out.

The second patient described developed Parkinsonism during treatment with standard IFN- $\alpha$ 2b and ribavirin but his extra-pyramidal symptoms persisted following drug withdrawal suggesting, perhaps, an unmasking or subsequent development of Parkinson's disease.

Both patients had cirrhosis and the possibility that the Parkinsonian symptoms might have reflected the development of hepatic encephalopathy was considered, but neither patient showed any of the classical clinical, psychometric or EEG features of this syndrome nor did their clinical course mirror descriptions in the literature of hepatocerebral degeneration (29), 'motor' hepatic encephalopathy (30) or hepatic myelopathy (31).

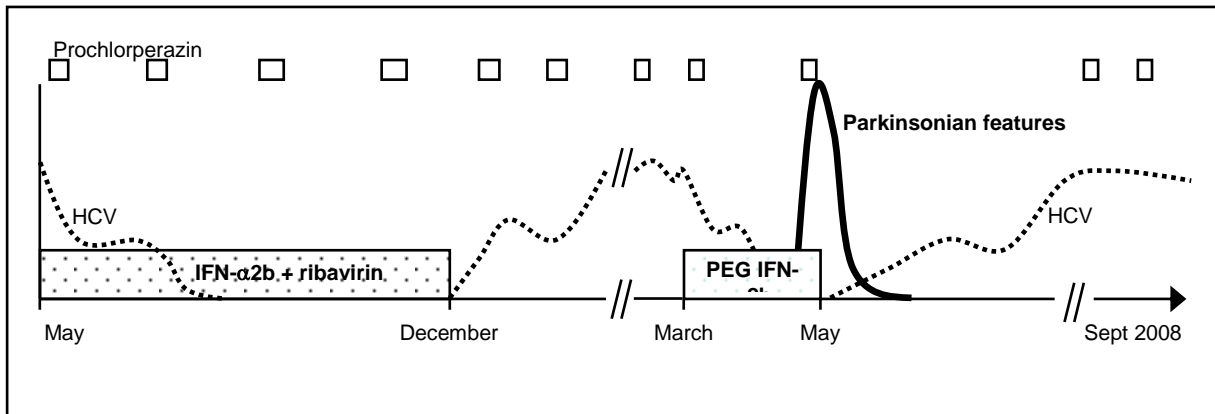
The mechanism responsible for the development of extrapyramidal symptoms in relation to treatment with IFN- $\alpha$ 2b is unclear. Intraperitoneal IFN- $\alpha$  administration has been shown to inhibit dopaminergic neural activity and to decrease cerebral dopamine levels in rodents [32]. Thus, IFN- $\alpha$  may affect neurotransmitter balance directly, although traditionally it has not been thought to cross the blood-brain-barrier [33]. The degeneration of dopaminergic neurons in Parkinson's disease is associated with an activated glial reaction combined with an inflammatory cascade involving cytokines such as IFN- $\gamma$ , tumour necrosis factor- $\alpha$ , and interleukin-1 $\beta$  [34-36]. IFN- $\alpha$  is an immunomodulatory cytokine and it could trigger a similar inflammatory process.

The diagnosis of drug-related Parkinsonism is often missed [37]. Physicians should be alert to the possibility that drug-related Parkinsonism may complicate the use of IFN- $\alpha$  2b for treatment of HCV infection. Early recognition of the features is essential; treatment should be stopped immediately but even then reversal of the Parkinsonian features cannot be guaranteed [16, 17].



**Figure 1.** Evolution of the Parkinsonian features, in Patient 1, in relation to his level of HCV viraemia and anti-viral medication; the periods during which the patient received prochlorperazine are indicated.

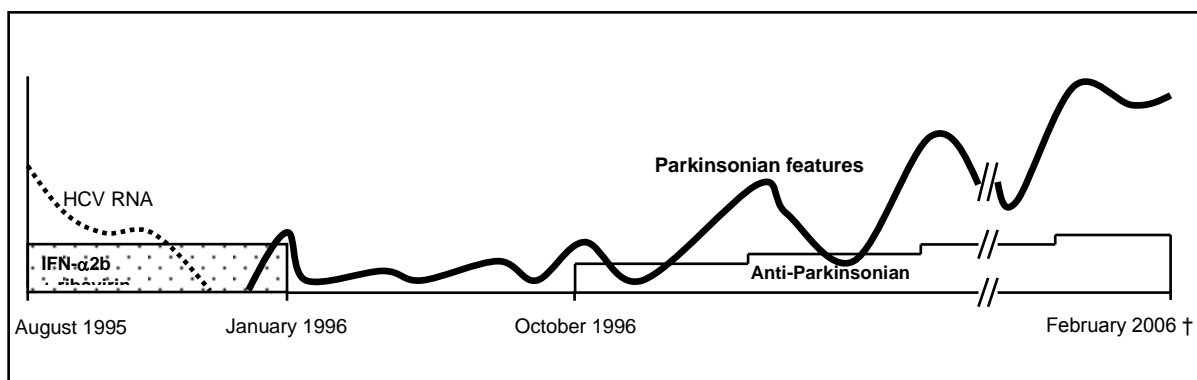
The y axis scale provides an arbitrary representation of the relative severity of the Parkinsonian features and the level of HCV RNA.



HCV: hepatitis C virus; IFN: interferon

**Figure 2.** Evolution of the Parkinsonian features, in Patient 2, in relation to his anti-viral therapy and anti-Parkinsonian medication.

The y axis scale provides an arbitrary representation of the relative severity of the Parkinsonian features and the complexity of the anti-Parkinsonian drug regimen.



HCV: hepatitis C virus; IFN: interferon

1. Chisholm M. Member's Debate on Hepatitis C, 30<sup>th</sup> June. Scottish Parliament, Edinburgh, 2004.
2. World Health Organisation. Global surveillance and control of hepatitis C. Report of a WHO Consultation organised with the Viral Hepatitis Prevention Board, Antwerp, Belgium. *J Viral Hepat* 1999; **6**: 35-47.
3. Hutchinson SJ, Roy KM, Wadd S, Bird SM, Taylor A, Anderson E, Shaw L, Codere G, Goldberg DJ. Hepatitis C virus infection in Scotland: epidemiological review and public health challenges. *Scott Med J* 2006; **51**: 8-15.
4. Hepatitis C in England: The First health Protection Agency Annual Report 2005. London: health Protection Agency centre for infections. December 2005.
5. Manns MP, McHutchison JG, Gordon SC, Rustgi VK, Shiffman M, Reindollar R, Goodman ZD, Koury K, Ling M, Albrecht JK. Peginterferon alfa-2b plus ribavirin compared with interferon alfa-2b plus ribavirin for initial treatment of chronic hepatitis C: a randomised trial. *Lancet* 2002; **358**: 958-965.
6. Fried MW, Shiffman ML, Reddy KR, Smith C, Marinos G, Goncales FL Jr, Häussinger D, Diago M, Carosi G, Dhumeaux D, Craxí A, Lin A, Hoffman J, Yu J. Peginterferon alfa-2a plus ribavirin for chronic hepatitis C virus infection. *N Eng J Med* 2002; **347**: 975-982.
7. Hughes CA, Shafran SD. Chronic hepatitis C virus management: 2000-2005 update. *Ann Pharmacother* 2006; **40**: 74-82.
8. National Institute for Health and Clinical Excellence. TA075 Hepatitis C- pegylated interferons, ribavirin and alpha interferon. January 2004.
9. Booth JC, O'Grady J, Neuberger J; The Royal College of Physicians of London and the British Society of Gastroenterology. Clinical Guidelines on the management of hepatitis C. *Gut* 2001; **29**: 11-21.
10. Fried MW. Side effects of therapy of hepatitis C and their management. *Hepatology* 2002; **36**: S237-S244.
11. Crone C, Gabriel GM. Comprehensive review of hepatitis C for psychiatrists: risks, screening, diagnosis, treatment, and interferon-based therapy complications. *J Psychiatr Pract* 2003; **9**: 93-110.
12. Raison CL, Demetrashvili M, Capuron L, Miller AH. Neuropsychiatric adverse effects of interferon-alpha: recognition and management. *CNS Drugs* 2005; **19**: 105-123.
13. Meyers CA, Scheibel RS, Forman AD. Persistent neurotoxicity of systemically administered interferon-alpha. *Neurology* 1991; **41**: 672-676.

14. Atasoy N, Ustundang Y, Konuk N, Atik L. Acute dystonia during pegylated interferon alpha therapy in a case with chronic hepatitis B infection. *Clin Neuropharmacol* 2004; **27**: 105-107.
15. Mizoi Y, Kaneko H, Oharazawa A, Kuroiwa H. [Parkinsonism in a patient receiving interferon alpha therapy for chronic hepatitis C]. *Rinsho Shinkeigaku* 1997; **37**: 54-56.
16. Bersano A, Aghemo A, Rumi MG, Ballabio E, Candelise L, Colombo M. Recovery after L-DOPA treatment in peginterferon and ribavirin induced parkinsonism. *Eur J Intern Med* 2008; **19**: 370-371.
17. Tolosa E, Coelho M, Gallardo M. DAT imaging in drug-induced and psychogenic parkinsonism. *Mov Disord* 2003; **18**: S28-S33.
18. García-Ruíz PJ, Mena MA, Penafiel N, De Yebenes JG. Cinnarizine-induced parkinsonism in primates. *Clin Neuropharmacol* 1992; **15**: 152-154.
19. Hubble JP. Drug-induced parkinsonism. In: Watts RL, Koller WC, Editors. *Movement disorders: neurologic principles and practice*. New York: McGraw-Hill, 1996.
20. Melamed E, Achiron A, Shapira A, Davidovitz S. Persistent and progressive parkinsonism after discontinuation of chronic neuroleptic therapy: an additional tardive syndrome? *Clin Neuropharmacol* 1991; **14**: 273-278.
21. Booij J, Speelman JD, Horstink MW, Wolters EC. The clinical benefit of imaging striatal dopamine transporters with [123I]FP-CIT SPET in differentiating patients with presynaptic parkinsonism from those with other forms of parkinsonism. *Eur J Nucl Med* 2001; **28**: 266-272.
22. Fleming P, Makar H, Hunter KR. Levodopa in drug-induced extrapyramidal disorders. *Lancet* 1970; **2**: 1186.
23. Kawans HL, Bergen D, Bryn GW. Prolonged drug-induced Parkinsonism. *Confin Neurol* 1973; **35**: 368-377.
24. Negrotti A, Calzetti S. A long-term follow-up study of cinnarizine- and flunarizine-induced parkinsonism. *Mov Disord* 1997; **12**: 107-110.
25. Hardie RJ, Lees AJ. Neuroleptic-induced Parkinson's syndrome: clinical features and results of treatment with levodopa. *J Neurol Neurosurg Psychiatry* 1988; **51**: 850-854.
26. Burn DJ, Brooks DJ. Nigral dysfunction in drug-induced parkinsonism: an <sup>18</sup>F-dopa PET study. *Neurology* 1993; **43**: 552-556.
27. Stephen PJ, Williamson J. Drug-induced parkinsonism in the elderly. *Lancet* 1984; **2**: 1082-1083.

28. Glue P, Fang JW, Rouzier-Panis R, Raffanel C, Sabo R, Gupta SK, Salfi M, Jacobs S. Pegylated interferon-alpha2b: pharmacokinetics, pharmacodynamics, safety, and preliminary efficacy data. Hepatitis C Intervention Therapy Group. *Clin Pharmacol Ther* 2000; **68**: 556-567.
29. Stracciari A, Mattarozzi K, D'Alessandro R, Baldin E, Guarino M. Cognitive functioning in chronic acquired hepatocerebral degeneration. *Metab Brain Dis* 2008; **23**: 155-60.
30. Giewekemeyer K, Berding G, Ahl B, Ennen JC, Weissenborn K. Bradykinesia in cirrhotic patients with early hepatic encephalopathy is related to a decreased glucose uptake of frontomesial cortical areas relevant for movement initiation. *J Hepatol* 2007; **46**: 1034-9.
31. Conn HO, Rössle M, Levy L, Glocker FX. Portosystemic myelopathy: spastic paraparesis after portosystemic shunting. *Scand J Gastroenterol* 2006; **41**: 619-25.
32. Shuto H, Kataoka Y, Horikawa T, Fujihara N, Oishi R. Repeated interferon-alpha administration inhibits dopaminergic neural activity in the mouse brain. *Brain Res* 1997; **747**: 348-351.
33. Bocci V. Central nervous system toxicity of interferons and other cytokines. *J Biol Regul Homeost Agents* 1988; **2**: 107-118.
34. Boka G, Anglade P, Wallach D, Javoy-Agid F, Agid Y, Hirsch EC. Immunocytochemical analysis of tumor necrosis factor and its receptors in Parkinson's disease. *Neurosci Lett* 1994; **172**: 151-154.
35. Hunot S, Dugas N, Faucheux B, Hartmann A, Tardieu M, Debre P, Agid Y, Dugas B, Hirsch EC. FcεRII/CD23 is expressed in Parkinson's disease and induces, *in vitro*, production of nitric oxide and tumor necrosis factor-α in glial cells. *J Neurosci* 1999; **19**: 3440-3447.
36. Liu B, Hong J-S. Role of microglia in inflammation-mediated neurodegenerative diseases: mechanisms and strategies for therapeutic intervention. *J Pharmacol Exp Ther* 2003; **304**: 1-7.
37. Hansen TE, Brown WL, Weigel RM, Casey DE. Underrecognition of tardive dyskinesia and drug-induced parkinsonism by psychiatric residents. *Gen Hosp Psychiatry* 1992; **14**: 340-344.