

# Developmental conduction aphasia after neonatal stroke

Revision 2

15/01/2018

Gemma B Northam<sup>1,2\*</sup>, Sophie Adler<sup>1,2</sup>, Kathrin C J Eschmann<sup>1,&</sup>, Wui K Chong<sup>2</sup>, Frances M Cowan<sup>3,4</sup>, Torsten Baldeweg<sup>1,2\*</sup>

1) Great Ormond Street Institute of Child Health, Developmental Neurosciences Programme, University College London, London, WC1N 1EH, UK; 2) Great Ormond Street Hospital for Children NHS Foundation Trust, Great Ormond Street, London, UK; 3) Imperial College London and 4) Imperial College Health Care Trust, London, UK.

**\*Corresponding authors:** UCL Great Ormond Street Institute of Child Health, 30 Guilford Street, London WC1N 1EH, U.K., e-mail: [t.baldeweg@ucl.ac.uk](mailto:t.baldeweg@ucl.ac.uk);

**&** current address: Experimental Neuropsychology Unit, Saarland University, Saarbrücken, Germany.

**Word count:** 5849 (including title page, abstract, references), body of text: 4050

**Keywords:** conduction aphasia, language, children, neonatal, stroke, plasticity

**Abbreviations:** CELF=Comprehensive Evaluation of Language Fundamentals; CTOPP=Comprehensive Test of Phonological Processing; DWI=diffusion-weighted imaging; ROI=region of interest.

This article has been accepted for publication and undergone full peer review but has not been through the copyediting, typesetting, pagination and proofreading process which may lead to differences between this version and the Version of Record. Please cite this article as an 'Accepted Article', doi: 10.1002/ana.25218

**ABSTRACT**

**Objective:** Impairment of speech repetition following injury to the dorsal language stream is feature of conduction aphasia - a well-described 'disconnection syndrome' in adults. The impact of similar lesions sustained in infancy has not been established.

**Methods:** We compared language outcomes in term-born individuals with confirmed neonatal stroke (n=30; age: 7-18 years, left-sided lesions in 21 cases) to matched controls (n=40). Injury to the dorsal and/or ventral language streams was assessed using T<sub>1</sub>- and T<sub>2</sub>-weighted MRI and diffusion tractography. Language lateralization was determined using functional MRI.

**Results:** At the group level, left dorsal language stream injury was associated with selective speech repetition impairment for non-words (p=0.021) and sentences (p<0.0001). The majority of children with significant repetition impairment had retained left hemisphere language representation, but right hemisphere dominance was correlated with minimal or absent repetition deficits. Post-hoc analysis of the repetition-impaired group revealed additional language-associated deficits, but these were more subtle and variable.

**Interpretation:** We conclude that (i) despite the considerable plasticity of the infant brain, early dorsal language stream injury can result in specific and long-lasting problems with speech repetition that are similar to the syndrome of conduction aphasia seen in adults, and that (ii) language reorganization to the contralateral hemisphere has a protective effect.

## **INTRODUCTION**

Conduction aphasia was first described by Carl Wernicke<sup>1</sup> and was characterized by relatively intact comprehension, with paraphasic expressions and word-finding problems. The notion of impaired repetition was introduced by Lichtheim<sup>2</sup> and is now a core part of modern diagnostic criteria<sup>3,4,5</sup>. Conduction aphasia was regarded as a 'disconnection syndrome' by Geschwind<sup>3</sup> representing an interruption of connections between the anterior and posterior language areas<sup>4,6</sup>. This early connectionist model was expanded by recent imaging studies into the dual stream model of language<sup>7,8</sup>. This distinguishes a 'dorsal language stream', of which the arcuate fasciculus is a key element, from an anatomically distinct 'ventral stream'. The dorsal stream connects speech regions in the temporal lobe with the inferior parietal cortex and posterior frontal lobe. These regions are involved in mapping speech sounds to articulatory representations, which is critical for speech repetition, especially when repeating and learning novel words. In contrast, the ventral stream projects rostrally via the anterior temporal lobe towards the inferior frontal lobe and involves the extreme capsule fiber system and uncinate fasciculus<sup>9,10,11</sup>. This stream serves 'sound to meaning mapping' by associating speech with semantic and conceptual representations in the anterior temporal lobe, a system important for meaningful speech<sup>7,8</sup>.

However, the roles of the two streams during language development continues to be debated<sup>12,13,14,15</sup> and the differential impact of early dorsal versus ventral stream lesions is not known. Nevertheless, it is generally accepted that damage to perisylvian language areas in infancy or childhood does not result in analogous aphasia syndromes to those in adults<sup>16,17,18,19,20</sup>, presumably as a result of cerebral plasticity. A critical question is whether the left dorsal stream, and in particular the arcuate fasciculus, fulfils specific functional roles that cannot be compensated for by the ventral stream or the right cerebral hemisphere.

This question is of direct clinical relevance in view of the comparatively high incidence of stroke in the neonatal period<sup>21</sup>, which commonly occurs in the territory of the left middle cerebral artery that supplies most of the dorsal stream regions. Given the association between adult dorsal stream injury and conduction aphasia, we sought to determine whether repetition deficits might be present following similar lesions in a cohort of term-born children who

sustained a stroke at birth<sup>22</sup>. We chose a range of repetition tasks, involving digit strings, non-words and sentences of increasing complexity, separating participants into dorsal and non-dorsal (including ventral stream) lesion groups.

Speech repetition problems are thought to impact on language learning and are established predictors of impaired literacy and language development in childhood<sup>23</sup>. Also in view of the presumed functional role of the dorsal stream in language learning<sup>13</sup> we assessed speech repetition in the context of other abilities, such as vocabulary and comprehension, reading and spelling. Language lateralization was assessed using functional MRI, given that repetition deficits might be modified by interhemispheric reorganization<sup>4</sup>.

## **PATIENTS AND METHODS**

### **STUDY POPULATION**

We recruited 30 term-born English-speaking individuals (age: 7-18 years) with MRI-confirmed ischemic/hemorrhagic stroke in the neonatal period. Participants were drawn from a prospective cohort of neurologically symptomatic infants, born at or referred to the Hammersmith Hospital, London<sup>22</sup>. All had early MRI, which were reviewed for the present study, and were followed-up regularly. A term-born control group (n=40) was also recruited, group-matched for age (range: 6-18 years), sex and maternal education (**Table 1**). A total of 13 individuals were bilingual with native English proficiency (stroke cohort: n=8, controls: n=5). All stroke cases were independently mobile, nine had hemiparesis and four had had post-neonatal seizures, but only two were currently using anti-epileptic medication. The majority of strokes were ischemic, affecting the territory of the left middle cerebral artery. All but two children were in mainstream education, with 12 (40%) receiving additional educational support.

### **NEUROIMAGING AT FOLLOW-UP**

**Structural MRI acquisition:** All participants were scanned with a 1.5T Avanto Siemens scanner. Three-dimensional data sets were acquired using a T<sub>1</sub>-weighted 3D-FLASH sequence (TR=11ms, TE=4.94ms, flip angle=15°, field of view=256mm, matrix size=256x256, voxel

size=1x1x1mm<sup>3</sup>) and a T<sub>2</sub>-weighted FLAIR sequence (TR=6000ms, TE=353ms, flip angle=150°, field of view=256mm, matrix =256x256, voxel size=1x1x1mm<sup>3</sup>). Diffusion weighted imaging (DWI) data were acquired using an eddy-current-nulled twice-refocused EPI sequence with high-angular resolution (b-value=3000s/mm<sup>2</sup>, TE=128ms, 60 diffusion-weighted directions, in-plane resolution 2.1x2.1mm<sup>2</sup>, 3mm slice thickness, all as in ref.<sup>24</sup>).

**Functional MRI (fMRI):** Language lateralization was examined using a well-validated verb generation task<sup>25</sup> using a block design with two separate runs of 10 active task and rest phases each. Functional data were analyzed using SPM8 software (<http://www.fil.ion.ucl.ac.uk/spm/software/spm8/>) and threshold-independent lateralization indices in Broca's region and the cerebellum were calculated for each participant<sup>26</sup>.

**Lesion identification and quantification:** All follow-up scans were evaluated by a pediatric neuroradiologist (WKC) using a standardized protocol for territory of lesion, including the assessment of cortical and subcortical structures in each hemisphere and, secondly, for injury to peri-sylvian gray and white matter sites which form the putative dorsal and ventral language streams. Lesions were traced (by KCJE, blinded to any other clinical information) in native space, on T<sub>1</sub>-weighted images guided by additional tissue contrast derived from co-registered T<sub>2</sub>-weighted images (examples cases shown in **Figure 1A**). Lesion maps were then spatially normalized using the VBM toolbox (<http://dbm.neuro.uni-jena.de/vbm/>) and overlay maps were created using MRICroGL (<http://www.cabiatl.com/mricrogl>).

**Quantification of damage to language streams:** Patients with lesions in the left hemisphere were categorized into three groups based on lesion location: (i) 'dorsal lesions', (ii) 'ventral lesions', (iii) 'combined dorsal and ventral lesions'. A fourth 'other lesions' group were cases with lesions elsewhere including those with right hemisphere injury. Grouping was guided by neuroradiological review and quantitative analysis of grey matter injury. DWI-based tractography was used to confirm language tract damage at group level.

a) **Quantification of cortical involvement:** this was quantified using predefined ROI (shown in **Figure 1B**) based on combined fMRI evidence<sup>27,8</sup> and putative termination regions of the arcuate fasciculus and extreme capsule/uncinate fasciculus<sup>8,11</sup>. Dorsal stream regions

included the pars opercularis of the inferior frontal gyrus, the inferior parietal lobule, the posterior part of the superior temporal gyrus (Wernicke's area) and the middle and posterior parts of the middle temporal gyrus. Regions included in the ventral stream were the pars triangularis and pars orbitalis<sup>11</sup> of the inferior frontal gyrus and the anterior temporal lobe (superior, middle and inferior temporal gyri, anterior to Heschl's gyrus). First, ROI masks were created based on the AAL atlas<sup>28</sup>. The lateral projection of Heschl's gyrus was used to divide temporal ROIs into anterior and posterior portions. The individual normalized lesions masks were then overlaid onto each ROI allowing for calculation of the number of overlapping voxels. Percentage overlap of each lesion within these cortical ROIs and the total percentage of cortical lesion overlap within each language stream was calculated.

b) *DWI-tractography of white matter tracts* belonging to the dorsal and ventral streams (**Figure 1B**) were dissected using probabilistic streamline fiber-tracking as described in detail elsewhere<sup>24</sup>. In brief, the arcuate fasciculus (AF) and its segments were dissected using two-regions-of-interest (ROI) tractography<sup>29</sup>. The frontal seed ROI was identified lateral to the pyramidal tract, while the temporal lobe target ROI was defined by a single coronal slice just posterior to the transverse temporal gyri. The parietal ROI was determined using the boundaries of the inferior parietal lobule. The direct AF segment connected the frontal and temporal ROIs, while the anterior indirect segment connected the frontal and parietal ROIs. The posterior indirect segment was created by tracking between the parietal and temporal ROIs. Tractography of the ventral stream was defined as follows<sup>30</sup>: In view of the limited resolution we combined uncinata fasciculus (UF) and extreme capsule into one fiber system (UF/ECFS). The UF was determined using a seed ROI placed on four adjacent axial slices in the white matter of anterior temporal lobe. The fibers of the extreme capsule were collected from the white matter of the superior temporal gyrus anterior to Heschl's gyrus. The target ROI for both tracts was the white matter of the extreme capsule, identified on four axial slices. The total apparent volume and mean fractional anisotropy were determined within a binary mask created for each tract.

## NEUROPSYCHOLOGICAL ASSESSMENT

All patients and controls received a comprehensive evaluation of language and intellectual abilities. Intelligence was assessed using the Wechsler Abbreviated Scale of Intelligence (WASI) and separate verbal, non-verbal and full-scale IQ scores were calculated.

**Language assessments:** The Expressive and Receptive scales from the Comprehensive Evaluation of Language Fundamentals (CELF-3<sup>UK</sup>) assessed a range of expressive and receptive abilities. The receptive scale included: 'Concepts and Directions' (interpretation, recall and execution of oral commands that require logic operations), 'Word Classes' (identifying semantic relationships between two words by selecting and repeating two words out of three or four spoken words that 'go together best'), and 'Semantic Relationships' (interpreting semantic relationships in sentences using multiple choice questions). The remaining subtests formed the expressive score: 'Formulating Sentences' (construction of grammatically and syntactically correct sentences using a particular word based on a picture), 'Repeating Sentences' (see below) and 'Sentence Assembly' (production of two accurate sentences from an array of words).

**Speech repetition:** 1) Non-word repetition was assessed using the phonological memory component from the Comprehensive Test of Phonological Processing (CTOPP). 2) Sentence repetition was assessed using the 'Repeating Sentences' subtest from the CELF-3<sup>UK</sup>, involving the verbatim repetition of sentences of increasing length and syntactic complexity. 3) Repetition of digit strings was evaluated using the Memory for Digits test from the CTOPP and the digit span test from the age-appropriate Wechsler Scale.

**Additional assessments** included the Expressive and Receptive One-Word Picture Vocabulary tests, the Test for Reception of Grammar (to test understanding of grammatical contrasts of increasing difficulty), the Wechsler Objective Reading Dimensions (to evaluate spelling, reading and comprehension abilities) and the Phonological Awareness component of the CTOPP (testing the ability to perceive and manipulate sounds of spoken words).

## STATISTICAL ANALYSES

Group differences in demographic, clinical and cognitive data were tested using independent samples t-tests,  $\chi^2$ , analysis of variance and Mann-Whitney tests, where appropriate. Univariate analyses of variance were used to test the effect of language stream lesions on neuropsychological scores and brain measures. Language-specific effects are more readily detected when differences due to general cognitive ability (as reflected in full scale IQ scores) are taken into account<sup>24</sup>. Similarly, lesion effects on cognition can be revealed when alteration in language lateralization is taken into account, especially in populations with developmental brain injury<sup>31</sup>. Therefore, covariation for full-scale IQ and language lateralization was performed where appropriate. Bonferroni correction for multiple comparisons was applied (for a total of 10 comparisons:  $p < 0.005$ ). We used two fixed factors in analyses of variance ('dorsal lesion' and 'ventral lesion'), denoting for each case if a lesion was present or not present within those regions.

#### **ETHICAL APPROVAL AND PATIENT CONSENT**

Ethical approval for the study was obtained from institutional Research Ethics Committee and written informed consent was obtained from all participants or their parents.

#### **RESULTS**

##### **DORSAL AND VENTRAL STREAM INJURY**

Lesions within either the dorsal or the ventral language stream (in the left cerebral hemisphere) were identified in 20 out of 30 individuals. Eight cases had isolated dorsal injury, four had isolated ventral stream injury and eight cases had varying degrees of injury to both streams. Ten participants had injury outside of these regions. Representative case examples are shown in **Figure 1A**. In patients with dorsal stream damage, the most common sites of injury were the inferior parietal lobule (11/16 cases) and posterior part of the superior temporal gyrus (12/16 cases). In the ventral lesion group, the most common site of injury was the anterior temporal lobe (6/11 cases). The 'other lesion' group included all cases with injury to the right hemisphere and lesions confined to the left somato-motor regions, as shown in the overlay



map in **Figure 1C**. DWI-tractography confirmed that injury involving regions of the dorsal language stream affected the left arcuate fasciculus volume ( $p=0.001$ ). Lesions affecting the left ventral stream areas most consistently affected the extreme capsule/uncinate fiber volume ( $p=0.010$ ). Isolated lesions in the dorsal and ventral streams were of similar size to those of the other lesions group (14.8, 16.7, 11.3ml, respectively, only combined ventral and dorsal lesions were larger (83.8ml,  $F(3,26)=6.1$ ,  $p=0.003$ ).

### LANGUAGE PROFILE

In the patient group, total expressive and receptive language scores (CELF-3<sup>UK</sup>) were lower than controls, but nevertheless in the average range (within 1 SD of the mean) and in keeping with the lower FSIQ scores of this group (**Table 1**). The combined group with dorsal and/or ventral lesions in left hemisphere scored more poorly in language tasks than expected for their general level of cognitive functioning (CELF total scores lower than non-verbal IQ by 10 points) compared to the other lesion group ( $t=2.24$ ,  $p=0.033$ ), which were not different from controls ( $p=0.131$ ).

Analyses of the CELF-3<sup>UK</sup> and CTOPP language subtest scores revealed that dorsal stream injury was (at the group level) associated with specific deficits in non-word repetition ( $F(1,27)=5.87$ ,  $p=0.023$ ) and repeating sentences ( $F(1,27)=7.19$ ,  $p=0.013$ ) (**Table 2, Figure 2** and shown as profile plots for individual example cases in **Figure 3**). This effect that was not observed for ventral stream injury (all  $p>0.154$ ). There were no differences between lesion groups on repetition of digits strings, total expressive/receptive language scores, receptive grammar, phonological awareness or literacy (all  $p>0.245$ ). The sentence repetition score of the other lesion group was not different from control values ( $p=0.465$ ).

To explore whether individual differences in repetition could be accounted for by shifts in language lateralization we covaried for fMRI laterality index in Broca's region; speech repetition effects remained significant ( $p<0.0001$ ) in the dorsal lesion group (**Table 2**). Interestingly, a deficit emerged for the ventral lesion group in the comprehension of verbal

instructions (concepts and direction subtest from the CELF-3<sup>UK</sup>,  $p=0.002$ ). Covariation for lesion volume did not alter the pattern of findings.

Types of errors identified in the impaired repetition group were highly varied (even within individuals) and included: sentence rephrasing, simple omissions, substitutions, additions or reversals/transposals of single words. The most severely affected cases frequently forgot the entire sentence immediately. While the errors typically allowed patients to retain the semantic gist<sup>32</sup>, occasionally the meaning was altered. For example, for the target sentence: “The girl who lives upstairs in my block of flats is in my class”, the response of case 1 (in Figure 3) was: “The girl that lives in the block of flats upstairs is in the same school as me” (scoring 0/3). An example for the latter error type: target sentence: “The computers and printers were donated by the school governors”, and response (case 3 in Figure 3): “The school computers were donated by the government last year” (scores 0/3). None of the cases had paraphasic speech or made spontaneous attempts at self-correction.

The severity of sentence repetition deficits varied within the dorsal lesion group. Based on IQ-corrected scores, seven cases showed no obvious or minor sentence repetition problems (within 1 SD of the mean), six cases showed a moderate impairment (1-2 SDs below average) and three cases had severe repetition problems ( $>2$  SDs). These scores provided the basis for dividing the dorsal lesion group into those with *normal repetition* ( $n=7$ ) and those with *impaired repetition* ( $n=9$ ,  $>1$  SD). Bilingualism was not associated with repetition impairment (Fisher's exact:  $p=0.691$ ).

## REPETITION DEFICITS AND LANGUAGE LATERALIZATION

Subsequent group comparisons between dorsal injury cases with and without repetition impairment did not reveal differences in lesion size or degree of cortical involvement in any of the language regions of interest examined (all  $p>0.211$ ) and there was no difference in arcuate fasciculus volumes (all  $p>0.310$ ) in both hemispheres. Similarly, examination of lesion overlay maps did not show obvious qualitative differences (showing maximal overlap in the left temporo-parietal junction, **Figure 4A**), with the exception of two cases with large fronto-temporo-parietal lesions in the normal repetition group (cases 3 and 4 in Figure 1).

Examination of fMRI lateralization patterns in individual cases (**Figure 3**) suggested that speech repetition is better in individuals with right hemisphere language dominance (case 4), despite instances where the lesion location was similar to that of individuals with a severe deficit (case 3). This hypothesis was tested by comparing fMRI laterality indices between repetition impairment groups (**Figure 4**). Cases with impaired speech repetition had more positive (left-lateralized) values in Broca's region compared to the unimpaired group, who were more likely to recruit their (intact) right hemisphere (Mann-Whitney:  $p=0.005$ ). This was confirmed for the fMRI lateralization in the cerebellum (Mann-Whitney:  $p<0.001$ ), which was structurally intact in all patients and shows reliable cross-lateralization in relation to the frontal lobe<sup>33</sup>. Atypical cerebellar lateralization was correlated ( $\rho=0.80$ ,  $p=0.001$ ) with preserved repetition performance (**Figure 4**).

#### **ASSOCIATED LANGUAGE DEFICITS**

To determine if the speech repetition impairment is associated with other language deficits, the repetition-impaired group was compared with the remaining stroke sample. After adjusting for FSIQ, this group also had lower scores in (i) CELF-3<sup>UK</sup> receptive language (Cohen's  $d=1.55$ ,  $p=0.001$ ), (ii) reading ( $d=0.95$ ,  $p=0.011$ ), (iii), spelling ( $d=0.89$ ,  $p=0.018$ ), (iv) receptive and expressive vocabulary ( $d=1.52/1.05$ ,  $p=0.001/0.013$ , respectively) and (v) receptive grammar ( $d=.84$ ,  $p=0.047$ ). These deficits were more subtle and variable across individuals but specific to language abilities, as verbal and non-verbal IQ scores did not differ. Of note, these associated language deficits were directly correlated with the degree of sentence repetition impairment, even after covarying for FSIQ (ranging from  $r=0.67-0.42$ , all  $p<0.05$ ).

#### **DISCUSSION**

Our key findings are that (i) at the group level, neonatal left dorsal language stream injury can lead to long-lasting impairment in verbatim sentence repetition, which is similar to conduction aphasia in adults and (ii) that this function was relatively preserved in cases with right hemisphere language dominance.

In keeping with earlier studies we confirm that injury to left hemisphere eloquent regions is associated with language decrements<sup>34,35</sup>, independent of lesion size<sup>35</sup> and that many

affected cases do not show a language shift to the right hemisphere<sup>35,36</sup>. In contrast to previous work, we propose the existence of a developmental form of conduction aphasia that occurs following early left dorsal stream injury and is characterized by a persistent deficit in verbatim speech repetition. The most common lesion location in the left temporo-parietal junction (Figure 4A, middle column) was similar to that seen in adults with conduction aphasia<sup>5</sup> which typically involves the left posterior planum temporale, inferior parietal lobule (including area Spt<sup>7,37,38</sup> or the arcuate fasciculus<sup>39</sup>. Interestingly, case 3 in Figure 3 with severely impaired repetition had a lesion involving the left anterior arcuate fasciculus, leaving posterior area Spt intact. This supports the notion that the necessary and sufficient basis for the speech repetition deficit is a 'disconnection' between posterior and anterior association cortices<sup>3,6,40</sup>. Children with injury to other regions of the left or right cerebral hemispheres, including the left ventral language stream, did not show such impairments, confirming the anatomical specificity of this finding.

Acquired fluent aphasia is described in childhood<sup>41,42,17</sup> and in some cases conduction aphasia has been documented<sup>43,44,45</sup>. However, apart from a single case report following a stroke at three years of age<sup>17</sup> repetition deficits are generally transient, presumably due to lesion resolution or functional reorganization. In contrast, our study provides evidence for long-lasting repetition impairment despite the early timing of the injuries, when the potential for cerebral plasticity is presumably at a maximum.

#### **DEVELOPMENTAL IMPLICATIONS FOR THE DUAL STREAM MODEL**

We propose that this cohort shows a 'developmental variant' of conduction aphasia which differs from the adult-onset form in certain respects. Our affected patients fulfil three of the classical criteria, with the exception of paraphasic speech. A milder phenotype is not at all uncommon in a developmental context and perhaps also not surprising given the enormous potential for plasticity in the developing brain.

A critical difference relates to the fact in our cohort injury occurred at an early stage of brain development, prior to the emergence of spoken language. Given the putative functional roles of the dorsal stream for auditory-motor integration, such damage may also have a

detrimental effect on word learning<sup>7,46,47</sup> and development of phonological ability, whilst the later-maturing role in verbal memory and syntactic integration<sup>48</sup> could have an impact on the comprehension and formulation of complex sentences. We speculate that the associated deficits observed here in phonology and literacy, vocabulary, and complex language may reflect these presumed developmental functions of the dorsal stream<sup>13,46</sup>. Interestingly, these subtle and variable deficits are directly correlated with the degree of repetition impairment, supporting the possibility that they may represent a 'knock-on' effect secondary to a primary repetition impairment<sup>23,49</sup>.

In view of this we propose the term 'developmental conduction aphasia' to highlight the association with early connectionist models of language<sup>2,3,40,6</sup> and the similarities in lesion distribution<sup>50,5</sup>. We acknowledge the absence of paraphasic speech in comparison with the adult-onset form and emphasize the putative developmental functions of the dorsal stream. Nevertheless, speech repetition impairment is a striking feature common to both forms, which perhaps reveals a major functional specialization of the dorsal stream, seemingly invariant to the timing of injury.

Our findings extend the dual stream model<sup>7</sup> to the special case when stroke injury occurred before the emergence of speech and language. Importantly, it appears that the ventral stream cannot compensate for the loss of left dorsal stream function, but that right hemisphere language dominance has a protective effect. We speculate that in the majority of cases this reflects a lesion-induced switch to the unaffected, contralateral hemisphere<sup>51</sup>.

An additional finding was a deficit in the ability to comprehend and follow verbal instructions in cases with ventral stream lesions, which was accentuated when functional lateralization was taken into account. Although the number of cases with isolated ventral injury was small, this finding is compatible with the proposed role of the ventral stream in speech comprehension<sup>7,8</sup>.

## **LIMITATIONS OF STUDY DESIGN AND METHODS**

Our cohort was diverse in terms of lesion distribution. Nevertheless, a major advantage was that all cases were term-born children with a perinatal stroke confirmed on neonatal MRI.

Given the focus on left hemisphere lesions, it was clearly not possible to make inferences about the impact of injuries to right hemisphere homologues<sup>19,52</sup>. We also minimized the known difficulties in quantifying large brain lesions<sup>35</sup> by manual measurement of lesions in native space. The possibility of crossed functional and structural lateralization<sup>4</sup> cannot be excluded as multiple expressive and receptive fMRI tasks were not employed, but the clinical protocol reliably predicts hemispheric dominance across a wide age range<sup>25,53</sup>.

Unlike in adult stroke patients, where the integrity of the right hemisphere arcuate fasciculus appears to facilitate speech recovery<sup>54</sup>, we did not find differences between repetition deficit groups in the architecture of language tracts on the right side<sup>30,55</sup>. We also found no evidence for differences in lesion site or size in the left posterior temporal lobe<sup>50</sup> or sex differences<sup>56</sup>, although our study had limited power to detect such effects. The only robust difference was in atypical language laterality, either as a result of extensive left hemispheric injury or specific language cortex lesions<sup>51</sup> which apparently can release the compensatory plasticity of the right cerebral hemisphere<sup>57</sup>.

## CONCLUSIONS

This is the first study to examine the impact of early injury to the dorsal stream and identifies a developmental form of conduction aphasia with similar anatomical lesion distribution and common neuropsychological features to the classical 'disconnection syndrome' described in adults. Although the absence of paraphasia in our cohort is noteworthy, a milder phenotype is not uncommon in developmental variants and may reflect the inherent plasticity of the immature brain. In those children who did not show interhemispheric transfer, the demonstration of long-lasting repetition deficits (and more subtle additional language problems) provides intriguing evidence that there are inherent limitations to cerebral plasticity, even when damage occurs in the very young. This finding is particularly important given the association with subsequent academic difficulties in this population<sup>45</sup> and underscores the need for early identification and remediation. It also offers a neuroanatomical basis for a key behavioral marker of specific language impairment<sup>22</sup>, by showing that non-word and sentence repetition is highly dependent on the integrity of the left dorsal language stream.

## **ACKNOWLEDGEMENT**

We thank Tina Banks for performing all MRI scanning and all the families of the children involved in this study. We are grateful to Dr Paul Johns for critical comments on the manuscript. This research was funded by Action Medical Research UK and Great Ormond Street Hospital Children's Charity and supported by the National Institute for Health Research Biomedical Research Centre at Great Ormond Street Hospital NHS Foundation Trust and University College London.

## **AUTHOR CONTRIBUTIONS**

GBN, TB and FC contributed to the conception and design of the study. GBN, FC, TB, SA, KCJE and WKC contributed to the acquisition and analysis of data. GBN, TB and FC contributed to drafting the text and preparing the figures.

## **POTENTIAL CONFLICTS OF INTEREST**

The authors have no conflicts of interest to declare.

## **REFERENCES**

1. Wernicke C. Der aphasische Symptomencomplex. Eine psychologische Studie auf anatomischer Basis [The aphasic symptom complex: a psychological study from an anatomical basis]. Breslau: M. Crohn und Weigert 1874.
2. Lichtheim L. On aphasia. *Brain*. 1885;7:51.
3. Geschwind N. Disconnexion syndromes in animals and man. II. *Brain*. 1965 Sep;88(3):585-644.
4. Bernal B, Ardila A. The role of the arcuate fasciculus in conduction aphasia. *Brain*. 2009 Sep;132(Pt 9):2309-16.
5. Dronkers NF, Baldo J. Language: aphasia. *Encyclopedia of neuroscience*: Elsevier Ltd; 2010.
6. Mesulam MM. Fifty years of disconnection syndromes and the Geschwind legacy. *Brain*. 2015 Sep;138(Pt 9):2791-9.
7. Hickok G, Poeppel D. Dorsal and ventral streams: a framework for understanding aspects of the functional anatomy of language. *Cognition*. 2004 May-Jun;92(1-2):67-99.
8. Saur D, Kreher BW, Schnell S, et al. Ventral and dorsal pathways for language. *Proc Natl Acad Sci U S A*. 2008 Nov 18;105(46):18035-40.
9. Parker GJ, Luzzi S, Alexander DC, Wheeler-Kingshott CA, Ciccarelli O, Lambon Ralph MA. Lateralization of ventral and dorsal auditory-language pathways in the human brain. *Neuroimage*. 2005 Feb 01;24(3):656-66.
10. Anwender A, Tittgemeyer M, von Cramon DY, Friederici AD, Knosche TR. Connectivity-Based Parcellation of Broca's Area. *Cereb Cortex*. 2007 Apr;17(4):816-25.



11. Frey S, Campbell JS, Pike GB, Petrides M. Dissociating the human language pathways with high angular resolution diffusion fiber tractography. *J Neurosci*. 2008 Nov 05;28(45):11435-44.
12. Brauer J, Anwender A, Friederici AD. Neuroanatomical prerequisites for language functions in the maturing brain. *Cereb Cortex*. 2011 Feb;21(2):459-66.
13. Friederici AD. Language development and the ontogeny of the dorsal pathway. *Front Evol Neurosci*. 2012;4:3.
14. Dehaene-Lambertz G, Hertz-Pannier L, Dubois J. Nature and nurture in language acquisition: anatomical and functional brain-imaging studies in infants. *Trends Neurosci*. 2006 Jul;29(7):367-73.
15. Dubois J, Poupon C, Thirion B, et al. Exploring the Early Organization and Maturation of Linguistic Pathways in the Human Infant Brain. *Cereb Cortex*. 2016 May;26(5):2283-98.
16. Bates E, Reilly J, Wulfeck B, et al. Differential effects of unilateral lesions on language production in children and adults. *Brain Lang*. 2001 Nov;79(2):223-65.
17. Chilosi AM, Cipriani P, Pecini C, et al. Acquired focal brain lesions in childhood: effects on development and reorganization of language. *Brain Lang*. 2008 Sep;106(3):211-25.
18. Muter V, Taylor S, Vargha-Khadem F. A longitudinal study of early intellectual development in hemiplegic children. *Neuropsychologia*. 1997 Mar;35(3):289-98.
19. Stiles J, Reilly J, Paul B, Moses P. Cognitive development following early brain injury: evidence for neural adaptation. *Trends Cogn Sci*. 2005 Mar;9(3):136-43.
20. Mosch SC, Max JE, Tranel D. A matched lesion analysis of childhood versus adult-onset brain injury due to unilateral stroke: another perspective on neural plasticity and recovery of social functioning. *Cognitive and behavioral neurology : official journal of the Society for Behavioral and Cognitive Neurology*. 2005 Mar;18(1):5-17.
21. Schulzke S, Weber P, Luetsch J, Fahnenstich H. Incidence and diagnosis of unilateral arterial cerebral infarction in newborn infants. *Journal of perinatal medicine*. 2005;33(2):170-5.
22. Ricci D, Mercuri E, Barnett A, et al. Cognitive outcome at early school age in term-born children with perinatally acquired middle cerebral artery territory infarction. *Stroke*. 2008 Feb;39(2):403-10.
23. Conti-Ramsden G, Botting N, Faragher B. Psycholinguistic markers for specific language impairment (SLI). *J Child Psychol Psychiatry*. 2001 Sep;42(6):741-8.
24. Northam GB, Liegeois F, Tournier JD, et al. Interhemispheric temporal lobe connectivity predicts language impairment in adolescents born preterm. *Brain*. 2012 Dec;135(Pt 12):3781-98.
25. Liegeois F, Connelly A, Salmond CH, Gadian DG, Vargha-Khadem F, Baldeweg T. A direct test for lateralization of language activation using fMRI: comparison with invasive assessments in children with epilepsy. *Neuroimage*. 2002 Dec;17(4):1861-7.
26. Wilke M, Lidzba K. LI-tool: a new toolbox to assess lateralization in functional MR-data. *J Neurosci Methods*. 2007 Jun 15;163(1):128-36.
27. Vigneau M, Beaucousin V, Herve PY, et al. Meta-analyzing left hemisphere language areas: phonology, semantics, and sentence processing. *Neuroimage*. 2006 May 01;30(4):1414-32.
28. Tzourio-Mazoyer N, Landeau B, Papathanassiou D, et al. Automated anatomical labeling of activations in SPM using a macroscopic anatomical parcellation of the MNI MRI single-subject brain. *Neuroimage*. 2002 Jan;15(1):273-89.
29. Catani M, Jones DK, ffytche DH. Perisylvian language networks of the human brain. *Ann Neurol*. 2005 Jan;57(1):8-16.
30. Thiebaut de Schotten M, Ffytche DH, Bizzi A, et al. Atlasing location, asymmetry and inter-subject variability of white matter tracts in the human brain with MR diffusion tractography. *Neuroimage*. 2011 Jan 01;54(1):49-59.
31. Skirrow C, Cross JH, Harrison S, et al. Temporal lobe surgery in childhood and neuroanatomical predictors of long-term declarative memory outcome. *Brain*. 2015 Jan;138(Pt 1):80-93.



32. Baldo JV, Klostermann EC, Dronkers NF. It's either a cook or a baker: patients with conduction aphasia get the gist but lose the trace. *Brain Lang.* 2008 May;105(2):134-40.
33. Lidzba K, Wilke M, Staudt M, Krageloh-Mann I, Grodd W. Reorganization of the cerebro-cerebellar network of language production in patients with congenital left-hemispheric brain lesions. *Brain Lang.* 2008 Sep;106(3):204-10.
34. Ballantyne AO, Spilkin AM, Hesselink J, Trauner DA. Plasticity in the developing brain: intellectual, language and academic functions in children with ischaemic perinatal stroke. *Brain.* 2008 Nov;131(Pt 11):2975-85.
35. Raja Beharelle A, Dick AS, Josse G, et al. Left hemisphere regions are critical for language in the face of early left focal brain injury. *Brain.* 2010 Jun;133(Pt 6):1707-16.
36. Tillema JM, Byars AW, Jacola LM, et al. Cortical reorganization of language functioning following perinatal left MCA stroke. *Brain Lang.* 2008 May;105(2):99-111.
37. Buchsbaum BR, Baldo J, Okada K, et al. Conduction aphasia, sensory-motor integration, and phonological short-term memory—an aggregate analysis of lesion and fMRI data. *Brain and language.* 2011;119(3):119-28.
38. Rogalsky C, Poppa T, Chen KH, et al. Speech repetition as a window on the neurobiology of auditory-motor integration for speech: A voxel-based lesion symptom mapping study. *Neuropsychologia.* 2015 May;71:18-27.
39. Fridriksson J, Kjartansson O, Morgan PS, et al. Impaired speech repetition and left parietal lobe damage. *J Neurosci.* 2010 Aug 18;30(33):11057-61.
40. Catani M, Mesulam M. The arcuate fasciculus and the disconnection theme in language and aphasia: history and current state. *Cortex.* 2008 Sep;44(8):953-61.
41. van Dongen HR, Paquier PF, Creten WL, van Borsel J, Catsman-Berrevoets CE. Clinical evaluation of conversational speech fluency in the acute phase of acquired childhood aphasia: does a fluency/nonfluency dichotomy exist? *Journal of child neurology.* 2001 May;16(5):345-51.
42. Paquier PF, Van Dongen HR. Review of research on the clinical presentation of acquired childhood aphasia. *Acta neurologica Scandinavica.* 1996 Jun;93(6):428-36.
43. VanDongen HR, Loonen CB, VanDongen KJ. Anatomical basis for acquired fluent aphasia in children. *Ann Neurol.* 1985 Mar;17(3):306-9.
44. Martins IP, Ferro JM, Trindade A. Acquired crossed aphasia in a child. *Developmental medicine and child neurology.* 1987 Feb;29(1):96-100.
45. Tanabe H, Ikeda M, Murasawa A, et al. A case of acquired conduction aphasia in a child. *Acta neurologica Scandinavica.* 1989 Oct;80(4):314-8.
46. Lopez-Barroso D, Catani M, Ripolles P, Dell'Acqua F, Rodriguez-Fornells A, de Diego-Balaguer R. Word learning is mediated by the left arcuate fasciculus. *Proc Natl Acad Sci U S A.* 2013 Aug 06;110(32):13168-73.
47. Francois C, Ripolles P, Bosch L, et al. Language learning and brain reorganization in a 3.5-year-old child with left perinatal stroke revealed using structural and functional connectivity. *Cortex.* 2016 Apr;77:95-118.
48. Skeide MA, Friederici AD. The ontogeny of the cortical language network. *Nat Rev Neurosci.* 2016 May;17(5):323-32.
49. Everitt A, Hannaford P, Conti-Ramsden G. Markers for persistent specific expressive language delay in 3-4-year-olds. *Int J Lang Commun Disord.* 2013 Sep-Oct;48(5):534-53.
50. Selnes OA, Knopman DS, Niccum N, Rubens AB. The critical role of Wernicke's area in sentence repetition. *Ann Neurol.* 1985 Jun;17(6):549-57.
51. Lidzba K, de Haan B, Wilke M, Krageloh-Mann I, Staudt M. Lesion characteristics driving right-hemispheric language reorganization in congenital left-hemispheric brain damage. *Brain Lang.* 2017 Oct;173:1-9.

52. Trauner DA, Eshagh K, Ballantyne AO, Bates E. Early language development after peri-natal stroke. *Brain Lang.* 2013 Dec;127(3):399-403.
53. Liegeois F, Connelly A, Cross JH, et al. Language reorganization in children with early-onset lesions of the left hemisphere: an fMRI study. *Brain.* 2004 Jun;127(Pt 6):1229-36.
54. Forkel SJ, Thiebaut de Schotten M, Dell'Acqua F, et al. Anatomical predictors of aphasia recovery: a tractography study of bilateral perisylvian language networks. *Brain.* 2014 Jul;137(Pt 7):2027-39.
55. Catani M, Allin MP, Husain M, et al. Symmetries in human brain language pathways correlate with verbal recall. *Proc Natl Acad Sci USA.* 2007 Oct 23;104(43):17163-8.
56. Berthier ML, Froudust Walsh S, Davila G, et al. Dissociated repetition deficits in aphasia can reflect flexible interactions between left dorsal and ventral streams and gender-dimorphic architecture of the right dorsal stream. *Frontiers in human neuroscience.* 2013;7:873.
57. Heiss WD, Thiel A. A proposed regional hierarchy in recovery of post-stroke aphasia. *Brain Lang.* 2006 Jul;98(1):118-23.
58. Chabrier S, Peyric E, Drutel L, et al. Multimodal Outcome at 7 Years of Age after Neonatal Arterial Ischemic Stroke. *The Journal of pediatrics.* 2016 May;172:156-61.e3.

Accepted Article

**Table 1.** Demographic and clinical characteristics of the study group (means and standard deviations in parenthesis).

	Control group (n=40)	Stroke group (n=30)	Statistical comparison
<b>Demographics</b>			
Age (years)	13.5 (3.0)	12.4 (3.4)	t=1.4, df=68, p=0.17
Sex ratio (male : female)	21:19	18:12	$\chi^2= 0.39$ , df=1, p=0.62
Handedness (left/ambidextrous : right)	9:31	12:18	$\chi^2= 2.50$ , df=1, p=0.114
Maternal education (additional schooling, years)	4.2 (3.0)	4.1 (2.5)	t=0.08, df=56, p=0.93
Full scale IQ&	112 (16)	99 (14)	<b>t=3.7, df=68, p&lt;0.0001</b>
Expressive language score (CELF-3 <sup>UK</sup> )&	108 (13)	95 (17)	<b>t=3.5, df=68, p=0.001</b>
Receptive language score (CELF-3 <sup>UK</sup> )&	104 (14)	91 (16)	<b>t=3.6, df=68, p&lt;0.0001</b>
<b>Clinical characteristics</b>			
Hemisphere affected (Left / Bilateral / Right)		21 / 3 / 6	
Stroke location (Left / Bilateral / Right):			
MCA main branch	-	7 / 1 / 0	
MCA cortical	-	10 / 1 / 3	
MCA lenticulo-striate	-	2 / 0 / 1	
Haemorrhagic	-	2 / 1 / 2	

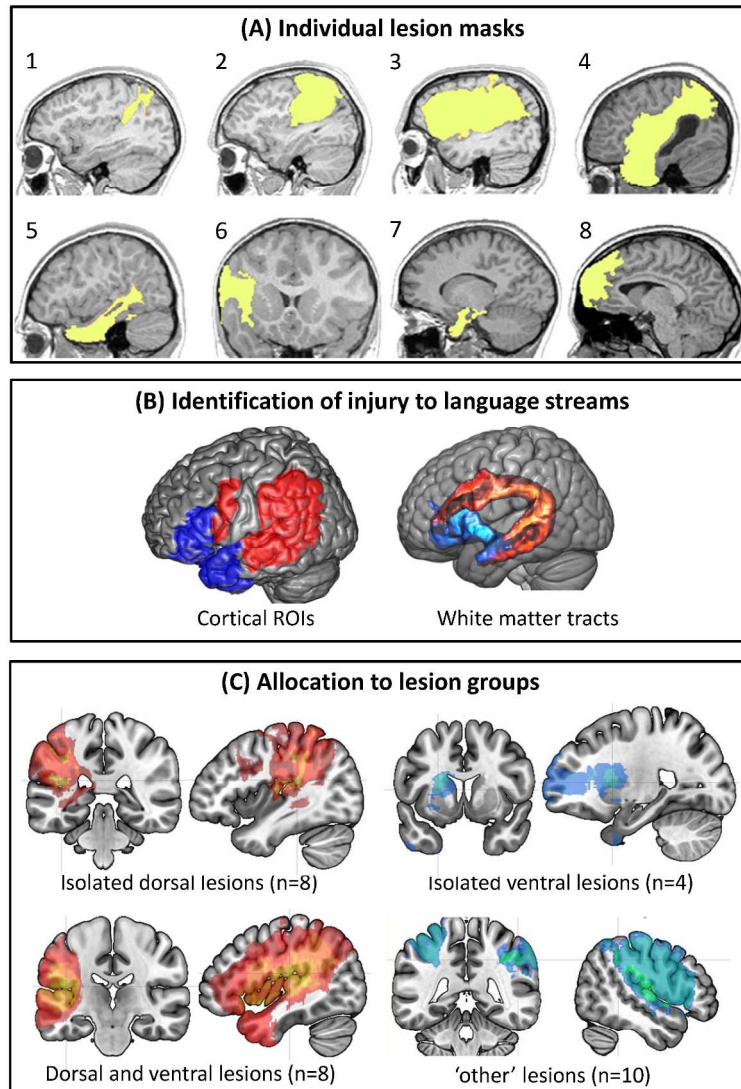
MCA=Middle cerebral artery; CELF3UK=Clinical Evaluation of Language Fundamentals.

& - average reference range: 85-115.

**Table 2.** Language scores in the dorsal stream lesion group versus remaining lesion cases.

		Dorsal lesion	Mean score (SD)	ANCOVA 1 (covariate: FSIQ)	ANCOVA 2 (covariates: FSIQ & LI in Broca's area)	
CEL3 <sup>UK</sup> subtest scores	Expressive language	Formulating sentences	Yes	10.5 (3.2)	F=0.18, p=0.676	F=0.00, p=0.994
			No	9.2 (3.5)		
		Repeating sentences	Yes	6.8 (3.2)&	<b>F=7.19, p=0.013</b>	<b>F=21.2, p&lt;0.0001*</b>
			No	8.8 (3.3)		
		Sentence assembly	Yes	7.5 (3.3)	F=0.05, p=0.834	F=1.1, p=0.300
			No	8.8 (3.0)		
	Receptive language	Concepts and directions	Yes	7.7 (3.1)	F=0.01, p=0.972	F=1.3, p=0.272
			No	7.8 (3.2)		
		Word classes	Yes	9.1 (3.2)	F=0.01, p=0.938	F=0.76, p=0.392
No			7.8 (3.5)			
Semantic relationships		Yes	9.2 (2.9)	F=0.91, p=0.349	F=1.15, p=0.295	
		No	9.4 (3.6)			
CTOPP subtest scores	Phonological memory	Memory for digits	Yes	9.1 (3.1)	F=1.39, p=0.250	F=1.51, p=0.231
			No	9.4 (2.6)		
	Non-word repetition	Yes	9.8 (2.7)	<b>F=5.87, p=0.023</b>	<b>F=8.6, p=0.007</b>	
		No	11.1 (2.2)			
	Phonological awareness	Elision	Yes	10.3 (2.2)	F=0.36, p=0.557	F=0.66, p=0.426
			No	10.6 (2.5)		
Blending words		Yes	10.5 (3.3)	F=0.89, p=0.352	F=3.53, p=0.072	
		No	11.1 (3.8)			

CEL3<sup>UK</sup> =Clinical Evaluation of Language Fundamentals, CTOPP= Comprehensive Test of Phonological Processing. SD=Standard deviation, LI=Lateralisation index. \*post-hoc test survived Bonferroni correction (p<0.005). & - mean scaled score below the normal range (<7).



Classification of lesion cases into language stream groups: (A) Lesion masks were created from tracings on T1-weighted MRI scans. Example cases show typical left hemisphere lesions involving the: (i) dorsal stream (cases 1 and 2); (ii) dorsal stream in combination with the ventral stream (cases 3, 4, 5 and 6); (iii) ventral stream (case 7); and (iv) a lesion outside language regions (case 8, anterior cerebral artery territory). The neocortical damage in case 6 is restricted to the inferior frontal gyrus, including its most ventral and dorsal aspects, therefore injuring parts of both language streams. !! + (B) Individual cortical regions of interest (ROIs) used to determine the extent of involvement within the dorsal (red) and ventral (blue) language streams. White matter tracts measured to determine injury to the dorsal stream (the arcuate fasciculus - red) and the ventral stream (uncinate fasciculus/extreme capsule - blue). Tracts shown are the mean of the control group.!! + (C) Lesion-overlay maps. The most common sites of injury in cases with dorsal stream damage was the inferior parietal lobule (affected in 11/16 cases) and posterior superior temporal gyrus (affected in 12/16 cases). Ventral lesions involved the anterior temporal lobe (in 6/11 cases) and the left lenticulo-striate region (shown here in blue). The remaining cases (n=10) had lesions outside of language

regions, involving right hemisphere lesions and injury restricted to the superior parietal and motor cortex on the left side, and formed the 'other lesion' group. † ‡

209x297mm (300 x 300 DPI)

Accepted Article

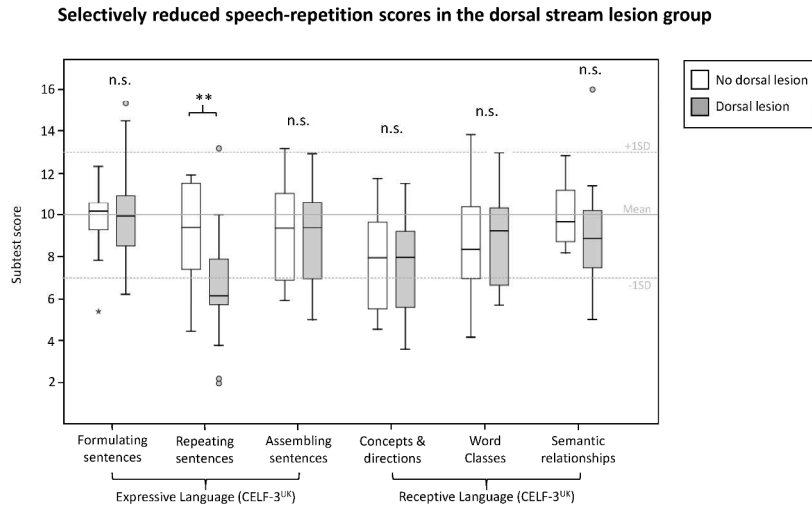


Figure 2: Selectively reduced sentence-repetition scores in the dorsal stream lesion group. Language CELF-3UK subtest scores (adjusted for full-scale IQ) in the dorsal stream lesion group compared to those with lesions elsewhere. The continuous line represents the subtest mean, each dotted line corresponding to  $\pm 1$  SD. \*\* $p=0.013$ .

297x209mm (300 x 300 DPI)

Accep

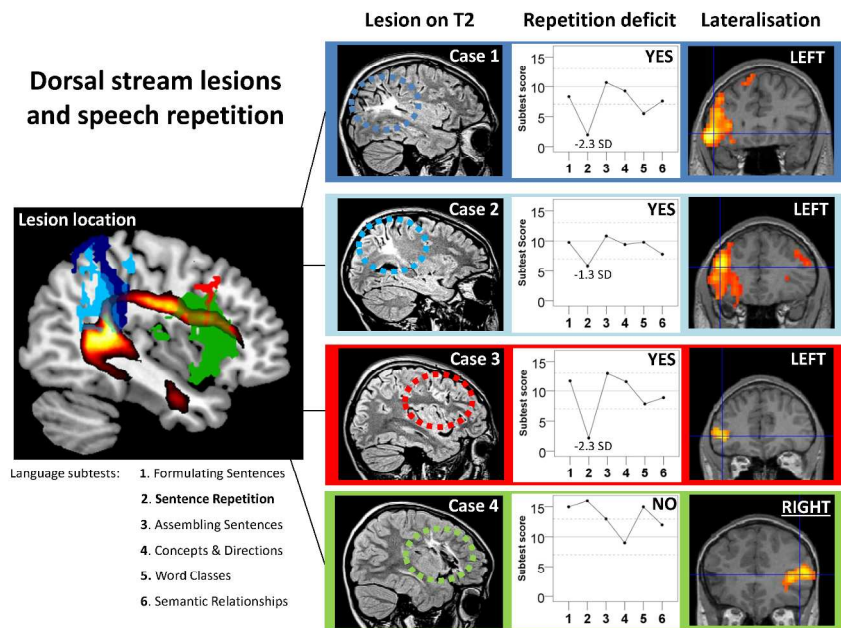


Figure 3: Left dorsal stream lesions and presence of speech repetition impairment in individual example cases. Left side: Overlay map displays lesions of four individual cases in relation to the arcuate fasciculus (shown in red/yellow). Right side: 'Lesion on T2' shows lesion cases (colour-coded to correspond to lesions maps on the left). 'Repetition deficit' shows the language profile of each case, across all CELF-3UK subtests (1.-6., listed left bottom). 'Lateralisation' shows fMRI activation ( $p < .001$ ) in Broca's region. Cases 1-3 are severely impaired on sentence repetition and show left language lateralisation. In contrast, case 4 with an extensive dorsal stream lesion has no repetition impairment, most likely owing to complete functional reorganisation to the right hemisphere.

297x209mm (300 x 300 DPI)

Accep



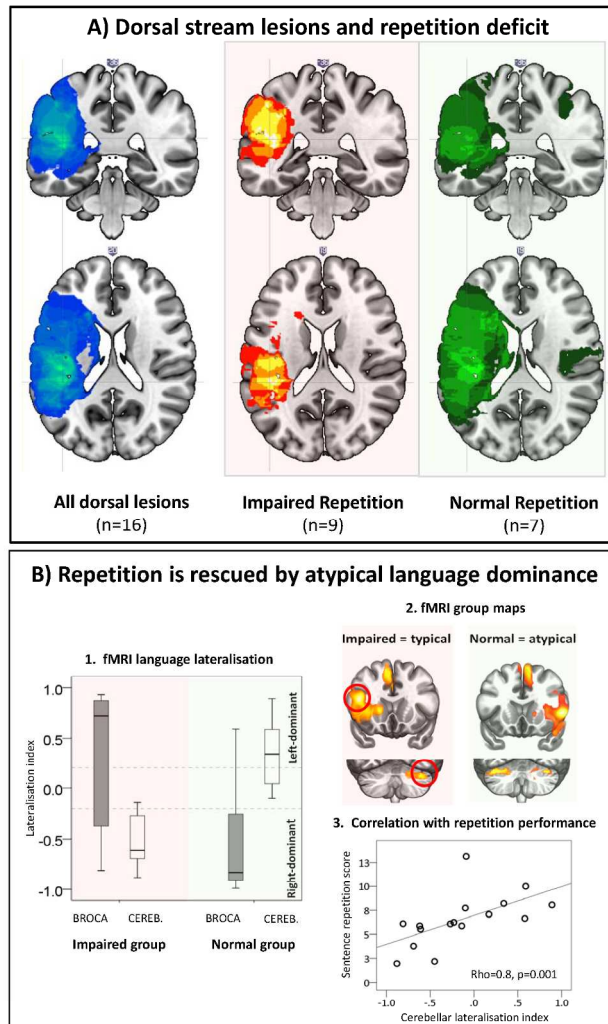


Figure 4: Repetition impairment after left dorsal stream injury is associated with atypical language dominance: (A) Lesion overlay maps in the total dorsal stream lesion group and two subgroups with and without repetition impairment. There was no qualitative difference in lesion distribution. (B) 1. Boxplot displaying the difference in the lateralisation indices in Broca's area and cerebellum in the group with impaired repetition versus the group with normal repetition. Cases with impaired repetition showed typical (left-dominant) activation in Broca's area and the contra-lateral cerebellum. 2. fMRI group maps displaying mean activation in Broca's area (top) and the cerebellum (bottom) in the two groups ( $p < 0.001$ ). 3. Correlation between sentence repetition scores (IQ-adjusted) and language lateralisation in the cerebellum. Note: the outlier case shows typical left lateralisation in Broca's area.

209x297mm (300 x 300 DPI)