

## **A retrospective multicenter study of the natural history of fetal ovarian cysts**

Athanasios Tyraskis<sup>1</sup>, Spyros Bakalis<sup>2</sup>, Carolina Scala<sup>3</sup>, Argyro Syngelaki<sup>4</sup>, Stefano Giuliani<sup>5</sup>, Mark Davenport<sup>1</sup>, Anna L. David<sup>2</sup>, Kypros Nicolaides<sup>4</sup>, Simon Eaton<sup>6</sup>, Paolo De Coppi<sup>6</sup>

1. Paediatric Surgery Unit, King's College Hospital, London, UK
2. Institute for Women's Health, University College London, UK
3. Fetal Medicine Unit, St. George's Hospital, London, UK
4. Harris Birthright Centre, King's College Hospital, London, UK
5. Department of Paediatric and Neonatal Surgery, St. George's University Hospitals NHS Foundation Trust, Blackshaw Rd, SW17 0QT, London, UK
6. Stem Cells and Regenerative Medicine, DBC, UCL Institute of Child Health and Great Ormond Street Hospital London, UK

Corresponding Author:

Paolo De Coppi, MD, PhD  
NIHR Professor and Consultant Paediatric Surgeon  
Head of Stem Cells & Regenerative Medicine Section  
Developmental Biology & Cancer Programme  
UCL Great Ormond Street Institute of Child Health  
30 Guilford Street  
London WC1N 1EH  
Tel: 020 7905 2641  
p.decoppi@ucl.ac.uk

## **Abstract**

**Aim:** We investigated the natural history of prenatally diagnosed ovarian cysts to estimate the risk of torsion for cysts according to their size and sonographic appearance.

**Methods:** Cases of fetal ovarian cysts were identified at three tertiary fetal medicine units from January 2000 until January 2015. Data were collected on cyst size and pre- and postnatal sonographic features until an outcome of either pre- or postnatal aspiration, surgery, torsion, or resolution of the cyst resulted. In those where the cyst resolved, we identified subsequent scans to monitor for torsion and absence of the ovary. Continuous data was reported as median and inter quartile range, Fisher's exact test was used to test differences between groups with 95% confidence intervals of proportions reported, and logistic regression for the significance of size on the frequency of torsion.

**Results:** In the 15 year period 37 patients with unilateral ovarian cysts were included in this study, and of these 12 (32%) resolved spontaneously prenatally, 14 (38%) resolved spontaneously postnatally, 5 (14%) girls underwent surgery postnatally and there were 6 (16%) cases of torsion. Lowest rate of torsion was in cysts 0 - 20mm (n = 0, 0%), and increased with increasing size in cysts >50mm (n = 2, 33%) although the overall trend failed to reach statistical significance (p = 0.1). Cysts of 0-40mm had a significantly higher rate of spontaneous resolution without any invasive intervention (90% in cysts 0-40mm vs. 44% in cysts >40mm, P = 0.003). However, the difference in the rate of torsion was not statistically significant (10% in cysts 0-40mm vs. 25% in cysts >40mm, P = 0.26). The median number of weeks to postnatal resolution was 10 (5 – 27) weeks in those treated conservatively.

**Conclusion:** Cysts >40mm in maximum diameter at the time of diagnosis are significantly less likely to resolve spontaneously. No complications were observed in cysts < 20mm diameter, however torsion

showed no significant correlation with cyst size. Further studies are needed to clarify the role of prenatal or postnatal aspiration of ovarian.

Type of study: Retrospective case series

Level of evidence: IV

## Introduction

Follicular ovarian cysts in fetal life are a response to maternal and placental oestrogens and gonadotrophins and occur as commonly as 1 in every 1,000 fetuses [1]. These cysts are often treated conservatively prenatally and managed expectantly postnatally until resolution. There are increasing data to suggest that there is a significant risk of ovarian torsion prenatally and that this risk is related to the cyst diameter [2]. This has led some groups to attempt prenatal aspiration of cysts to decrease their size and hopefully their chance of prenatal torsion. Most groups advocate a cut-off cyst diameter of 40 or 50mm as an indication for prenatal aspiration [3,4,5]. However, all previous studies have investigated a single cyst size cut-off to determine the risk of torsion rather than describe the prevalence of torsion according to cyst size.

The sonographic appearance of the cyst may also be significant in determining treatment strategy in addition to its size. Simple cysts are assumed to be viable whereas complex cysts (especially if a fluid-debris level is present internally) have a high likelihood of already having torsed. Thus the simple cysts would be the target of treatment in order to prevent ovarian loss [6,7].

Due to the rarity of large ovarian cysts and incomplete follow-up, the natural evolution of these cysts has not been well studied, and the degree of risk of torsion with increasing cyst diameter has yet to be quantified.

The aim of this study was to investigate the natural history of prenatally diagnosed ovarian cysts; to estimate the risk of torsion for cysts according to their size and sonographic appearance, and to assess likelihood of cyst resolution.

## Method

This is a multicentre retrospective study of pregnant women referred to three tertiary-referral fetal medicine units with follow-up of their infants in three pediatric surgery centres. Three fetal medicine centres and their respective paediatric surgical centres were included in this study (King's College Hospital, St. George's Hospital, University College London Hospital) with a further contribution from the department of paediatric surgery at Great Ormond Street Hospital (the referral center for babies born at University College London Hospital). Cases of fetal ovarian cysts were identified using the ViewPoint (GE Healthcare, UK) ultrasound (US) database at each hospital. To ensure complete capture of fetal ovarian cysts, a search for "ovarian or pelvic or abdominal cyst(s)" was performed on scans from January 2000 until January 2015. All identified cases were screened for eligibility where inclusion criteria were unilateral or bilateral cyst(s) that were suspected to be of ovarian origin. Patients were excluded if they were not followed up in one of the three fetal medicine centres, but rather had just been referred for a second opinion and one ultrasound scan to ensure completeness of both prenatal and postnatal information.

Data on cyst dimensions and sonographic appearance were gathered from all prenatal scans from time of diagnosis until birth. Postnatal follow up data was obtained from all patients until the time of resolution, aspiration or surgical excision. Any cases which during follow-up were determined to have cysts of non-ovarian origin were excluded. The size measurements used to subdivide patients for the subsequent analysis was the maximum diameter of the cyst at the time of the first prenatal US scan in one of the three included tertiary fetal medicine centres. Median and interquartile range of cyst size according to gestational age was reported and a subgroup analysis was performed according to the maximum diameter on any prenatal US rather diagnosis. Patients who underwent prenatal aspiration

were included in the overall analysis and more information on their individual clinical course was provided.

Ovarian loss in patients with ovarian cysts may occur due to torsion, and for the purpose of this study was defined as: a necrotic ovary at the time of surgery, or a complex cyst which regressed without any identifiable ovarian tissue on the ipsilateral side on more than one US scans post regression. Simple cysts were defined as a thin-walled cyst with anechoic contents, and complex cysts included those with internal septations, debris, or other echoic content which did not appear solid (solid complex cysts were excluded due to the risk of being teratomas). Postnatal resolution was defined as resorption of the cyst with two identifiable ovaries on US. Prenatal resolution was defined as resorption of the cyst on subsequent antenatal US (most of these patients did not go on to have postnatal US).

This study was registered as an audit approved by the Clinical Audit and Safety Department of Great Ormond Street Hospital (approval number: 1524) and therefore did not require formal ethical committee approval.

Two-tailed Fisher's exact tests were used to test for significant differences between the different size groups, GraphPad Prism (Version 6) <sup>®</sup> was used for this statistical analysis. 95% level of confidence was defined as significant. Continuous data was reported as median and interquartile range. Overall trend according to size was tested using a logistic regression on STATA 13 <sup>®</sup>. Finally a 95% confidence interval of proportion was calculated using the GraphPad Quick Calcs online software. A P value of <0.05 was considered significant.

## Results

A total of 109 patients were identified with a diagnosis of fetal ovarian cyst(s). 58/109 were referred to our centres only for a second opinion, and had no further contact besides a single consultation. As we did not have a complete data for follow-up and outcomes they were excluded from our study. 14 were lost to follow-up either pre or postnatally, and the remaining 37 patients were included in the study (Figure 1). Spontaneously resolution occurred in 12/37 (32%) cysts prior to birth, and 14 (38%) resolved spontaneously after birth. Postnatal surgery occurred in 7 infants and 4 of those were found to have torsed necrotic ovaries and in 1 infant the ovary was twisted along the axis of the Fallopian tube but was viable following detorsion and de-roofing. There were 6 cases of ovarian loss in total; 4 of those were identified at the time of postnatal surgery and the remaining 2 had a complex cyst which regressed without any remaining ovarian tissue on the ipsilateral side on multiple sonographic examinations (ovarian loss in Figure 1).

The distribution according to size and frequency of outcomes can be seen in Table 1. Rates of torsion increased incrementally from 0% for cysts 0-20mm, 14% (n = 1) in cysts 21-30mm, and 31-40mm, 20% (n = 2) in cysts 41-50, and up to 33% (n = 2) in cysts >50mm at the time of diagnosis. Prenatal resolution occurred less often with increasing size: 86% (n = 6) of cysts 0-20mm, 43% (n = 3) of those 21-40mm, and 0% of those > 40mm. Of the cysts which remained postnatally, a similar decrease in spontaneous resolutions was observed – 75% (n = 7) of those 0-40mm, 50% (n = 5) of those 41-50mm, and 33% (n = 2) of those >50mm. No cyst <20mm underwent any invasive procedure, compared to 14% (n = 2) of cysts 21-40mm, 40% (n = 4) of patients in the 41-50mm, and 50% (n = 3) of patients with cysts >50mm at diagnosis. Interestingly, a significant difference is present when performing a subgroup analysis comparing cysts of up to 40mm to those that were >40mm. Smaller cysts of  $\leq 40$ mm resolved spontaneously in 90% (n = 19) of cases compared to only 44% (n = 7) of cysts >40m (P = 0.003).

However, there was no significant difference in the rate of torsion of cysts  $\leq 40\text{mm}$ , 10% ( $n = 2$ ), compared to 25% ( $n = 4$ ) in cysts  $>40\text{mm}$  ( $P = 0.26$ ). Of those cysts that resolved postnatally without intervention, the median number of weeks to resolution was 10 with an interquartile range of 5 - 27 weeks.

Of relevance, diameters also change during the gestation with the median value for the largest diameter of the cyst increasing from 19<sup>th</sup> to the 34<sup>th</sup> week of gestation after which we found that it plateaued (Figure 2). At the time of diagnosis, 25 (68%) of the cysts were simple in sonographic appearance, 9 (24%) were complex, and for 3 (8%) the appearance was not commented on. Of the 25 that were simple, 18 (72%) resolved without any intervention, 8 prenatally and 10 postnatally. A total of 7 (28%) of the 25 simple cysts had an invasive procedure, 2 (8%) had a postnatal aspiration (and both subsequently resolved), and 5 (20%) patients underwent operations (1 of which had already undergone a prenatal aspiration), 2 (8%) had viable ovaries and 2 (8%) had torsed necrotic ovaries. Of those 2 that were necrotic, both had a complex appearance on the first postnatal ultrasound scan which was done in the first week of life, and one of which had an auto-amputated cyst which was 'wandering' and was located in the right upper quadrant of the abdomen on one scan.

Nine cysts were complex at the time of diagnosis, 3 (33%) underwent torsion, and 6 (67%) in total resolved (4 prenatally and 2 postnatally). All four that resolved prenatally were  $< 40\text{mm}$  at the time of diagnosis. One of the complex cysts which underwent torsion was 28mm at the time of diagnosis; the other two were 54mm and 97mm. Three patients did not have the appearance of their cyst commented on at the time of diagnosis. Two of those resolved postnatally and one had a repeat ultrasound a week later prenatally and the cyst was found to be complex. Postnatally this patient had a laparoscopic resection of a necrotic ovarian cyst that had undergone torsion.



Two prenatal aspirations were performed on the basis of their size. One cyst was simple, initially measuring 64mm but growing to 102mm prenatally, occupying most of the fetal abdomen. 320mls of straw coloured fluid was aspirated prenatally, however, this patient subsequently required surgical deroofting due to re-accumulation of fluid postnatally, at which time the ovary was seen to be viable. The second was a large complex cyst measuring 97mm at diagnosis and the decision was made to aspirate due to signs of fetal anaemia at which time blood stained fluid was aspirated. The first postnatal ultrasound and operation were performed in the first week of life and found the cyst to be in the epigastric region. Subsequently this patient became symptomatic and a decision was made to operate, and was found to have a necrotic ovary separate to the Fallopian tube of which only a remnant remained (presumably following resorption of necrotic tissue), suggesting that the torsion had occurred prenatally.

Postnatal aspiration was employed on two cysts, one measuring 45mm at diagnosis and one measuring 50mm at diagnosis. Both had grown 5-10mm after birth leading to the decision to aspirate. They had good outcomes and these cysts went on to resolve completely within the first year of life.

## Discussion

There is a paucity of actual evidence for the predictability of torsion of >40mm or >50mm ovarian cysts which are often deemed as 'large' and at high risk of torsion according to a single size cutoff. [3, 8] Our study is the largest case-series to date that describes the natural history of prenatally diagnosed ovarian cysts according to a more detailed size categorization (multiple progressive size groups rather than two groups based on an arbitrary cutoff). We found that cysts of <20mm in size had no adverse outcomes nor did they require any postnatal intervention. Rates of torsion and surgery both increased with cyst size but a logistic regression using the actual cyst measurements failed to show any significant differences in the rate of torsion as cyst size increased ( $p = 0.1$ ). This may be due to insufficient number of cases in our study. Spontaneous resolution of the cysts also decreased consistently with increasing cyst size. Although there was no clear cutoff for a size at which the risks of torsion or incidence of surgery increased dramatically, our data indicated an increment in all outcomes (need for surgery, torsion or failure to resolve spontaneously) for cysts of 40mm and greater. For this reason we did a subgroup analysis comparing ovarian cysts measuring up to 40mm to those >40mm, the rates of spontaneous resolution of the larger cysts were significantly lower (44% vs. 90%,  $P < 0.01$ ).

The timing of torsion in our cohort is not obvious but the clinical evidence points more to prenatal torsion. Of the 6 cases of torsion in our study, 1 had an operation in the first week of life that only found a cyst which was separate from a remnant of the fallopian tube indicating that the torsion had undergone a significant period of time prior, only consistent with prenatal torsion. Of the remaining 5 patients, 3 of those had operations after the first week of life and the remaining 2 had a cyst which resolved after the neonatal period with no ovary identifiable on repeated ultrasound scans, thus, making it impossible to be certain regarding the timing of torsion. As none of these patients became symptomatic postnatally, and 5 (83%) were complex on US prenatally with the last 1 having a complex

appearance on the first postnatal US in the first week of life, there is a strong suspicion that torsion occurred prenatally. This finding could make an argument for prenatal aspiration [2], a technique still rarely performed and utilised by us only in 2 cases.

Authors have supported the use of prenatal aspiration as a method of decreasing the risk of torsion in larger cysts due to the assumed greater risk of torsion in those cysts. The size at which aspiration is considered is 40-50mm depending on the study [2-3]. Encouraging results from one study using prenatal aspiration show significantly decreased risk of torsion from 85% rate of torsion in cysts 50mm or larger which were not aspirated to 14% in those which were [3]. Our study did not confirm that cysts larger than 50mm had such high rates of torsion, nevertheless, larger prospective studies are necessary for more accurate quantification of this risk, and the subsequent potential benefit of prenatal aspiration.

Postnatal aspiration was effective in both patients in which it was performed, however there is a paucity of cases in the literature in order to corroborate its effectiveness. The infrequent reporting of postnatal aspiration rather than surgery in the literature makes evaluating its outcomes particularly difficult. It is dependent on the particular expertise being available and favorable positioning of the cyst with no overlying bowel to make safe aspiration possible. Some authors have employed it in 1-2 cases in their larger cohorts of which one complication of intraperitoneal bleed has been noted [13]. Another caution which other authors have emphasized is the re-accumulation of the cysts, one study observing this in 1 of 5 cases aspirated [6,8], a complication not occurring when surgical de-roofing or cystectomy is performed [12].

Being complex in appearance is not a predictive risk factor for torsion but rather an indicator that there has been a haemorrhagic process into the cyst. The cause can be benign such as a ruptured blood vessel, or may represent a necrotic process leading to vessel disruption and bleeding into the cyst. All of our cases that underwent torsion and necrosis were found to have a complex sonographic appearance prior

to the diagnosis of necrosis. One third of our cases that were complex had undergone torsion, slightly lower than one of the largest studies in the literature; Galinier et al. found that of 55 haemorrhagic cysts that 30 (55%) were either absent or unidentifiable on follow-up indicating ovarian loss [6].

## **Conclusion**

Cysts in our study tended to increase in size until the 34<sup>th</sup> week of gestation. While this retrospective study confirmed that size is a significant factor in the clinical evolution of fetal ovarian cysts, we showed that cysts greater than 40mm, rather than 50mm as previously reported, are significantly less likely to resolve spontaneously. Larger studies are needed to investigate if cysts greater than 40mm are at significantly higher risk of torsion. Cysts less than 20mm in size are unlikely to have any complications. Aspiration both pre and postnatally may provide a therapeutic option but clinicians must be aware of risks of reaccumulation of fluid as well as that a complex sonographic appearance could be secondary to both haemorrhage into an otherwise viable ovarian cyst or torsion and necrosis, and may represent worse candidates for a therapeutic aspiration.

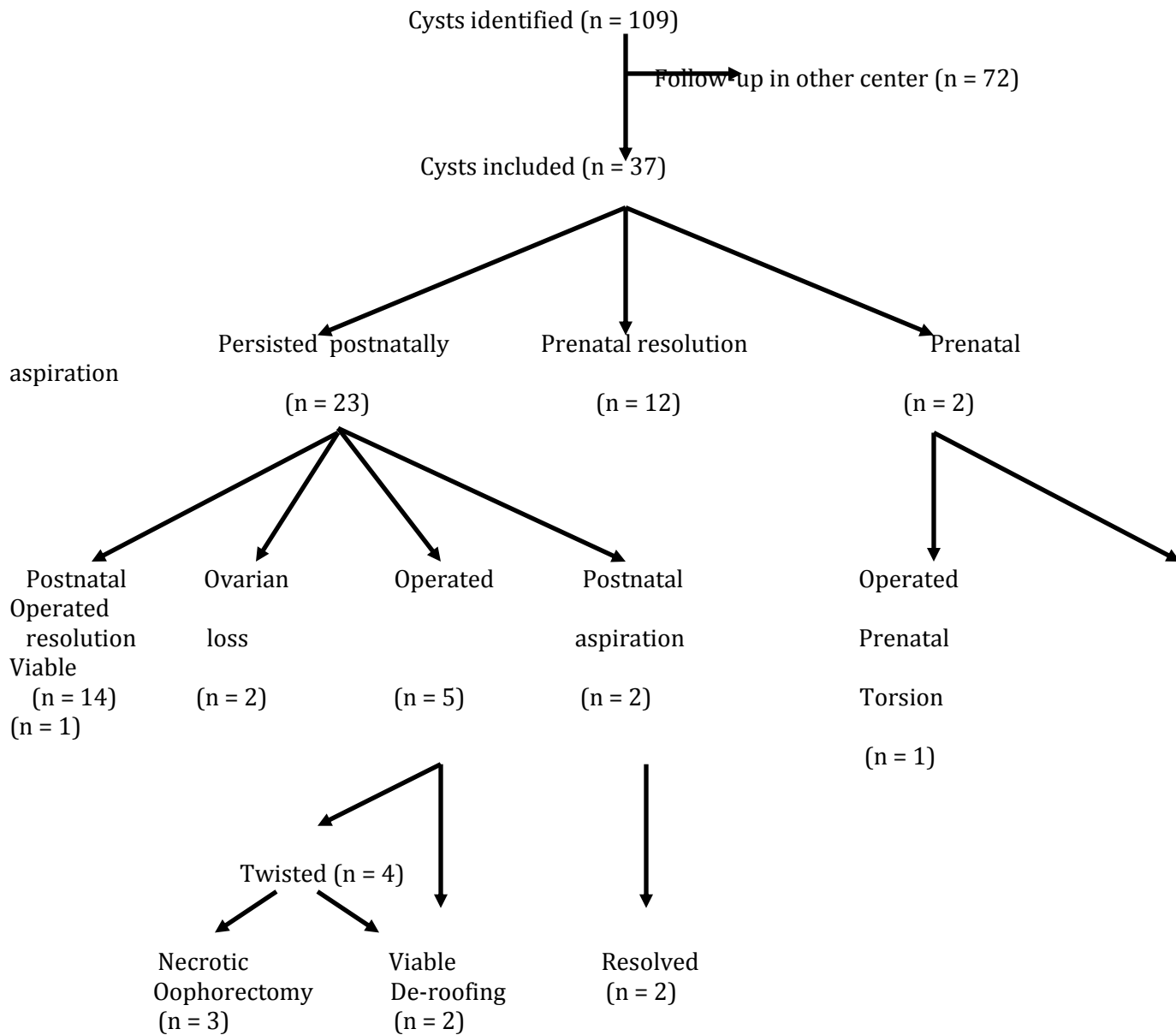
## **Acknowledgments**

ALD is supported by the National Institute for Health Research University College London Hospitals Biomedical Research Centre. PDC is supported by NIHR and the Great Ormond Street Hospital Biomedical Research Centre and SE is supported by Great Ormond Street Hospital Biomedical Research Centre and by Great Ormond Street Hospital Children's Charity.

## **References**

- 1 Pilar S. F., Juan D., Martinez C. , *et al.* Quiste de ovario fetal: diagnostico prenatal, evolucion perinatal y tratamiento. *Ginecologia y obstetricia de Mexico* 2012; 80: 84-90.
- 2 Giorlandino C. *et al.* Successful intrauterine therapy of a large fetal ovarian cyst. *Prenatal diagnosis* 1990; 10: 473-475.
- 3 Bagolan P. *et al.* The management of fetal ovarian cysts. *Journal of pediatric surgery* 2002; 37: 25-30.
- 4 Noia G. *et al.* Invasive fetal therapies: approach and results in treating fetal ovarian cysts. *The journal of maternal-fetal & neonatal medicine : the official journal of the European Association of Perinatal Medicine, the Federation of Asia and Oceania Perinatal Societies, the International Society of Perinatal Obstet* 2012; 25: 299-303.
- 5 Crombleholme T. M., Craigo S. D., Garmel S., *et al.* Fetal ovarian cyst decompression to prevent torsion. *Journal of pediatric surgery* 1997; 32: 1447-1449.
- 6 Galinier P. *et al.* Fetal ovarian cysts management and ovarian prognosis: a report of 82 cases. *Journal of pediatric surgery* 2008; 43: 2004-2009.
- 7 Enriquez G. *et al.* Conservative versus surgical treatment for complex neonatal ovarian cysts: outcomes study. *AJR. American journal of roentgenology* 2005; 185: 501-508.
- 8 Brandt M. L., Luks F. L., Filiatrault D., *et al.* Surgical indications in antenatally diagnosed ovarian cysts. *J Pediat Surg* 1991; 26: 276-282.
- 9 Luzzatto C., Midrio P., Toffolutti T., *et al.* Neonatal ovarian cysts: management and follow-up. *Pediatric surgery international* 2000; 16: 56-59.
- 10 Bundscherer A. D. K. Ultrasound-guided percutaneous puncture of large ovarian cysts in 5 neonates. *Monatsschrift kinderheilkunde* 1995; 143: 691-695.
- 11 Kessler A. *et al.* Percutaneous drainage as the treatment of choice for neonatal ovarian cysts. *Pediatric radiology* 2006; 36: 954-958.
- 12 Mizuno M., Kato T., Hebiguchi T., *et al.* Surgical indications for neonatal ovarian cysts. *The Tohoku journal of experimental medicine* 1998; 186: 27-32.
- 13 Monnery-Noche M.-E. *et al.* Fetal and nonatal ovarian cysts: is surgery indicated? *Prenatal Diagnosis* 2008; 28: 15-20.

**Figure 1.** Flowchart of outcomes for all patients.





**Table 1.** Table showing the outcomes of fetal ovarian cyst cases according to the cyst maximum diameter at prenatal diagnosis.

<b>Maximum diameter at diagnosis (mm)</b>	<b>Number of cysts</b>	<b>Resolution prenatally</b>	<b>Resolution postnatally</b>	<b>Aspiration (performed prenatally)</b>	<b>Postnatal surgery</b>	<b>Torsion</b>
<b>0-20</b>	7	6	1	0	0	0
<b>21-30</b>	7	3	3	0	1	1
<b>31-40</b>	7	3	3	0	1	1
<b>41-50</b>	10	0	5	2 (0)	2	2
<b>&gt;50</b>	6	0	2	2 (2)	3	2
<b>Total</b>	37	12	14	4 (2)	7	6



**Table 2.** Table of outcomes according to initial appearance of cyst on ultrasound.

<b>Cyst appearance on ultrasound</b>	<b>Number of cysts</b>	<b>Resolution prenatally</b>	<b>Resolution postnatally</b>	<b>Aspiration (performed prenatally)</b>	<b>Postnatal surgery</b>	<b>Torsion</b>
<b>Simple</b>	25	8	10	3 (1)	5	2
<b>Complex</b>	9	4	2	1 (1)	2	3
<b>Unknown</b>	3	0	2	0	0	1

**Figure 2.** The median and interquartile range values for maximum diameter according to the gestational age of the patient when the US was performed.

