

## An emerging opportunistic infection: Fatal animal-astrovirus encephalitis in a paediatric stem cell transplant recipient

Su Han Lum<sup>1</sup>, Andrew Turner<sup>2</sup>, Denise Bonney<sup>1</sup>, Malcolm Guiver<sup>2</sup>, Judith Breuer<sup>3</sup>, Robert Wynn<sup>1</sup>

<sup>1</sup>Department of Blood and Marrow Transplant, Royal Manchester Children's Hospital

<sup>2</sup>Clinical Virology Department, Manchester Royal Infirmary

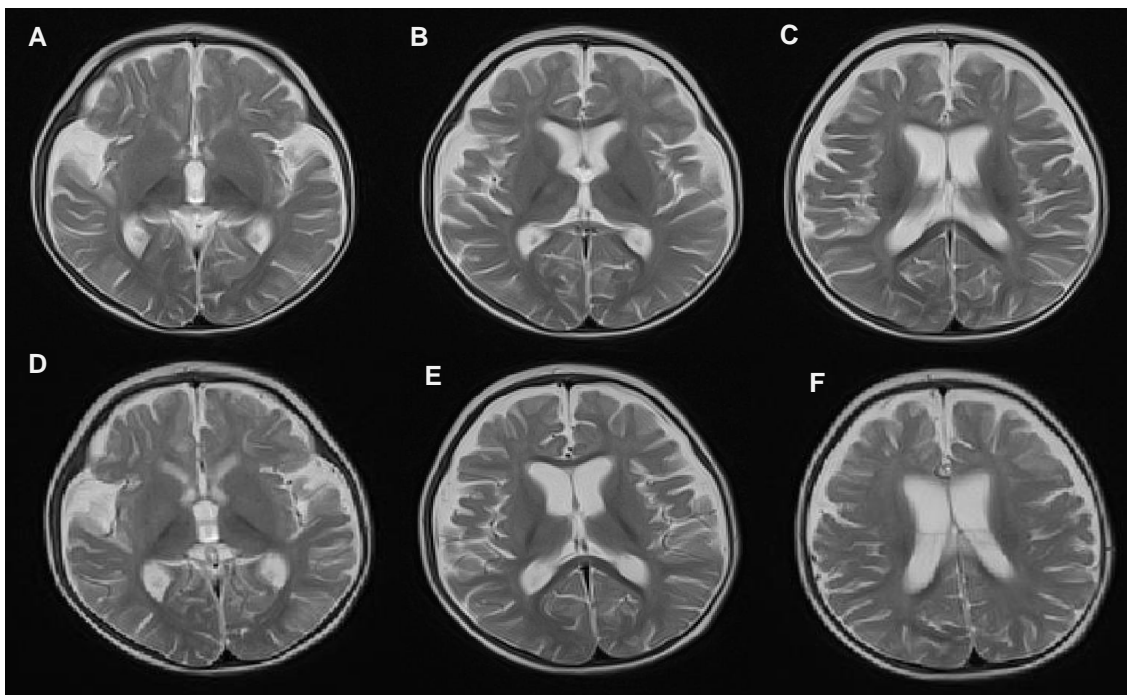
<sup>3</sup>Research Department of Infection, Division of Infection and Immunity, University College London

**Introduction:** Neuroinvasive astrovirus is an emerging life-threatening infection in immunocompromised hosts. We describe a 8-month-old child who died of fatal animal astrovirus encephalitis following a haematopoietic stem cell transplant for acute myeloid leukaemia (AML) with high-risk cytogenetics, t (10;11) in first remission.

**Materials (or patients) and methods:** The child achieved remission following ADE therapy and received two courses of consolidation with FLAG-IDA. The treatment was complicated by *Enterobacter* neutropenic fevers and enteritis due to human astrovirus infection, followed by persistent asymptomatic astrovirus detection in her stools. HLA-matched, major ABO-mismatched unrelated donor bone marrow transplant was done following conditioning regimen with busulfan, cyclophosphamide, melphalan and alemtuzumab and post-transplant graft-versus-host prophylaxis with ciclosporin. Neutrophil engraftment was demonstrated on Day + 17 and donor chimerism was 100%. Early transplant course was complicated by culture negative neutropenic fevers, veno-occlusive disease and grade 1 cutaneous graft-versus-host disease that responded to topical steroid. Nutrition rehabilitation was complicated by protracted human astrovirus positive diarrhoea, which was finally resolved upon discharge home on Day +94. Her stool was astrovirus negative on Day + 92. Her ciclosporin was tapered off by Day +100

**Results:** The child became encephalopathic at Day+120 and subsequently developed uncontrolled dystonic movement. Cerebrospinal fluid analysis done on two occasions showed albuminocyttoplasmic dissociation and real-time PCR was negative for herpesviridae (herpes simplex virus I and II, varicella zoster, cytomegalovirus, Epstein-Barr virus, HHV6, and HHV7), papovaviridae (BK, JC) adenovirus, enteroviruses, parechovirus, norovirus, human astrovirus, measles, and Toxoplasma. Cerebrospinal fluid culture did not yield any positive results. Repeat brain images indicated progressive brain volume loss, very poor myelination and high signal within bilateral basal ganglia. Brain biopsy showed non-specific necrotic neurons with featureless nuclei and pyknotic cells. Despite receiving a top up donor marrow to facilitate immune reconstitution, the child died of irreversible global brain dysfunction on Day +196. Encephalitis due to Astrovirus HAstV-VA1/HMO-C-UK1 was diagnosed based on deep sequencing of post-mortem brain biopsy tissue. This astrovirus belongs to VA1 and HMO-C group of astroviruses and is associated with neurological illnesses in mink and cattle.

**Conclusion:** Our patient is the third paediatric patient with astrovirus HAstV-VA1/HMO-C-UK1 encephalitis and only 6 human infections with this virus have been reported to date. The diagnosis of animal-astrovirus encephalitis is challenging and these cases illustrate the value of including testing for astrovirus HAstV-VA1/HMO-C-UK1 in the diagnosis of encephalitides in immunosuppressed patients. We suggest that deep sequencing for this virus should be performed promptly in an immunodeficient host with unexplained encephalopathy.



MRI images on Day +120 (figure A, B, C) and Day +140 (figure D, E, F) showed progressive global volume loss with poor myelination