

Quantitative Analysis of Vitreous Inflammation using Optical Coherence Tomography in Patients Receiving Sub-Tenon's Triamcinolone Acetonide for Uveitic Cystoid Macular Oedema

SUBTITLE – OCT derived measurements vitreous inflammation decrease with clinical resolution of inflammation in CMO, providing a quantitative and objective marker of disease activity in uveitis.

KEY WORDS – uveitis, cystoid macular oedema, optical coherence tomography, imaging, outcome measures

Sreekanth Sreekantam*¹, Trystan Macdonald*², Pearse A Keane³, Dawn A Sim³, Philip I Murray^{1,4}, Alastair K Denniston^{2,4}

¹Birmingham and Midlands Eye Centre, Sandwell and West Birmingham NHS Trust, Birmingham, United Kingdom

²University Hospitals Birmingham NHS Foundation Trust, Birmingham, United Kingdom

³NIHR Biomedical Research Centre for Ophthalmology, Moorfields Eye Hospital NHS Foundation Trust and UCL Institute of Ophthalmology, London, United Kingdom

⁴Academic Unit of Ophthalmology, Centre for Translational Inflammation Research,
College of Medical and Dental Sciences, University of Birmingham, Birmingham,
United Kingdom

* These authors contributed jointly to this study and share the role of first author.

Correspondence to –

Mr. Alastair Denniston,

Consultant Ophthalmologist (Uveitis/Medical Retina) & Hon Reader

Institute of Immunology and Immunotherapy
College of Medical and Dental Sciences
University of Birmingham
Edgbaston
Birmingham
B15 2TT
UK

Email - a.denniston@bham.ac.uk

Abbreviations

CMO – Cystoid macular oedema

EMA – European Medicines Agency

FDA – United States Food and Drug Administration

OCT – ocular coherence tomography

RPE – retinal pigment epithelium

STTA - Sub-Tenon's Triamcinolone Acetonide

Disclosure

Drs. Keane and Sim have received a proportion of their funding from the Department of Health's NIHR Biomedical Research Centre for Ophthalmology at Moorfields Eye Hospital and UCL Institute of Ophthalmology. The views expressed in the publication are those of the author and not necessarily those of the Department of Health.

Drs. Keane and Sim have received travel grants from the Allergan European Retina Panel.

Abstract:

BACKGROUND/AIMS : To evaluate the vitreous signals obtained on spectral domain optical coherence tomography (SD-OCT) in patients with uveitic cystoid macular oedema (CMO) and compare these signals before and after sub-Tenon's triamcinolone acetonide injection.

METHODS

Design: Retrospective study with standardised longitudinal imaging pre- and post-intervention. The study cohort comprises 22 patients (22 eyes) with uveitic CMO receiving a Sub-Tenon's Triamcinolone Acetonide (STTA) injection. Post-hoc analysis of SD-OCT images using custom software provided an "absolute" measurement of vitreous signal intensity, which was expressed as a ratio to the retinal pigment epithelium intensity ("VIT/RPE-relative intensity") in arbitrary units.

Main Outcome Measure: Difference in VIT/RPE-relative intensity before and after treatment.

RESULTS: Treatment with STTA resulted in a significant reduction in VIT/RPE-Relative Intensity, which was associated with both a reduction in central retinal thickness (CRT) and improvement in visual acuity. Mean (SD) VIT/RPE-Relative Intensity pre-treatment was 0.139 (0.074) vs. 0.053 (0.028) post-treatment ($p=3 \times 10^{-5}$). Mean (SD) CRT was 581 μ m (119 μ m) pre-treatment vs 333 μ m (95 μ m) post-treatment ($p=2 \times 10^{-8}$); the mean reduction in CRT was 248 (95%CI: 189-306). The correlation coefficient between VIT/RPE-Relative Intensity and CRT was 0.534

($p=0.011$) and between VIT/RPE-Relative Intensity and visual acuity was 0.702 ($p=0.0001$).

CONCLUSION: This study provides evidence that the OCT-derived VIT/RPE-Relative intensity may be useful as a quantitative and objective marker of disease activity and treatment response in uveitis complicated by CMO. This first longitudinal study of this novel OCT parameter is an encouraging step in the development of sensitive objective OCT-based endpoints for trials of efficacy in uveitis.

Introduction

Uveitis, a group of conditions characterised by intraocular inflammation, is a major cause of blindness worldwide (1). The commonest cause of sight loss in uveitis is cystoid macular oedema (CMO), which accounts for around a third of blindness caused by the disease (2). CMO may be reversible with prompt corticosteroid treatment (3) such as with Sub-Tenon's triamcinolone acetonide (STTA), leading to visual recovery (4-6).

Vitreous inflammation can be seen on examination as a characteristic "haze", caused by the presence of proteinaceous exudate in the vitreous. The level of vitreous haze is considered to be a good marker of inflammation in the underlying uveal tract. For this reason the National Eye Institute (NEI) "Vitreous Haze Score" is the trial endpoint most commonly accepted by regulatory bodies. The NEI scale is determined by examining the vitreous using an indirect ophthalmoscope with comparison to standardised photographs. Weaknesses are that it is subjective, non-continuous, poorly discriminatory at lower levels of inflammation and has low sensitivity in a clinical trial context (7-10).

Optical coherence tomography (OCT), an imaging modality that provides high resolution, cross sectional images of ocular tissues non-invasively is well-established in the measurement of macular pathology, including macular oedema (11-13). Most analysis of OCT images is qualitative, but quantitative analysis - such as the measurement of central macular thickness in macular oedema - provides an objective and sensitive measure of deviation from normal, change over time and response to therapy. We and others are using these principles to develop measures all the key components of intraocular inflammation, such that the clinical assessment

of uveitis may become more objective and reliable (8, 14-18). We have shown in two independent cohorts using two different OCT-platforms that measurements of vitreous inflammation derived from OCT scans are repeatable, reliable and correlated with clinical measures of disease activity, notably the NEI Vitreous Haze Score (17-18). To help ensure internal standardisation, we utilised the reflective intensity of the retinal pigment epithelium (RPE) as a reference, thereby producing a ratio ("VIT/RPE-Relative Intensity) (17-18)..

The aim of this paper is to further validate the use of the VIT/RPE-Relative Intensity as a marker of disease activity in uveitis by assessing whether it is capable of detecting changes in the vitreous pre-/post-STTA, and whether these correlate with other signs of reduction in disease activity.

Materials and Methods

Study Population:

This is a retrospective, longitudinal study comprising 22 patients with uveitic CMO attending a tertiary uveitis clinic at the Birmingham & Midlands Eye Centre, Sandwell & West Birmingham Hospitals NHS Trust, United Kingdom. All patients had a complete ophthalmic assessment including visual acuity, slit lamp examination, grading of anterior chamber inflammation, intraocular pressure measurement, fundus examination and grading of vitreous inflammation using the NEI Vitreous Haze Score. Approval for data collection and analysis was obtained from a U.K. National Health Service research ethics committee and adhered to the tenets set forth in the Declaration of Helsinki. All patients were consented for posterior STTA administration.

Procedure:

Povidone iodine and oxybuprocaine drops were used to sterilize and anesthetize the eye before the procedure. The conjunctiva and sub-Tenons layer were lifted 10mm from the limbus superotemporally using blunt serrated forceps. The sub-Tenon's cannula was attached to a 2ml syringe containing 1ml of 40mg/ml triamcinolone acetonide, and inserted, advancing the needle 12-14mm into the posterior sub-Tenons space into which the full dose (i.e. 40mg triamcinolone acetonide) was administered (19).

Image Acquisition:

Optical coherence tomographic image sets were obtained using Heidelberg Spectralis OCT (Heidelberg Engineering, Germany). The images were obtained immediately prior to the procedure and at the first subsequent clinical review. The volume scan images were centred on the fovea and the TruTrack Active and AutoRescan features were used to ensure that follow-up scans were matched to the baseline scan.. The enhanced depth protocol was not used.

Quantitative Assessment of Vitreous Signal Intensity:

As per our previously published protocol, OCT scan images were imported into 'OCTOR', a program for easy navigation and manual grading of the scans validated in previous studies (20-21). Masked to all clinical data, primary graders marked out 1) the uppermost extent of the vitreous space included in the scan - the "vitreous top", 2) the internal limiting (ILM) membrane, 3) the inner layer of the RPE, and 4) the outer layer of the RPE on all the scans. This was done on five sections going through the central fovea subfield of the Early Treatment Diabetic Retinopathy Study (ETDRS) grid. The area between lines 1 and 2 was defined as the "vitreous space"(VIT), whilst the area between 3 and 4 was defined as the "RPE space" (RPE). The software then calculated the mean intensity values of all image pixels contained within each space as absolute values. A relative value, the VIT/RPE-Relative Intensity, could then be derived to minimise the potential effects of confounders such as lens opacities or anterior chamber inflammation (Figure 1).

Statistical Analyses:

Clinical and imaging data were analyzed with frequency and descriptive statistics. Snellen visual acuities were converted to LogMAR (logarithm of the minimum angle

of resolution) visual acuity for the purposes of statistical analysis. Spearman's correlation was used to assess the relationship between the VIT/RPE-Relative Intensity and clinical/retinal imaging parameter. The Mann-Whitney U test was used in independent samples and Wilcoxon Signed Ranks test in dependent samples.

Statistical analysis was performed using IBM SPSS software version 20.0 for Windows (SPSS, Inc, Chicago, Illinois, USA). P values < 0.05 were considered significant.

Results

Baseline Characteristics:

The study included 22 eyes of 22 patients, before and after treatment with STTA. Their baseline characteristics are listed in Table 1.

VIT/RPE-Relative Intensity

Treatment with STTA was associated with a significant reduction in OCT-measured VIT/RPE-Relative Intensity (Figure 2). The mean (SD) VIT/RPE-Relative Intensity pre-treatment was 0.139 (0.074) vs. 0.053 (0.028) post-treatment ($p=3\times 10^{-5}$).

Mean Central Retinal Thickness

Treatment with STTA was associated with significant reduction in the OCT-measured mean central 1 mm of retinal thickness (CRT). Mean (SD) CRT was 580.5 μm (119.4 μm) pre-treatment vs 332.7 μm (95.4 μm) post-treatment ($p=2\times 10^{-8}$); the mean reduction in CRT was 247.7 (95%CI: 189.1-306.3). The correlation coefficient between VIT/RPE-Relative Intensity and CRT was 0.534 ($p=0.011$; Figure 3).

Visual acuities

Treatment with STTA was associated with significant improvement in visual acuity ($p=0.0001$). The number of patients with a visual acuity greater than 6/12 increased from 1 (4.54%) to 17 (77.3%) with a corresponding reduction in those with 6/12 or worse from 19 (86.4%) to 5 (22.7%) (Fisher exact test, $p=0.0001$). The correlation

coefficient between VIT/RPE-Relative Intensity and visual acuity was 0.702 (p=0.0001; Figure 4).

Discussion

This study provides the first ‘treatment-response’ data to support our proposal that OCT can be used to provide an objective measure of treatment response in uveitis based on changes in the vitreous. It builds on our previous feasibility study in which we demonstrated proof of concept that the VIT/RPE-Relative Intensity could provide an objective and quantitative measure of vitreous inflammation. Both that cross-sectional study and a validation study in an independent cohort showed that the VIT/RPE-Relative Intensity was higher in uveitic eyes with active inflammation than uveitic eyes without active inflammation or healthy controls, and that it correlated with the clinical NEI vitreous haze score (17-18). We also showed association with other markers of disease activity such as visual acuity, AC cells and AC flare. Importantly the VIT/RPE Relative Intensity was also shown to be a repeatable measure with high inter-grader reproducibility (17-18).

In this study we have demonstrated that the VIT/RPE-Relative Intensity decreases significantly in response to STTA and that this reduction was associated with improvement in another measurable sign of disease activity, CMO. Critically this study demonstrates VIT/RPE-Relative intensity is sensitive enough to measure changes in the vitreous undetectable using the clinical NEI Vitreous Haze Score. As highlighted by a number of authors, the poor discrimination of the NEI Vitreous Haze Score at lower levels has led most clinical trials in this field to require subjects to have a minimum NEI Vitreous Haze Score of 2+ for inclusion. This has significantly

limited enrolment (7-10,22). In an observational study comparing a photographic-based score to the NEI score, Hornbeak noted that had they used the traditional 'cut-off' 86% of participants would have been excluded. Although a significant proportion of that cohort were scored as 0 on the NEI Vitreous Haze Score it cannot be argued that all these cases were inactive as both the Hornbeak study and our current study indicate that an appropriately sensitive tool is able to discriminate within this group (9). Whereas the Hornbeak study was cross-sectional, our longitudinal study is the first to show a tool capable of detecting change in uveitis activity within these lower levels of inflammation, even when both the pre-treatment and post-treatment clinical Vitreous Haze Score was 0.

There is an urgent need to develop sensitive objective measures of inflammation in uveitis, for use as endpoints in clinical trials and to inform treatment decisions in routine clinical practice. The FDA advises that a trial endpoint must be 'well-defined and reliable' and recommends that treatment benefit should be a measure of how a patient "survives, feels or functions". Other measures that do not capture these are regarded as "surrogate measures of benefit".

All measures of disease activity in uveitis are "surrogate measures". The FDA requires a surrogate to be "reasonably likely, based on epidemiologic, therapeutic, pathophysiologic, or other evidence to predict clinical benefit". In the context of developing and assessing surrogate measures for use as trial endpoints in uveitis, we propose that they must meet two *essential criteria*: (1) The surrogate should be 'biologically relevant' given our understanding of the pathophysiology of the disease; and (2) The surrogate should be 'functionally relevant' with evidence of a

downstream effect on visual function, but recognizing that this effect may be delayed and indirect. Provided a surrogate satisfies these criteria, it should then be assessed for *desirable criteria* such as objectivity, repeatability, and sensitivity,

This study provides further evidence of the biological and functional relevance of VIT/RPE relative intensity..Its biological relevance is demonstrated by its association with other markers of inflammation such as the central retinal thickness. Its functional relevance is supported by its correlation with visual recovery, however it is recognized that this is largely indirect, the primary mechanism of improvement being the restoration of central macular architecture as the oedema resolves.

The OCT-derived VIT/RPE-Relative intensity is the first instrument-measured marker of vitreous inflammation, and is an example of how extended applications of OCT and other imaging modalities have the potential to revolutionise our approach to the diagnosis, assessment and management of uveitis. Research into VIT/RPE-Relative intensity levels during the development of CME and its relation to vascular changes visualized on fluorescein angiography may inform our understanding of the natural history of this sight-threatening complication, and help guide treatment..

Furthermore the sensitivity of this small study to detect a change at a highly statistically significant level ($p = 0.00003$), shows how the acceptance of OCT-derived objective indices could transform our approach to effectiveness trials in uveitis. .The limitations of our current endpoints in uveitis provide major constraints to effectiveness trials (7-10,23), which may lead to a trial 'failing' (i.e. not meeting its primary endpoint) even in the presence of an effective therapy. This in turn

discourages further investment, and leads to an absence of high-quality trial data to inform clinicians, funders and policy makers with regard to many of the therapies being considered for use in uveitis. The high sensitivity and reproducibility of instrument-based measures such as the OCT-derived VIT/RPE relative intensity can provide endpoints with much higher 'signal:noise' ratio than current clinical measures enabling smaller, faster, cheaper trials. Such endpoints can already be adopted as 'signals' to inform investment decisions in early phase studies, but their adoption in later-phase licensing studies will depend on achieving the further validation required by regulatory bodies such as the FDA.

Study limitations

This study involves retrospective analysis of longitudinal OCT image sets obtained from a small number of patients with uveitis and OCT-confirmed CMO. It therefore has the limitations of a retrospective design, and we acknowledge that given the nature of this cohort the focus of the clinical assessments at the time will have been directed towards the CMO, and not on accurate grading of the clinical vitreous haze. We also note that visual acuity data were recorded as Snellen measurements rather than the preferred LogMAR notation. It should be noted however that the primary focus of this paper is on the post-hoc analysis of the OCT image sets and their change over time, rather than on the associated clinical changes.

The design of the study was pragmatic in using scans conducted under normal macular scanning conditions. We and others have proposed a number of techniques for optimising the visualisation of vitreous using current Spectral Domain

and emerging technology (8,10, 17-18). Increasing the proportion of the vitreous which is visualised is likely to improve this technique further, enhancing sensitivity and repeatability; it also enables anatomic localisation of foci of inflammation within the vitreous cavity related to the distribution and type of uveitis.

This study is based on a small cohort, with a range of uveitic diagnoses. This heterogeneity is common in uveitis studies (8,10), and indeed the consistent performance of the VIT/RPE relative intensity tool across this range of patients is very encouraging for its future usefulness as an outcome measure. Critically, despite its size and heterogeneity, the study achieved its primary endpoint at a high level of statistical significance .

A barrier to the potential adoption of our technique as described in this study is that it is time-consuming, taking around 3-5 minutes per scan. Recently however we have developed a software package for automation of this process. This custom software entitled VITreous ANalysis (VITAN) can segment and annotate the scans automatically, reducing the time taken to derive measures of vitreous reflectivity to a few seconds per scan, with benefits in speed, cost, and further reduction of subjectivity or human error in marking the boundaries of anatomical structures (24).

To conclude, in this study we have further demonstrated the relevance of the OCT-derived VIT/RPE-Relative intensity as a quantitative and objective marker of disease activity and treatment response in uveitis complicated by CME. This first longitudinal study of this novel OCT parameter is an encouraging step in the

development of sensitive objective OCT-based endpoints for trials of efficacy in uveitis.

References:

- (1) Nussenblatt RB. The natural history of uveitis. *Int Ophthalmol* 1990 Oct;14(5-6):303-308.
- (2) Rothova A, Suttorp-van Schulten MS, Frits Treffers W, Kijlstra A. Causes and frequency of blindness in patients with intraocular inflammatory disease. *Br J Ophthalmol* 1996 Apr;80(4):332-336.
- (3) Levin MH, Pistilli M, Daniel E, Gangaputra SS, Nussenblatt RB, Rosenbaum JT, et al. Incidence of Visual Improvement in Uveitis Cases with Visual Impairment Caused by Macular Edema. *Ophthalmology* 2014 Feb;121(2):588-595.e1.
- (4) Salek SS, Leder HA, Butler NJ, Gan TJ, Dunn JP, Thorne JE. Periocular triamcinolone acetonide injections for control of intraocular inflammation associated with uveitis. *Ocul Immunol Inflamm* 2013 Aug;21(4):257-263.
- (5) Sen HN, Vitale S, Gangaputra SS, Nussenblatt RB, Liesegang TL, Levy-Clarke GA, et al. Periocular corticosteroid injections in uveitis: effects and complications. *Ophthalmology* 2014 Nov;121(11):2275-2286.
- (6) Leder HA, Jabs DA, Galor A, Dunn JP, Thorne JE. Periocular triamcinolone acetonide injections for cystoid macular edema complicating noninfectious uveitis. *Am J Ophthalmol* 2011 Sep;152(3):441-448.e2.
- (7) Madow B, Galor A, Feuer WJ, Altaweel MM, Davis JL. Validation of a Photographic Vitreous Haze Grading Technique for Clinical Trials in Uveitis. *Am J Ophthalmol* 2011 8;152(2):170-176.e1.
- (8) Denniston AK, Dick AD. Systemic therapies for inflammatory eye disease: past, present and future. *BMC Ophthalmol* 2013 Apr 24;13:18-2415-13-18.
- (9) Hornbeak DM, Payal A, Pistilli M, Biswas J, Ganesh SK, Gupta V, Rathinam SR, Davis JL, Kempen JH. Interobserver agreement in clinical grading of vitreous haze using alternative grading scales. *Ophthalmology*. 2014 Aug;121(8):1643-8. doi: 10.1016/j.ophtha.2014.02.018. Epub 2014 Mar 31. PubMed PMID: 24697913; PubMed Central PMCID: PMC4122589
- (10) Barry RJ, Denniston AK. Controversies in the Pharmacological Treatment of Uveitis. *Curr Pharm Des* 2015 Sep 8. [Epub ahead of print] PubMed PMID: 26350535
- (11) Hee MR, Puliafito CA, Wong C, Duker JS, Reichel E, Rutledge B, et al. Quantitative assessment of macular edema with optical coherence tomography. *Arch Ophthalmol* 1995 Aug;113(8):1019-1029.
- (12) Ouyang Y, Keane PA, Sadda SR, Walsh AC. Detection of cystoid macular edema with three-dimensional optical coherence tomography versus fluorescein angiography. *Invest Ophthalmol Vis Sci* 2010 Oct;51(10):5213-5218.

- (13) Alasil T, Keane PA, Updike JF, Dustin L, Ouyang Y, Walsh AC, et al. Relationship between optical coherence tomography retinal parameters and visual acuity in diabetic macular edema. *Ophthalmology* 2010 Dec;117(12):2379-2386.
- (14) Agarwal A, Ashokkumar D, Jacob S, Agarwal A, Saravanan Y. High-speed optical coherence tomography for imaging anterior chamber inflammatory reaction in uveitis: clinical correlation and grading. *Am J Ophthalmol* 2009 Mar;147(3):413-416.e3.
- (15) Li Y, Lowder C, Zhang X, Huang D. Anterior chamber cell grading by optical coherence tomography. *Invest Ophthalmol Vis Sci* 2013 Jan 9;54(1):258-265.
- (16) Sharma S, Lowder CY, VasANJI A, Baynes K, Kaiser PK, Srivastava SK. Automated Analysis of Anterior Chamber Inflammation by Spectral-Domain Optical Coherence Tomography. *Ophthalmology* 2015 Jul;122(7):1464-1470.
- (17) Keane PA, Karampelas M, Sim DA, Sadda SR, Tufail A, Sen HN, et al. Objective measurement of vitreous inflammation using optical coherence tomography. *Ophthalmology* 2014 Sep;121(9):1706-1714.
- (18) Zarranz-Ventura J, Keane PA, Sim DA, Llorens V, Tufail A, Sadda SR, Dick AD, Lee RW, Pavesio C, Denniston AK, Adán A; EQUATOR Study Group. Evaluation of objective vitritis grading method using optical coherence tomography: influence of phakic status and previous vitrectomy. *Am J Ophthalmol*. 2015 Oct 14. pii: S0002-9394(15)00637-6. doi: 10.1016/j.ajo.2015.10.009. [Epub ahead of print] PubMed PMID: 26476212.
- (19) Venkatesh P, Kumar CS, Abbas Z, Garg S. Comparison of the efficacy and safety of different methods of posterior subtenon injection. *Ocular Immunology & Inflammation* 2008 Sep-Oct;16(5):217-223.
- (20) Sadda SR, Joeres S, Wu Z, Updike P, Romano P, Collins AT, et al. Error correction and quantitative subanalysis of optical coherence tomography data using computer-assisted grading. *Invest Ophthalmol Vis Sci* 2007 Feb;48(2):839-848.
- (21) Sadda SR, Keane PA, Ouyang Y, Updike JF, Walsh AC. Impact of scanning density on measurements from spectral domain optical coherence tomography. *Invest Ophthalmol Vis Sci* 2010 Feb;51(2):1071-1078.
- (22) Lowder C, Belfort R, Jr, Lightman S, Foster CS, Robinson MR, Schiffman RM, et al. Dexamethasone intravitreal implant for noninfectious intermediate or posterior uveitis. *Arch Ophthalmol* 2011 May;129(5):545-553.
- (23) Denniston AK, Holland GN, Kidess A, Nussenblatt RB, Okada AA, Rosenbaum JT, et al. Heterogeneity of primary outcome measures used in clinical trials of treatments for intermediate, posterior, and panuveitis. *Orphanet J Rare Dis* 2015 Aug 19;10:97-015-0318-6.
- (24) Keane PA, Balaskas K, Sim DA, Aman K, Denniston AK, Aslam T, et al. Automated Analysis of Vitreous Inflammation Using Spectral-Domain Optical Coherence Tomography. *Transl Vis Sci Technol* 2015 Sep 16;4(5):4.

Tables and figures:

TABLE 1: Baseline Characteristics

Age	47.4 years (23y – 74y)
Gender	
Female	17 (77%)
Male	5 (23%)
Anatomical Site of Uveitis	
Panuveitis	10 (45%)
Intermediate Uveitis	8 (36%)
Anterior Uveitis	4 (18%)
Aetiology	
Idiopathic	14 (64%)
Sarcoidosis	4 (18%)
TINU	1 (5%)
Behcet's	1 (5%)
Reiter	1 (5%)
VKH	1 (5%)
AC Cells	

0	6
0.5+	6
1+	4
2+	4
3+	0
4+	0
Not available	2
AC Flare	
0	12 (54.54%)
0.5+	2 (9.09%)
1+	6 (27.27%)
2+	0
3+	0
4+	0
Not available	2 (9.09%)
Vitreous haze	
0	15 (68.18%)
0.5+	0
1+	2 (9.09%)
2+	1 (4.54%)
3+	0
4+	0
Not available	4 (18.18%)

Timing of Post-Intervention Review	
Median (range) duration to follow-up OCT scan and review post-treatment	7 weeks (4 – 19 weeks)



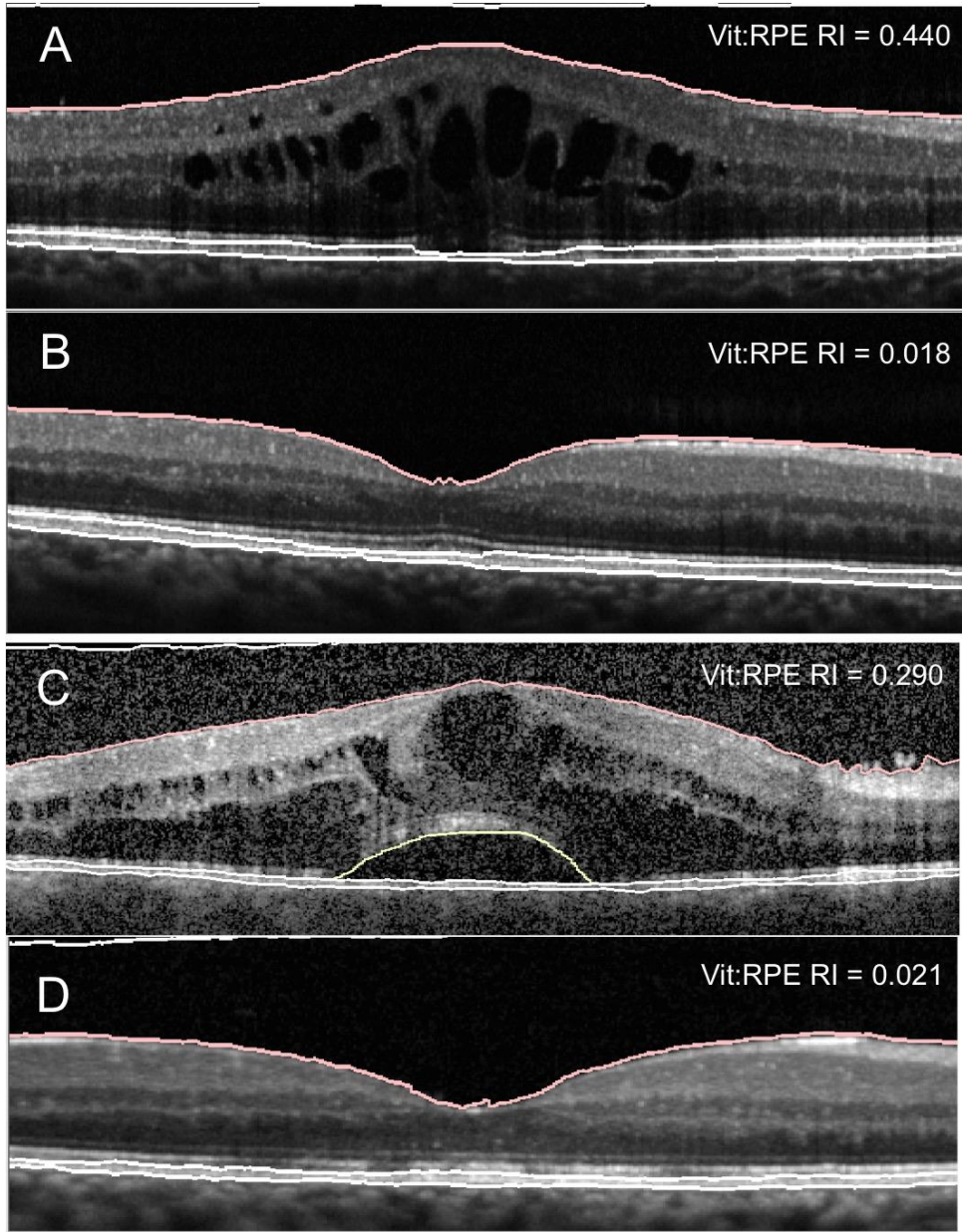


Figure 1. Quantitative assessment of the vitreous using OCT demonstrated in a 47 year old male with intermediate uveitis (A,B) and a 48 year old female with panuveitis (C,D). Both patients were assessed

by standard macular-focussed OCT both before (A,C) and after (B,D) treatment with Sub-Tenon's Triamcinolone Acetonide (STTA), with calculation of the Vitreous/RPE-Relative Intensity (Vit/RPE RI)..

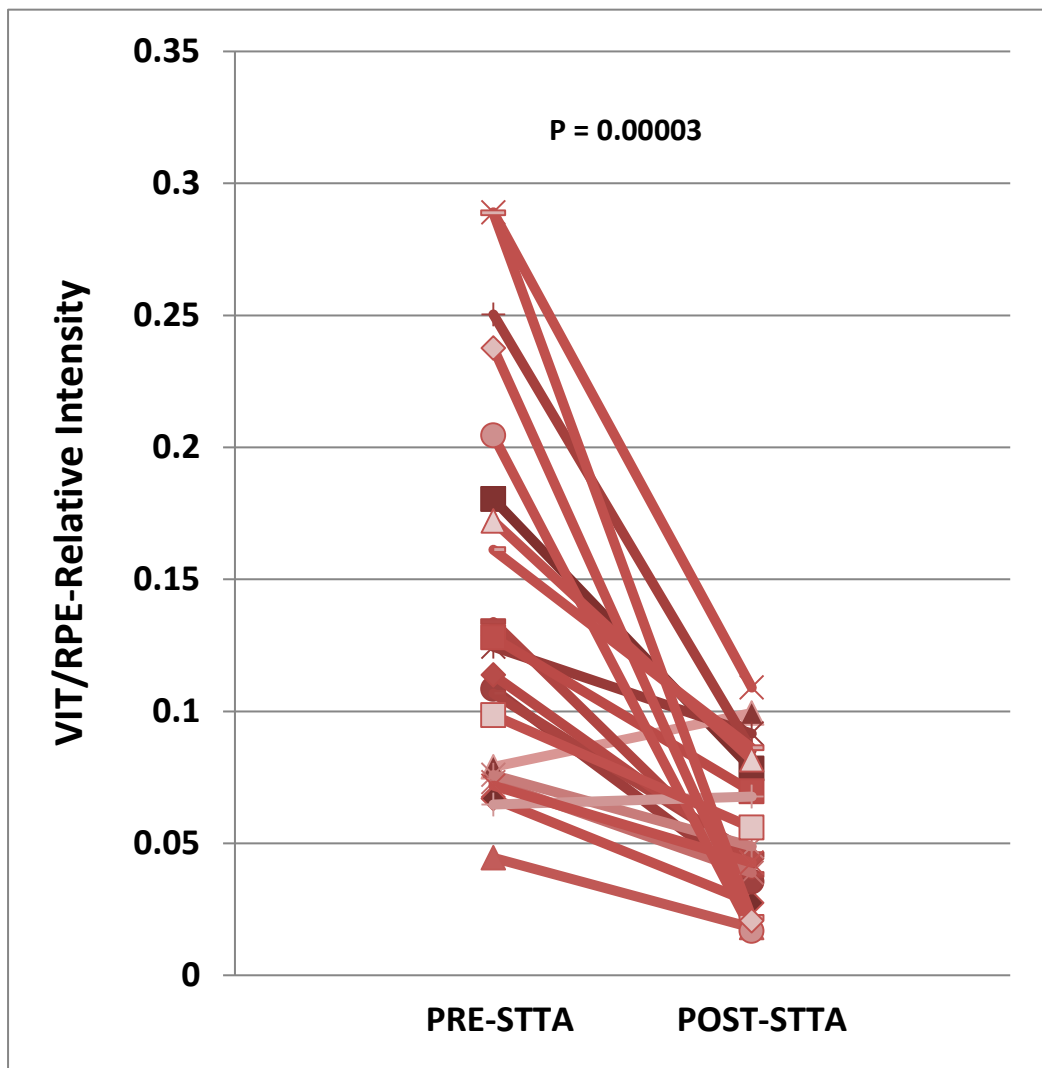


Figure 2. VIT/RPE-Relative Intensity before and after treatment with Sub-Tenon Triamcinolone Acetonide (STTA) for Uveitic Cystoid Macular Oedema (CMO).

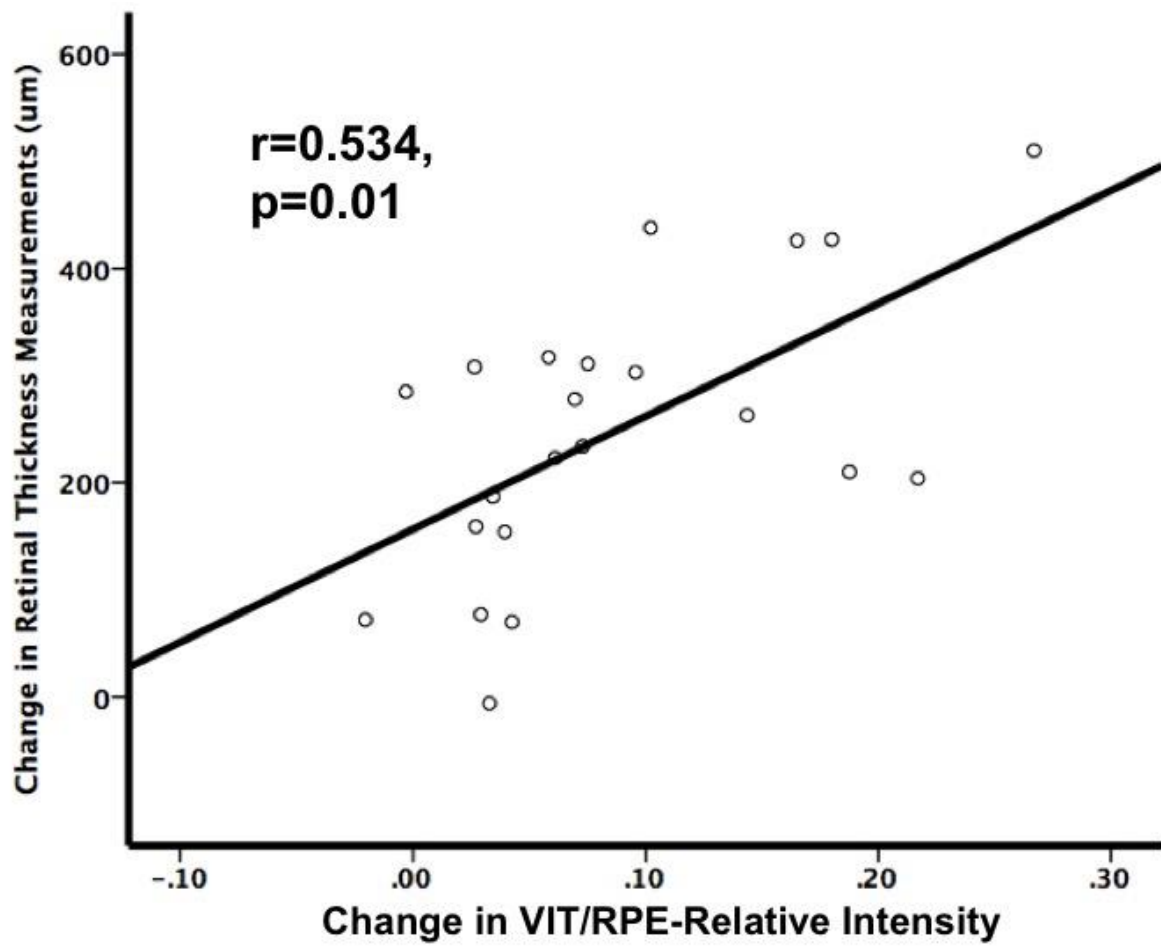


Figure 3. Correlation between change in VIT/RPE–Relative intensity and change in mean central retinal thickness.

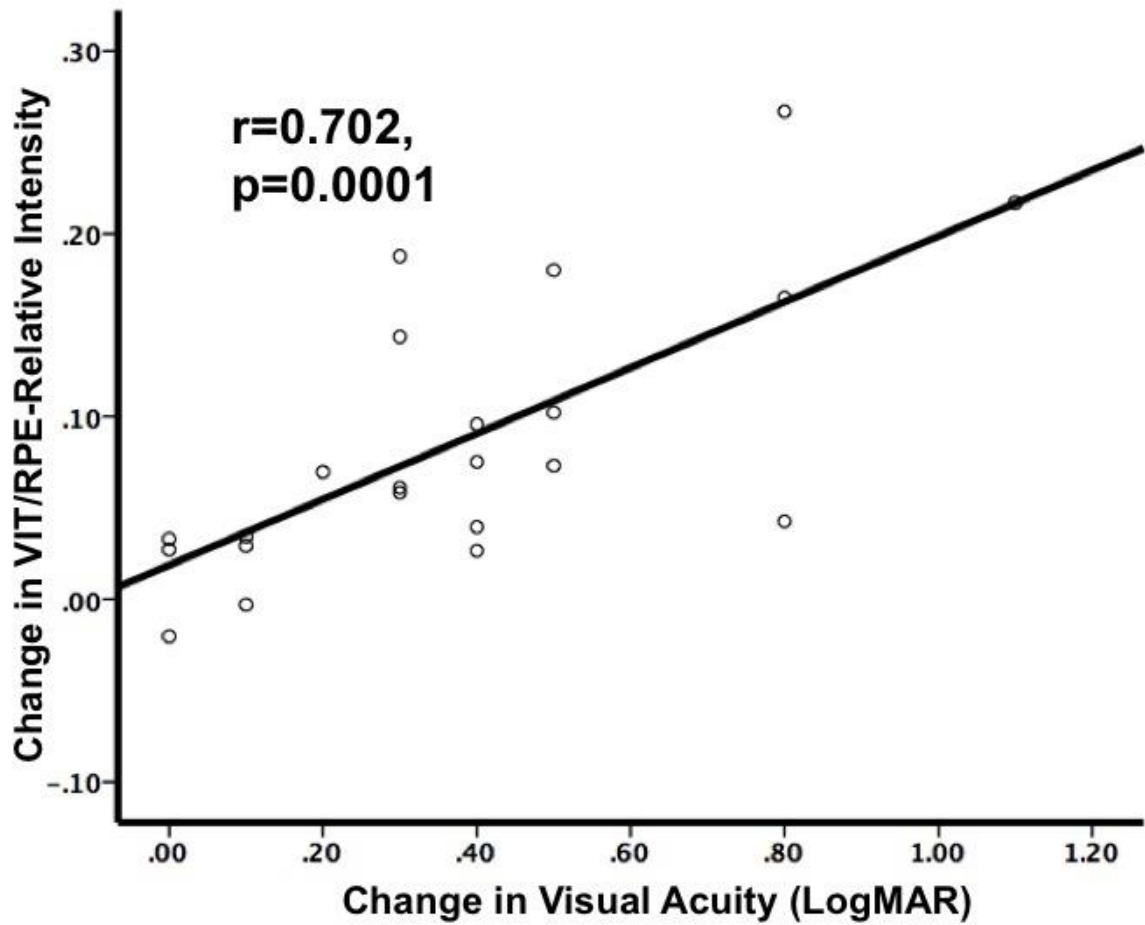


Figure 4. Correlation between change in VIT/RPE–Relative intensity and change in visual acuity.
