

Autopsy validation of ^{123}I -FP-CIT dopaminergic neuroimaging for the diagnosis of DLB

OPEN ▲

Alan J. Thomas, PhD
Johannes Attems, MD
Sean J. Colloby, PhD
John T. O'Brien, DM
Ian McKeith, FMedSci
Rodney Walker, PhD
Lean Lee
David Burn, MD
Debra J. Lett, BA
Zuzana Walker, MD

Correspondence to
Dr. Thomas:
alan.thomas@ncl.ac.uk

ABSTRACT

Objective: To conduct a validation study of ^{123}I -N-fluoropropyl-2b-carbomethoxy-3b-(4-iodophenyl) nortropane (^{123}I -FP-CIT) SPECT dopaminergic imaging in the clinical diagnosis of dementia with Lewy bodies (DLB) with autopsy as the gold standard.

Methods: Patients >60 years of age with dementia who had undergone ^{123}I -FP-CIT imaging in research studies and who had donated their brain tissue to the Newcastle Brain Tissue Resource were included. All had structured clinical research assessments, and clinical diagnoses were applied by consensus panels using international diagnostic criteria. All underwent ^{123}I -FP-CIT imaging at baseline, and scans were rated as normal or abnormal by blinded raters. Patients were reviewed in prospective studies and after death underwent detailed autopsy assessment, and neuropathologic diagnoses were applied with the use of standard international criteria.

Results: Fifty-five patients (33 with DLB and 22 with Alzheimer disease) were included. Against autopsy diagnosis, ^{123}I -FP-CIT had a balanced diagnostic accuracy of 86% (sensitivity 80%, specificity 92%) compared with clinical diagnosis, which had an accuracy of 79% (sensitivity 87%, specificity 72%). Among patients with DLB, 10% (3 patients) met pathologic criteria for Lewy body disease but had normal ^{123}I -FP-CIT imaging.

Conclusions: This large autopsy analysis of ^{123}I -FP-CIT imaging in dementia demonstrates that it is a valid and accurate biomarker for DLB, and the high specificity compared with clinical diagnosis (20% higher) is clinically important. The results need to be replicated with patients recruited from a wider range of settings, including movement disorder clinics and general practice. While an abnormal ^{123}I -FP-CIT scan strongly supports Lewy body disease, a normal scan does not exclude DLB with minimal brainstem involvement.

Classification of evidence: This study provides Class I evidence that ^{123}I -FP-CIT dopaminergic neuroimaging accurately identifies patients with DLB. *Neurology*® 2017;88:276-283

GLOSSARY

AD = Alzheimer disease; **CBD** = corticobasal degeneration; **CERAD** = Consortium to Establish a Registry for Alzheimer's Disease; **CI** = confidence interval; **DLB** = dementia with Lewy bodies; **FTLD** = frontotemporal lobar degeneration; **^{123}I -FP-CIT** = ^{123}I -N-fluoropropyl-2b-carbomethoxy-3b-(4-iodophenyl) nortropane; **LBD** = Lewy body disease; **RBD** = REM sleep behavior disorder; **PD** = Parkinson disease; **UPDRS** = Unified Parkinson's Disease Rating Scale.

Early identification and accurate diagnosis of dementia are priorities because disease-modifying treatments need to be administered at the earliest stage. Accurate diagnosis is more difficult during earlier phases of disease, and the need to use biomarkers to improve accuracy is correspondingly more pressing and included in recent diagnostic criteria.^{1,2} For example, dementia with Lewy bodies (DLB) is the second commonest cause of degenerative dementia after Alzheimer disease (AD).³ Diagnostic criteria for DLB have high accuracy in specialist centers (sensitivity and specificity both >80%),⁴ although case detection in many centers is less accurate.

Supplemental data
at Neurology.org

From the Institute of Neuroscience (A.J.T., J.A., S.J.C., I.M., D.B., D.J.L.), Newcastle University, Campus for Ageing and Vitality, Newcastle Upon Tyne; Department of Psychiatry (J.T.O.), University of Cambridge School of Clinical Medicine; Department of Neurology (R.W.), Barts Health NHS Trust, Royal London Hospital; North Essex Partnership University NHS Foundation Trust (L.L., Z.W.), Epping; and Division of Psychiatry (Z.W.), University College London, UK.

Go to Neurology.org for full disclosures. Funding information and disclosures deemed relevant by the authors, if any, are provided at the end of the article. The Article Processing Charge was paid by the authors.

This is an open access article distributed under the terms of the Creative Commons Attribution-NonCommercial-NoDerivatives License 4.0 (CC BY-NC-ND), which permits downloading and sharing the work provided it is properly cited. The work cannot be changed in any way or used commercially without permission from the journal.

Dopaminergic neurons in the substantia nigra pars compacta project to the striatum (the nigrostriatal pathway). Their loss is associated with the presence of α -synuclein aggregates (Lewy bodies and Lewy neurites), which are a core neuropathologic feature of DLB and Parkinson disease (PD).⁴ Autopsy studies report a loss of dopamine transporters associated with loss of nigrostriatal neurons,⁵ which can be assessed with imaging. Such imaging, using PET and SPECT ligands, is abnormal in PD, multiple system atrophy, corticobasal degeneration (CBD),⁶ progressive supranuclear palsy,⁶ frontotemporal lobar degeneration (FTLD),⁷ and DLB.⁸ Dopaminergic neuroimaging is a biomarker included as a suggestive feature in the consensus diagnostic criteria for DLB,⁴ and a review of ¹²³I-N-fluoropropyl-2b-carbomethoxy-3b-(4-iodophenyl) nortropane (¹²³I-FP-CIT) SPECT studies, with clinical diagnosis used as the standard, reported a sensitivity of 78% and specificity of 90% for differentiating AD from DLB.⁹

Although ¹²³I-FP-CIT imaging has good accuracy for DLB in degenerative dementia, its validation has rested mainly on comparisons with a consensus clinical diagnosis.¹⁰ The gold standard for biomarker validation is autopsy, but only 2 small studies have evaluated ¹²³I-FP-CIT against neuropathology in DLB. One examined 20 patients (8 with DLB) and found that ¹²³I-FP-CIT had a sensitivity of 88% and specificity of 100%.¹¹ The other investigated neuronal loss and pathology in 23 cases (7 with DLB), reporting an association between neuronal density in the substantia nigra and reduced uptake on ¹²³I-FP-CIT.¹² There is therefore a need to validate ¹²³I-FP-CIT diagnostic accuracy in autopsy-confirmed DLB. Here, we report such a validation using brain tissue from the Newcastle Brain Tissue Resource in 55 patients with dementia who had ¹²³I-FP-CIT SPECT imaging in research studies during life.

METHODS The primary purpose of this study was to assess the diagnostic accuracy of ¹²³I-FP-CIT dopaminergic imaging in people with neurodegenerative dementia. This study provides Class I evidence that ¹²³I-FP-CIT dopaminergic neuroimaging accurately identifies patients with DLB.

Patients and clinical diagnosis. Patients >60 years old (at clinical assessment) in the Newcastle Brain Tissue Resource who had had ¹²³I-FP-CIT imaging in the context of a dementia were

included in this study. We did not include patients with PD or healthy controls.

Standard protocol approvals, registrations, and patient consents. Clinical research studies were approved by local research ethics committees and the UK Department of Health Administration of Radioactive Substances Advisory Committee. Participants gave written informed consent; if they were not competent, assent was obtained from their nearest relative. At death, the relative gave permission for tissue donation and use of autopsy material and previous clinical data for research in accordance with research ethics committee procedures for Newcastle Brain Tissue Resource.

Individuals were recruited from memory and dementia services where they received clinical diagnoses from board-certified psychiatrists or neurologists. They participated in prospective studies of dementia at Newcastle University or University College London. All undertook structured research assessments and had ¹²³I-FP-CIT SPECT imaging. These studies took place from the late 1990s through the first decade of this millennium, and clinical diagnostic criteria evolved over this time. Most patients were assessed with the 1996 consensus criteria for DLB,¹³ but some were assessed with the 2005 criteria.⁴ The latter criteria were modified in that ¹²³I-FP-CIT was not used for clinical diagnosis of patients for this analysis, and all clinical (and pathologic) diagnoses were applied blinded to ¹²³I-FP-CIT findings. Patients with AD met the National Institute of Neurological and Communicative Disorders and Stroke–Alzheimer’s Disease and Related Disorder Association criteria for AD.¹⁴

Patients underwent structured clinical assessments and neurocognitive testing, including the Mini-Mental State Examination¹⁵ and Cambridge Cognitive Examination.¹⁶ Parkinsonism was assessed with the motor subsection of the Unified Parkinson’s Disease Rating Scale (UPDRS).¹⁷ Assessments were repeated annually until patients could no longer comply, and final assessments nearest to death were recorded for this analysis.

¹²³I-FP-CIT SPECT imaging. With the use of a previous imaging protocol,¹⁸ Newcastle patients were scanned for 30 minutes with a triple-head gamma camera (Picker 3000XP), 4 hours after injection of 150 MBq of ¹²³I-FP-CIT (DaTSCAN, GE Healthcare, Chalfont St. Giles, UK). In London, acquisition was 30 to 45 minutes with a brain-dedicated Strichman Medical Equipment 810 gamma camera 3 to 4 hours after injection (185 MBq).⁸

After reconstruction, scans were visually rated at each site by independent raters (5 in Newcastle, 3 in London) blinded to clinical information, and a consensus rating of either abnormal (consistent with Lewy body disease [LBD]) or normal was agreed on, as previously reported.^{18,19}

Neuropathology. Cases were independently assessed neuropathologically by researchers blinded to clinical and ¹²³I-FP-CIT findings.²⁰ The right hemisphere, brainstem, and cerebellum were fixed in 4% buffered aqueous formaldehyde for 4 to 6 weeks. Sections from paraffin-embedded blocks from frontal, temporal, parietal, and occipital cortices; cingulate and hippocampus; striatum (including both caudate nucleus and putamen); amygdala; midbrain; and locus coeruleus were cut at 6 μ m and mounted on 4% 3-aminopropyltriethoxysilane-coated slides.²⁰

Immunostaining with monoclonal antibodies against hyperphosphorylated tau (AT8, dilution 1:4,000, Innogenetics, Ghent, Belgium), β -amyloid (4G8, dilution 1:15,000, 4G8, Signet Laboratories, Inc, Dedham, MA), and α -synuclein (dilution 1:200, Chemicon, Hofheim, Germany) was carried out. Before this, slides were microwaved for antigen retrieval in 0.01 mL citrate buffer for 10 minutes (AT8), pressure cooked in 0.01 mol/L EDTA for 90 seconds (α -synuclein), or immersed for 1 hour in formic acid (4G8).

Immunopositivity was assessed with a MenaPath horseradish peroxidase polymer detection kit (Menarini Diagnostics, Berkshire, UK) with chromogen 3,3 diaminobenzidine and counterstained with hematoxylin. Finally, tissue was dehydrated through an alcohol series, cleared, and mounted with DPX (CellPath, Powys, UK).²⁰

Neuropathologic diagnoses were assigned with the use of accepted international neuropathologic criteria, including neuritic Braak stages,²¹ Consortium to Establish a Registry for Alzheimer's Disease (CERAD) scores,²² and Newcastle-McKeith criteria.⁴ Of note, AD was diagnosed if neuritic Braak stages were V or VI and CERAD scores were B or C. We diagnosed AD if neuropathologic findings indicated a "high probability of AD" (according to National Institute on Aging-Reagan Institute criteria) and when Thal β -amyloid phases were available (total $n = 17$; AD $n = 9$ including 5 mixed AD/DLB) a "high AD neuropathologic change" (according to National Institute on Aging-Alzheimer's Association criteria).

A final clinicopathologic diagnosis was applied, combining available data from the clinical research and health service records with this neuropathologic assessment but not including results of the ¹²³I-FP-CIT imaging. It is common for older people to have more than one neuropathology contributing to their dementia. Here, the term mixed LBD + AD is used to classify patients who fulfilled the neuropathologic criteria for both DLB (limbic/neocortical LBD) and AD (Braak stage V/VI and CERAD B/C).²⁰ These final clinicopathologic diagnoses were used to validate the ¹²³I-FP-CIT results.

Statistical analysis. The Statistical Package for Social Sciences software (SPSS version 23) was used for statistical evaluation. For group comparisons, χ^2 tests were used for categorical variables, and for continuous variables, we tested for normality of distribution with t tests or Mann-Whitney tests. Diagnostic accuracy of ¹²³I-FP-CIT (sensitivity, specificity, and overall accuracy) against autopsy was calculated from standard 2×2 frequency tables, and 95% confidence for these was calculated with Minitab (version 16.1).

RESULTS At baseline ¹²³I-FP-CIT, there were 33 patients with DLB and 22 patients with AD (see table 1 for details and figure 1). There were no group differences in sex, but patients with AD were older at death. In most cases, the neuropathologic diagnoses

confirmed the clinical baseline diagnoses; 70% of DLB cases had pure LBD, and 73% of AD cases had pure AD, with a few patients having LBD + AD at autopsy (3 with DLB, 4 with AD). Three patients (1 with clinical DLB, 2 with AD) had FTLD with no other significant neuropathology, and one patient with DLB had CBD. Table 2 details clinical features. Groups were similar in cognition at baseline and final assessments, and as expected, there was more parkinsonism in the DLB group at both time points. Patients with DLB also had more depression, although levels were not clinically significant. The proportion of patients with core features of DLB was similar to that in previously published studies. Most patients were assessed before the 2005 criteria, so ascertainment of REM sleep behavior disorder (RBD) was limited, but 6 patients with DLB had RBD. No patients had neuroleptic sensitivity, but very few had been exposed to such medication.

Autopsy validation of ¹²³I-FP-CIT imaging. To assess the validity of ¹²³I-FP-CIT for detecting LBD in the context of dementia, all cases with either pure LBD or mixed LBD + AD ($n = 30$) were regarded as having proven LBD, and all other cases were classified as non-LBD ($n = 25$: 21 with AD, 3 with FTLD, 1 with CBD). Of the 30 LBD cases, 24 had abnormal ¹²³I-FP-CIT imaging (sensitivity 80%, 95% confidence interval [CI] 92–62), and of the 25 non-LBD cases, 23 had normal ¹²³I-FP-CIT imaging (specificity 92%, 95% CI 99–74). Balanced diagnostic accuracy was 86% (95% CI 94–74).

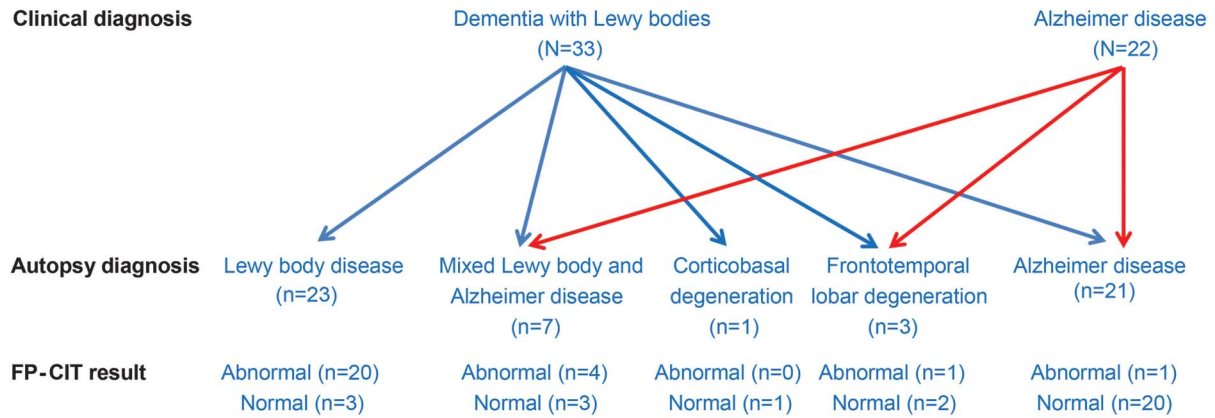
Accuracy of clinical diagnosis. We compared the diagnostic accuracy of clinical diagnosis (blinded to ¹²³I-FP-CIT) at the time of ¹²³I-FP-CIT imaging vs autopsy diagnosis. Of the 30 autopsy LBD cases, 26 were diagnosed clinically as having DLB and 4 were

Table 1 Demographic and pathologic data by baseline clinical diagnosis

	DLB (n = 33)	AD (n = 22)	
Age at ¹²³ I-FP-CIT, y	75.6 (7.2)	78.9 (6.9)	$t = 1.71, df = 55, p = 0.09$
Age at death, y	78.8 (6.8)	86.0 (6.8)	$t = 3.84, df = 53, p < 0.001$
M:F, n	21:12	13:9	$\chi^2 = 0.116, df = 1, p = 0.734$
Interval between ¹²³ I-FP-CIT and death, y	3.3 (2.3)	7.1 (3.5)	$U = 606, p < 0.001$
Interval between last assessment and death, mo	12.3 (11.2)	34.9 (32.2)	$U = 538, p < 0.001$
Neuropathologic findings at autopsy, n			
LBD	23	0	
AD	5	16	
Mixed LBD and AD	3	4	
Frontotemporal lobar degeneration	1	2	
Corticobasal degeneration	1	0	

Abbreviations: AD = Alzheimer disease; DLB = dementia with Lewy bodies; ¹²³I-FP-CIT = ¹²³I-N-fluoropropyl-2b-carbomethoxy-3b-(4-iodophenyl) nortropane; LBD = Lewy body disease.

Figure 1 Flowchart showing relationship of clinical diagnosis to autopsy and ¹²³I-FP-CIT imaging findings



¹²³I-FP-CIT = ¹²³I-N-fluoropropyl-2b-carbomethoxy-3b-(4-iodophenyl) nortropane.

clinically diagnosed as having AD (sensitivity 87%, 95% CI 96–70). Of the 25 non-LBD cases, 18 were diagnosed as having AD and 7 as having DLB (specificity 72%, 95% CI 88–51). Balanced diagnostic accuracy was 79% (95% CI 89–66).

To assess possible reasons for misleading ¹²³I-FP-CIT scan results, we re-examined all clinical records, research records, and autopsy findings for the 8 clinically misclassified cases, 2 false positives and 6 false negatives (see figure e-1 at Neurology.org for examples). Both false-positive cases had been diagnosed as DLB, and the ¹²³I-FP-CIT scans were

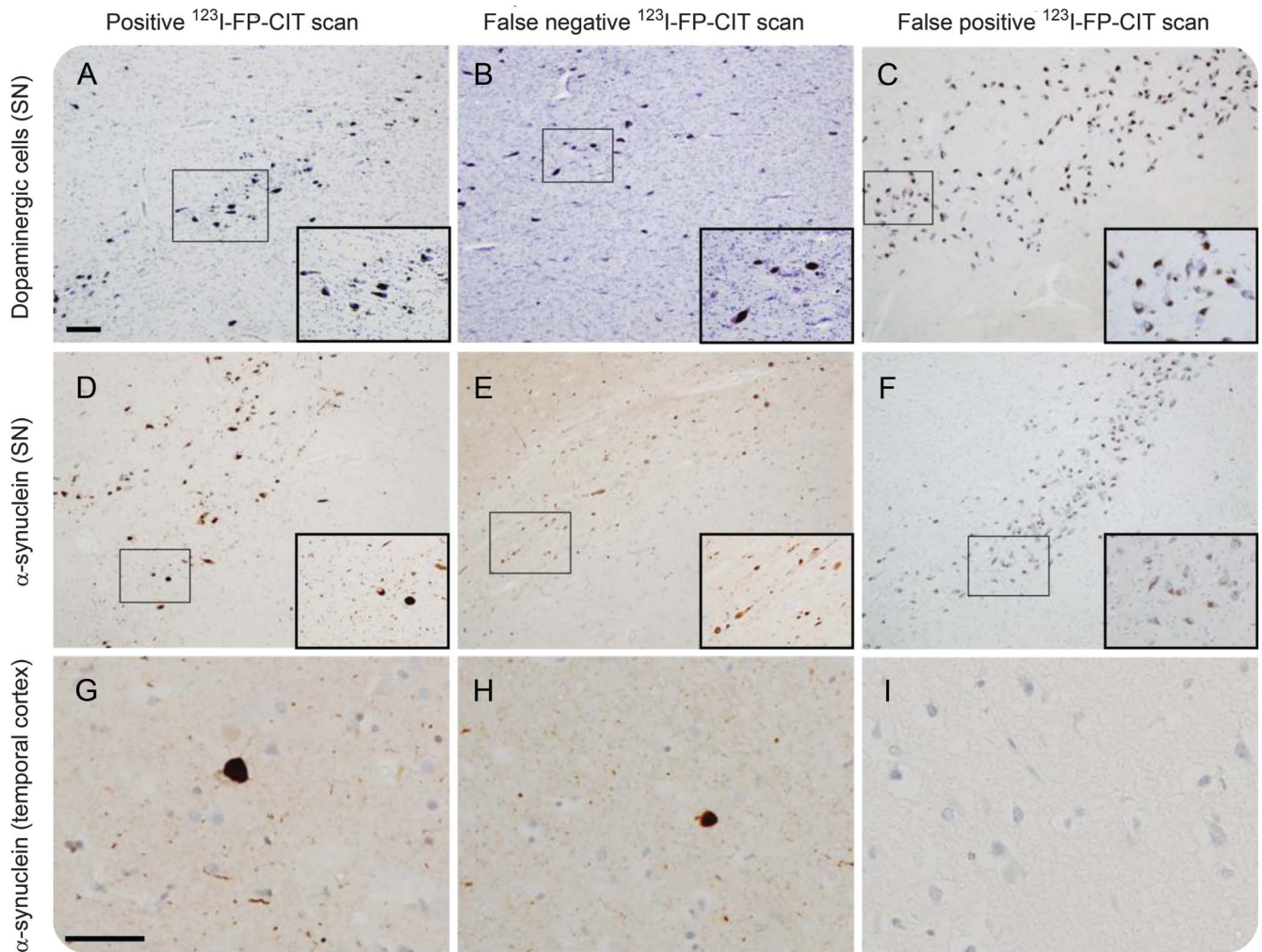
reported as abnormal by all blinded raters. One had parkinsonism (UPDRS score = 33) and cognitive fluctuations. Neuropathologically, this case had FTLD with no LBD or AD pathology, including no α -synuclein pathology in the substantia nigra but considerable reduction in overall nigral volume, which may have contributed to the parkinsonism and abnormal ¹²³I-FP-CIT. The other case (figure 2) had all 3 core features of DLB (UPDRS score = 13) and pathologically had AD. Again, there was no evidence of α -synuclein pathology in the substantia nigra or in the striatum, but there were abundant neurofibrillary

Table 2 Clinical features of study participants

	DLB (N = 33)	AD (N = 22)	
MMSE score at ¹²³ I-FP-CIT	17.9 (6.2)	19.3 (5.8)	t = 0.834, df 53, p = 0.41
MMSE score nearest death	11.9 (9.4)	14.0 (5.9)	U = 277, p = 0.57
CAMCOG score at ¹²³ I-FP-CIT	60.1 (20.2)	61.8 (18.8)	t = 0.317, df 49, p = 0.75
CAMCOG score nearest death	43.0 (28.8)	47.8 (21.6)	t = 0.255, df 3, p = 0.82
UPDRS score at ¹²³ I-FP-CIT	21.7 (13.5)	5.7 (5.7)	U = 100, p < 0.001
UPDRS score nearest death	31.8 (13.2)	15.0 (12.2)	t = 3.87, df 38, p < 0.001
Geriatric Depression Scale score at ¹²³ I-FP-CIT	4.1 (2.3)	2.8 (2.3)	t = 1.98, df 49, p = 0.05
Geriatric Depression Scale score nearest death	5.7 (4.0)	2.8 (3.0)	t = 2.42, df 33, p = 0.02
Core features of DLB, n (%)			
Fluctuating cognition	27 (82)	5 (23)	
Recurrent visual hallucinations	29 (88)	1 (5)	
Spontaneous parkinsonism	23 (70)	2 (9)	
Medication at baseline, n, %			
Antidementia	9 (27)	2 (9)	
Antiparkinsonian	8 (24)	0 (0)	
Antipsychotic	3 (9)	3 (14)	
Antidepressant	5 (15)	3 (14)	

Abbreviations: AD = Alzheimer disease; CAMCOG = Cambridge Cognitive Examination; DLB = dementia with Lewy bodies; ¹²³I-FP-CIT = ¹²³I-N-fluoropropyl-2b-carbomethoxy-3b-(4-iodophenyl) nortropane; MMSE = Mini-Mental State Examination; UPDRS = Unified Parkinson's Disease Rating Scale.

Figure 2 Photomicrographs of typical ^{123}I -FP-CIT-positive, false-negative, and false-positive cases



Photomicrographs illustrating a case with clinical dementia with Lewy bodies (DLB) and abnormal (positive) ^{123}I -N-fluoropropyl-2b-carbomethoxy-3b-(4-iodophenyl) nortropine (^{123}I -FP-CIT) scan with marked neuronal dopaminergic cell loss in the substantia nigra (SN) (A) and Lewy bodies in the SN (D) and temporal cortex (G). A false-negative ^{123}I -FP-CIT scan in an individual with clinical and pathologic dementia with Lewy bodies but only mild cell loss (B) and α -synuclein pathology of low severity in the SN (E) and moderate severity in the temporal cortex (H). A false-positive ^{123}I -FP-CIT scan in an individual with clinical and pathologic Alzheimer disease virtually without dopaminergic cell loss in the SN (C) and no α -synuclein pathology in the SN (F) or temporal cortex (I). Scale bar in panel A represents 200 μm and is valid for panels A-F; scale bar in panel G represents 50 μm and is valid for panels G-I. For the dopaminergic neurons, cresyl fast violet was used. For the α -synuclein immunohistochemistry, Novocastra antibody (1:200 dilution) was used with hematoxylin as counterstain.

tangles in the nigra without severe neuronal loss. Neither case had sufficient pathology in the striata to account for the abnormal scans. Both of these cases had severe dementia at the time of baseline assessment (Mini-Mental State Examination scores of 9 and 11) and died 1 and 2 years after study entry, thereby precluding repeated longitudinal assessments.

Of the 6 false-negative cases, 3 had a clinical baseline diagnosis of AD and had mixed LBD + AD pathology at autopsy. In all cases, at baseline, they had no parkinsonism, one had possible visual hallucinations only, and one had possible cognitive fluctuations. Neither of these symptoms was regarded by the consensus clinical raters as sufficient evidence of a symptom to support DLB, so both were classified

as pure AD cases clinically. They lived 6, 10, and 11 years after baseline assessment. During this time, one patient developed parkinsonism (last UPDRS score = 36) and complex visual hallucinations, and one developed parkinsonism (no UPDRS score recorded) in addition to the possible visual hallucinations. At autopsy, both showed moderate neuronal loss in the substantia nigra. The third patient developed mild parkinsonism (UPDRS score = 13), auditory hallucinations, and paranoid delusions, with mild nigral neuron loss at autopsy. The other 3 false-negative cases all met consensus criteria for probable DLB at the time of ^{123}I -FP-CIT, having complex visual hallucinations and marked cognitive fluctuations, and neuropathologically fulfilled the criteria for DLB,

with up to moderate nigral neuron loss at autopsy (see figure 2 for example). Of these cases, 2 had mild parkinsonism (UPDRS scores 15 and 17), while the third had moderate parkinsonism (UPDRS score = 28). Full neuropathology details of all cases are available in table e-1.

DISCUSSION In this large clinical/imaging/pathologic validation study, we found that ^{123}I -FP-CIT imaging had very good diagnostic accuracy (86%, sensitivity 80%, specificity 92%) for distinguishing DLB from AD. These figures are similar to those reported in clinical studies of ^{123}I -FP-CIT in DLB,⁹ in which a consensus diagnosis from a panel of 3 to 5 experts was used as the gold standard. This suggests that this method of validation of diagnosis, at a time when autopsy is not possible, is indeed valid.

The value of a test depends on its setting. For screening in large populations, a high sensitivity is crucial, but for specialist settings, for diagnostic tests such as ^{123}I -FP-CIT, it is more important to have a high specificity; a specificity of >80% has been suggested.²³ The 92% specificity achieved strongly supports the value of ^{123}I -FP-CIT imaging in distinguishing DLB from AD, but it is important to note that abnormal ^{123}I -FP-CIT imaging also occurs in FTL⁷ and other neurologic conditions such as progressive supranuclear palsy and CBD,⁸ so the accuracy reported here does not necessarily apply in other settings.

The value of a test also depends on how much it adds to clinical diagnosis. Here, the substantially larger specificity compared with clinical diagnosis (92% vs 72%) is important. However, such conclusions need to be interpreted in the context of the wide CIs for our findings. Furthermore, while ^{123}I -FP-CIT accuracy is consistent across centers, this is not the case for clinical diagnosis, especially for DLB; 4.2% of cases of DLB are diagnosed in the community vs 7.2% in secondary care,³ and our clinical diagnostic rates are higher than in other secondary care settings (8% vs 2%).²⁴ Thus, in our specialist centers, the additional value of ^{123}I -FP-CIT imaging for improving diagnosis is likely to be less than would be expected in other settings with lower diagnosis rates. However, decisions about using expensive imaging assessments in primary care need to be carefully balanced against the potential benefits.

It is important to note that the patients in this study were derived from secondary dementia services. Hence, our findings should not be generalized to settings such as movement disorder services or primary care. Patients were also assessed as having a neurodegenerative pattern of dementia, and we did not include patients with significant cerebrovascular disease. However, our findings are relevant for situations

in which ^{123}I -FP-CIT imaging is typically used, namely when clinical assessment indicates a neurodegenerative cause.

Two false-positive cases were clinically DLB. Both had moderate to severe dementia at baseline, perhaps limiting the accuracy of clinical assessment. In one case, FTL⁷ may have led to neuronal loss in the substantia nigra and explained the abnormal ^{123}I -FP-CIT, as has been reported previously.⁷ The other case provides no pathologic explanation for the abnormal ^{123}I -FP-CIT. Three false-negative cases had AD at the time of ^{123}I -FP-CIT but lived several years and developed symptoms characteristic of DLB and thus may have developed LBD later. The other 3 appear to be genuine false-negative cases whose LBD may have been predominantly limbic and neocortical at presentation, further suggested by at worst only moderate neuronal loss in the substantia nigra at autopsy. All 3 had prominent visual hallucinations and cognitive fluctuations. Thus, 3 of 33 (10%) of the DLB cases could not have been diagnosed with ^{123}I -FP-CIT at the time of the initial assessment. The presence of DLB without detectable dopaminergic deficits on ^{123}I -FP-CIT imaging is consistent with previous reports showing synucleinopathy in limbic and neocortical areas (most frequently in the amygdala and olfactory lobe) when only little or no such pathology is found in the substantia nigra.^{25,26} It is important to remember that while the high specificity of ^{123}I -FP-CIT means an abnormal scan strongly supports DLB, a normal scan occurs in a proportion of people with DLB, here 10%, and does not exclude DLB. ^{123}I -FP-CIT imaging is not a direct marker of synuclein pathology but only a measure of its effect on neurons, which can be damaged by other pathology, as occurred here in the false-positive case with FTL⁷.

The clinical accuracy of our study does not fully reflect present practice. Most cases were diagnosed with the use of 1996 rather than 2005 criteria. All patients with DLB with RBD had an abnormal ^{123}I -FP-CIT scan and LBD pathology, which, although numbers are small, is consistent with reports that the inclusion of RBD improves the diagnosis of DLB.²⁷ This suggests that if we had missed such patients, then their inclusion might have further improved the sensitivity. A more important limitation of our study is the gap between ^{123}I -FP-CIT and autopsy, which was greater in those with AD. Previous autopsy studies have reported similar findings, i.e., that patients with DLB come to autopsy more quickly,²⁷ consistent with their higher mortality.²⁸ However, such a difference would seem more likely to reduce the diagnostic accuracy of ^{123}I -FP-CIT. It is estimated that it takes at least 5 years to develop LBD sufficient to cause clinical symptoms,²⁹ and longer-lived patients with AD might develop DLB and thus

become false-negative scan patients. Indeed, this is what appears to have happened with some study patients. On the other hand, longer-lived patients with DLB with abnormal scans who developed AD would remain true-positive patients. We should add that this study has important strengths: patients were recruited from experienced DLB centers by clinicians skilled in clinical diagnosis, ¹²³I-FP-CIT imaging, and neuropathology, and we have a sample size much larger than in the 2 small previous reports (whose patients were also included in this study).

We report the largest autopsy study examining the neuropathologic diagnoses in patients who had undergone ¹²³I-FP-CIT imaging in the context of dementia. Although our findings need replication in other centers and in future prospective studies, ¹²³I-FP-CIT is a valid biomarker of DLB with high sensitivity and specificity. This strongly supports the use of ¹²³I-FP-CIT dopaminergic imaging in the diagnosis of DLB.

AUTHOR CONTRIBUTIONS

A.J.T. designed the study, conducted the analyses, and wrote the first draft and the revised versions of the paper. J.A. contributed to the design, data acquisition, and critical revisions. S.J.C. contributed to the conception, data analysis, and critical revisions. J.T.O., I.M., and D.B. obtained funding for the Newcastle clinical study and acquired data and contributed to the critical revisions for this paper. R.W., L.L., and D.J.L. acquired data and contributed to the critical revisions. Z.W. obtained funding for the London clinical study and contributed to the study design and longitudinal data collection and to the revision of the intellectual content of the paper. All authors have given final approval to the submitted manuscript and agree to be accountable for its accuracy and integrity.

ACKNOWLEDGEMENT

We thank Durval Costa for undertaking and rating scans and Lauren Walker for providing the images for figure 2.

STUDY FUNDING

This research was supported by the National Institute for Health Research Newcastle Biomedical Research Unit in Lewy Body Dementia based at Newcastle Upon Tyne Hospitals NHS Foundation Trust and Newcastle University. The views expressed are those of the authors and not necessarily those of the NHS, the National Institute for Health Research, or the Department of Health. Tissue for this study was provided by the Newcastle Brain Tissue Resource, which is funded in part by a grant from the UK Medical Research Council (G0400074) and in part by Brains for Dementia research, a joint venture between Alzheimer's Society and Alzheimer's Research UK.

DISCLOSURE

A.J. Thomas has received support from GE Healthcare, the manufacturer of ¹²³I-FP-CIT (DaTSCAN), for investigator-led research. J. Attems and S.J. Colloby report no disclosures relevant to the manuscript. J.T. O'Brien reports personal fees from GE Healthcare, personal fees from TauRx, personal fees from Cytos, grants and personal fees from Avid/Lilly, and personal fees from Axona. I. McKeith reports grants and personal fees from GE Healthcare during the conduct of the study. R. Walker and L. Lee report no disclosures relevant to the manuscript. D. Burn reports consultancy fees from BIAL and Profile Pharma and lecture fees from Acadia Pharmaceuticals. D.J. Lett reports no disclosures relevant to the manuscript. Z. Walker has received funding for travel, consultancy and speaker fees, and research support from GE Healthcare,

consultancy fees from Bayer Healthcare, and research support from Lundbeck. Go to Neurology.org for full disclosures.

Received April 19, 2016. Accepted in final form October 13, 2016.

REFERENCES

- Dubois B, Feldman HH, Jacova C, et al. Revising the definition of Alzheimer's disease: a new lexicon. *Lancet Neurol* 2010;9:1118–1127.
- Sperling RA, Aisen PS, Beckett LA, et al. Toward defining the preclinical stages of Alzheimer's disease: recommendations from the National Institute on Aging-Alzheimer's Association workgroups on diagnostic guidelines for Alzheimer's disease. *Alzheimers Demen* 2011;7:280–292.
- Vann Jones SA, O'Brien JT. The prevalence and incidence of dementia with Lewy bodies: a systematic review of population and clinical studies. *Psychol Med* 2014;44:673–683.
- McKeith IG, Dickson DW, Lowe J, et al. Diagnosis and management of dementia with Lewy bodies: third report of the DLB consortium. *Neurology* 2005;65:1863–1872.
- Piggott MA, Marshall EF, Thomas N, et al. Striatal dopaminergic markers in dementia with Lewy bodies, Alzheimer's and Parkinson's diseases: rostrocaudal distribution. *Brain* 1999;122(pt 8):1449–1468.
- Plotkin M, Amthauer H, Klaffke S, et al. Combined ¹²³I-FP-CIT and ¹²³I-IBZM SPECT for the diagnosis of parkinsonian syndromes: study on 72 patients. *J Neural Transm* 2005;112:677–692.
- Morgan S, Kemp P, Booij J, et al. Differentiation of frontotemporal dementia from dementia with Lewy bodies using FP-CIT SPECT. *J Neurol Neurosurg Psychiatry* 2012;83:1063–1070.
- Walker Z, Costa DC, Walker RW, et al. Differentiation of dementia with Lewy bodies from Alzheimer's disease using a dopaminergic presynaptic ligand. *J Neurol Neurosurg Psychiatry* 2002;73:134–140.
- O'Brien JT, Oertel WH, McKeith IG, et al. Is ioflupane I123 injection diagnostically effective in patients with movement disorders and dementia? Pooled analysis of four clinical trials. *BMJ Open* 2014;4:e005122.
- McKeith I, O'Brien J, Walker Z, et al. Sensitivity and specificity of dopamine transporter imaging with ¹²³I-FP-CIT SPECT in dementia with Lewy bodies: a phase III, multicentre study. *Lancet Neurol* 2007;6:305–313.
- Walker Z, Jaros E, Walker RW, et al. Dementia with Lewy bodies: a comparison of clinical diagnosis, FP-CIT single photon emission computed tomography imaging and autopsy. *J Neurol Neurosurg Psychiatry* 2007;78:1176–1181.
- Colloby SJ, McParland S, O'Brien JT, Attems J. Neuropathological correlates of dopaminergic imaging in Alzheimer's disease and Lewy body dementias. *Brain* 2012;135(pt 9):2798–2808.
- McKeith IG, Galasko D, Kosaka K, et al. Consensus guidelines for the clinical and pathologic diagnosis of dementia with Lewy bodies (DLB): report of the Consortium on DLB International Workshop. *Neurology* 1996;47:1113–1124.
- McKhann G, Drachman D, Folstein M, Katzman R, Price D, Stadlan EM. Clinical diagnosis of Alzheimer's disease: report of the NINCDS-ADRDA work group under the auspices of Department of Health and Human Services Task Force on Alzheimer's disease. *Neurology* 1984;34:939–944.

15. Folstein MF, Folstein SE, McHugh PR. "Mini-Mental State": a practical method for grading the cognitive state of patients for the clinician. *J Psychiatr Res* 1975;12:189–198.
16. Roth M, Tym E, Mountjoy CQ, et al. CAMDEX: a standardised instrument for the diagnosis of mental disorder in the elderly with special reference to the early detection of dementia. *Br J Psychiatry* 1986;149:698–709.
17. Fahn S, Elton RL, Members UP. Unified Parkinson's Disease Rating Scale. In: Fahn SER, Marsden CD, Goldstein M, Calne DB, editors. *Recent Developments in Parkinson's Disease*. Florham Park: MacMillan Healthcare Information; 1987:153–163.
18. O'Brien JT, Colloby S, Fenwick J, et al. Dopamine transporter loss visualized with FP-CIT SPECT in the differential diagnosis of dementia with Lewy bodies. *Arch Neurol* 2004;61:919–925.
19. Walker Z, Costa DC, Janssen AG, Walker RW, Livingstone G, Katona CL. Dementia with Lewy bodies: a study of post-synaptic dopaminergic receptors with iodine-123 iodobenzamide single-photon emission tomography. *Eur J Nucl Med* 1997;24:609–614.
20. Walker L, McAleese KE, Thomas AJ, et al. Neuropathologically mixed Alzheimer's and Lewy body disease: burden of pathological protein aggregates differs between clinical phenotypes. *Acta Neuropathol* 2015;129:729–748.
21. Braak H, Braak E. Neuropathological staging of Alzheimer-related changes. *Acta Neuropathol* 1991;82:239–259.
22. Mirra SS, Heyman A, McKeel D, et al. The Consortium to Establish a Registry for Alzheimer's Disease (CERAD), part II: standardization of the neuropathologic assessment of Alzheimer's disease. *Neurology* 1991;41:479–486.
23. Postuma RB, Berg D, Stern M, et al. MDS clinical diagnostic criteria for Parkinson's disease. *Movement Disord* 2015;30:1591–1601.
24. Kane J, Barker S, Surendranathan A, et al. Clinical diagnosis of dementia with Lewy bodies in routine secondary care clinical services: results from the DIAMOND-Lewy study. *Am J Neurodegenerative Dis* 2015;4(suppl 1):178.
25. Beach TG, Adler CH, Lue L, et al. Unified staging system for Lewy body disorders: correlation with nigrostriatal degeneration, cognitive impairment and motor dysfunction. *Acta Neuropathol* 2009;117:613–634.
26. Zaccai J, Brayne C, McKeith I, Matthews F, Ince PG; MRC Cognitive Function, Ageing Neuropathology Study. Patterns and stages of alpha-synucleinopathy: relevance in a population-based cohort. *Neurology* 2008;70:1042–1048.
27. Ferman TJ, Boeve BF, Smith GE, et al. Inclusion of RBD improves the diagnostic classification of dementia with Lewy bodies. *Neurology* 2011;77:875–882.
28. Garcia-Portacek S, Farahmand B, Kareholt I, Religa D, Cuadrado ML, Eriksdotter M. Mortality risk after dementia diagnosis by dementia type and underlying factors: a cohort of 15,209 patients based on the Swedish Dementia Registry. *J Alzheimers Dis* 2014;41:467–477.
29. McCann H, Stevens CH, Cartwright H, Halliday GM. Alpha-synucleinopathy phenotypes. *Parkinsonism Relat Disor* 2014;20(suppl 1):S62–S67.



NEW!

Innovations in Care Delivery – A curated collection featuring advances in neurologic care

This *Neurology*[®] special interest Web site provides a forum to explore new care models from multiple disciplines, access to sources on health care innovation, and expert opinions on current research from *Neurology* journals. Curated by Brian C. Callaghan, MD, and Kevin A. Kerber, MD.

Stay ahead of the curve at Neurology.org/innovations.

Neurology[®]

Autopsy validation of ¹²³I-FP-CIT dopaminergic neuroimaging for the diagnosis of DLB

Alan J. Thomas, Johannes Attems, Sean J. Colloby, et al.
Neurology 2017;88:276-283 Published Online before print December 9, 2016
DOI 10.1212/WNL.0000000000003512

This information is current as of December 9, 2016

Updated Information & Services	including high resolution figures, can be found at: http://www.neurology.org/content/88/3/276.full.html
Supplementary Material	Supplementary material can be found at: http://www.neurology.org/content/suppl/2016/12/09/WNL.0000000000003512.DC1
References	This article cites 28 articles, 11 of which you can access for free at: http://www.neurology.org/content/88/3/276.full.html##ref-list-1
Citations	This article has been cited by 2 HighWire-hosted articles: http://www.neurology.org/content/88/3/276.full.html##otherarticles
Subspecialty Collections	This article, along with others on similar topics, appears in the following collection(s): Alzheimer's disease http://www.neurology.org/cgi/collection/alzheimers_disease Dementia with Lewy bodies http://www.neurology.org/cgi/collection/dementia_with_lewy_bodies SPECT http://www.neurology.org/cgi/collection/spect
Permissions & Licensing	Information about reproducing this article in parts (figures, tables) or in its entirety can be found online at: http://www.neurology.org/misc/about.xhtml#permissions
Reprints	Information about ordering reprints can be found online: http://www.neurology.org/misc/addir.xhtml#reprintsus

Neurology® is the official journal of the American Academy of Neurology. Published continuously since 1951, it is now a weekly with 48 issues per year. Copyright © 2016 The Author(s). Published by Wolters Kluwer Health, Inc. on behalf of the American Academy of Neurology. All rights reserved. Print ISSN: 0028-3878. Online ISSN: 1526-632X.

